AfraTafreeh.com

NUTRITION IN SURGERY

Introduction 00:00:06

- How to assess the nutrition in surgical patient
  1. MAC
  2. Biceps/ triceps skin fold thickness
  3. Body mass index
  4. S. albumin (**best indicator**)
- BMI
- Weight loss < 6 months
- Acute disease defects

Tool known as MUST
↓
Malnutrition Universal Screening Tool
↓
Score of 0, 1, 2 is given

Artificial nutrition

- When patient goes for > 7 days of inadequate intake
  - Enteral → given through GIT
  - Parenteral → Given through veins

Enteral nutrition

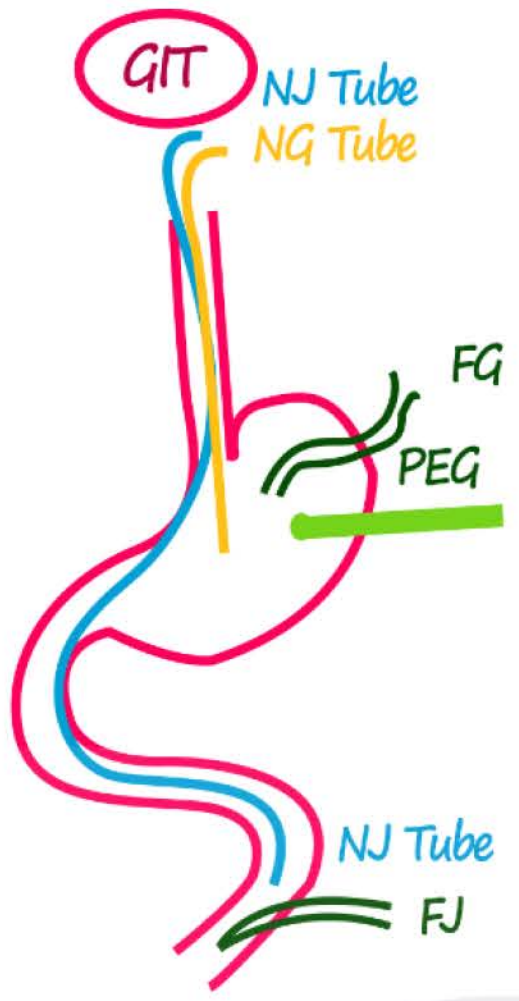

1. Nasogastric tube
2. Nasojejunal tube
3. Percutaneous endoscopic gastrostomy tube
4. Feeding gastrostomy
5. Feeding jejunostomy

(4–5: Surgical method)

Parenteral

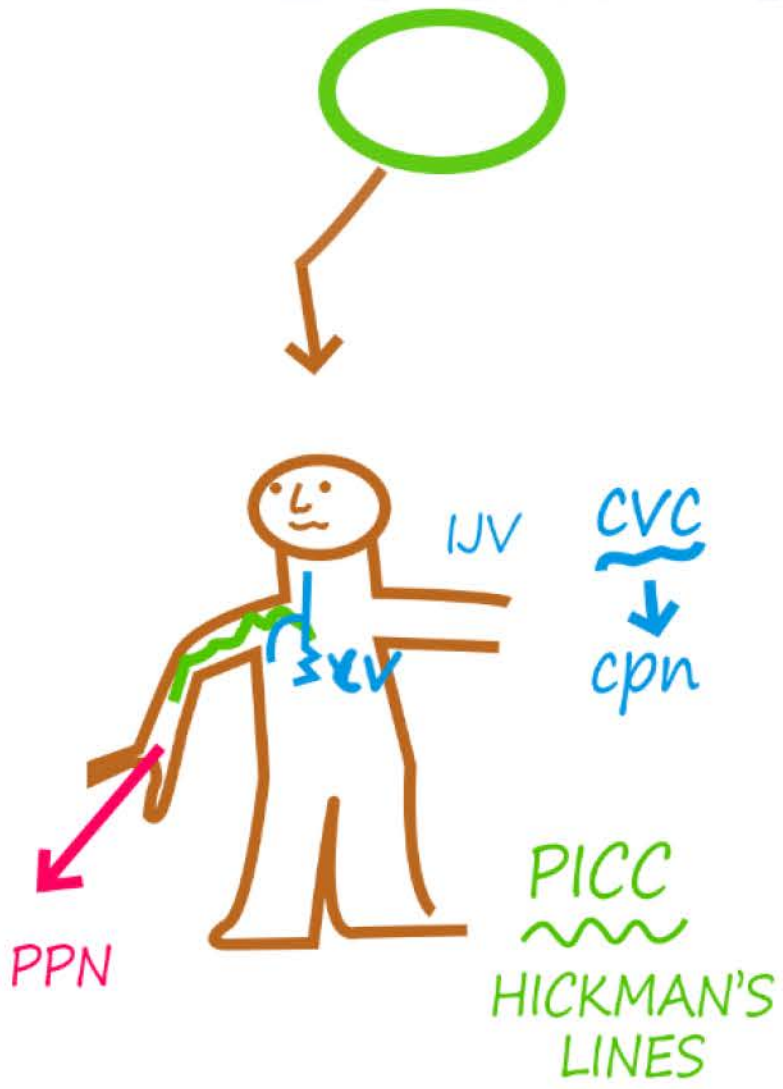

AfraTafreeh.com

- < 2 weeks – peripheral parenteral nutrition (PPN)
- Central parenteral nutrition
  - Internal jugular vein
  - Subclavian vein
- Long canula is inserted into the central vein → peripherally inserted central vein catheter (PICC) → Hickmann line

Enteral nutrition 00:07:56

Nasogastric feeding

- Given through NG tube – Ryles tube
- Common length used in adults – 110-130cm

- NEX Rule: Take a tape and measure from tip of nose to ear and ear to xiphisternum
- NEMU rule: In pediatric children, it is measured from nose to ear and from ear to midpoint between xiphisternum and umbilicus

Insertion of ryle's tube

- Sitting with neck flexed position → Ideal
- If patient is unable to sit → Fowler's position

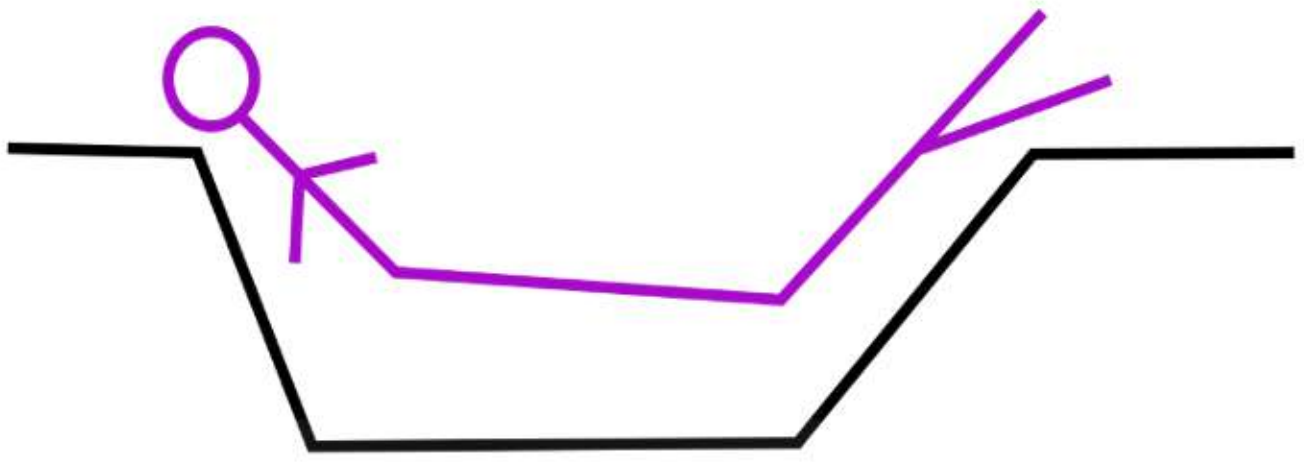

- We have to confirm whether the tip is in stomach
  - Bell of steth
  - Aspirate bile/ gastric juice
  - X-ray abdomen
- Ideal method: - Aspirate and check pH of fluid → Acidic
- Problems
  1. Microaspiration → to avoid use ryle's tube < 4weeks
  2. Blockage
  3. Displaced

Nasojejunal tube

- Intervention
  - Radiologist → Fluoroscopy
  - MGE → Endoscopy
- Invasive procedure

TUTORIALS
LOGIN FOR SUCCESS
AiraTalreen.com

AfraTafreeh.com

- Commercially available tube: - FREKA tube → 240cm length

Indications for shifting from nasogastric tube → Nasojejunal tube

- Comatosed/ unconscious → aspirate contents → NJ tube
- Nutrition for > 4-6 weeks → PEG Tube

↓

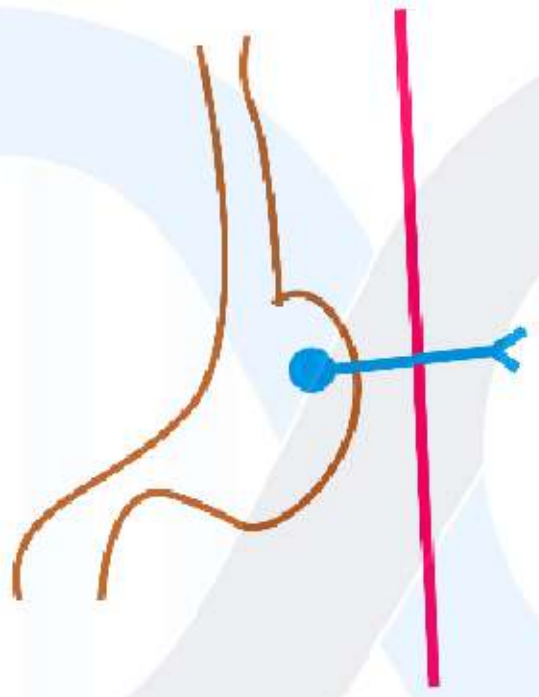

- Gastrostomy tube is inserted directly into stomach through percutaneous endoscopic guidance
- 2 techniques
  - Pull through
  - Direct stab technique
- Problem with PEG tube
  1. Peritubal leakage
  2. Skin excoriation
  3. Blockage, displacement

Surgically done techniques

- Feeding gastrostomy

- Feeding jejunostomy

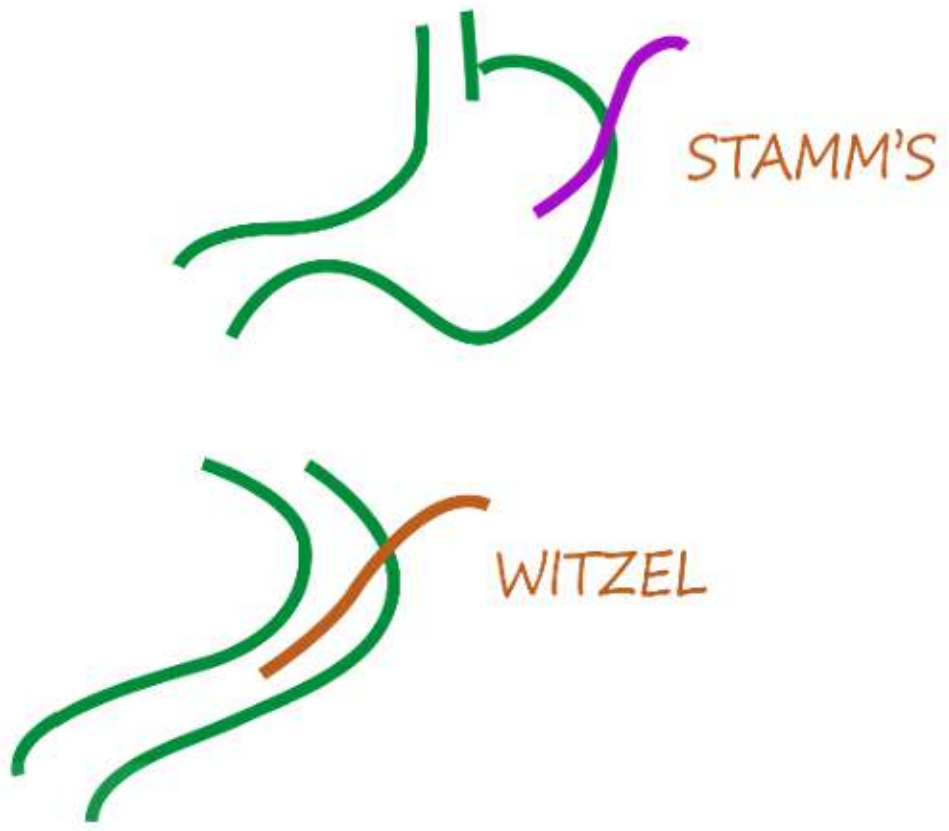

- 2 methods
  - Stamm's technique (direct entry)
  - Witzel technique (Tunnel technique)
- Used when patient required nutrition for >6weeks

AfraTafreeh.com

NG tube → < 4weeks
NJ tube → <4 weeks (unconscious patient)
PEG → >4-6 weeks
FG, FJ → > 6 weeks

- **Recent protocol for feeding in acute pancreatitis**

↓
NG feeding
↓
If patient does not tolerate/ have edema
↓
NJ feeding

AfraTafreeh.com

Complications of enteral nutrition 00:23:14

1. Most common are tube related
   - Blockage
   - Displacement
2. Osmotic diarrhea
3. Electrolyte disturbances
4. Refeeding syndrome

Parenteral nutrition 00:24:54

Parenteral nutrition

If GIT is not good
↓
1. High output EC fistula
2. Crohn's disease (severe)
3. Radiation enteritis
4. Duodenal fistulas
5. Short bowel syndrome

BP is not good
↓
1. Shock
   ↓
   If food given through GIT during shock
   - Mesenteric Ischemia
2. Severe sepsis
3. Severe acute pancreatitis

TUTORIALS
LOGIN FOR SUCCESS

Venous access

Peripheral vein
(< 2 weeks)

CVC
IJV
Subclavian vein

PICC
Hickmann line
↓

If used for more duration ↓ Thrombophlebitis	Femoral vein -Most common and best → **SCV** -In a trauma patient → **IJV**	Major advantages ↓ Catheter related Sepsis less common

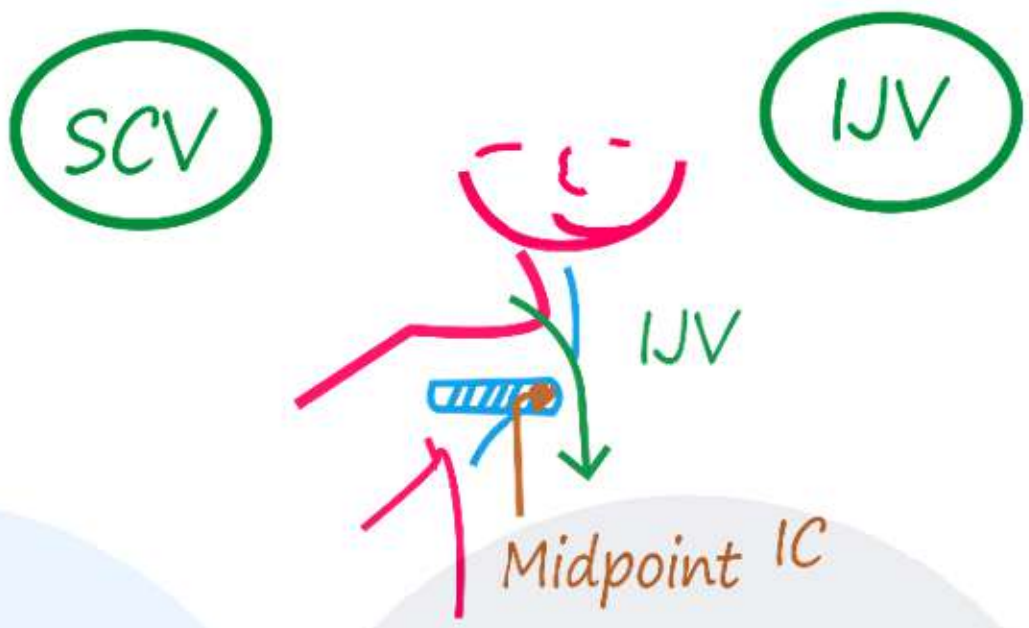

- IJV line: Between 2 heads of sternocleidomastoid
- SCV:
  - Given infraclavicular at midpoint of Clavicle
  - Ultrasound guidance is used
  - Complication: - Pneumothorax
  - Major advantage: - More comfortable for patient

SCV approach is best when

- Tip of catheter should be in SVC
- X-ray chest is advised to ensure -
  1. Tip in SVC
  2. To confirm no pneumothorax

TUTORIALS LOGIN FOR SUCCESS AfraTafreen.com

AfraTafreeh.com

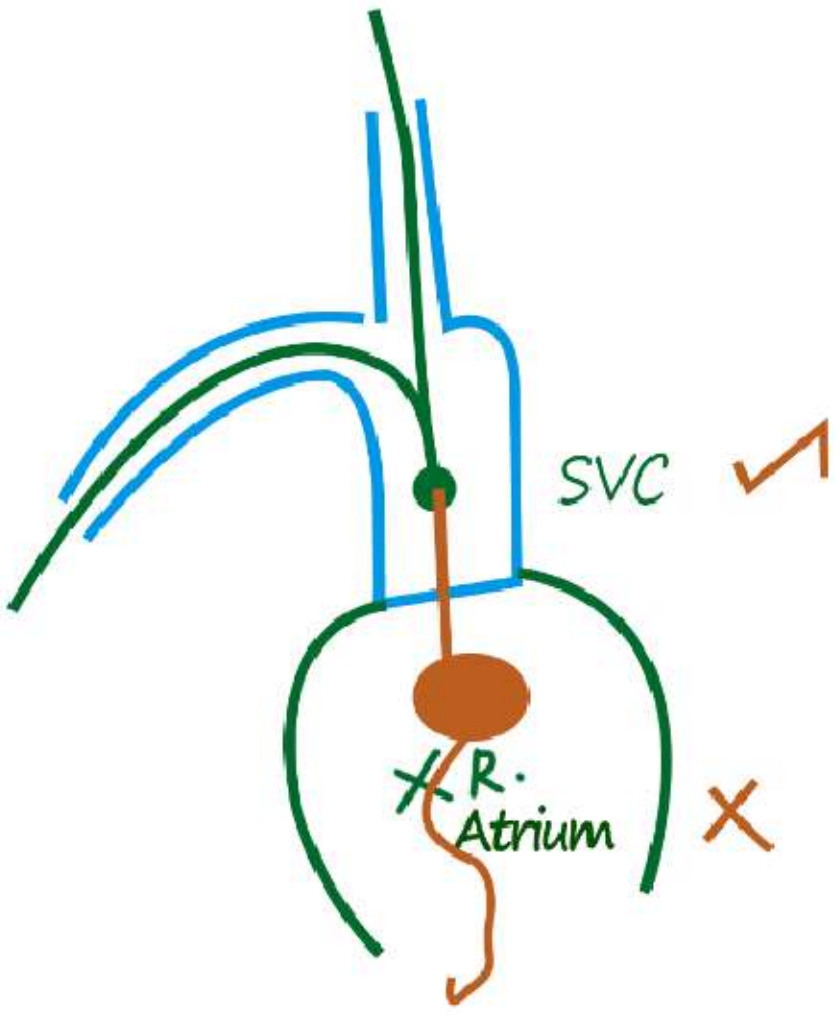

Parenteral nutrition bag 00:34:48

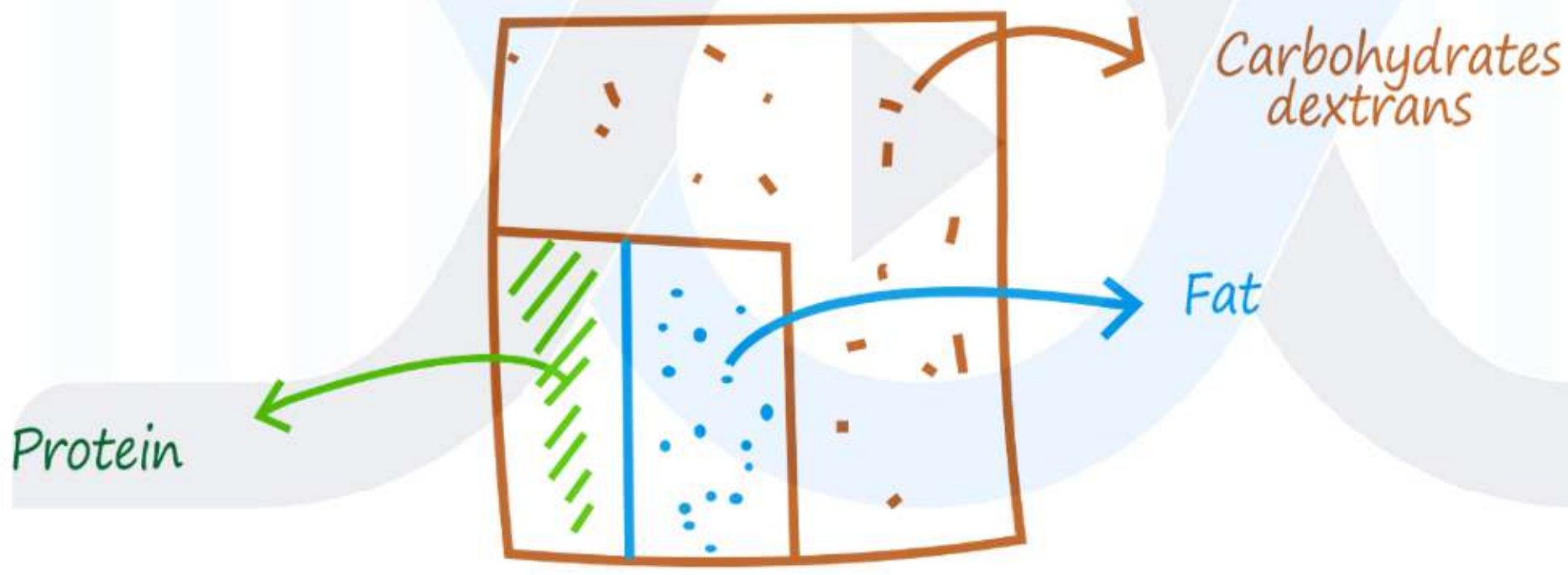

Components

- Carbohydrates – 60%
- Lipids – 20%
- Protein – 20%
- Ratio – 60:20:20
- Essential minerals and vitamins are also present

– 1gm carbohydrate – 3.4 kcal

– 1gm protein – 4 kcal

– 1gm fat – 9 kcal

+

Glycerol – 10 kcal

- Patient having high carbohydrate TPN increases osmolarity
  - Liberate ↑ CO_2 → **RQ > 1**
- Low osmolarity TPN
  ↓
  - Low carbohydrate
  - Low CO_2
  - RQ < 1
  - Can be used in patients of pulmonary failure

Fat free TPN 00:39:18

- Contains only carbohydrates (75%) and Proteins (25%) in ratio of 3:1
- Fat free TPN is good for Liver failure patients
- Indicated in Hepatic steatosis
  - Fatty liver
  - Jaundice
- Long term TPN (stable patient)
  ↓
  Monitor →
  - Weekly twice
    i. Blood glucose
    ii. Sr. electrolytes
  - Weekly once
    i. RFT
    ii. LFT

AfraTafreeh.com
TUTORIALS LOGIN FOR SUCCESS

AfraTafreeh.com

- When patient develops catheter related sepsis → catheter to be changed
- It is confirmed by clinical features

Clinical features

- Fever ⊕, local redness ⊕

↓

- Blood c/s
- Blood aspirate c/s

} Both same organism – catheter related sepsis

- Blood c/s
- Tip c/s

} Both same organism – catheter related sepsis

Complications of TPN 00:45:06

- Most common → catheter related complications

↓

Sepsis (infection)

Blockage

- Catheter insertion complication
  - Pneumothorax
  - Cardiac tamponade
- Catheter related thrombus
- Puncture of DNS/NS bottle is not done as it results in **air embolism**

Metabolic complications:

1. Fatty acid deficiency
2. Liver dysfunction

DX TUTORIALS LOGIN FOR SUCCESS

3.Glucose imbalance

4.Neutrophil dysfunction

5.Vitamin/ mineral deficiency

6.Fluid overload

Electrolyte disturbances

- Na^+
- K^+
- Ca^+ — increase or decrease hyperphosphatemia
- Mg^+
- PO4 decreases (Hyperphosphatemia is not seen)
- Can develop **Hyperchloremic metabolic acidosis**

Refeeding syndrome Q 00:51:36

AfraTafreeh.com

- Feed after prolonged fasting

↓

Increase blood sugar

↓

Insulin → K^+ → hypokalemia

Phosphate

Calcium ↓ **(PCM decrease)**

Magnesium

- Most common: TPN > EN
- Prevented by slow refeeding and correct electrolytes
- Complications:
  - CCF
  - Arrhythmias

AfraTafreeh.com

Other MCQ's

- Hyperglycemia → 1st sign of sepsis
- Fatty liver (Hepatic steatosis)

↓

Jaundice

↓

Liver failure

- Stop TPN temporarily till LFT are normal
- Restart with fat free TPN

- Excess fat →

1. Hypercholesterolemia
2. Liver failure
3. Lipoprotein x formation
4. Hypersensitivity

Therefore, Fat free TPN is preferred in 3:1 ratio

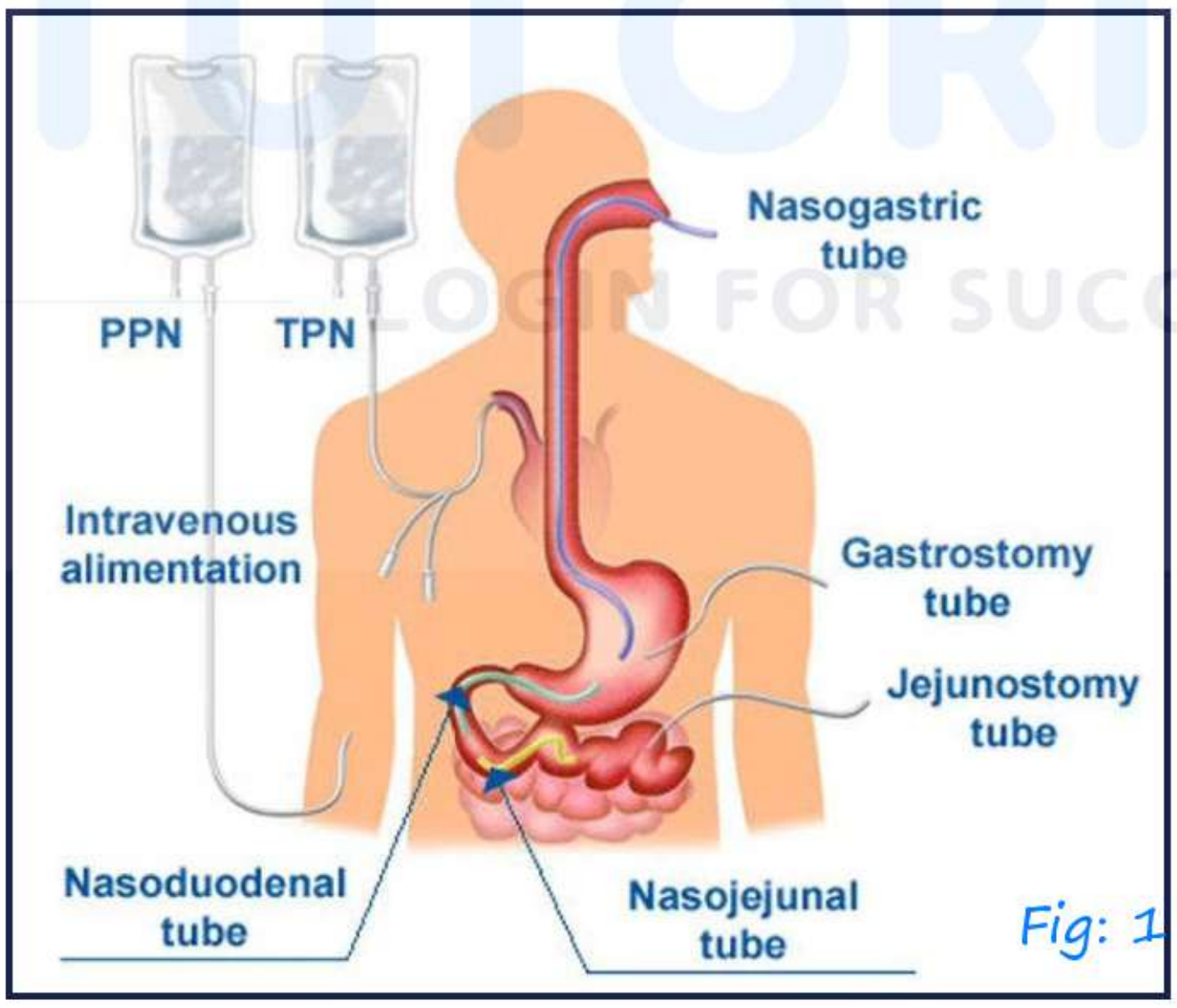

Fig: 1

TUTORIALS
LOGIN FOR SUCCESS

Ryles tube Fig: 2

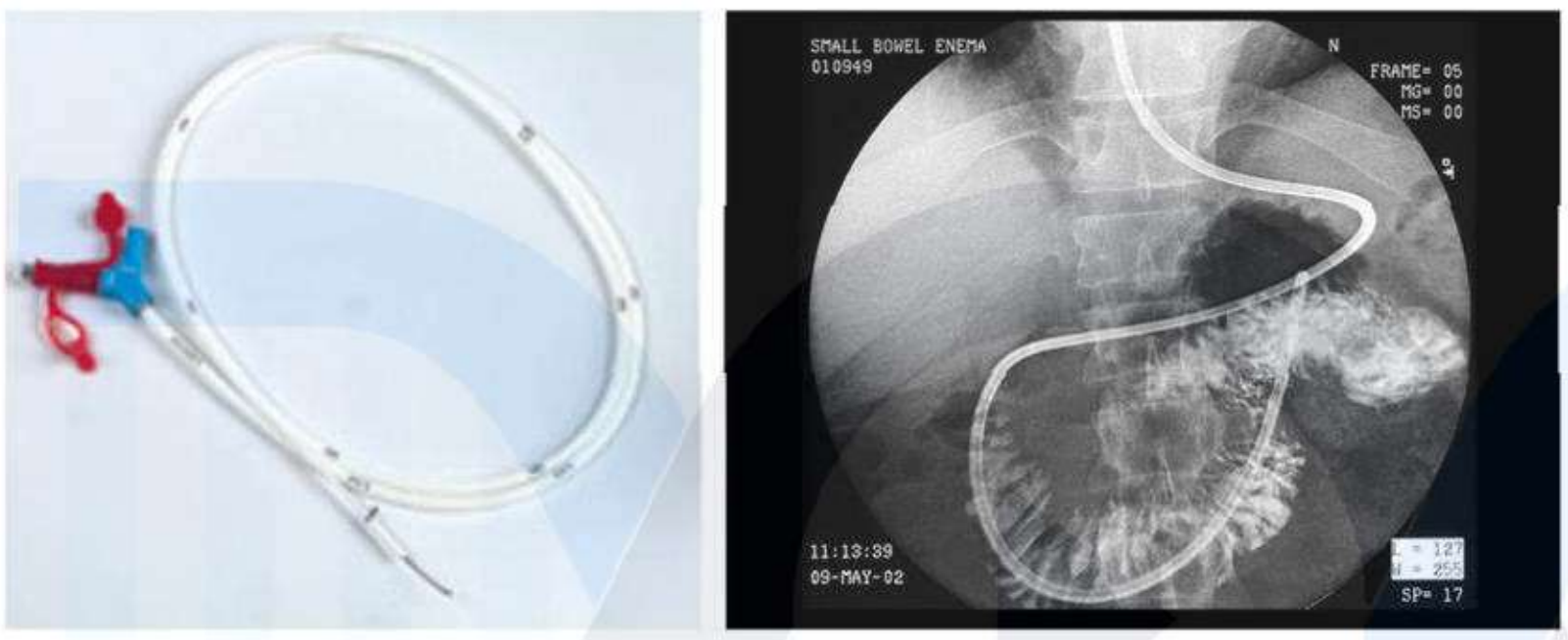

FREKA tube Fig: 3

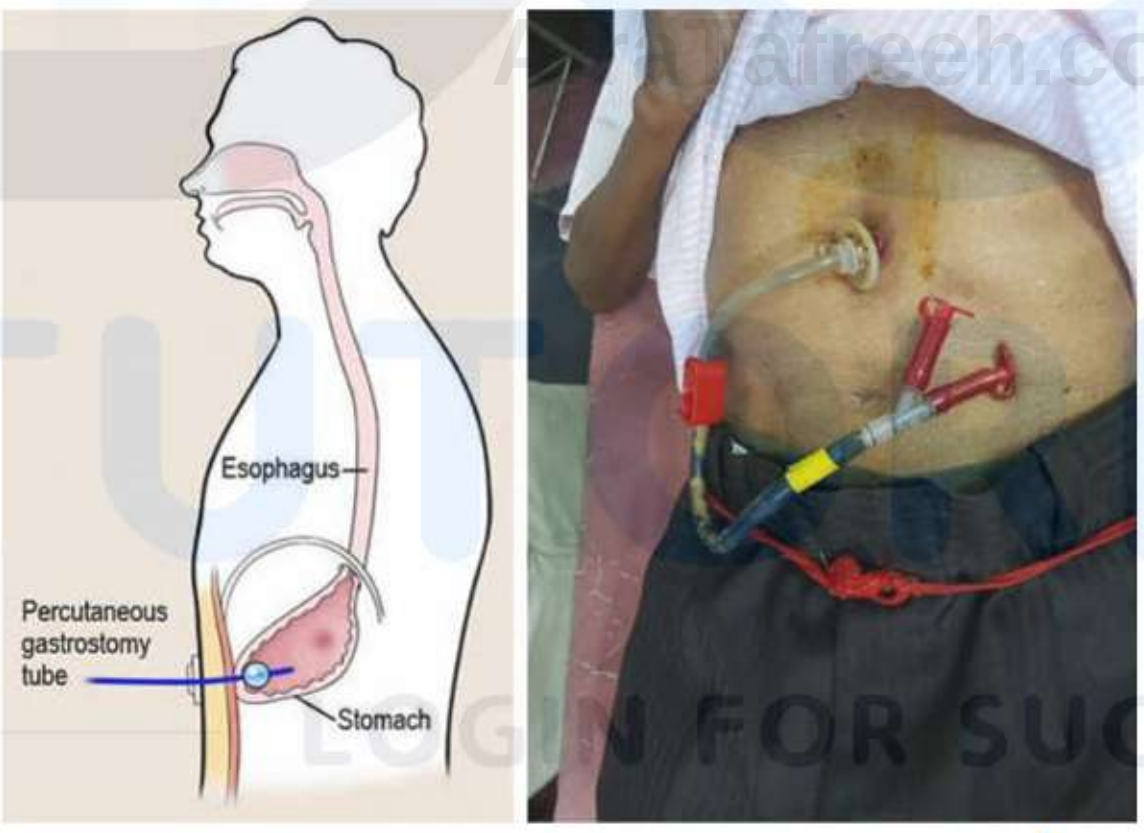

PEG tube Fig: 4

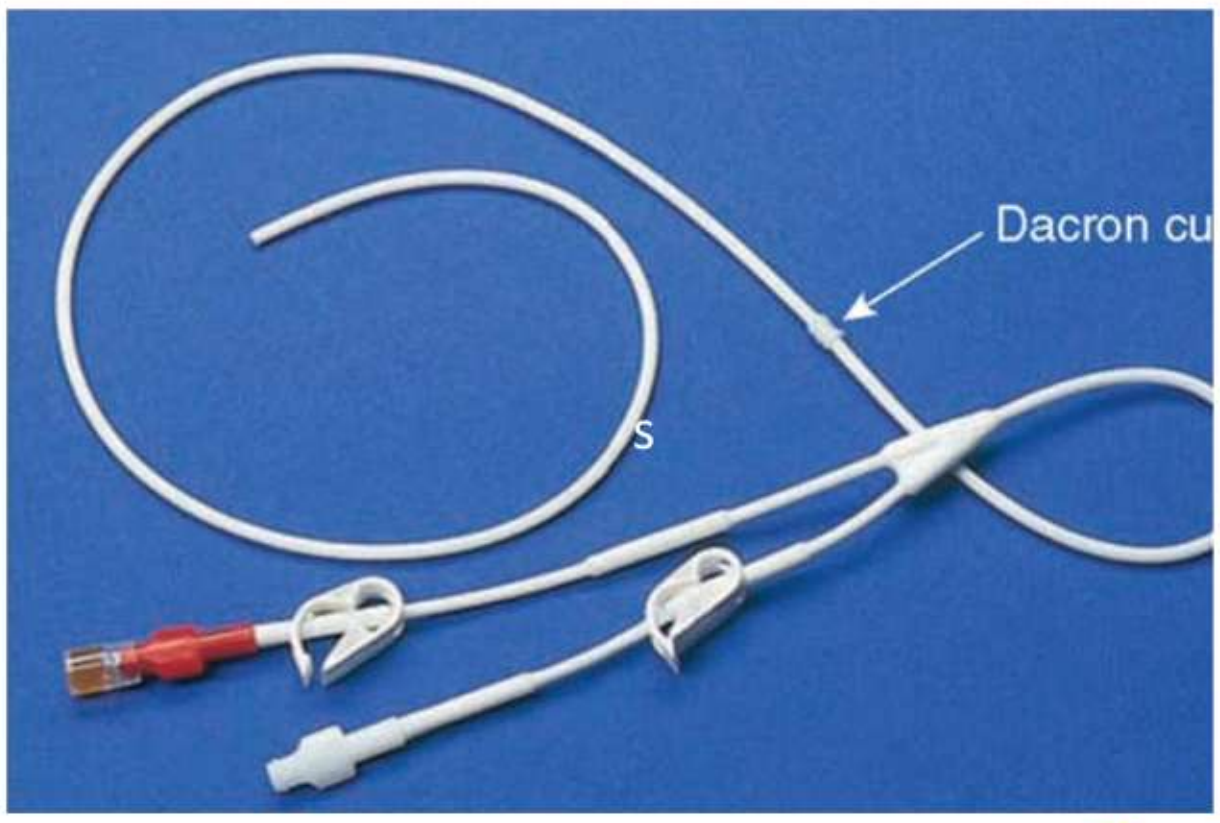

PICC-Hickmann line Fig: 5

TUTORIALS
LOGIN FOR SUCCESS

AfraTafreeh.com

Fig: 6



central venous catheter

TPN Bag

Fig: 7

TUTORIALS
LOGIN FOR SUCCESS

SHOCK

Basics of shock 00:00:04

- Most common cause of death in a surgical patient – shock



AfraTafreeh.com
TUTORIALS
LOGIN FOR SUCCESS

i. Cardiac output – Amount of blood pumped out from heart.

ii. Peripheral arterial resistance – oxygen consumed in periphery and blood will flow through veins & veins also exhibit

↓

Blood returning to heart

↓

Sample of returning blood taken

↓

Mixed venous oxygen saturation (MVOs) measured

↓

Normal value – 50-70%

- MVOS - % of oxygen in returning blood.

AfraTafreeh.com

Hemorrhagic shock vs Septic shock 00:04:16

Hemorrhagic shock	Septic shock
• Decreases blood volume	• No decrease in blood volume • Blood is pooled into vessels
• CO → Decreases	• Increases
• Peripheral arterial resistance ↓ Vasoconstriction ↓ Cold peripheries	• Peripheral vasodilatation ↓ Warm peripheries
• Oxygen consumption is high	• Poor/decreased O2 consumption • Anaerobic metabolism ↓ Lactic acidosis
• Venous resistance is low	• Low
• MVOS – <50% (50–70%)	• **>70%** Q NEET PG 2019

Types of shock 00:10:40

- Hypovolemic shock (Hemorrhagic shock)
- Cardiogenic shock
- Neurogenic
- Anaphylactic shock (Distributive shock)
- Septic stock (Distributive shock)

Features	Hemorrhagic	Cardiogenic
PR	↑	↑/↓
SBP	↓	↓
CO	↓	↓
PVR	↑	↑
	Cold peripheries	

Features	Neurogenic	Anaphylactic	Septic
PR	↓	↑↑	↑
SBP	↓	↓	↑/↓
CO	↓	↓	↑
PVR	↓	↓	↓
	Peripheral vasodilatation → warm peripheries		

AfraTafreeh.com
TUTORIALS
LOGIN FOR SUCCESS

Compensated shock → in which the body adapts

- Kidney, Lung, Brain } adequate blood supply
- Blood flow to skin, muscles and GIT are compromised
- **Tachycardia**
- **Cold peripheries**

AfraTafreeh.com

Decompensated shock

- Human can tolerate up to 15% blood loss
- Blood loss is more → decrease BP

  Increase PR

  Results in organ failure (MODS)

  - ARDS
  - Acute renal failure
  - Liver failure
  - Coagulopathy

Resuscitation parameters 00:19:20

- Parameters monitored
  - Urine output
  - CVP
  - Sr. Lactate
- Urine output
  - Best clinical monitor to know adequate resuscitation
  - Best clinical indicator of tissue perfusion
  - Best clinical parameter
- CVP
  - Best to calculate drug dosage and fluid input
  - Not accurate for cardiogenic and septic shock
- Sr. lactate
  - Best lab value to know tissue perfusion

    ↓

    <2 mmol/L – good resuscitation

    >5mmol/L- bad resuscitation

End point of resuscitation can be found out by

1.Systemic perfusion → by measuring – s. lactate
Base deficit
MVOS

2.GIT perfusion → by measuring gastric mucosal pH
(assess mucosal flow) Gut tonometry
Sublingual capnometry
Laser flow doplometry

3.Brain perfusion → near infrared spectroscopy

4.Muscle perfusion → near infrared spectroscopy

Indexes to monitor

- Shock index: – $\frac{HR}{SBP}$ → >0.9 – Decompensated shock

  Example: $\frac{90}{90}$ =1

- Modified shock index (MSI) = HR/ MAP

  ↓ (best) Most sensitive index

  $$MAP = \frac{SP + 2\,(DP)}{3}$$

  Low MSI – Hyperdynarnic state

  High MSI – hypodynamic state → bad

- ROPE = $\frac{PR}{PP}$ > 3 → Decompensated shock

  ↓

  P. Rate over pulse pressure evaluation

AfraTafreeh.com
TUTORIALS
LOGIN FOR SUCCESS

AfraTafreeh.com

Hemorrhagic shock 00:31:33

- Can be divided into 4 classes based on percentage of blood loss
- Class
  - I – 0-15%, <750ml → compensated shock
  - II – 15-30%, 750-1500 ml
  - III – 30-40%, 1500-2000 ml
  - II – >40%, >2000 ml
- Class I → example blood donation

	Class I	Class II	Class III	Class IV
% Blood loss	0-15%	15-30%	30-40%	>40%
CNS	Slight anxiety	Anxiety increase	Mild confusion	Confused lethargic comatosed
PR<100/minute	100/minute	100-120 / minute	120-140 / minute	>140/minute
SBP	N	N	↓	↓↓
PP (SBP-DBP)	N	↓	↓	↓
RR	N	↑	↑	↑
U.O	>30ml/hour	20-30 ml/hour	<20ml/hour	Anuria
Base deficit	0 to -2	-2 to -6	-6 to -10	>-10

PP decrease in class II shock

↓

750-1500ml blood lost

↓

Adrenaline, Nor adrenaline increase → increase PR

↓

Peripheral vasoconstriction

Increase venous return

↓

C.O maintained

SBP maintained

PR= SBP – DBP

(N– increase)

decrease

Cold extremities

↓

Increase diastolic pressure

AfraTafreeh.com
TUTORIALS
LOGIN FOR SUCCESS

Management of hemorrhagic shock

- First line: - fluids
  - Class I: (>750 ml) – oral fluids, IV crystalloids
  - Class II: IV crystalloids
  - Class III: crystalloids + blood
  - Class IV: massive blood transfusion

CRASH II trial

- Injection tranexamic acid 1 gm given when
  - SBP <90mmHs (or) stat dose
  - PR >110/minute

↓

AfraTafreeh.com

8 hours: - another dose as infusion

Fluids

↓

Crystalloids are fluid of choice

↓

7.5% HTS

↓

NS/RL

1 litre fluid according to ATLS → 2 green venflon

Blood

↓

1. No time for cross matching

↓

O negative

2. Males, post reproductive ♀

↓

O positive

3. Ideal: - crossmatch transfer

Resuscitation ATLS

Balanced resuscitation

↓

To avoid coagulopathy, transfuse blood in the ratio 1:1:1

↓

1 unit of PRBC
1 unit of plasma
1 unit of platelet

Permissible hypotension

↓

Permissible BP:70-90 mm Hg

↓

Increase – rebleed
Decrease – brain ischemia

TUTORIALS LOGIN FOR SUCCESS

Cannulas 00:52:24

- Short, wide bore cannulas are used (VENFLANS)

↓

2 cannulas

Green – 18G → 90ml/min

- Color of cannulas
  - 16 G – grey – rapid infusion – 200ml/minutes
  - 18 G – green – adults – 90ml/minutes
  - 16 G – pink – adults
  - 16 G – blue – pediatric
  - 16 G – yellow – neonatal
- 14G – orange canula -270 ml/minute
- Maximum fluid can be infused – grey (200ml/minute)

Septic shock 00:57:58

- Sepsis → SIRS + Known source of infection
- Septic shock → sepsis + hypotension

AfraTafreeh.com

SIRS

- Defined by 2 or more of the following

  Love – leucocyte count: - WBC < 4000 (or) > 12000

  T – temperature: P - $<35^\circ$c (or) $>38^\circ$c

  H – HR: - >90/minutes

  R – RR: - >20/minutes

  $PaCo_2$ < 32 mm Hg
- ≥2 organ failed – MODS

  SOFA – sequential organ failure assessment

  qSOFA – quick sequential organ failure assessment
- qSOFA

  - R -RR > 22/ minutes -1

AfraTafreeh.com

- C -confused state -1
- B -SBP <100mmHG – 1
- Score ≥2: - increase mortality by 10%

Surviving sepsis guidelines 01:04:50

- IV fluids
- Vasopressors → **nor adrenaline**

3 hours of admission

↓

1. Sr. lactate
2. Blood c/s before antibiotics
3. Broad spectrum antibiotics
4. 30ml/kg of crystalloid for hypotension

   s. lactate ≥4mmol/l

6 hours of admission

↓

1. MAP ≥ 65mmHg (Fluid → vasopressors)
2. CVP: - 8-12 mmHg
3. MVOS: - 65%
4. SVC O2: - 70%

Saturation

↓

Remeasure sr. lactate

↓

Good resuscitation: - < 2mmol/L

Bad resuscitation: - >5mmol/L

TUTORIALS LOGIN FOR SUCCESS

Metabolic response to trauma and surgery

01:10:40

Ebb and flow model

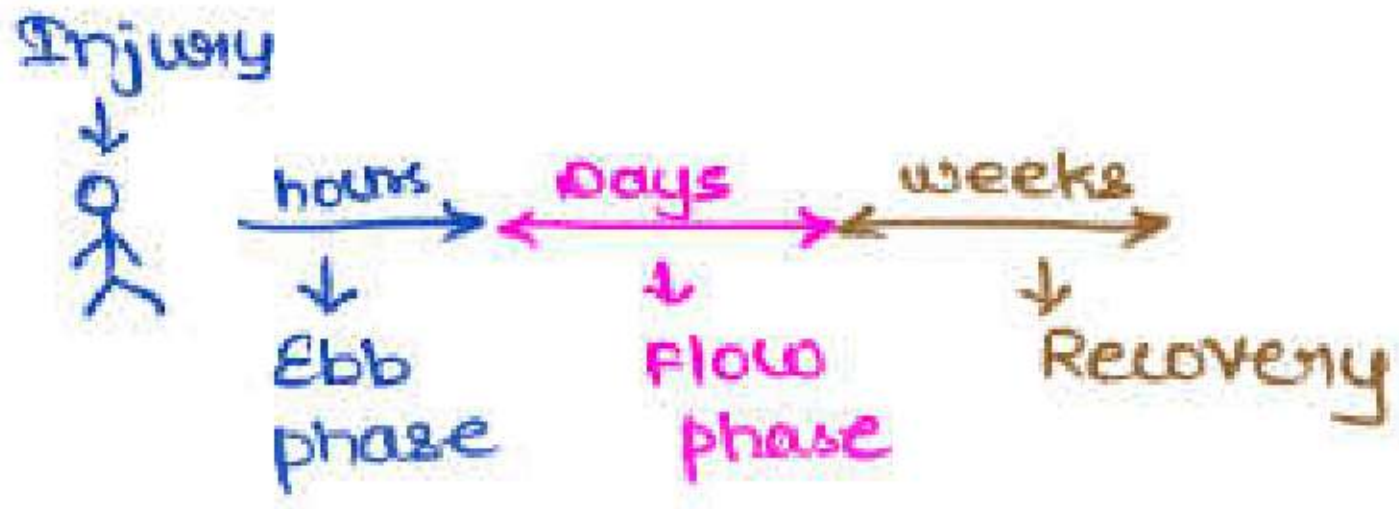

Ebb phase: – < 24 hours

Maintenance of blood volume

Catecholamines

↓

Preserve energy store

AfraTafreeh.com
TUTORIALS
LOGIN FOR SUCCESS

- Physiological
  - Decrease BMR
  - Decrease temperature
  - Decrease O2 consumption
  - Increase Co2
  - Increase HR
  - Increase Gluconeogenesis
  - Increase WBC
  - Vasoconstriction
- Hormones
  - Catecholamines
  - Cortisol
  - Aldosterone

AfraTafreeh.com

Flow phase → 3-10 days

↓

Catabolic phase

- Physiological
  - increase BMR
  - increase temperature
  - increase O_2 consumption
  - Increase urinary N_2 excretion
    Negative nitrogen balance
  - Increase acute phase proteins
    ↓
  - Increase GRP
  - Increase Fibrinogen
- Hormones
  - Insulin
  - Glucagon
  - Cortisol
  - Catecholamines
  - IL – 1
  - IL – 6
  - TNF α
  - Insulin resistance + → uncontrolled hyperglycemia

Anabolic phase → 10-60 days

positive nitrogen balance

Hormones

↓

Growth hormone

IGF

BLOOD TRANFUSION

Donors 00:00:25

- Amount of blood donated in one sitting – 450ml
- A person can donate blood for 3 times in a year.
- Blood is stored in a bag with preservative

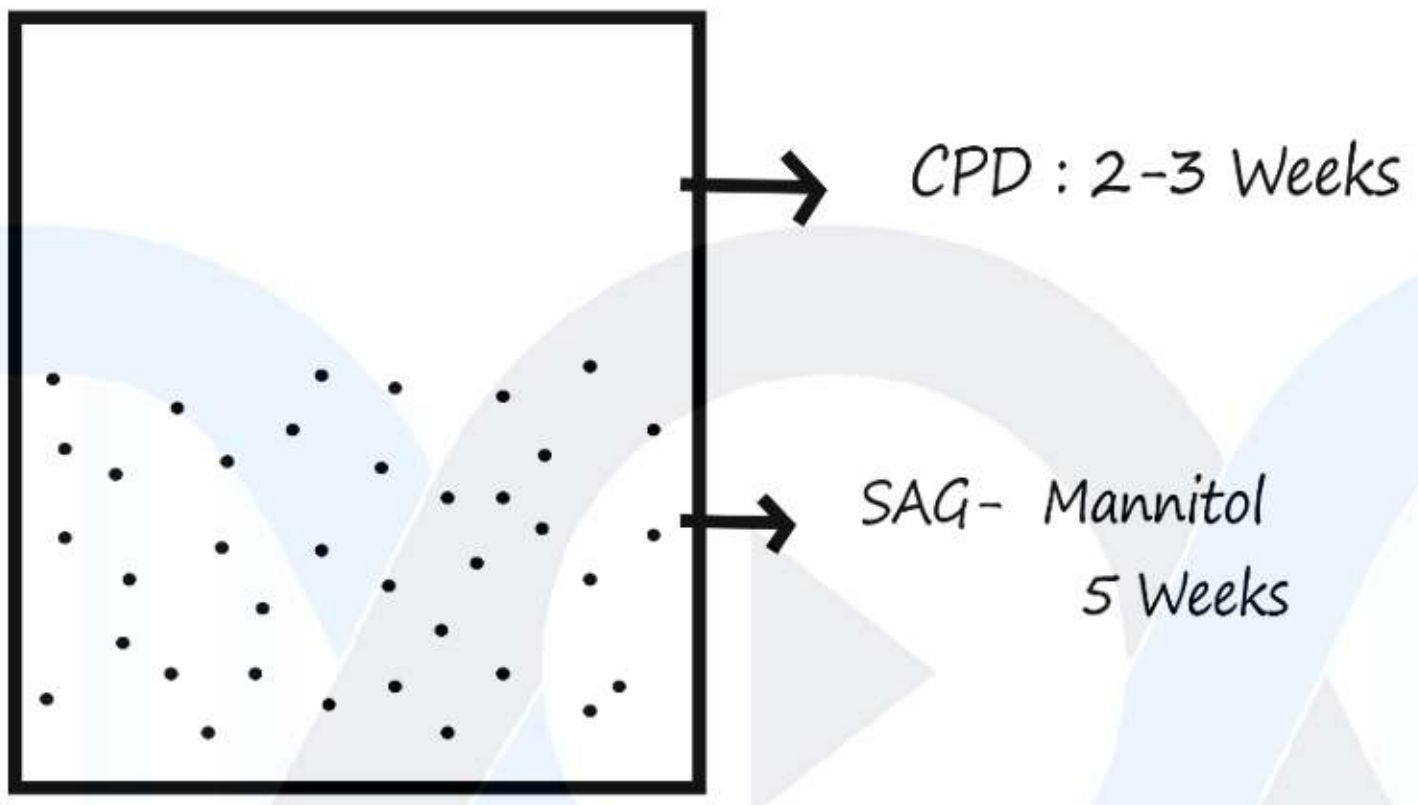

- Blood given by donor is screened for infection

  ↓

  - HIV I & II
  - HBV
  - HCV
  - Syphilis
- In India, we screen for malaria.
- In western countries, we screen for Creutzfeldt Jacob disease.

Storage 00:03:16

- Blood is stored in fridge at 2-6°C.

AfraTafreeh.com

Components 00:04:30

- Whole blood is deficient of platelets
- In 24hrs, WBC and platelets become nonfunctional
- Components

1.Packed RBC → Hematocrit: 50-70%

→ 330 ml

→ Used in patients in CCF

→ Increases Hb/dl

→ Increases 3% of hematocrit

→ Lack coagulation factors

2.FFP (Fresh Frozen Plasma) → Rich in coagulation factors 2,7,9,10

→ Factor 8 decreases

→ used to reverse coagulopathy

- Warfarin toxicity
- Obstructive jaundice (Increases PT)

→ Stored at -40°C for 2 years

→ 250 ml

→ ABO matching done

→ Rh compatible is not needed

→ When Rh positive is given to Rh negative → Rh(D) immunoglobulin should be given

3.Cryoprecipitate: Increases factor 8 and Fibrinogen

→ Mainly used for hemophilia patients

→ 15ml stored at -30°C for 2 years.

4.Platelets → Used within 5 days

→ Stored at 24°C

→ Used in dengue fever thrombocytopenia

Component	Duration	Temperature
• Platelets	5 days	20-24°C
• PRBC • WBC	5 weeks (35 days)	2-6°
• FFP	2 years	-40°
• CP	2 years	-30°

5.Prothrombin complex concentrate

- Rich in factors 2,7,9,10

AfraTafreeh.com

Complications of Blood Transfusion 00:12:36

Complication of blood transfusion

- **Immune mediated**
  - **Acute**
    1. Hemolytic reaction
    2. Febrile non hemolytic rection
    3. Anaphylaxis
    4. Urticaria
    5. TRALI → most common with FFP
  - **Delayed**
    1. Hemolysis
    2. GVHD
    3. Post transfusion purpura
- **Non-Immune mediated**

TUTORIALS LOGIN FOR SUCCESS

AfraTafreeh.com

1.Hemolytic Reaction

↓

1st sign - itching (awake patient)

1st sign – Bleeding from operating site (patient under Anesthesia)

↓

Hypotension, Hematuria

↓

Renal Failure

2.Febrile non hemolytic reaction

↓

- Most common complication of blood transfusion
- Prevented by using leucocyte reduction filter.

Non-Immune Method

Acute	**Delayed**
↓	↓
1.Sepsis	1.Iron overload
2.Fluid overload	2.Infections
3.Iron overload	↓
4.Air embolism	- HIV I & II
5.Hyperkalemia	- HBV
6.Hypocalcemia	- HCV
7. Metabolic alkalosis	- Malaria

TUTORIALS LOGIN FOR SUCCESS

Stored blood

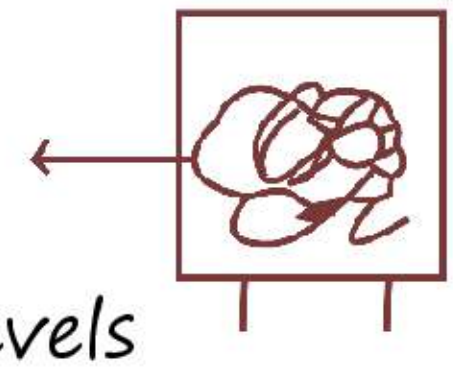

- pH decreases
- Increases K^+ levels
- Decreases 2,3 DPG
  ↓
  Decreases O_2 carrying capacity
- Decreases platelets → function lost
- Decreases factors 8 → 10-20% available
- In stored blood, factor VII & IX are stable

Massive Blood Transfusion 00:21:23

- $\geq$ 10 units of PRBC transfused
  (or)
  Equal volume is replaced

AfraTafreeh.com

Complications

Electrolyte disturbances
↓
- ↓ hypocalcemia
- ↓ hypokalemia
- ↑ hyperkalemia
- Metabolic alkalosis (most common) (Na Citrate → Na HCO_3^-
- Metabolic acidosis

- Decreases 2,3 DPG → decreases O_2 carrying capacity
- Hypothermia
- Iron overload
- Dilutional thrombocytopenia → Coagulopathy

AfraTafreeh.com

Autologous blood transfusion

- It is a phenomenon in which can own blood is stored for 3 weeks and used.

Preoperative blood transfusion protocol (Bailey)

- **> 8gm – not used**
- **6-8 gm – not beneficial unless there is any bleeding**
- **<6 gm - Beneficial**

TUTORIALS
LOGIN FOR SUCCESS

SUTURES, NEEDLES, BLADES

Introduction 00:00:06

- First used: - ant



Sutures

Non absorbable		Absorbable	
Natural	Synthetic	Natural	Synthetic
Silk	Polypropylene	Catgut (sheep's small intestine)	Polyglycolic A
Nylon	Polyester		Polyglactic A
Steel	Poly butester		Polyglycaprone
	Poly tetra fluro-ethylene		Polydioxanone (PDS)
	Dacron		

AfraTafreeh.com

Properties 00:05:06

1.Tensile strength: -

- Force required to break the suture
- Depends upon
  - Thickness of suture
  - Nature of material
  - In vivo absorption
- As the thickness increase, tensile strength increases

Tensile ∝ thickness

2.Elasticity: - memory ⊕ → prolene

3.Monofilament vs multifilament material

Monofilament ↓	Multifilament ↓
•Risk of infection decrease	•Risk of infection increase
•Poor knotting property	•good knotting property
•Example: prolene	•braided material
	•Example: vicryl (polyglactic acid)

4.Size of suture

10'0, 8"0, 6'0, 4'0, 3'0, 2'0, 0, 1

↓

As the size increases, thickness increases ascending order

- 10'0
  8'0 — vascular, ophthalmic surgeries
  6'0
- 1'0 → abdominal closure, tendon repair
- Highest tensile strength – 1'0
- Lowest tensile strength – 10'0

5.Absorbable

- Catgut → enzymatic degradation
  Highest reaction is seen in catgut while absorption
  → banned in UK
- Polyglactic acid → hydrolysis

Catgut 00:14:02

- Derived from S.I submucosa of sheep
- Stored in Isopropyl alcohol
- Brown in color
- 2 types

Plain
↓
- Absorbed in 10 days
- Tensile strength→ 7-10 days

chromic
↓
- Absorbed in 60-90 days
- Tensile strength → 21-28 days

- Application: - subcutaneous sutures, muscle approximation, circumcision
- Major problem is → it has got highest enzymatic reaction

AfraTafreeh.com

Vicryl 00:18:38

- Polyglactic acid
- Known as work horse material
- Violet in color
- Absorbable
- Made of co-polymer of galactic acid ⊕ lactic acid
- Multifilament → risk of infection ⊕
- **Absorbed in 60-90 days**

Types

- Vicryl plus: + antibiotic coated → TRICHLOSAN
- Vicryl rapide: - absorption takes in 10 days
- Barbed vicryl: - does not need knot cosmetic surgery – face lift surgery, pain ⊕⊕

DOC TUTORIALS LOGIN FOR SUCCESS

Applications

- Bowel anastomosis 3-0
- Bile duct anastomosis 4-0
- Muscle closures
- Subcutaneous sutures
- Subcuticular skin sutures
- Vicryl meshes (Peritoneal side mesh - Inlay mesh)

Moncryl

- White vicryl
- Poliglycaprone
- Absorption 90-120 days
- Complete hydrolysis
- Monofilament
- Used for subcuticular sutures

Polydioxanone (PDS) 00:25:54

- Longest absorption period → 180 days
- Monofilament
- Blue in color
- Classically used in linea alba closures
- Tracheobronchial repair
- Pancreatic duct repair/ anastomosis
- Gets absorbed by hydrolysis

AmrafreeH.com
TUTORIALS
LOGIN FOR SUCCESS

Prolene 00:27:38

- Also known as polypropylene
- Non absorbable
- Blue in color
- Monofilament
- Classical property – memory+

  (Monofilament, memory+) → More knots needed (6-7 knots)
- Applications
  - Hernia repair
  - Tendon repair
  - Fascia repair

AfraTafreeh.com

- Linea alba closure
- Pancreatic duct anastomosis
- Vascular anastomosis → 3-0, 4-0, 6-0
  (Aorta repair → 3-0; femoral artery repair → 4-0; ophthalmic sutures → 6-0)
- Diaphragmatic repair
- Meshes are made with prolene → white in color

• 3-0 prolene is used for aorta repair
• 4-0 prolene is used for femoral artery repair
• 6-0 prolene is used for ophthalmic surgery

Silk 00:31:54

• Multifilament material
• Derived from silk worm
• High risk of infection
• Though comes under classification of non - absorbable, but it is slowly absorbed in 2 years
• Skin closure
• Lambert sutures

TUTORIALS
LOGIN FOR SUCCESS

PTFE, Dacron } Vascular graft materials

Dacron ↓ ideal for Aorta graft

Needles 00:34:22

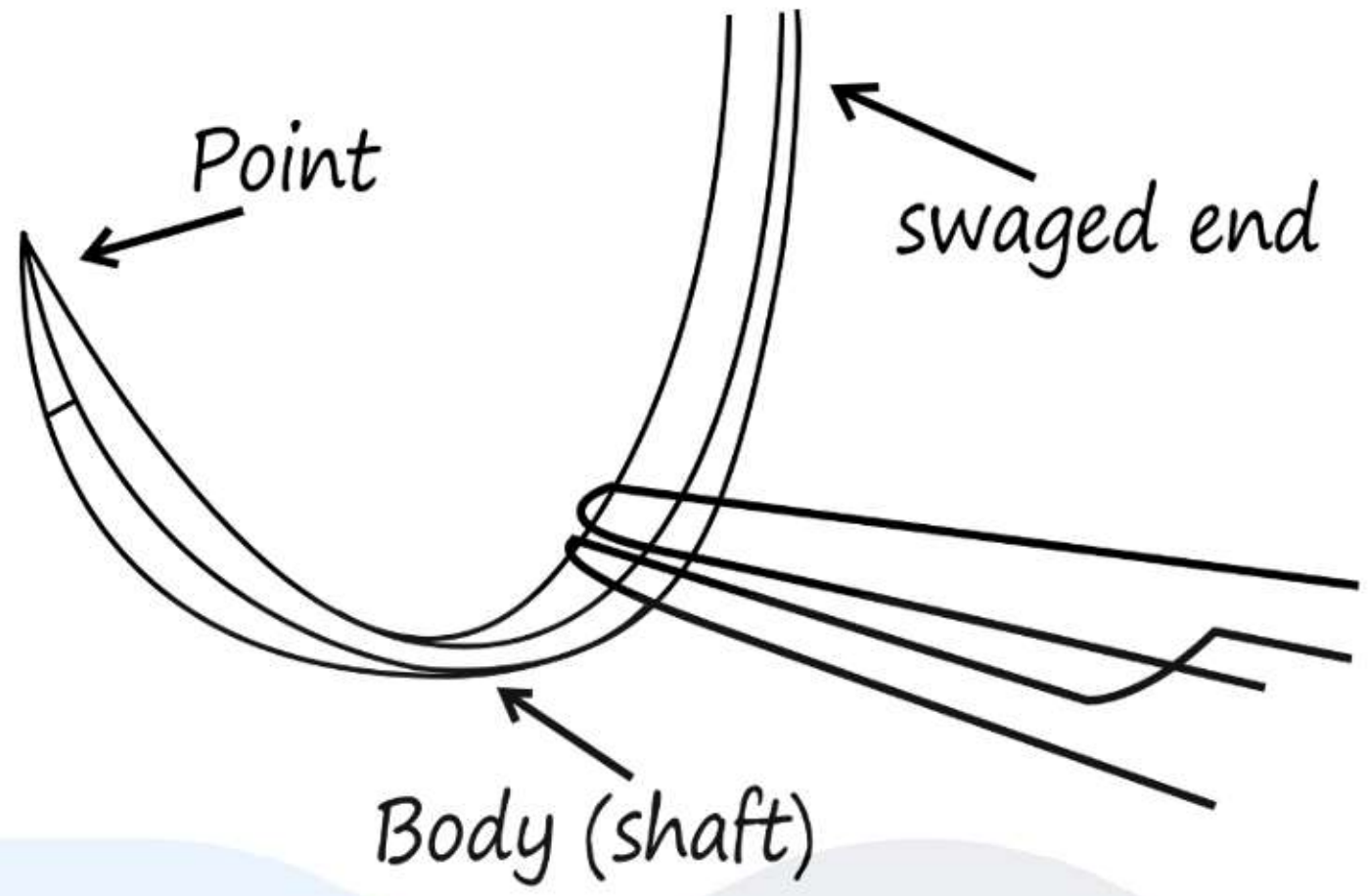

AfraTafreeh.com

– straight needles not used now due to high risk of injury
– if used, only for skin sutures

- half circle needle → most commonly used
↓
Bowel anastomosis, skin closure

 –1/4 circle needle → eye surgery

–complex needle → oral cavity surgery

–'J' shaped needle → vagina

AfraTafreeh.com

- 3 shapes of needle available

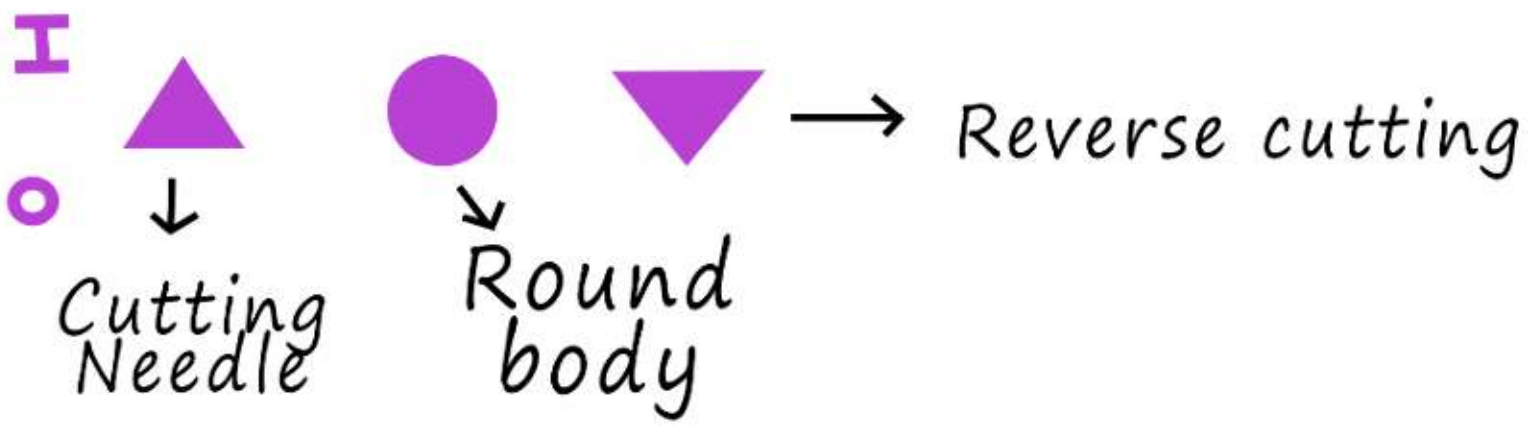

- Round body needle
  - Less damage to tissue
  - Used in Bowel
    Bile duct
    Vascular sutures
- Cutting needle
  - Damage to tissues ⊕
  - Can penetrate tough structures
    ↓
    Fascia
    Tendon
    Skin

TUTORIALS
LOGIN FOR SUCCESS

- Reverse cutting needles
  - Used in vascular surgeries
  - Less damage to tissue
  - Easy to pass

Blades 00:41:28



- 11' size → stab incisions

  I & D of abscess

  Draining hydrocele
- 15' size → small fine incisions
- 22' size → long incisions → laparotomy, thoracotomy

AfraTafreeh.com

TUTORIALS
LOGIN FOR SUCCESS

Suturing techniques 00:44:58

- 3 instruments needed for suturing
  - Needle holder
  - Toothed forceps
  - Straight scissors



AfraTafreeh.com

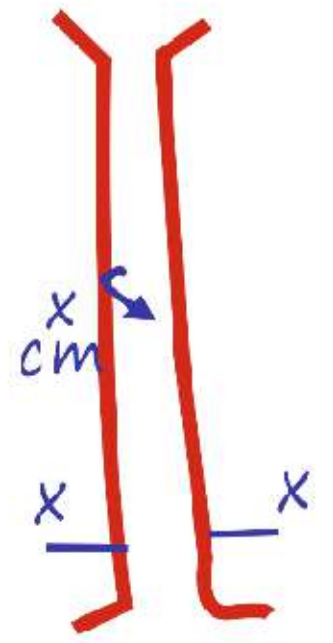

-depth of wound – x cm

-Suture should be taken at a distance of x cm on both sides

-distance of next suture should be 2x

↓↓

X:2x rule

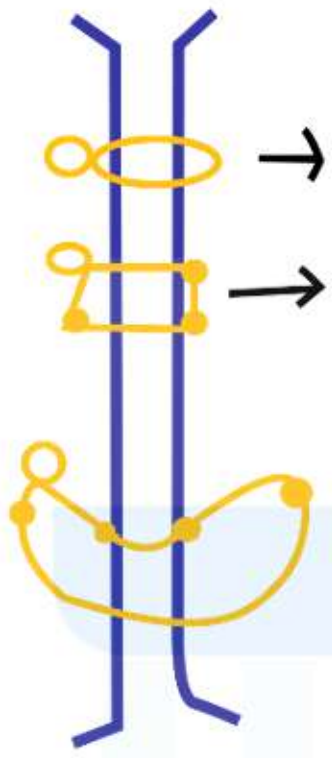

→ Simple

→ Horizontal mattress suture

→ Vertical mattress suture

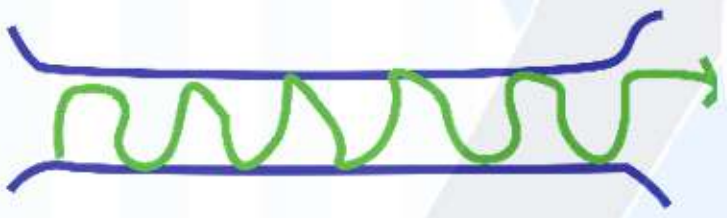

Subcuticular suture

Continuous suture

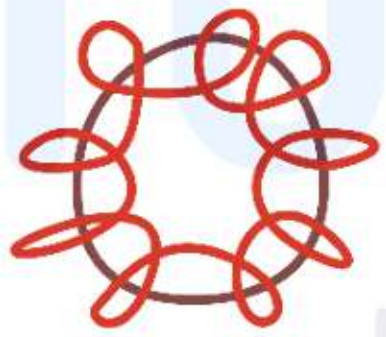

→ Purse string suture

TUTORIALS
LOGIN FOR SUCCESS

Removal of skin suture

- Scalp: – 6–8 days
- Lips, eyelids, face – 3–5 days

- Laparotomy
  Thoracotomy
  Ear lobe

} 8–10 days

- Palms, soles, back→ 10-14 days
- Skin staplers
- Tissue glue: - cyanoacrylate glue

Bowel anastomosis

- 3'0 vicryl
- Halstead matheson technique (best)

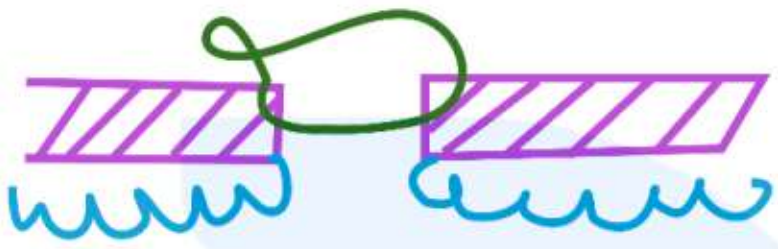

Single layer extramucosal suture

kocher's technique

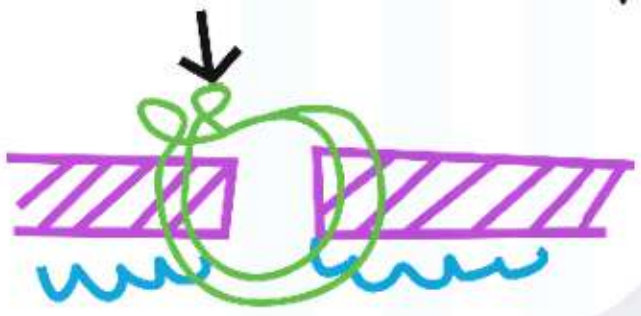

2 layer suture → not done now

AfraTafreeh.com



Seromuscular suture
Lambert technique
3'0 silk

End to end anastomosis of bowel

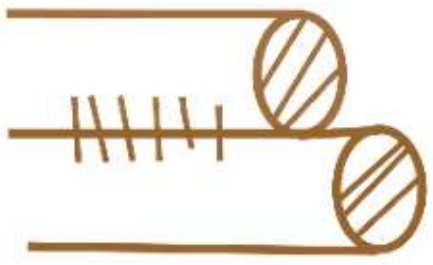

side to side anastomosis of bowel

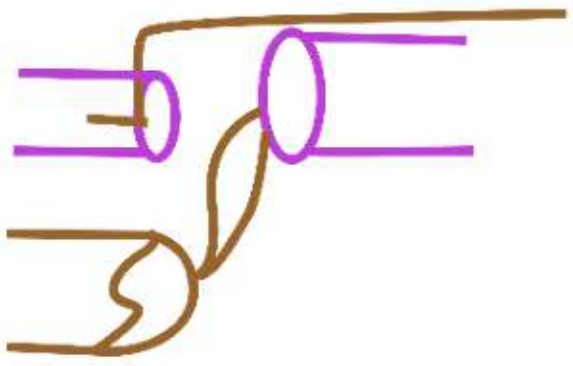

Cheatle cut

AfraTafreeh.com

Staplers

1.Transverse linear cutter stapler (TLC)

↓

Side to side anastomosis

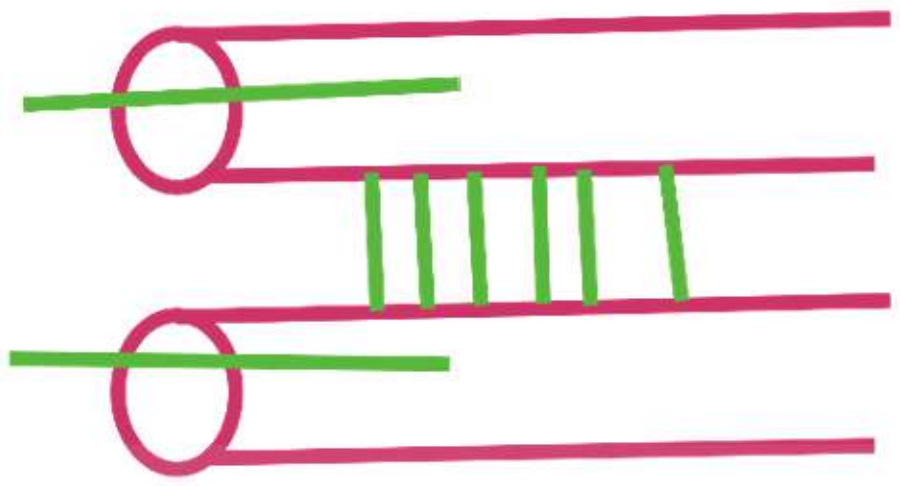

2.End to end anastomosis stapler (EER)

(Circular stapler)

↓

Anterior resection/Ca rectum

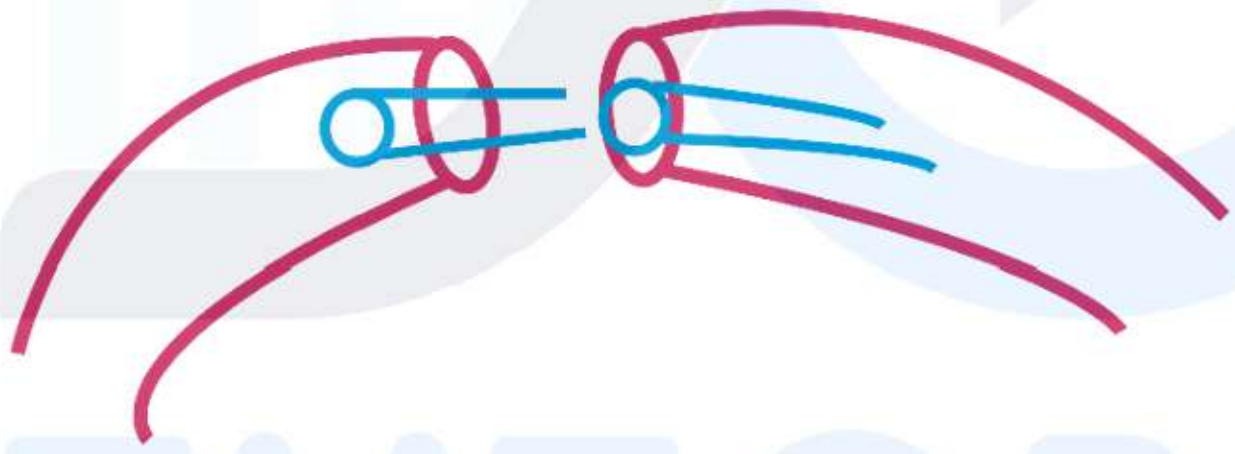

3.Thoracoabdominal stapler (TA stapler)

↓

Only stapler, no cutting

Vascular anastomosis

- Needle present on both sides

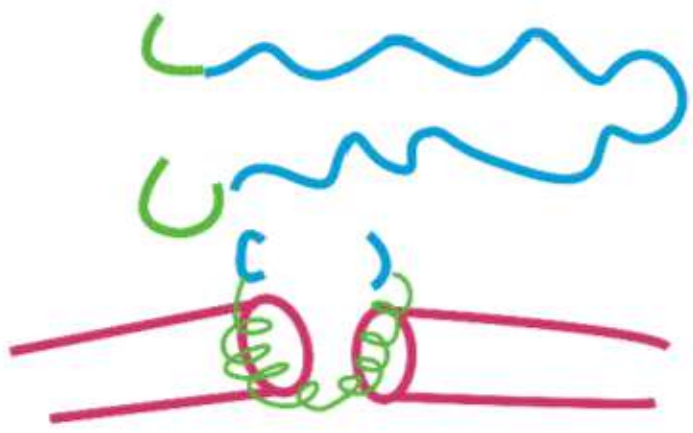

- In vascular repair, final knot should be made outside, hence 2 needles
- If knot is inside → nidus formation → act as emboli

→ CARREL's triangle.

IMAGES:



Fig: 1

Fig: 2

AfraTafreeh.com

Fig: 3

Fig: 4



Fig: 5

Storage material used in CATGUT SUTURE is ISOPROPYL ALCOHOL

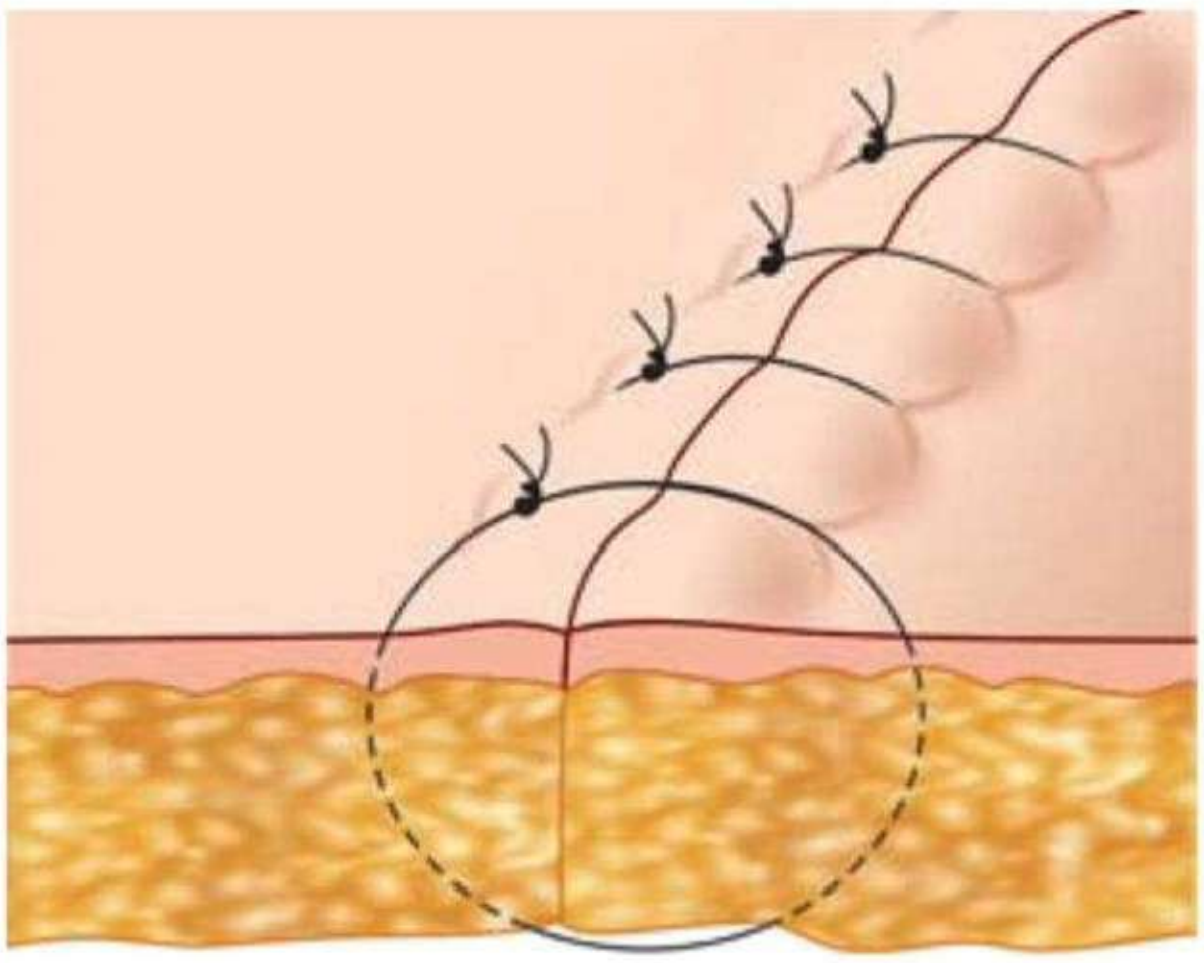

Simple sutures Fig: 6

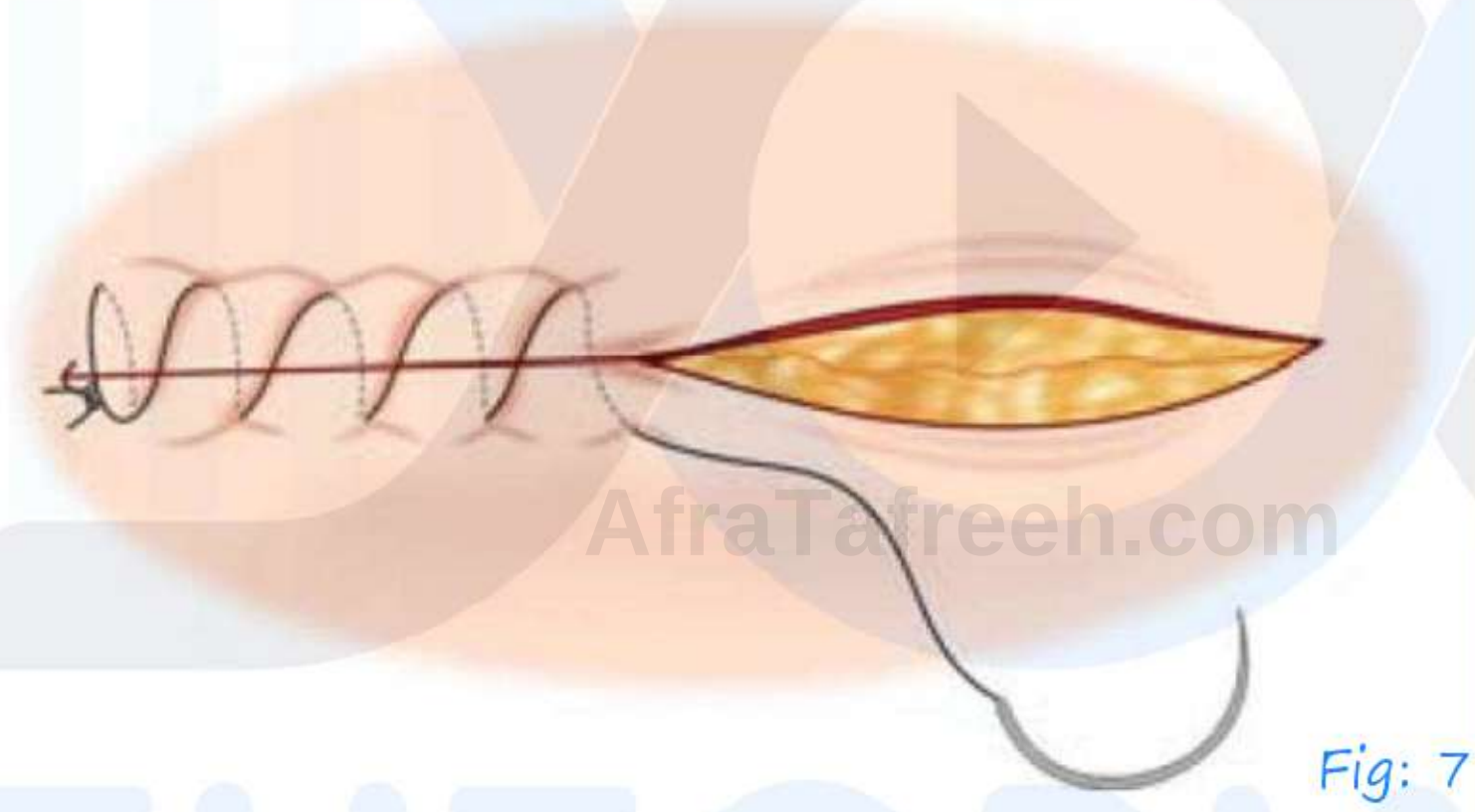

Fig: 7

Vertical mattress Horizontal mattress Fig: 8

AfraTafreeh.com
DOC TUTORIALS
LOGIN FOR SUCCESS

AfraTafreeh.com

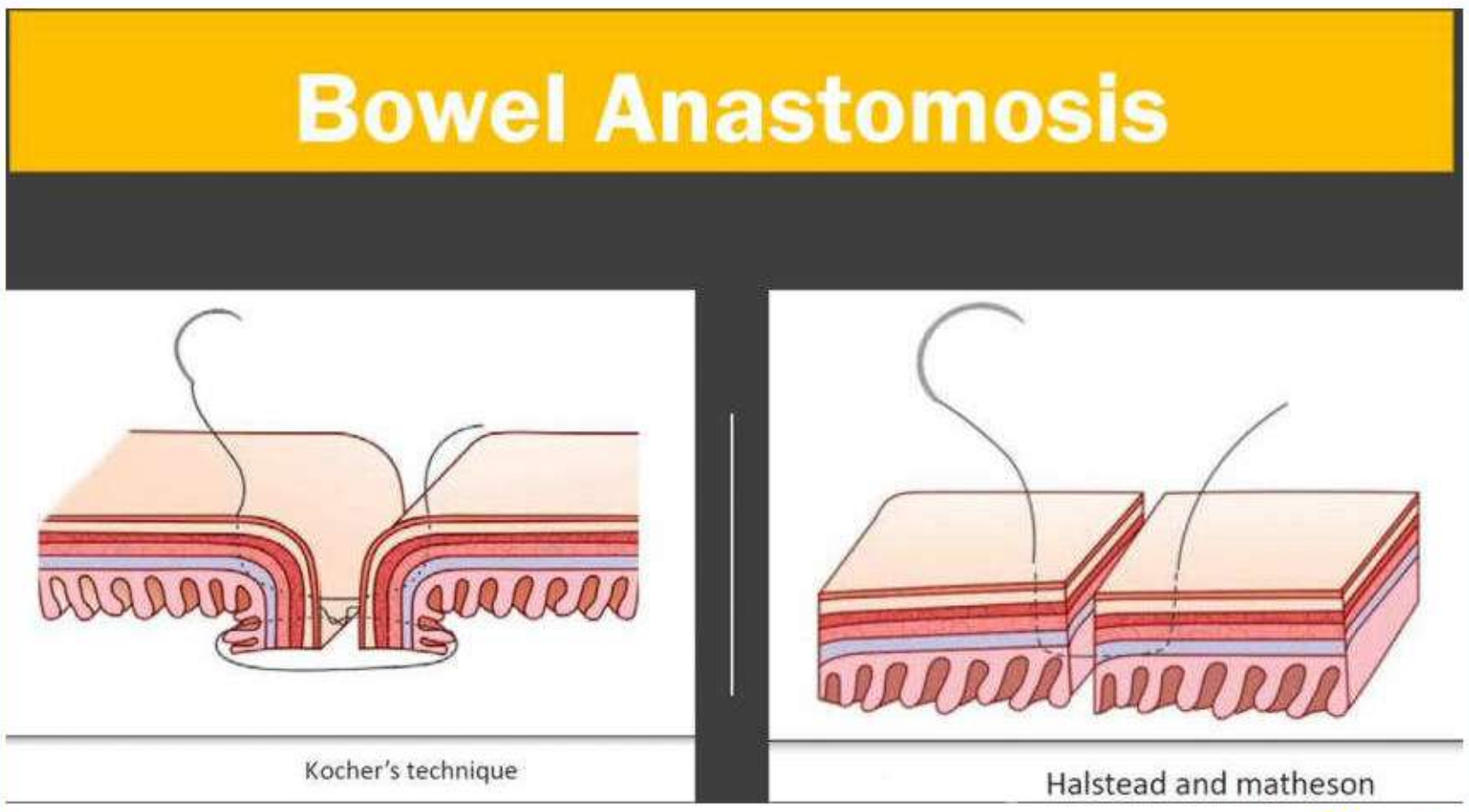

Fig: 9

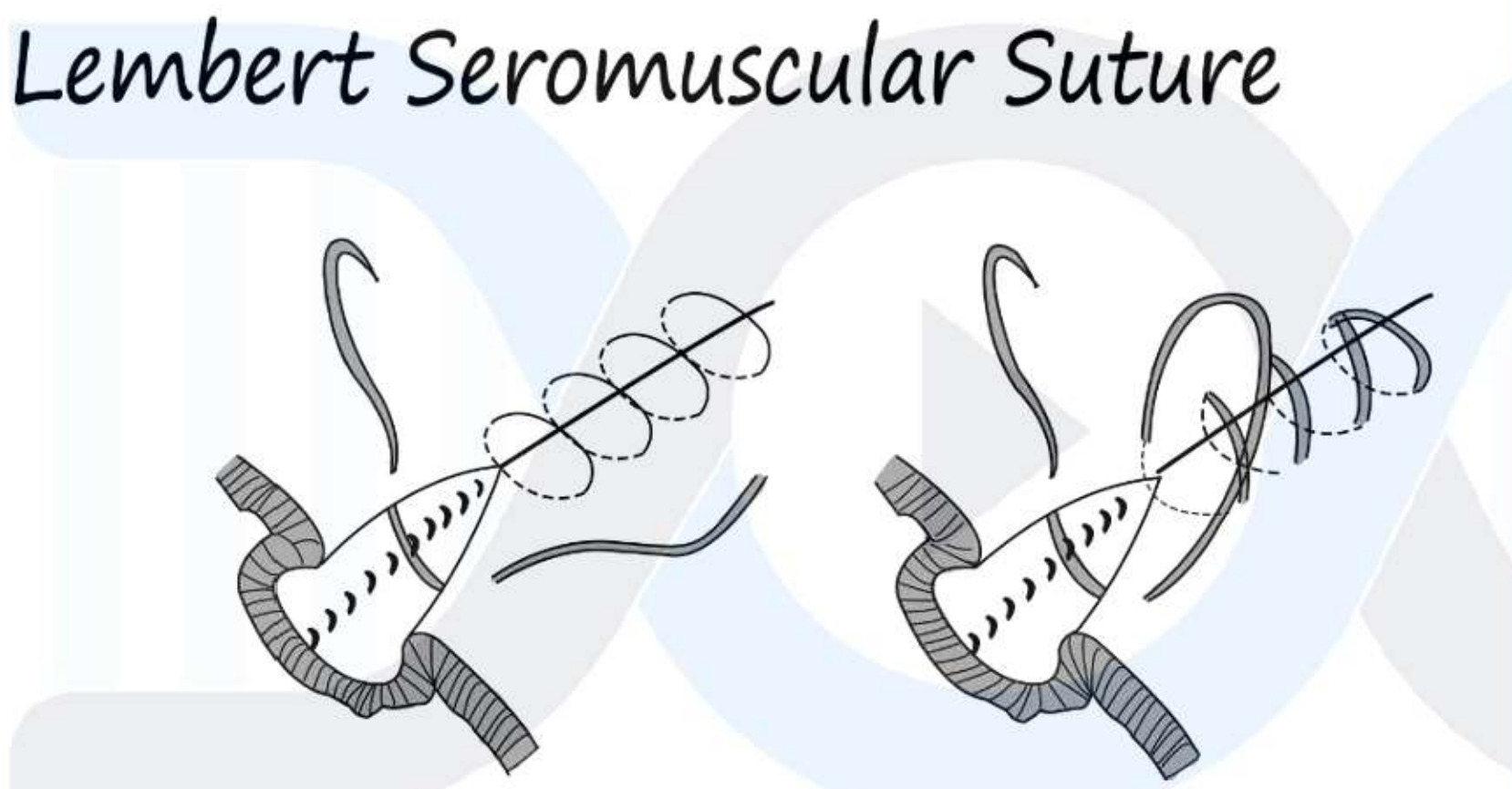

Lembert Suture (interrupted and continuous) Fig: 10

- Linear stapler

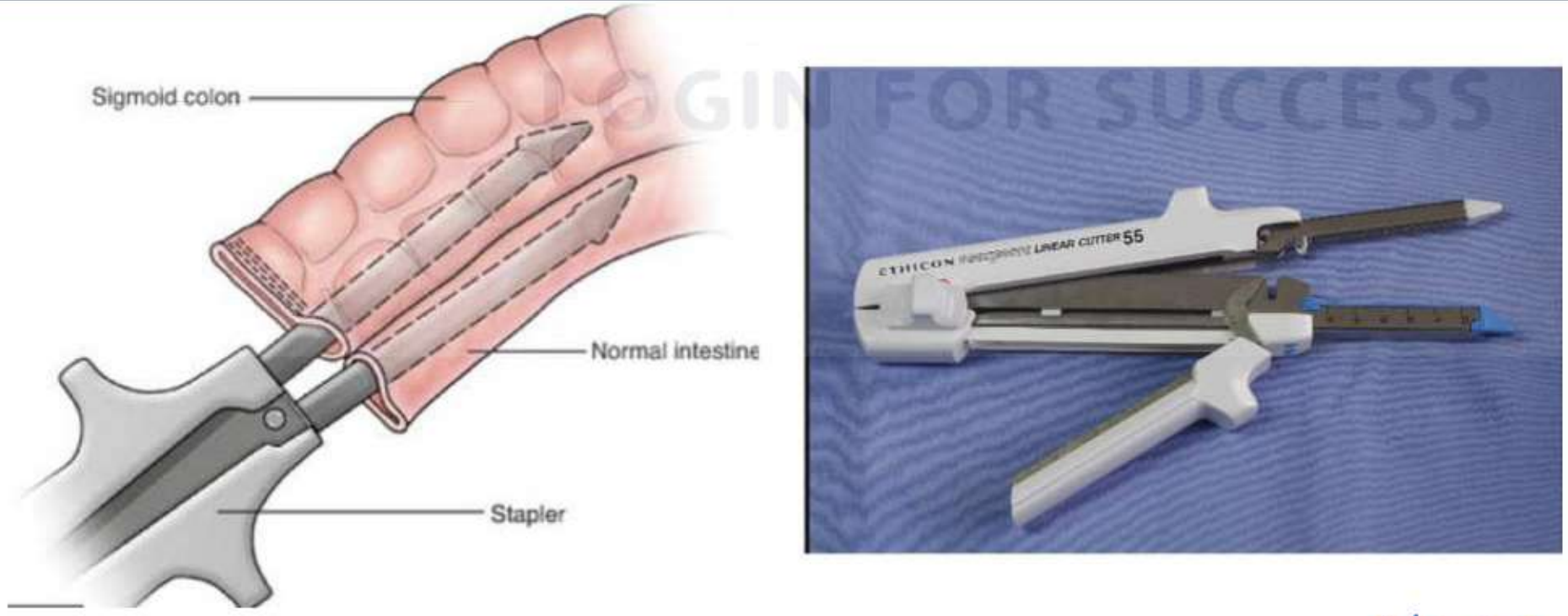

Fig: 11

- *Circular stapler*

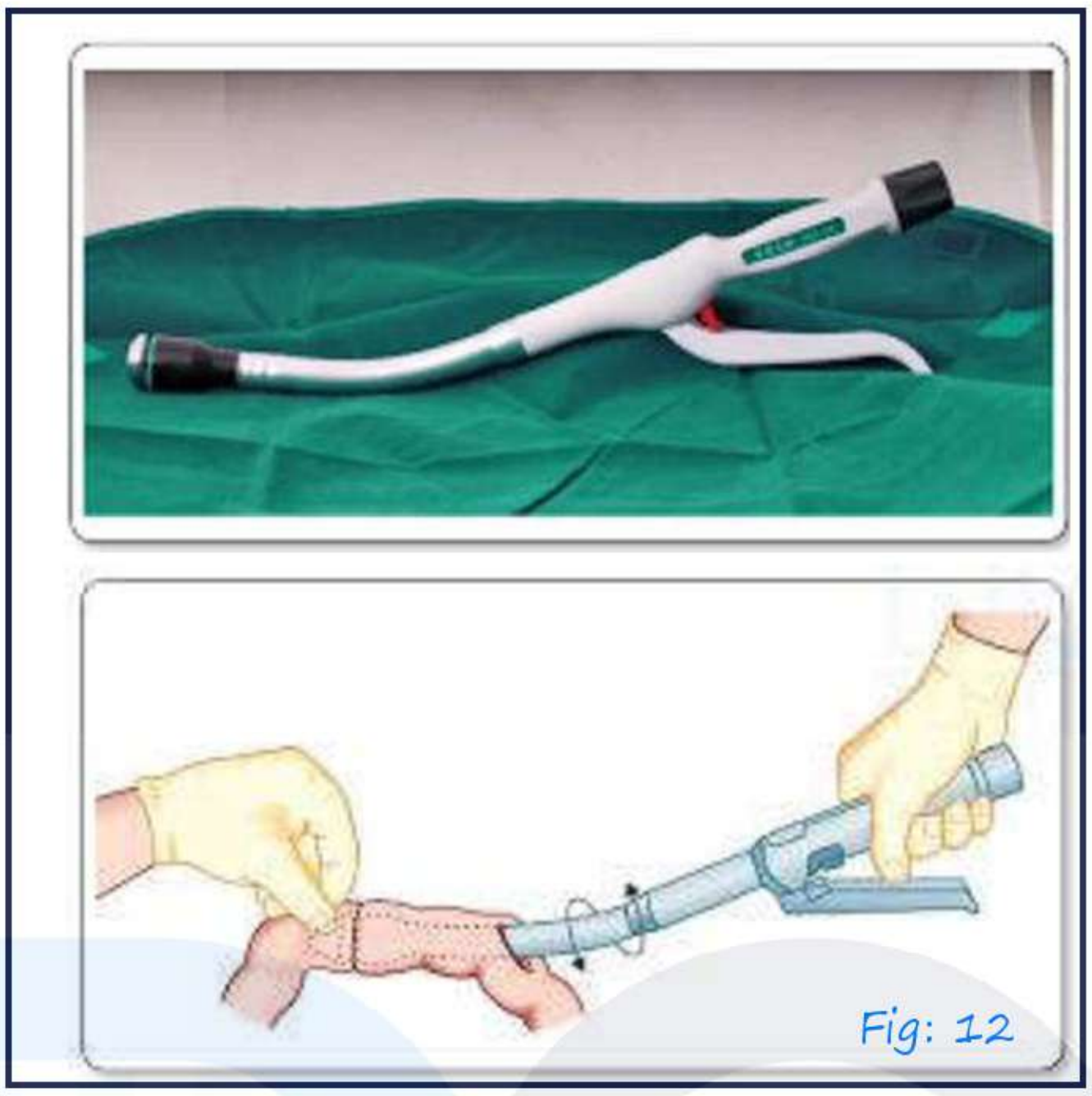

Fig: 12

- *Thoraco-abdominal stapler*

Fig: 13

- *Color codes of pins*

Fig: 14

AfraTafreeh.com
TUTORIALS
LOGIN FOR SUCCESS

AfraTafreeh.com

Color	Tissue type	Open staple height	Closed staple height
Grey	Mesentery	2.0mm	0.75 mm
White	Vascular	2.5 mm	1.0 mm
Blue	Standard	3.5 mm	1.5 mm
Gold	Standard/ Thick	3.8 mm	1.8 mm
Green	Thick	4.1 mm	2.0 mm

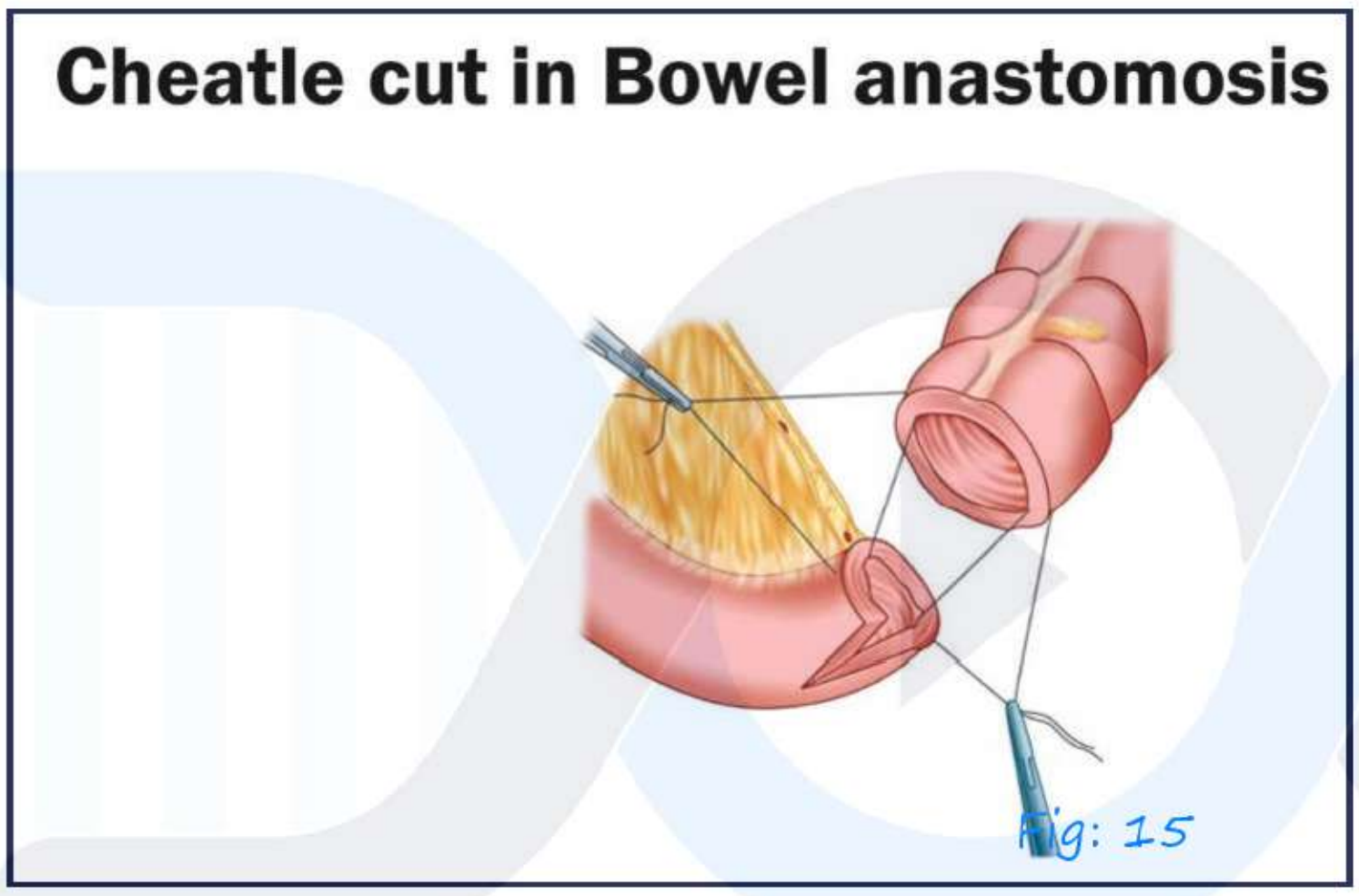

Fig: 15

- Carrel triangle in vascular anastomoses

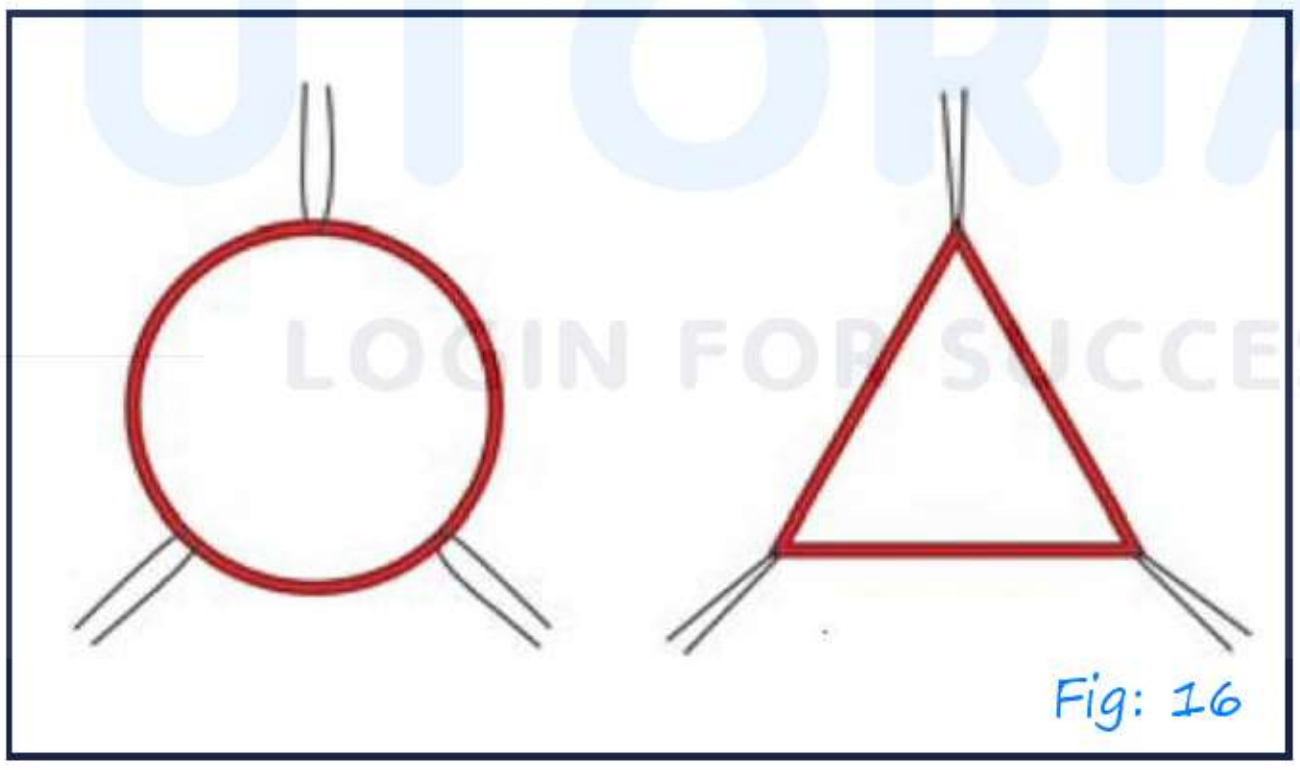
Fig: 16

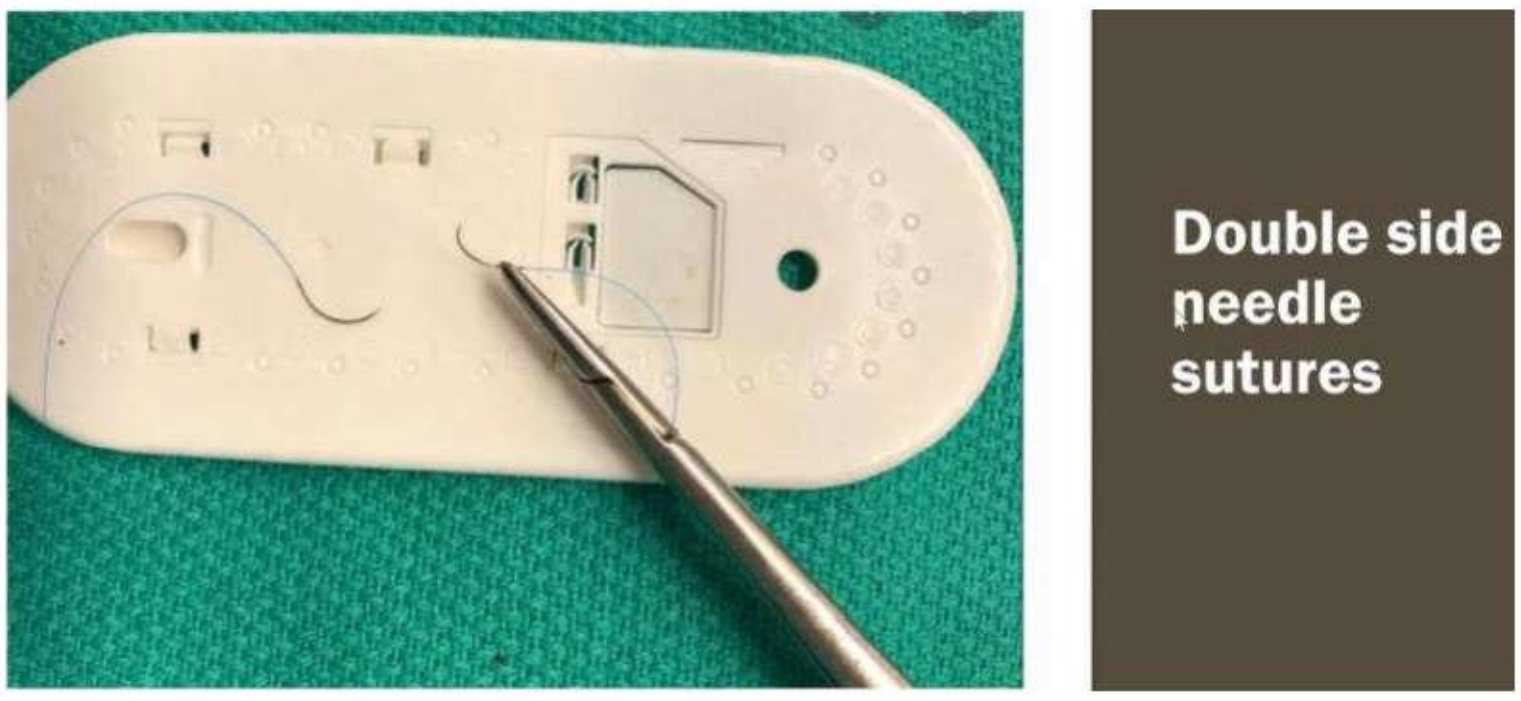

Fig: 17

- Used in Vascular suturing

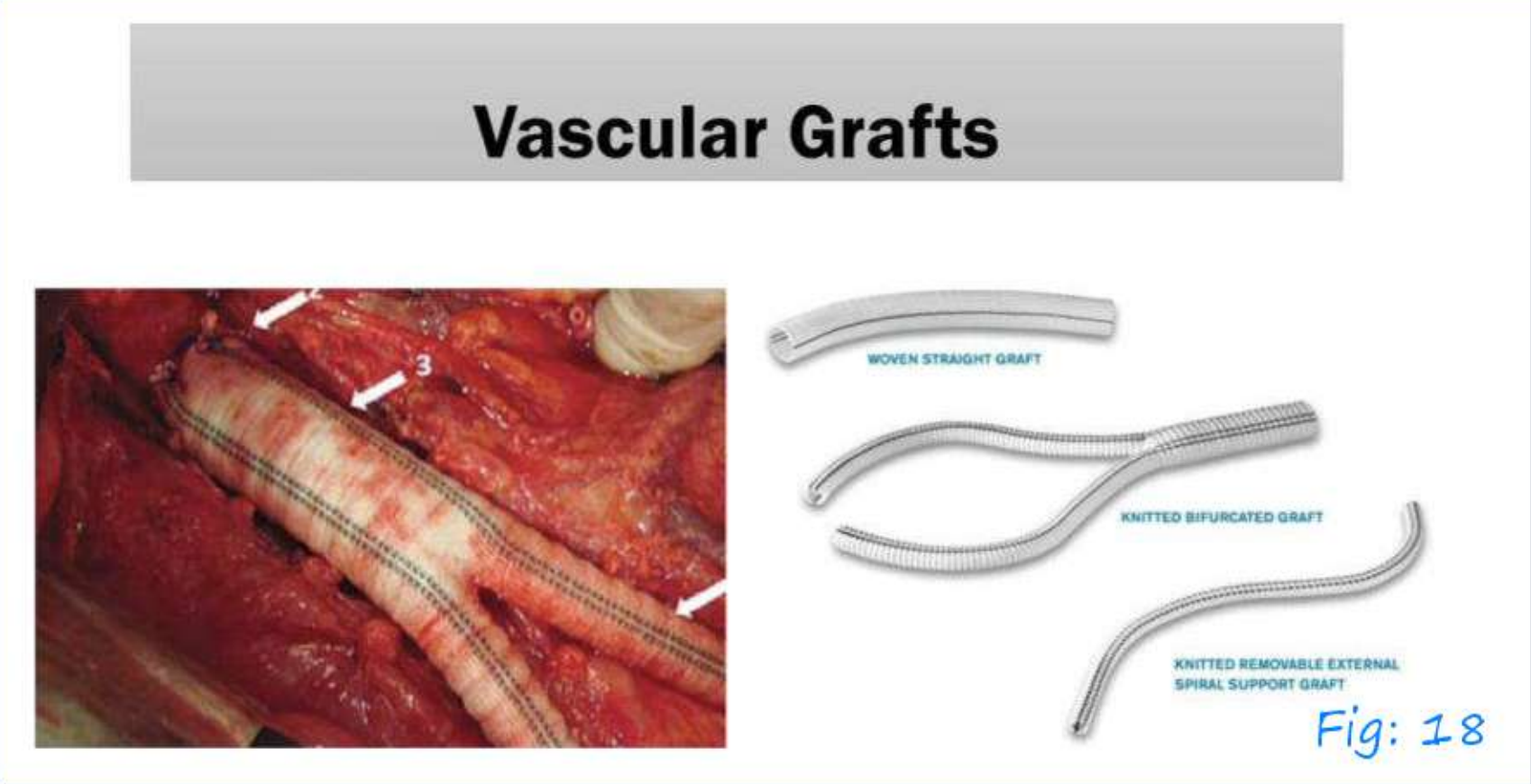

Fig: 18

Each needle and it's use

- Half circle needles - gastrointestinal tract
- J-Shaped needles - vagina
- Quarter circle needles – Eye surgeries
- Compound curvature – Oral cavity

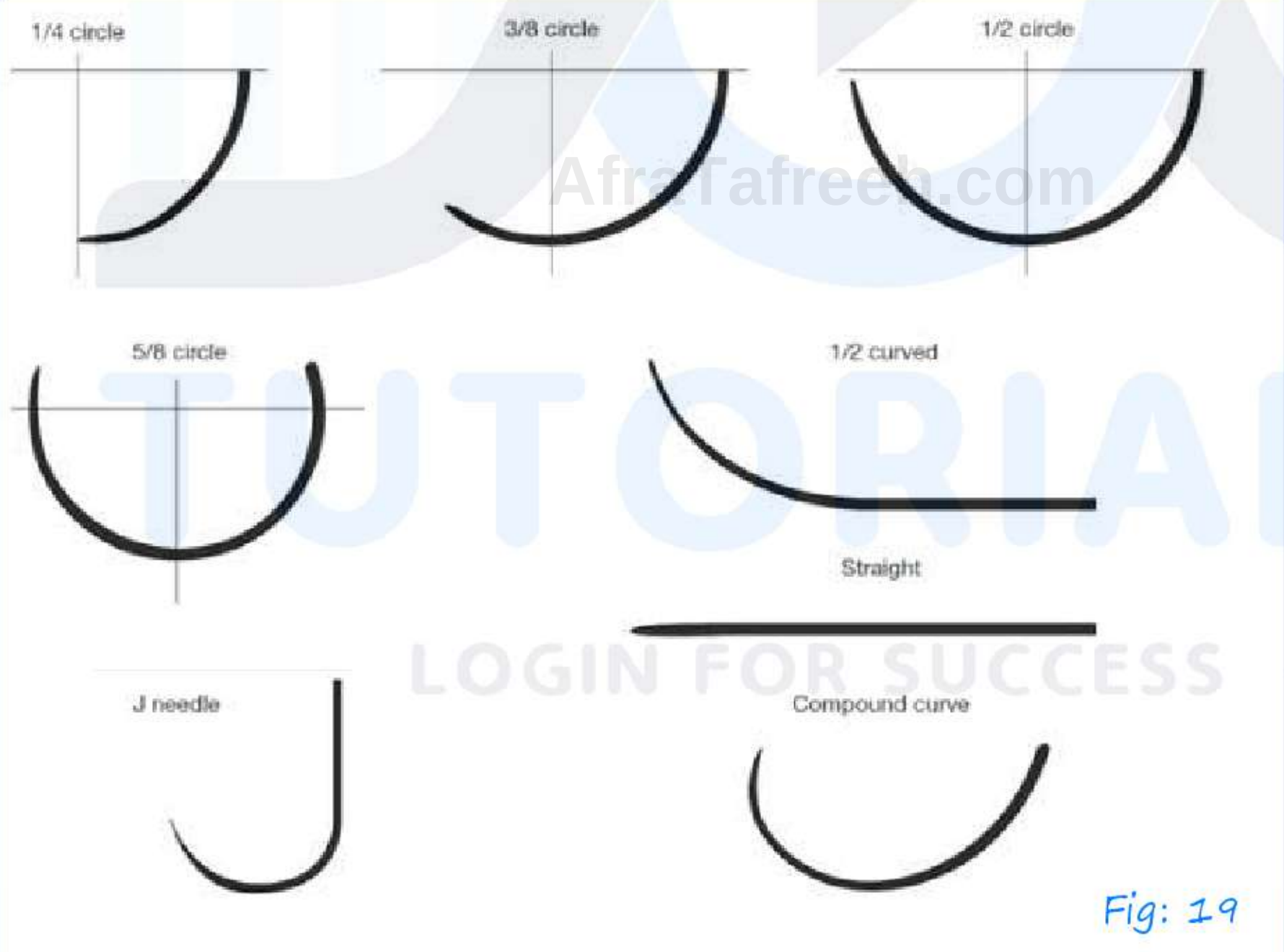

Fig: 19

AfraTafreeh.com

Incisions on Body-Langer's Lines

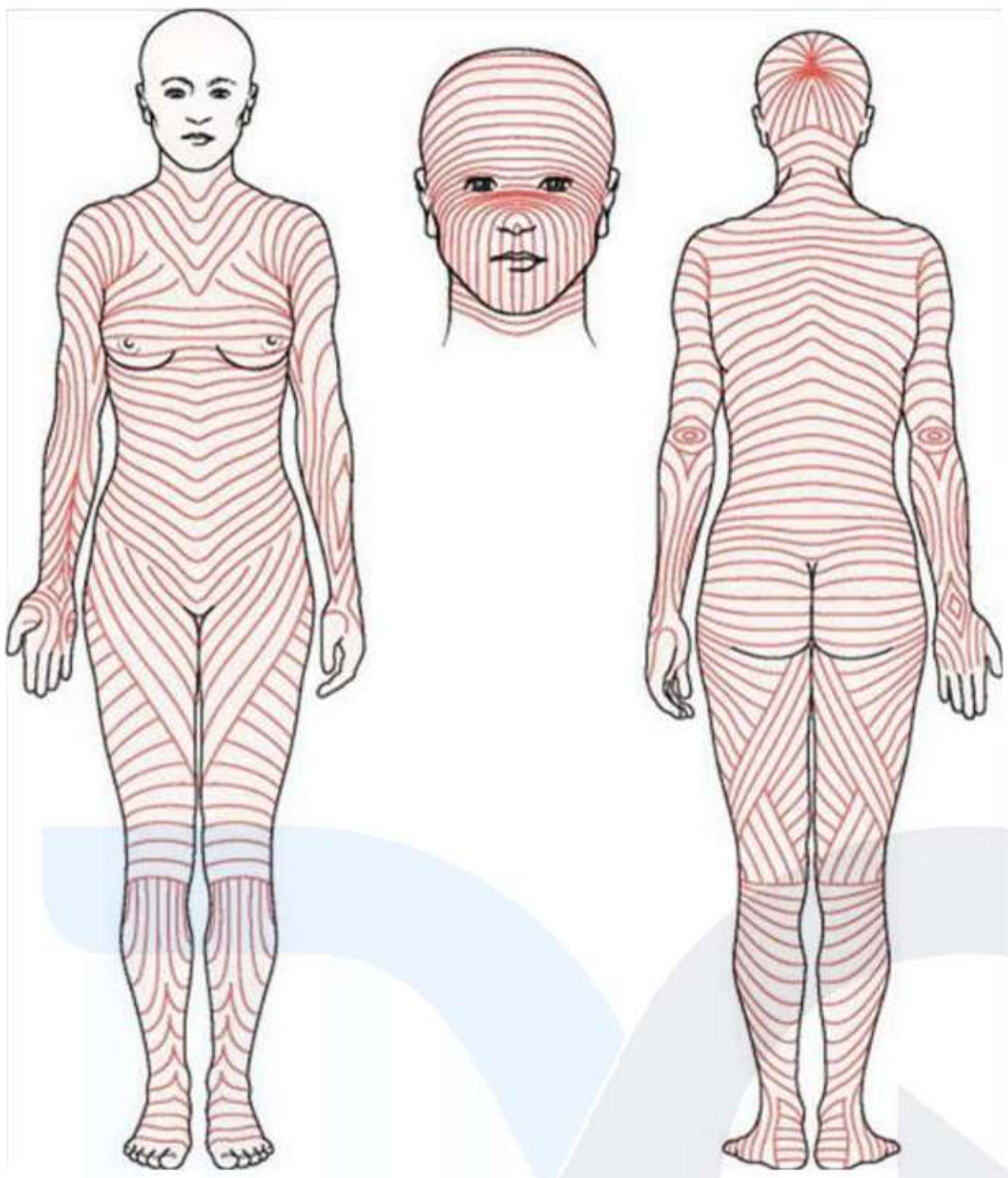

Fig: 20

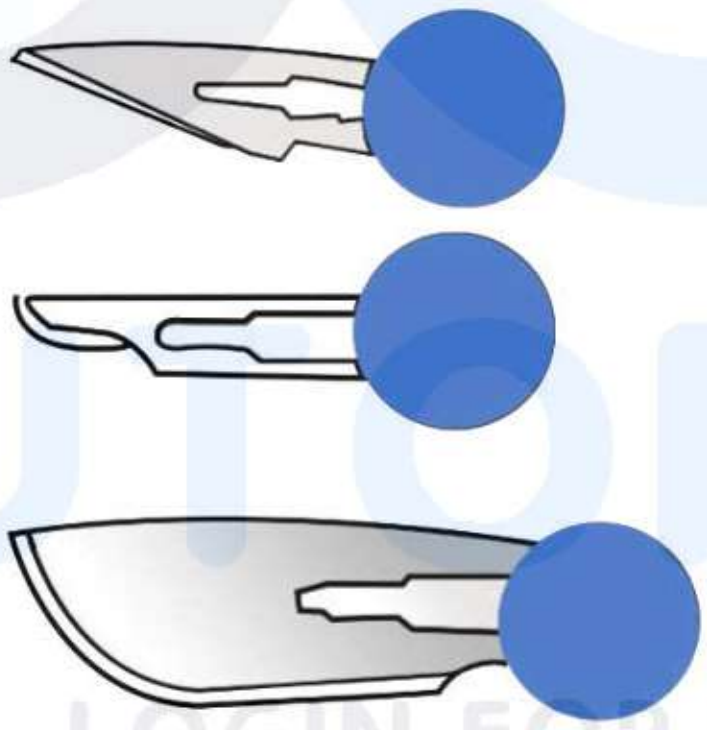

Fig: 21

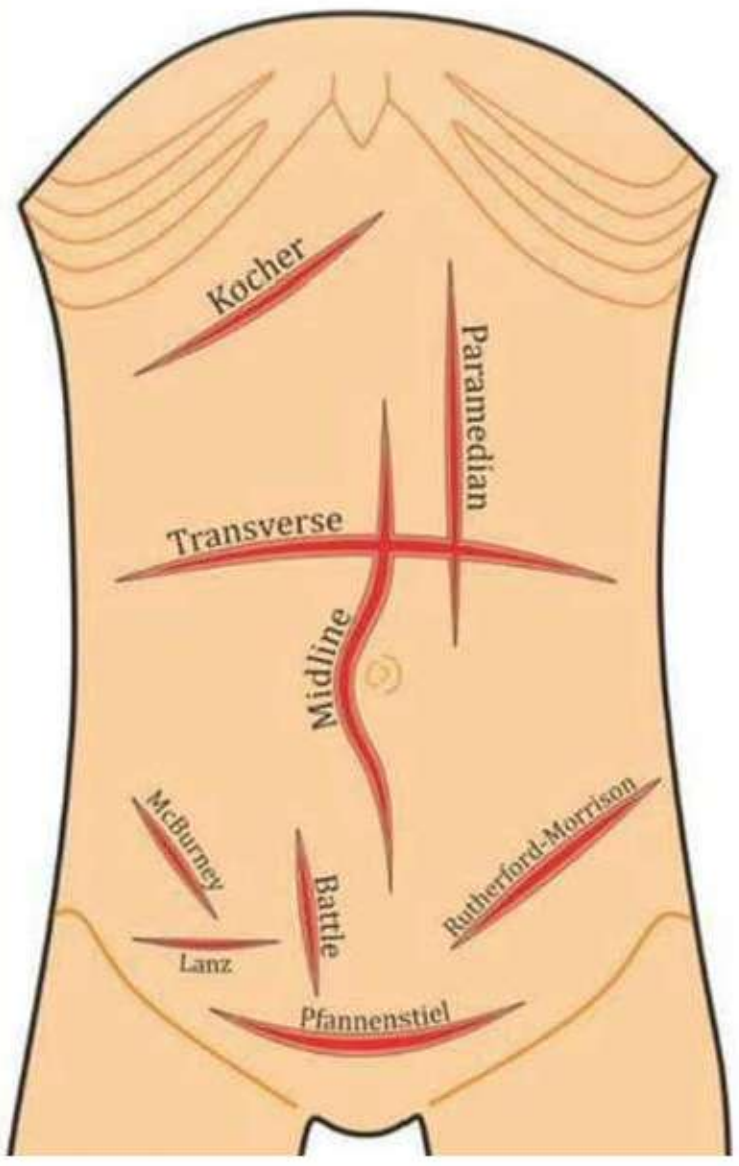

Incisions on Abdomen

Fig: 22

Fig: 23

KNOTS:



Fig: 24



Fig: 25

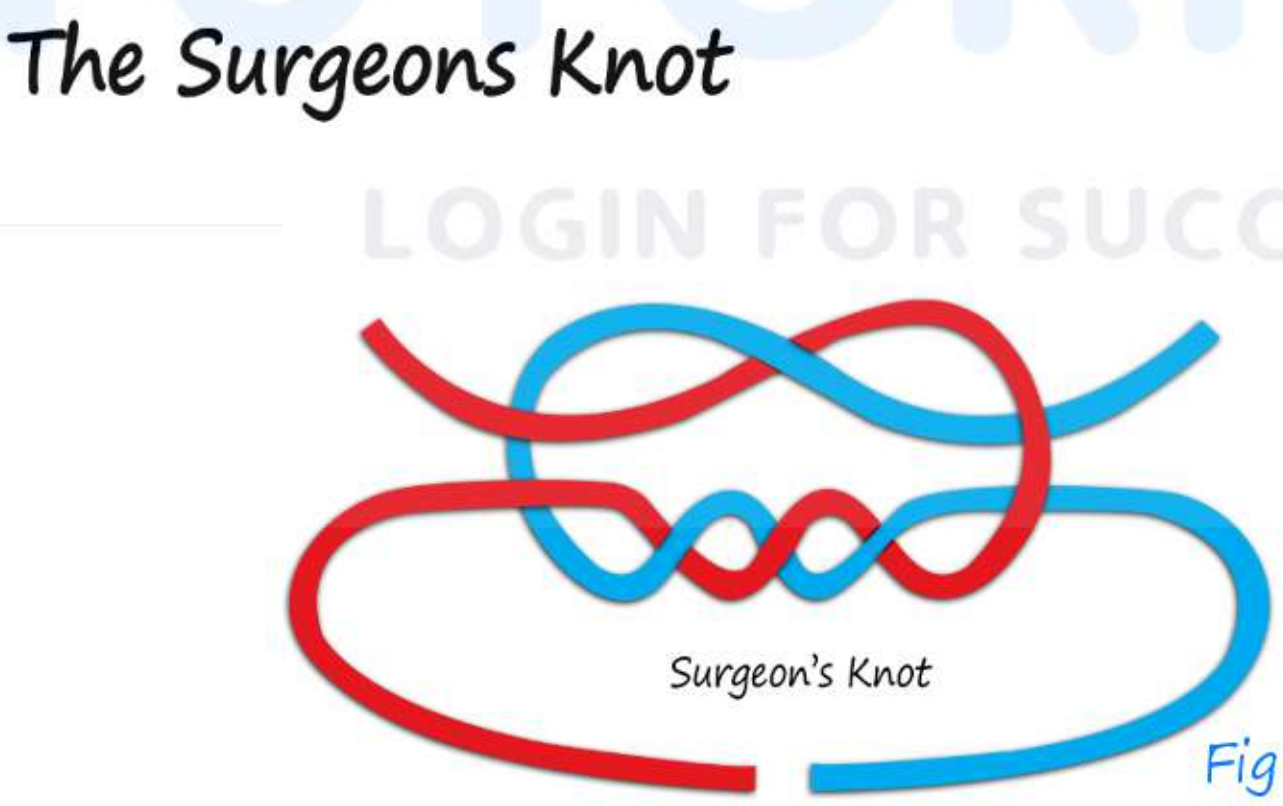

Fig: 26

DOC TUTORIALS
AfraTafreeh.com
LOGIN FOR SUCCESS

- Aberdeen knot is used to finish the complete suture
- Jenkin's rule –

  Length of suture needed = length of wound * 4

AfraTafreeh.com

INSIDE THE OT

Diathermy video demo 00:00:05

- Monopolar diathermy: -
  - Current passes through the probe into patient body and then from earth plate attached to patient body current enters into machine
  - Monopolar diathermy probe has 2 buttons – blue and yellow
  - Blue is for coagulation and yellow is for cutting
  - It is most common cause of accident inside the OT – can cause electric burns
  - We should not use monopolar diathermy in
    1. Parotid area, because it will have lateral spread and can damage facial branches
    2. In the thyroid – can damage RLN and ELN
    3. In fingertip and penis → end artery is coagulated and they will go for necrosis
  - We can use diathermy in a patient with pacemaker, but do not place the earth plate near the pacemaker, current should not pass through the pacemaker and earth plate is placed away from the pacemaker.
- Bipolar diathermy -
  - Some machine with 2 wires. It has a probe with 2 limbs

DOT TUTORIALS LOGIN FOR SUCCESS

- Current will pass from one limb into patient body and goes through second limb. So, the current passes in the small area of patient body between limbs and complete circuit
- In both monopolar and bipolar diatherymy, electric current is converted into heat energy. This heat is going to coagulate in bipolar forceps.
- Bipolar can be used in finger tips, parotid, thyroid, penis at any place safely (everywhere)
- It is safest instrument. No accidental burns is advantage
- Disadvantage: - we can only do coagulation with bipolar but with monopolar, we can do both coagulation and cutting
- No earth plate needed in bipolar

AnyTafreeh.com TUTORIALS LOGIN FOR SUCCESS

Laparoscopy 00:06:37

1. Monitor – to see the inside of abdomen
2. Camera source – 10mm scope is connected to it. The end of scope is not straight, it is 30° scope can be of different sizes 10mm, 5mm
3. Light source – we can increase and decrease the power of light
4. Gas insufflation – The maximum value we can use in laparoscopy is 15mm of Hg. CO_2 gas cylinder is connected back to machine

AfraTafreeh.com

5.Long instruments – we have toothed forceps, non-toothed forceps, artery forceps attached to them (needle holder etc.)

Maryland instrument – used for holding tissue, look like artery/forceps

6.Verres needle – used to insufflate gas into abdomen. It has a sharp end and a blunt end with spring mechanism. By sharp end, we pierce abdominal wall. Once we enter inside abdomen, the Verres valve opens up and the blunt end comes and it count injure bowel – It is used for closed technique of laparoscopy

7.Trocar: – it can be sharp or blunt with differen5t sizes like 10mm,5mm

- While operating, we put trochar in abdomen and we can pass instruments through the trocars inside the abdomen
- It has a washer so that the gas will not leak throughout

DOT TUTORIALS LOGIN FOR SUCCESS

Table positions in operation theater 00:13:18

a. Supine position

- Patient lies horizontal with arms by the side
- Most of surgery are done in this position
- GI surgeries are done in this position

b. Prone position – used for spine surgery

c. Trendelenburg: – head down and leg end is elevated, so veins in the legs get collapsed, so while operating

on lower limb, the bleeding will not be there from veins

Example: – surgery for varicose veins

d. Reverse Trendelenburg: – head is up with leg side is down

- Surgeries done are thyroid, parotid, any head and neck surgery. So that vessels in this place are collapsed and bleeding is less
- Head ring is used sand bags under the shoulder so that the patient is hyper extending the neck
- It is a typical dog dark position, with reverse Trendelenburg. Typically used for thyroid surgeries
- No severe extension should be there
- Reverse Trendelenburg is contraindicated in patient with cervical spondylosis – since patient can land up in quadriplegia

DOCTUTORIALS
LOGIN FOR SUCCESS

e. Pyelolithotomy position (or) renal position

↓

Here we elevate the break area in the OT table, so that the kidney will come up

In this position, patient arms are hyper abducted → major problem, so patient may develop brachial plexus injury

- Any surgeries related to kidneys are done in this position

AfraTafreeh.com

- It is a lateral position, with the central split of table elevated called lateral renal position

f. Kratzke's (or) jack-knife position → patient is in prone position

- Pilonidal sinus is operated in this position
- Complication – positional asphyxia can happen (due ot long standing prone position)

g. Lithotomy position: - used for hemorrhoids, fistula, fissure, vaginal deliveries

h. Lyod Davis position

- Patient is in Trendelenburg position, his limbs are separated
- Advantage is one person can stand between limbs and assistant surgeon can stand on one side
- During laparoscopy, this position is used for pelvic surgeries also used

i. Head up position – Reverse Trendelenburg⊕ raise or tilt up the Right side of table

- For laparoscopic cholecystectomy
- Position of the patient is the best retractor
- In this position, calots Δ/e will automatically open up, all surrounding structures are moving away without a retraction
- Without this maneuver, lap cholecystectomy cannot be done.

j. Fowlers sitting position

- Generally, for neuro surgeries

TUTORIALS LOGIN FOR SUCCESS

- During neuro surgery, if veins are not properly ligated, they can develop air embolism in this position (by negative pressure).so, we have to ligate all veins before cutting

k. Recovery or Durant's position

- If a patient develops air embolism immediately put the table head below down and turn the patient left laterally (or) the ® side is up
- Because in this position, the air gone inside will go into ® atrium base, that is most not dependent position (or) apical portion now and the air won't go into pulmonary arteries
- Apex of ventricle comes to top
- With the help of central vein, we can suck this air (or) prevent the gas entering lungs and prevent major complications. This is called as recovery position called as Durant's position

LOGIN FOR SUCCESS

Review :-

- Brachial plexus injury → occurs in renal (lateral) position
- Common peroneal nerve injury → occurs in lithotomy position, in long periods and if not kept a sponge pad under (knee bend) where the limb is resting.
- Asphyxia can happen in Jack knife position
- Monopolar and bipolar diathermy circuit diagrams

AfraTafreeh.com

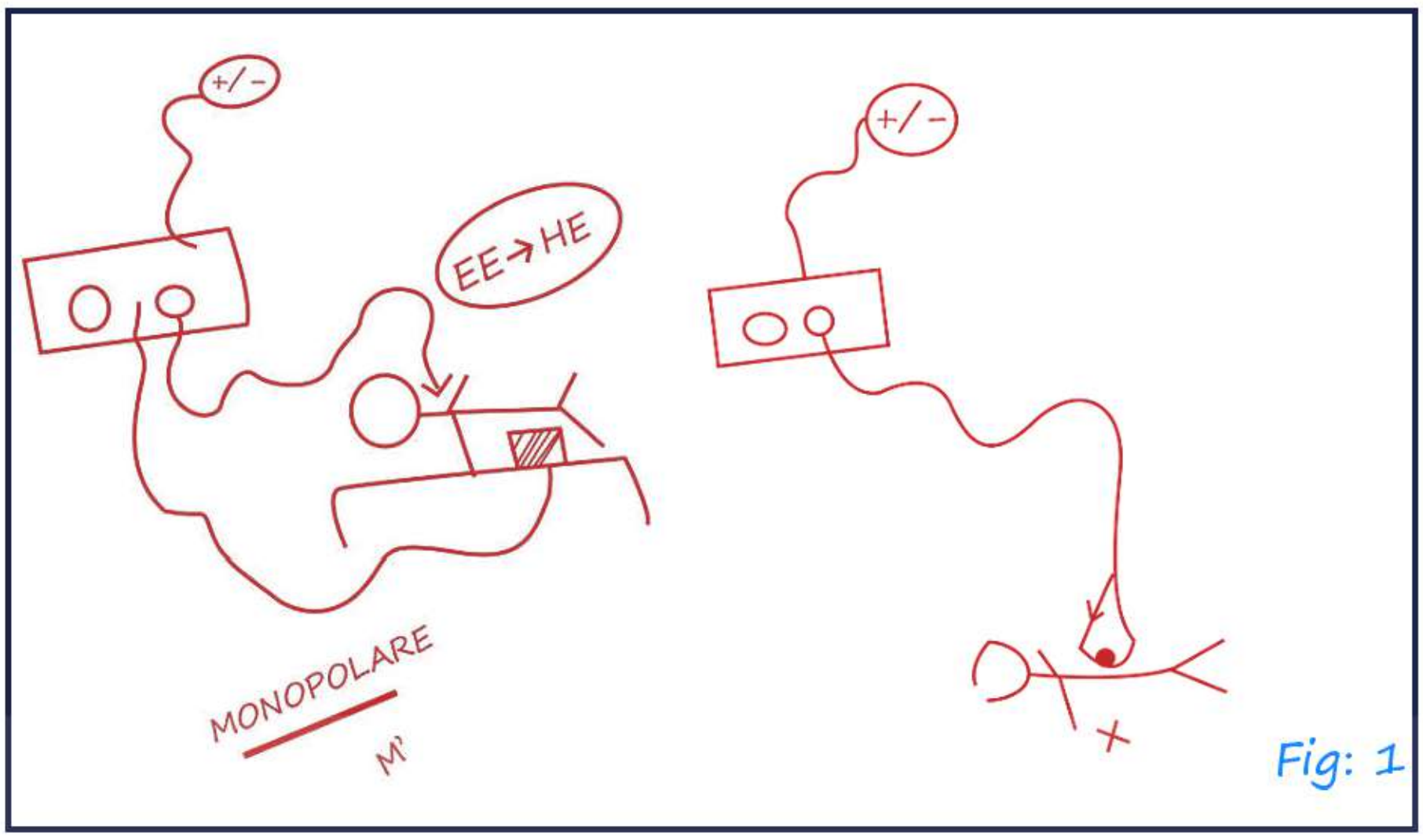

Fig: 1

- Most common causes of accident in OT is due to monopolar diathermy → electrical burns can occur in patient
- Two types of mechanisms area seen in diathermy
  - Pure cut – It cuts the tissue and it cannot stop bleeding

    (Can't coagulate)
  - Pure coagulation – It only coagulates
- When both properties are combined → it is called blend/blended current. There are 3 types of blends
- In cutting current, there is high frequency wave, at low voltage continuously with no break is seen



- If we give high voltage of damped sine wave that is give high voltage current and stop i.e., in bursts, then again give high voltage current and stop → called coagulation

- Blended – is a mixture of continuous and damped sine wave
- Here fulguration happens that is destructive coagulation of the tissues with charring. So, it coagulates and cuts at the same time

AfraTafreeh.com

	Cutting: Coagulation
Blend 1	50:50
Blend 2	40:60
Blend 3	25:75 (more coagulation) ↓ Damped sine wave is half

Harmonic scalpel: - 00:41:22

- Here electrical energy is converted to ultra-sonic waves

AfraTafreeh.com

- It causes protein denaturation and cause coagulation
- Waves used at frequency of 20,000 to 50,000 Hz
- Produces denaturation by vibration. So, there is no heat production
- It has a precise cut, hence can be used close to vital structures. (There is no lateral damage than the site of apply)

Ligasure device: -

- It is a combination of harmonic and diathermy
- Involves same technology of monopolar diathermy
- Here electrical energy is converted to coagulation effect by means of patents own collagen and elastin
- It is cheaper in cost than harmonic scalps
- It can cut 7mm vessels without need of ligation
- It takes little extra time compared to harmonic scalpel
- Patient own collagen and elastin are attracted to the operated site and they will seal and divide

TUTORIALS
LOGIN FOR SUCCESS

Advanced techniques in surgery 00:45:14

- **Basics of laparoscopic surgery: -**
  - Monitor, camera, CO_2 insufflation, light source are the components
  - Light sources we currently use are
    i. Halogen
    ii. Xenon

Halogen →250 watts inbuilt lamp, it is economical

Xenon → 300 watts lamp, it is expensive

Xenon is Much cooler in abdomen and currently used mostly

- Camera will be connected to the scope of 10mm and 5mm size
- Scope can be 0° tip (or) 30° beveled tip

Advantages of lap over open surgery: -

- Cosmetic
- Fast recovery
- Early return to job
- Less pain
- Better visualization by surgeon

AfraTafreeh.com

Basic principles in lap: - "IVITROS"

- I – Insufflate the abdomen with a gas
- V – Visualize with the camera scope
- I – Identify the pathology
- T – Triangulation of all ports for ergonomic design
- R – Retraction is mainly done by positioning of table
- O – Operate
- S – Seal – closing the port and come out.

Gas used in lap

- We use CO2 commonly
- Can also use nitrogen, room air

- CO_2 is rapidly absorbed from peritoneal cavity. It has 200 times increased diffusing property; hence it is easily cleared from abdominal cavity (or) from circulation
- It has less incidence of gas embolism
- On insufflation, The max pressure inside abdomen should be 12-15 mmHg

  In VATS, the pressure is 5-8 mmHg
- **Gas insufflation – most critical step**
- We can insufflate gas by

1. Verres needle method, closed laparoscopy gas insufflation.
   - Site of insertion → supraumbilical, sometimes infraumbilical
   - **Palmer's point** → in patient with many previous surgeries we cant put Verres needle in umbilical area, it can puncture the bowel which is adherent to under surface of abdominal wall. In such case, we will go 3 cm below the Left costal margin in the mid clavicular line → this point is palmers point

- Once we put needle, the rate of flow of Co_2 is 1-4 liter/minute

2. Hassan's open method → incision given and trocar placed
   - Bowel injury is common here
   - Risk of major vessel injury is very less here

- Verres needle method → risk of bowel injury is less risk of major vessel injury is present
- In open method when trocar is placed, the structures being pierced are skin, superficial fascia, deep fascia, fascia transversalis and parietal peritoneum and Linea alba in the middle which is fusion of both side fascia transversalis.
- Types of trocars
  - Sharp trocar – we use it Verres technique after putting Verres Needle
  - Blunt Hassan cannula – used in open technique
- Critical step – is to put a primary trocar, because high chance of Injury, as we insert it blindly
  - We will put the camera in the first port
  - Then under vision secondary trocars are passed so, no major injury is seen
  - Injury of abdominal wall vessels like inferior epigastric artery, superior epigastric artery are expected in the 2° trocar insertion
  - If there is injury and bleeding in 2° trocar/port. Then we manage by
    1. Extend the incision by 3mm on both sides and take a suture with prolene like a figure of 8 on above and below

AfraTafreeh.com

AfraTafreeh.com

2.Immediately remove trocar and place a foleys catheter and inflate the balloon and pull it. Then it will compress the structures, how fix the catheter. It causes tamponade effect. For 24 hours foleys should not be removed.

Optical visiport / camera port: -

- Camera guided port – even the first trocar is inserted under vision
- Safe in patients of previously done surgeries
- Decreased incidence of bowel injury
- In long instrument → it has long channel and has a radiate to hold on to a tissue
  It is having insulation on the metal structure inside
- If there is insulation break, from there current will go laterally and damage the bowel near by
- So, we should check for insulation damage before surgery
- If bowel injury – patient comes with delayed bowel perforation and peritonitis

Physiological effects in laparoscopy 01:09:25

- There is peritoneal cavity inside abdomen. We insufflate gas into this cavity and then do surgery
- When we insufflate gas – first thing happens is peritoneal stretching and it cause vagal stimulation so

suddenly the pulse rate drops to 30/40 also in some patients (sinus brady cardia)

- The most common arrhythmia is sinus bradycardia during surgery
- The gas can compress the IVC and decrease the venous return of blood. So, decrease C.O and decrease S.B.P
- As a compensation to this, the H.R may increase during procedure.
- The diaphragm is pushed upwards, so, all the values in lung are decreased like TLC, R.C etc.

  The lung is compressed and so the anesthetist has to give more PEEP
- There is increase ICT
- Decrease of renal blood flow → so renal output decrease

  All these features equal to abdominal compartment syndrome
- Metabolic acidosis may also happen (Due to CO2 absorption)
- Renin angiotensin system activated, so Na and water retention is seen.

Complications in laparoscopy 01:14:16

1.Bleeding from trocar site

- Direct closure by figure of 8 suture
- Foleys bulb for 24 hours

AfraTafreeh.com

2.If bile (or) bowel contents coming out of trocar, then don't remove the port and remain it. Then put another port and see what happened, sometimes we may enter only one side of bowel, so from other port, repair it.

If we remove the first port, we may bot identify the site of puncture

- If it is manageable by lap, manage it and if it is not manageable, then convert it into open and repair it.

3.Capacitance coupling injury → it is a complication of monopolar diathermy injury

- The part is made up of metal and the cuff is by plastic / rubber
- Through this port we pass instrument and operate
- Current passes through instrument
- If current is passed through an insulated device, between 2 metal components, there will be an electrical energy created on the metal even w/o damage of insulator → called capacitance current.
- This electrical energy can damage any bowel closely attached with it. This damage is capacitance coupling injury
- So, to prevent this we have to use a fully metal port, that will transport current to abdominal wall (act as earth plate) and do not cause injury to bowel

TUTORIALS LOGIN FOR SUCCESS

- If rubber/plastic, they won't conduct to wall, then go to bowel and injury it.
- The bowel will be damaged without our knowledge and patient develops bowel injury, necrosis, peritonitis
- Direct coupling injury → if insulator is broken
- Indirect coupling injury → while operating we touch another metal part, it causes injury to bowel

Demerits in laparoscopy

- Long learning curve
- Loss of tactile sensation
- 2D vision (now-a-days 3D camera available)
- Difficulty in controlling intra op bleeding
- Time consuming
- Complicated set of instruments

TUTORIALS
LOGIN FOR SUCCESS

SILS/SPA/LESS →(Laparoscopic single site surgery)

01:26:02

- Single port with multiple channels passing through umbilicus
- It is scar less surgery
- SILS – single incision laparoscopic surgery
- SPA – single port access
- It is a 15mm umbilical port
- Major disadvantage – instruments have complicated ergonomic design

AfraTafreeh.com

- Patient has high chance of developing port site hernia
- After lap surgery, the gas CO_2 can retain inside and irritate the diaphragm and patient may complain of shoulder pain
- In 48 hours, gas gets absorbed and patient is relieved just give paracetamol

HALS – Hand assisted lap surgery 01:29:38

- We will also put hand inside and retract the spleen/bowel etc.
- Main advantage – after splenectomy, we can remove spleen through hand assisted port itself
- Endoscopy with multiple channels → it is passed through rectum/vaginal / mouth / bladder and can do operation called as NOTES – Natural orifice transluminal endoscopic surgery
- There is no port or no scar

TYPES –

- POEM – per oral endoscopic myotomy (Oral cavity for achalasia)
- Trans oral cystogastrostomy, we can put a stent between cyst and stomach
- TOGA – Transoral Gastroplasty (Bariatric surgery)
- ROSE – Restorative obesity surgery end luminally → bariatric surgery
- TAMIS – Trans anal minimally invasive surgery

VATS: - video assisted thoracoscopic surgery

01:33:02

- We can do esophagectomy, pneumonectomy, tumors in chest
- We insufflate 5-8 mmHg CO_2 only
- Main method creating space is by collapsing one lung
- If we operate on R side, we collapse R side lung, by putting a biluminal ET tube

Robotic surgery: - 01:34:46

- Surgeon sits in a console, with a joystick
- Robot is called Davinci Robot
- Assisting surgeon stands near patient and do Docking that is fixing the laparoscopy to the instruments. Ports we have to put (Robot don't) and connect it to robot and introduce robotic hand inside

AfraTafreeh.com
DOC TUTORIALS
LOGIN FOR SUCCESS

Advantages: -

- Tremor reduction
- 3D vision
- More degree of freedom – 7 degrees
- Better dissection
- Fine suturing
- scaling of movement
- More ergonomic
- Comfortable operating set up
- Telerobotic possible

AfraTafreeh.com

OPERATION THEATRE PROTOCOLS

Zones in OT 00:00:30

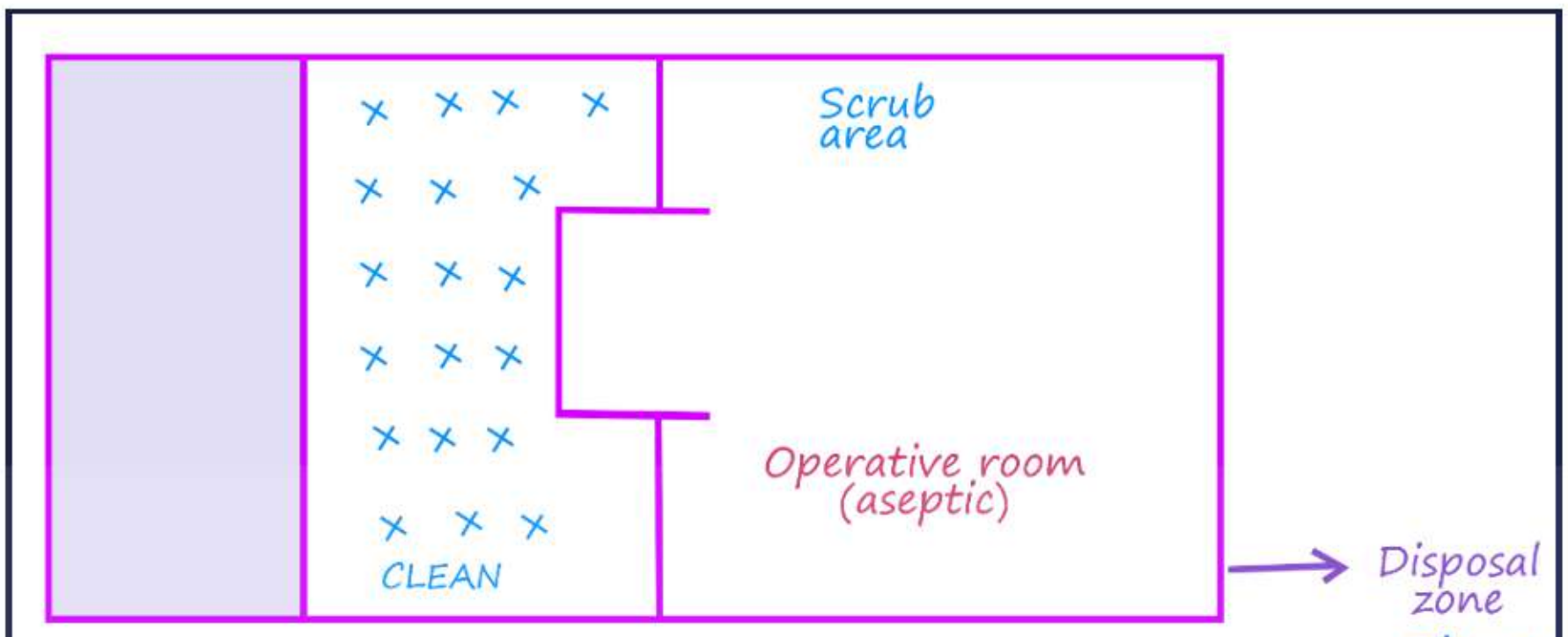

Fig: 1

Protective zone

- Changing OT dress
- Anesthesia HOD room
- ICU
- Post anesthesia care unit

Zones in OT

1. P – Protective zone
2. C – Clean zone
3. O – Operating (aseptic)
4. D – Disposal zone

- Scrub done in aseptic zone
- Instruments addressed in clean zone

Air flow

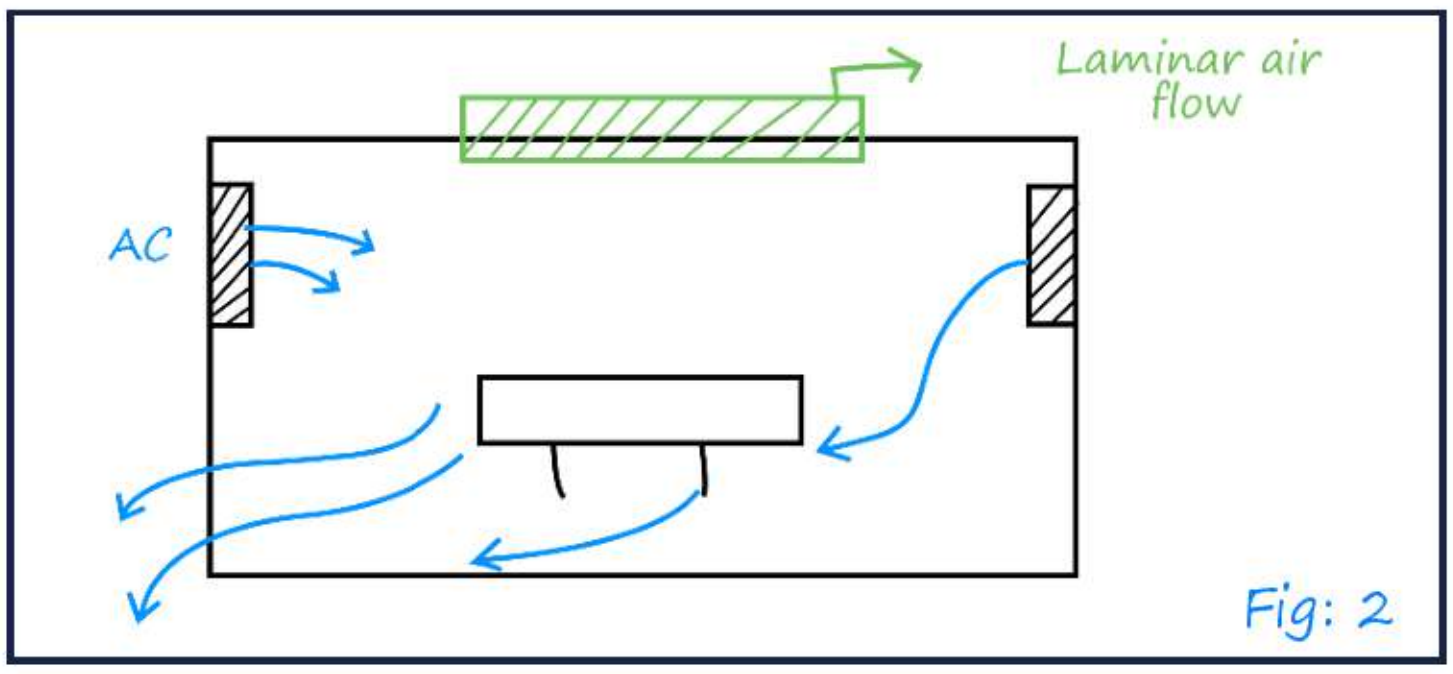

- In Ⓝ OT: - 15-25/ hours
- Laminar air flow: - 100-300/ hours

  ↓ 2/min

  Used in orthopedic, CTVS theatre
- Ⓝ temperature of theatre: - 18-22°c
- Humidity: - 50-60%

WHO protocol surgical safety 00:07:51

1.Sign in: -

- Before induction of anesthesia
  - Name
  - Age
  - Disease
  - Site marked [Q]
  - H/O drugs allergy
  - H/O medication
  - H/O DM, HTN
  - Consent – written/ oral

    ↓

    > 1% risk of any complaints to be explained in consent

AfraTafreeh.com

2.Time out: -

- Surgeon
- Anesthetist
- Staff nurse
  - Individually examine the patient
  - Introduction
  - Anticipated blood loss
  - Time duration
  - Confirm the site and disease

↓

Best method to prevent operating wrong limb

↓

Surgeon and anesthetist should individually examine the patient

- Prophylactic antibiotic given before 1hour of incision

TUTORIALS
LOGIN FOR SUCCESS

3.Sign out: -

- Before shifting out of OT room
  - Gauze count
  - Pad count
  - Instrument count
  - Amount of blood lost
  - 1 pad soaked – 500ml
  - Any event or reaction during S_x
  - Instrument malfunction should be noted
- Sign In – Before induction of anesthesia

- Time out – Before skin incision
- Sign out – Shifting out OT

Universal precaution kit (PPE Kit) 00:19:45

- Using for
  - HIV
  - HbsAg
  - HCV
- Now used for covid-19

Components

- Respirator/ N95 mask/ surgical mask
- Face shield/ Goggles
- Double gloves

AfraTafreeh.com

Inner	**Outer**
↓	↓
Bigger	Normal

TUTORIALS
LOGIN FOR SUCCESS

- Plastic apron/ Gown
- Boots
- Please put HIV/ HbsAg/ HCV cases as 1st/ only case
- Transfer of objects done using kidney tray
- Restricted people inside OT
- All these should be disposed in proper containers
- Wash → Scrubbing [Q]
- Wearing a PPE kit
- Removal of PPE kit [QQ]

AfraTafreeh.com

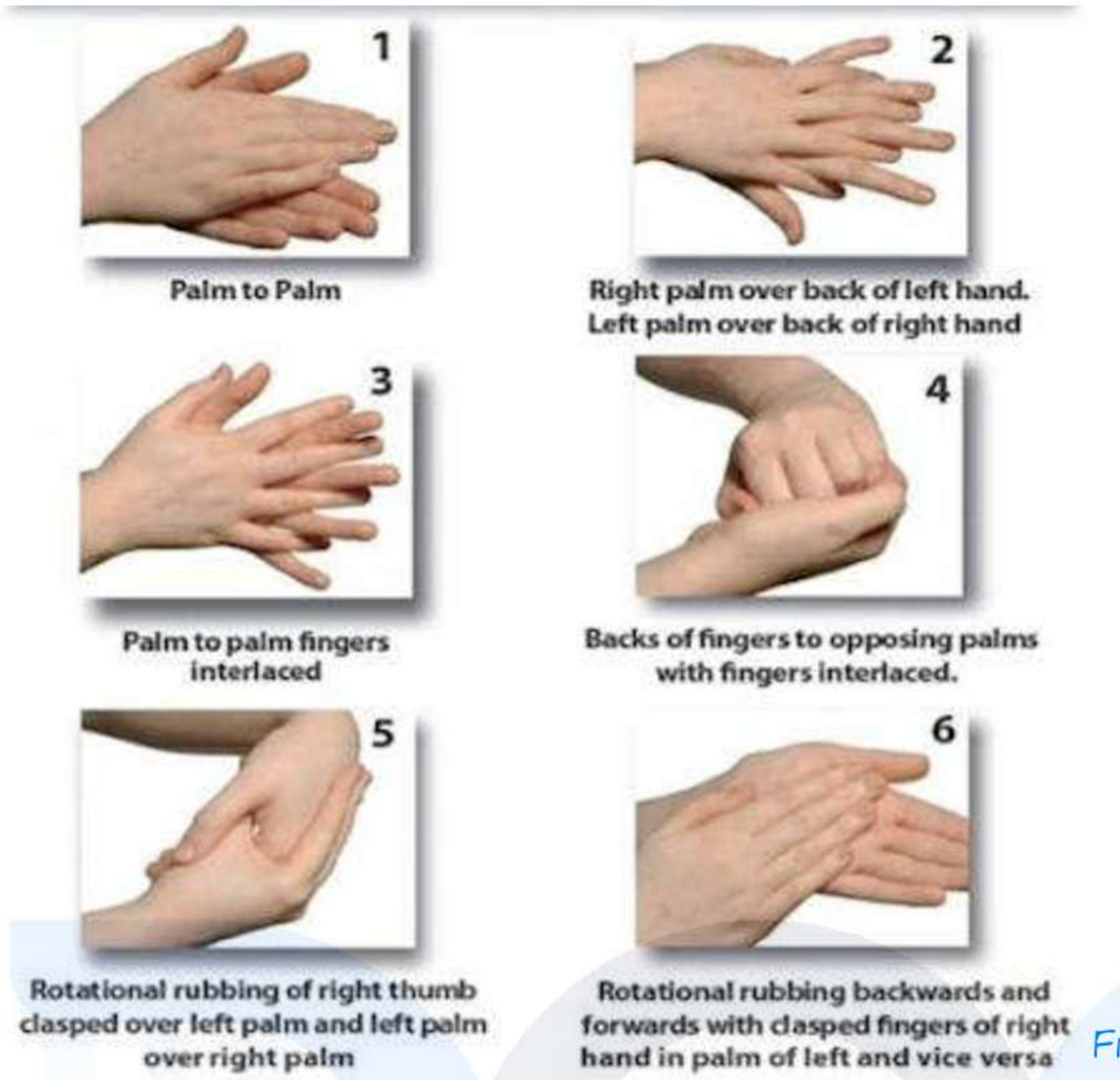

Fig: 3

Sequence of Putting on **Personal Protective Equipment (PPE)**
The type of PPE used will vary based on the level of precautions required, such as standard and contact, droplet or airborne infection isolation precautions. The procedure for putting on and removing PPE should be tailored to the specific type of PPE.
1.GOWN - Fully cover torso from neck to knees, arms to end of writs, and wrap around the back - Fasten in back of neck and waist

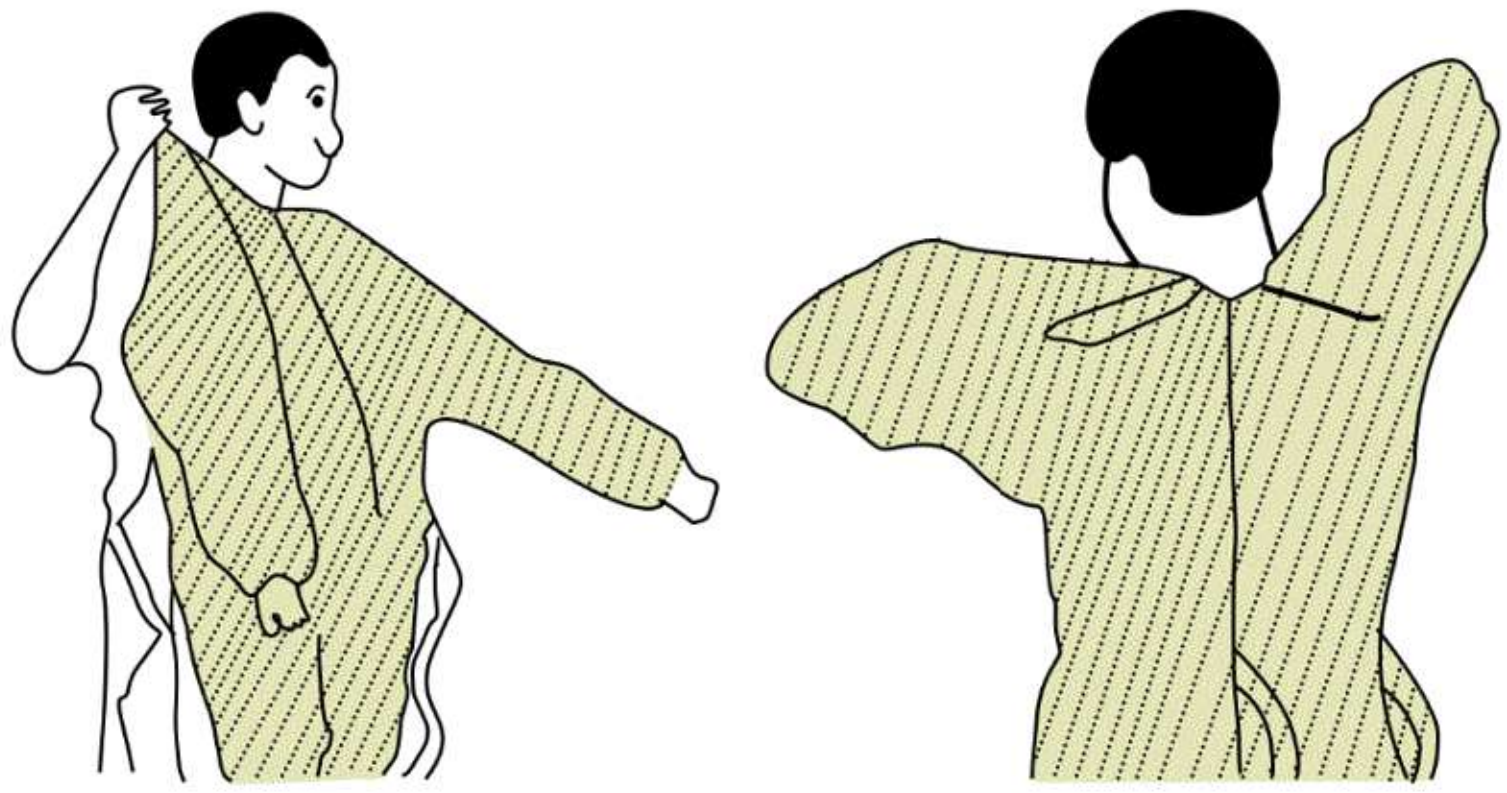

2.Mask of Respirator

- Secure ties or elastic bands at middle of head and neck
- Fit flexible band to nose bridge
- Fit snug to face and below chin
- Fit check respiratory

AfraTafreeh.com
TUTORIALS
LOGIN FOR SUCCESS

3.Googles or Face shiels

- Place over face and eyes and adjust to fit.

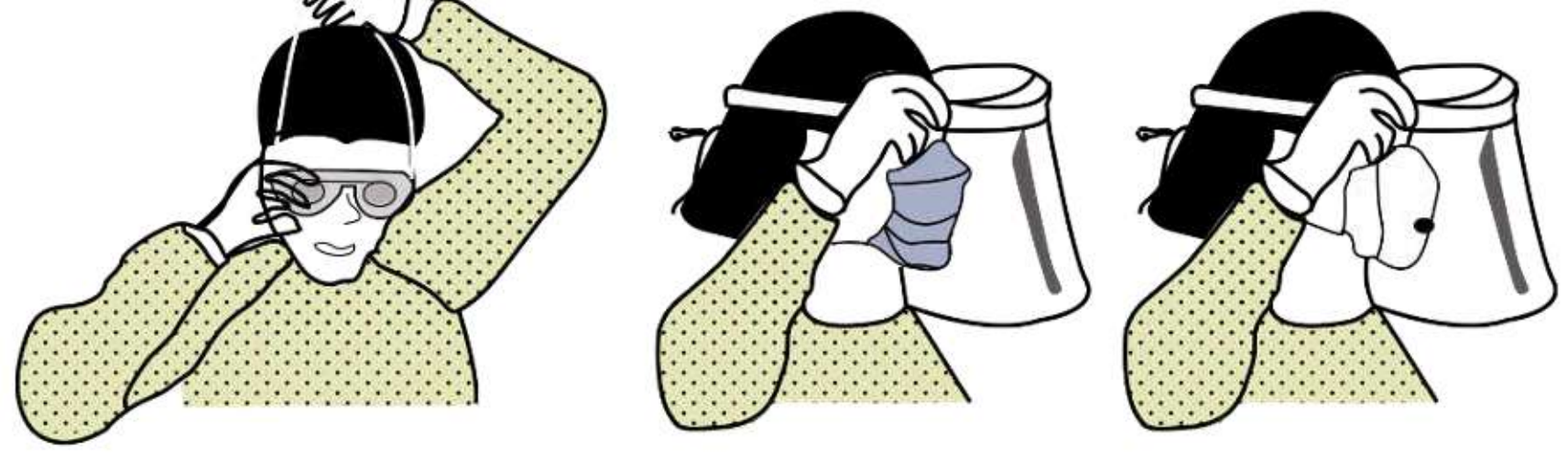

4.Gloves

- Extend to cover wrist of isolation gown.

AfraTafreeh.com

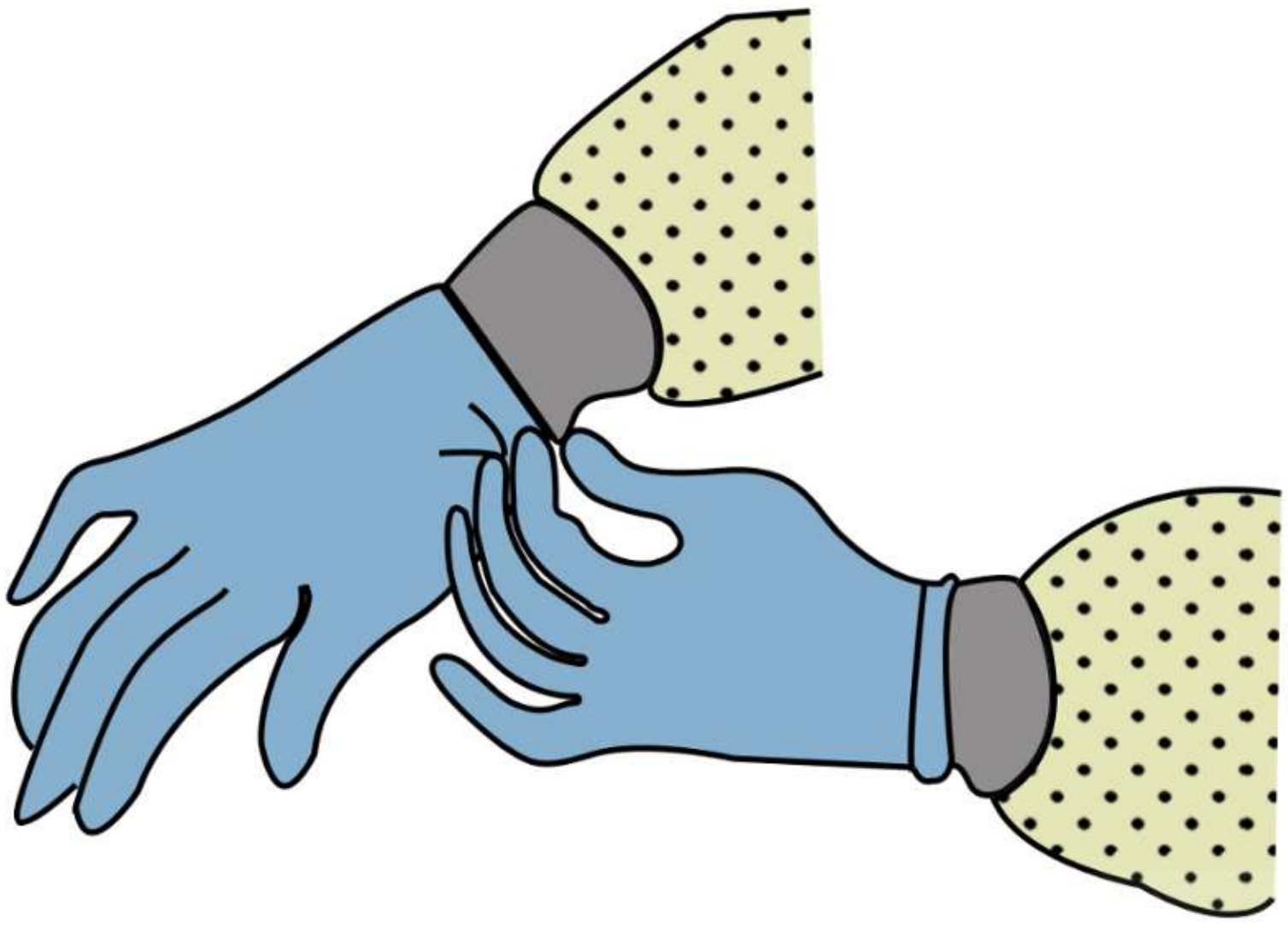

Use safe work practices to protect yourself and limit the spread of contamination

- Keep hands away from face
- Limit surfaces touched
- Change gloves when torn or heavily contaminated
- Perform hand hygiene

Sequence for removing Personal Protective Equipment (PPE)

Except for respiratory, remove PPE at doorway or in anteroom. Remove respiratory after leaving patient room and closing door.

1.Gloves

- Outside of gloves is contaminated
- Grasp outside of glove with opposite gloved hand; peel off
- Hold removed glove in gloved hand

- Slide fingers of ungloved hand under remaining glove at wrist
- Peel glove off over first glovet
- Discard gloved in waste container

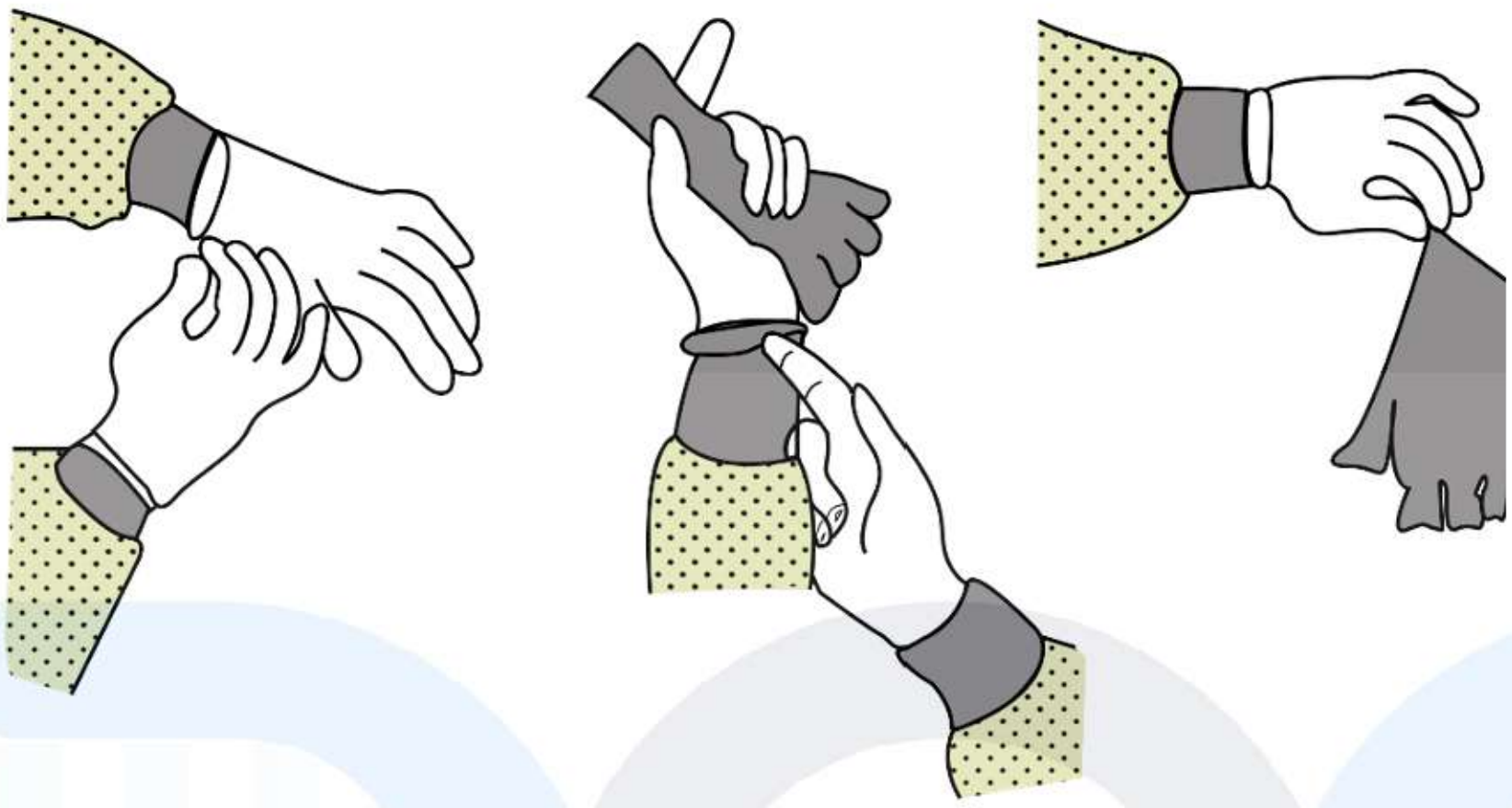

2.Googles or face shield

- Outside of googles of face shield is contaminated!
- To remove, handle by head band or ear pieces
- Place in designated receptacle for reprocessing or in waste container.

3.Gown

- Gown front and sleeves are contaminated!
- Unfasten ties
- Pull away from neck and shoulders, touching inside of gown only
- Turn gown inside out

AfraTafreeh.com
TUTORIALS
LOGIN FOR SUCCESS

AfraTafreeh.com

- Fold or roll into a bundle and discard.

4.Mask or Respirator

- Front of mask/respiratory is contaminated – Do not touch
- Grasp bottom, then top ties on elastics and remove
- Discard in waste container

TUTORIALS LOGIN FOR SUCCESS

Needle Injuries 00:35:02

- Hollow needles have more risk of injury than surgical needles
- MC finger injured during surgery – NON-DOMINANT HAND INDEX FINGER

SURGICAL SITE INFECTION

Types of surgeries 00:00:16

1. Clean surgery
   - Surgery in which we don't open any cavity and we are not contaminating the operative field by any bacteria
   - E.g.: Hernia operation
   - Thyroid operation
   - Breast operation
   - Heart operation
   - Any small swelling like lipoma, orthopedic surgery
2. Clean contaminated surgery
   - We are going to contaminate E.g., we open the bowel for GJ, PJ/Stomach/Biliary system for biliary enteric anastomosis, uncomplicated appendicitis
3. Contaminated surgery
   - Cavity opened by itself and bacterial spillage is seen
   - E.g.: Diverticulitis
   - Perirectal abscess
   - Appendicular abscess
   - Infected laceration

   (Diverticulitis, Perirectal abscess, Appendicular abscess, Infected laceration: **The Lumen gets opened & abscess collected**)
4. Dirty wound:
   - It is worst wound full of spillage of pus
   - Acute cholecystitis – Purulent & heavy contamination is seen
   - E.g: Traumatic wound, bowel obstruction and perforation

AfraTafreeh.com

Prophylactic antibiotic –

- Always in surgery we give prophylactic antibiotic, it is given one hour before skin invasion we give one dose usually 3rd generation cephalosporin
- If surgery extending >4hrs another dose is given. for every 4hrs extension, we have to give one dose
- A prophylactic antibiotic is given maximally for 24hrs only, after 24hrs no need to give an antibiotic
- Antibiotic is restarted whenever there is a documented infection based on pus C/S report

	No prophylactic antibiotic	**Prophylactic antibiotic**
1.Clean wound → Here we can avoid prophylactic antibiotic as risk is some	1% risk of SSI	1% SSI
2.Clean contaminated	5-10%	3%
3.Contaminated	10-20%	6%
4.Dirty	40%	<9% (**7%**)

Surgical site infection (SSI) 00:10:52

- Nothing but a wound infection
  1.Occurring within <30days of surgery
  2.<1year of prosthesis keeping (Mesh, implant, valve)
- Most common organism is
  1.Staph epidermidis
  2.S. aureus

- For infra inguinal incisions and opened cavities (Biliary, abdominal) → E. coli > Klebsiella
- 2 Grading systems for SSI

1.Southampton grading system

- Grade I – E – Erythema in the wound
- Grade II – I – Inflammation wound
- Grade III – S – Serous discharge from wound
- Grade IV – P – Purulent discharge from wound
- Grade V – A – Anatomical separation of wound

2.Asepsis score

- A – Additional treatment needed from patient giving antibiotic doing I & D, debridement
- S – Serous discharge
- E – Erythema
- P – Purulent discharge
- S – Separation of the wound (Anatomical)
- I – Isolation of bacteria from the wound
- S – Stay prolonged for >14days

AfraTafreeh.com
TUTORIALS
LOGIN FOR SUCCESS

Prevention of SSI 00:16:54

1.1hour before invasion give prophylactic antibiotics
2.During surgery every 4hrs another dose is given
3.Avoid hyperglycemia intraoperatively (>200mg/dl)
4.Avoid hypothermia
5.Avoid hypotension
6.Avoid hypoxia intra op and also post OP, so give post OP O2 for 4 hours at least
7.Shaving is no more recommended (No preparation needed)

AfraTafreeh.com

- We can do hair epilators (or) hair clippers
- No razors
- No skin hair cream

8. Proper sterile precautions have to be followed

Factors preventing the wound healing

a. Patient factors
   - Patient with malnutrition (↓)
   - Chronic diseases like DM, CKD, CAD
   - Hypercholesterolemia
   - Obesity
   - Jaundice
   - Old age

b. Surgery/Surgeon factors
   - Emergency surgery is more common cause than elective surgery (Good) Poor prognosis
   - Absorbable sutures > Non absorbable (Good) Poor prognosis

     ↓

     May lead to breakage of wound
   - Improper techniques of closure Jenkins's rule → Length of suture = 4 x length of incision

Post-operative fever 00:24:42

- Example: We have done a laparotomy & Closure done
- 1st post OP Day → A → Most common cause – Atelectasis of lung because of pain, patient is not talking deep breath
  - We should advice patient to do infective spirometry
- 2nd post OP Day → B → Bladder infection

- Foley's catheter gets infected
- It is most common hospital acquired infection → UTI
- Also look for atelectatic lung if it is not expanding
- It can go for pneumonia
- To prevent it removes foley's on 2nd day it self

- 3rd post OP Day → C → Catheter related infections superficial thrombophlebitis
  - Change catheters on 3rd day, otherwise it goes for superficial thrombophlebitis
- 4th post OP Day → D → DVT
  - Prevented by – Early mobilization
  - Pharmacological methods like LMW heparin and mechanical like pneumatic compression devices
- 5th POD → S (5 is looking like S)
  - SSI – Surgical site infection
  - Most common organism – Staph epidermidis or E. coli based on operation
- 6th POD → Burst abdomen → And bowel comes out before burst abdomen & Bowel coming out there is a serious discharge coming out from wound. It is called SALMON sign (Gush of serous fluid)
  - For burst abdomen we do a tight abdominal closure not done now a days because it causes Abdominal compartment syndrome
  - Now a days we do
    1. Bagotta bag closure
    2. Vacuum assisted closure device
- 7th day: Intra-abdominal abscess due to a leakage (or) collection → causes fever with chills and rigors pt

AfraTafreeh.com

is in supine position → Most common site of abscess is hepatorenal pouch/Morrisons pouch

- Pt is in sitting (or) ambulatory position → Collection is most common in the pelvic/Pouch of douglas
  - Over all most common collection is pouch of douglas
  - IOC-CECT abdomen
  - Once diagnosed then do percutaneous drainage USG guided pig tail catheter drainage

Fig: 1

Fig: 2

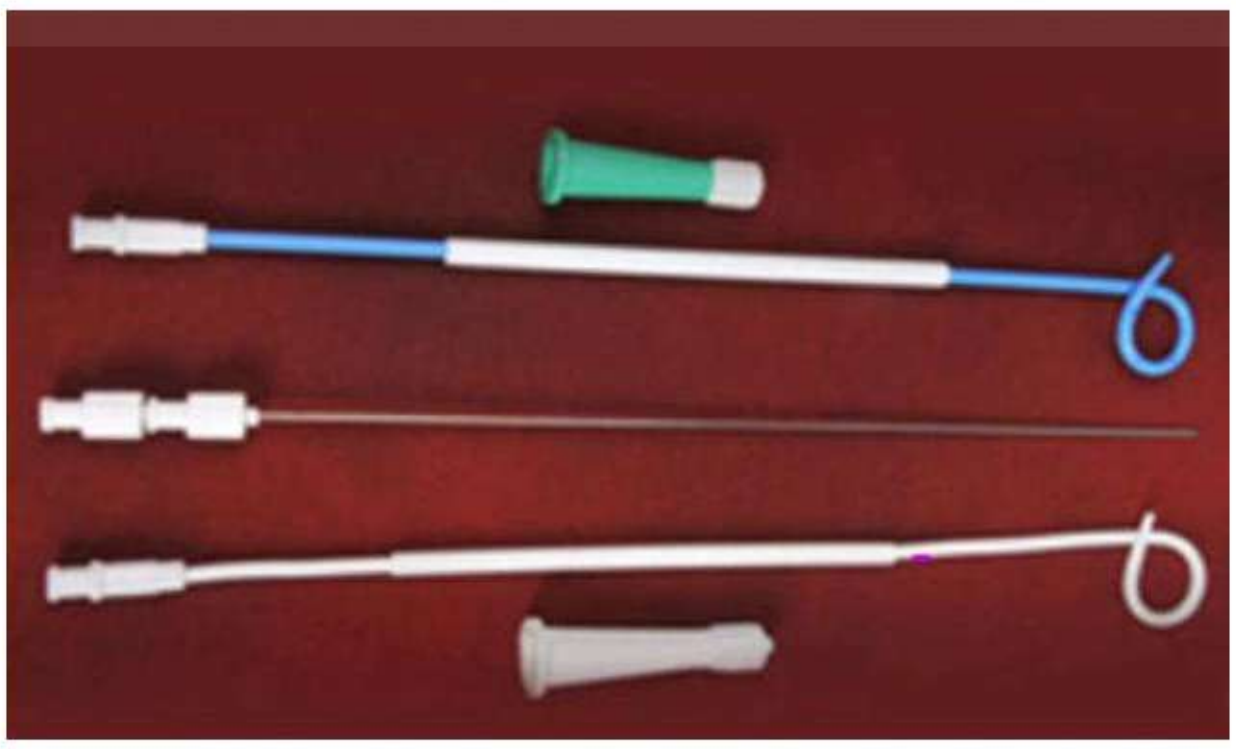

Fig: 3

TUTORIALS LOGIN FOR SUCCESS

INSTRUMENTS USED IN SURGERY

Types of Foley Catheter

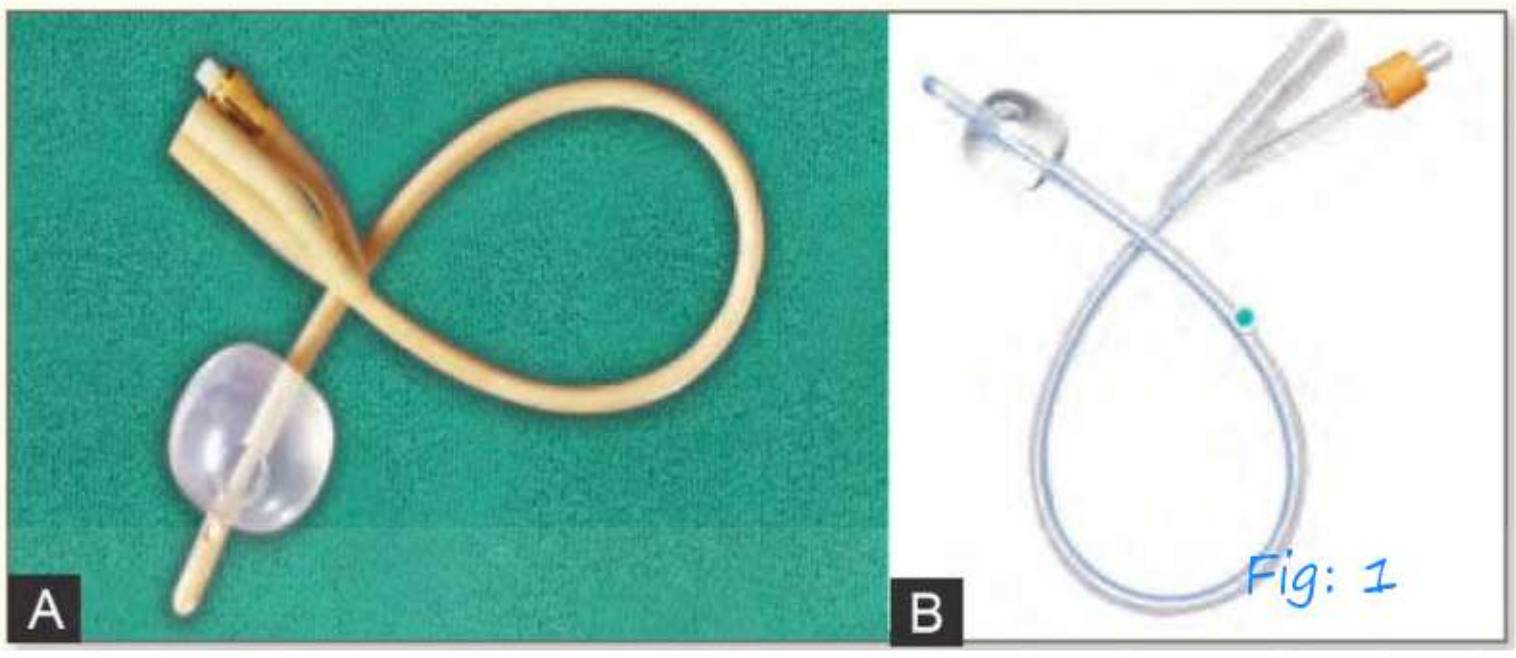

Fig: 1

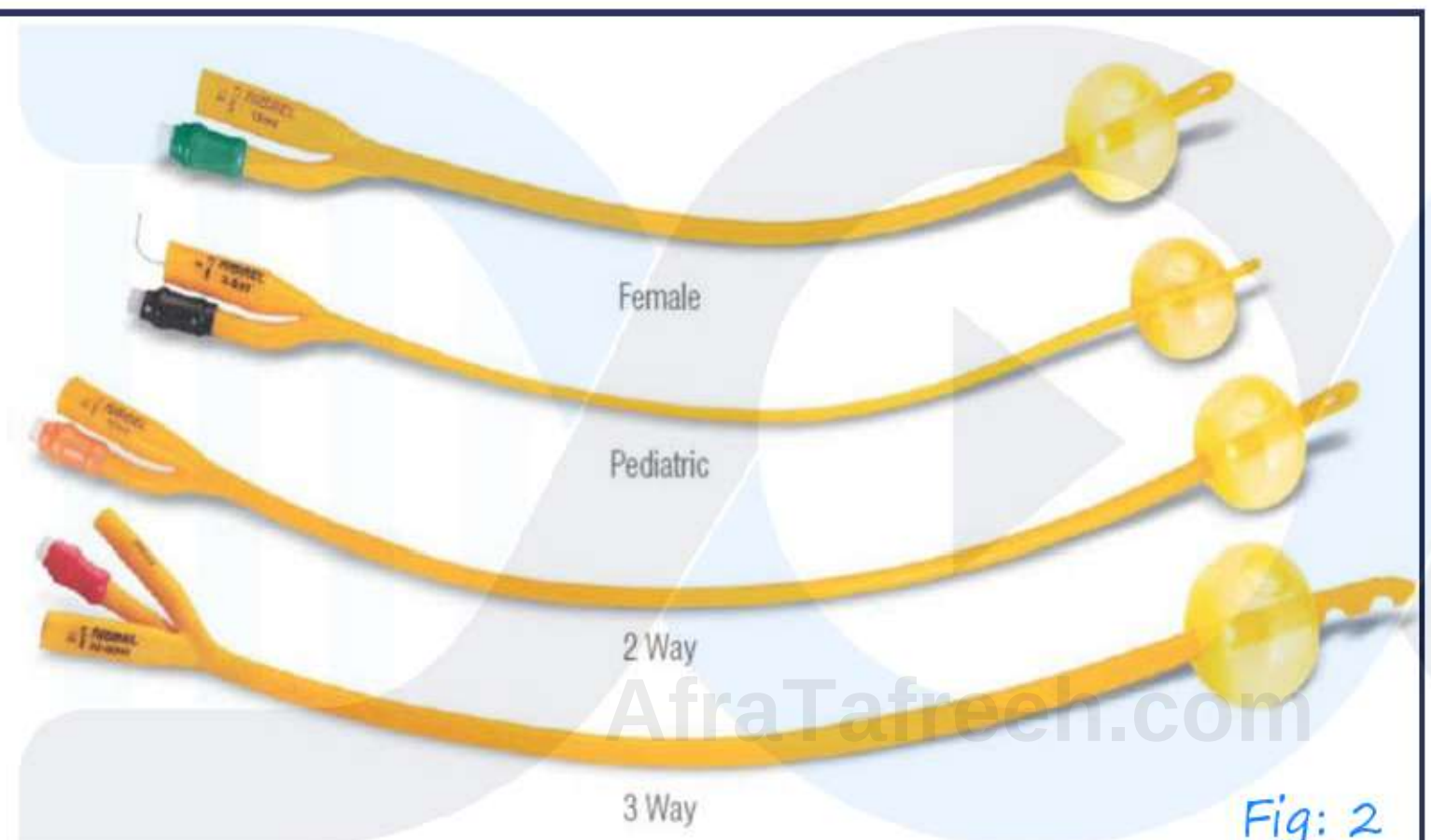

Fig: 2

Foley's colors

Color		Size French	Size Millimeter
	Green	6	2.0
	Blue	8	2.7
	Black	10	3.3
	White	12	4.0
	Green	14	4.7
	Orange	16	5.3
	Red	18	6.0
	Yellow	20	6.7
	Purple	22	7.3
	Blue	24	8.0
	Black	26	8.7

AfraTafreeh.com
TUTORIALS
LOGIN FOR SUCCESS

AfraTafreeh.com

Size of Foley's catheter

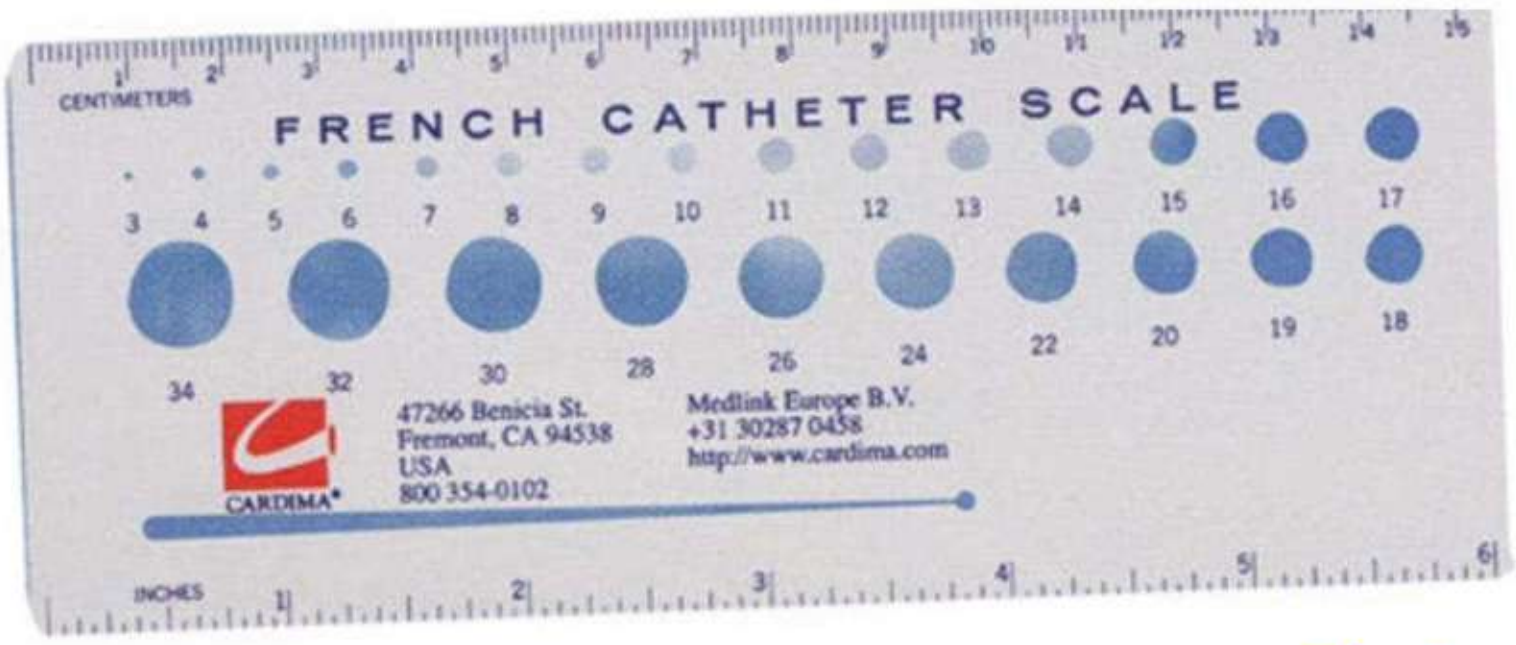

Fig: 3

Mallecot's Catheter

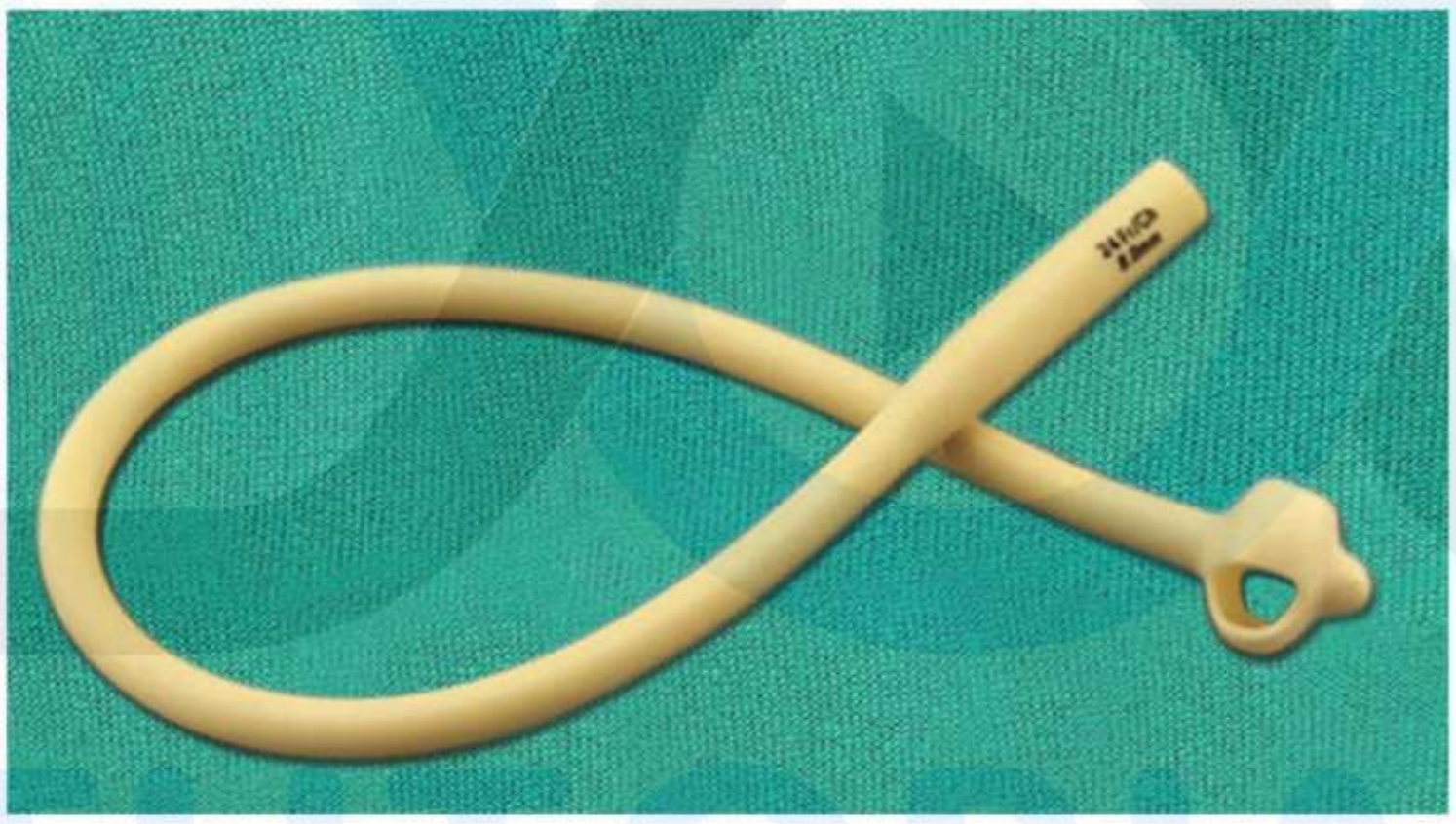

Fig: 4

Deaver's

Fig: 5

TUTORIALS LOGIN FOR SUCCESS

Morris

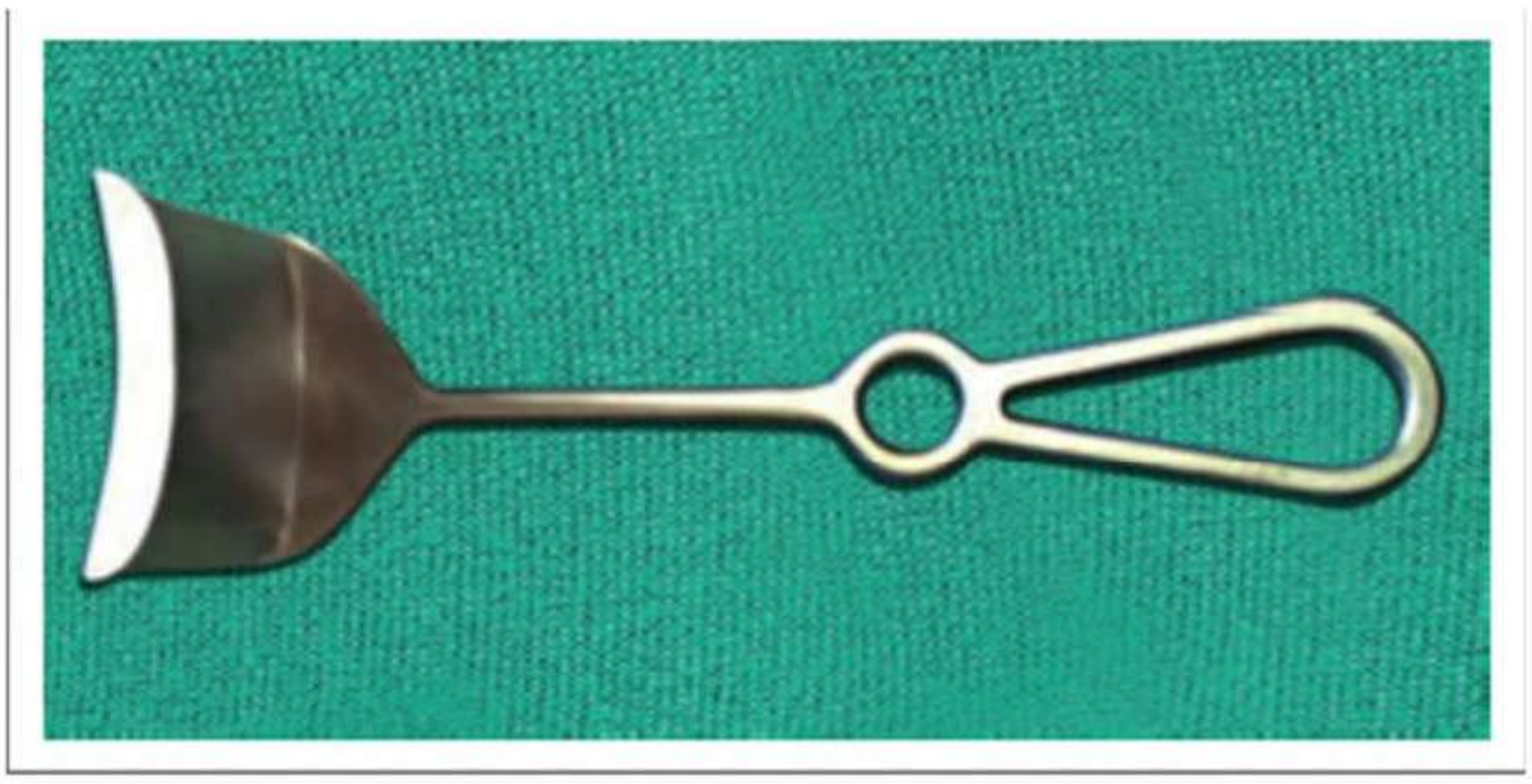

Fig: 6

LangenBack

Fig: 7

TUTORIALS
LOGIN FOR SUCCESS

Czerny

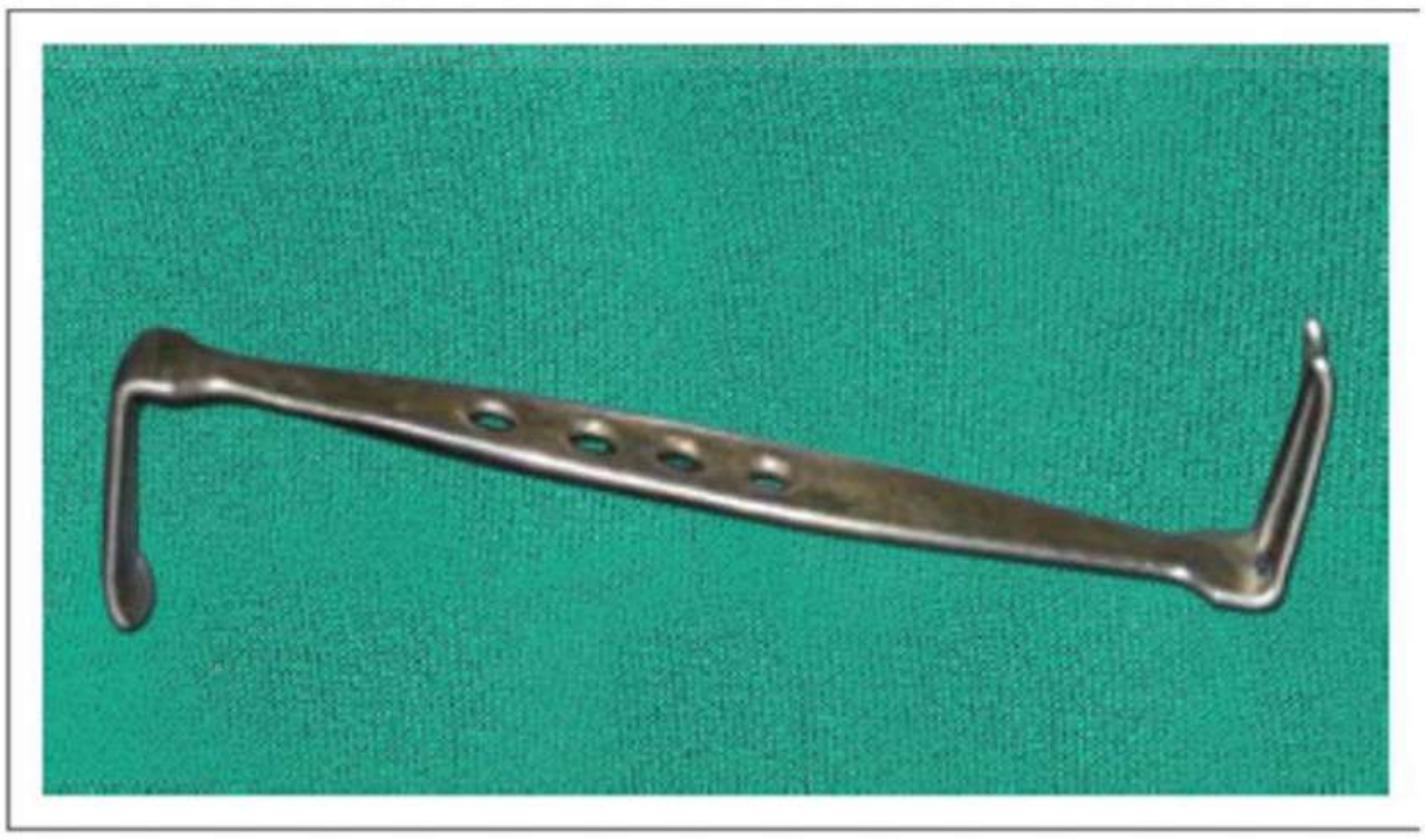

Fig: 8

AfraTafreeh.com

Doyen's

Fig: 9

Thompson

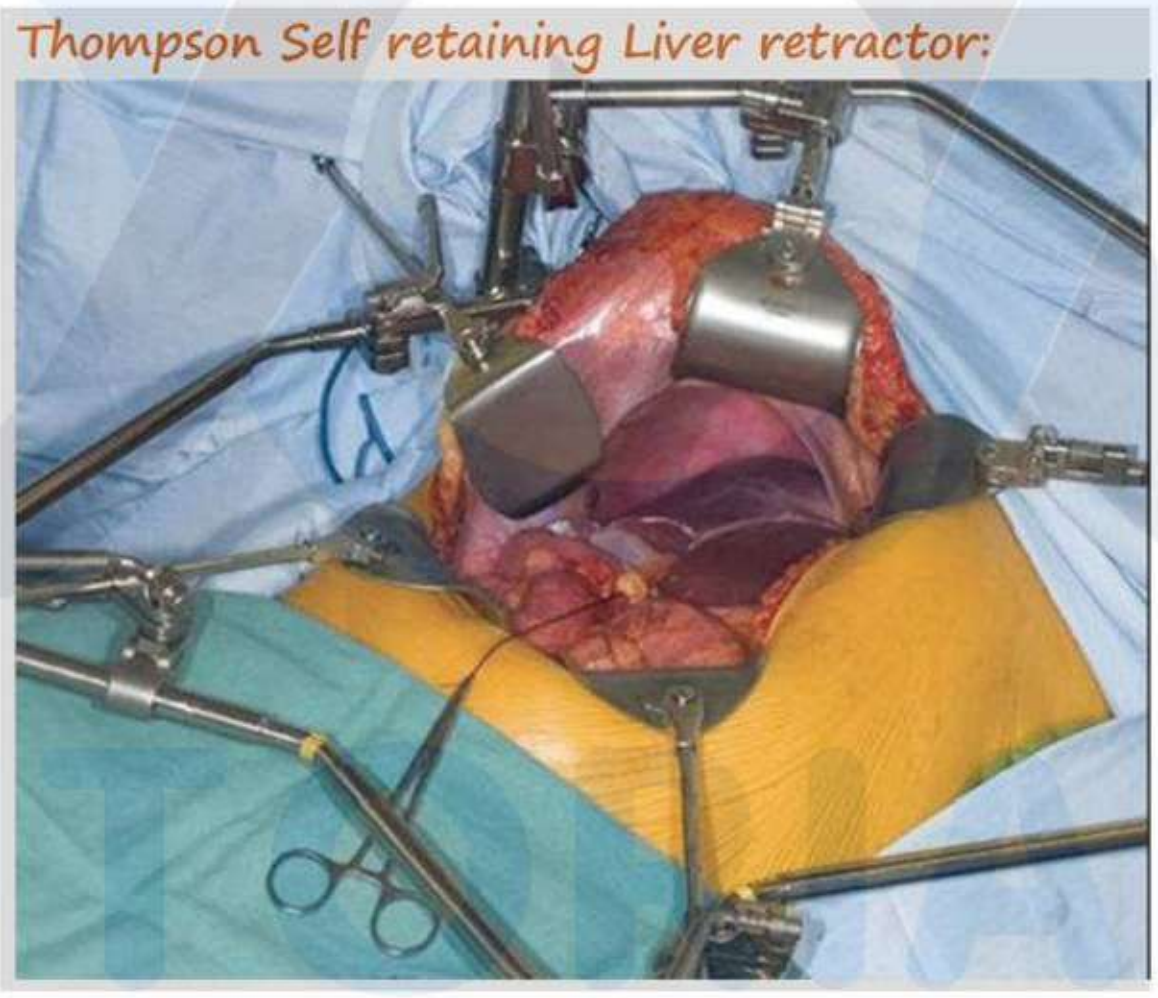

Fig: 10

DOC TUTORIALS
LOGIN FOR SUCCESS

Balfour self retaining Abdominal retractor

Fig: 11

Cat's Paw retractor

Fig: 12

Joll's Thyroid retractor

Fig: 13

Desjardin Stone removal

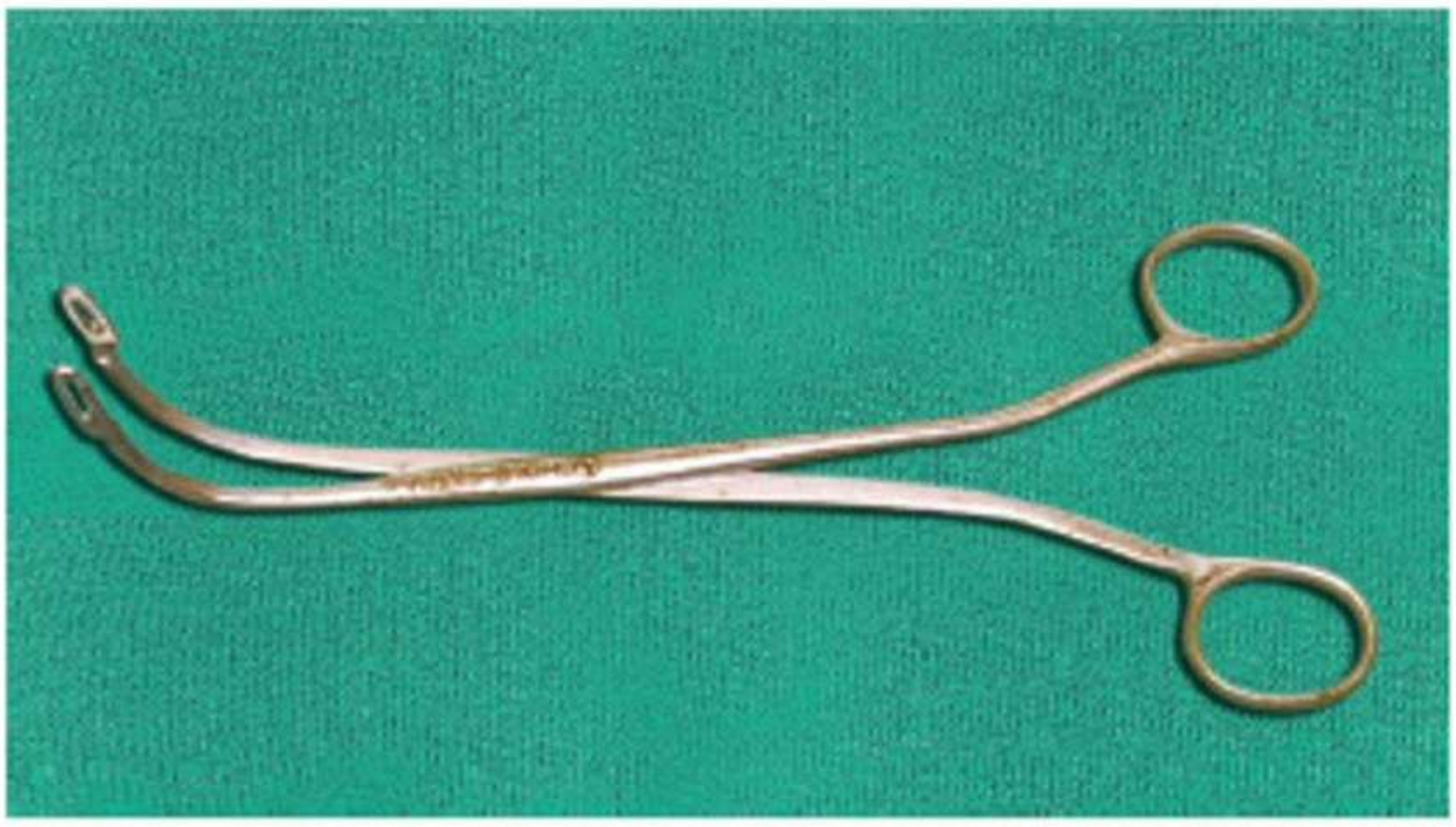

Fig: 14

AfraTafreeh.com
TUTORIALS
LOGIN FOR SUCCESS

AfraTafreeh.com

Allis tissue forceps

Fig: 15

Babcock's Forceps

Fig: 16

TUTORIALS
LOGIN FOR SUCCESS

Kocher's Tissue Forceps

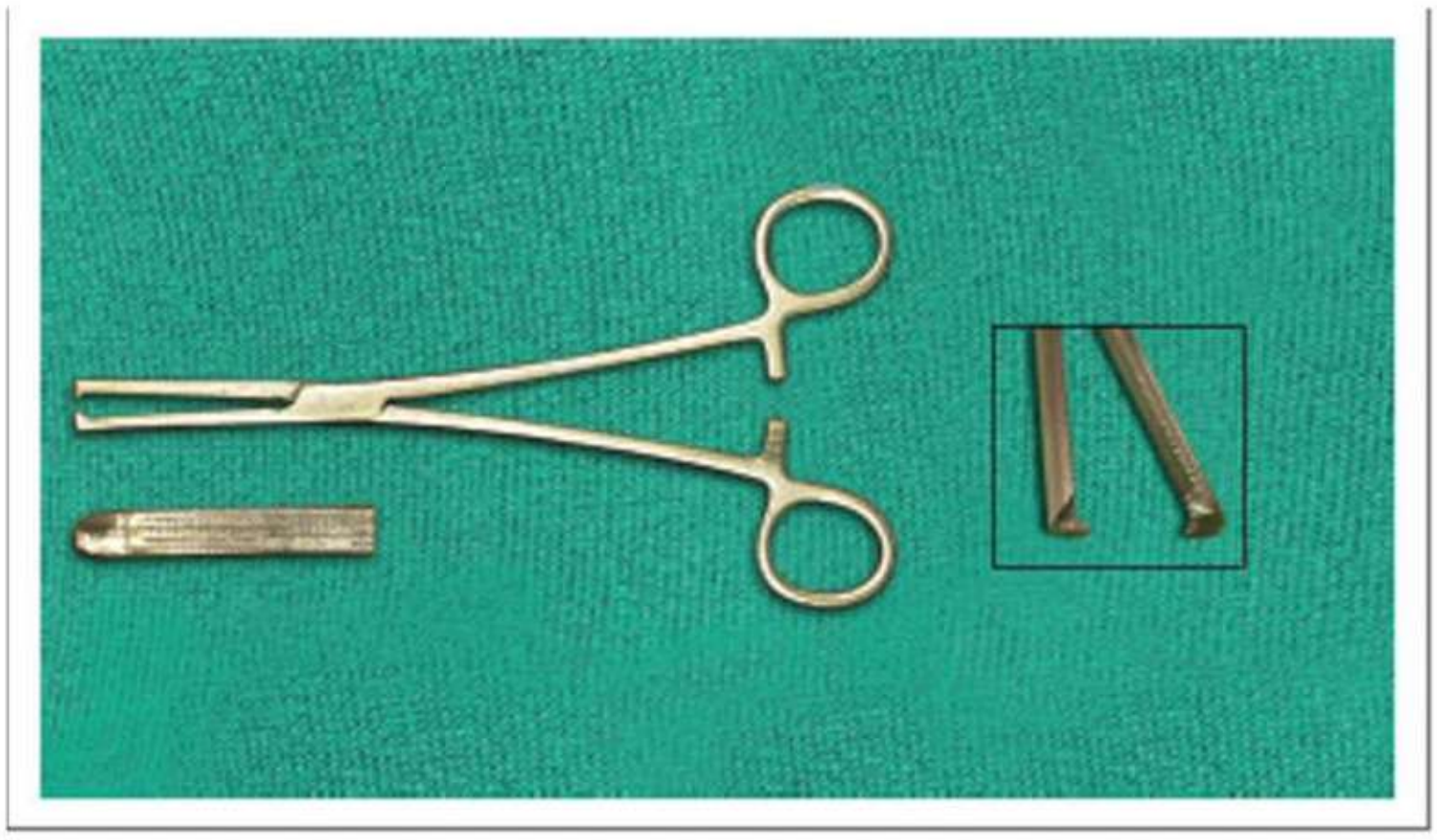

Fig: 17

Lane's Tissue Forceps

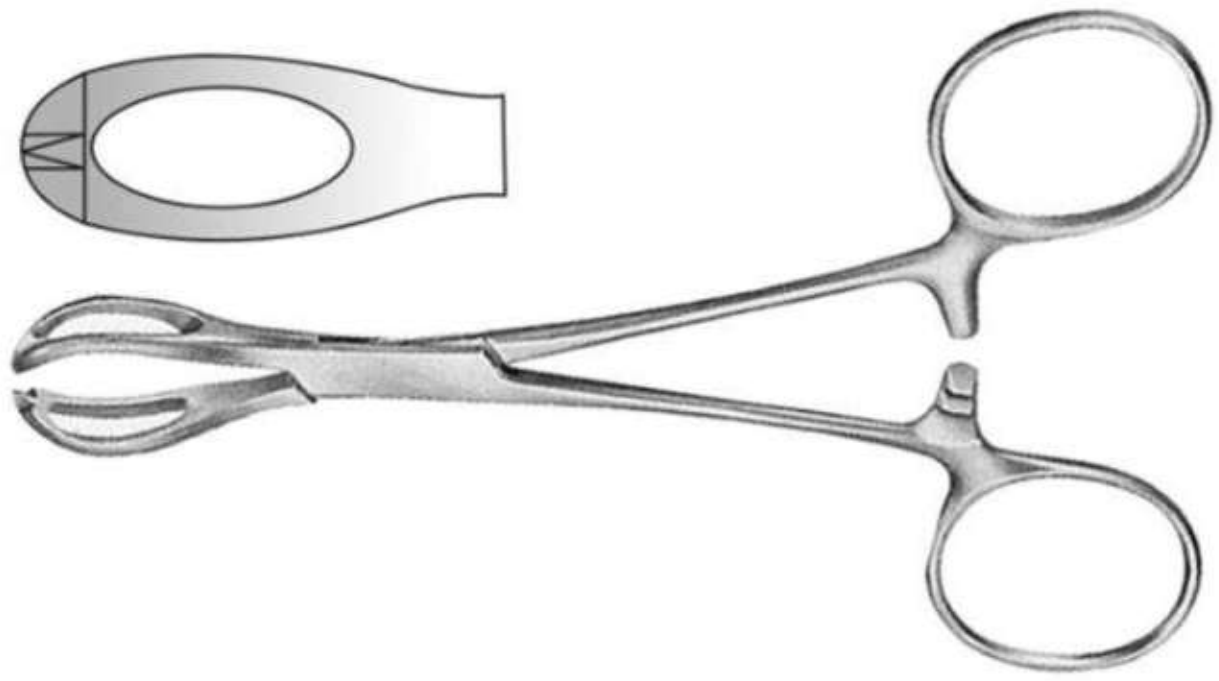

Fig: 18

Cheatle Forceps

Fig: 19

AfraTafreeh.com
TUTORIALS
LOGIN FOR SUCCESS

Needle Holder

Fig: 20

AfraTafreeh.com

Spencerwell's Artery forceps

Fig: 21

Toothed and non Toothed Forceps



Fig: 22

TUTORIALS
LOGIN FOR SUCCESS

Ramples Sponge holder

Fig: 23

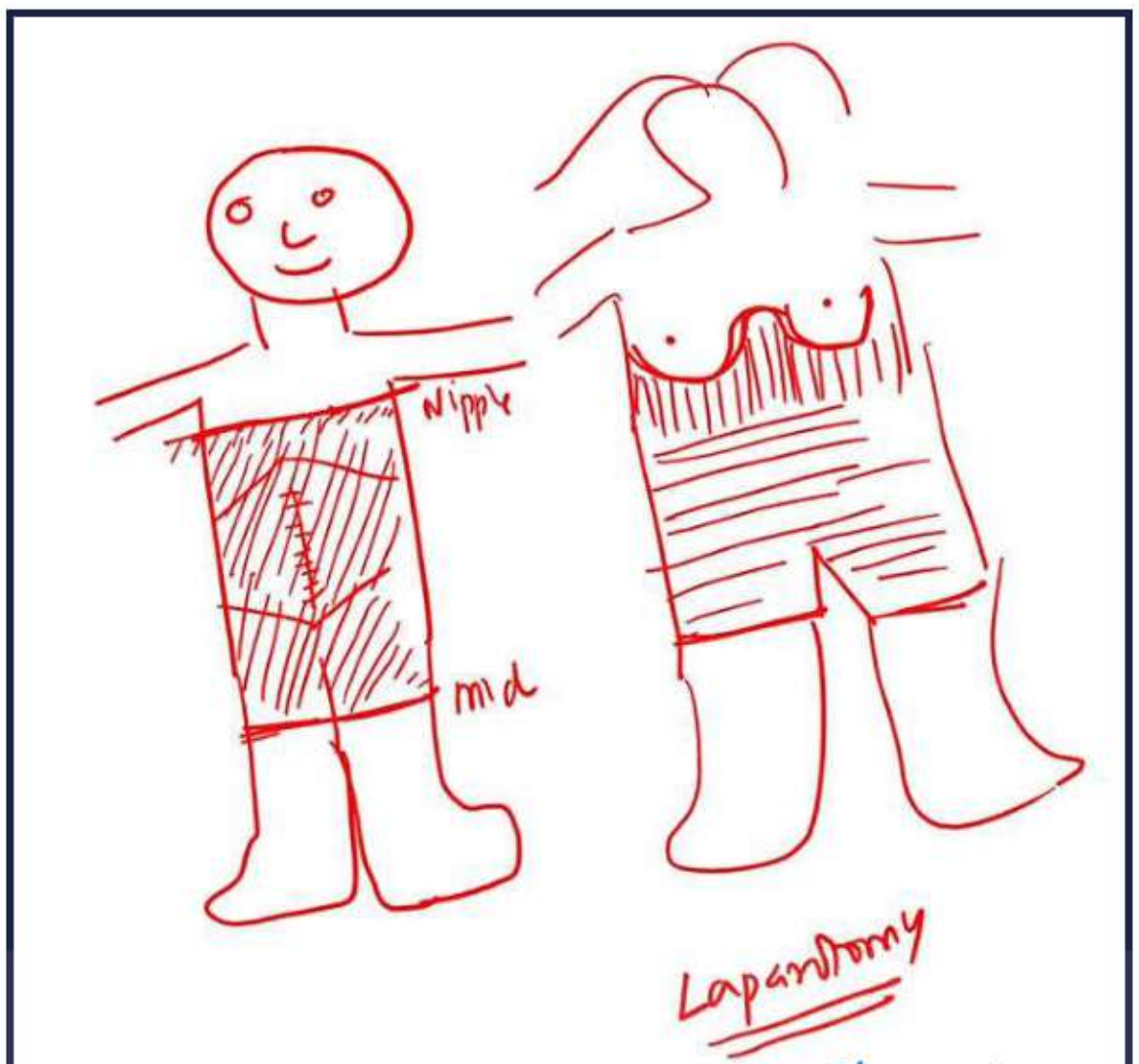

Fig: 24

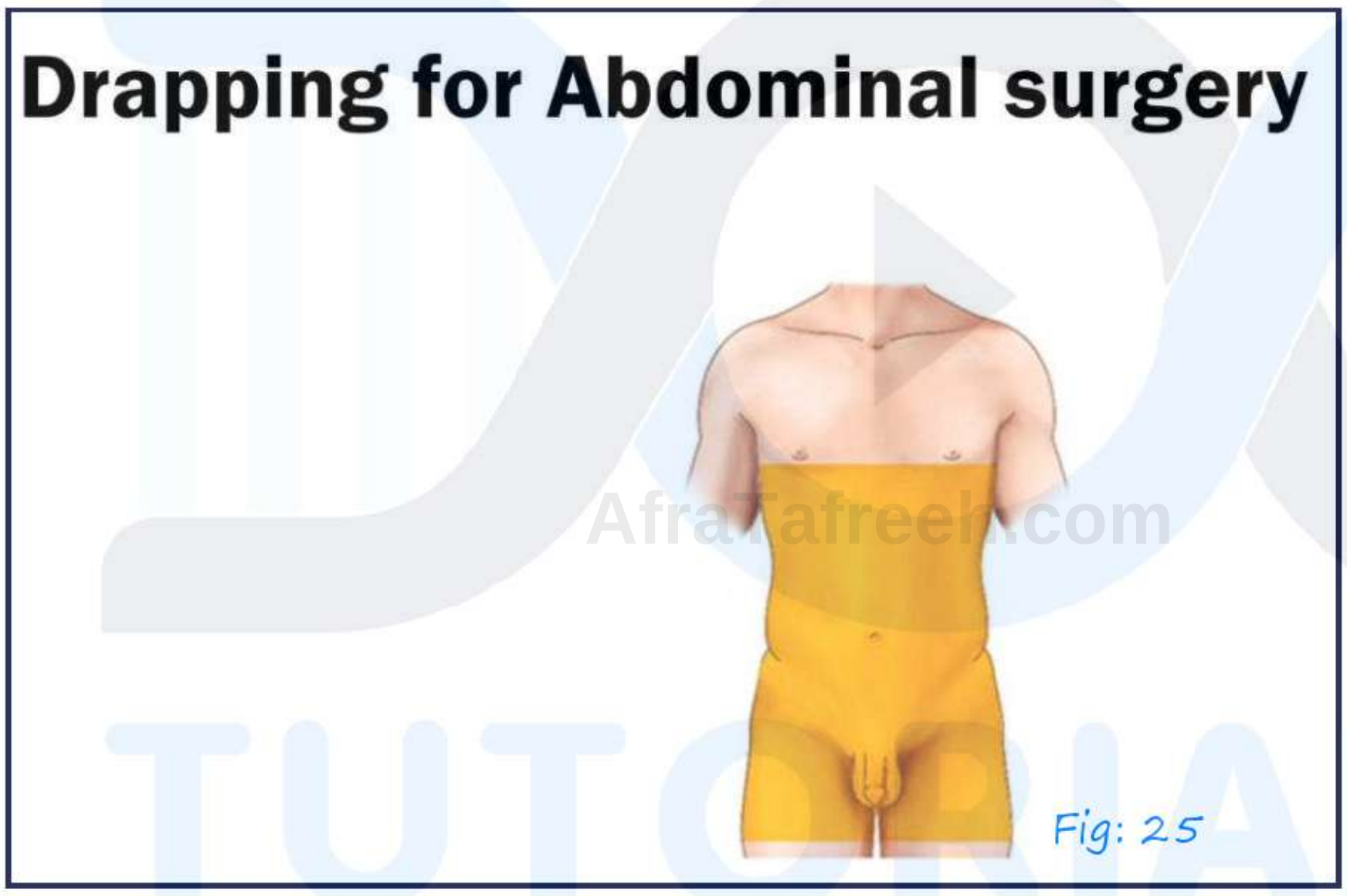

Fig: 25

AfraTafreeh.com
TUTORIALS
LOGIN FOR SUCCESS

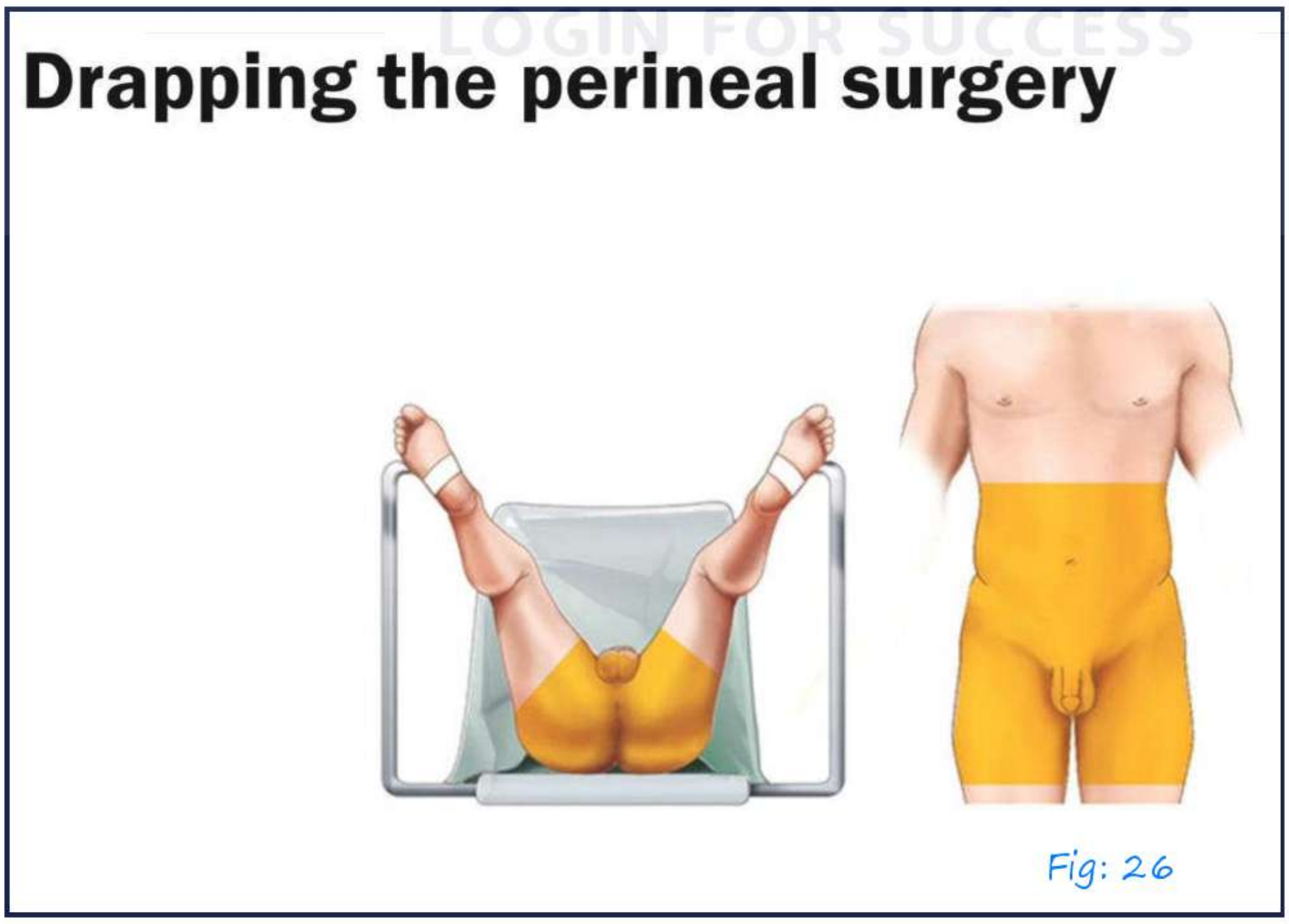

Fig: 26

AfraTafreeh.com

Clamps

Fig: 27

Bull dog clamp

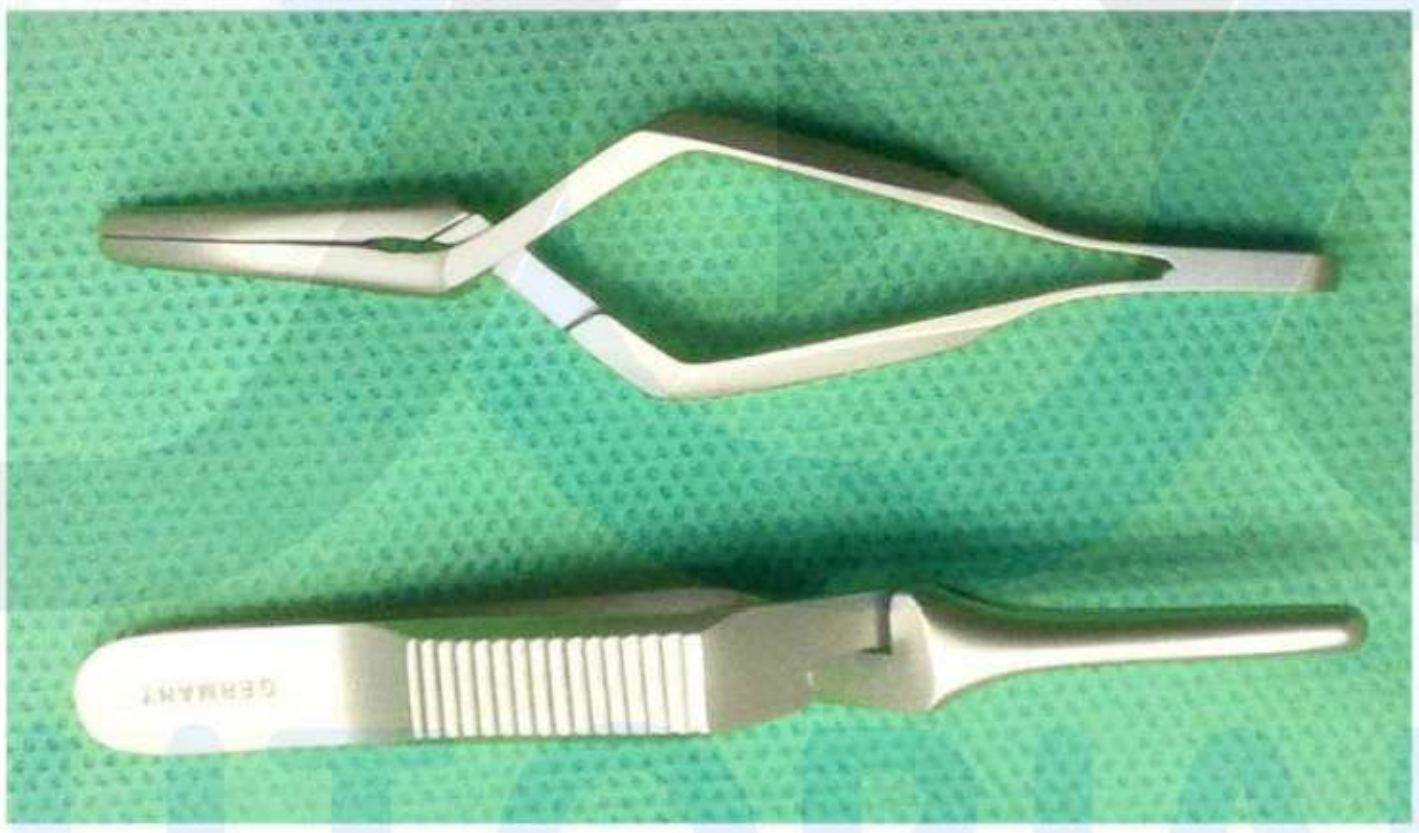

Fig: 28

DOC TUTORIALS
LOGIN FOR SUCCESS

Doyen's Bowel Occlusion clamp

Fig: 29

Satinski's clamp

Fig: 30

Use of Satinsky clamp

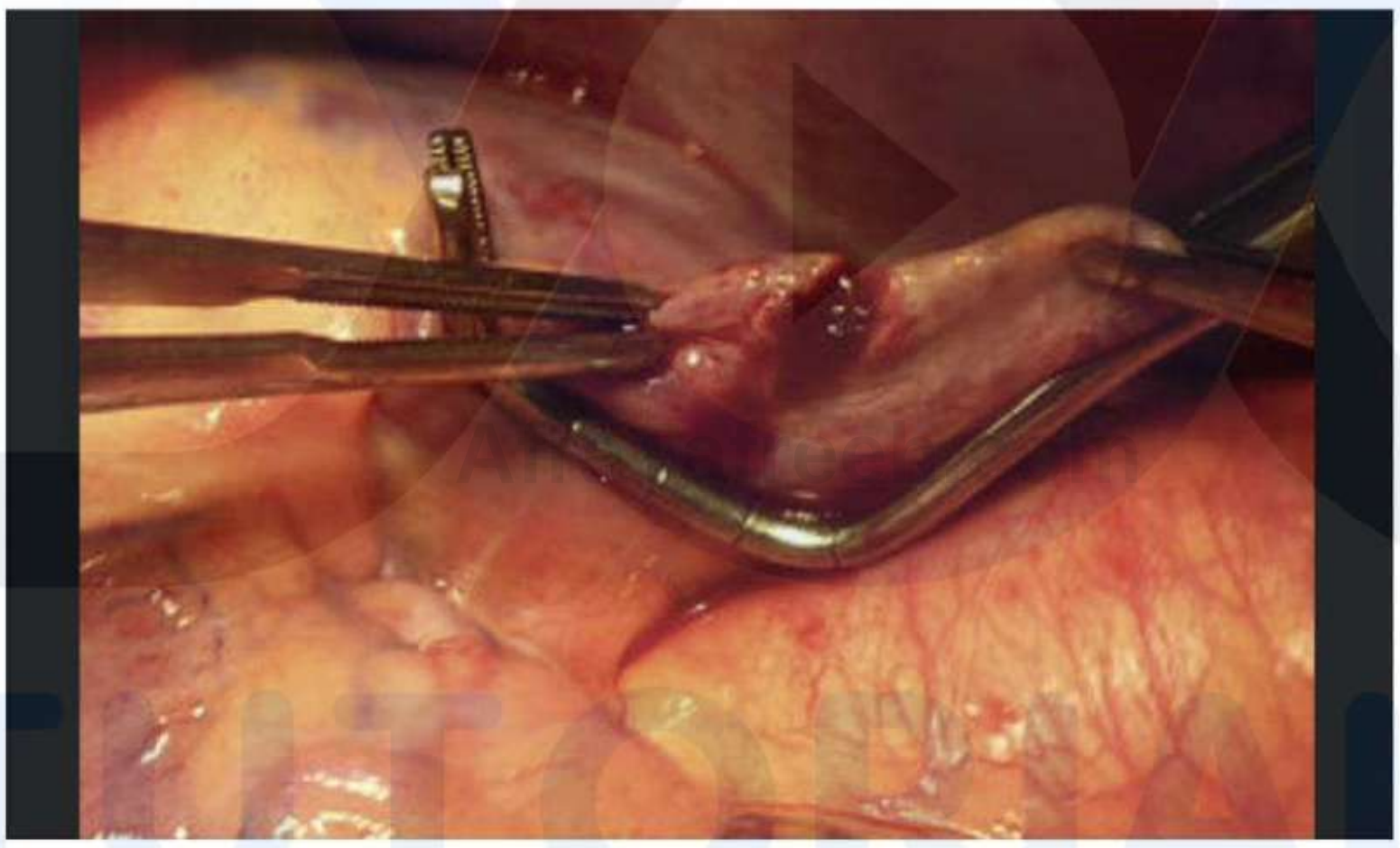

Fig: 31

LOGIN FOR SUCCESS

Towel Clips

Fig: 32

AfraTafreeh.com

Handles

Fig: 33

Humby knife handle

Fig: 34

TUTORIALS
LOGIN FOR SUCCESS

Electronic Dermatome

Fig: 35

Drains

Corrugated Rubber drain

Fig: 36

Suction Drain

Fig: 37

AfraTafreeh.com
TUTORIALS
LOGIN FOR SUCCESS

Jackson pratt drain

Fig: 38

AfraTafreeh.com

Intercostal tube drain

Fig: 39

DP stent

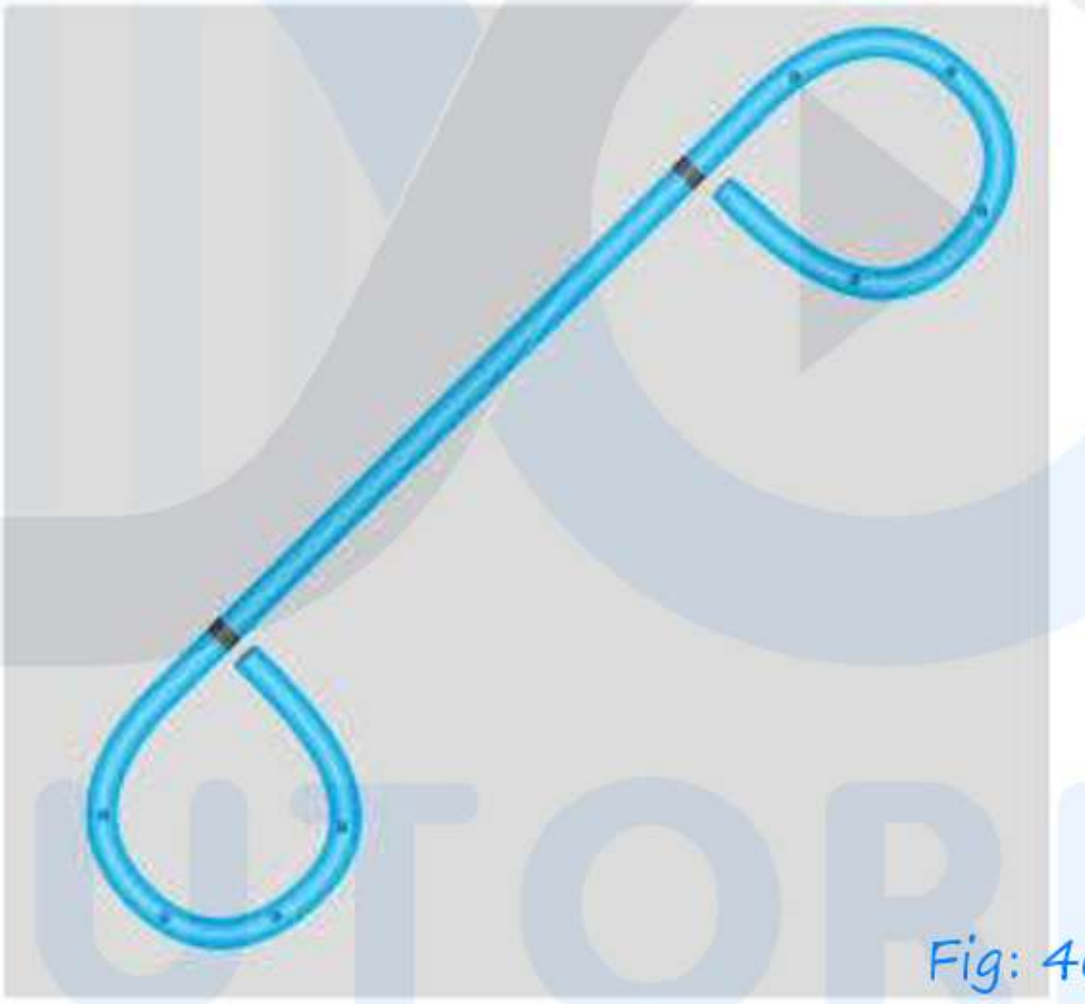

Fig: 40

TUTORIALS
LOGIN FOR SUCCESS

T tube drain

Fig: 41

INTRODUCTION TO TRAUMA

Introduction 00:00:05

Causes of death in trauma patient

- Patient die in few hours (or) days to week (or) may die immediately on receiving in the casualty.

Immediate causes of death

- The golden period of trauma is 1st hour
- Most important most common cause is – head injury
- Other important causes are → Aortic, common carotid artery injury, Tracheobronchial injury
- The platinum minutes in trauma are first 10 minutes.
  So, in first 10 minutes of trauma we should be aggressive.

Cause of death in hours

- Airway causes – Airway obstruction
  Tracheobronchial
- Breathing causes – Pneumothorax
- Circulatory causes – Hemorrhagic shock, cardiac tamponade hemothorax

Cause of death in Days to week

- Sepsis
- Delayed CNS Causes

CASUALITY

- In casuality we can get 2 types of patients.

Multiple casuality

- Hospital has enough man power to manage the patient.
- Here priority is given to the disease.
- No triage needed.

Mass Casualty

- Eg – Bomb blast, bus accident (50-60 people brought to hospital)
- The team may go to the site.
- Severity is given priority
- Here there is no enough man power
- Triage is used in mass casuality.

TUTORIALS
LOGIN FOR SUCCESS

Triage 00:07:45

1.Red badge – Immediate, urgent treatment needed patients are given a red badge and some patients like

- Tension pneumothorax
- Pericardial tamponade
- Tracheobronchial injury

} Are managed at the site. They have to be managed with in 1 hour time.

2.Yellow badge – they can be managed in 1-2 hours' time. A little delay can be given, they don't need immediate intervention.

Eg – Open type of pneumothorax, major bone fracture

3.Green badge – They are walking, stable wounded cases.

Don't shift them to hospital.

They can come to hospital by themselves

They are minor injuries, so can wait.

4.Black badge – They are dead (or) moribund patients

↓

We cannot save them.

AfraTafreeh.com

No shifting of them.

TUTORIALS

Triage – means sort out

- When patient is admitted in casuality trauma centre –

LOGIN FOR SUCCESS

  1. Primary survey is done

     A – Looking after airway

     B – Looking after breathing

     C – Circulation

     D – Disability

     E – Exposure

- In cases of severe traumas, it is "cABCDE"

AfraTafreeh.com

C – controlling of exanguinating hemorrhage is done by packing, compression, artery forceps.

A – Airway 00:14:44

- Assessment of airway – clinically by
  a. Asking name → If he is speaking without gasping his airway is good. If he is unable to tell his name (or) gasping – there is airway problem.
  b. GCS scoring → If ≤ 8. It is inadequate airway.

TUTORIALS
LOGIN FOR SUCCESS

First step in management

- Put a hard cervical collar and stabilize the neck.
- When will we suspect a compromised airway?
  - Patient is unable to speak
  - Patient is unconscious
  - GCS < 8
  - Inhalational burns

Airway maintenance manuevres

- Tongue falling back is the most common cause of airway obstruction.
- It is prevented by
  i. Jaw thrust
  ii. Chin lift
  iii. Apply Guedel airway

- No hyper extension of neck is there is cervical spine injury, we may damage spinal cord.
- All these things are done by paramedical person in the trauma spot. The moment he comes to hospital, it is verified, he has done these or not.

Assess of airway for intubation

LEMON assessment

- Look externally → Open mouth and see for dentures, food bolus which may obstruct
- Evaluate for 3-3-2 rule

  3 – If we can put 3 fingers vertically after opening the mouth. Then mouth opening is good.

  3 – Keep 3 fingers from hyoid bone to chin. This 3-finger breadth is good (distance)

  3 – From thyroid notch to floor of mouth – 2 finger breadths.

TUTORIALS
LOGIN FOR SUCCESS

Mallampatti classification

- Class I – Soft palate + uvula both are seen
- Class IV – Both not visualized
  - Put a torch light inside mouth and examine, if soft palate and uvula are visualized, then it is easy to intubate. If not visualized difficult to intubate.
- obstruction → Look for any cause of obstruction

  eg – Trismus

  Huge tonsils

AfraTafreeh.com

- Neck spine tenderness → If there is spine injury and we intubate. Then we can cause Quadriplegia after intubation because while intubating we will hyperextend the neck.

Intubation 00:21:40

Orotracheal Intubation

- It is most commonly done intubation.
- It is C/I in only one place patient with maxillofacial injury. Here try only one time for intubation, > 1 time should not be tried.

Nasotracheal Intubation

- It is C/I in any maxillofacial fracture
  - Base of skull fracture
  - Cribriform plate fracture
  - CSF rhinorrhea
  - Epistaxis
- ATLS manual – 10th edition advices to go for video laryngoscopy.
- Alternate method for cases C/I for intubation – Tracheostomy.

DX TUTORIALS LOGIN FOR SUCCESS

Tracheostomy 00:28:14

1.Needle Tracheostomy

Fig: 1

- Put a 16G needle in cricothyroid membrane. So, also called as cricothyroidotomy. It is an emergency procedure through that space we pass a 3mm/4mm catheter is passed and this catheter is connected to high flow oxygen.

AfraTafreeh.com

- This procedure can be used for a maximum of 30 minutes. Beyond that is causes CO_2 stagnation and hypercapnia can result.
- It is an emergency procedure and we have to immediately plan for elective procedure.
- This needle thoracotomy is C/I for children <12 years

  ∵ It can cause subglottic stenosis

2.Emergency Tracheostomy

- Here a vertical incision is made on trachea at the level of 2nd and 3rd rings

AfraTafreeh.com

- Cuffed E.T tube is put inside after opening of trachea.
- Definitive airway – putting cuffed tracheal tube. It can be orotracheal/nasotracheal

B – Breathing 00:37:00

- Now, we should assess the patients breathing is good or not.
- Clinical examination is to be done for breathing
- Inspection → Both chests are expanding well on inspection
- Palpation → Palpate for any tenderness in the chest (or) any flail chest, multiple rib fracture, any crepitus.
- Auscultation → will show if there good air entry/not rule out hemothorax, pneumothorax.
- If it is pneumothorax, if we find out its tension pneumothorax, then we should immediately put a wide bore needle/cannula (16G venflan) @ mid clavicular line in the 2nd intercostal space (at the place of accident)

  ↓

  As per Bailey & love
- ATLS 10th edition → needle to be placed in 5th intercostal space of mid axillary line in adults.

  In children → 2nd I.C space in mid clavicular line.

TUTORIALS LOGIN FOR SUCCESS

- It is a temporary procedure, immediately we plan & put an intercostal drainage tube @ 5th intercostal space in the mid axillary line.
- If patient is not at all breathing, then connect him to a ventilator especially the people who are unconscious and not breathing by themselves Eg. (Head injury patients)

C – Circulation 00:37:04

- By palpating pulses and cold peripheries, we can find circulation is good/not.
- Pulse rate is increased in Grade II hemorrhagic shock grade – II – (750 – 1500ml blood is lost)
- The thready pulse and feeble pulse mean patient has gone into G-III shock (1500 – 2000ml blood is lost)
- We have to follow "One on floor – four more" to find where the blood is lost how much of blood is lost (in bailey and love)
- These are the bleeding spots we should look for
  - One on floor → can be clot, soaked pad
  - Clenched first size clot – amount of blood is 350ml
  - Soaked pad – 500ml of blood is lost.
- We should look for 4 cavities –
  - Chest cavity – 1500ml blood loss
  - Abdominal cavity – 1500ml blood loss
  - Pelvic fractures – can lose 2000ml blood

AfraTafreeh.com

- Extremity fracture – femur fracture 1-1.5L blood loss

Management

- Give 2 short wide bore peripheral cannula are preferred in Hemodynamic shock or trauma patients.
- Minimum should be **2 green venflan (18G)**
- If we want to give more fluids, we can use grey 16G/orange cannula 14G.

  Then various methods used to cannulate are.

  1. Cut down saphenous vein – usually done in burns cases
  2. Intraosseous transfusion – usually preferred for children < 6 years only. Below the tibial tuberosity
     - Best in shock patient, for who peripheral veins are not available is (go with central vein) IJV (Best) for trauma patients.
     - For giving nutrition – subclavian vein is best
     - In all these cases, we use crystalloids. As per new books, we infuse 1L of crystalloids (previously 2L)
     - Crystalloid of choice in trauma

       Sabiston → 7.5% HTS (hypertonic saline)

       ATLS manual – Isotonic normal saline

- when we use more amount of Crystalloids, there is dilutional coagulopathy. (So restricted fluid 1L)

Damage control Resuscitation 00:46:22

1. We allow only permissive hypotension.
   our aim is to bring S.B.P around 70-90 mm Hg
   - If it becomes > 90, already closed vessels will open and they rebleed.
   - If it becomes <70, the essential organs like kidney, brain will not get adequate blood and go for ischemic damage.
   - In only head injury patients, we maintain SBP > 90, to allow perfusion into brain.
2. To restrict crystalloids & Colloids
3. Replacement fluid in trauma is 1:1:1 known as balanced resuscitation.
   1 unit of packed RBC, 1 unit of plasma, 1 unit of platelets.
   This combination prevents coagulopathy

AllaTalleem.com
LOGIN FOR SUCCESS

CRASH – II Trail

- Giving Inj. Tranexamic acid is given at spot (<10 mins) – 1gm i.v and infuse another dose – 8 hours → 1 gm infusion.
- Given for people who SBP < 90 and PR > 110/min (In a patient of trauma with hemorrhage)

AfraTafreeh.com

D – Disability 00:51:24

DISABILITY SCORING SYSTEMS :-

- ISS – Injury Severity score
- RTS – Revised trauma score
- TRISS – TRIS score
- AIS – Abbreviated injury score
- MESS – Mangled extremity severity score
- GCS – Glasgow coma score

E – Exposure 00:53:26

- From head to foot, we expose and see for other injuries.

Log roll

- Indication – If we want to examine the spine of patient (or) any associated injury. (spine injury examination)
- We need 4 persons, one is examining person, he is leader other 3 will turn patient to opposite side from supine position to lateral position, simultaneously. (In Bailey image only 3 people do, it is wrong).
- while doing this examination, we should also do.

  a. a P/R exam – to find out any active bleed P/R and Vermooten sign (floating prostate) (In a case of membranous urethral rupture)

  ↓

  It is C/I now-a-days

b. Look for anal wink reflex

- If we poke with needle in perianal area, we immediately see anal sphincter contracting. IT tells integrity of spine integrity in unconscious patient.

C/I for log roll – suspected pelvic fracture

→ Log roll is a part of primary survey

Primary Survey

1. Airway → Maxillofacial injury – one time we try orotracheal intubation, if it fails, go for tracheostomy. Nasotracheal intubation is C/I in maxilla facial injury.
2. Breathing → In emergency tension pneumothorax, needle is placed in 2nd intercostal space, mid clavicular line in bailey. Now changed to 5th intercostal space, mid axillary line in ATLS
3. Circulation → we have to use, minimum two green cannulas 18G.
   If required can also use Grey 16G and orange 14G
4. Disability → Scoring systems
5. Exposure → Examine, log roll is done.

AfraTafreen.com
TUTORIALS
LOGIN FOR SUCCESS

Secondary Survey 01:00:20

- It is done after stabilizing the patient.
- As the log roll in 1° survey is time taking, it is obsolete now.
- As there is important, we do a imp 2° survey → whole body CT scan for severe injury case in 2° survey

AfraTafreeh.com

- When patient is stable, we should ask history of AMPLE
  - A – Allergy H/O
  - M – Medicine H/O
  - P – Past H/O (HIV, Pregnancy etc.)
  - L – Last meal consumption (needed to plan surgery)
  - E – Elaborate mechanism of injury.

2° Survey investigations

- Previously x-ray cervical spine, X-ray chest, X-ray pelvis are done.
- Now – instead of all these, go for a **whole-body CT scan.**

W.B CT scan

1. X-ray chest = 0.02 mSv

   As per bailey, one whole CT scan = TB x – ray chest

   ↓

   For mcq purpose, given in bailey and love. But it is wrong, actually it was 600 x-ray chest.

   (or)

   One whole body CT scan = 12-16 mSv

   (or)

   6 months of radiation exposure

- By doing this much of exposure the patient has 2% risk of cancer is there in these patients.

DOC TUTORIALS LOGIN FOR SUCCESS

- So, don't take whole body CT unnecessarily. we do it only for severe score injury patients.
- W.B CT → provisional report is obtained in few minutes. Detailed report is available in 30-60 minutes.

X-ray cervical spine

For whom we take x-ray cervical spine

a. NEXUS criteria – [National Emergency X – ray utilization study]

   N – Patient with neurological deficit

   E – Ethanol consumption

   X – Xtreme mechanism of injury

   U – Unable to recall (LOC)

   S – Spine tenderness – Advice X-ray cervical spine

b. Canadian 'C' spine rule

AfraTafreeh.com
DX TUTORIALS
LOGIN FOR SUCCESS

Transfer Of Patients 01:10:38

Transfer of patient from 1° survey to 2° survey to x-ray room

1. Transfer the patient only on a hard rigid board.
2. Patient should be wearing a hard cervical collar (Philadelphia collar)
   (At the time of X-ray only, it should be removed & then put it again)
3. Pelvic binder is used and it should be there unless we rule out pelvic fracture.

AfraTafreeh.com

4.Position of patient should always be supine in transfer. Prone position transfer is advised in unconscious patients. Don't shift patient in lateral position.

5.Doctor accompanies the trauma patient to radiology room. He can keep on talking to patient. By this doc make sure that patient do not have any disturbance in his consciousness during the transport time. (To look for any disturbance in patients neurological status)

Management of trauma patient 01:13:57

1.Early Total care

- Done within 36 hours

↓

If none of these right-side points present i.e.,

- BP stable
- S. lactate < 2 mmol/L
- Normothermia
- Normal coagulation
- Urine output > 1 ml/kg/hr
- No hypoxia
- No hypercapnia

2.Damage control surgery/Resuscitation

- Indication – "HAC" – lethal triad of trauma
- H – Hypothermia < 34°C

A – Acidosis pH < 7.2

DOC TUTORIALS LOGIN FOR SUCCESS

C – Coagulopathy

- S. lactate – if > 5 mmol/L means it is a bad resuscitation and patient needs and emergency damage control surgery.
- If SBP < 70mmHg → DCS
- ISS > 36 – DCS
- Blood transfused > 15 units → DCS

Damage control surgery DCS – The target is 01:19:00

- To stop bleed.
- To stop further contamination

3 phases DCS 01:19:52

Phase – I

- Happening in emergency OT
- Open abdomen with long midline incision
- Go inside, look for any damage and try to repair at the earliest Eg. if there is active bleed.
  - Bleed from liver → 4 side packing to liver is done
  - Bowel injury with contamination – Do clip and drop method.
- Don't do anastomosis, only clip the ends.
- Ileostomy/colostomy is done.
- keep an external drain in the abdomen

AfraTafreeh.com
TUTORIALS
LOGIN FOR SUCCESS

AfraTafreeh.com

- Don't close the abdomen, only keep Bagotta bag (or) OPSITE dressing to close it temporarily. Because it has to be opened 48 hours after.

Phase II –

- It happens in SICU
- Here we correct the HAC (Hypothermia, acidosis, coagulation)
- For 0 to 48
- hours, we manage patient in SICU – HAC

Phase – III

- If there is liver injury – call liver surgeon
  Vascular injury – Vascular surgeon
- Everyone will be in O.T & abdomen is opened in elective OT with full set up of all specialists.
- Here definitive surgery for saving organs in an elective OT. with help of all specialists.
- After that we close the abdomen
- If "Phase" word is present in question – then it is from Sabiston, Bailey and love says it as stages

Stages 01:24:21

- I – select the patient for DCS
- II – Phase I emergency OT
- III – Phase II in ICU
- IV – Phase III – Elective OT

- V – Closure of abdomen

Damage control surgery in various organs

01:25:40

Vascular surgery

- If there is arterial tear/disruption – we use PTFE graft (poly tetra fluoro ethylene (interposition))
- If there is venous tear – ligate the vein (even femoral vein can be ligated)
- Cardiac injury (bleeding from ventricle) – Keep a PLEDGET (or) a mesh and suture over it → PLEDGET repair is done for ventricle repair.
- Atrial tear we can directly close it (as atrium don't contract vigorously)

iraTafreeh.com

Solid organs

- Liver – 4P – pack, plug, pringle, push
  ↓
  by help of balloon catheter/tamponade
- Spleen – DCS for spleen is splenectomy
- Pancreas – we do triple tube osteotomy – external drainage done.

GIT

- Stomach – we can directly repair the stomach
- S.I/L.I – we do clip and drop method.

AfraTafreeh.com

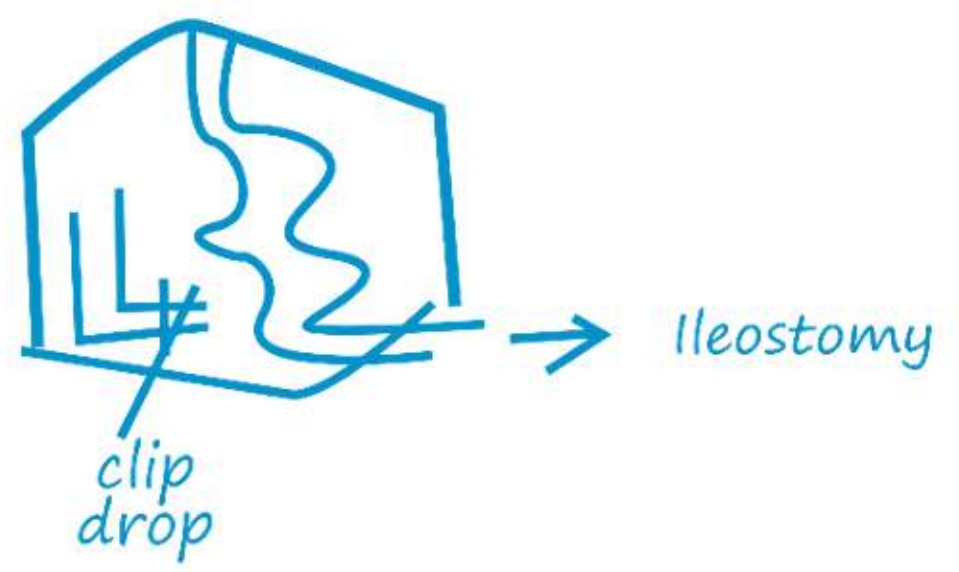

Fig: 2

- If there is tear in small intestine, then make S.I as Ileostomy and distal part is clip and drop inside. proximal part is made as ileostomy.

Pulmonary Parenchyma

- If bleeding from pulmonary parenchyma → Do wedge excision of bleeding part.
- Wedge stapling is done for these cases

Fig: 3

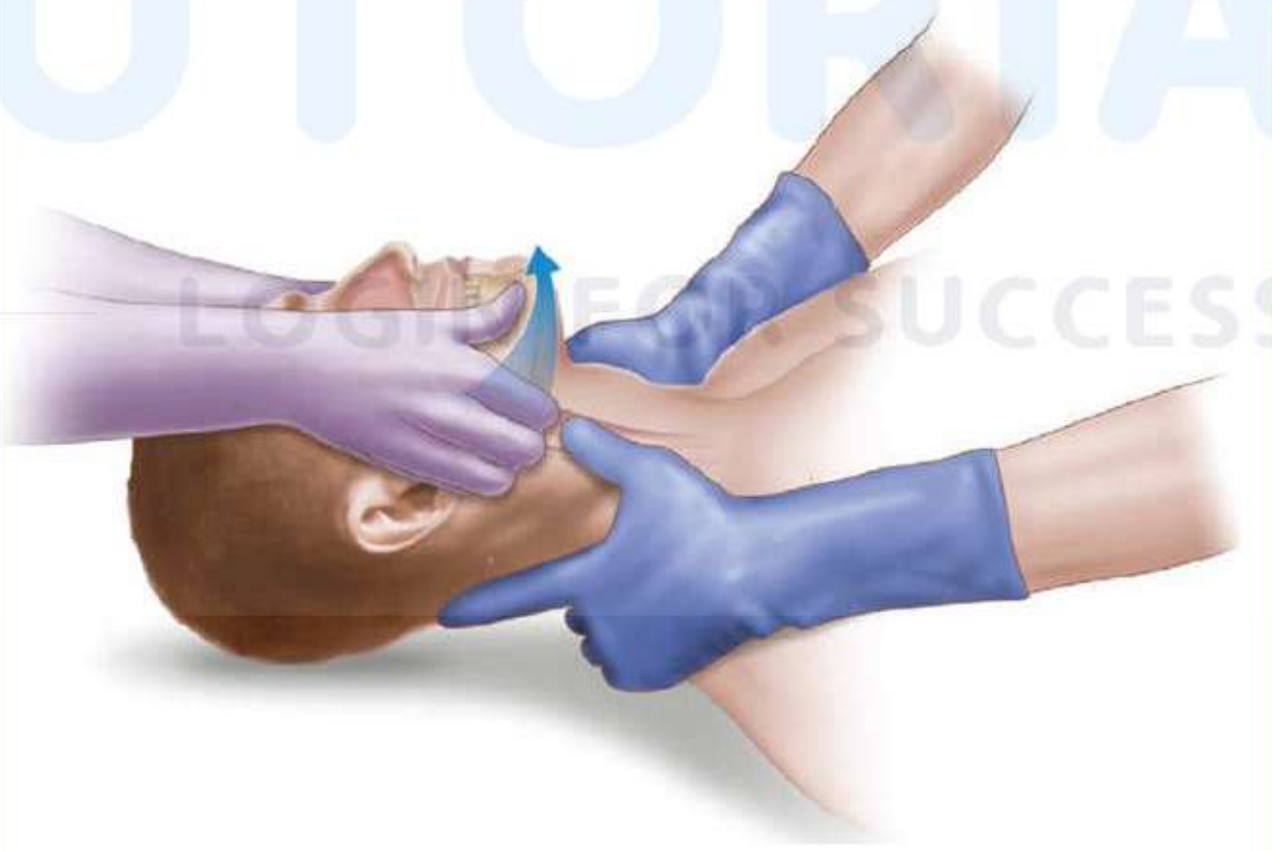

Jaw thrust Fig: 4

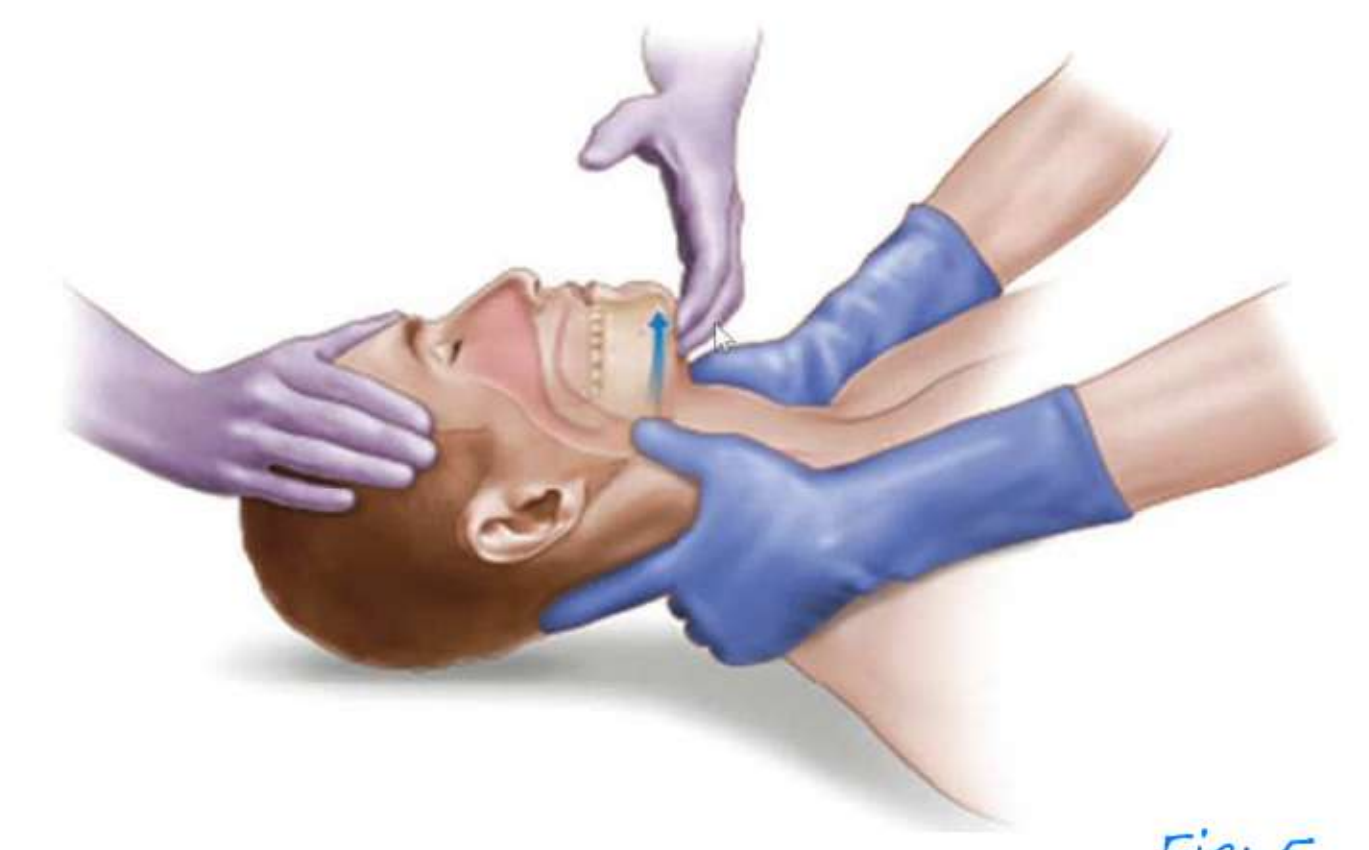

Chin lift

Fig: 5

Mallampatti classification

Fig: 6

AfraTafreeh.com
TUTORIALS
LOGIN FOR SUCCESS

AfraTafreeh.com

SCORING SYSTEMS IN TRAUMA

Scoring systems in Trauma

RTS	TRISS	MESS
↓ Revised Trauma Score ↓ R – RR T – Tie & see BP S – GCS	↓ Combined Scoring System ↓ R – RTS I – ISS S – Seen age S – Specific Mechanism	↓ Mangled Extremity Scoring System ↓ Preserve/ amputate

TUTORIALS
LOGIN FOR SUCCESS

Mess 00:03:00

- Used by orthopedic surgeon whether to preserve limb/amputate limb
  - M – Main energy
  - E – Extremity Ischemia
  - S – Seen age of patient
  - S – Shock
- ≤ 6 – Preserve the limb
- ≥ 7 – Amputation

Abbreviated Injury Scale (AIS) 00:05:04

- Code of 1 2 3 4 5 6 7

↓

Severity of injurity

↓

1 – Mild

2 – Moderate

3 – Serious

4 – Severe

5 – Critical

6 – Maximum (Fatal)

- AIS – 1 – region

2 – Type of anatomical structure

3, 4 } Specific anatomical

5, 6 } Level of injury

AIS code – 1: - Region of injury

- 1 – Head
- 2 – Face
- 3 – Neck
- 4 – Thorax
- 5 – Abdomen and Pelvis
- 6 – Spine
- 7 – UL
- 8 – LL
- 9 – Burns and other injuries

AfraTafreeh.com

ISS 00:10:42

- Injury severity score – used in polytrauma
- ISS = Head + thorax + Abdomen

  a^2 + b + C

  = 4 + 9 + 16

  = 29

- 3 regions of highly injured are considered and score given based injury score.
- Total score = 1-75 [AIS]

  1-8 – minor →1

  9-15 – moderate →2

  16-24 – serious →3

  25-49 – severe →4

  50-74 – critical →5

  > 75 – Fatal →6

- Damage control surgery done if ISS ≥ 36
- Major trauma → ISS ≥ 15 → Whole body CT scan
- ISS → 1-75
- DCS → ISS ≥ 36
- Major trauma → ISS > 15

qSOFA

↓

quick sequential organ failure assessment

↓

R – RR ≥ 22/min – 1

C – Confused – 1

DOC TUTORIALS LOGIN FOR SUCCESS

B – SBP ≤ 100 – 1

≥ 2 → 10% mortality

GCS (Glasgow coma scale) 00:19:40

Eye (4)

↓

Spontaneous – 4

Command – 3

Pain – 2

No response – 1

Verbal (5)

- One – oriented – 5
- Confused – Confused – 4
- Word – inappropriate – 3
- Sounds – incomprehensive – 2
- Nowhere – No sound – 1

Motor (6)

- Obey – Obeys – 6
- Localizes – localizes pain – 5
- With – withdrawal – 4
- Flexion – flexion – 3 (Decortication)
- Extension – Extension – 2 (Decerebrate)
- Now – No response – 1
- Q. Min score – 13

  Max. score – 15

AfraTafreeh.com

- Q. Intubated: verbal – VNT – No score
  → max possible – 10 (4+6)
- Q. Motor – Best of score is taken
- GCS $\geq$ 8 – Intubate
- GCS of dead – 3

GCS – P 00:27:30

- P – Pupil reactive score

R L

x x

- Both not reactive – 2
- One not reactive – 1
- Both reactive – 0

GCS: 10	Final GCS – P
P: 2	10 – 2
	8

TUTORIALS
LOGIN FOR SUCCESS

GCS: – 10 VNT	Final GCS – P
P: – 1	10 – 1
	9 VNT

ATLS – 10th

Transfuse blood

TASH score (Trauma associated severe Hemorrhage)
↓
- Systolic BP
- Hb
- Fast
- Fracture long/pelvic bones
- HR
- BE (Base excess)
- Gender

> 27–100% blood transfusion

MC Laughlin score
↓
Massive blood transfusion ≥ 10 units
↓
- HR > 105
- SBP > 110
- pH < 7.25
- Hematocrit < 32%

– 20% chance for each variable

– 80% chances of massive transfusion

AfraTafreeh.com
TUTORIALS
LOGIN FOR SUCCESS

AfraTafreeh.com

HEAD FACE AND NECK INJURY

- In AIS
  - Head injury – Region no. 1
  - Face injury – Region no. 2
  - Neck injury – Region no. 3

Traumatic neurosurgery

- Normal cerebral blood flow → 50-55ml/min
- If flow <20ml/ml → Results in cerebral hypoxia
- Normal CPP cerebral perfusion pressure is 75-105mmHg

  = MAP – ICP

  = (90-110) – (5-15)

Munro – Kellie doctrine 00:03:22

- Skull is a closed compartment
- It is made up of

  1.Brain

  2.CSF

  3.Various dural (Blood) Sinuses
- If any one component increases there is no place in skull to expand so, it has to compromise other component
- Eg. If there is hematoma in skull it will compress the brain – so herniation of brain happens herniation

TUTORIALS
LOGIN FOR SUCCESS

causes lot of neurological deficit and even respiratory arrest can happen

- Normal ICP is 5-15mmHg if it is >20 then herniation happens so there to prevent herniation, CSF is reduced by certain methods

Herniations 00:07:10

- If there is hematoma on ® side of the skull → Eg: SDH, EDH it can cause
  1.Midline shift of brain
  2.Lingulate gyrus herniation
  3.Uncus (Uncal part of temporal lobe herniation)
- The pyramid tract from one side will go down cross and supply opposite side UL & LL
- In uncus herniation → Causes compression of
- Normal localizing sign
  - I/L Pyramidal tract → Cause C/L hemiplegia
  - I/L Oculomotor nerve → Cause I/L fixed dilated pupil K/A Hutchinson pupil

Kernohan's notch phenomenon

- If hematoma is becoming bigger and bigger the uncus of temporal lobe instead of compressing same side – Pyramidal tract. It compresses opposite side tract causing

↓

AfraTafreeh.com

False localizing sigh → I/L hemiplegia is seen (I/L Hutchinson pupil)

So, we confuse where/On which side hematoma is present

Uncal herniation

- I/L tract compression → C/L hemiplegia
  I/L dilated pupil
  Hutchinson pupil
- So previously a bind burr hole is done on the side of fixed and dilated to relieve pressure (No time to do a CT scan)
- But in Kernohan's notch phenomena – We see
- I/L hemiplegia & I/L Hutchinson pupil or oculomotor normal involvement
- Brainstem herniation – Respiratory arrest is seen
- Cerebellum herniation → Causes Cushing's triad (hypertension, bradycardia and respiratory irregularities)
- Generally, in trauma → Patient with hypotension and tachycardia. If patient with HTN and brady – Suspect Cushing's triad

To Prevent herniation

- We need to decrease the ICP <20mmHg to avoid 2° brain damage

- 1° brain damage is due to direct prob – eg: Hematoma → EDH, SDH
- Damage happening or a complication due to hypoxia hypercapnia, ↑ICP, ↓PaCO2 - ↑PaCO2 all this cause 2° damage of brain

To decrease ICP

- Head end is elevated by 15° – 30°
- Give injury I.V mannitol to ↓ICP by ↓CSF frusemide can also be given if B.P is normal. In trauma steroids are absolutely C/I
- Sedation is given (Or patient is agitated & shouting → causes ↑ICP) with help of barbiturates (Because is C/I, because they can cause respiratory depression)
- Propofol is recommended for ICP control
- Other things to do are
- As a prophylactic measure to prevent hypoxia
  - Give nasal oxygen
  - Hyperventilation is needed → To prevent hypercapnia
  - Maintain hypothermia
  - Sodium valproate to prevent seizures
  - Prophylactic antibiotics given to skull patients and patients with external ventricular drainage

AfraTafreeh.com
TUTORIALS
LOGIN FOR SUCCESS

AfraTafreeh.com

Best method to calculate ICP:

- By pitting a external ventricular catheter. It also helps to drain CSF
- Lumbar puncture is highly C/I to reduce ICP because it results in herniation of brain stem & patient may die

Nutrition

- If everything is good enteral nutrition can be started in 72 hours either by nasogastric/Nasojejunal
- All above procedures are being done in a marrow IW
  - ICP < 20mmHg
  - CPP > 70mmHg
  - MAP > 90 mmHg
  - PaO2 → 80-100mmHg/10-12Kpa
  - PaCO2 → 35-45mmHg/4-6Kpa
  - Kpa – Kilopascal

TUTORIALS
LOGIN FOR SUCCESS

GCS

- It is between 3-15
- Patient is intubated if GCS ≤ 8
- Classification of head injury is based on GCS
- Minor → GCS is 15, No LOC
- Mild → GCS is 14-15 Loc (+)
- Moderate → 9-13
- Severe → GCS ≤8 – Pt needs intubation

Base of skull fracture 00:30:10

- Can occur in head injury

Anterior cranial fossa

Fig: 1

- It is nothing but cribriform plate
- Clinical features
- CSF – Rhinorrhea
- Epistaxis
- Anosmia
- Panda eyes/Racoon eye/Black eye → Hematoma tracks in subgaleal region and region and presents as hematoma in eyeball
- Frontal lobe confusion is seen
- Test

1. Put the fluid on blotting paper the blood will collect in the center and CSF is collected in periphery like halo sign
2. β2 Transferrin is elevated in CSF

AfraTafreeh.com

AfraTafreeh.com

Middle cranial fossa

- Nothing but petrous part of temporal bone

Clinical features

- CSF otorrhoea
- Hemotympanum
- CSF paradoxical rhinorrhea is seen
- Classical sign → Brusing over the mastoid process 'battle sign'
- Facial nerve involvement can be seen (Paralysis)

Posterior cranial fossa / Occipital bone

- C/F: Visual disturbance due to 6th Normal involvement
- **Vernet syndrome** due to compression of jugular foramen – 9,10,11 cranial nerve going through jugular foramen are involved
- Basilar artery injured

LOGIN FOR SUCCESS

Brain injury

Primary brain injury

- Concussion
- DAI Diffuse axonal injury
- Hemorrhages

  ↓

  EDH

  SDH

SAH

ICH

Secondary brain injury

- Happen due to hypoxia
- Hypercapnia
- Increased ICP

Concussion

- It is the mildest of all injuries
- NECT is normal
- Chronic encephalopathy is seen (Post-concussion syndrome)
- Colorado classification of concussion
  - Type I → Simple confusion
  - Type II → Amnesia present
  - Type III → LOC (+)

AnuTahcom.com
TUTORIALS
LOGIN FOR SUCCESS

Diffuse axonal injury

- It is an acceleration – Deceleration injury of brain
- Shearing force is excreted is between grey & white matter
- HPE will show punctate spots (+)
- Clubbed axons will be seen
- In NCCT – Everything is normal
- MRI is IOC – Shows punctuate hemorrhage
- It is the worst form and worst prognosis

AfraTafreeh.com

Hematomas

- Most common type of hemorrhage inside skull – ICH
- It is mostly d/t HTN – Causing putamen hemorrhage
- These cases present with CVA

Trauma related hematomas 00:45:28

- EDH – Most common type
- SDH
- SAH

EDH

- Most common type of trauma hematomas
- Most common in young patients it is a high-level impact injury
- Due to injury/# to pterion bone (Thinnest part of skull)
- Bleeding from middle meningeal artery inside
- C/F: Lucid interval – normal period of consciousness followed by loss of consciousness
- It is not specific to EDH
- IOC: NCCT – Shows a biconvex hematoma/Lens shaped
- Collection of blood outside durometer
- Treatment: Burr hole is done immediately at the injured point & let out

LOGIN FOR SUCCESS

- Sometimes the part of skull is removed evacuate hematoma and put the bone back
- Craniotomy → It is done when > 30cc clot
  - > 5mm midline shift
  - > 1.5cm thickness of hematoma
- Mortality in EDH is <5%

SDH

- It is a type of acceleration – Deceleration injury
- Collection of blood below durometer
- These ate very suck patients
- There is H/O LOC (+)
- Bleeding is forming the birding cortical veins which are disturbed due to acceleration – Deceleration
- 2 types

Acute SDH

- Occurs in 0-3 days
- Subacute (intermediate) is between 3-21 days
- NCCT scan finding → Concave – Convex appearance
- Treatment: Had bad prognosis → Open immediately the skull & remove hematoma (Decompression is done by craniectomy) Acute SDH has >40% mortality

AnaTafreeh.com
TUTORIALS
LOGIN FOR SUCCESS

AfraTafreeh.com

Chronic SDH (>21days of trauma)

- Common in old age people who are on anticoagulants like platelets clopidogrel and minor trauma – causes slow bleeding and they present after 21days we stop the anticoagulants. If patient is deteriorating burr hole is the treatment of choice
- EDH common in young age, SDH common in old age

SAH

- Most common cause of SAH is trauma (As per new bailey) (As per old bailey – It is berry aneurysm)
- In NCCT shows sub arachnoid cisterns with blood collection the patients have thunder clap headache in case spontaneous rupture of berry aneurysm
- SAH – is bad prognosis
- In post mortem most common cause of hematoma is SDH (In forensic books)
- Important management here is NCCT

TUTORIALS
LOGIN FOR SUCCESS

Indications of NCCT 00:58:18

- NICE – National institute of health and clinical excellence guidelines
- NICE advises to take CT scan with <1hr when following points are seen

1. If GCS <13 @ any point of time
2. GCS <15 @ 2hours after trauma

3. Patient has focal neurological deficit – Includes loss of consciousness also
4. Patient developing seizures
5. Patient had # of skull – Depressed #/Non depressed #/Base of skull#
6. If patient develop >1 episode of vomiting

CT scan should be taken <8hrs if following points seen

1. Patient age >65 year
2. Patient on anticoagulant drugs
3. Patient gives dangerous mechanism of injury
4. When there is retrograde amnesia for about 30minutes

AfraTafreeh.com
TUTORIALS
LOGIN FOR SUCCESS

Fracture of skull

- Non depressed
- No treatment required
- Depressed
- If depression is > thickness of skull then do surgery

Management of head injury patients in an outline

01:03:28

- Minor trauma: Patient with GCS - 15 and No LOC → Discharge him home
- Mid trauma: Patient with GCS 14, 15 + LOC
  - Evaluate them take a NCCT
  - Criteria for discharge

AfraTafreeh.com

1.Pt GCS should be 15/15

2.Normal CT scan

3.Pt. should not have alcohol influence

4.Responsible adult is present along with the patient

- **Moderate cases**
  - Admit them, Do a NCCT
  - Manage them in neuro ICU

- **Severe cases:**
  - Intubation is done and admit in neuro ICU

Glasgow outcome scale of head injury Patients:

- At the time of discharge, we give score

1.Dead patient, not all recovered

2.Pt is in vegetative state

3.Pt has severe disability like paraplegia/Quadriplegia

4.Pt has moderate disability like bells phenomenon/Monopoiesis

5.Pt has good recovery

- AIS 2 – Facial injury
- AIS 3 – Neck injury
- Most common in the face is nasal bone # next is zygomatico-orbital complex

- They are 3types
  - Lefort I - # line at the level of hard palate
  - Lefort II - Is a pyramidal #
  - Lefort III – Dangerous # craniofacial dysjunction, pt. may have CSF otorrhea
  - IOC – CT facial bones
  - Treatment – ORIF – Open reduction and internal fixation
  - One time oro-tracheal intubation can be tried, if not go for tracheostomy
  - Most common site of # in mandible is neck of condyle
  - 2nd – Angle of mandible
  - 3rd – At level of canine tooth
  - 4th – At middle of mandible
  - IOC – CT scan of mandible
  - Treatment OC – ORIF
  - Zygomatic orbital complex – Most common in face as per bailey and love

AfraTafreeh.com
TUTORIALS
LOGIN FOR SUCCESS

Orbit:

- Most common wall site in orbit # is floor > Medial wall > lateral wall > roof (Roof is strong, floor is week)

AfraTafreeh.com

- Inferior rectus muscle can be trapped in the floor of orbit # and it is an emergency manage immediately
- IOC → For zygomatic orbital complex → CECT facial bones
- Treatment OC → ORIF

Neck injury 01:23:40

- AIS – 3 – Neck injury
  - Region in body which has highest mortality rate is neck injury especially due to penetrating trauma
  - We divide neck into 3regions
  - Zone I – From sternal notch to cricoid
  - Zone II – From cricoid bone to angle of mandible
  - Zone III – From angle of mandible to base of skull
  - Most surgically accessible is Zone II Zone having major vessels – Carotid, IJV and highest mortality is seen with zone II
  - Zone I – Injury to trachea and oesophagus
  - Zone III – Most difficult to access by surgery

In **blunt cerebrovascular injury (BCVI)**, Blunt trauma in neck → There will be disruption of common carotid artery and vessels hematoma collected

- BVCI has Denver's grading system

- Type I– Luminal narrowing on CT Angio of carotid <25% narrowing

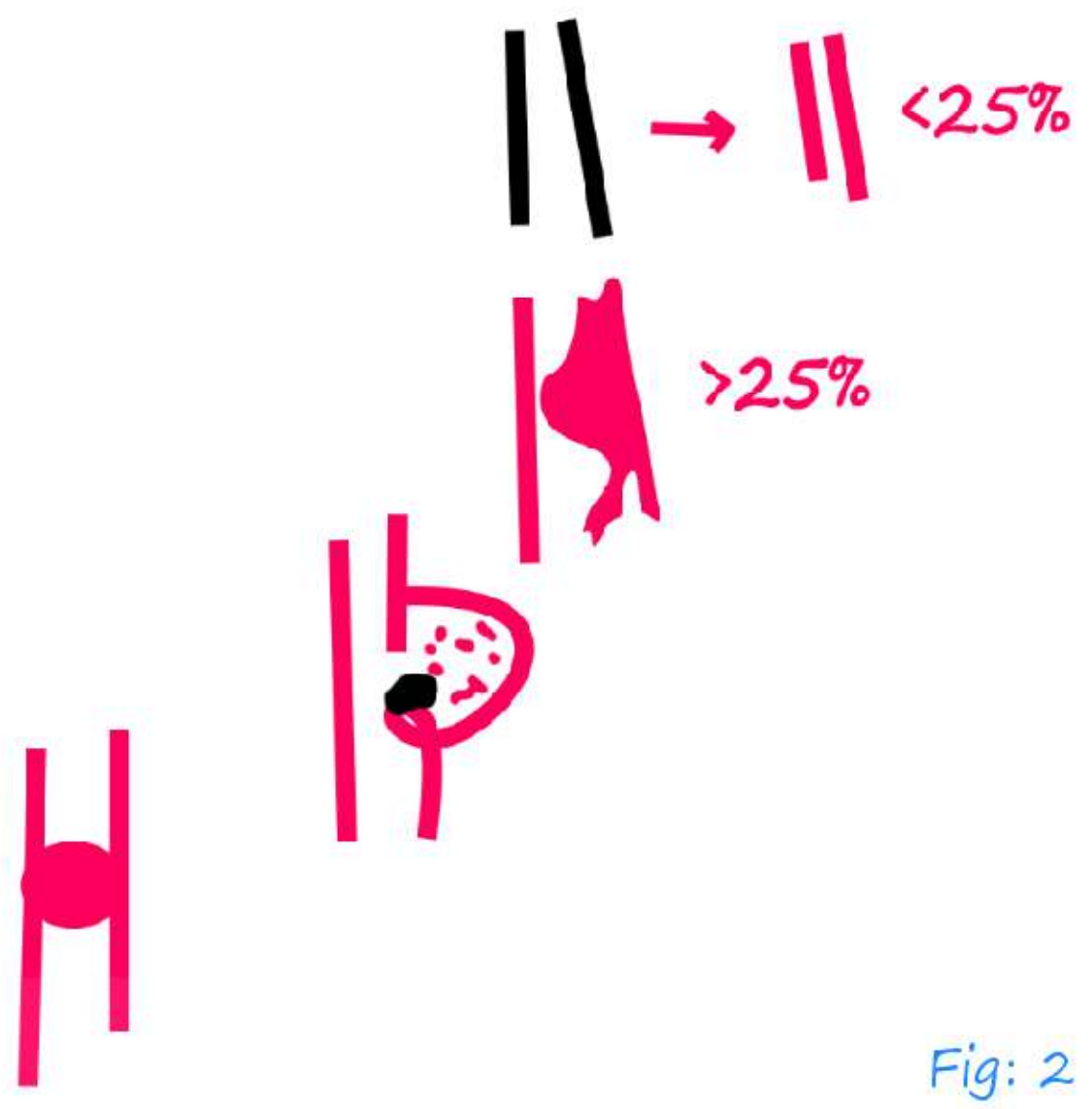

Fig: 2

- Type II – Dissection hematoma in the neck >25% narrowing is seen
- Type III – Vessel is disrupted and there is a pseudoaneurysm present
- Type IV - There is occlusion of blood flow
- Type V – Complete transection with extravasation of blood immediate surgery should be done
- I, II, III, IV can be managed by antiplatelet drugs and anticoagulants

AfraTafreeh.com

THORACIC TRAUMA

Thoracic Trauma 00:00:05

- Most common in the chest → Fracture of rib
- Thoracic injury is AIS – 4
- Most common cause of immediate mortality in blunt trauma

  ↓

  Tracheo-Bronchial injury
- Most common cause of death in penetrating trauma – Haemothorax

Dangerous dozen 00:02:11

Dangerous Doxen Injuries

Immediate like threatening injuries

↓

Red in triage

1. Airway obstruction
2. Pericardial tamponade
3. Tension pneumothorax
4. Open pneumothorax
5. Haemothorax
6. Flail chest

Potentially life threatening

↓

1. Aortic injury
2. Tracheo-bronchial injury
3. Myocardial contusion/injury
4. Diaphragm injury
5. Lung contusion
6. Esophageal injury

- In ATLS, 10th edition, FLAIL chest has been removed from immediate life-threatening injury and tracheobronchial injury is added to immediate L.T.I
- All the immediate L.T.I comes under red card in triage.

ICD Tube 00:06:06

- Safety triangle of chest–
  - Anteriorly – Lateral border of pectoralis major
  - Posteriorly – Latissmus dorsi lateral border
  - Apex – Formed by base of axilla
  - Inferior – Line drawn at the level of nipple – 5th intercostal space.



Fig: 1

- If we want to put ICD, it should be in the triangle only.
- In Bailey and love, the posterior boundary is given as mid axillary line → It is wrong.
- Best place to put ICD is 5th ICS mid axillary line
- ICD tube should be kept in the pleural space and the tip of tube should be facing upwards in case of pneumothorax and hemothorax

AfraTafreeh.com



Fig: 2

- In pleural effusion and empyema, the tip of tube should be downwards to drain pus/fluid.

How to insert ICD –

- Make the patient hand in hyper abducted position.
- Drape the left side of chest from clavicle, axilla with povidine iodine solution.
- Infiltrate local anesthesia at the site, upto the pleura.
- Take a 11-size blade and put skin incision horizontal, so that ICD tube can go inside
- Take a stay suture are taken with silk at the site of incision, so that we can fix tube (ICD) after inserting, to make it air tight.

- Now, with a blunt artery forceps splay the intercostal muscles perpendicularly.
- Once you reach pleura, put your finger and dilate the tract.
- This intercostal muscle splaying should go up to the level of upper border of rib (should not go at inferior

border of rib) because at inferior border and on inner surface, there is I.C artery, I.C vein, I.C nerve.

- Blunt dissection done
- Pleura opened
- Immediately insert ICD tube such that all the opening in the tube are inside the chest

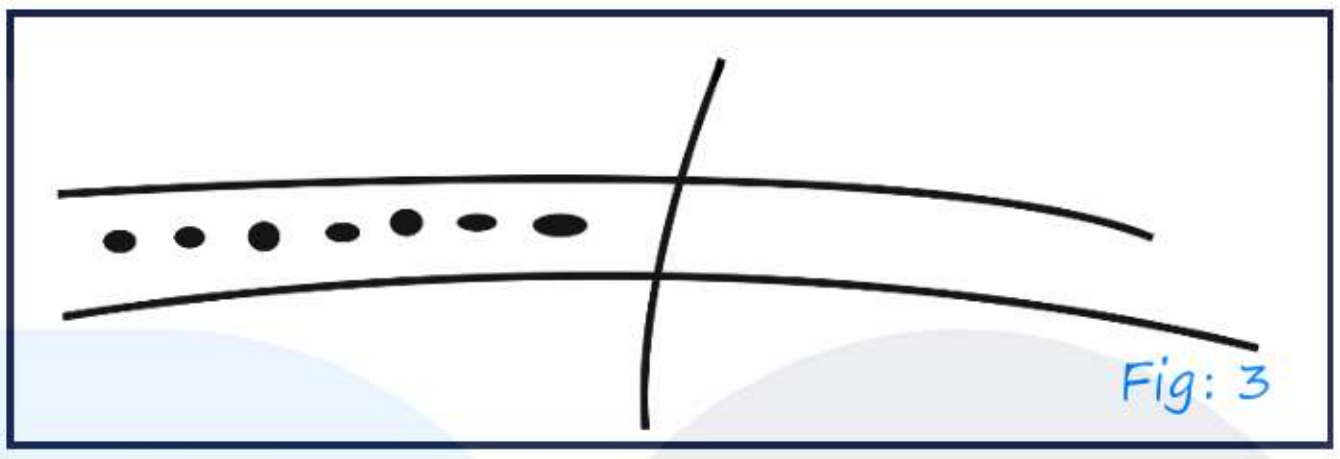

Fig: 3

- There are different sizes of tubes and 28 french is enough for pneumothorax.
  - 32 Fr for hemothorax.
- Once tube is fixed, the outer end of tube is connected to the underwater drain – so that atmospheric air won't enter the chest
- Every time the patient breaths the air will be coming out as bubbles and if hemothorax, blood will be coming out.
- There is air fluid level in the tube, every time the patient takes breathing inspiration and expiration, the air column moves up and down. This ensures that tube is in correct position and working of tube is correct.
- If air column not moving up and down there are problems.

DOC TUTORIALS LOGIN FOR SUCCESS AfraTafreeh.com

AfraTafreeh.com

a. Blockage of tube
b. Tube has come out (Displacement of tube)
c. Lung has expanded fully (No need of ICD tube here after)

- We can ensure the ICD tube is not blocked by asking the patient to cough. On coughing we can see the air column moving up and down.
- If we want to do a suction of thick blood/there is an obstruction we can use – 5 cm to -20 cm water pressure of suction is used intermittently. (not continuous suction) or (not high pressure suction)

When to remove the ICD –

1. When lung is fully expanded
2. Daily fluid <50ml/day

- When going to remove ICD, ask patient to take a deep (breath) inspiration. On inspiration – pleural space is obliterated and there is no chance of air entering the lung/chest cavity while removing the tube. Otherwise – there is a chance of pneumothorax (or) ask patient to do Valsava maneuvre while removing the tube.
- When you are putting ICD – you see – gush of blood flowing out on puncture – It is hemothorax.

Will you clamp?

↓

DX TUTORIALS LOGIN FOR SUCCESS

No benefit of clamping the tube
So, connect the ICD tube and start resuscitating with blood.

Heimlich valve

- It is a valve only used for pneumothorax.

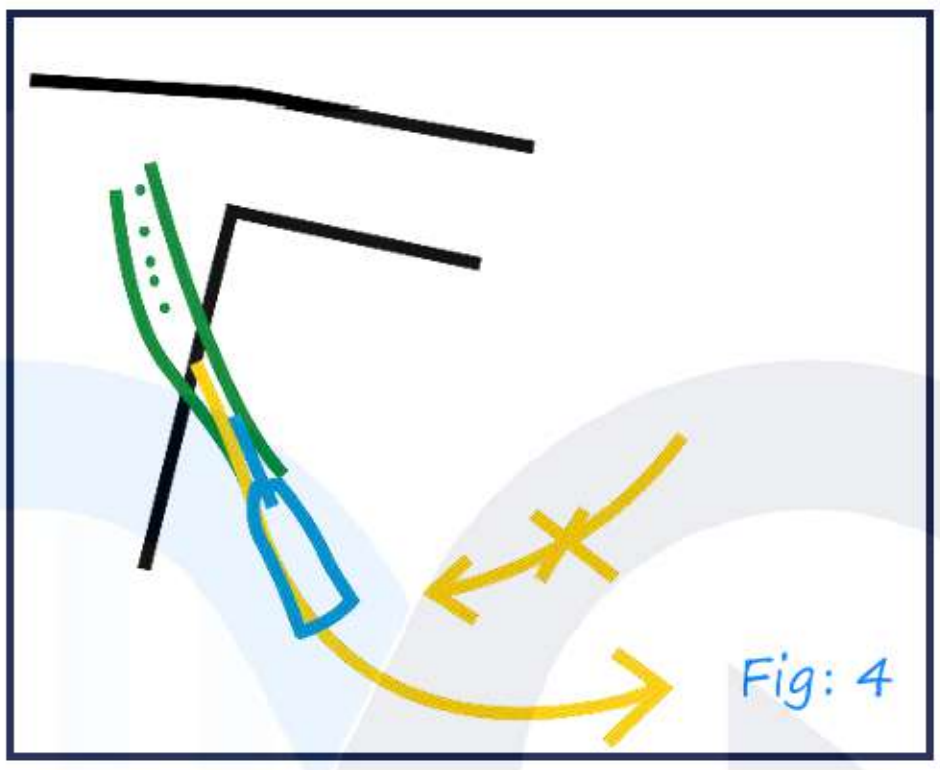

Fig: 4

- It is a one-way valve. It only allows air to go out and not allow the air to go inside.
- Main advantage is the patient can be ambulatory with this tube, no need of IC tube to be kept under water.

ICD tube

- Placed in safety triangle.
- Ideal place is mid axillary line – 5th intercostal space
- Always pass at the upper border of rib
- Pneumothorax/Hemothorax tip is facing towards apex of lung.
- How to confirm ICD is in place - observing air water column to move up and down with

AfraTafreeh.com

respiration. X-ray chest is taken to confirm position of ICD.

- Suction pressure used in -5 to -20cm of water, if there is any obstruction in ICD.
- Clamping of ICD is of no use.

Pericardial Tamponade 00:26:34

- Most common mechanism – penetrating trauma

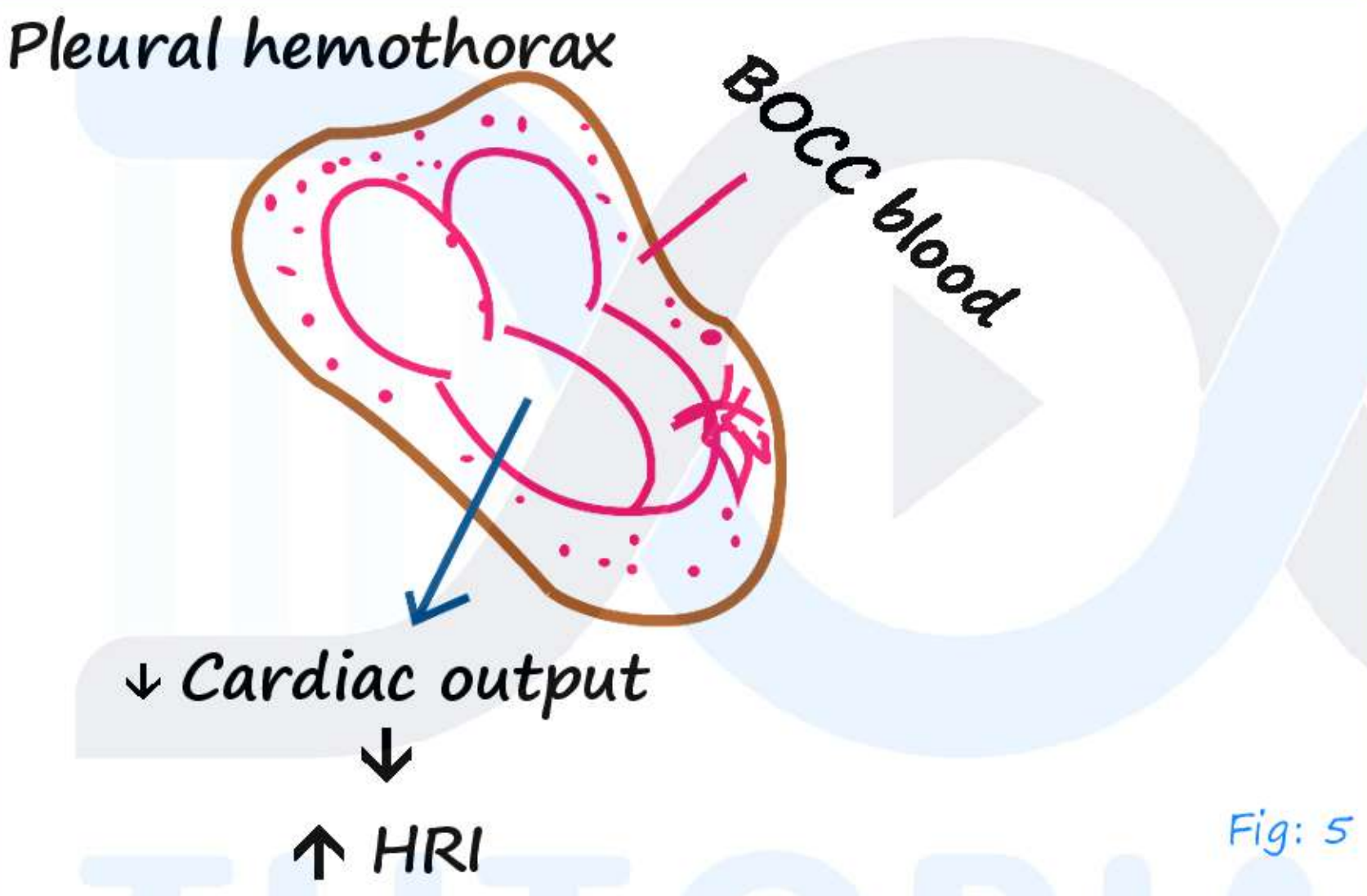

Fig: 5

- Heart pumps inside the pericardial sac
- If there is rupture (or) penetrating trauma of heart & heart is bleeding and the blood is collected in pericardial space.
- 50 cc blood is enough to cause tamponade effect
- Every pumping of heart – some amount of blood comes out of heart.
- It will compress the heart and cause tamponade effect and decreased cardiac output – results in increase H.R
- Pericardial tamponade is characterized by **Beck's triad**

  - Raised JVP – because of SVC get compressed

- Low B.P
- Muffled heart sounds.

- **Kussmaul sign** – In normal inspiration – CVP decreases

  (Chest cavity size increases)

  In Kussmaul sign – On inspiration – already there is tamponade effect on heart and there is no more place for veins to expand, so there is increase JVP paradoxically.

- IOC – eFAST

  X-ray – Ice bag appearance

- When you diagnose pericardial tamponade, it is an emergency.

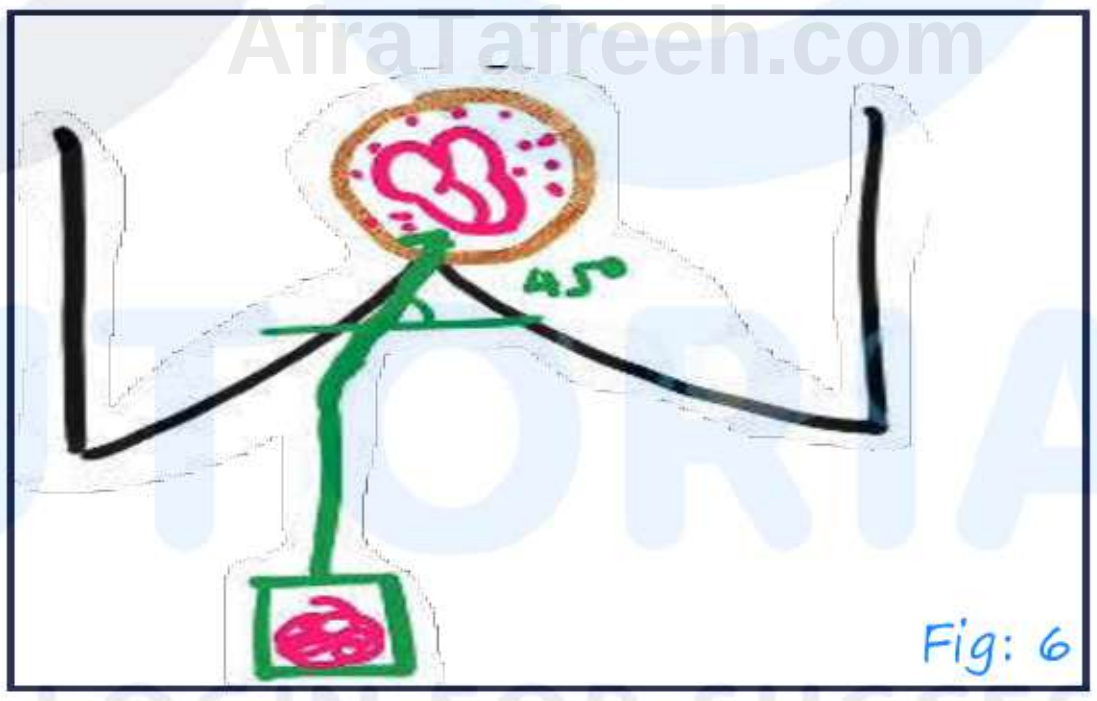

Fig: 6

- Under and echo guidance, pass a needle at 45° at xiphisternum level, put a catheter to drain to blood out.
- Even if you remove 10ml it has dramatic response on patient.
- 1st line treatment – Needle pericardiocentesis.

  Definitive treatment – Thoracotomy and repair the defect in heart.

AfraTafreeh.com

- Most common complication in needle pericardiocentesis – Arrhythmia if you touch the heart.

Tension Pneumothorax 00:33:45

Fig: 7

- Pleura is covering the lung which in turn covered by chest wall (outer)
- Pleural sac usually contains some amount of pleural fluid.
- Here in tension pneumothorax air is getting trapped inside the pleural sac and causing more and more compression of lung.
- It can happen, through a rib fracture and the sharp end of rib has penetrated the pleura only and it is now remaining as an opening and air form outside atmosphere is entering into pleural sac.
- Every time the patient takes inspiration, air from atmosphere enter into pleural sac → causes tension pneumothorax and lung gets compressed.
- This causes mediastinal shift to opposite side.

- Trachea pushed to opposite side
- Increased JVP
- Cardiac output Decreases → Increases PR → Decreases BP

- Most common mechanism – **Blunt trauma.** It also happen in penetrating trauma
- There are absent breath sounds on the side of tension pneumothorax
- There is tympanic percussion seen on that side.
- Important difference between tension pneumothorax and percardiac tamponade is absent breath sounds in tension pneumothorax.

Treatment of Tension Pneumothorax

- Put a needle in 2nd intercostal space, mid clavicular line, 16G venflan.
- Definitive treatment for pneumothorax → ICD tube

ATLS 10th edition

- **Adults : 5th ICS in MAL**
- **Children : 2nd ICS in MCL**

Pericardial Tamponade	Tension Pneumothorax
• Increases JVP • Decreases BP • Decreases CO	• Increases JVP • Decreases BP • Decreases CO

AfraTafreeh.com

• Most common cause – penetrating injury • Muffled S_1S_2 • No Mediastinal shift	• Blunt trauma • Breath sounds absent • Mediastinal shift present
Immediate 1st line treatment	
• Needle pericardiocentesis definitive treatment • Thoracotomy	• Needle thoracostomy • ICD is enough

Pneumothorax

- **Simple Pneumothorax**
- **Open Pneumothorax**

Simple Pneumothorax



Fig: 8

- Not happen in trauma
- It occurs due to any rupture of bulla inside/rupture of any cavity, that will let out air, this air is collected in the pleural cavity and can go back into

lung also. It is now working as closed compartment inside.

- It may have associated (pleural effusion) fluid collection known as hydropneumothorax
- It is a simple medicine case, not seen in trauma.
- T/t – ICD

Open Pneumothorax

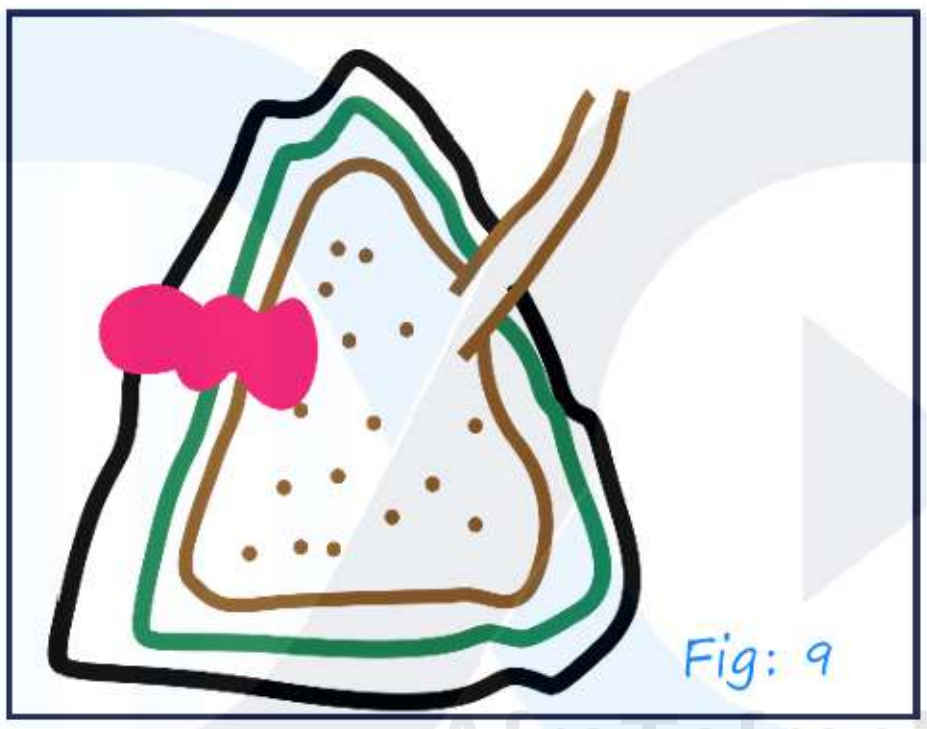
Fig: 9

AfraTafreen.com

- Important for surgeon and comes in immediate 6 life threatening injuries.
- Most common mechanism – blunt trauma/penetrating trauma. eg: Broken rib has torn the chest wall and pleura to lung.
- If the size of wound is >2/3 diameter of trachea (or) >3cm diameter – Then the atmospheric air goes into lung through the wound, not through the trachea.
- Air goes in during inspiration and goes out during expiration through the wound.

AfraTafreeh.com

- This type of pneumothorax is called **sucking chest wound.** There will be ineffective ventilation (or) ventilation perfusion ratio.
- So, in big wound which is sucking chest wound, we immediately put a membranous sheet on wound and cover it/close it on 3 sides
- So, on every breath, air comes out and then closes 2 will how allow the new air to go in.
- It is immediate Treatment → 3 way flap (or) valve closure of sucking chest wound
- Definitive treatment – Put ICD and close full wound until the wound heal, we will keep ICD.

Hemothorax 00:51:06

- Collection of blood inside thoracic cavity.
- Most common cause blunt injury > penetrating injury.
- Most common vessel to bleed – Intercostal artery
- Most common vessel injured in massive hemothorax (around 1.5L)
  - Internal mammary artery also aortic injury, pulmonary artery injury.

  It needs intervention.
- X-ray is diagnostic – shows huge collection of blood.
- On clinical examination, patient has low BP, Increased PR and patient is in hemorrhagic chock.

- eFAST helps to diagnosis pericardial tamponade, pneumothorax, hemothorax.
- In any type of pneumothorax, eFAST shows **barcode sign** (or) **stratosphere sign.**
- In normal lung, we get "**sea shore sign**" (air in the lung)
- 1st line T/t of hemothorax – ICD tube insertion

Indications of thoracotomy – in hemothorax

1. In Blunt trauma patient > 1500 ml coming out
2. In penetrating trauma patient > 1000 ml blood coming out
3. In any injury > 200ml/hr for > 3 hours

AfraTafreeh.com

Fractures In Chest 00:56:02

Fractures in the chest

Sternal fractures
↓
- High velocity injury causes it, generally uncommon
- Clinical features – Myocardial contusion is usually associated
  - ECG abnormality is seen

Rib fractures
- Simple fractures
  ↓
  Most common
  - 1st rib & 10th
  - 12th rib fracture are uncommon
- Flail chest

DX TUTORIALS LOGIN FOR SUCCESS

AfraTafreeh.com

- If 1st rib occurs, the contents of scalene triangle are at risk as it the boundary for scalene triangle like
  - Subclavian artery injury
  - Brachial plexus injury
  - Apex of lung can be injured

- If 10th – 12th ribs are fractures, we should think of
  - On left side – splenic trauma
  - On right side – liver injury
- 4th to 6th ribs can be fractured in CPR

Flial chest

- 3 (or) more ribs, fractured in 2 (or) more places is flail chest as per bailey.
- As per ATLS → 2 or more ribs at 2 (or) more places is flail chest (it is correct, actually)
- Even 1 rib fracture can cause flail chest, if there is dysarticulation of costo-chondral junction.
- In flail chest, fracture is not the prob, underlying pulmonary injury/confusion is the problem.
- Flail chest is a simple clinical diagnosis. By seeing a simple phenomenon, the fractured segment will become a flail segment

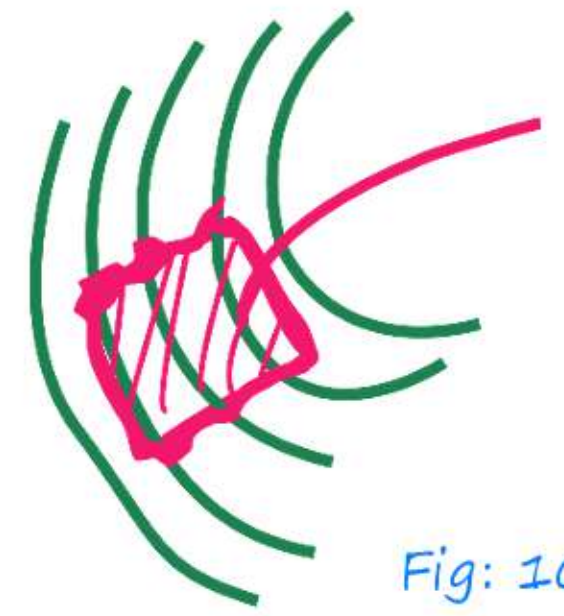
Fig: 10

- Flail segment goes for a paradoxical respiration i.e on expiration the chest wall moves in and flail segment moves out. Inspiration chest wall moves out and flail segment moves in.
- On clinical examination – patient has hypoxia major cause of hypoxia is due to pain (patient do shallow breathing) and also another cause is underlying confusion.
- Glod standard IOC – 3D CT thorax – It is also radiological IOC (not x-ray)
- It shows underlying lung injury and rib fracture both.

AfraTafreeh.com
TUTORIALS
LOGIN FOR SUCCESS

Management of Flail chest

- Admit the patient and analgesics to be given

  nasal O_2

  Strap the ribs

  rest
- If PaO_2 is normal – No problem
- If PaO_2 < 60% (or) R.R > 18/min – Then only go for IPPV (Intermittent positive pressure ventilation)
- After recovery of patient go for rib internal fixation is done.
- Most important prognostic factor in these patients is underlying pulmonary contusion.

AfraTafreeh.com

Diaphragmatic Injuries 01:07:18

- Diaphragm can in injured by penetrating injury (or) blunt injury. Penetrating injury is the most common.
- Suspect diaphragmatic injury in case of any penetrating injury below the 5th intercostal space.

- Penetrating injuries are usually small defects
  It is missed diagnosis
  They present very late

- Blunt injury – Big defect is seen
  contents from abdomen immediately enter chest due to negative suction pressure.
- Presents at time of injury with diaphragmatic hernia, on X-ray bowel can be seen in the chest.
- One clinical examination itself we can diagnose patient has tachypnea, dyspnea.
- Most common organ to herniate is stomach.
- Bag and mask ventilation C/I.
- IPPV through a E.T tube is given.
- IOC – VATS – Video assisted thoracoscopic surgery
  D. lap – Diagnostic lap. It is best, because we can diagnose and repair the hernia.

- **Bergvist triad**
  – It is associated with diaphragm rupture

DOCTUTORIALS LOGIN FOR SUCCESS

- Fracture of ribs
- Fracture of spine (or) pelvis

Aortic Injury 01:12:45

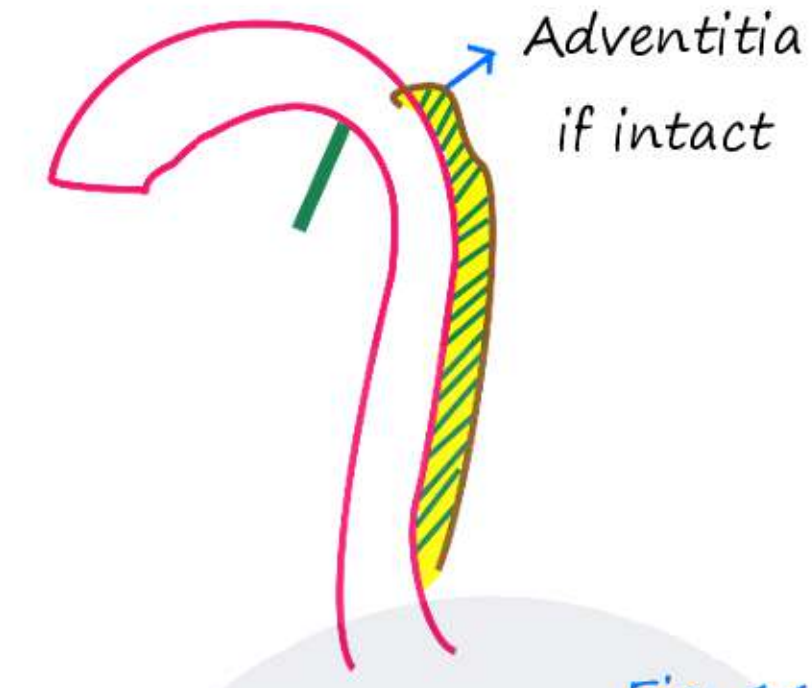

Fig: 11

- It is common in blunt trauma chest, it is acceleration – deceleration type of injury.
- Most common site of injury is distal to ligamentum arteriosum, there is a disruption of tunica intima.
- So, there is a dissection in tunica intima to T. media layer
  - There is an aneurysm happening called dissecting aneurysm.
  - Most of the time T. adventitia is intact.
  - If adventitia is intact, then blood is trapped between intima and media layers and form dissecting aneurysm.
- Clinical Features –

  When B.P measure between 2 limbs there is difference

  Right U.L vs Left U.L has disproportionate BP

  U.L vs L.L has disproportionate Bp – sometimes

  (Asymmetry of B.P with hypotension is seen)

AfraTafreeh.com

- X-ray chest – shows wide mediastinum and left bronchus may be depressed.
- Immediately go for eFAST – shows mediastinal collection
- If patient is stable – IOC – CT Angio
  Unstable – IOC – Transoesophageal echo
- T/t – Immediately provide permissive hypotension SBP <120 by using short acting **Esmolol**. To prevent bleeding and more direction aneurysm happening

Intervention – 2 methods

1. Endovascular – If it is a partial tear we can do TEVAR (Thoracic Endovascular Aortic Repair)
2. Open Surgery – when there is ruptured vessel that is bleeding severely, open up and repair with Dacron graft

- Dacron is used for aortic grafting.

Tracheobronchial Injury 01:17:56



Fig: 12

- If there is a disruption, the air won't go to lung, but comes out and patient has severe hypoxia.
- It is an immediate life threatening injury.
- Clinical features – Subcutaneous emphysema
  Pneumothorax
  Severe hypoxia
- If we put ICD – there is a massive air leak from ICD tube, every time the patient breaths (clue)
- This needs immediate open & repair.

Potentially life-threatening injuries – (6)

- Diaphragm – IOC → D. lap
- Aortic – IOC → CT Angio vs TEE
- Trachea bronchial injury → Immediate life threatening injury (ATLS 10e)
- Esophageal injury

AfraTafreen.com
TUTORIALS
LOGIN FOR SUCCESS

Myocardial contusion

- Seen in blunt trauma.
- Seen in patients with ECG abnormalities
- Patients have no elevated enzyme levels.
- Close monitoring is enough, most of them will recover, look for arrhythmias.
- Trans esophageal echo can be done.
- Normal 2D echo may show wall movement abnormalities.

AfraTafreeh.com

Pulmonary Confusion

- Most common after blunt trauma.
- Patient may land in hypoxia, dyspnea, tachypnea.
- On X-ray, up to 24 hours won't show any change.
- CT chest – IOC
- Treatment – No need of fluid restriction
  Normovolemia is maintained.
- Only when severe hypoxemia is happening, we should go for mechanical ventilation

Emergency Thoracotomy – Done in OT

1. Usually left anterio lateral thoracotomy for left side injuries.
2. Right A.L thoracotomy for right side injuries
3. Median sternotomy for cardiac injuries.
4. Clamshell thoracotomy

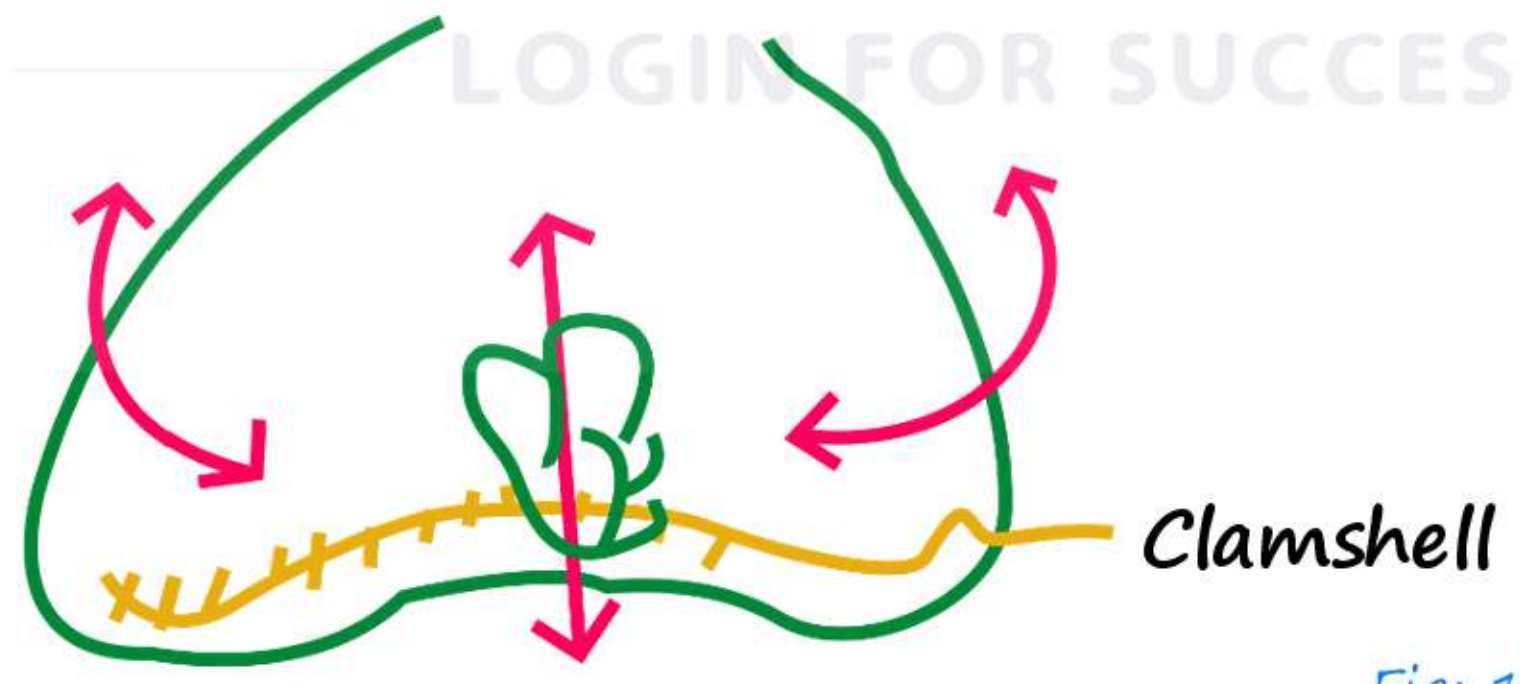

Fig: 13

- Put incision on both sides and lift the chest and go inside is known as CLAMSHELL thoracotomy.

Indications of emergency thoracotomy

1.Hemothorax – 1500 ml in blunt trauma
1000 ml in penetrating trauma
2000 ml/hr in 3 hours.

2.Aortic injury

3.Diaphragmatic injury

4.Open pneumothorax

5.Pericardial tamponade

6.Esophageal injury

Rare cases like

7.Air embolism – go open up and take it out

8.Bronchial vessel bleed.

Emergency department thoracotomy 01:29:10

- Done in casualty itself
- In this

1.We can do internal cardiac massage

2.Control major bleed from aorta/heart/lung

3.Massive leak in bronchus

4.If there is bleeding from lower limb, we cross clamp the descending aorta.
So that brain and heart receive adequate blood supply.

- Incision here is **left anterolateral incision**
- Now a day only indication for emergency thoracotomy is penetrating injury with signs of life presents

AfraTafreeh.com

- EDT is not useful for patients for whom
  1. CPR is done > 5 mins with no ET tube.
  2. CPR done > 10 mins with ET tube.
  3. Patients with blunt trauma with no signs of life.

Scenarios asked in the ICD as Viva

1. If air column not moving up and down, it implies → there is blockage/displacement of tube.
2. If there is excessive air coming out of ICD tube, it signifies the tracheo – bronchial injury.
3. Where will you point the tip of ICD tube in
   a. Pneumothorax
   b. Haemothorax
   – point towards apex.
4. When will you remove ICD tube – when lung is fully expanded/fluid coming out is <50ml
5. Can we clamp on excessive bleeding in hemothorax – does it have tamponade effect? → No

- Pericardial effusion – On X-ray ice bag appearance
  - To arrest bleeding from lower limb, we have to divert blood to upper part of body – we have to clamp the descending thoracic aorta.
- Instead of clamping descending aorta, we can use special endovascular balloon occlusion called **REBOA** – Resuscitative endovascular balloon occlusion of aorta.
- It is a quicker and less invasive method than opening clamping aorta.

TUTORIALS LOGIN FOR SUCCESS

- We pass it through femoral artery by using 7 french sheath introducer, this canula is passed up into aorta, sheath is introduced. Balloon is reached upto descending tract aorta
- Then balloon is inflated and blood will now flow down it is a temporary procedure, now a days advised

AfraTafreeh.com
TUTORIALS
LOGIN FOR SUCCESS

AfraTafreeh.com

ABDOMINAL INJURIES

Diagnostic peritoneal lavage (DPL) 00:00:46

- It can be done in hemodynamically unstable patients also
- It is an invasive procedure
- Indications → Abdominal trauma
  - Unstable cases
  - Penetrating injuries (to look for bowel injury)
- Where ever fast is not available, it is still used

Steps

- Patient is lying supine
- Open abdomen at level of umbilicus
- Slowly open various layers, catch and open peritoneum. Everything done under vision
- Either supra (or) infra umbilically open peritoneum
- Now insert a tube (usually a suction catheter small catheter). We connect it with one litre (1L) of ringer lactate (RL)
- Then the patient lies in different positions like supine for some time, lateral for sometimes etc.
- Then we have to let out the fluid and examine the fluid after some time

- **We say DPL is positive**

  1.When aspirating in syringe, if we get > 10ml blood

2.When > 1lakh RBC/ µL (or) mm^3

3.>500 WBC/ µL (or) mm^3

- It is equal to 20ml blood in peritoneal cavity

4.>175 IU/L of amylase +++

5.Presence of bile, bilirubin increased (++)

6.Presence of alkaline phosphatase

7.Presence of food particles/ vegetables matter

- DPL is 97-98% sensitive for finding any injury inside the abdominal cavity
- Now a days, only role of DPL is patients with multiple injury when non time to examine every injury & we have to rule to abdominal injury (otherwise it is totally replaced by FAST scan)

AfraTafreeh.com

Disadvantages of DPL

- It is invasive
- It is non-repetitive
- Many times it is false positive and we have done non therapeutic laparotomy is done unwantedly in those cases (here the bleeding may be due to small hematoma in spleen which is sealed, small mesenteric tear stopped bleeding, etc)
- Retroperitoneal injuries cannot be diagnosed (not useful)

DPL —**replaced by**→ FAST (**4 regions**) —**replaced by**→ eFAST (**6 regions**)

AfraTafreeh.com

Focussed assessment of sonography of trauma

00:09:41

- It is non invasive
- It is repetitive
- Rapid test, done in 5min
- It can be done by casualty M.O (or) Surgeon, no need of radiologist

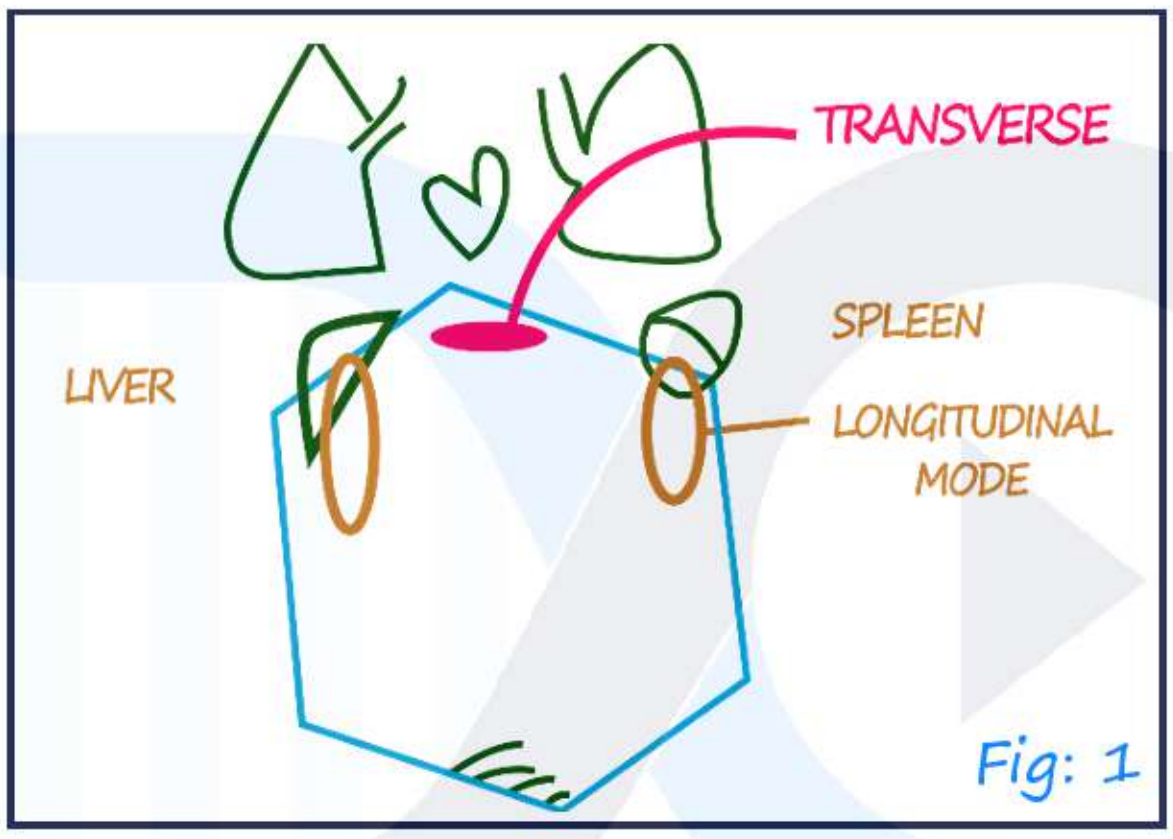

Fig: 1

- The regions we focus are liver, spleen, heart, lungs, pelvis
- The probe in kept in transverse mode in epigastric region. It is used for pericardial tamponade effect
- In Ⓡ hypochondrium and Ⓛ hypochondrium, we use longitudinal mode
- On Ⓡ side, it is used to look for liver injury
- On Ⓛ side, it is used to look for spleen injury
- In pelvis, we used both transverse mode and pelvic mode
- eFAST – is the FAST extended to chest also Ⓡ & Ⓛ side (Right side thoracic cavity and left sided thoracic cavity)

- Totally 6 regions are examined in eFAST. In thoracic region Ⓡ & Ⓛ side → we can find out pneumothorax lung we get **barcode sign** aka **stratosphere sign**
- >100ml blood in any area is detected

Disadvantages of FAST

- It is operator dependent
- It can't detect bowel injury
- It can't detect retro peritoneal injury including kidney injury
- It is not done in (or not sensitive in) penetrating trauma
- It can detect bleeding >100ml only (<100ml it can't pick up)
- Hematoma appears as hypoechoic shadow

AfraTafreeh.com

Abdominal injury 00:17:20

TUTORIALS LOGIN FOR SUCCESS

- Overall, most common injured organ in abdomen – spleen
- Order of organs injured in different injuries are
  a. Blunt trauma → spleen > liver > small intestine
  b. Penetrating trauma → liver > stomach > small intestine > diaphragm
     - Latest grading according to National trauma directory board (NTDB)
  c. Gunshot → small intestine > colon > liver

AfraTafreeh.com

d. Seat belt → mesentery, in GIT site → D-J flexure.
It is an acceleration-deceleration injury

e. Bomb blast → Urban blast → Ear drum > lungs
→ underwater blast → T. ileum

Protocol in management of blunt trauma & penetrating trauma 00:22:50

- Patient with blunt trauma abdomen – immediately do eFAST
- If patient with blunt trauma + features of peritonitis, like severe guarding, rigidity, tense abdomen, no need to do eFAST → directly go for exploratory laparotomy
- If eFAST is negative, wait and watch, do follow up
- If eFAST is positive and patient is stable → do CECT abdomen only for stable patients
- Id eFAST is positive and patient is unstable → directly shift him for exploratory laparotomy
- In unstable patient, there will be either hollow organ injury (or) solid organ injury (will be dealt separately)

DX TUTORIALS LOGIN FOR SUCCESS

Penetrating trauma 00:26:34

- Gun shot – Go for exploratory laparotomy
- Sharp object – [No role of eFAST]
  i. If patient unstable, peritonitis seen → take to exploratory laparotomy
  ii. If patient is stable local exploration of wound

- On local exploration, if there is no peritoneal breach, observe for 1-2 days, start oral nutrition and discharge patient
- On local exploration, if there is no peritoneal breach → go for a CECT abdomen
- On CECT abdomen – if there are finding present, peritonitis, gas, ongoing bleed → needs exploratory laparotomy
- In peritoneal breach if everything is normal, admit the patient and observe serial haemoglobin should be observed for every 8 hours. Look for WBC count is not increasing
  - We will discharge after 2 days
- If Hb falls by 3gm/dL, (or) increase WBC count, go for exploratory laparotomy.

Injury of hollow organs in abdomen 00:31:34

- Stomach (1st), colon (2nd), small intestine (3rd), rectum (4th)
- Most common mechanism of injury
  1. Stomach – penetrating trauma
  2. Colon – penetrating trauma
  3. Rectum – penetrating trauma
  4. For small bowel → Blunt trauma > penetrating trauma

AfraTafreeh.com

Stomach injury

- In blunt trauma of stomach, most common site of injury occurs in antrum in the greater curvature.
- In penetrating trauma – don't miss anterior penetration and posterior wall penetration should also be looked and examined by opening the lesser sac
- Treatment of gastric trauma is always repair with 2-0 vicryl sutures (sometimes 2 layered repair is also done)

Small bowel injury

- It is most common by blunt trauma > penetrating trauma
- If patient is stable → we can be definitive repair like repair tear (or) resecting anastomosis
- If patient is unstable – do DCS damage control surgery. DSC → e.g. if there is injury of jejunum, make proximal jejunum as stoma and distal part is clip and drop it inside called **clip and drop method**

Colon injury

- Here also if patient is unstable/ severe contamination of peritoneum with faecal material – do **clip & drop method**

Rectum

- If patient has less contamination – go for repair
- If patient has high contamination – do Hartman's procedure, it is a type of clip and drop
- We do a proximal colostomy, which ever part of rectum is fully damaged, that part is removed & distal part we will leave inside as Hartman's pouch
- In all these places, we will go reversal, once patient becomes stable and recovered (we will reversal the procedures)

Pancreaticoduodenal injury 00:38:46

- In blunt trauma of abdomen → most common site of pancreas injured is the neck
- In penetrating trauma of pancreas, it is seen equally in all places, head, body and tail
- Blunt trauma is the most common cause of injury to pancreas
- In 50% of patient's serum amylase is elevated
- **Duct disruption** – most common important prognostic factor
- IOC – CECT abdomen
- Isolated duodenal injury – directly repair and keep drain in nearby place
- Distal pancreatic injury with duct disruption → Distal pancreatectomy + splenectomy

AfraTafreeh.com

- If patient is having injury at head level → isolated head of pancreas injury → BEGER procedure (DPPHR – Duodenum Preserving Pancreatic Head Resection)
- Only head of pancreas is removed
- Distal pancreatectomy + splenectomy is done for distal injuries
- If there is combined pancreas head + duodenal injury → go for trauma Whipple's operation AKA Pancreatico-duodenectomy
- In normal Whipple's, we do reconstruction like gastro jejunostomy, hepaticojejunostomy etc. But in trauma Whipple's only resection is done, no reconstruction is done. After patient recovers then we go for reconstruction op only resection @ 1st stage
- All these operations are done in stable patients

Unstable duodeno-pancreatic injury

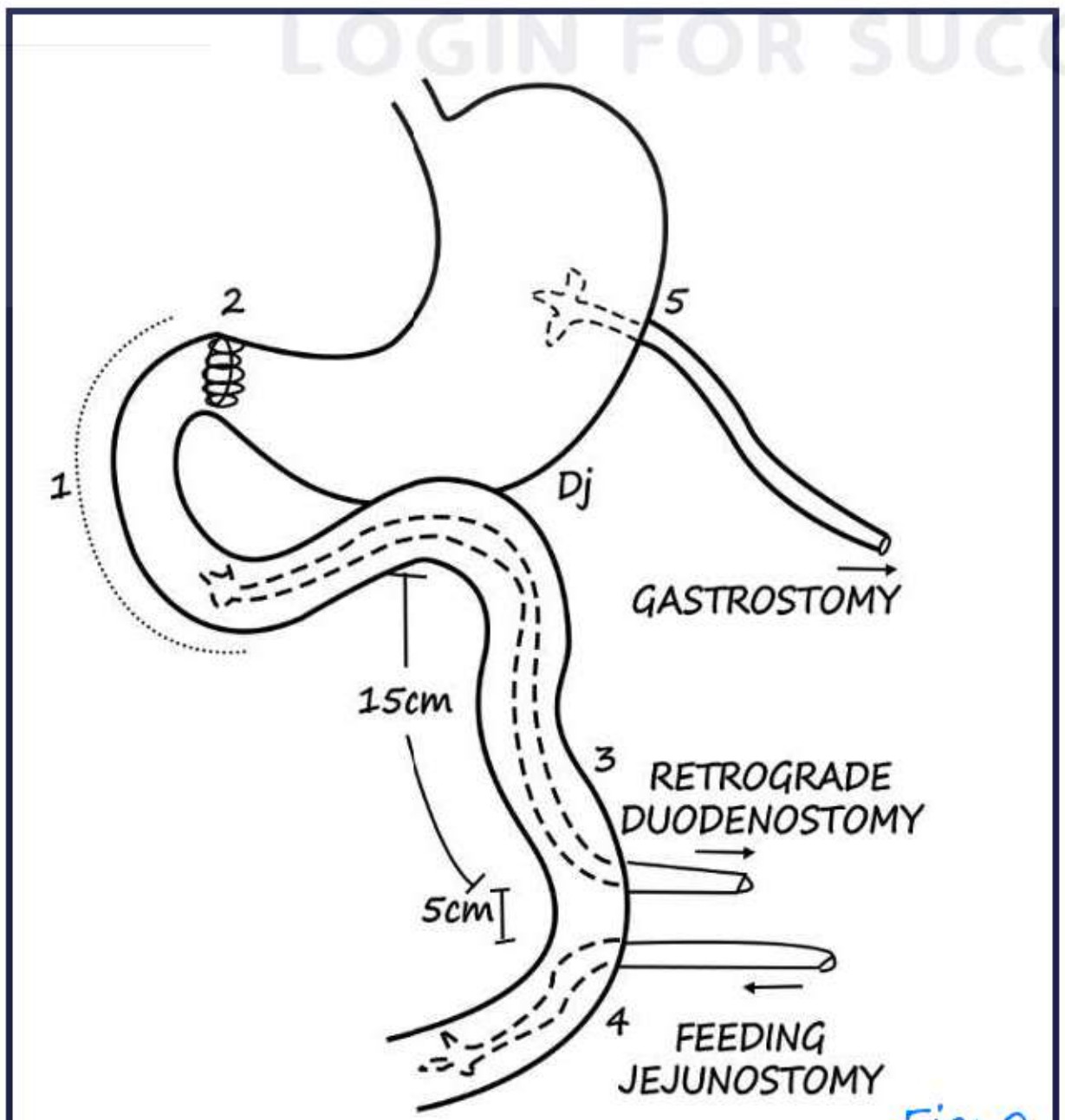

Fig: 2

- "**Triple tube ostomy**" procedure is done
- We put 3 tubes 1st tube is kept inside duodenum to drain known as venting duodenostomy (letting out bile secretion, pancreatic secretion everything outside)
- It is going to decompress duodenum
- 2nd → isolate the stomach by putting small sutures & opening stomach and put a pyloric exclusion. Avoid contents of gastric juice to go inside called pyloric exclusion
- Venting decompressive gastrostomy is done
- We will also do feeding jejunostomy → 3rd tube
- One tube to let out duodenal contents, one tube to let out gastric contents, another tube for feeding into jejunum
- Apart from these tubes, drains are kept in pelvis & abdomen and hypochondrium

TUTORIALS
LOGIN FOR SUCCESS

Solid organ injuries 00:48:35

- Liver: most common mechanism of liver injury → penetrating trauma
- Spleen: most common mechanism of injury – Blunt trauma
- Kidney: most common mechanism of injury – Blunt trauma

AfraTafreeh.com

- Pancreas: most common mechanism of injury – Blunt trauma

Liver injury -

- AAST grading – American association for surgery on trauma

Grade	Liver			Spleen
	Subcapsular hematoma	**Laceration**	**Subcapsular hematoma**	**Laceration**
I	<10% That id under the liver capsule if there is <10% area hematoma	Laceration is <1cm depth	<10%	<1cm
II	10-50% (if it is	1-3cm depth	10-	1-3cm
III	>50%	>3cm depth	>50%	>3cm
IV	There is parenchymal disruption/ involvement of 25-75%	New points added in latest scale are 1-3 Couinaud segments involved in single lobe (G_4)	There segmental (or) hilar vessels disruption present >25% Devascularised spleen	

V	>75% parenchymal disruption	>3 segments involved in single lobe is G-5. In G-5 retro-hepatic IVC & main hepatic vein injury ⊕	Main hilum is disrupted shattered spleen
VI	Hepatic avulsion (came out of original place)		

AfraTafreeh.com
TUTORIALS
LOGIN FOR SUCCESS

Liver trauma 00:56:46

Liver trauma

- **Most common by penetrating trauma**
- **Blunt trauma**

- In isolated liver injury, if patient is stable, directly we can repair it

AfraTafreeh.com

- If liver injury and patient is unstable → DCS is done (damage control surgery)

DCS of liver – 4p's

1.Push

- If liver is bleeding, we should push it posteriorly by keeping a pad anteriorly, then keep 4 quadrant pack all around the liver, (called push and pack) count the number of packs kept

2.Plug

- If bleeding is coming from inside, like laceration u plug it with Foley's catheter and inflate the balloon. Sengstaken blackemore tube is also used. Don't use omentum to plug

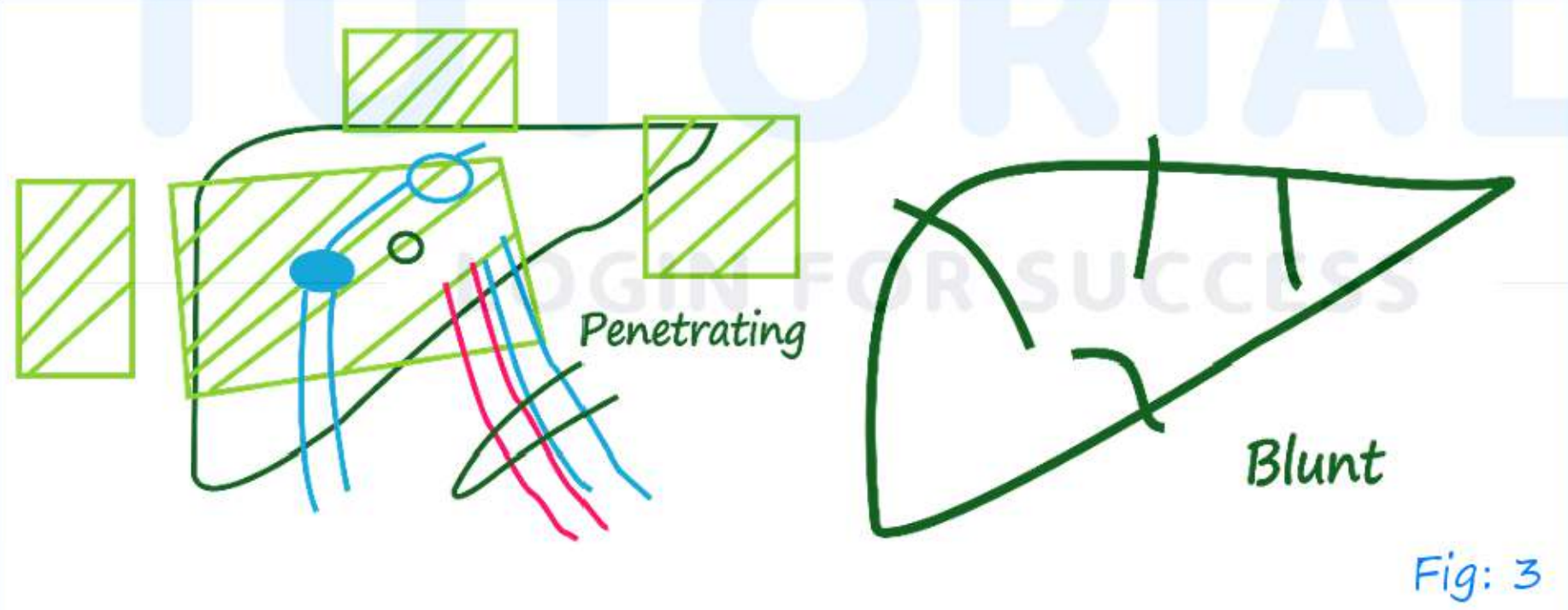

Fig: 3

3.Pringle

- Pringle is a maneuvre by which we occlude the inflow vessels like hepatic artery, portal vein at the epiploic foramen. Maximum we can do this for 45 minutes

- If after pringle also, it is bleeding through it signifies that bleeding is from hepatic vein, IVC source pringle will arrest only portal vein and hepatic artery source bleed

4.Pack

- The pack removed after >48 hours – called phase III of DCS (reopen and remove pack). Now repair can be done by surgeons' team. Hepatic artery can be ligated (can be compromised) portal vein needs repair.

Spleen injury 01:02:40

AfraTafreeh.com
TUTORIALS
LOGIN FOR SUCCESS

- Important clinical features: 9-11th rib fracture – Left side
- Most common mechanism – Blunt trauma
- Severe tenderness ⊕ on left side
- Clinical examination – KEHR sign ⊕
  - Balance sign ⊕
- Kehr sign is referred pain to left shoulder due to the collection of blood on the left side of diaphragm, due to irritation of phrenic nerve
- Unilateral shifting dullness → Because of huge hematoma on left side, there is resonance of right side, but dullness persists on left side (Dullness will not shift). This is called balance sign

AfraTafreeh.com

X-ray chest and abdomen findings

- Fracture ribs is noted
- Left lung atelectasis is seen
- Obliteration of splenic outline
- Obliteration of psoas shadow
- Fundal gas shadow is pushed medially
  - eFAST – 1st investigation done
  - IOC – CECT abdomen, only in stable patients

Splenic trauma 01:02:46

- If patient is unstable, (no controversy) – directly do surgery immediately open abdomen
- If patient is stable, plan for CECT
- Unstable patient → open abdomen with long midline incision
- Grade 1,2,3 injuries → try to preserve spleen by spleenography procedure, by keeping mesh (or) omentum
- In grade 4,5 → go for splenectomy (non-controversy) for unstable patient, we fill find out the grade, during surgery only
- Stable patient → CECT abdomen – shows the grade of injury
- Grade 1,2,3 injury → conservative, non-operative management
- Grade 4,5 – (Have huge controversy) sabiston says – go for splenectomy

- Recent guidelines say even for grade 4,5 (of stable patient0 spleen injury are successfully managed by non-operative management
- Keep them under close observation & follow up
- In stable patient – serial CT scan is done (after 22 hours)
- Finding in it to say there is failure of non-operative management is tumor blush. It implies there is false aneurysm developed in splenic artery
- Tumor blush should be noted and should do an Angioembolization

Renal injury 01:15:16

- Retroperitoneal organ
- Most common mech is blunt injury
- Haematuria is seen in 40% cases
- IOC – CECT abdomen (no use of FAST)
- 90% of patients are managed by non-operative management
- 10% patient needs intervention
- E.g.: patient comes with right renal injury; left kidney is normal. CT scan shows grade 4 renal injury on right side, but patient is stable – so doing conservative management
- If we do (NOM) Non operative management, compulsorily we must do one investigation – to know

AfraTafreeh.com
DX TUTORIALS
LOGIN FOR SUCCESS

AfraTafreeh.com

functioning of kidney. Sometimes due to hematoma, the renal artery may be dismantled (or) hematoma compressing renal artery, such times kidney will never receive blood supply, and though the injury is grade-4, kidney gets wasted

- So, IVP should be done (in old days)

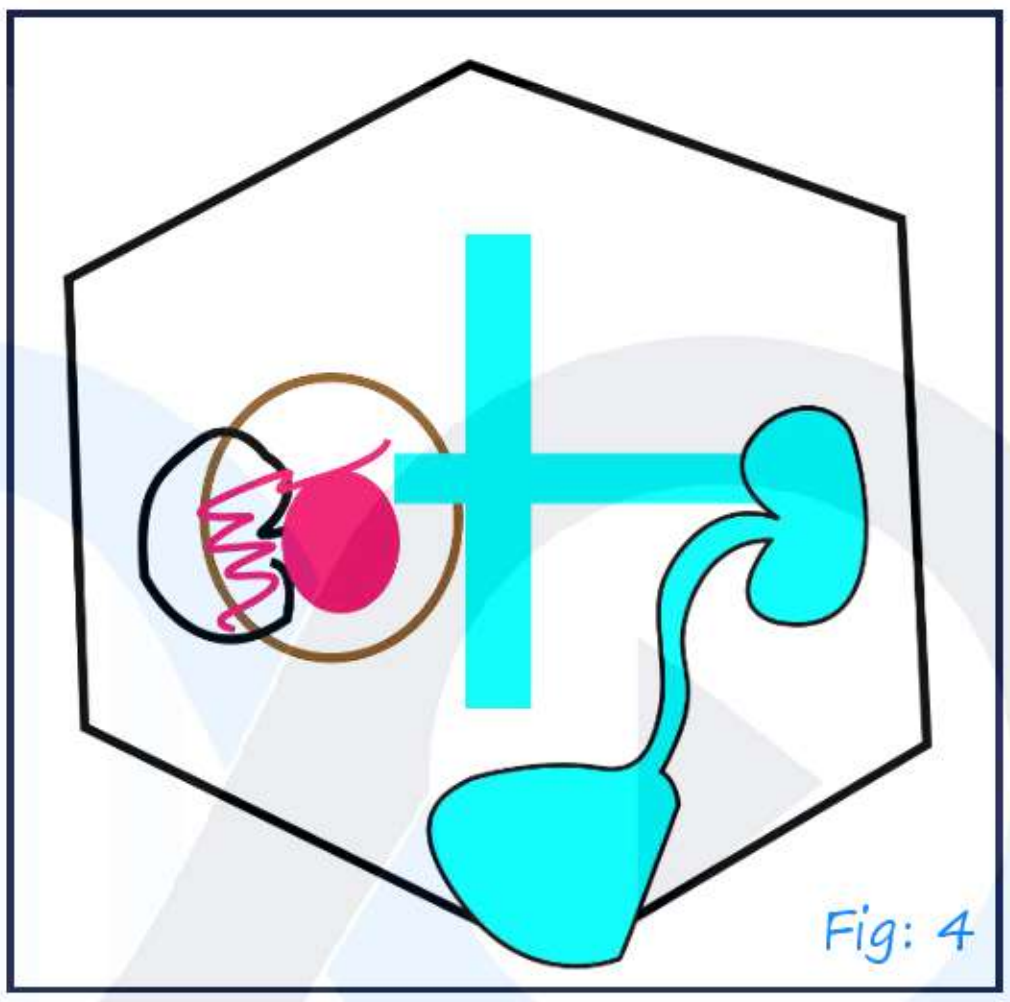

Fig: 4

- Now a days CT-pyelogram is done
- On IVP $\xrightarrow[\text{case}]{\text{In this}}$ left kidney, is visualised and urine is coming out from left kidney
- But right kidney is not visualised → means, immediately we should explore the renal hilum by laparotomy & do repair at the earliest possible, (then kidney survives)
- After repair, do on table IVP
- If kidney is successfully surviving – leave it as such
- If kidney is not surviving/ no enhancement on IVP/ kidney is already gangrenous – such cases, we go for nephrectomy

Renal injury grading

- Grade I – There is subcapsular hematoma, not expanding hematoma is confines to Gerotas fascia – not expanding
- Grade II – There is a laceration in kidney <1cm hematoma is confined to retroperitoneum only (in gerotas fascia)
- Grade III – Laceration >1cm and no urine extravasation
- Grade IV – Deep laceration, with urine extravasation seen. Renal artery and renal vein injury is present. Hematoma is expanding

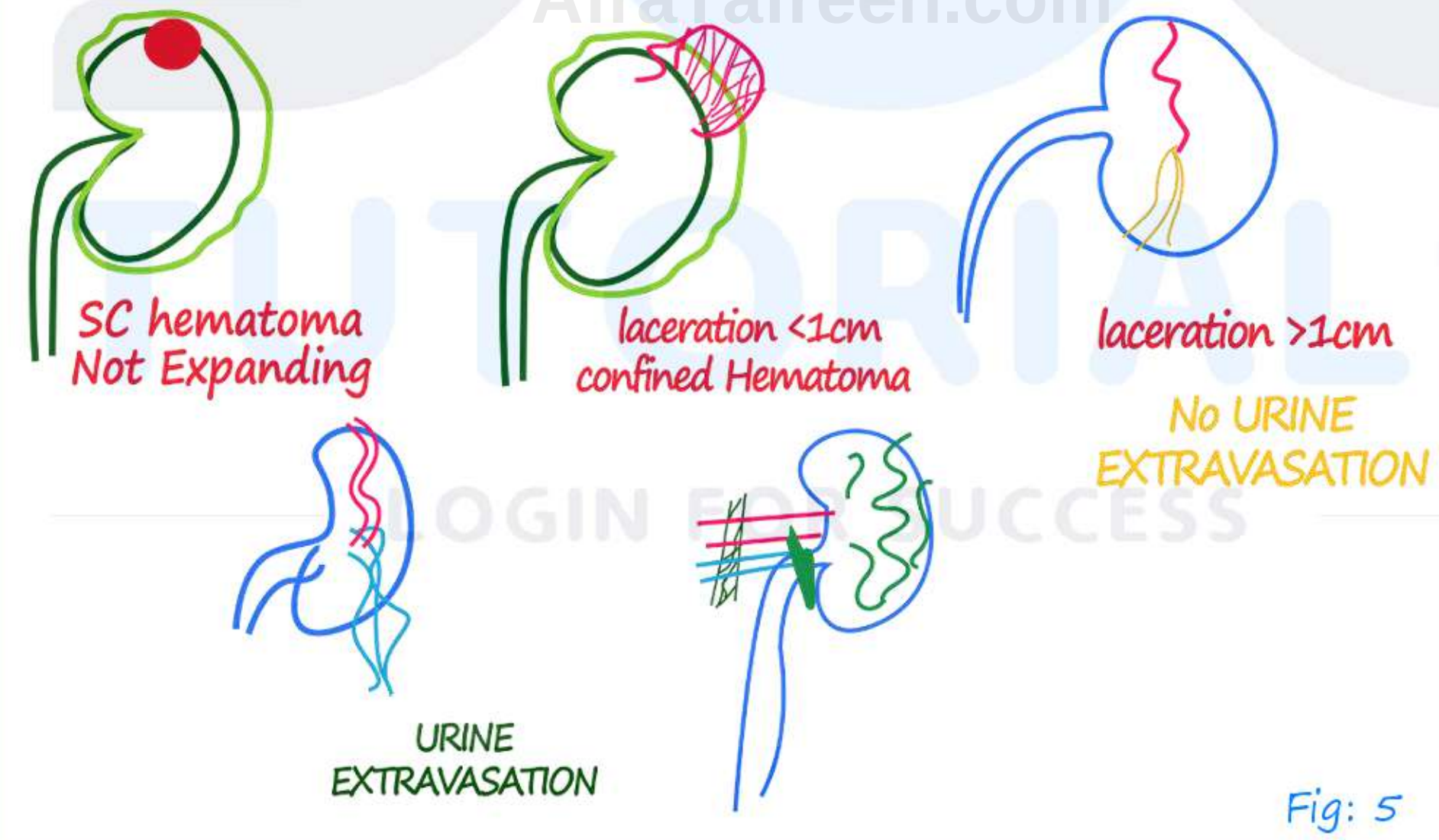

Fig: 5

- Grade V – Kidney is shattered
  - Renal hilum is avulsed
  - Uretero-pelvic junction avulsion
  - Complete occlusion/ cut off main renal art/ renal vein

AfraTafreeh.com

- If patient is stable, any grade → non operative management & go for IVP alone
- If patient is unstable → If no time for repair → do nephrectomy

TUTORIALS
LOGIN FOR SUCCESS

BURNS

Introduction 00:00:15

- Belongs to AIS – 9
- Most common cause of death in spot: – Asphyxia > neurogenic shock
- Most common cause of death in 1 –3 days (early death)

↓

Hypovolemic shock

- Most common cause of late death (>3 days) – septic shock
- Overall, most common cause of death – septic shock

AfraTafreeh.com

Admission criteria 00:03:50

1. >20% partial thickness in >10 years of age
2. >10% partial thickness in <10 years of age
3. >5% full thickness any age
4. Even 1% burns in eyes, face, fingers, genitalia
5. Electrical burns
6. Chemical burns
7. No body to take care
8. Psychiatric
9. Suspicious burns

TUTORIALS LOGIN FOR SUCCESS

AfraTafreeh.com

TBSA of burns

- Rule of 9 Wallace rule
- Palm rule 1%
- Lund and Browder → Best in children
- Berkow formula

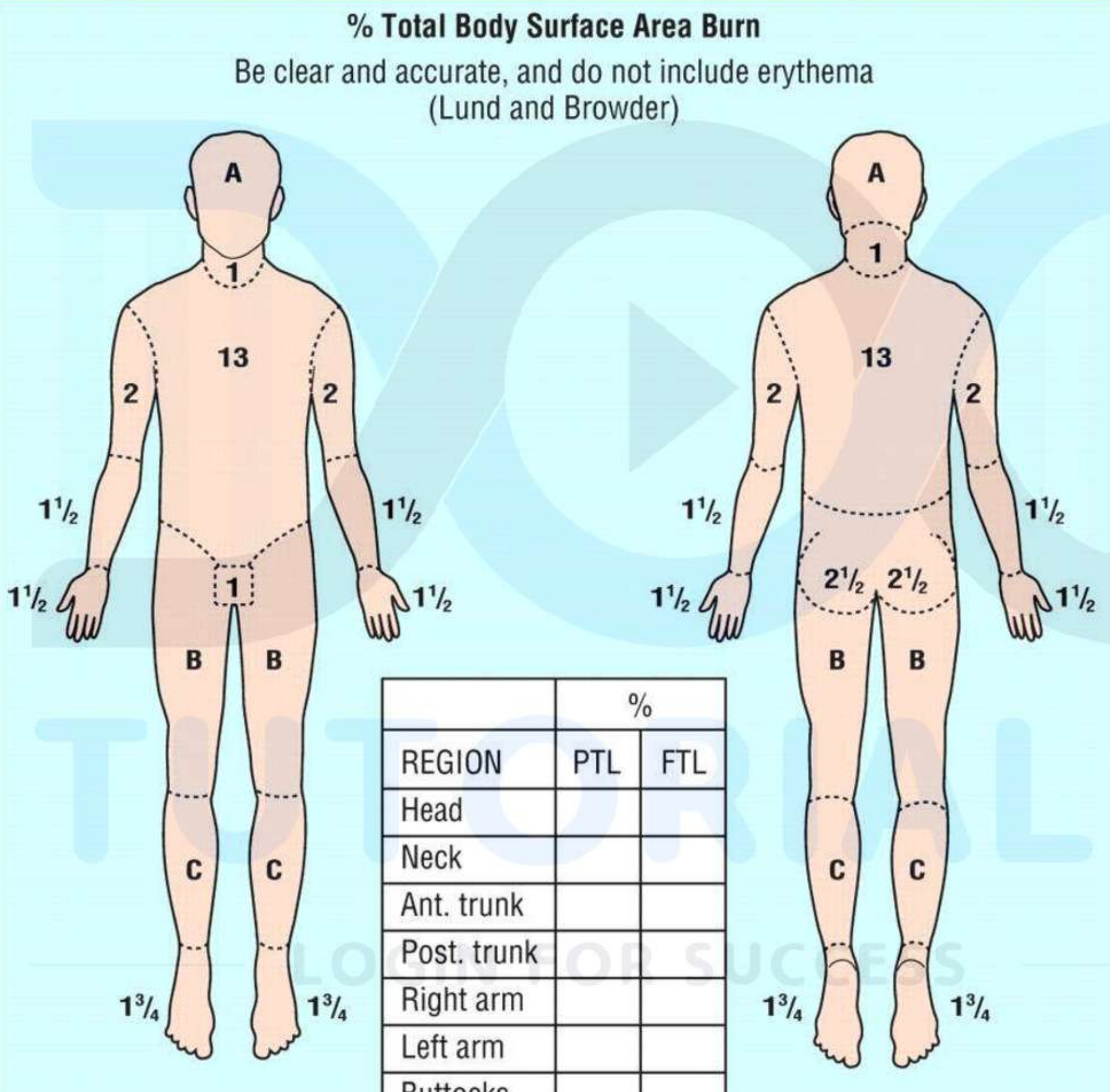

	%	
REGION	PTL	FTL
Head		
Neck		
Ant. trunk		
Post. trunk		
Right arm		
Left arm		
Buttocks		
Genitalia		
Right leg		
Left leg		
Total burn		

AREA	Age 0	1	5	10	15	Adult
A = 1/2 OF HEAD	9 1/2	8 1/2	6 1/2	5 1/2	4 1/2	3 1/2
B = 1/2 OF ONE THIGH	2 3/4	3 1/4	4	4 1/2	4 1/2	4 3/4
C = 1/2 OF ONE LOWER LEG	2 1/2	2 1/2	2 3/4	3	3 1/4	3 1/2

- According to Berkow formula, TBSA of infant is 21%

- Head 19%
- Neck 2%

Depth of burns 00:12:16

- IOC: – Laser flowmetry

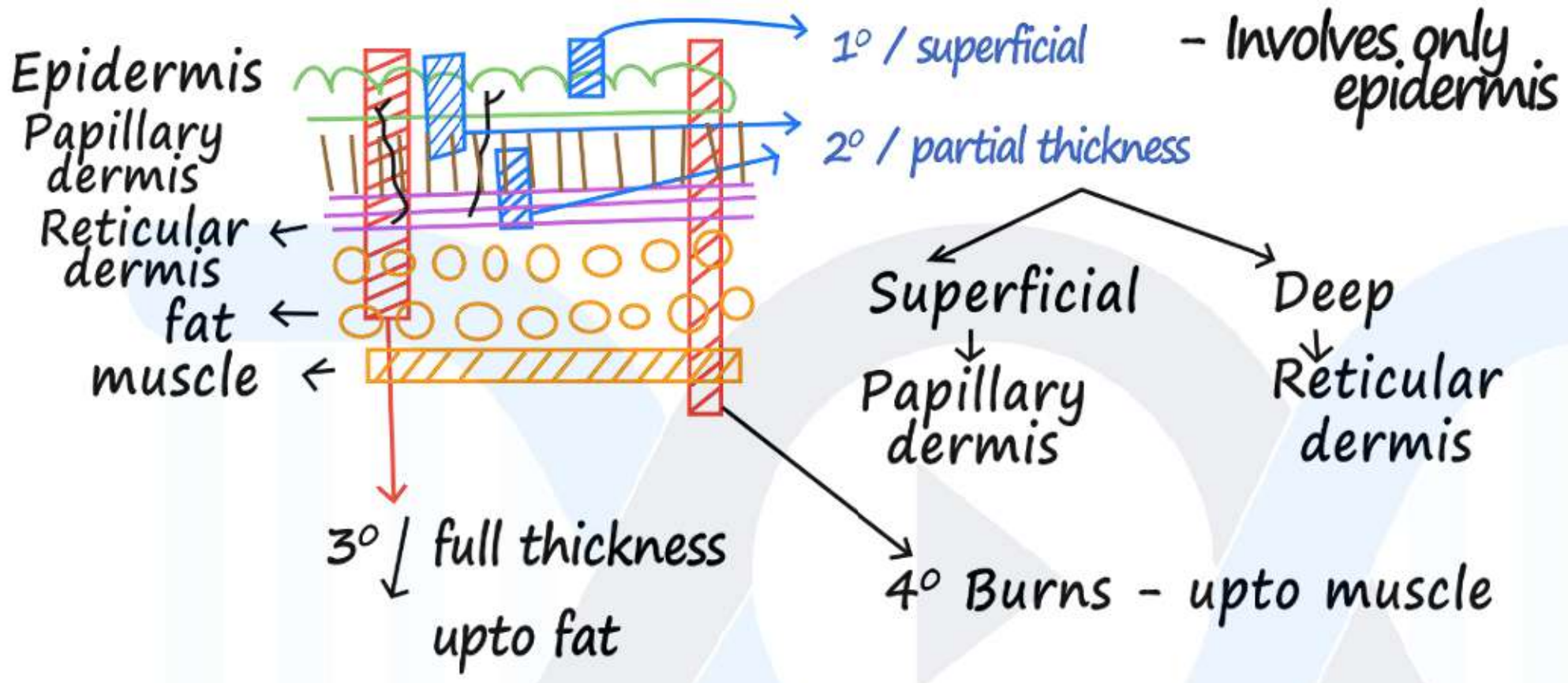

AfraTafreeh.com

Zones of burns

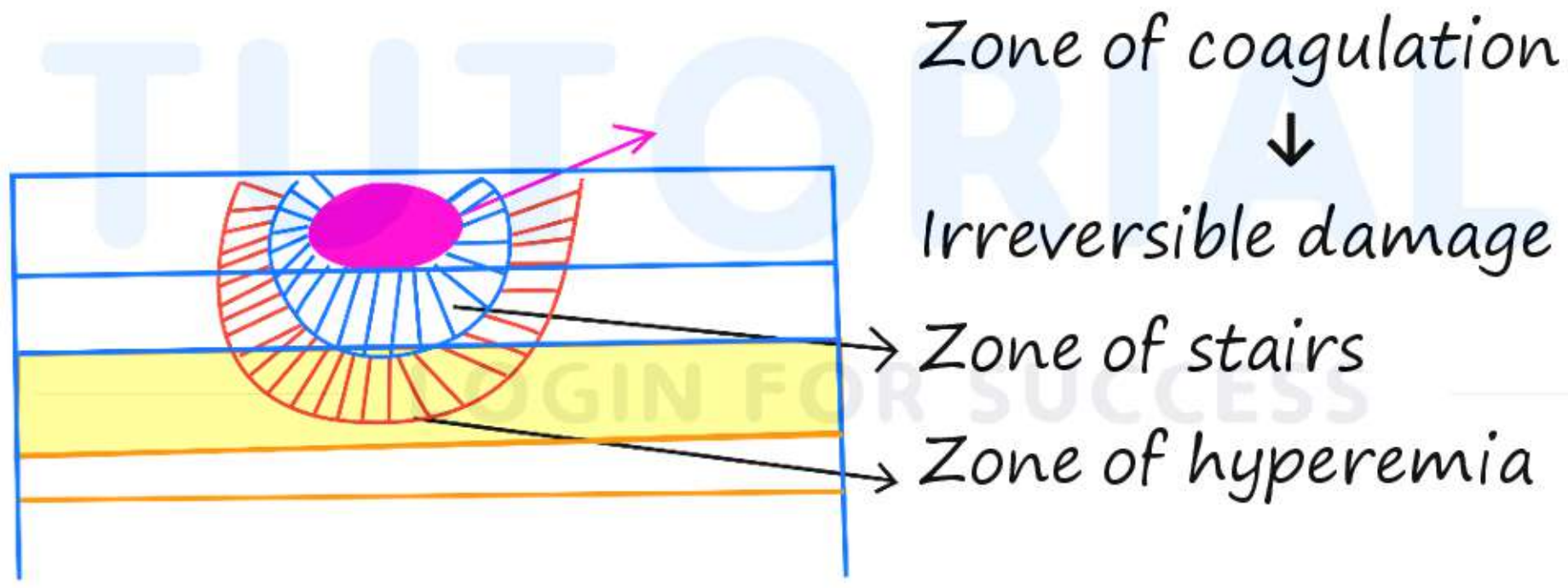

- Zone of coagulation → irreversible damage
- Zone of stairs – can either recover or go for irreversible damage
- Sone of hyperemia
  - Reversible
  - Vasodilatation ⊕

AfraTafreeh.com

- Inflammation

Clinical examination of each burn –

- 1st degree burns / superficial burns
  - Painful and severe erythema
  - Blanches on pressure ⊕
  - Severe erythema
  - Heals without scar in 7 days
- 2nd degree burns/partial thickness burns

Blisters → Superficial 2°	Blisters → Deep 2°
• Painful blisters	• Painless blisters
• Blanching ⊕	• Blanching is absent
• Superficial touch (cotton) ⊕	• ⊖
• Pin prick ⊕	• ⊕
• Takes 3 weeks – 5 weeks to heal	• 3 – 5 weeks
• Heal without scar	• Heal with the scar

- 3rd degree burns
  - Form eschar (++)
  - Superficial touch
  - Pin prick
  - Painless burns

TUTORIALS LOGIN FOR SUCCESS

- If there is circumferential eschar → forms compartment syndrome
  - ↓ Escharotomy ↓ Mid axial plane
  - ↓ contractures on healing

- 4th degree burns
  - Involve deeper structure
  - Muscles and tendons

Fluid management 00:26:30

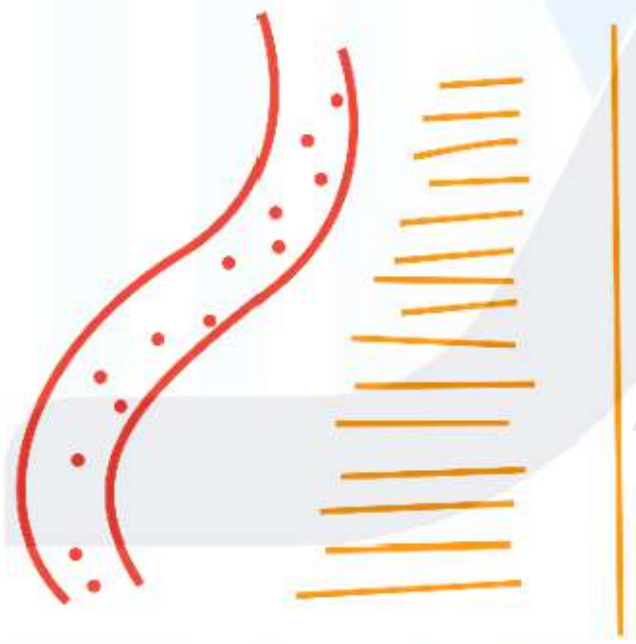

- Initial 12 hours, capillaries will be leaking
  ↓
  Protein will be leaking
  ↓
  Crystalloids → RL is fluid of choice → **Parkland formula**
- If colloids are given, they penetrate and enter extracellular space → edema

- After 12 hours
  - Dextran

AfraTafreeh.com
TUTORIALS
LOGIN FOR SUCCESS

AfraTafreeh.com

- Albumin
- Hydroxyethlstarch

- Parkland formula:

  1st 24 hours (from time of burns) – 4x wt. (kg) x TBSA

  Example: 4x50x20

  4000ml

  ½ in 8 hours ½ in 16 hours

ATLS formula 00:30:28

- >14 years: – 2x wt. (kg) x TBSA (2nd and 3rd degree burns)
- <14 years: – 3x wt. (kg) x TBSA (2nd and 3rd degree burns)
- 4th years electrical: – 4x wt. (kg) x TBSA
- > 14 years: – urine output 0.5ml/kg/hour
- < 14 years: – urine output 1 ml/kg/hour
- 4th electrical burns: – urine output 1.5ml/kg/hour
- In children – maintenance fluids in 24 hours

  ↓

  100ml/kg – 24 hours – 1-10 kg

  + 50ml/kg – 24 hours – 11-20kg

  +20 ml/kg – 24 hours ->20kg

  Example 25kg → 10 x 100 = 1000 ml

  10 x 50 = 500 ml

  5 x 20 = 100 ml

  1600 ml

- Colloids – after 12 hours

↓

"Muir and Barclay" formula

↓

Amount = 0.5 x wt. in kg x TBSA

= 1 portion

↓

36 hours	
4/4/4 -12 hours	100/100/100
6/6 – 12 hours	100/100
12 hours – 12 hours	100

- Most common cause of early death – Hypovolemic shock
- Hypovolemic shock can happen if TBSA >15% adults.

AfraTafreeh.com
TUTORIALS
LOGIN FOR SUCCESS

Nutrition in burns 00:40:52

- >20% TBSA → NG tube < 6 hours

Start nutrition

↓

Gut mucosal damage

Formulas: –

- Curreri
- Sutherland
- Davies

AfraTafreeh.com

Curreri formula 00:42:22

- Age: – 16–59: – 25 (wt.) + 40 (TBSA)

  = given in kCals

  >60 years: – 20 (Wt.) + 65 (TBSA)

- Pediatric

  ↓

  IV: – crystalloids + colloids

  ↓

  – Galveston

  – Brooke

Management of burns 00:46:06

- A – airway

  – singeing of hair, Hoarseness of voice ⊕

  ↓

  Intubate prophylactically

  ↓

  If delayed – Cricothyroidotomy

- B –
- C – cut down in GSV → 16 G/18G → fluids should be rushed
- D
- E

TUTORIALS
LOGIN FOR SUCCESS

How to manage burns wound

- Exposure treatment: – head (scalp), face burns

  Superficial burns

  Superficial partial thickness

  ↓

  Wash it and apply topical ointment

Topical ointments 00:49:54

1. Silver sulfadiazine – (1%)
    - cannot penetrate deeper tissues
    - used for superficial burns only
2. Silver nitrate (0.5%) → can cause black pigmentation
3. Mafenide acetate (5%)
    - painful
    - penetrate deeper into eschar
    - it can cause metabolic acidosis
4. Cerium nitrate
   Cerium bromide } Immunomodulatory → elderly

   ↓

   make the eschar sterile

- Deep 2° burns → collagen

Controversy to break/not

AfraTafreeh.com
TUTORIALS
LOGIN FOR SUCCESS

Ruptured blister → remove the blistered skin → collagen

- 2° deep/3° burns

  Split skin grafting

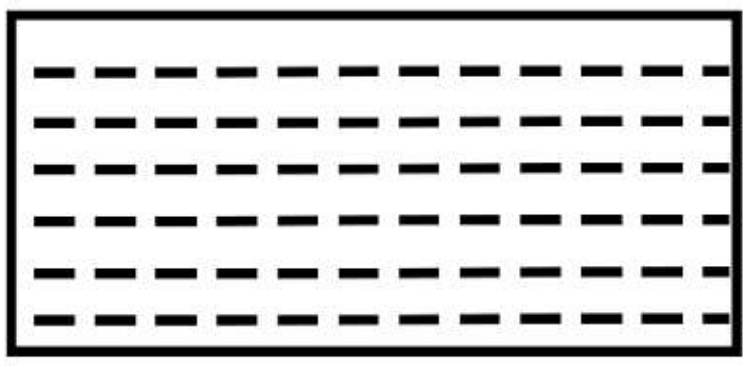

AfraTafreeh.com

- 1° - ointment
- 2° superficial → ointment / collagen
- 2° deep → ointment / collagen / SSG
- 3° → Escharotomy + SSG

↓

Contracture scars are developed → 'Z' plasty

Chemical burns 00:57:42

Chemical burns

Alkali

↓

- More dangerous
- More destructive

↓

Wash with water

Eyes → immediately wash with water

Acid

↓

Hydrofluoric acid

↓

M/c → hand

Hypocalcemia

Arrhythmias ⊕

↓

- Calcium gluconate gel 10% is applied
- Severe → Bier's block

↓

IVRA – prilocaine

Instead of prilocoine, calcium gluconate is given as IV

- If arrhythmia happens

↓

Debride and do not do SSG now

TUTORIALS LOGIN FOR SUCCESS

Electrical burns 01:01:52

Electrical burns

Low voltage
↓
- domestic
- small, painful, deeper

↓
Tetany ⊕

High voltage
↓

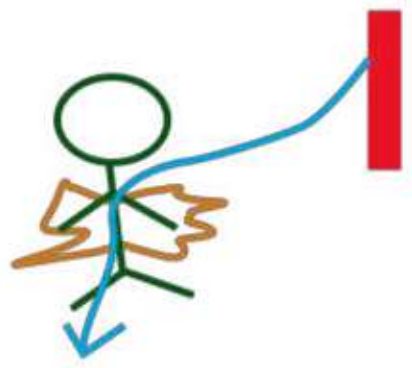

- Flash burns (arc)
- Flames
- Current entry/exist totally gone
  - Muscle necrosis
  - Compartment syn.
  - Myoglobinuria
  - Acute tubular necrosis
  - Direct cardiac damage

↓
- Increase ECG changes
- Elevated Cardiac enzymes

↓
Urine output >2ml/kg/hour

AfraTafreeh.com

Frost bite 01:07:06

- Due to continuous exposure to cold
- Frozen of limb
- Cold burns

↓
- Tissue dies

AfraTafreeh.com

- Vasoconstriction
- Reperfusion injury by free radicals

- 4 degrees
  - I degree – hyperemia
  - II degree – painful blisters, skin loss +
  - III degree – Hemorrhagic blisters, lost skin
  - IV degree – muscle and bone also involved

Trench foot 01:09:38

- Continues immersion of limb in cold water
- Immersion injury
- Treatment: – (refer page 632 bailey)
  - Rapid rewarming with water of 42° c
  - NSAIDS
  - Deep wound dry
  - Prevent infection
  - Dead/live demarcation
  - No early surgery is advised
- In 24 hours of receiving the patient

↓

Nerve blocks
TPA injected } Prevent amputation
(Tissue plasminogen activator)

Disaster injuries 01:14:00

- Tsunami – most common cause of death – drowning
- earthquake – most common cause of death – crush injury
- volcanoes – most common cause of death – suffocation

– urban bomb blasts

↓

Most common injure – ear drum > lungs

– underwater bomb blasts → GIT injury

↓

Terminal ileum

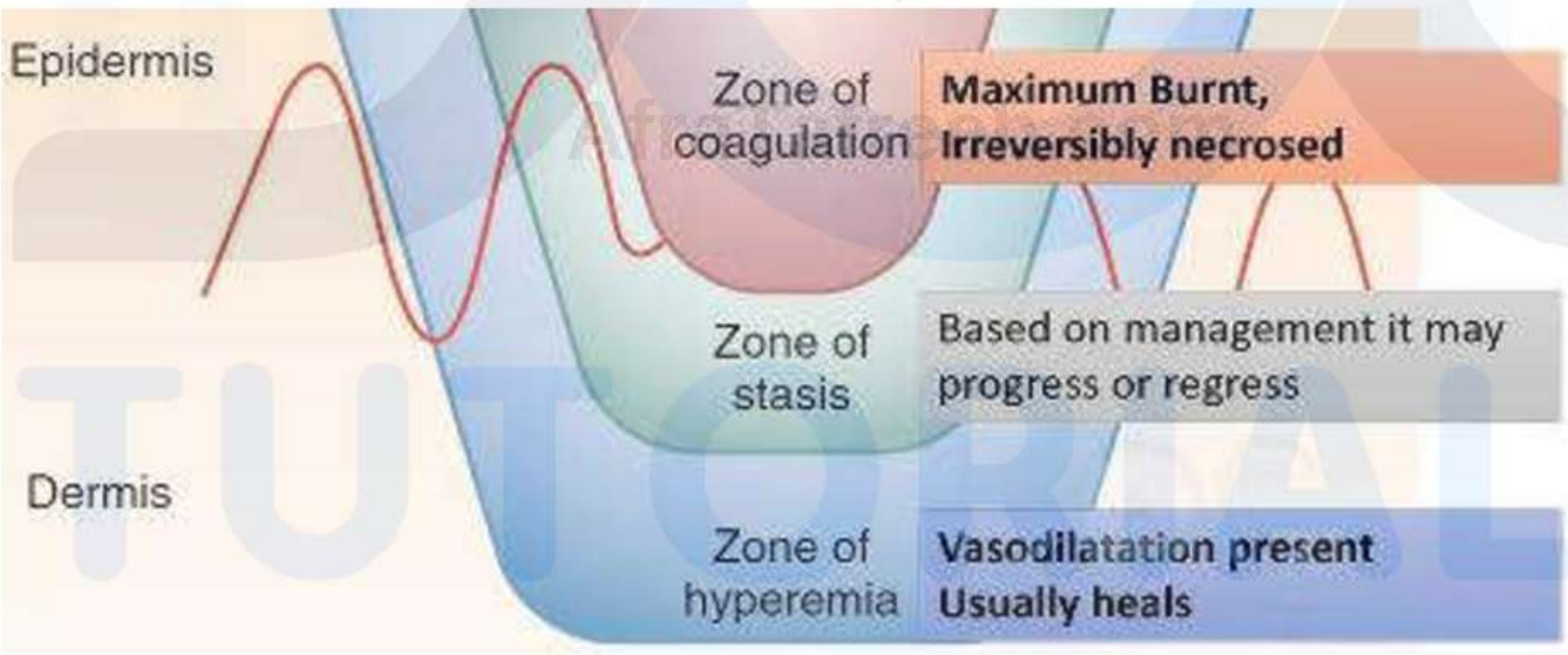

Age	0-1	1-4	5-9	10-14	15
A – 5 of head	9.5%	8.5%	6.5%	5.5%	4.5%
B – 5 of one thigh	2.75%	3.25%	4%	4.25%	4.5%
C – 5 of one leg	2.5%	2.5%	2.75%	3%	3.75%

AfraTafreeh.com

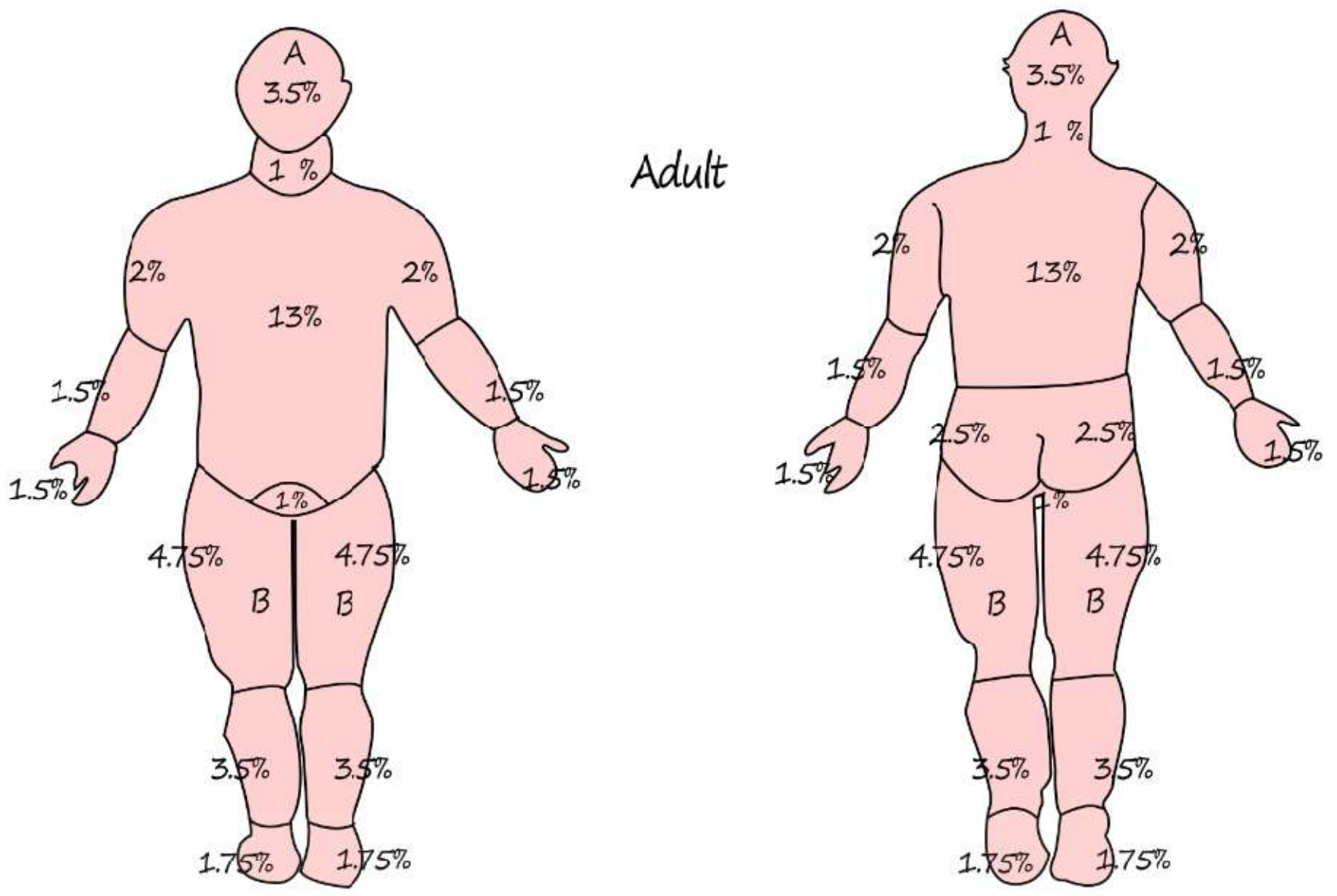

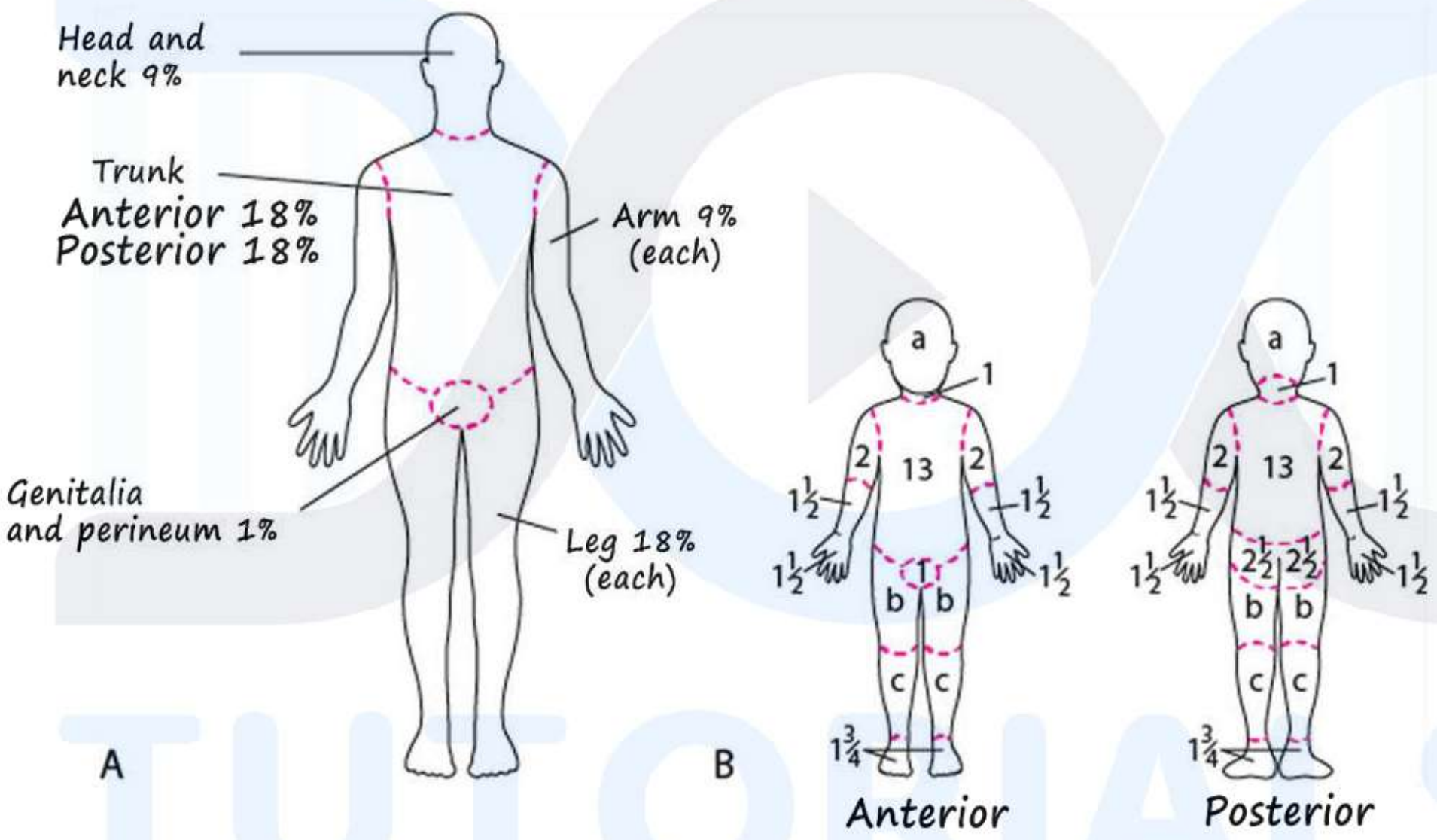

DOC TUTORIALS LOGIN FOR SUCCESS

- Relative percentage of body surface (%BSA) affected by growth

Body part	0yr	1yr	5yr	10yr	15yr
a = ½ of head	9 ½	8 ½	6 ½	5 ½	4 ½
b = ½ of 1 thigh	2 ¾	3 ¼	4	4 ¼	4 ½
C = ½ of 1 lower leg	2 ½	2 ½	2 ¾	3	3 ¼

Berkow formula to estimate burns size (%) based on area in isolated body part

Age (Year)						
Body part	0-1	1-4	5-9	10-14	15-18	Adult
Head	19	17	13	11	9	7
Neck	2	2	2	2	2	2
Anterior trunk	13	13	13	13	13	13
Posterior trunk	13	13	13	13	13	13
Right buttock	2.5	2.5	2.5	2.5	2.5	2.5
Left buttock	2.5	2.5	2.5	2.5	2.5	2.5
Genitalia	1	1	1	1	1	1
Right upper arm	4	4	4	4	4	4
Left upper arm	4	4	4	4	4	4
Right lower arm	3	3	3	3	3	3
Left lower arm	3	3	3	3	3	3
Right hand	2.5	2.5	2.5	2.5	2.5	2.5
Left hand	2.5	2.5	2.5	2.5	2.5	2.5
Right thigh	5.5	6.5	8	8.5	9	9.5
Left thigh	5.5	6.5	8	8.5	9	9.5
Right leg	5	5	5.5	6	6.5	7
Left leg	5	5	5.5	6	6.5	7
Right foot	3.5	3.5	3.5	3.5	3.5	3.5
Left foot	3.5	3.5	3.5	3.5	3.5	3.5

AfraTafreeh.com
TUTORIALS
LOGIN FOR SUCCESS

AfraTafreeh.com

First degree -

Fig: 1

Second degree –

Fig: 2

TUTORIALS
LOGIN FOR SUCCESS

Special features of each type -

First degree	Second degree superficial	Second degree deep	Third degree
1. No blister formation 2. Blanch to touch 3. Painful 4. Heal without	1. Blisters formed 2. Blanch to touch 3. Painful 4. Heal without	1. Blisters seen 2. Do not blanch to touch 3. Pinprick pain ++	1. Eschar formation 2. Black or brown 3. Painless

scarring in 5-10days	scarring in 7-14 days	4. Sensation decreased 5. Heals with scar in 3-9weeks	4. Heals with wound contrac ture only or by SSG only

- Cotton and pin are needed to find out the degree of burn.

Fig: 3

Fig: 4

TUTORIALS
LOGIN FOR SUCCESS

AfraTafreeh.com

Third degree –

Fig: 5

Fourth degree –

Fig: 6

LOGIN FOR SUCCESS

Note :-

Parkland formula

- TBSA% x Weight (Kg) x 4 = Volume (ml) needed
- Half this volume is given in first 8hrs and the second given in the subsequent 16hrs
- The volume replacement is by crystalloids

2nd degree superficial burns

Watch Video from 01:18:45 to 01:19:12

Second degree deep burns

Fig: 7

Meshed grafts

Fig: 8

AfraTafreeh.com
TUTORIALS
LOGIN FOR SUCCESS

AfraTafreeh.com

Escharotomy

Fig: 9

Eschar

Fig: 10

Fig: 11

Contracture release

Fig: 12

Management of second-degree burns

Materials	High yield points
Silver sulphadiazine	Most common used Not penetrated deeper tissue like **eschar**
Silver nitrate	Needs frequent applications **stain black**
Mafenide acetate	Penetrates deeper layers (Eschar) Painful application can cause **metabolic acidosis**
Cerium bromide	**Best agent** Has immune modulatory action Expensive

AfraTafreeh.com
DOC TUTORIALS
LOGIN FOR SUCCESS

AfraTafreeh.com

Fig: 13

Electrical burns

Fig: 14

Fig: 15

Frost bite

Fig: 16

Trench foot

Fig: 17

DOC TUTORIALS LOGIN FOR SUCCESS

AfraTafreeh.com

MISCELLANEOUS

Mesenteric Tear 00:00:18

- Mesentery is attached to small bowel.
- Root of mesentery – 15cm

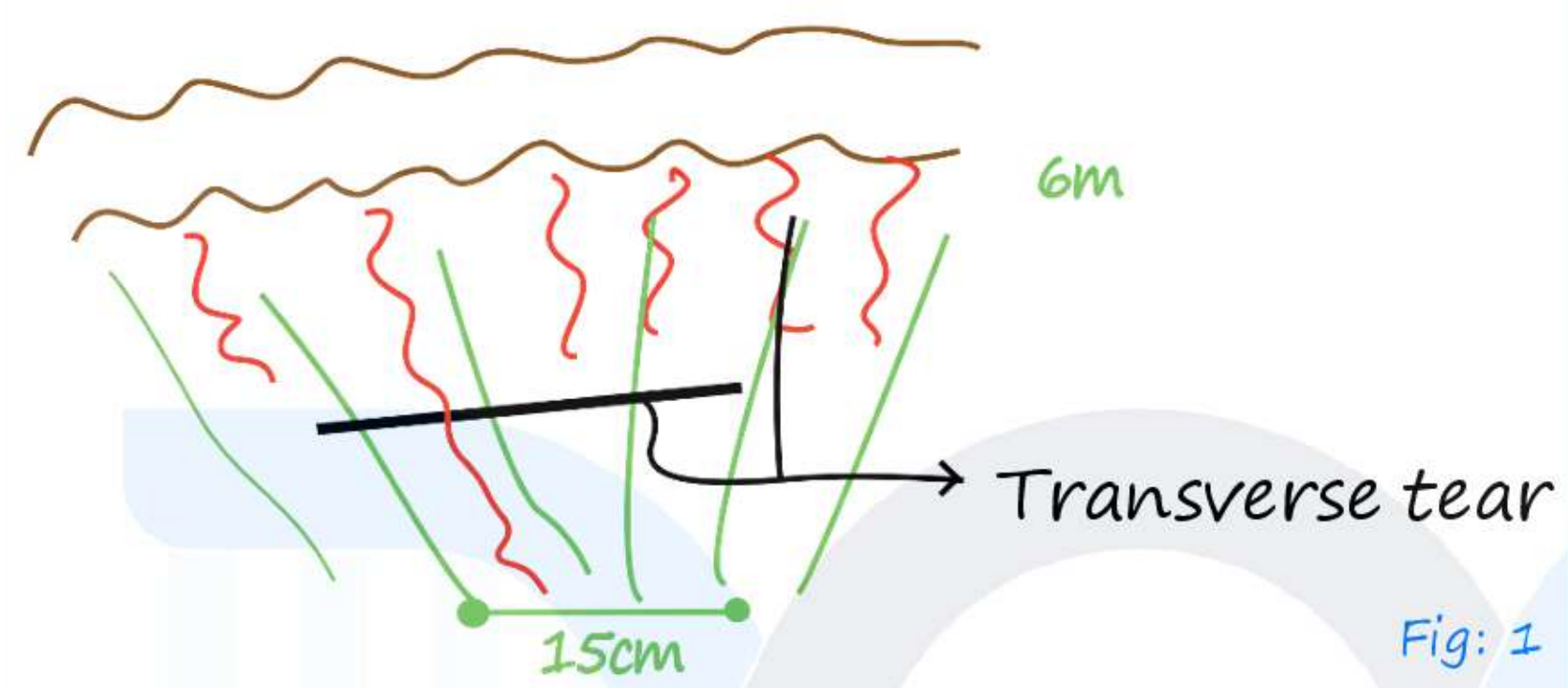

Fig: 1

- 2 types of tear
  - Longitudinal tear
  - Transverse tear
- Longitudinal tear is less dangerous because it is vertical, it is not going affect bowel blood supply any where

  ↓

  Needs repair and arrest
- Transverse tear will affect part of bowel and it becomes gangrenous

  ↓

  Needs ressection and anastomosis

Retroperitoneal Hematoma 00:02:05

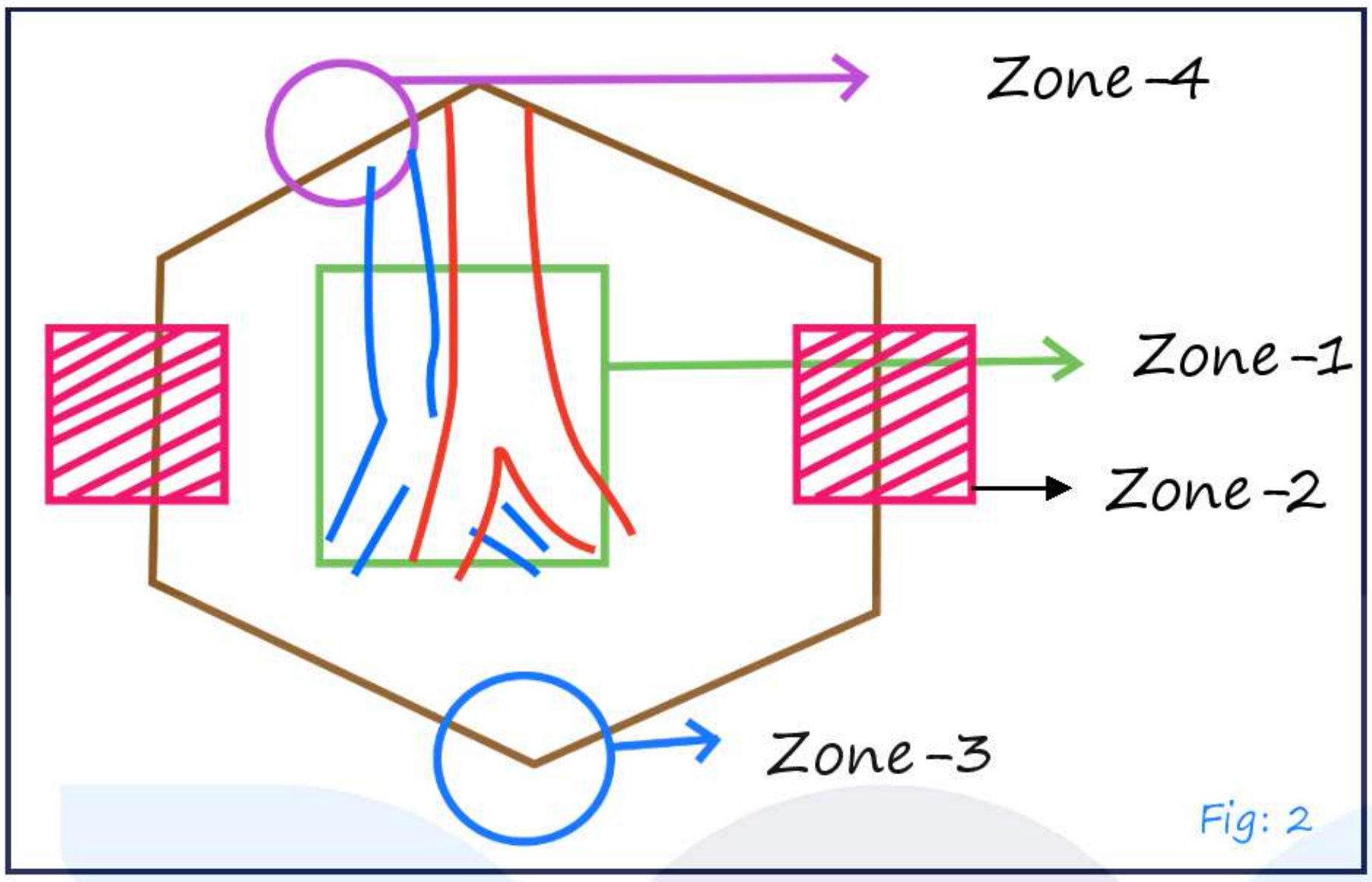

Fig: 2

- Zone 1: Aorta/IVC injury
  ↓
  Left visceral medial rotation
  ↓
  Mattox maneuver

  Right visceral medial rotation
  ↓
  CATTLE BRASCH MANEUVRE
  ↓
  includes Kocher's maneuver
  ↓
  (Mobilizing duodenum)

- Zone – II
  - Hematoma in kidney
  - Renal vessels injury
  - Non operative management – 90%
- Zone – III
  - Pelvic hematoma
  - Non operative management – pelvic binder is applied
- Zone – IV

AfraTafreeh.com

AfraTafreeh.com

- Retro-hepatic IVC injury
- If patient stable – non operative management

  unstable – surgery

Fullen's Zones 00:08:18

- SMA injuries

Fig: 3

- Superior mesenteric artery arises from L_1, running behind the pancreas and comes out and gives middle colic artery branch and comes out and gives multiple branches to bowel.
- 4 zones
  - Zone I – Retro-pancreatic zone

    ↓

    Mattox maneuver
  - Zone II – Middle colic artery

    ↓

    reach this area by opening lesser sac.
  - Zone III
  - Zone IV

  } Distal SMA branches

    ↓

    Surgical treatment

TUTORIALS LOGIN FOR SUCCESS

Compartment Syndrome 00:10:54

- Leg compartment

  ↓

  Etiology – closed fractures of tibia and fibula

  venous obstruction (DVT)

  arterial injuries

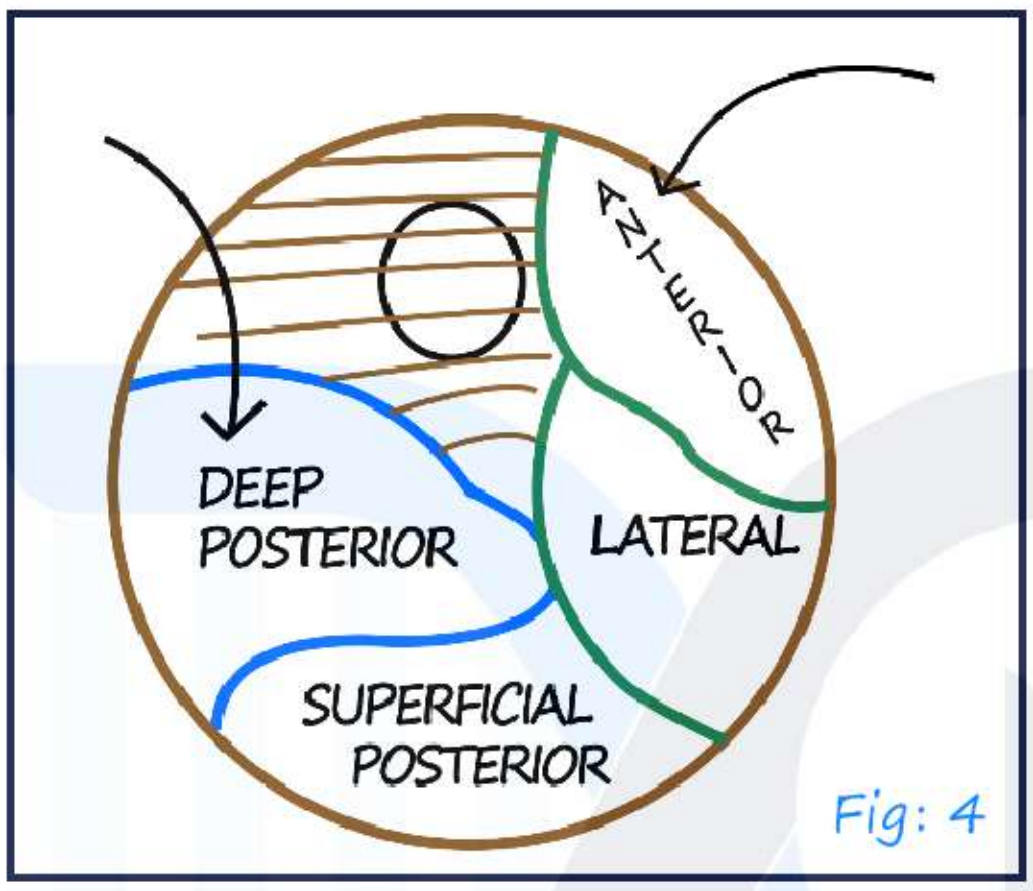

Fig: 4

- Anterior and lateral compartments are lateral to tibia
- Decreases blood flow to peripheries

  ↓

  Clinical features: Early sign → **pain** on passive stretching
- Hallmark to say compartment syndrome – paresthesia between first- and second-digit space


Fig: 5

- Last sign: Pulselessness

AfraTafreeh.com

Indications of Fasciotomy

- Stryker needle catheter measures the compartment pressure by directly poking the fascia.
  - If pressure > 30mmHg → Fasciotomy (ortho)
- Pressure gradient (Bailey)

  ↓

  Diastotic pressure – compartment pressure

  ↓

  <35 mmHg → fasciotomy
- Compartment syndrome > 6hrs → Fasciotomy
- Paralysis of limbs

Fasciotomy –

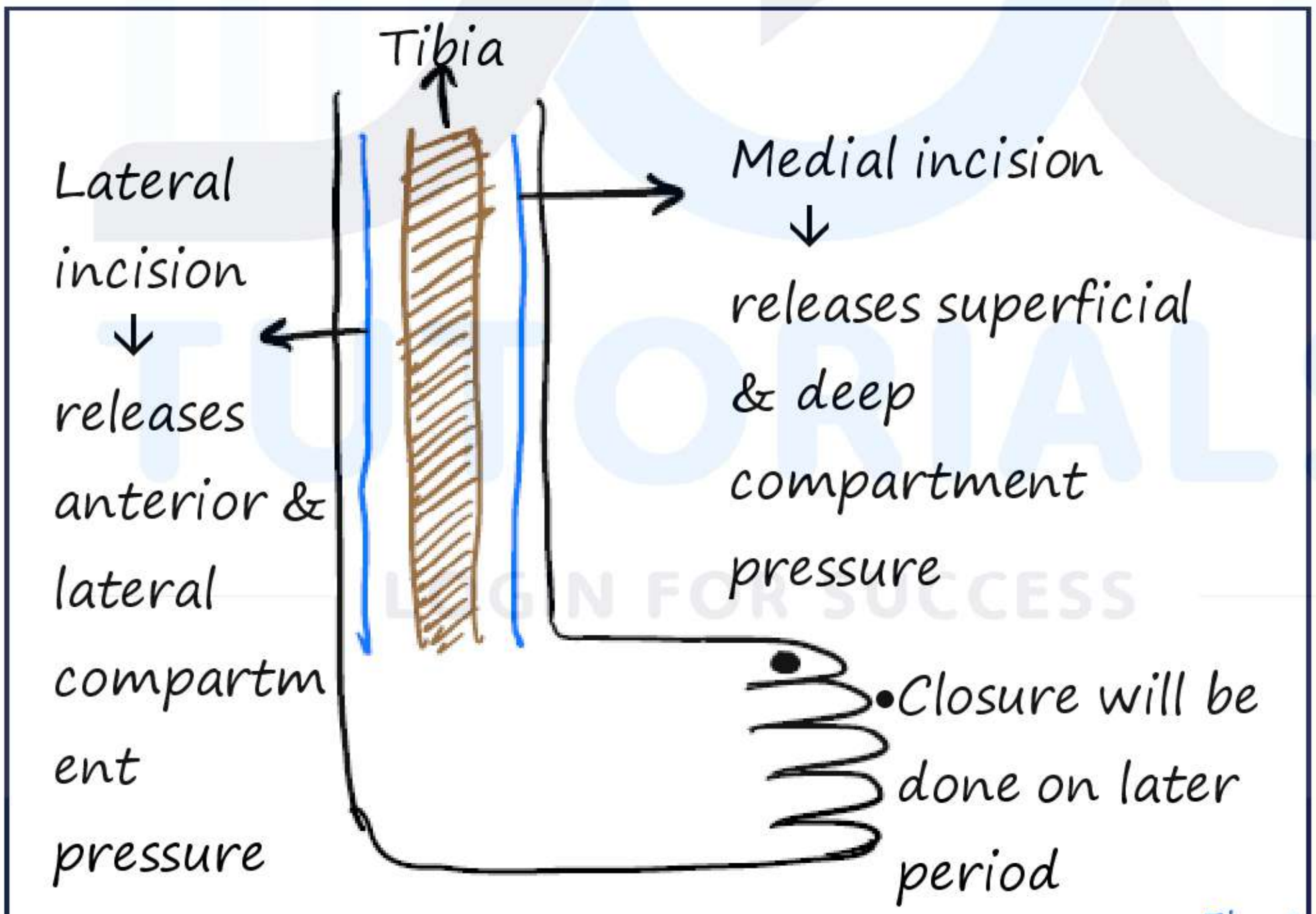

Fig: 6

Abdominal Compartment Syndrome 00:19:15

- 1° – primary abdominal compartment syndrome
  ↓
  d/t direct injury
- 2° → During resuscitation
  ↓
  Fluid accumulates
  ↓
  ACS
- Normal abdominal pressure: - 5-8 mmHg
- Intra-abdominal HTN - ≥ 12 mmHg (3times, 4-6 hrs)
- ACS - > 20 mmHg (3times; 1-3hrs)
  ↓
  1.IVC compression → Decreases CO, Increases HR
  2.Renal blood flow compression → Decreases UO
  3.Diaphragm compression → Decreases TLC
  4.CVP increases → Increases ICT

AfraTafreen.com
DOC TUTORIALS
LOGIN FOR SUCCESS

Measure

- Foley's – '3' way lumen
  - Inflation of balloon
  - Drain the urine
  - 3rd lumen → pressure monitoring catheter passed



- Grades of ACS
  - I – 10-15 cm of H_2O

AfraTafreeh.com

- II – 16-25 cm of H_2O
- III – 26-35 cm of H_2O
- IV – ≥ 36 cm of H_2O

- Intra bladder pressure – gold standard pressure to measure intraabdominal pressure
  ↓
  < 10cm H_2O – N

Other Methods –

- Gastric mucosal pH
- Near infrared spectroscopy
- CECT abdomen

Treatment

- Grade 3 – > 26cm H_2O – plan Laparostomy
  > 36 cm H_2O – Definitive

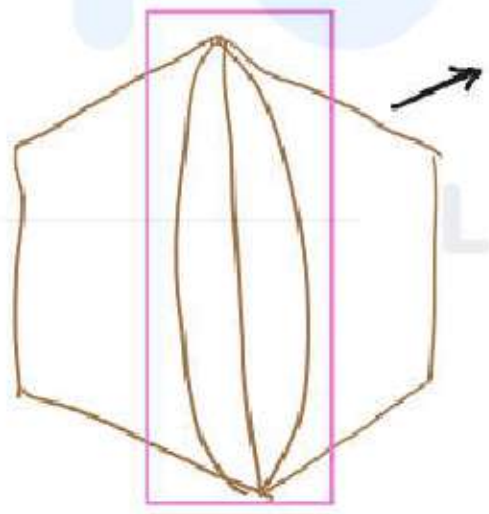

Laparostomy
↓
Open the abdomen from xiphisternum to pubic symphysis → IAP increases

Fig: 7

- Intra bladder pressure should be monitored after laparostomy.
- Abdomen is temporarily closed with
  - Mesh

- Bagota bag
- VAC device (latest)
- Opsite film

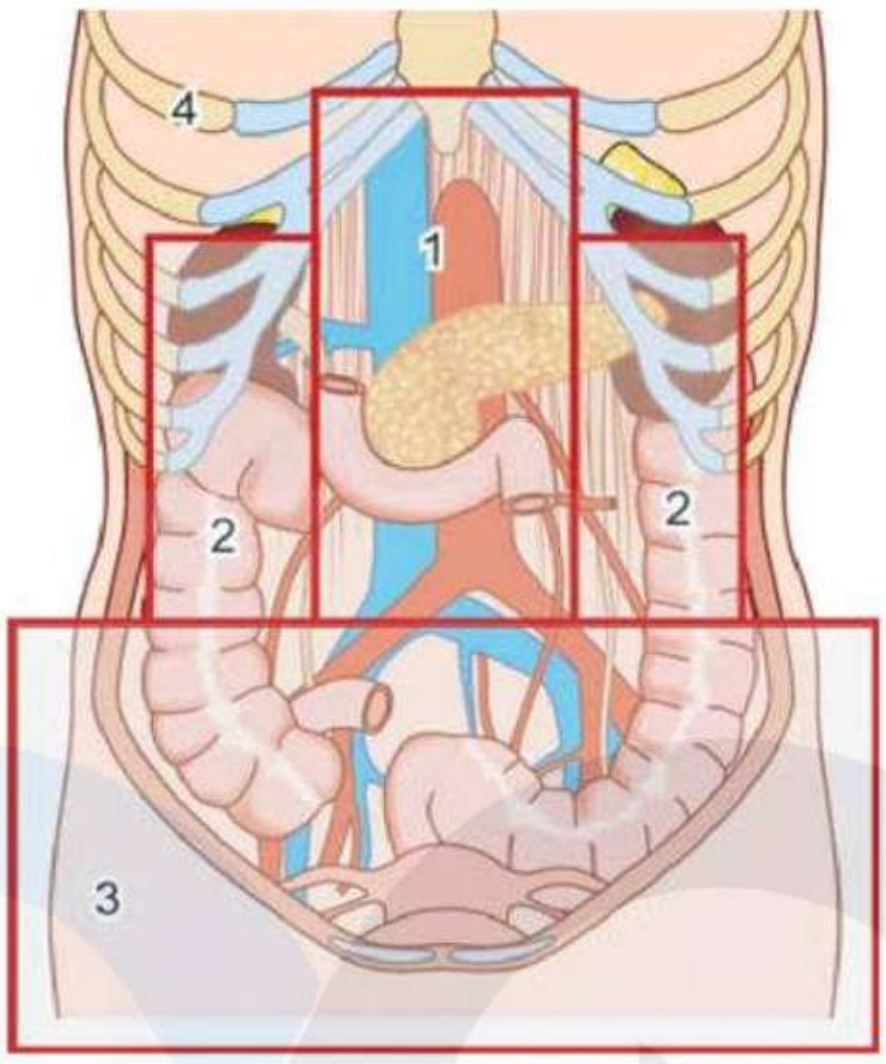

Fig: 8

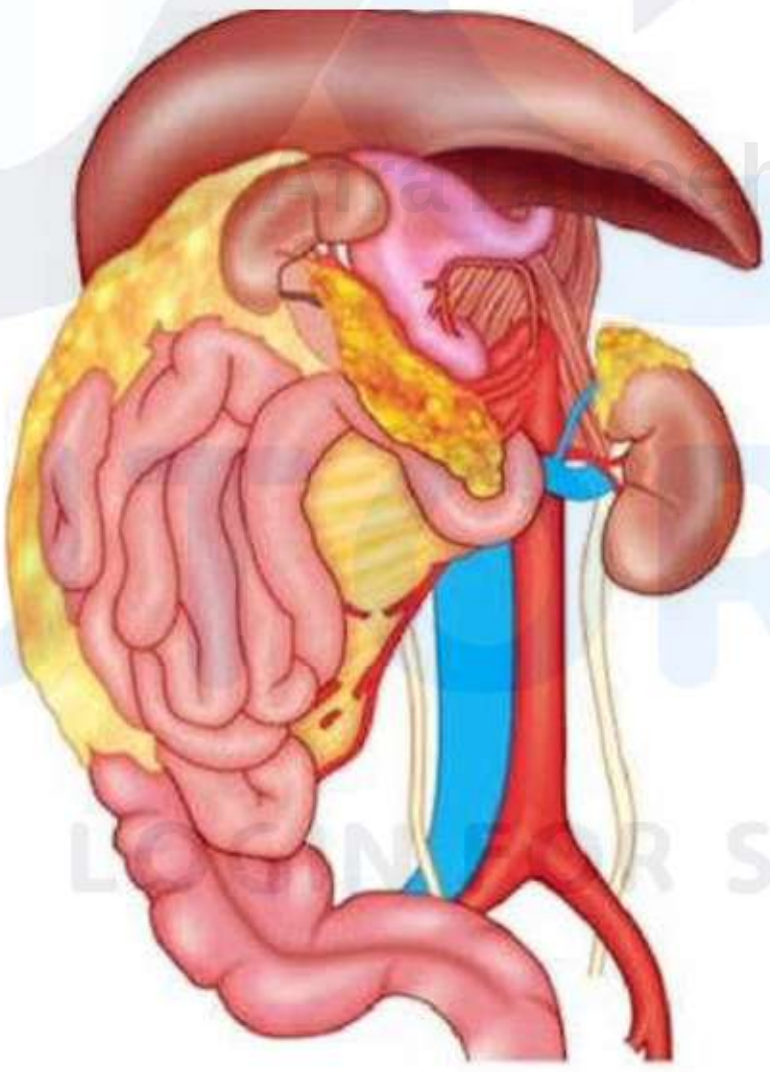

'MATTOX maneuver' Fig: 9

AfraTafreeh.com

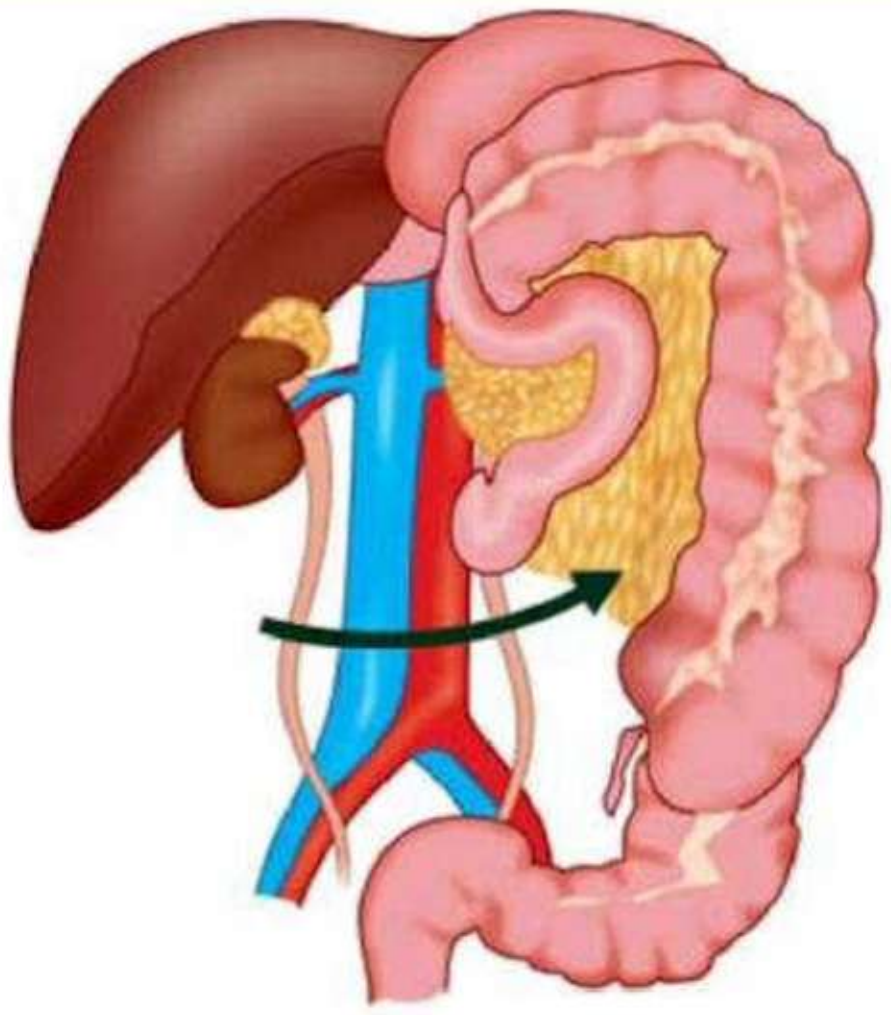

"Kocher's maneuver"

Fig: 10

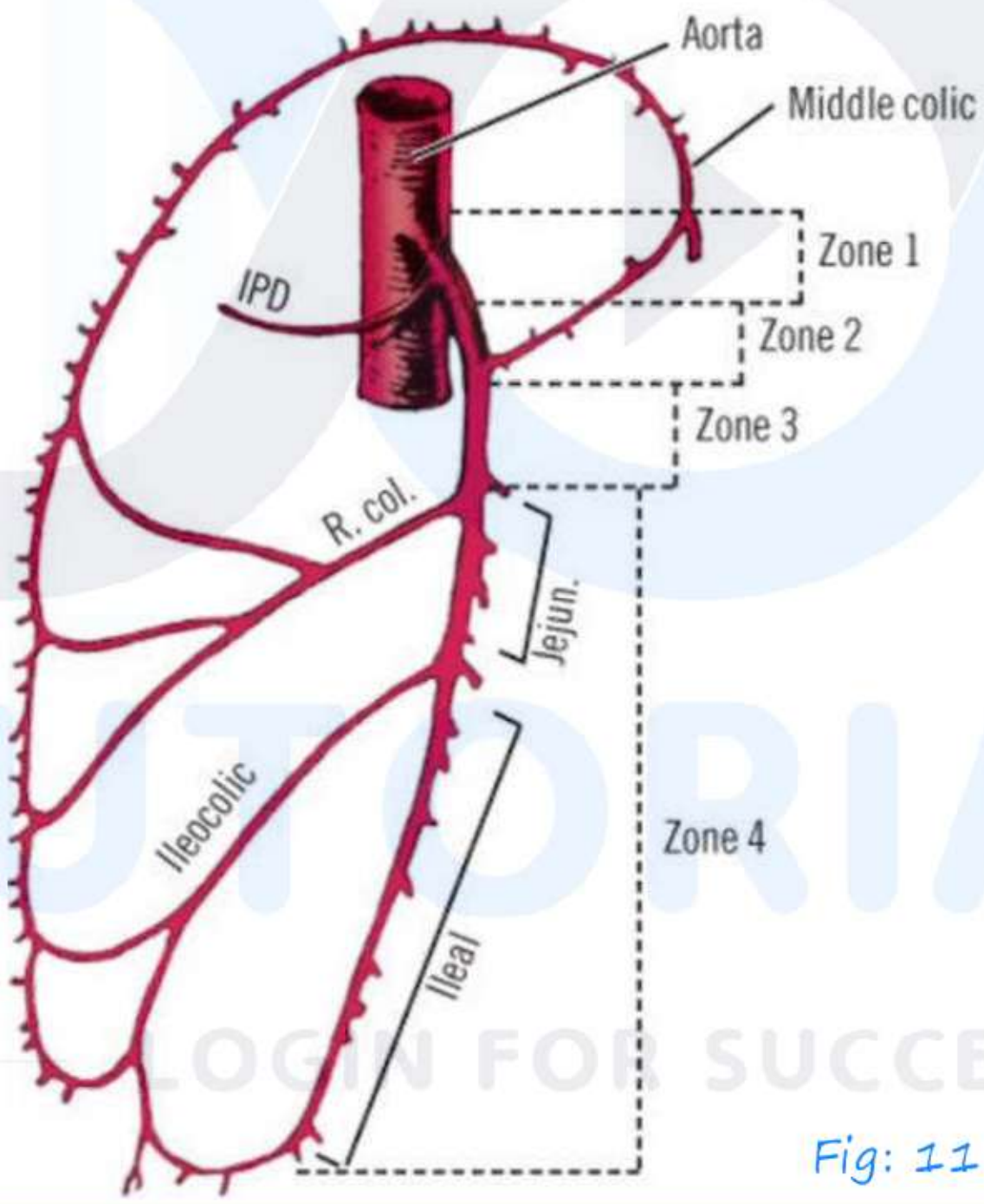

Fig: 11

Stryker Catheter

Fig: 12

ATLS PROTOCOL

ATLS latest protocol 00:00:32

	Old edition	Changes
1.Fluid infusion	2 liters – NS, RL 2 cannulas – 18G	•1 liter crystalloid •7.5% hypertonic saline (sabiston) •Children → 20ml/kg/ wt.
2.Massive blood transfusion → replacing entire volume	10 units whole blood	10 units PRBC: FFP: Platelets 1:1:1 •In pediatric, 10ml-20ml/kg/wt. 1:1:1
3.Intubation	ET tube	Video laryngoscopes ae advised
4.Hemorrhagic shock	4 classes Class I - < 750ml Class II – 750-1500 Class III – 1500-2000	Base deficit is added I: 0 to -2 II: -2 to -6 III: -6 to -10 IV: > 10

AfraTafreeh.com
DOT TUTORIALS LOGIN FOR SUCCESS

AfraTafreeh.com

	Class IV – > 200	
5.Tranexamic acid	Not indicated	Crash II trail Injury tranexamic acid 1st IV stat 2nd IV infusion for 8 hours ↓ Advised for patients if •PR > 110/min •SBP < 90 mmHg
6.Life threatening injuries	6 injuries 1.Airway obstruction 2.Pericardial tamponade 3.Tension pneumothorax 4.Open pneumothorax 5.Hemothorax 6.Flail chest	Removed (6.) •Tracheobronchial injury (is added)
7.Tension pneumothorax	2nd ICS – MCL eFAST is not indicated	•5th ICS – mid axillary line (adults) •Children → 2nd ICS – MCL

TUTORIALS
LOGIN FOR SUCCESS

		• eFAST → Barcode stratosphere
8. Aortic rupture	Not indicated	• Permissive hypotension → SBP < 60-70 mm Hg ↓ Achieved by short acting esmolol
9. Urethral injury	P/R: - membranous urethral injury → Floating prostate (vermooten)	Not indicated to do per rectal examination
10. Post traumatic seizures	Prophylactic 1. Sodium valproate 2. Phenytoin	No prophylactic antiepileptic drugs are advised
11. X-ray c spine	Routine • AP & lateral views	Based on • Nexus criteria • Canadian 'c' spine rule N – Neurological deficit E – Ethanol X – Xtreme injury

AiraTafreeh.com
DOCTUTORIALS LOGIN FOR SUCCESS

AfraTafreeh.com

		U – Unable to recall S – Spine tenderness
12. Burns fluid	Parkland formula 4 x wt. x TBSA	**>14 years/ adults –** 2 x wt. x TBSA U.O – 0.5ml/kg/hr **< 14 years –** 3 x wt. x TBSA U.O – 1ml/kg/hr **4th degree/ electrical–** 4 x wt. x TBSA U.O – 1.5ml/kg/hr

TUTORIALS
LOGIN FOR SUCCESS

SALIVARY GLANDS

- 2 important major salivary glands – parotid, submandibular
- Both have 2 lobes and ducts
- Parotid duct is called Stensosn's duct, 5 cm long, it opens in the upper 3rd molar
- Submandibular gland duct is called Wharton's duct, 5 cm in length, which opens on floor of the mouth on either side of frenulum of tongue.
- Parotid gland is divided into superficial and deep by facial nerve doing with retromandibular vein. This is called Patey's fasciovenous plane.

AfraTafreeh.com

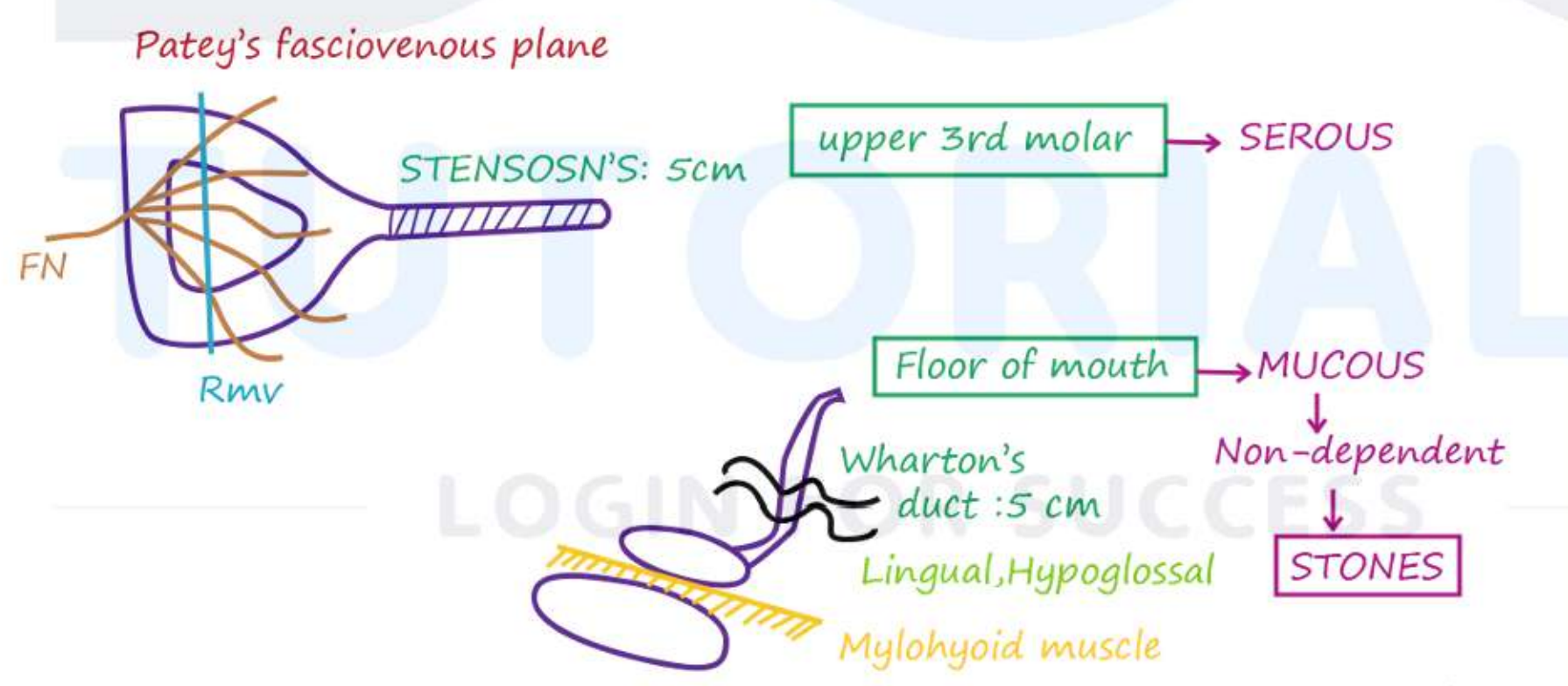

Fig: 1

- If we do operation above the plane – called superficial parotidectomy.
- If we remove entire gland – Total parotidectomy
- Submandibular gland is divided into superficial and deep lobes by mylohyoid muscle

AfraTafreeh.com

- Lingual nerve and hypoglossal nerve are closely related to deep lobe.
- Parotid gland secretion is thin, serous, watery secretion.
- Submandibular gland secretion is thick, mucus secretion. It has non-dependent drainage; stones are most common in submandibular gland.

Identification of Facial Nerve 00:03:19

- It is a crucial step in parotid surgeries

1. Conley's Pointer method
   - Junction between cartilaginous part and bony part of external auditory canal.
   - Also called as Tragal pointer (v)
   - The trunk of facial nerve is found inferior to this pointer.
   - Tragal cartilage pointer – 1cm inferior and 1cm medial to this land mark.
2. 1-2 mm above the point of posterior belly of digastric muscle's insertion, facial nerve is identified.
3. Facial nerve comes out of stylomastoid foramen.
4. Retrograde method from the branches.
5. Latest method is by using Nerve monitors.

Nerve Supply of Parotid Gland 00:07:16

- Parotid gland is supplied by inferior salivary nucleus, nerve is coming out through otic ganglion, nerve goes to parotid gland.
- It is parasympathetic flow.
- Pre ganglionic parasympathetic nerve is glossopharyngeal Nerve. It is usually crosses at the level of middle ear tympanic membrane.
- From otic ganglion, the nerve coming out is Auriculo – temporal nerve (branch of trigeminal nerve)
- Sympathetic supply comes from sympathetic plexus. It increases the flow of gland (To bring blood flow to gland)
- Parasympathetic supply is mainly to stimulate the secretion.
- During parotidectomy, if Auriculo-temporal nerve is injured. (A.T.N – post ganglio parasympathetic). Then it try to grow and get reinnervated by sympathetic. These two joins together and supply skin of the face called Frey's syndrome.

AfraTafreeh.com
TUTORIALS
LOGIN FOR SUCCESS

AfraTafreeh.com

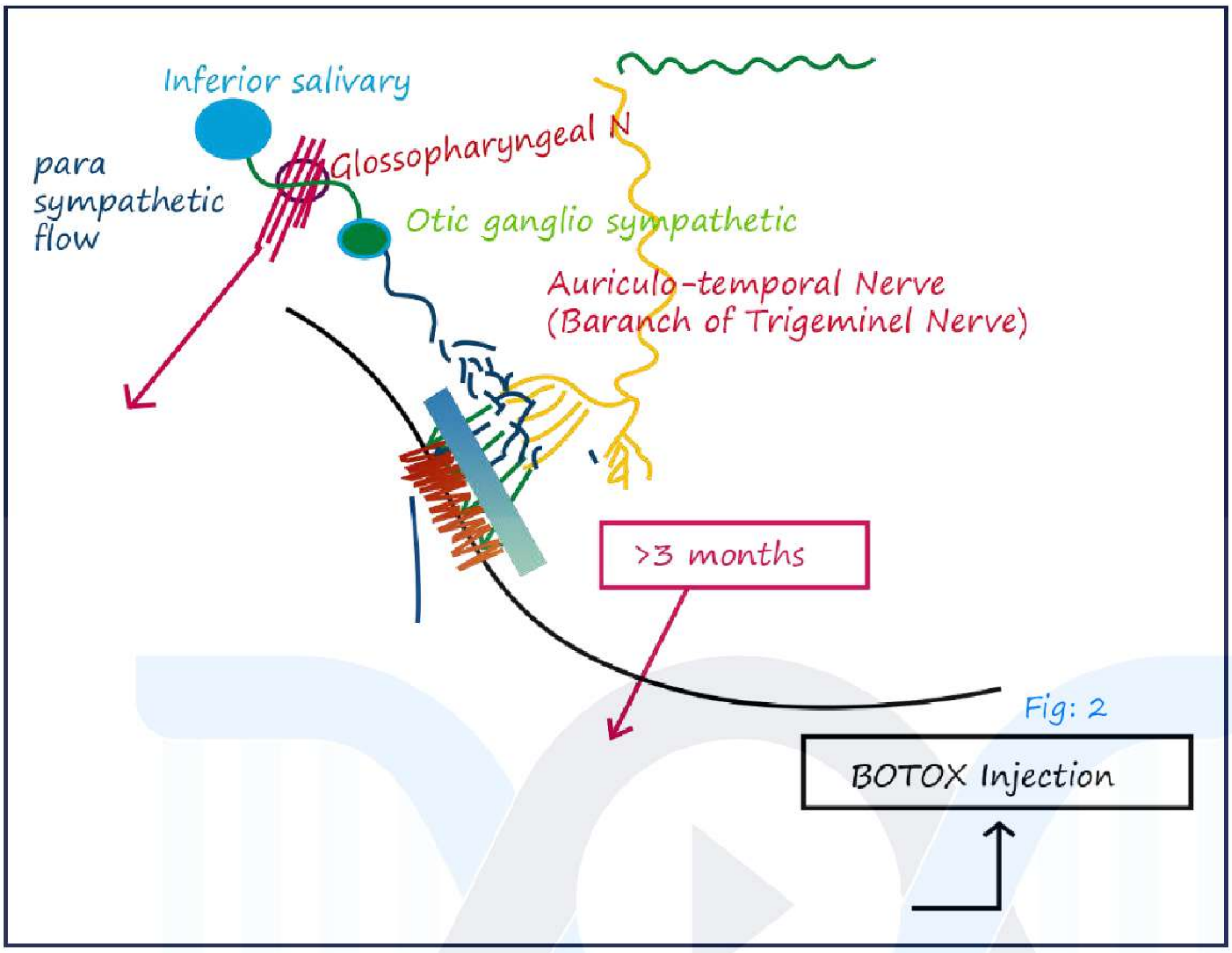

They produce gustatory sweating

↓

The moment he sees food, the sympathetic and parasympathetic flow increases and supply the skin of face, it produces pain, erythema and sweating.

- Usually, it happens 3 months after surgery.
- Treatment of choice for Frey's syndrome – Botox injection.
- In old times – they use to cut glossopharyngeal nerve called Jacobson's Tympanic neurectomy.
- IOC for Frey's → Starch Iodine test - starch iodine is applied on the area and when patient eats (stimulated) the reinnervated area turns blue. This area is injected with botox.

- Prevention of Frey's → By putting a Sternomastoid flap (or) a temporalis flap is placed between nerve and the skin to prevent re-innervation.

Submandibular gland 00:14:03

- 2 lobes (superficial and deep), Wharton's duct, thick mucinous secretion.
- More non-dependent drainage, so more chance of formation of stone (stones are most common)
- $CaCo_3$ stones are seen, they are radiopaque.
- Old concept → Distal to lingual N, open the duct, remove stone and lay open the duct proximal to lingual nerve, they do gland excision. Now-a-days this is not done/followed.
- White excision surgeon should be careful about 2 deep cervical nerves, lingual and hypoglossal nerve and 2 superficial nerves – cervical branch of facial nerve and mandibular branch of facial nerve.
- There are 800 minor salivary glands seen in oral cavity.
- Attached to submandibular duct, there are sublingual salivary glands– they are connected to this duct by special ducts of Rivinus and ducts of Bartholin (minor salivary gland ducts)

AfraTafreeh.com
TUTORIALS
LOGIN FOR SUCCESS

AfraTafreeh.com

- At angle of mandible, there can be an ectopic salivary tissue. most common site of ectopic salivary tissue → Stafne bone cyst at angle of mandible.

Ectopics 00:18:00

1. Ectopic salivary tissue → angle of mandible → stafne bone cyst.
2. Ectopic sebaceous tissue → on lips → Fordyce disease
3. Ectopic thyroid gland → Lingual thyroid (anterior 2/3 & posterior 1/3 part)
4. Ectopic parathyroid → In mediastinum
5. Ectopic gastric → In Meckel's diverticulum
6. Ectopic pancreas → Duodenum → stomach
7. Ectopic spleen → splenic hilum → tail of pancreas
8. Ectopic testis → Superficial inguinal pouch
9. Ectopic pregnancy → Fallopian tube (ampulla)
   ↓
   In ovary – spigelberg criteria
   In cervix – Rubin's criteria

TUTORIALS LOGIN FOR SUCCESS

Salivary Gland Tumors 00:21:14

- Divided into

	Benign	Malignant
Parotid	80%	20% – most common malignant is mucoepidermoid cancer
Submandibular	60%	40% – most common malignant is adenoid cystic cancer
Small salivary gland	10%	90% – most common malignant adenocarcinoma
↓ Most common benign tumor is pleomorphic adenoma		

AmraTarcen.com
TUTORIALS
LOGIN FOR SUCCESS

- In adults
  - Most common benign tumor is pleomorphic adenoma.
  - Most common malignant for parotid S.M
    - mucoepidermoid cancer
    - Adenoid cystic cancer
- In pediatric age group
  - 35% are malignant
  - Most common overall is hemangioma
  - Most common benign tumor is pleomorphic adenoma
  - Most common malignant is mucoepidermoid cancer.

AfraTafreeh.com

Classification of Salivary gland Tumors 00:25:22

Epithelial tumors: -

Benign

1. Pleomorphic adenoma (mixed tumors)
2. Warthin's tumor

Malignant

1. Mucoepidermoid cancer
2. Adenoid cystic cancer
3. Acinic cell tumor
4. Squamous cell cancer
5. Pleomorphic adenocarcinoma
6. Adeno cancers

Benign tumors -

Pleomorphic adenoma	Warthin's tumor
• Aka mixed tumor (epithelial & mesenchymal elements)	• Aka Adenolymphoma as it is derived from pre parotid lymphatics
• Most common benign tumor in all glands.	• Exclusively seen in parotid gland
• Gross features: They produce pseudopod like extensions into the normal tissue. So, we have to do parotidectomy 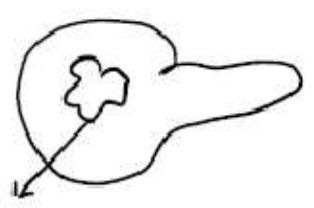 Pseudopod	• It has well defined capsule so enucleation can be done. 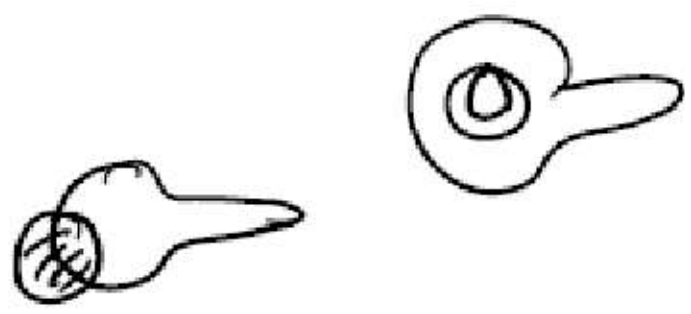

• Common site is tail of parotid gland	• It is seen most common in lower pole of parotid.
• Clinical features 1. It will lift the ear lobule 2. Obliterates retromandibular groove 3. Curtain sign + → Tumor can be moved sideways, but we cannot move tumor above the zygomatic attachment (place where fascia attaches) 4. If it is a deep lobe tumor, we can do bidigital palpation keep one finger behind the 3rd molar trigone and other finger from outside and do exam. 5. If deep lobe is enlarged the tonsil can be pushed medially.	• Presents as swelling at level of angle of mandible.
• All salivary and tumors are common in females.	• Warthin's is common in males, smokers.
	• It is B/L in 10% cases
	• It can be multicentric & multifocal • Tc 99m scan – It looks like **hotspot**

AfraTafreeh.com
TUTORIALS
LOGIN FOR SUCCESS

AfraTafreeh.com

- Lymphoepithelioma of parotid is rare and aka **Godwin's tumor** (Benign tumor)

Investigations of parotid gland tumors 00:34:00

- Do FNAC to confirm diagnosis
- For deep lobe tumors – do CT scan
- For bone involvement – CT scan
- Staging IOC – MRI ↙ looks like
- TC 99m scan – only for hotspot (Warthin's tumor)

Features suggestive of malignancy in a salivary gland tumor

- If facial nerve palsy (involvement present)
- Lymph node involvement present
- Sudden enlargement of gland present
- Severe pain present
- Skin ulceration present
- Satellite nodules.
- Restricted movement

↓

- IOC to confirm malignancy – FNAC
- Staging IOC – MRI
- Look for bone involvement – CT scan

Malignant tumors of salivary gland 00:37:22

Mucoepidermoid cancer	Adenoid cystic (or) cylindroma
• Most common malignant tumor of parotid gland • Can be low/high grade • Clinical features: – 30% L.N mets are present	• Most common malignant tumor of submandibular gland • Can be low/high grade • It can have present perineural infiltration • It can go upto base of skull • No L.N mets

- Acinic cell tumor → It is a low-grade tumor
  It is 2nd most common tumor in children.
  3% times it can be B/L

AfraTafreen.com

TUTORIALS LOGIN FOR SUCCESS

Surgical aspects of salivary tumors 00:40:00

- 3 operations can be done
- Superficial parotidectomy
  - Remove only superficial lobe of gland.
  - For superficial lobe – benign tumors.
- Total conservative parotidectomy
  - Remove superficial lobe + deep lobe without disturbing facial nerve (preserved)
  - Done for deep lobe benign tumors

AfraTafreeh.com

- Radial parotidectomy
  - Remove facial nerve + superficial lobe + deep lobe is removed
  - Indicated for malignancies and parotid.
- Incision made is Lazy 'S' incision / modified Blair/ Sistrunk ± and raise the skin flap.
- 1st step is to identify facial nerve trunk and carefully pressure all branches of facial nerve.
- Never use monopolar diathermy, only use bipolar diathermy
- Nerve which needs to be reconstructed as it is most important. Buccal branch of facial nerve by using greater auricular nerve. If it is injured during surgery reconstruct it.

Complications of parotidectomy 00:44:10

1. Nerve injury → Most common is branch of facial nerve (motor nerve)
   - So – Bell's phenomenon can develop
     - Nasolabial fold disappears
     - Deviation of mouth
   - Most common cutaneous nerve injured
     ↓
     Greater auricular nerve – paresthesia in shaving areas
   - Frey's syndrome → due to post ganglionic parasympathetic nerve

LOGIN FOR SUCCESS

Cranial nerve branch from trigeminal nerve (Auriculotemporal nerve)

2. Flap necrosis

3. Flap infection

4. Keloid formation

5. Salivary fistula if duct is not properly ligated

For salivary parotid fistula → 'SEABROOKE' operation

Submandibular duct obstruction 00:47:42

- Causes → most common cause of obstruction is stone ($CaCO_3$) can be seen on x-ray.
- 2nd most common cause – **stricture**
- If there is complete obstruction, there is a classical feature, after patient is eating, the secretions of gland are unable to drain and gland enlarges, pain appears and it slowly disappears after 1-2 hours. This is called **meal time syndrome** ← feature of complete obstruction.
- Incomplete obstruction – there is discomfort, they don't have meal time syndrome.
- Treatment – If stone is <4mm → Dormia basket retrieval is done.

  If done >4mm → use intraductal lithotripter.
- Parotid gland stones are very rare. they are radiolucent. we have to do a Ductography to find out stones (Sialography)

AfraTafreeh.com

- < 4mm stones – can be removed by Ductography
  > 4mm stones – removal of gland itself

- Most common site of minor small salivary gland tumor is – hard palate usually adeno cancers.

Ranula	Plunging ranula
• Extravasation cyst from sub-lingual gland	• Retention cyst of sublingual (or) submandibular gland
• Seen on under surface of tongue	• Extends from under surface of tongue into submandibular space
• Recent treatment – excision of sublingual gland	• So, P.R is bidigitally palpable
• Marsupialization is **not** advised	• Intra oral excision of submandibular/sublingual

DOC TUTORIALS
LOGIN FOR SUCCESS

NECK SWELLINGS

Neck triangles

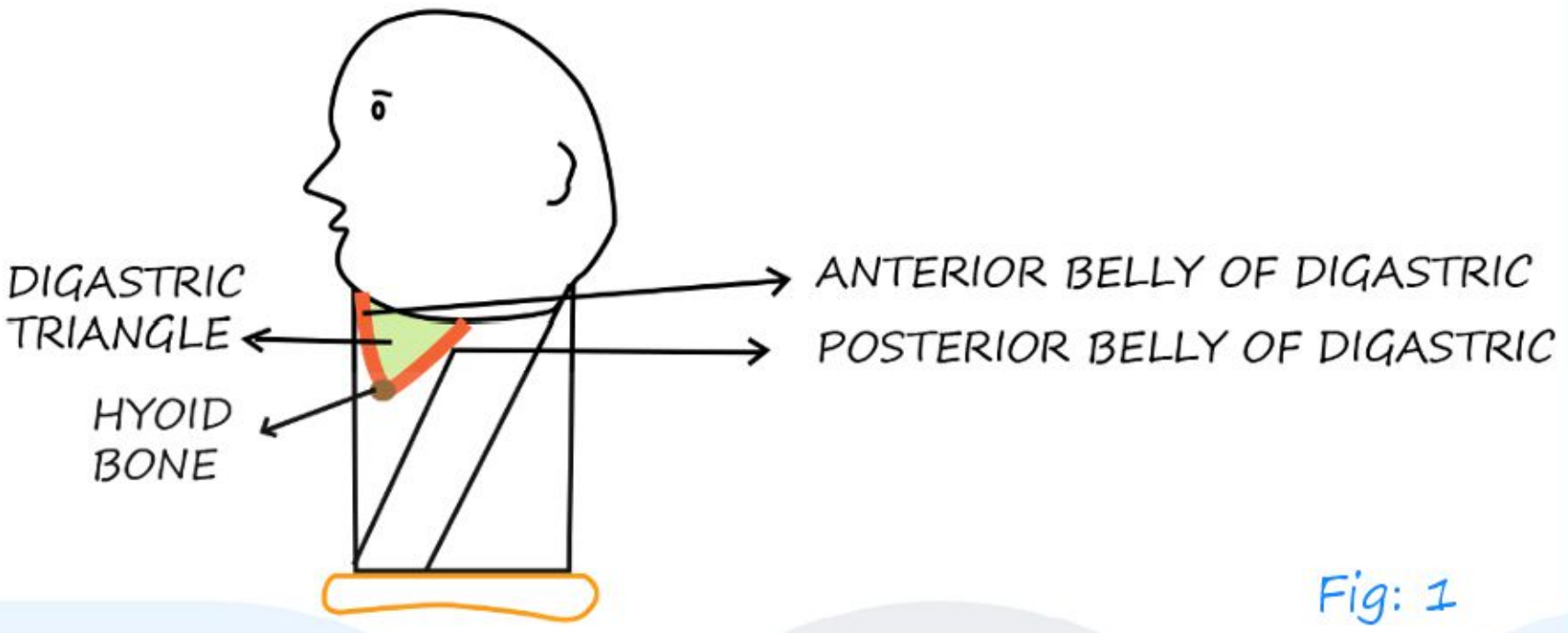

Fig: 1

AfraTafreeh.com
TUTORIALS
LOGIN FOR SUCCESS

- The triangle between anterior belly and posterior belly of digastric, hyoid bone as apex and mandible is called digastric triangle (or) submandibular triangle
- Carotid diagnosis - bounded by
  - Posterior belly of digastric
  - Superior belly of omohyoid
  - Sternocleidomastoid
- Muscular diagnosis – bounded by
  - Hyoid bone
  - Superior border of omohyoid
  - Sternocleidomastoid midline
- Submental diagnosis – between the 2 anterior belly of digastric

AfraTafreeh.com

Posterior triangles

- Suboccipital diagnosis – bounded by
- SCM
- Trapezius
- Inferior belly of omohyoid
- Supraclavicular diagnosis – bounded by
  - Inferior belly of omohyoid
  - SCM
  - Clavicle
- Most common swelling in the neck is lymph node

	Carotid triangle	Posterior triangle
Solid filled swelling Liquid filled swelling Gas filled swelling	Carotid body tumor Branchial cyst Laryngocele	Cervical rib Cystic hygroma Pharyngeal pouch

Carotid body tumour 00:06:53

- It is called as Chemodectoma
- It is called a non-chromaffin paraganglioma
- It is also called potato tumour

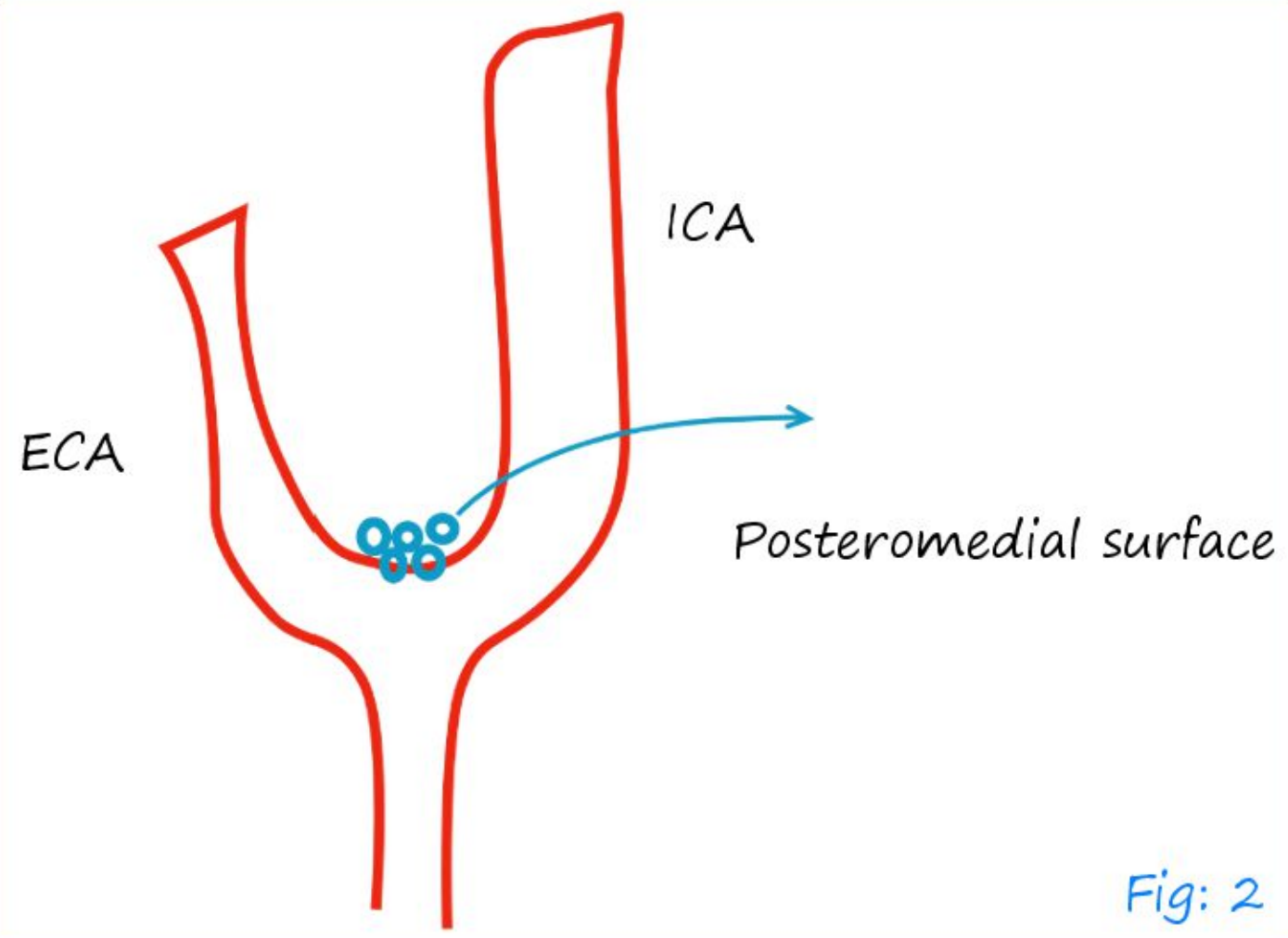

Fig: 2

- At bifurcation of common carotid artery, small chemoreceptors present on posteromedial surface of CCA bifurcation. These receptors are stimulated by hypoxia
- As these receptors stimulated, patient takes more breathing and more oxygen consumption. So, they cause hyperventilation and the patient stagnates more oxygen in the body
- In some people who have constant hypoxia, i.e., people living in high altitude, people with cyanotic heart disease. Their carotid body is continuously stimulated and they grow and become a tumour
- Clinical features – It is potato like firm consistency
  - Most common in middle aged females
- It is usually unilateral seen on anterior triangle of neck. It is mobile side to side (can't move vertically). This sign is Fontaine sign
- This swelling will have a transmitted pulsation

AfraTafreeh.com

- If kept 2 fingers on as swelling, the fingers are lifted and separated known as expansile pulsation
- If fingers are only lifted it is transmitted pulsation
- Expansile pulsations seen in aneurysms
- Transmitted pulse are seen in any swelling sitting on an artery
- Incidence of carotid body tumour is rare <0.5%
- Carotid body tumour can become malignant in around 10% cases

Shamblin classification 00:12:08

- Type I - The tumour is jut adherent to artery, <25% area, we can excise it without any
- Type II – Infiltration is more into artery, around 50% adherent so we should have 3-point control in CCA, ICA, ECA while excising tumor (any of 3 arteries can be injured) Excise tumor with 3-point control
- Type III – When it is >50% infiltrated (or) encasing the vessel, such cases we do resect the CCA and along with tumor use internal jugular vein as graft

IOC 00:14:48

- FNAC/ Biopsy is contraindicated
- IOC is angiogram, shows splaying of CCA branches of CCA branches called "LYRE SIGN"
- Duplex scan also can be done

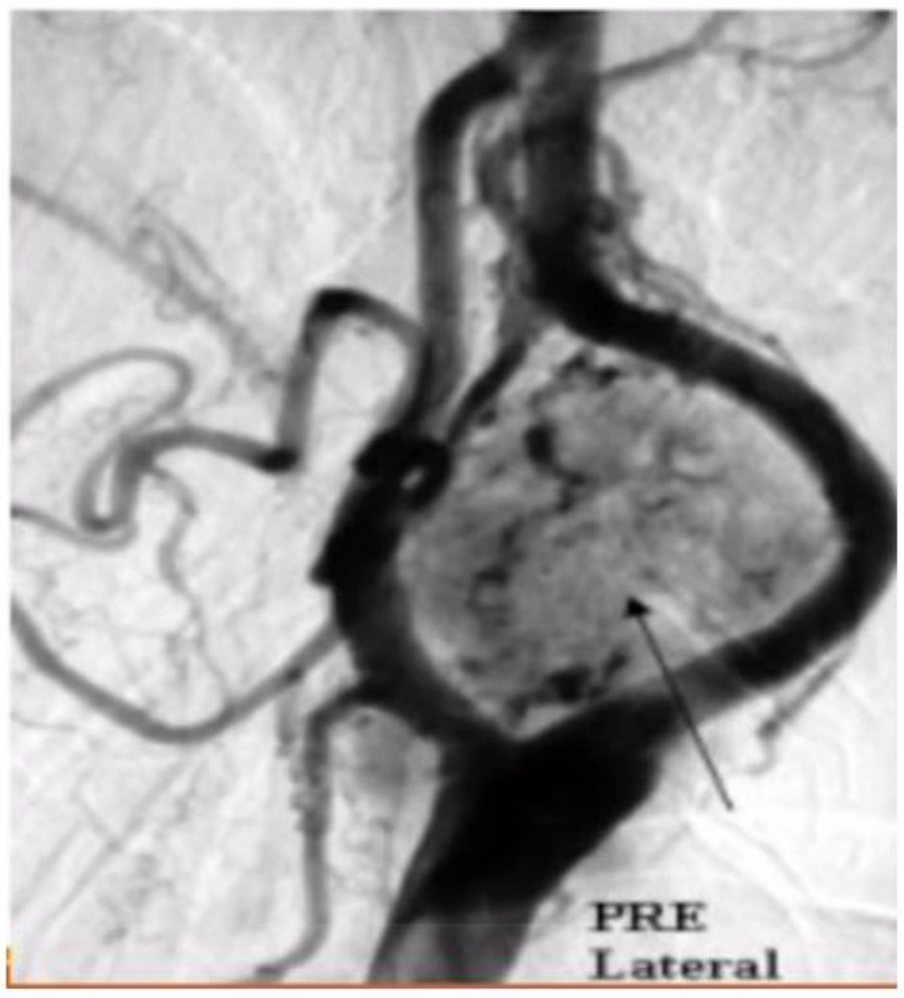

Fig: 3

Complications of surgery 00:15:54

- Most common nerve injured during the surgery → superior laryngeal nerve
- First bite syndrome → syndrome in which damage of sympathetic nerves around the common carotid artery CCA happens
- This results in reinnervation of sympathetic by parasympathetic branches (It is just opposite to Frey's syndrome). It results in pain happening in the neck on starting to chew
- If it is malignant, we have to give post op radiotherapy also is given (pre-op radiotherapy has no value) not given

AllaTaafeen.com
TUTORIALS
LOGIN FOR SUCCESS

AfraTafreeh.com

Thoracic outlet syndrome-

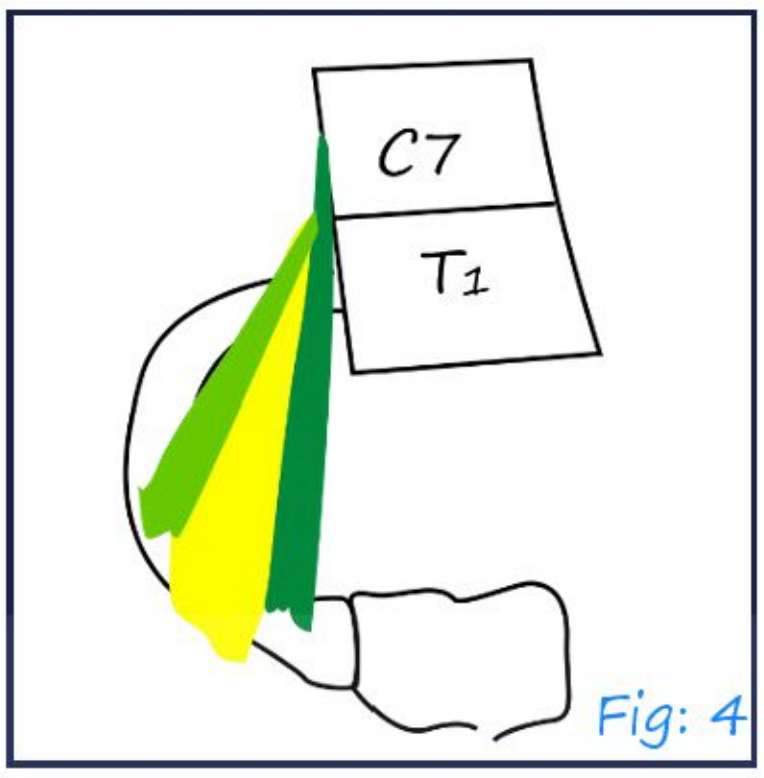

Fig: 4

- Scalenus anterior muscle attached to 1st rib
- Scalenus medius muscle also to 1st rib
- They are arising from transverse process of cervical spine. There is a triangle formed in between these 2 muscles called scalene boundaries are Scalenus anterior, Scalenus medius, clavicle
- Content coming out of triangle are
  i. Subclavian artery – branches of brachiocephalic trunk
  ii. Brachial plexus
    a. Upper trunk
    b. Middle trunk
    c. Lower trunk
- Sometimes there is cervical rib arising from C_7 can come into this triangle and causes compression
- This is one of the cause of thoracic outlet syndrome. It is most common cause of scalene triangle compression → **cervical rib** (overall)

TUTORIALS LOGIN FOR SUCCESS

- By cervical rib, there are 2 problems
  i. Subclavian artery compression called thoracic outlet syndrome of vascular type (Vascular TOS) →m/c
  ii. Compression of branchial plexus called Neurogenic TOS

Neurogenic TOS

- Most common nerve compressed is ulnar nerve (C_8, T_1) (lower trunk of branchial plexus) is commonly compressed → ulnar area pain → pian along medial side of arm and forearm

AfraTafreeh.com
TUTORIALS
LOGIN FOR SUCCESS

Vascular TOS

- It is the most common type of TOS
- Clinical features – pain (when patient starts working with hands) called intermittent claudication of upper limb (because of poor blood flow)
- Ulcers
- Gangrene
- Vertebral artery – branches of subclavian artery, joins Circle of Willis and supply brain
- If there is compression in the subclavian artery by cervical rib, the vertebral art gives collateral to upper limb. So, when patient starts working with

AfraTafreeh.com

hand, the blood flow to brain stops and it goes to upper limb

- This phenomenon is called subclavian steal phenomenon patient complains of giddiness as he starts working

Clinical examination findings

- A bony hard swelling (cervical rib) is seen (on close examination) in the posterior triangle base
- Sometimes, we can palpate a post stenotic aneurysm of S.C.A
- Tests: To look for occlusion of artery (to rule out occult TOS)

i. **Adson test**: Extend the upper limb outwards and turn to the same side and take a deep breath
   - If the radial artery pulse decreases (dynamicity of pulse decrease) which is easily palpable before, will not be palpable now)

ii. **Roos test**: Clinical of fingers in an abducted position, can see claudication pain and patient puts hands down

iii. **Halstaed test**: Ask the patient to stand in a military position. They will get pain in arm

iv. **Wright test**: Hyper extend the hand (VL) and the arm should touch same side ear causes pain in the arm (hyperabduction test)

TUTORIALS LOGIN FOR SUCCESS

Various causes of TOS 00:29:16

Cervical rib -

- 50% times bilateral
- Common in young age, in females
- It can be a complete rib and can be a partial rib or can be partial rib with membranes cord (or) a full rib with membranous cord

Fig: 5

AfraTafreeh.com

- Diagnosis: by taking x-ray neck A-P view
- Treatment: with help of cardiothoracic surgeons, excise the rib. Before surgery CT thoracic surgeon have CT scan neck to know exact anatomy

  i. CT scan neck / thorax

  ii. Angiogram

Other causes of TOS

Congenital	Acquired
- Cervical rib (most common causes)	- Fracture 1st rib - Fracture clavicle

AfraTafreeh.com

- Long C_7 transverse process - Abnormal 1st rib - Scalene muscle related anomaly - Huge pendulous breast, sagging shoulders	- Injury to scalene muscle - Any surgical scar/ soft tissue injury in neck

Branchial cyst 00:34:10

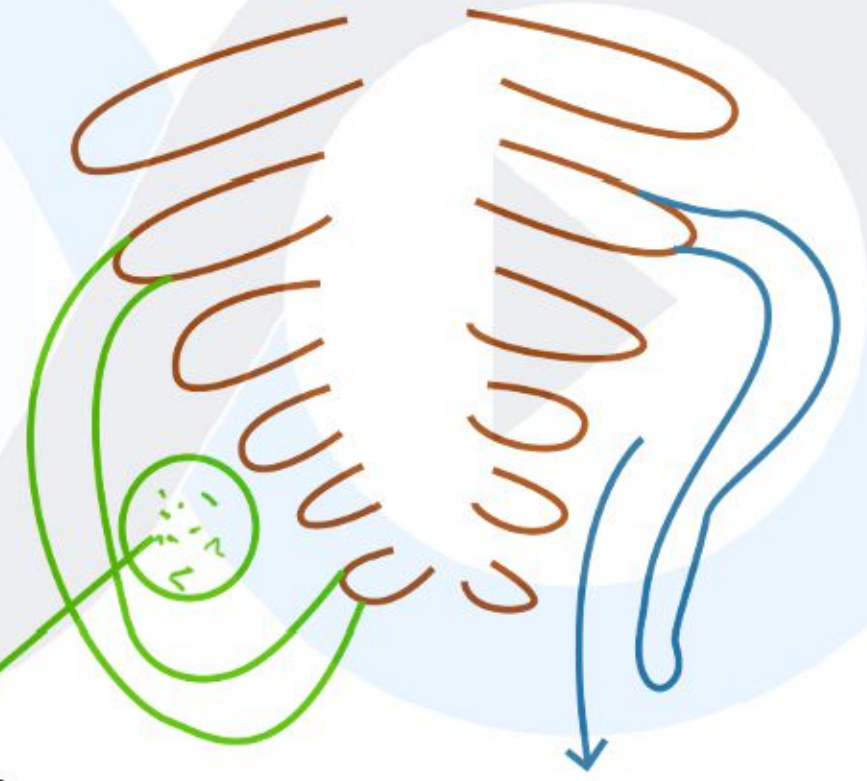

Fig: 6

- Embryologically, the 2nd arch goes down and fuses with 6th arch and the pouch formed in between coil disappear
- If it is not disappearing, it is called branchial cyst (fused with pouch)
- Another anomaly is the 2nd arch will grow and not fuse with 6th arch and remain as an opening called as branchial sinus (or) fistula (failure of fusion)

- The bronchial cyst is seen anterior to sternocleidomastoid in the upper 1/3
- Branchial fistula is seen in lower 1/3 anterior to sternocleidomastoid. This fistula will have a tract will go inside and opens posterior to tonsil in the tonsillar fossa
- 2nd arch anomaly causes opening in the lower third
- 1st arch anomaly causes pre auricular sinus
- 3rd arch anomaly causes clavicular/ suprasternal sinus
- Most common is 2nd arch only
- Branchial cyst is lined by squamous epithelium
- Branchial fistula is lined by ciliated columnar epithelium

AfraTafreeh.com

Branchial cyst	Branchial fistula
- Transillumination negative. Since, contain thick content – contain cholesterol crystals ⊕ (Cholesterol crystals ⊕, but transillumination positive is hydrocele) • Acquired – is a complication of branchial cyst • Complication:	Course → starts from lower $1/3^{rd}$ of SCM ↓ From there passes between the C.C.A bifurcation ↓ Pierces superior constrictor of pharynx ↓ Enters into tonsillar fossa

AfraTafreeh.com

- Infection: If we open it – acquired fistula/ sinus ↓ Seen in upper 1/3 of sternocleidomastoid muscle - Branchiogenic cancer ↓ Mostly squamous cell cancer – can also be a adenocancer if it develops from bronchial sinus remanent	
IOC: CECT neck - Bronchial sinogram – it shows where the tract is going and ending	
Treatment: Excise the branchial cyst	Treatment: For branchial fistula → make the stepladder incision on the neck. We have to remove the tract completely

Cystic Hygroma 00:43:16

- It is the congenital sequestration of lymphatics in the neck
- It is common in new-born period

- It is associated with Turner's syndrome, Trisomy 21, 18
- Baby is presenting with a huge swelling in the posterior triangle of neck
- It is the earliest swelling in humans one can note
- It can be found on antenatal USG
- These babies can present as obstructed labour also

Complications

- Respiratory difficulty
- Spontaneous resolution can also happen
- Obstructed labour

Treatment

AfraTafreeh.com
TUTORIALS
LOGIN FOR SUCCESS

- Conservative neck node dissection – It is morbid surgery but done in old days. There is risk of recurrence
- Latest treatment is to inject sclerosant
  - Sclerosants used ideally are Picibanil (OK432 old name), Bleomycin

AfraTafreeh.com

Laryngocele 00:46:34

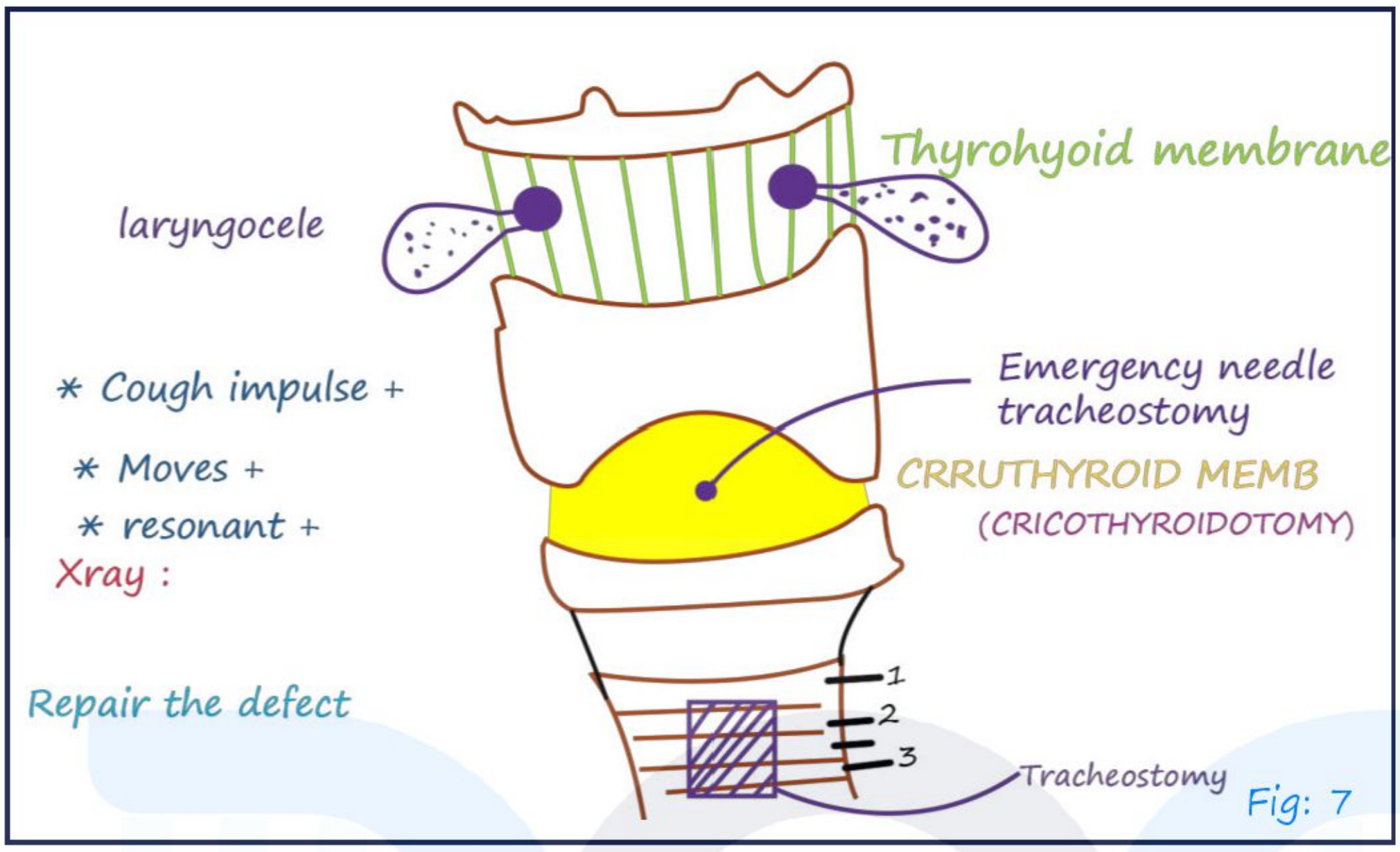

Fig: 7

- A trumpet blower (or) teacher etc because of shouting and other things who strain. These guys will develop weakness in the thyrohyoid membrane and laryngeal mucosa will protrude out from weakness spot, with the formation of swelling called laryngocele
- The cricothyroid membrane is the place where we do emergency needle tracheostomy called as cricothyroidotomy
- Tracheostomy is done between 2nd and 3rd and 4th rings
- Clinical features:
  - Cough impulse positive
  - Moves with deglutition
  - On x-ray, it shows the presence of swelling which is air filled. So, resonant on percussion
- Treatment: Repair the defect

Swellings showing movement with deglutition

i. Thyroid

ii. Thyroglossal cyst

iii. Laryngocele

iv. Sub hyoid bursa

v. Mid line dermoid

Pharyngeal pouch/ Zenker's diverticulum

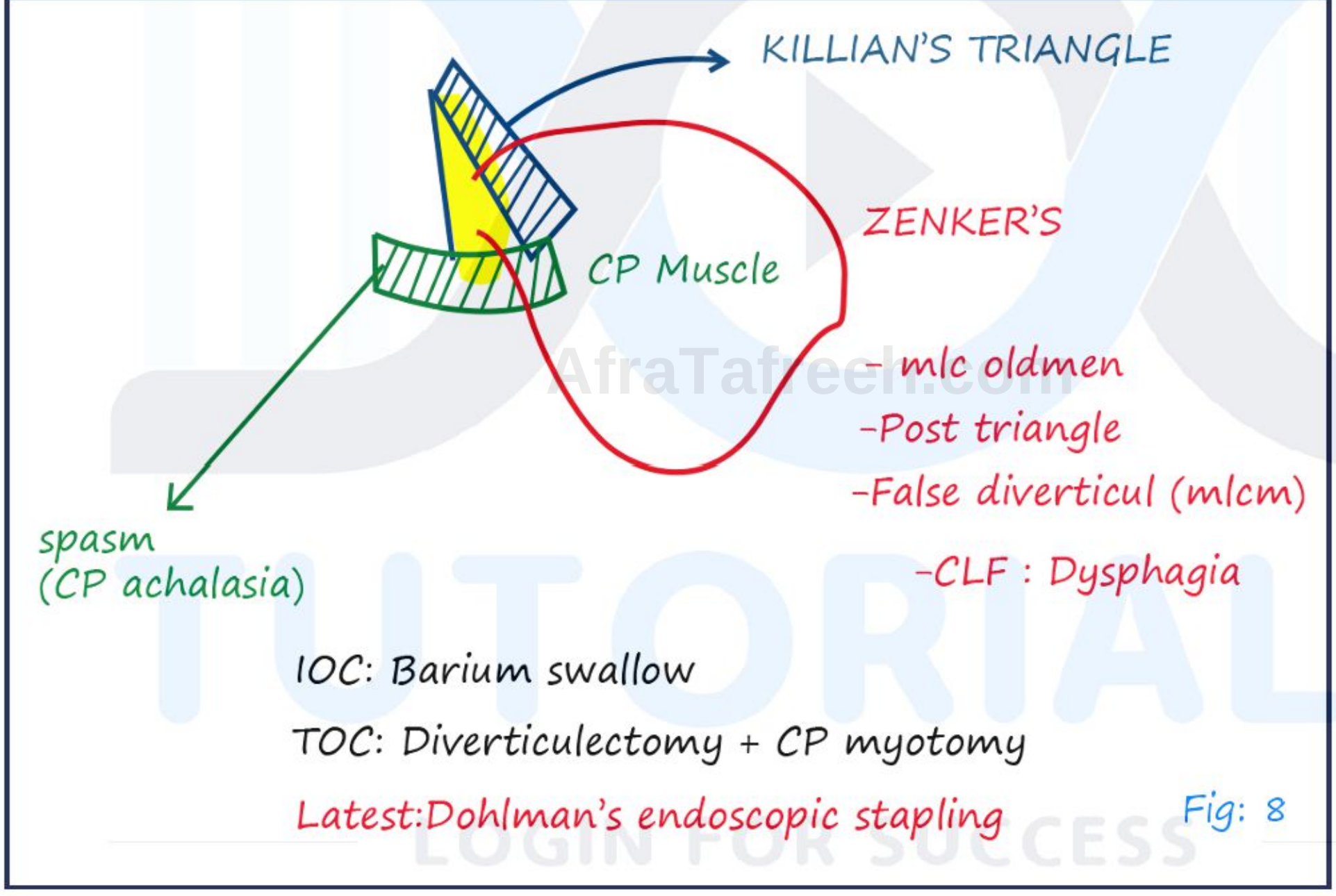

Fig: 8

AfraTafreeh.com
TUTORIALS
LOGIN FOR SUCCESS

- It is an air-filled swelling in the posterior triangle
- It is a defect in Killian's triangle
- Herniation of pharyngeal mucosa through this triangle is Zenker's
- Most common in old men > 60 years
- It is a false diverticulum. It contains only mucosa and submucosa
- Clinical features – patient present with dysphagia

AfraTafreeh.com

- Main cause here is spasm of cricopharyngeus muscle. So, it is also called as cricopharyngeal achalasia
- IOC – Barium swallow
- Treatment OC – Diverticulectomy + cricopharyngeal myotomy
- Latest treatment – Dohlman's endoscopic stapling procedure

TUTORIALS
LOGIN FOR SUCCESS

ORAL CAVITY LESIONS

Ulcers in oral cavity 00:00:14

Painful ulcers	Painless ulcers
1. Aphthous ulcers - usually due to stress vitamin B deficiency can be seen anywhere in oral cavity 2. Tuberculous ulcer seen on tip of tongue 3. Dental ulcers – usually seen on lateral margin of tongue, due to sharp teeth (or) wearing of dentures	1. Cancer 2. Gummatous ulcer in syphilis

Tafreeh.com
TUTORIALS
LOGIN FOR SUCCESS

Syphilis in oral cavity

- 1° - painless chancre
- 2° – Hutchinson's wart (in midline of tongue), snail track ulcers, mucous patches
- 3°
  - Gumma
  - Glossitis (Premalignant lesion for oral cancers)

Premalignant lesions of oral caner

- In India most common among males → oral cancer

AfraTafreeh.com

Oral cancer 00:03:44

High risk lesions

i. Leukoplakia

ii. Erythroplakia

iii. Chronic hyperplastic candidiasis (seen in immunocomprised patients)

Medium risk lesions [3S]

1.S-Submucous fibrosis

2.S-Syphilic glossitis

3.S-Sideropenic dysphagia

Low risk lesions

1.DLE

2.Oral lichen planus

3.Discoid keratosis congenita

Leukoplakia -

LOGIN FOR SUCCESS

- Most common predisposing factor
- White patch in the oral cavity, it has 2.4 % malignant potential
- Most common seen in smoking, DM ⊕
- Speckled leukoplakia has increased risk among different types
- Ask patient to stop smoking
- Laser is used for treatment

Erythroplakia

- Highest risk is seen with erythron, 17 times risk of malignant potential
- Velvety plaque is seen in tongue and oral mucosa

Chronic hyperplastic candidiasis

- Oral antifungal drugs are given

Submucous fibrosis

- Because of continuous betel nut chewing
- Arecoline in betelnut induces fibrosis
- Patient is unable to open the mouth
- It is a premalignant condition

AfraTafreeh.com
TUTORIALS
LOGIN FOR SUCCESS

Sideropenic dysphagia/ Plummer Vinson syndrome

- AKA Patterson Kelley syndrome
- Common in females of 20-40 years
- They develop cancers in oral cavity, oropharynx oesophagus all these are squamous cell caners
- They develop post cricoid web
- They come with iron deficiency anaemia
- Associated with koilonychia

Etiological factors causing oral cancer 00:10:40

i. Personal habits

- Smoking

AfraTafreeh.com

- Alcohol
- Tobacco
- Betel nut (arecoline)

ii. Dietary factors

- Deficiency of A, C, E (antioxidants)

iii. Environmental factors

- UV radiation causes lip cancer

iv. Infections

- HPV 16,18
- Syphilis
- Candidiasis
- HIV 1,2
- Immunocompromised patients

v. Genetic risk factors or syndrome

- Most common is p53 mutation (Lifraumeni syndrome)
- Plummer Vinson syndrome
- Fanconi anaemia

TUTORIALS
LOGIN FOR SUCCESS

Pathophysiology of oral cancers 00:13:36

- Field cancerisation → is the effect seen in oral cavity
- Means even if the cancer is in tongue, the other areas are still in the risk of cancer, because the same problem has happened every where
- Most common type of cancer in oral cavity → squamous cell cancer

- Because of field cancerisation – patient can develop
  i. Synchronous cancers – i.e., cancers happening in oral cavity within 6 months of primary
  ii. Metachronous – happening after 6 months of primary
- There is 15% chance of 2nd cancer due to field cancerisation effect
- Squamous cell cancer has property to spread by lymph node mets. Lymph node mets is usually systematic mets. (It goes from level 1 to level 2 then level 3, like that)
- Only one type of oral cancer can produce skip mets is Tongue cancer. Directly it can go to level 3 nodes directly
- Most common site of cancer in world – Tongue (lateral margin on anterior 2/3rd of tongue)
- Most common site of cancer in India – Buccal mucosa
- Most common site of cancer in western countries – most common in lower lips (90%)
- Other places we can get mets is gums i.e., alveolus cancer and cancer behind 3rd molar in an area called retromolar trigone area
- Bilateral mets can be seen in
  - Lip cancer (lower lip)
  - Soft palate cancer
  - Supraglottic cancer

AfraTafreeh.com
DOT TUTORIALS LOGIN FOR SUCCESS

AfraTafreeh.com

- T_1 < 2cm (or) **depth of invasion < 5mm, whichever is big, we should take it**
- T_2 – 2-4cm (or) **DOI 5-10mm**
- T_3 - >4cm (or) **DOI >10mm**
- T_4 – a → Infiltrating skin, Inferior alveolar nerve, floor
  - b – pterygoid plates, carotid sheath, ICA, bones, masticator space
- N_1 – single node <3cm
- N_{2a} – single node 3-6cm
- 2b – multiple Ipsilateral nodes 3-6cm
- 2c – multiple bilateral nodes 3-6cm
- N_3a – any nodes >6cm
- N_3b – extranodal extension ⊕ (ENE)
- M_1 -mets
- Most common site of distant mets is to **lungs**

TUTORIALS
LOGIN FOR SUCCESS

Grouping of stage

- Stage I – T_1No
- II – T_2 No
- III – T_3 N1, T_3 No, any $T_{1,2,3}$-N_1
- IVa – T_4a → involvement of skin, N_2
- IV_b - T_4b → involvement of bone and artery, N_3
- IV_c – M_1 → actual mets

Investigations of oral cancers 00:25:14

- Any ulcer in oral cavity not healing for >3weeks, we should thick of malignancy (or) any lymph node swelling in neck > 3 weeks
- Associated alarming features are trismus, odynophagia, pain, sore tongue
- IOC to diagnosis → wedge biopsy from edge of ulcer

- Wedge biopsy is taken in such a way that is, the smaller normal epithelium is taken for comparison is bigger area is taken from ulcer. So, the base of wedge should look on ulcer, and apex should look on normal area 2% toluidine blue is contrast used to find pre-malignant lesions in oral cavity
- Id node ⊕, then FNAC done under USG guidance if needed

Staging IOC 00:18:33

- Staging of oral, oropharyngeal and salivary gland tumors. All tumors are by MRI-STIR MRI
- Short TAU inversion recovery MRI-special MRI
- Here we use Gadolinium contrast
- T & N staging is done with help of STIR MRI

AfraTafreeh.com

AfraTafreeh.com

- M staging is done by CT thorax
- PET-CT is not only indicated in all oral cancer patients
- If we plan only radiotherapy, no surgery. At that time, we can go for PET CT, to find places with increased activity and RT is given to that site (for patients not planned for surgery)

Tongue cancer 00:31:38

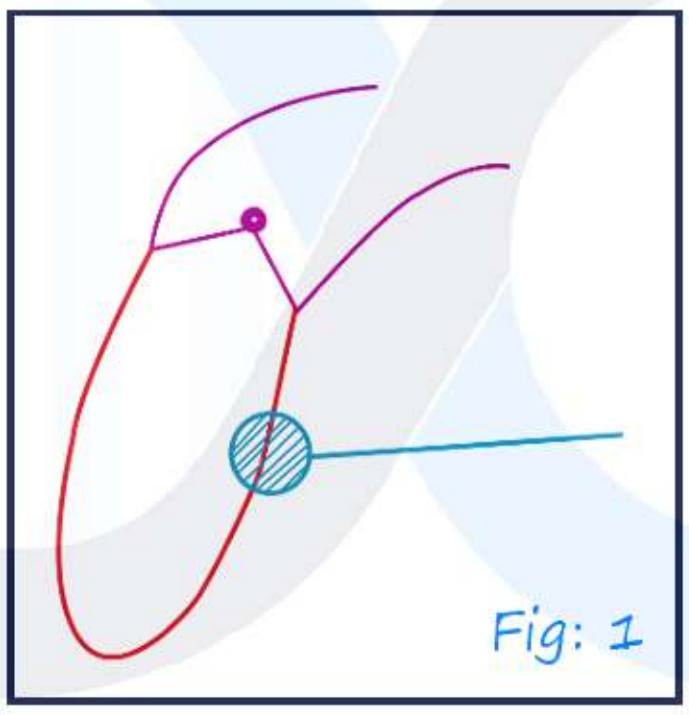

Fig: 1

- Cancer of tongue is common on the lateral margin od anterior 2/3 of the tongue
- It is usually a painless ulcer, so they don't come to hospital soon
- One day, when it infiltrates underlying nerves → pain happens. It can infiltrate deeper into pterygoid plates and even cause trismus

Management as per staging

- T_1 < 2cm
  - We can do a wedge resection with 1cm margin & can reconstruct it primarily

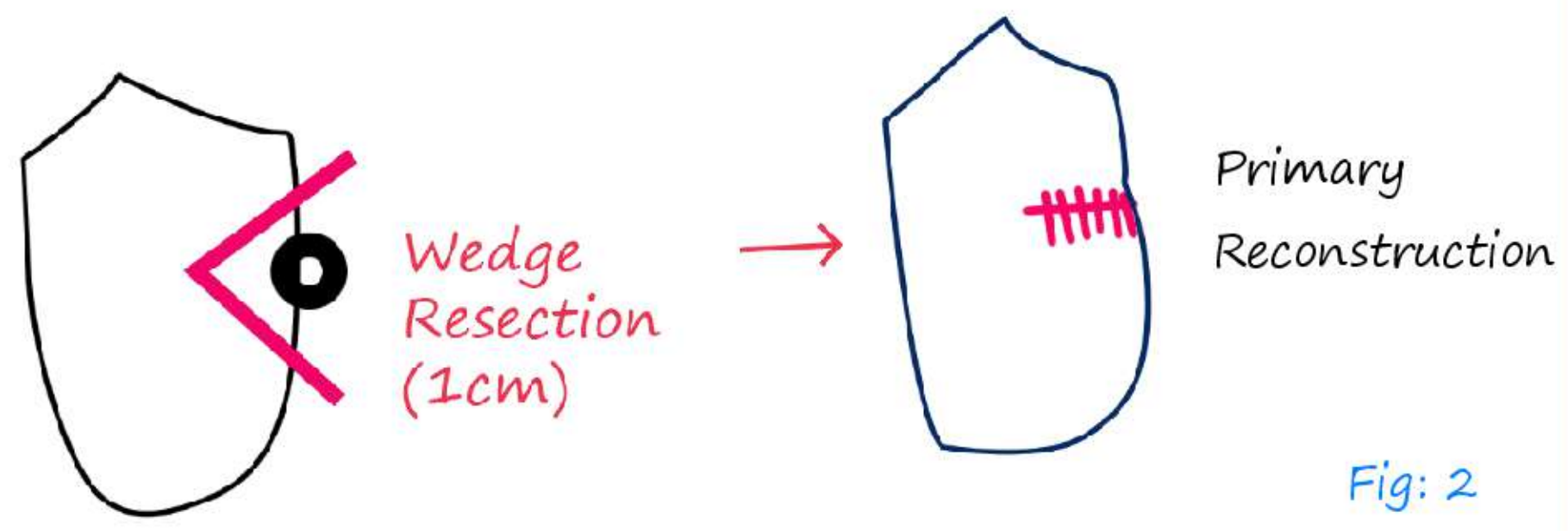

Fig: 2

- T_2 – growth > 2cm. Here we do Hemi glossectomy. Here we have to take radial forearm muscle, by using it reconstruct the half of tongue **(RFFF)-Radial Forearm Free Flap**

Fig: 3

AfraTafreeh.com
TUTORIALS
LOGIN FOR SUCCESS

- T_3 – 2-4cm
  a. If it crosses midline – go for glossectomy
  b. If it doesn't cross midline – go for hemiglossectomy

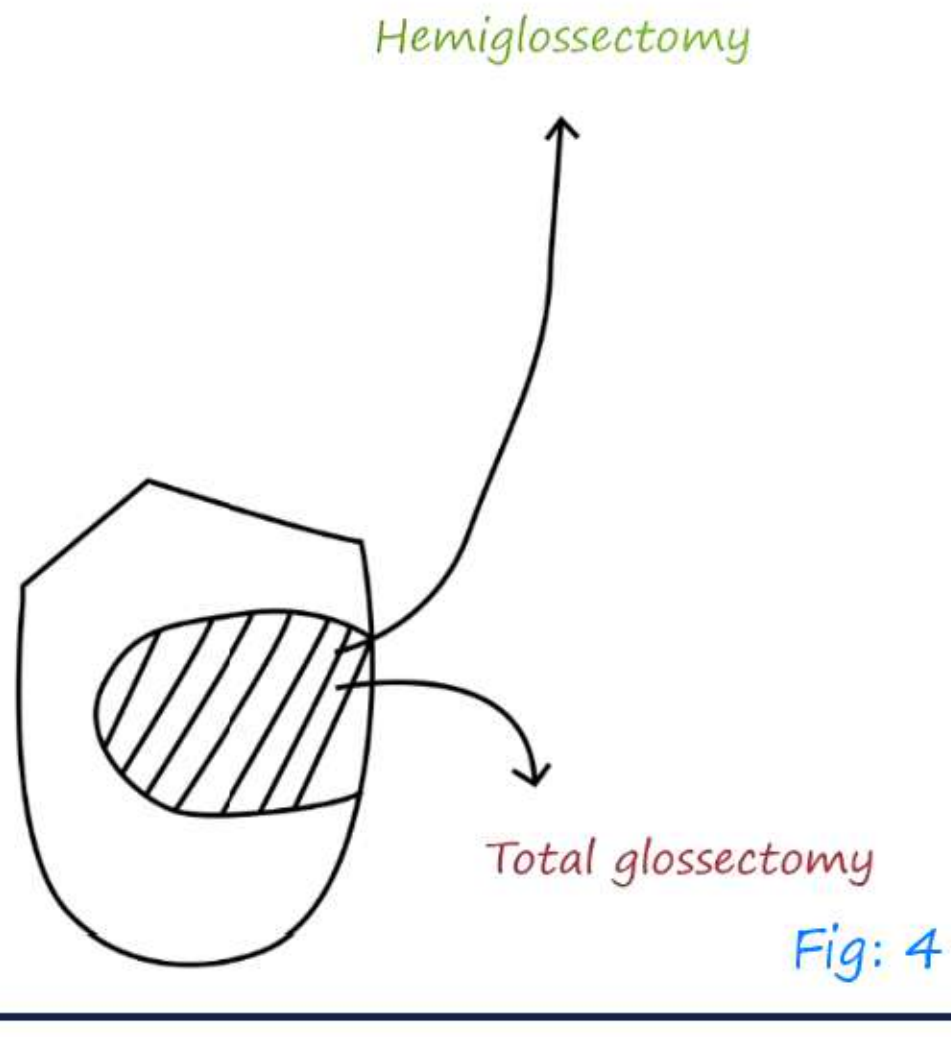

Fig: 4

AfraTafreeh.com

- In total glossectomy – completely removed anterior 2/3 of tongue and after that the area is reconstructed using a special flap PMMC (or) deltopectoral flap
- T_4 – cancer from tongue infiltrates mandible (or) floor

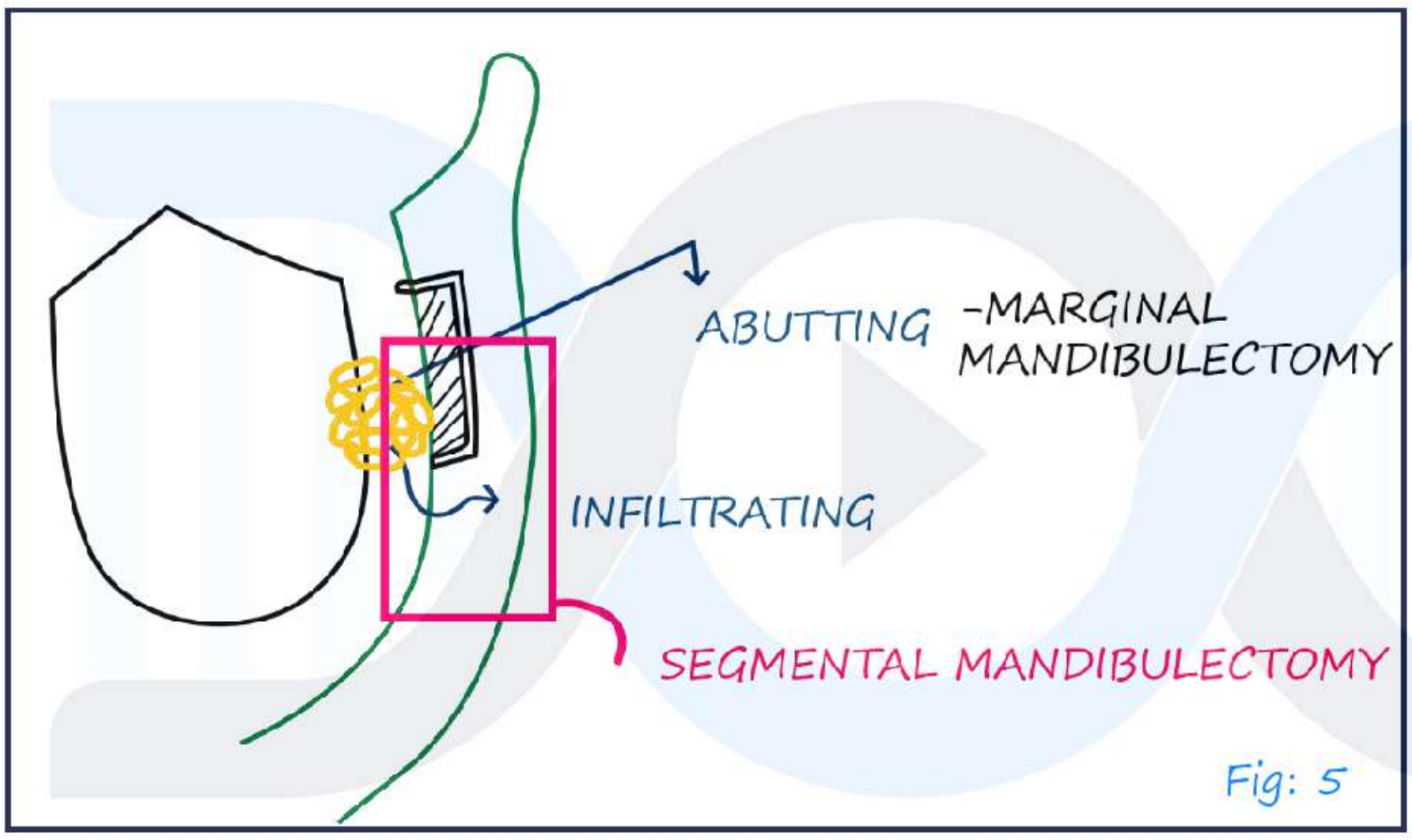

Fig: 5

TUTORIALS
LOGIN FOR SUCCESS

a. If it is abutting/ touching the mandible, we go for inner table mandibulectomy → marginal mandibulectomy
b. If it is infiltrating the mandible – the bone will be thickened, so go for a segmental mandibulectomy

- IOC to know bone involvement, whether it is abutting/ infiltrating – **CT facial bones**
- After segmental mandibulectomy, it is replaced by radius bone (to fill the gap)

- If growth from oral cavity is infiltrating the mandible and also having neck nodes – we do **commando operation**
- It is Morbid procedure, NoT done now a days
- It is indicated for any oral cavity cancer which is infiltrating mandible and also having nodes positive
  - COM – Combined
  - MA – Mandible
  - ND – Neck dissection
  - O – Operation

Flaps –

i. RFFF – most common used for tongue, based on radial artery

ii. PMMC – pectoralis major myocutaneous flap, based on thoracoacromian artery – only in males

iii. DP flap used in females, deltopectoral flap. It is based on internal mammary artery

AfraTafreeh.com
TUTORIALS
LOGIN FOR SUCCESS

Cancer lip 00:43:10

- 90% of cancers seen in lower lip, 10% → upper lip
- Mainly predisposed by UV light
- In upper lip → most common cancer is basal cell carcinoma (BCC)
  - Along the tear flow area

AfraTafreeh.com

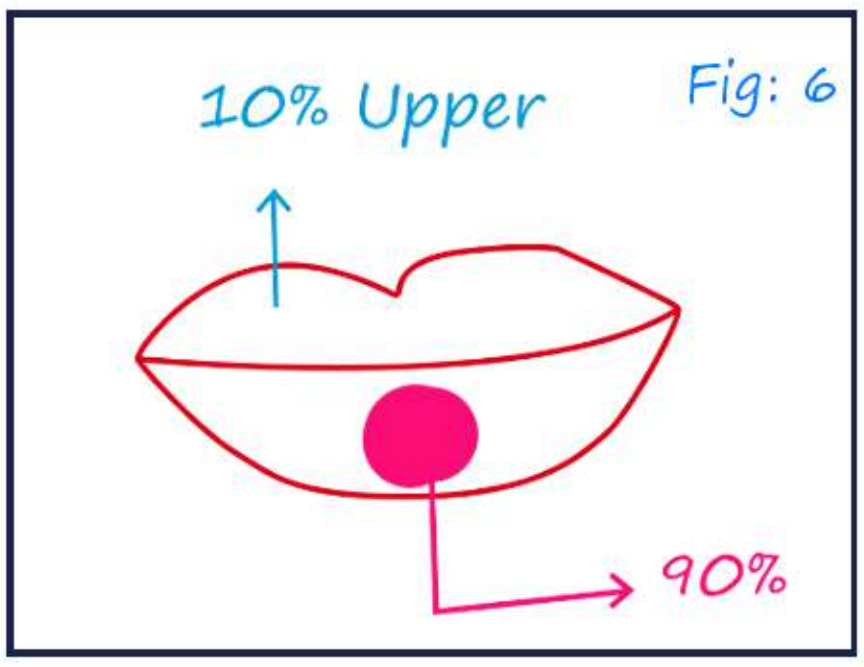

Fig: 6

- Squamous cell carcinoma, verrucous cancer can also happen here
- In lower lip – squamous cell cancers are seen

Treatment

Fig: 7

- We give 1cm margin to cancer, if the defect is <1/3rd of the original lip, then we can go for primary closure, we can pull it and close
- If the defect after surgery is > 1/3 → go for flaps

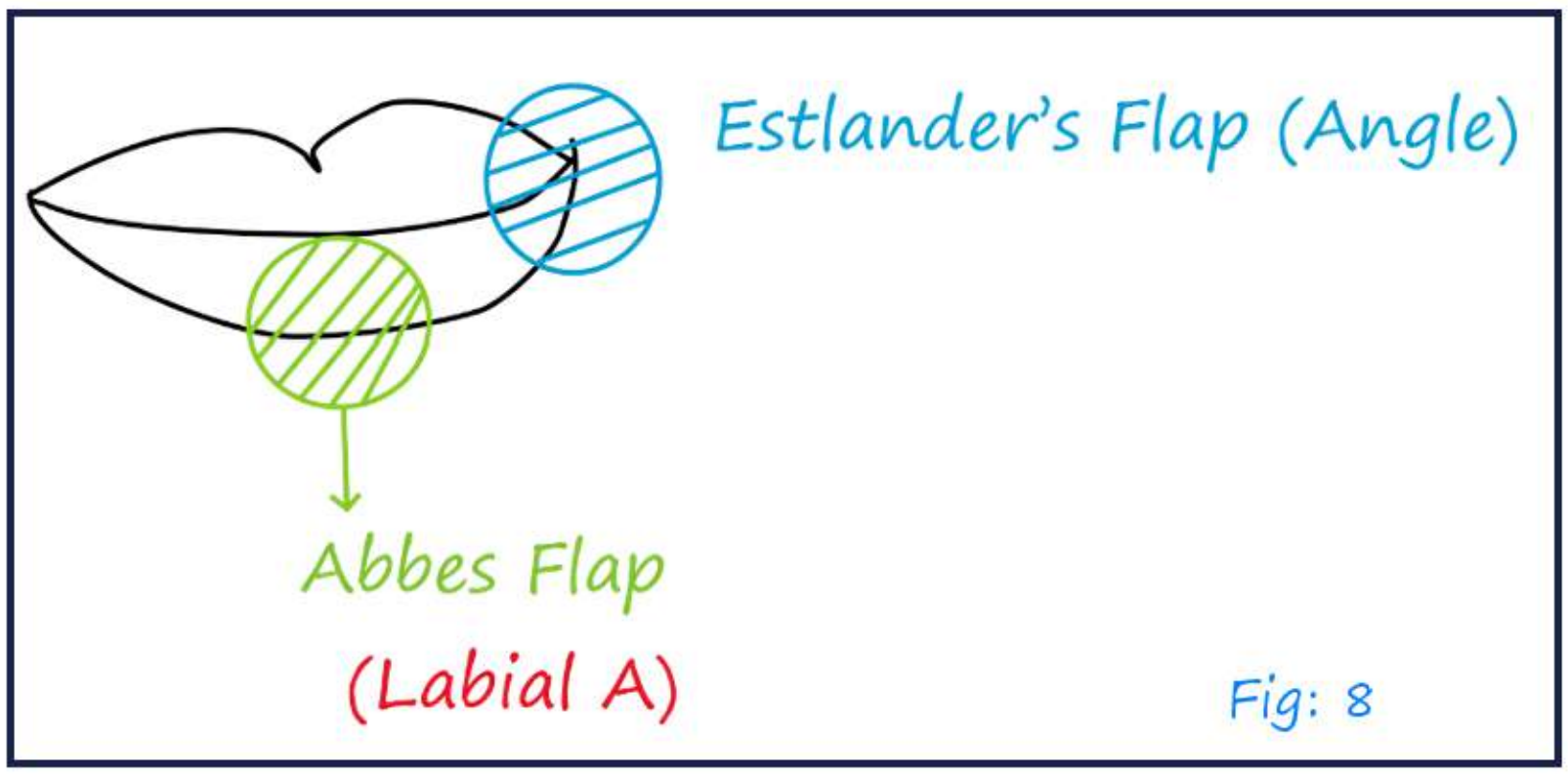

Fig: 8

i. Abbes flap → it is used if the defect is in centre of lip

- It is based on labial artery

ii. Estlander's flap – used for angle of lip

Flaps used for huge detects

i. Johanssen step ladder flap

ii. Karpandazic flap

iii. Burrow's Bernard flap

Cancer of buccal mucosa 00:46:50

- We have to do wide local excision; we can excise even the skin on face also
- After excision we do PMMC (for males)/DP flap (for females) for reconstruction
- Other areas of cancer :-
- Retro molar trigone cancer → can do through mouth. Since, it is deeper inside, so, split open mandible and go for Visor split mandible approach
- Alveolus – (gum cancers) → we do surgical excision

Radio therapy 00:48:45

- Is also equally preferred in oral caners
- EBRT – external beam radiotherapy is given in those days. Now we do interstitial brachytherapy → we put

AfraTafreeh.com

iridium needles and directly give radiotherapy on tumors

- Radiotherapy has its morbidity and mortality – dryness of mouth, salivary gland adenitis can happen
- All tumors in oral cavity, we can use R.T except Alveolus cancer
  - Since, if RT given, they go for osteoradionecrosis (R.T is C/I) only surgery done here
  - Surgical treatment – gold standard for all cases (or) surgical clearance with 1cm margin
  - After surgery we have to do reconstruct by 1° closure (or) by flap

Level of neck nodes 00:50:34

- Level 1 – sub mental, sub mandibular

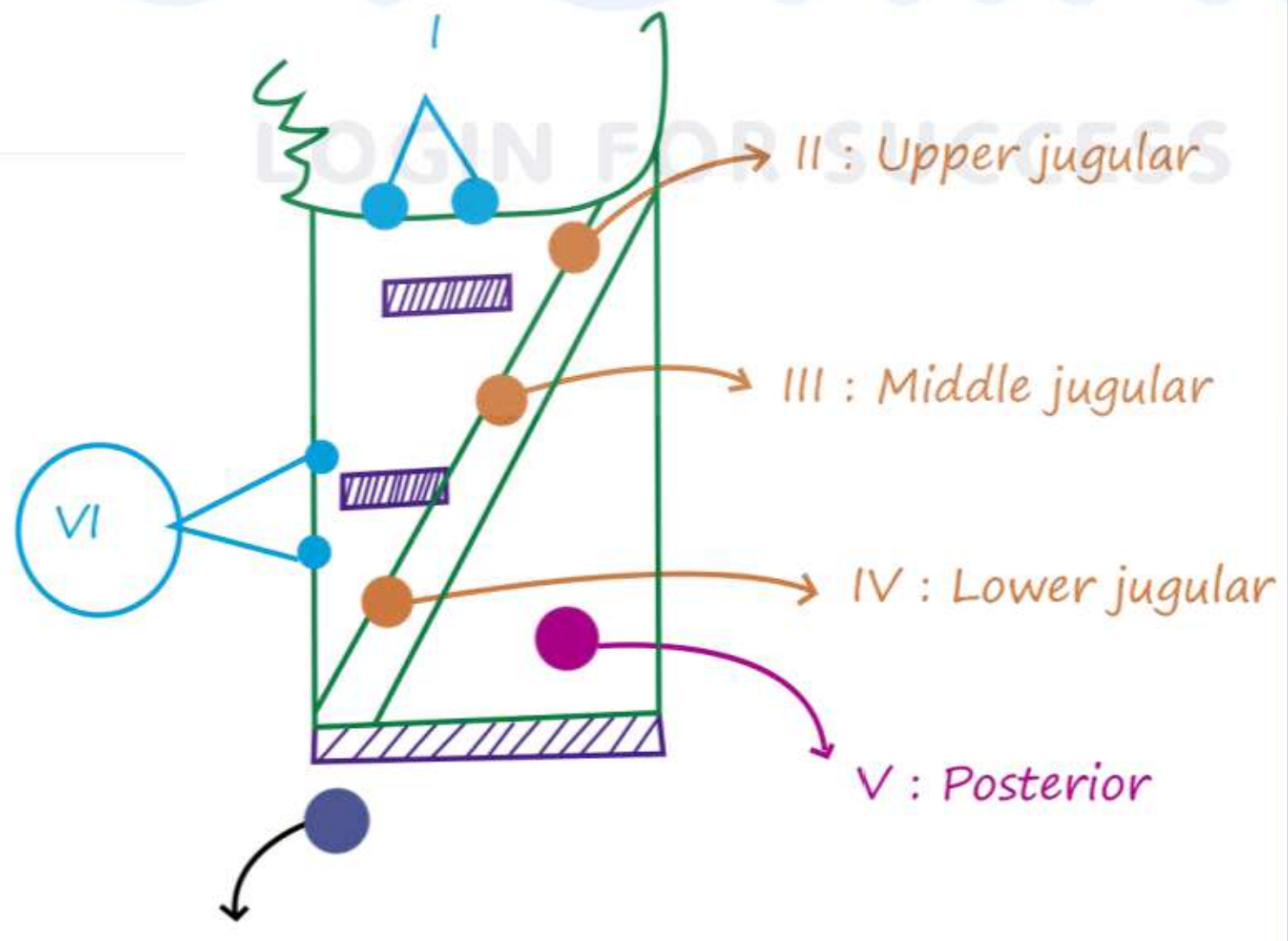

Fig: 9

- Level 2 – upper jugular

- Level 3 – middle jugular
- Level 4 – lower jugular
- Level 5 – nodes in posterior group
- Level 6 – pre tracheal and pre-laryngeal (delphian nodes)
  - Level 2 nodes are seen from base of skull to hyoid bone
  - Level 3 nodes are seen hyoid bone to cricoid cartilage
  - Level 4 nodes are seen cricoid cartilage to clavicle
- In centre/ midline nodes present between hyoid bone to clavicle are prelaryngeal / delphian nodes
- 3 neck node dissections are there based on levels of lymph node neck

  i. RND: Radical neck node dissection

  ii. MRND: Modified radial neck dissection

  iii. SOMHND – Superior omohyoid neck node dissection

AfraTafreeh.com
TUTORIALS
LOGIN FOR SUCCESS

RND

- Also, Crile's
- Structures removed
  - Level 1 to 5 nodes, strap muscles, fascia, fat , SCM, IJV, spinal accessory nerve, submandibular gland, part of parotid

AfraTafreeh.com

- Not removed/ preserved here is carotid artery, Vagus nerve, phrenic nerve, lingual nerve, hypoglossal nerve

MRND

- AKA BOCCA (type 3 MRND)

  ↓

  Functional neck node dissection

  ↓

  We preserve SCM, IJV, spinal accessory nerve

  ↓

  Remaining same

SO MHND

- It is a diagnostic procedure for no cases
- Now early N_1 cases are also being done
- Here they dissect above the superior belly of omohyoid
- Level 1, 2, 3 nodes are removed and submandibular gland removed
- All the operations are done by Schobinger 'T' shaped incision open flap, then close flap

TUTORIALS LOGIN FOR SUCCESS

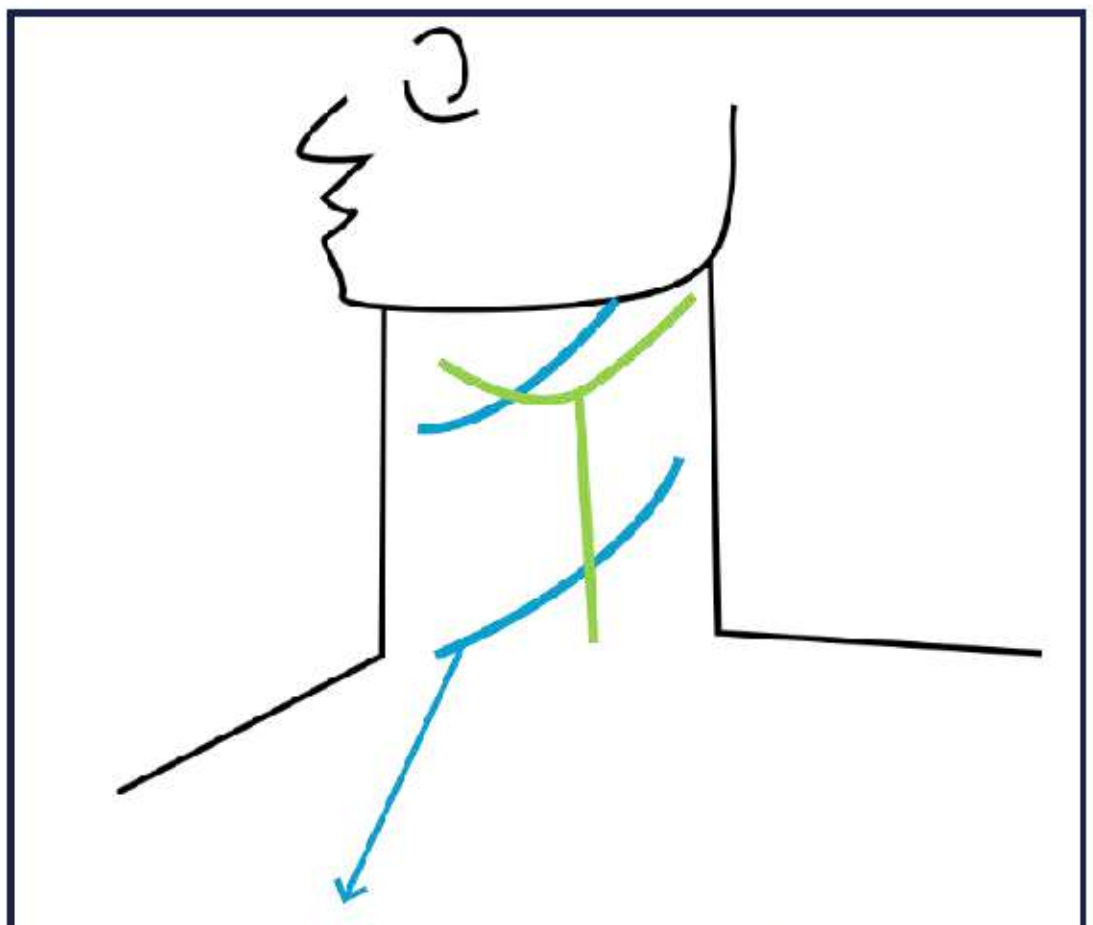

Mac Fee incision

Fig: 10

- Another incision is by putting 2 parallel incisions → Mac fee incisions

Complication of neck node dissection are:

i. Skin flap can go for necrosis
ii. Cranial nerve can go for palsy
iii. Carotid artery can blow out, it ruptures and patient can die

- Weber Ferguson incision is used for maxillary tumors and hard palate cancers

Dental cyst

- As known as radicular cyst
- Inflammatory pathology. It develops from erupted tooth; root of tooth gets infected

Dentigerous cyst

- Follicular odontoma

AfraTafreeh.com

- It is a developmental anomaly
- Some place where tooth not erupted. It forms a cyst. Inside cyst the tooth is seen
- Arises in unerupted tooth area
- It has soap bubble appearance on x-ray

Common features for both

- Most common in the upper jaw
- Most common in upper 2nd molar level (or) 3rd molar level
- Both are painless lined by stratified squamous epithelium. Resection is treatment of choice
- They expand the bone table as cyst expands (enlarged the bone)

Odontogenic kerato cyst

- It will not expand bone; it destroys the bone by enzymatic degradation (not expand bony table)
- These cysts will grow antero-posteriorly

DOC TUTORIALS LOGIN FOR SUCCESS

THYROID ANATOMY

Anatomical aspects of thyroid 00:00:32

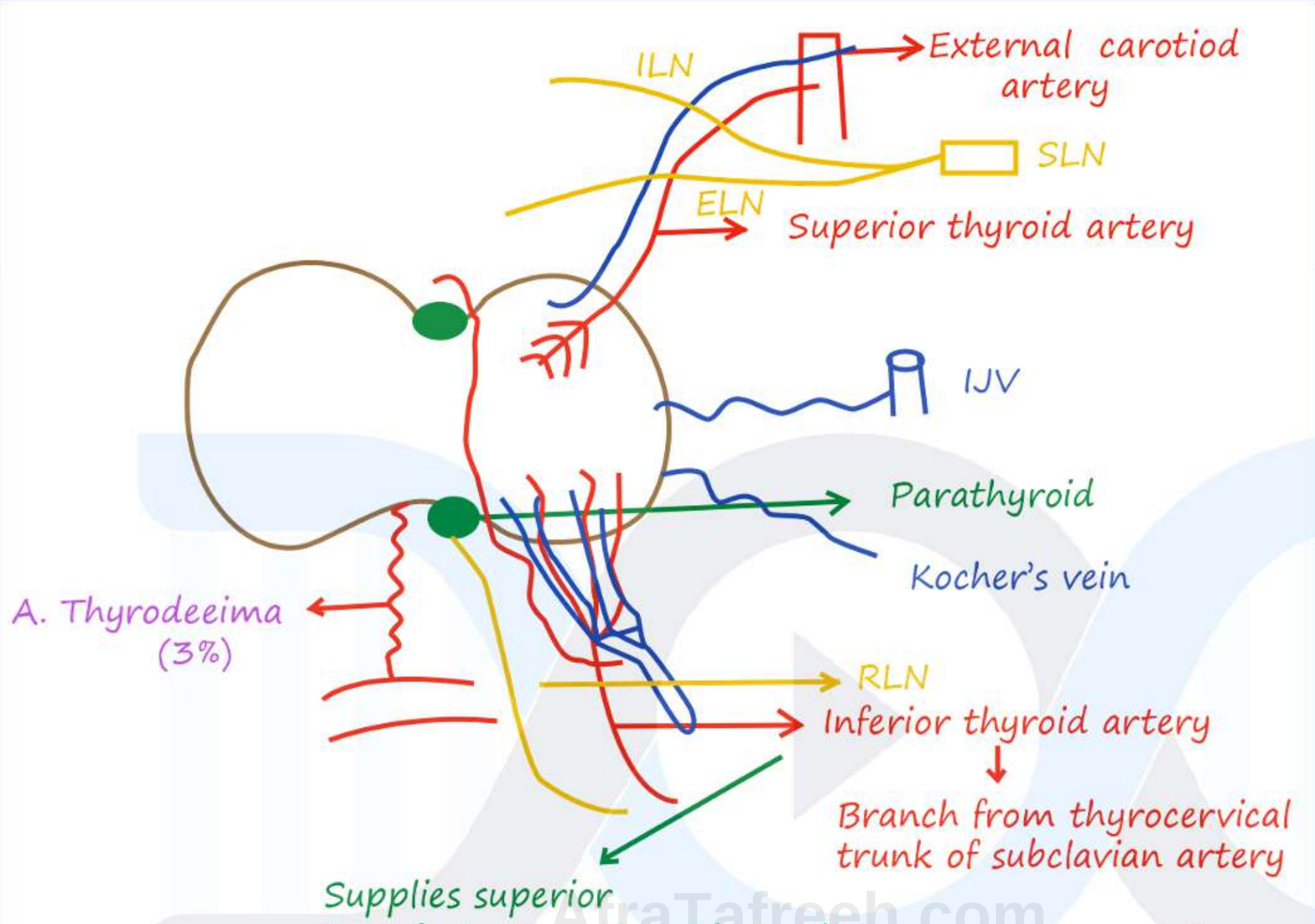

Fig: 1

- Superior thyroid vein drains into IJV
- Inferior thyroid vein drains into Brachiocephalic vein
- Middle thyroid vein drains into IJV
- Kocher's vein → drain either to IJV/ Brachiocephalic vein

- Thyroid gland – butterfly shaped gland derived from thyroglossal tract going from foramen caecum down and divides into thyroglossal ducts

AfraTafreeh.com

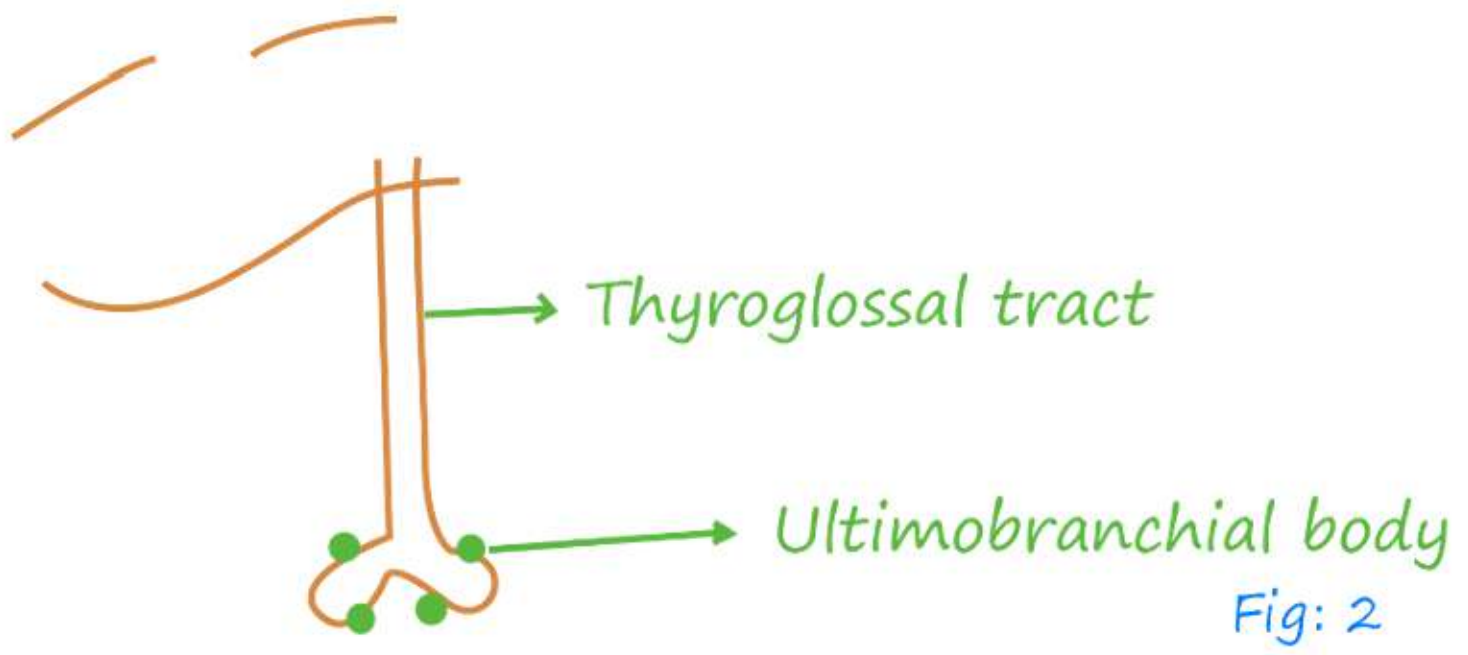

Fig: 2

- Parafollicular 'C' cells are derived from ultimobranchial body
- Thyroid if does not descend down and remains in posterior 1/3rd of tongue – lingual thyroid
  – Most common site of ectopic thyroid
- Superior laryngeal nerve divided into

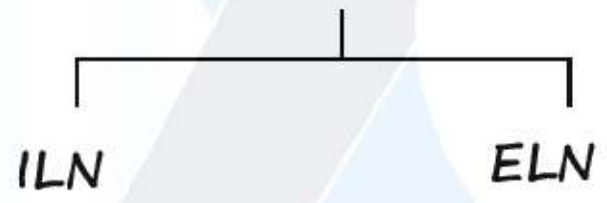

- RLN – Hooks around – Arch of aorta – left side
  – Subclavian artery – Right side
- To avoid injury to vessels, ligation done close to the gland
- To avoid loss of blood supply to parathyroid gland, inferior thyroid artery ligated close to the gland

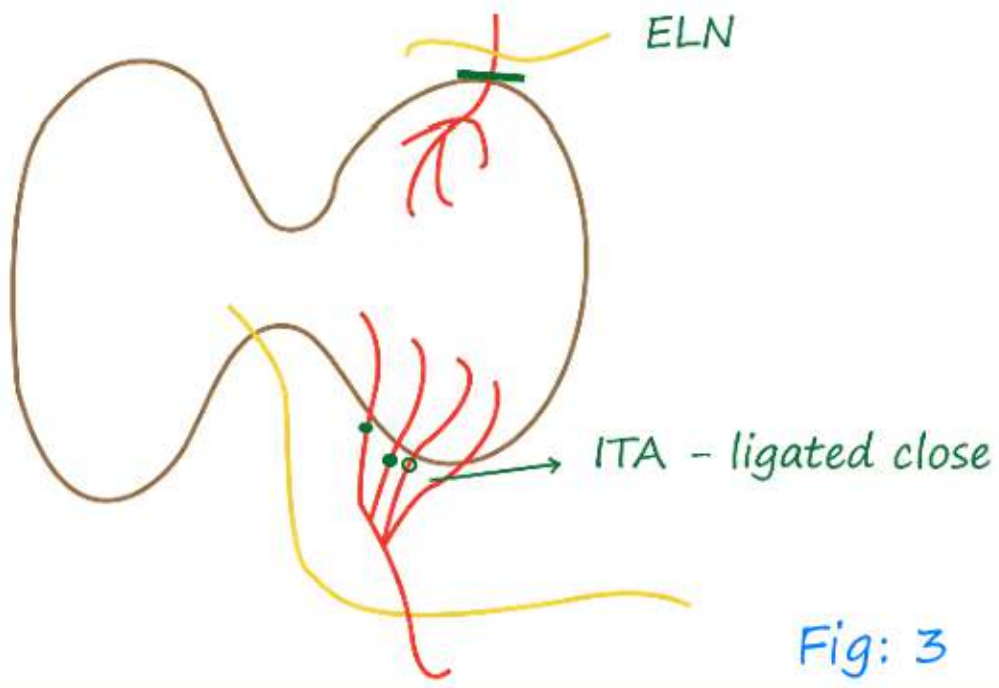

Fig: 3

Cernea classification 00:06:46

- Course of ELN
- 2 types: -
  - I: - >1cm away from superior pole
  - II: - <1cm from superior pole
  - IIa: - runs above the gland
  - IIb: - runs on the gland
- ILN – less chances of injury
- Most common nerve injured – ELN
- Others: -
  - RLN
  - ILN
  - Ansa cervicalis (AIIMS JUNE 2020)

AfraTafreeh.com

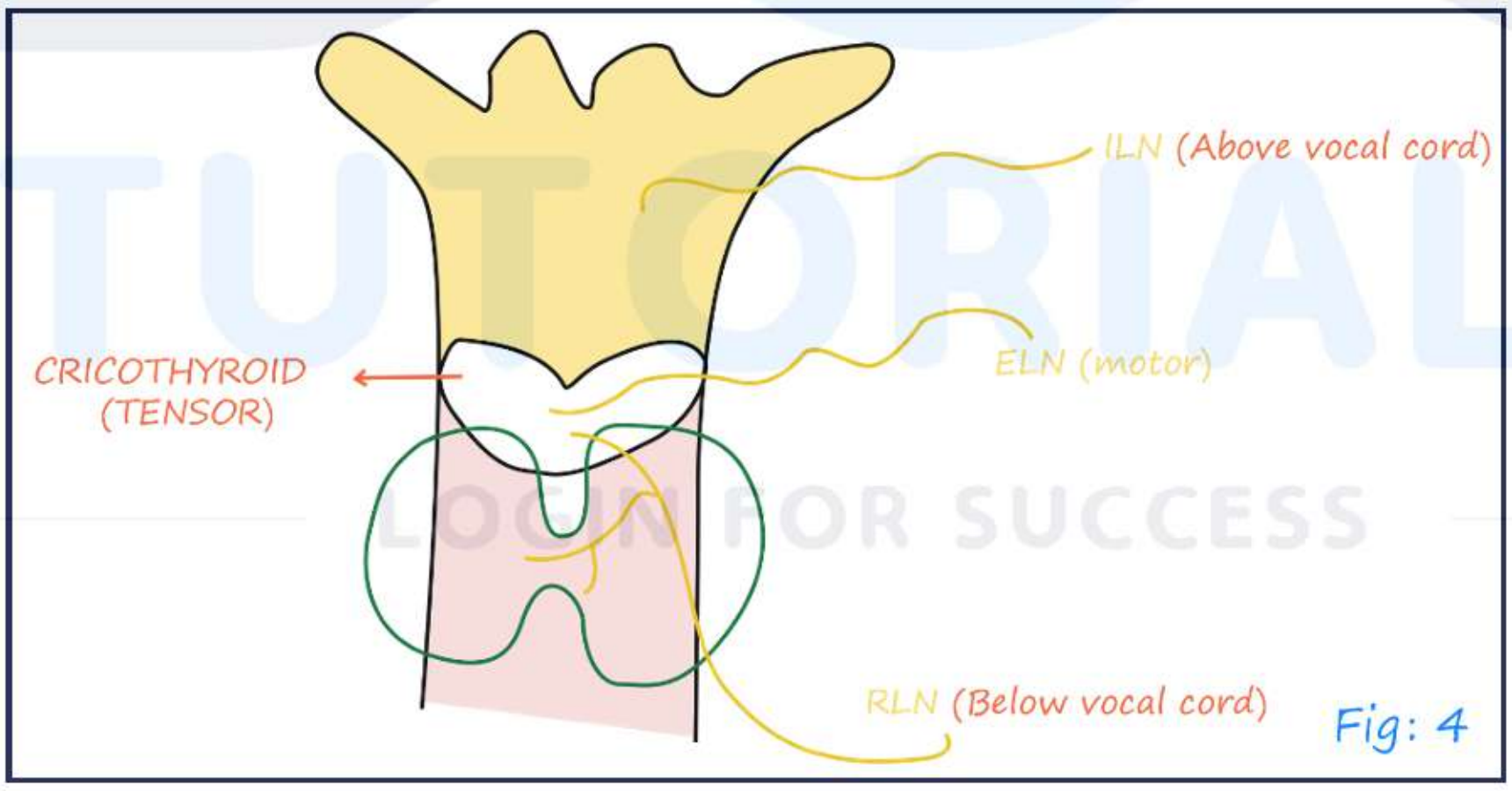

Fig: 4

- All muscles of larynx are supplied by RLN except cricothyroid
- Posterior cricoarytenoid
  - Abductor
  - Safety m/s of larynx
- ILN paralysed

AfraTafreeh.com

- Aspiration
- Paroxysmal nocturnal cough

- ELN paralysed – loss of timbre of voice (Huskiness)
- RLN injured – 1 nerve → Hoarsness
  - Both → Stridor

Note:-

S/P – extubating → Stridor
↓
Reintubate
↓
Shift to ICU (48hours)
↓
Shift to OT (ENT surgeon)
↓
No stridor ← **Extubate** → **Stridor** ⊕
↓
Tracheostomy
↓
3-6 months
↓
If permanent cadaveric position of VC ⊕
↓
Lateralisation of cord (Thyroplasty)
Arytenoidectomy

DOC TUTORIALS LOGIN FOR SUCCESS

RLN®

- Most common site of RLN injury – Beahr's triangle

BEAHR's TRIANGLE 00:14:48

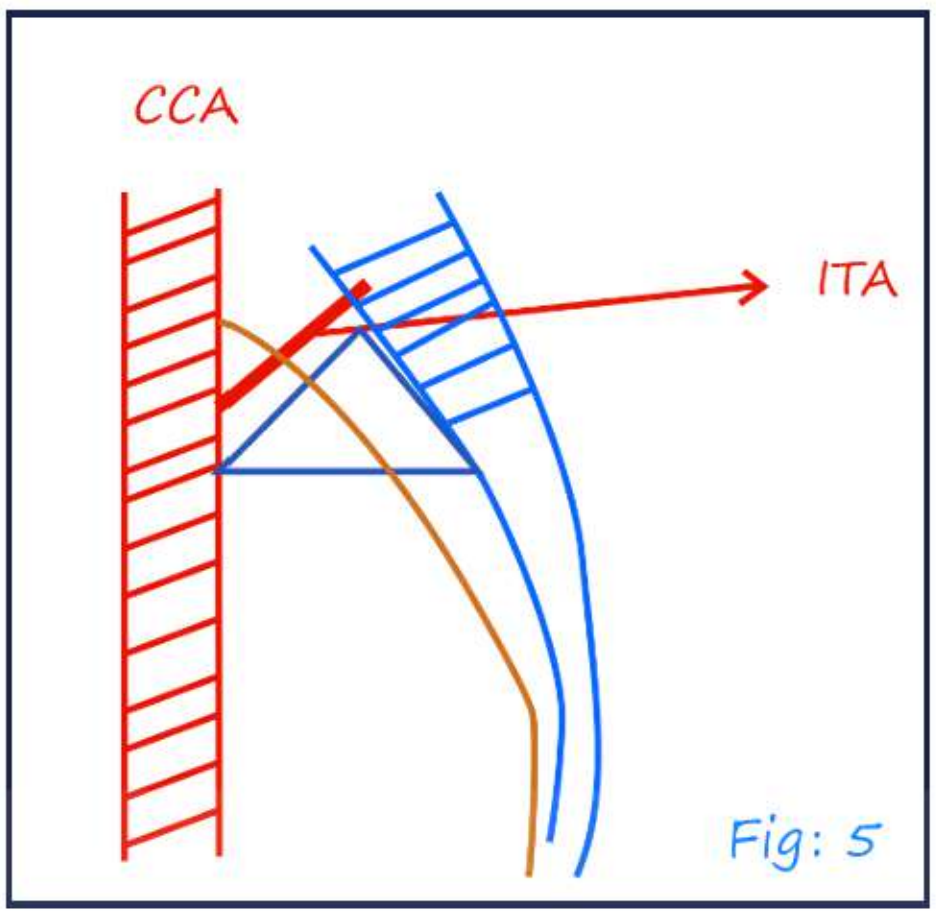

Fig: 5

- Laterally: – Common carotid artery
- Medially: – Tracheo esophageal groove
- Superiorly: – Inferior thyroid artery

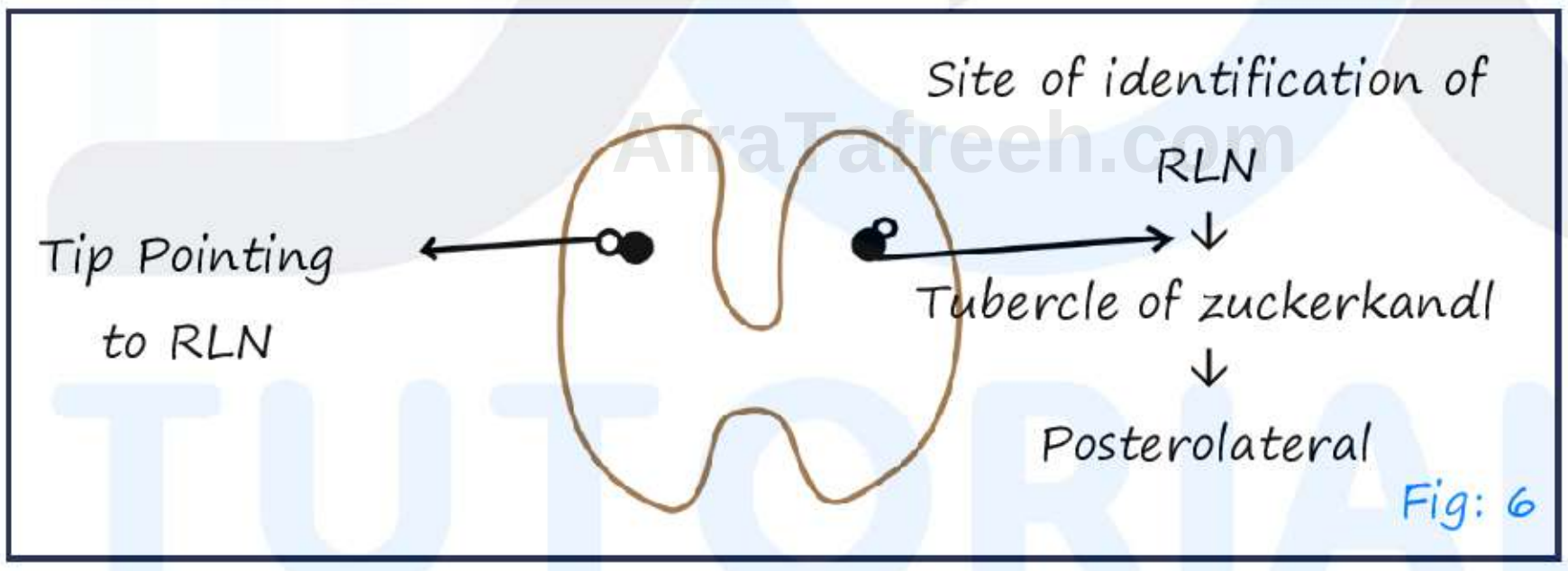

Fig: 6

Movement with deglutition 00:17:14

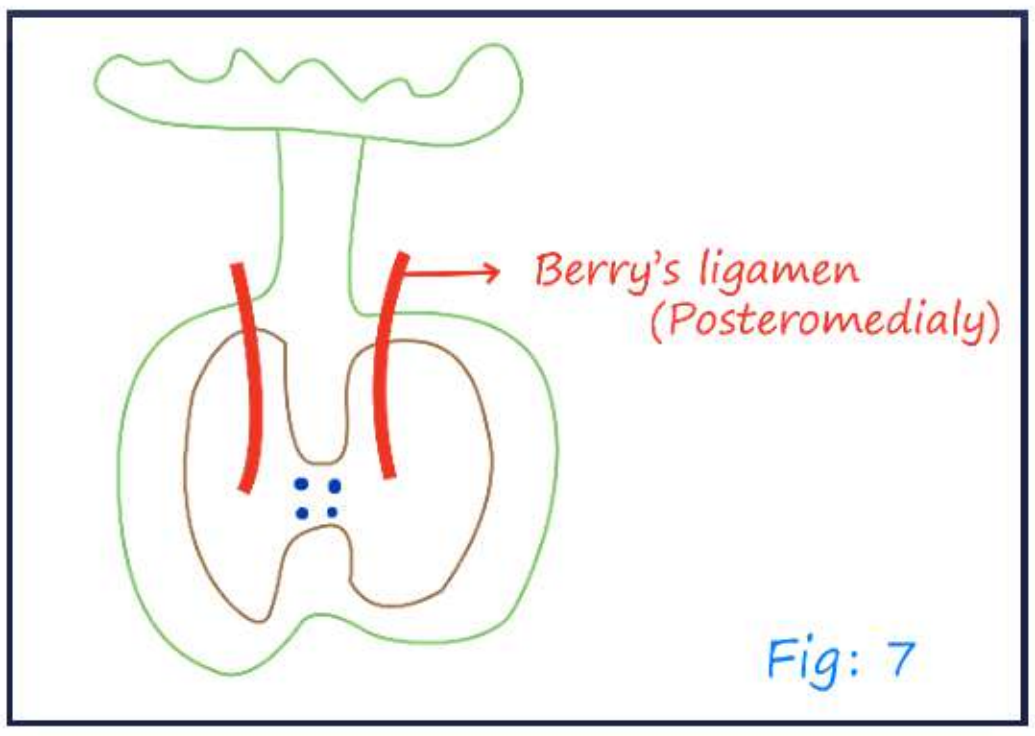

Fig: 7

- Thyroid gland surrounded by Pretracheal fasica

↓

AfraTafreeh.com

Attaches to hyoid bone

1. Pretracheal fascia
2. Direct attachment
3. Berry's ligament

} Reasons for movement of thyroid gland

One liner

- Most common of ectopic thyroid – Lingual thyroid
- Lateral aberrant thyroid (misnomer)

  ↓

  Mets from occult papillary cancer
- Arterial supply: - STA, ITA, Artery thyrodee Ima
- Veins supply: - STV, MTV, ITV, kocher's
- Most common of RLN injury – Beahr's triangle
- Most common nerve injured – ELN > RLN, ILN, Ansa cervicalis

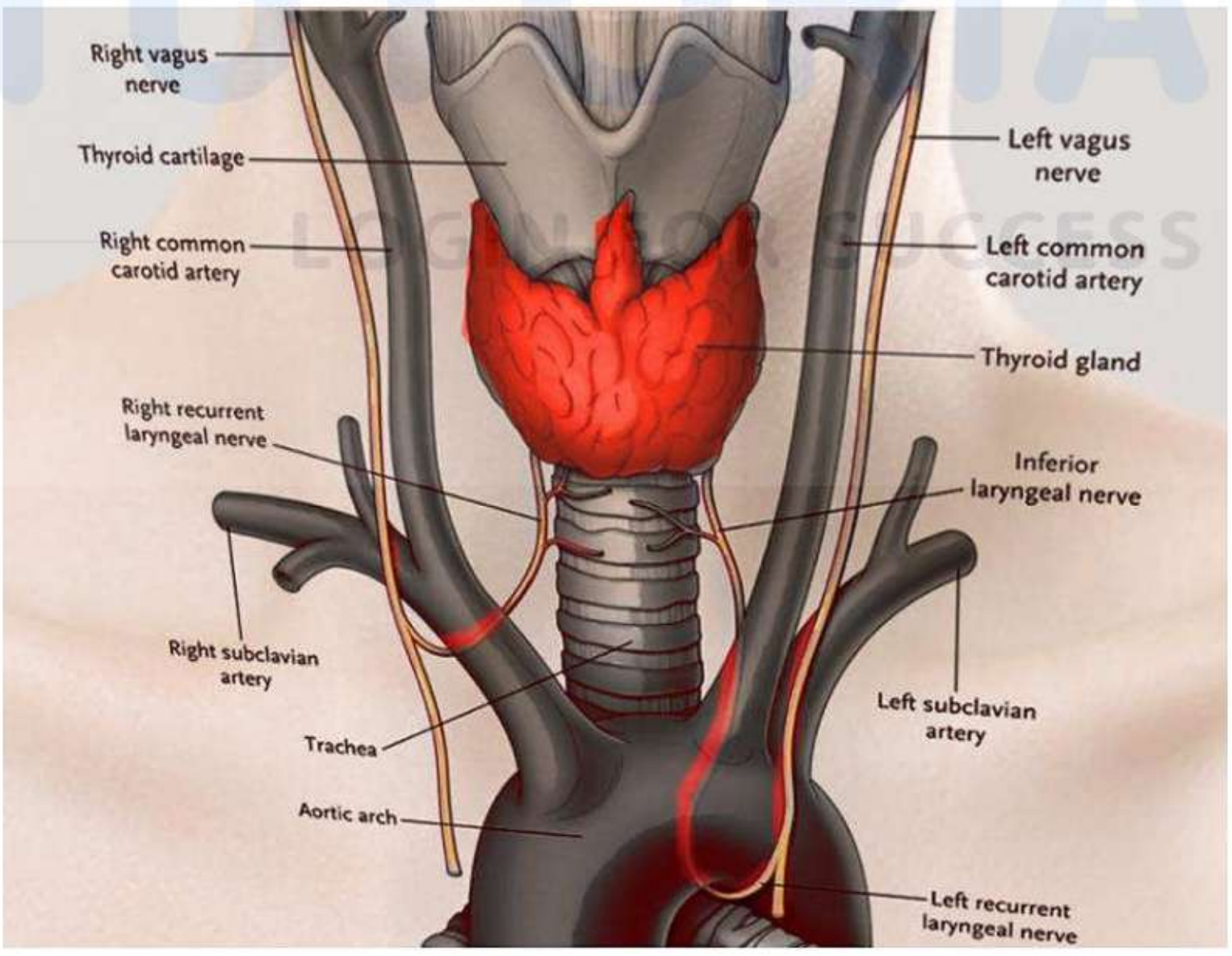

Fig: 8

Nerve Functions 00:22:42

- ILN – Sensation above VC
- RLN – Sensation below VC (all m/s of larynx)
- ELN – Tensor (Cricothyroid)
  - **IF PCA is injured → vocal cord is in cadaveric position**

AfraTafreeh.com
TUTORIALS
LOGIN FOR SUCCESS

AfraTafreeh.com

THYROID PHYSIOLOGY

Physiological aspects of thyroid 00:00:32

- RDA: - Iodine – 0.1-0.5 mg/day

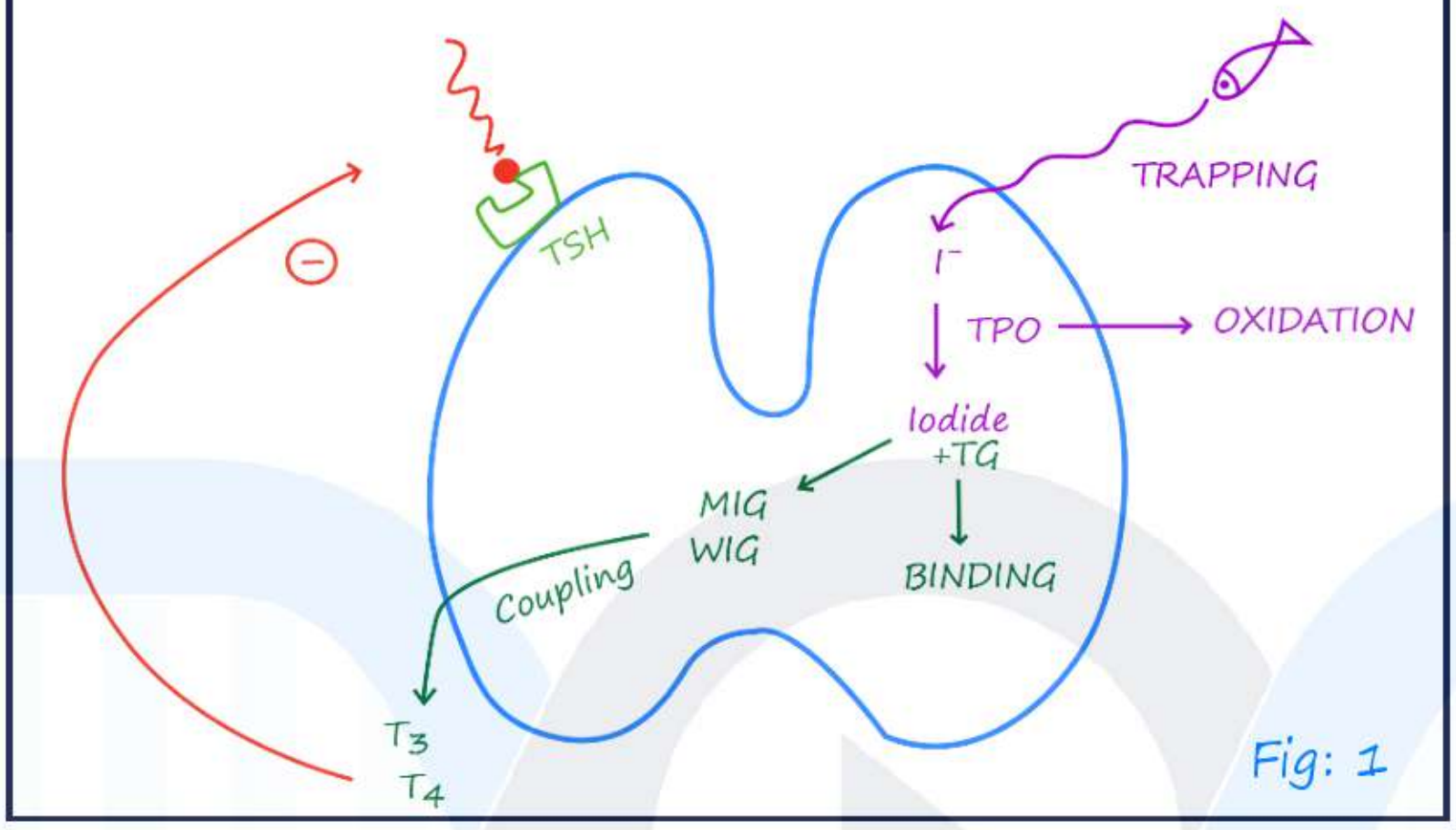

Fig: 1

- Trapping of Iodine
- Iodine oxidized to iodide by thyroid peroxidase enzyme – oxidation
- Iodide binds to thyroglobulin – Binding

↓

- Release of mono-iodoglobulin

↓ Di-iodoglobulin

- Coupling → release of T_3-T_4

↓

Feedback inhibition of TSH

Summary – Thyroid physiology
T – Trapping
O – Oxidation
B – Binding
C – Coupling

- T_3 half-life – 24 hours (Active form)
- T_4 half-life – 7 days
- In Periphery, $T_3 \rightarrow T_4$
- Deficiency of Iodine → Iodine deficiency goitre

↓

Most common of hypothyroidism (India)

- Congenital TPO deficiency → Pendred syndrome

↓

Congenital hypothyroidism and SNHL

AfraTafreeh.com

- Antibodies against TPO > TG > TSH-R

↓

Hashimotos thyroiditis

↓

Most common cause of hypothyroidism in western and worldwide

- Stimulatory → (other name → long-acting thyroid stimulator) antibodies against TSH, TG

↓

Graves d/s

↓

Most common cause of hyperthyroidism (worldwide)

TUTORIALS
LOGIN FOR SUCCESS

AfraTafreeh.com

Thyroid profile 00:06:32

- Free T_3: - 3-9 μ mol/L
- Free T_4: - 8-24 nmol/L
- TSH: < 3 mU/L
- Thyroglobulin → Tumor marker for follicular and papillary cancers
- TPO value → Hashimoto's

  ↓

  Anti-bodies against TPO, TSH-R, TG
- LATS – Graves disease

Hypothyroidism values 00:08:48

- Decrease T_3, T_4 decrease – TSH increase
- Ⓝ T_3, T_4 Ⓝ - TSH increase
- Early cases identify by free T_3 (decrease)

Hyperthyroidism values 00:09:40

- Increase T_3, T_4 increase – TSH decrease
- Ⓝ T_3, T_4 Ⓝ - TSH decrease
- Early cases identify by free T_3 (increase)
- Most sensitive indicator to identity hypothyroidism or hyperthyroidism – TSH

Refetoff syndrome 00:10:54

- Increase T_4 value, TSH Ⓝ/ increase
- Peripheral T_4 resistance ⊕

Hyperthyroidism causes 00:12:10

- Most common causes – Graves disease
- Jod Basedow toxicosis – Due to excessive consumption of iodides
- Iodides can cause feedback inhibition and cause hypothyroidism
  - Wolf Chaikoff Effect
- Thyrotoxicosis factitia – excess thyroxine consumption
- Hamburger toxicosis – thyroid gland of buffalo is consumed with burger
- Struma ovari
- Hydatiform mole
- Thyroiditis
  - Initially → toxicosis
  - Later → hypothyroidism

AfraTafreeh.com
TUTORIALS
LOGIN FOR SUCCESS

AfraTafreeh.com

INVESTIGATION OF THYROID

USG Neck 00:00:20

- TIRADS grading – Thyroid imaging and reporting data system

  ↓

  Based on

- C – Composition Gland
- E – Echogenicity
- S – Size of the gland
- M – Margin of the gland
- E – Echogenic foci

FNAC/FNNAC 00:01:59

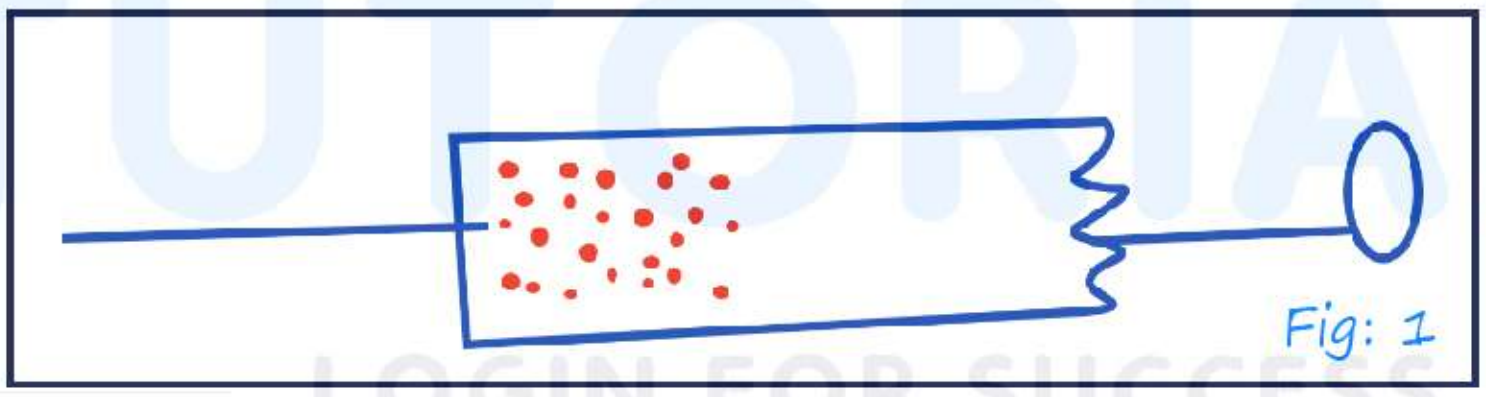

Fig: 1

- With fine needle tissue is aspirated
- FNNAC - Neddle is porked not aspirated

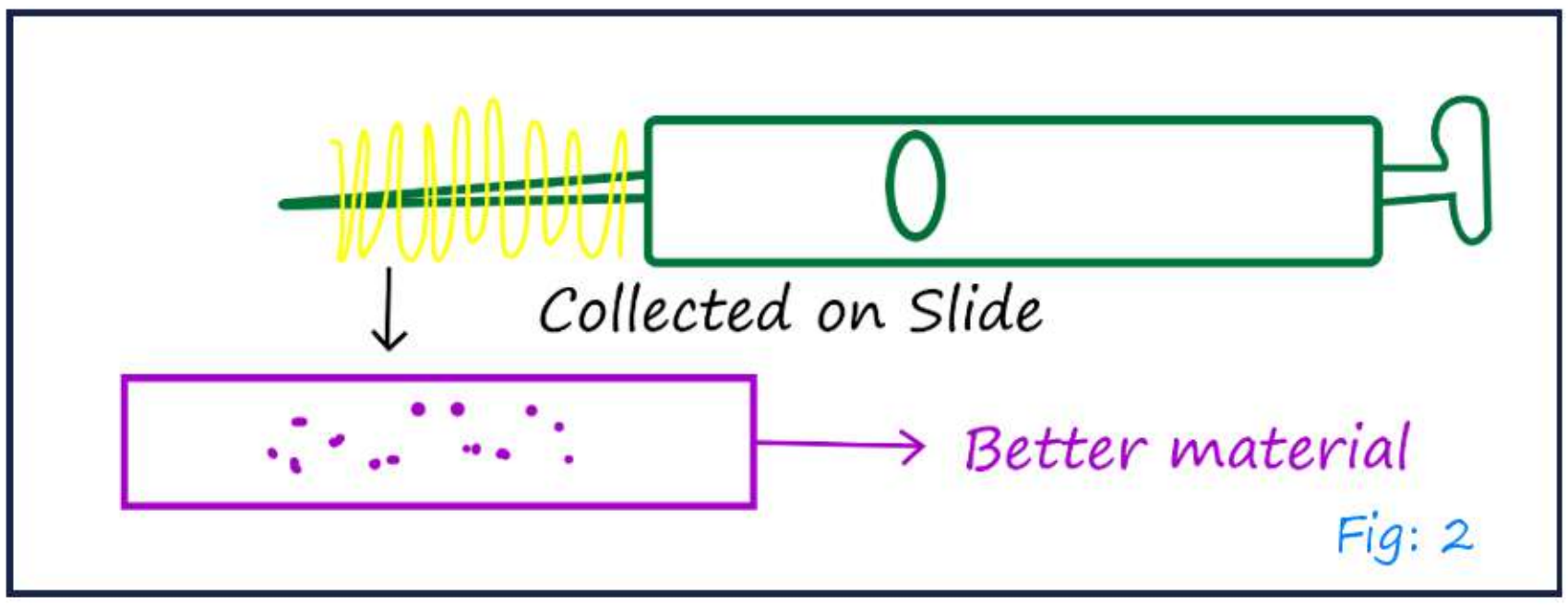

Fig: 2

Bethesda staging 00:03:12

- Thy 1 - Non diagnostic
- Thy 1c – Cystic lesion → Aspirate completely reaccumulates → aspiration can be done 3 times → surgery
- Indications for SX
  - Incomplete disappearance even after 3 times FNAC
  - Associated residual solid components ++
  - Malignant cells +
- Thy 2 – Benign
- Thy 3 – Follicular neoplasm
- Thy 4 – Suspicious of malignancy
- Thy 5 – Confirmed malignancy

AfraTafreeh.com

IDL scopy (Indirect Laryngoscopy) 00:06:09

- 3% have already Vocal Cord palsy

TUTORIALS
LOGIN FOR SUCCESS

RAIU study 00:06:43

- I 123 – 12-14 hours
- I 131 – 8days → Therapeutic
- I 132 – 2.5hrs
- TC 99m – 6 hrs
- The entire gland takes up radioactive iodine and emits β radiation
- Gamma camera is used to visualize (Thyroid scan)

AfraTafreeh.com

RAIU

Diagnostic

1. 16%: Hypo
   >48%: Hyper
   16-48%: (N)

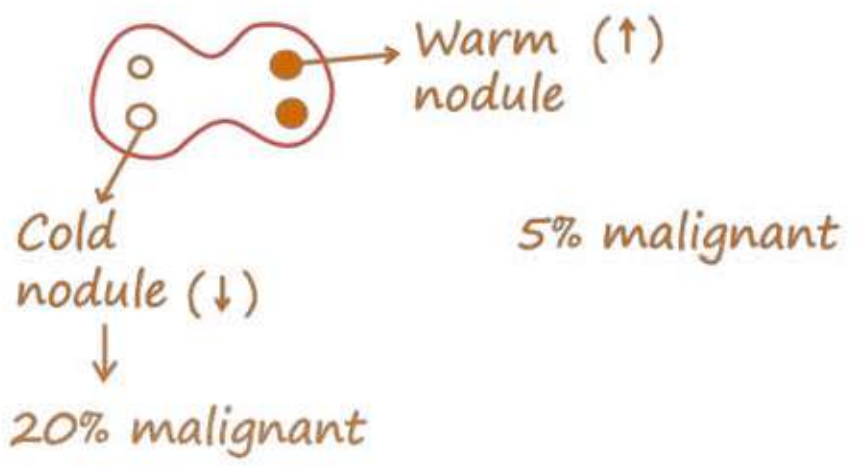

2.
3. To locate ectopic thyroid
4. To evaluate thyroglossal cyst (Children)
   - If (N) thyroid gland (+) cyst removed
   - If (N) thyroid gland cyst not removed (only functioning gland)
5. To look for metastasis (Only after total thyroidectomy)

Therapeutic

1. High dose to destroy mets are given
2. Rx of Graves' disease

TUTORIALS
LOGIN FOR SUCCESS

S/E

Immediate	Long term damage	Long term tumors
• Neck pain • Thyroiditis • Sialadenitis • VC paralysis • BM suppression • Cerebral edema	• Ovarian dysfunction • Testicular • Infertility • BM suppression • Pulmonary fibrosis • Hypo-parathyroidism	• Leukemia • Papillary Ca thyroid • Parotid tumors • Anaplastic cancers • Breast Ca • Gastric Ca • Bladder Ca • Lung Ca

AfraTafreeh.com

- Isolate the patient: 7 days
- Do not spit, Urinate, Kiss → In public places

TUTORIALS
LOGIN FOR SUCCESS

Hyperthyroidism

↑ RAIU
↓
↑ Secretion of gland

- Graves' disease
- 2° toxicosis
- Jod basedow effect
- Amiodarone
- Struma ovari
- Hydatiform mole
- TSH secreting pituitary tumor

↑ RAIU
↓
↑ Release
↓

- Thyroiditis
- Thyroiditis factitia
- Hamburger toxicosis

AfraTafreeh.com

C/I to use RAIU -

1. Severe ophthalmopathy
2. Pregnancy/Lactation
3. Children
4. Smoking females
5. Nodules (+)

- Graves's disease

↓

RAI therapy → 2 months – Euthyroid

6 months 50% euthyroid

50% Hyperthyroid/Hypothyroid

TUTORIALS
LOGIN FOR SUCCESS

CLINICAL ASPECTS OF THYROID

GOITRE 00:00:20

- Any thyroid swelling is known as Goitre. There four types of thyroid swellings: -
  - Diffuse
  - Nodular
  - Inflammatory
  - Neoplastic

Diffuse	Nodular
• Physiological	• Single nodular goitre
• Graves' disease	• Multi nodular goitre
• Colloid goitre	• Colloid goitre

AfraTafreeh.com

Inflammatory	Neoplastic
• Hashimoto's	• Papillary cancer
• Dequervain's	• Follicular cancer
• Reidel	• Hurthle cell Ca
• Acute infective	• Medullary cancer
	• Anaplastic cancer
	• Lymphomas

AfraTafreeh.com

Clinical Features 00:03:01

Hypothyroidism	Hyperthyroidism
• Obese	• Thin
• Loss of appetite	• ↑ of appetite
• Weight gain	• Weight loss
• Constipation	• Diarrhea
• Menorrhagia ↓ amenorrhea	• Amenorrhea • (Hypomenorrhea)
• Cold intolerance	• Heat intolerance
• ↓ Reflexes • (Delayed ankle jerk) -Hung up reflex -Pseudo-myotonic reflex	• ↑ Reflexes • Fine tremors
• O/E: - - Loss of lateral eyebrow - Macroglossia - Alopecia - Mask like facies	• O/E: - - Pretibial myxedema ↓ MPS deposition in front of tibia - Thyroid acrobachy (Late features) Subperiosteal resorption

TUTORIALS LOGIN FOR SUCCESS

Causes -	Types -
• Cretinism: - children • Myxedema: - Adults	• Graves (m/c) – 1° toxicosis + toxic features • 2° toxicosis -single nodule -multiple nodules →Plummer Vinson disease • Whenever toxic features seen, rule out CVS and CNS manifestations, eye signs
• m/c/c (India) – Iodine deficiency • m/c/c (West) – Hashimotos (world) • Wolf-Chaikoff effect (Rebound inhibition of thyroid production)	• Thyrotoxicosis factitia – excessive consumption of thyroxine
	• Jod Basedow toxicosis – excessive consumption of Iodide
	• Hamburger Toxicosis – due to eating of thyroid gland of cow and buffalo

AfraTafreeh.com
DOT TUTORIALS LOGIN FOR SUCCESS

AfraTafreeh.com

Toxicosis 00:13:04

- CNS Features
  - ↑ Tendon reflexes
  - ↑ Fine tremors in hand
  - ↑ Fasciculations

- CVS Features
  - Sinus atrial tachycardia (m/c)
  - AES (Atrial extra systole)
  - AF (Atrial fibrillation)
  - CCF (Congestive Cardiac failure)
  - Thyroid storm
  - Lerman scratch sound (2nd ICS Left side on expiration)

- **Eye signs**

  Exophthalmosis

  → In 1° toxicosis, CNS features and eye signs are more common (young age)

  → In 2° toxicosis, CVS features are more common (old age – compromised heart)

Hypothyroidism 00:16:28

- Supplement Iodine for most of the cases
- T. Thyroxine (25mg – 100mg)

  ↓

0.1 mg – Supplement therapy

0.2 mg – Substitution therapy

0.3 mg – Suppression therapy

↓

Papillary Ca Sx → TSH suppression

Clinical examination of thyroid 00:18:34

- Always examined from behind.

1.PIZZILO'S TEST

  - Short neck individuals
  - Both hands placed behind neck and do hyperextension of neck
  - Always examine lower border of gland.
  - If lower border is not visible → **Retrosternal Goitre** → can lead to SVC compression
  - Pemberton sign is +ve in SVC compression
  - From front 2 tests are done,
    - 3 finger examination – Lahey's
    - Thumb method used for any doubtful nodules → CRILE'S

AfraTafreeh.com

3 Finger Examination (Laheyl's test) — Thumb – Doubtful nodules Fig: 1

- Always look for common carotid artery pulse.

  ↓

  Palpate on superior border of thyroid cartilage.

  ↓

  Usually felt at the level of vertebra.

  ↓

  Chaissaigne's tubercle, against which artery is palpated.

- In case of malignancy, carotid artery is engulfed and not felt

  ↓

  BERRY SIGN

- Due to thyroid swelling on one side,

  Trachea is pushed and sternocleidomastoid Felt prominently.

  ↓

  TRIAL'S SIGN

Eye signs 00:27:17

- Exophthalmos
  - Should examine from supraciliary from above downwards

    ↓

    Eyeball prominent – NAFFZIGER'S TEST
  - Eversion of upper eyelid – GIFFORD TEST

    ↓

    Possible in proptosis and not possible in exophthalmos
- In proptosis – Pathology is behind eyeball
- In exophthalmos – Pathology in eyeball

  – Muller's muscle spasm
- Mild exophthalmos

  1.Von graefe sign – Lidlag sign

  2.Dalrympte's sign – Lid retraction – visible upper sclera

  3.Stellwag's sign – Starring look
- Moderate exophthalmos

  4.Joffroy's sign – Absent wrinkle forehead
- Severe

  5.Moebius sign – Inability to converge eyeballs

  6.Jellinek's → Pigments + upper eyelids
- Malignant exophthalmosis
  - Epiphora
  - Congestion
  - Redness
  - Paralysis of muscles.

AllaTalleeh.com TUTORIALS LOGIN FOR SUCCESS

AfraTafreeh.com

GRAVES DISEASE

Grave's disease

- 1° hyperthyroidism
- Diffuse toxicosis
- Most common in young females
- Associated with autoimmune disease – HLA B8, HLA DR_3, HLA-DQ_1
- Autoantibodies are produced against → TG, TPO, TSH-R (LATS*)

Clinical features 00:01:41

- CNS features
- Eye signs
- On examination – soft consistency

Thrill + (superior outer pole)

\+

Bruit-superior thyroid artery

Venous hum++

Diagnosis 00:03:12

- T_3, T_4 ↑
- TSH ↓
- Long-acting thyroid stimulatory antibodies positive

↓

Anti TG, TPO, TSH-R → ↑75%

- FNAC not beneficial since haemorrhagic aspiration can occur
- RAIU study > 48% uptake

↓

Thyroid scan

↓

Diffuse uptake

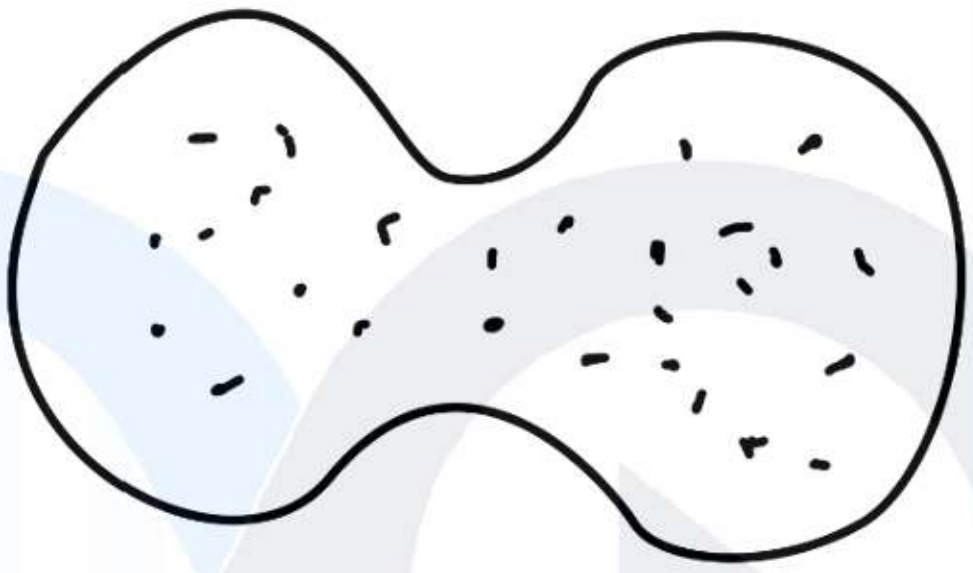

Fig: 1

AfraTafreeh.com
TUTORIALS
LOGIN FOR SUCCESS

Approach to the patient 00:05:10

Approach to the patient

↓

Prepare to euthyroid state

↓

Antithyroid drugs

+ Beta blockers

+ Lugol's iodine

↓

Euthyroid

- RAI therapy (I-131)
- Surgery

AfraTafreeh.com

Anti-thyroid drugs 00:06:40

1.Carbimazole: - 10mg TDS → cross placental barrier

→ (C/I in preg.)

↓

Inhibits

- Trapping of iodine
- Oxidation of iodine to iodine

2.Propylthiouracil: - DOC in pregnancy

↓

Inhibits

- Trapping
- Oxidation
- Peripheral conversion of $T_4 \rightarrow T_3$

- Agranulocytosis: Look for WBC count decrease

History of sore throat

↓

Stop carbimazole (methimazole) →PTU

↓

3 months minimum to become euthyroid

TUTORIALS LOGIN FOR SUCCESS

Block and replacement therapy 00:09:44

- High dose carbimazole + thyroxine as supplement
- Help in Yearly preparation of patient

Quick preparations 00:10:54

- β-blockers – decrease sympathetic activity

↓

T. propranol 40mg TDS

Now

T. Nadalol 160mg OD (long active)

↓

1 month

- last 10 days → Lugol's iodine

↓

10% KI

5% Iodine

↓

10 drops TDS

↓

Gland firm/ less vascular

RAI Therapy 00:13:20

- Female with a euthyroid status

↓

RAI therapy – gold standard

↓

I-131 (8 days)

Oral route

Isolate 8 days

↓

2 months: – Euthyroid

6 months: – 50% euthyroid

50% Hypo/ hyper-thyroidism

Clinical features for RAI therapy –

1.Pregnancy

2.Lactation

AfraTafreeh.com

3.Children

4.Severe ophthalmopathy

5.Smoking females

6.Nodules present in graves

- **Surgery**: - Subtotal/ total thyroidectomy

Indications for surgery -

1.RAI is C/I

2.Suspect a cancer

3.> 80 gm size

4.Compressive symptoms

5.Not responding to RAI

6.Want immediate relief

Thyroid storm 00:18:07

- Most common cause – Inadequate preparation

↓

RAI therapy

Surgery

- Clinical examination of Graves

  - Stress
  - Illness
  - Amiodarone drugs
  - Rough handling of thyroid

DOC TUTORIALS LOGIN FOR SUCCESS

Characterised by

- CVS problems: -
  - Atrial fibrillation
  - Congestive cardiac failure
- CNS problems
  - Agitation (10% mortality)
  - Depression

Clinical features -

- Tachycardia
- Hyperpyrexia
- Dehydration
- Breathlessness
- Atrial fibrillation
- Hyper excitability

↓

Admit in ICU

Basic supports	Antithyroid drugs
Nasal O_2 Tepid sponging IV fluids IV glucose	IV Propranolol Lugol's iodine Propylthiouracil/ carbimazole Potassium iodine IV

AfraTafreeh.com
TUTORIALS
LOGIN FOR SUCCESS

AfraTafreeh.com

Failures-

- Steroids – DEXA (adrenals are exhausted)
- Diazepam
- Digitalis   " **4D → 10% mortality** "
- Diuretics

Secondary toxicosis 00:23:50

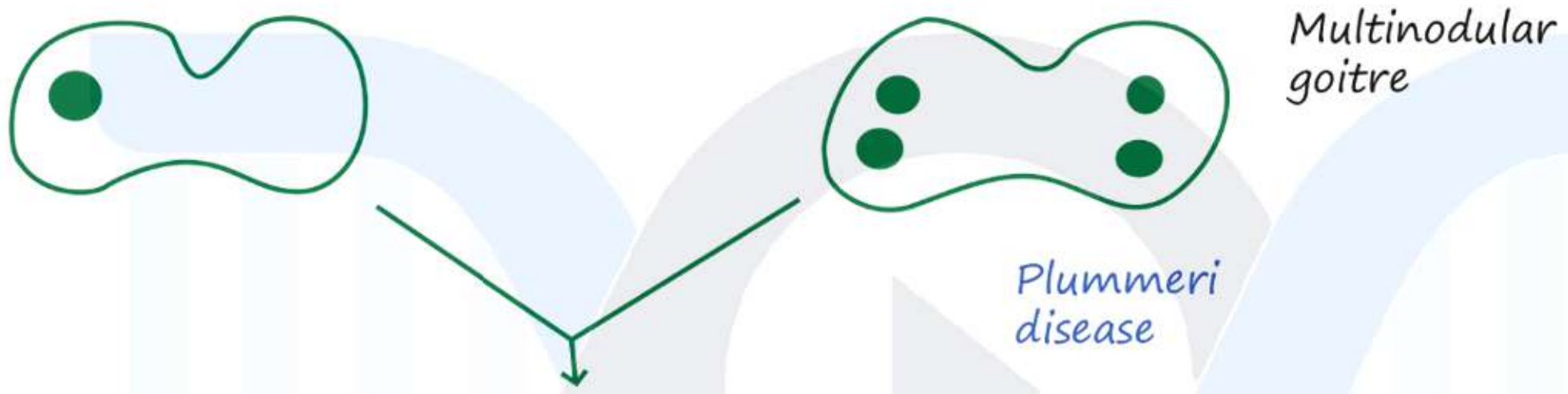

Fig: 2

- Most common – old age
- Most common – CVS issues
- Eye
  - Lid lag
  - Lid retraction

↓

Prepare them to euthyroid

↓

Don't use RAI

↓

Only treatment: - Surgery (Subtotal/ total thyroidectomy)

- Nodules – Not respond to RAI
- RAI scan – detects warm/ cold nodule

MISCELLANEOUS OF THYROID

Thyroiditis

- Inflammation of thyroid gland

Types of Thyroiditis 00:00:16

1.Hashimoto's

2.Reldel's

3.Dequervain's (Subacute, post viral inflammatory)

4.Acute (Bacterial)

Hashimoto's Thyroid 00:00:55

- Also known as – Lymphocytic thyroiditis
  - Auto immune thyroiditis
- Most common type
- Most common in females
- Most common cause – hypothyroidism
- Develop autoantibodies against
  - TPO (most common)
  - TG
  - TSH-R
- FNAC – Hurthle cells ++ (Ashkenazy)
  Lymphocytes ++
- Clinical features – Pain
  - Transient hyperthyroidism f/b hypothyroidism

AfraTafreeh.com
TUTORIALS
LOGIN FOR SUCCESS

AfraTafreeh.com

- Compressive symptoms

- Treatment – Pain killer
  - Steroids
  - T. Thyroxine
  - No surgery
- Surgery is indicated
  ↓
  Compressive symptoms
- Complication – compressive symptoms
  - premalignant
    ↓
    lymphoma
    Papillary

Reidel's Thyroiditis 00:05:46

- Fibrosing thyroiditis
- A/W → Dupuytren's contracture
  Retroperitoneal fibrosis
- FNAC is difficult
- Clinical features – Woody hard consistency
  Malignancy like clinical features seen
  Always hypothyroidism (Q)
  Compressive symptoms present
- Treatment – T. Thyroxine
  Steroids
  Tamoxifen
  Mycophenolate mofetil

TUTORIALS LOGIN FOR SUCCESS

Dequervain's - 00:08:14

- Associated with HLA B_{35}
- Predominantly Hyperthyroidism
- Mimics like Graves

↓

Differentiated by radioactive iodine study

- Graves ↓ Increased
- Dequervain's ↓ Decreased

- ESR increases

Acute Thyroiditis 00:10:51

- Bacterial thyroiditis – most common streptococcal
- No HLA association
- Persistent pyriform sinus fistula

  ↓

  Recurrent thyroiditis
- Clinical features – Severe neck pain

  Fever + swelling

  Increases white blood cells
- Complications – Laryngitis

  –Tracheal rupture

  –Perichondritis

  –Sepsis

  –IJV Thrombus

  –Esophageal rupture

TUTORIALS LOGIN FOR SUCCESS

AfraTafreeh.com

- Treatment – Antibiotics

  Post inflammatory – steroids

  Surgery

  ↓

  Pyriform sinus fistula should be removed.

Mediastinal Goitres 00:14:50

Divided into 2 types

Primary (1%)

↓

- Arises from ectopic thyroid in the anterior mediastinum
- Blood flow – Intra thoracic veins
- Sternotomy

Secondary (99%)

↓

- Retrosternal extension goitre
- Superior and inferior thyroid artery
- Treatment – Neck incision → TÖBOGAN MANUEUVER
- SVC compression

  ↓

  Pemberton sign

TUTORIALS LOGIN FOR SUCCESS

- IOC – CECT neck/thorax
- Retrosternal goitre → Indications for sternotomy

  ↓

  1. Neck surgery done cases
  2. Posterior mediastinum
  3. Recurrent retrosternal goitre
  4. Receives blood flow from mediastinum vessels
  5. Adhesions in mediastinum

Thyroglossal Cyst 00:20:40

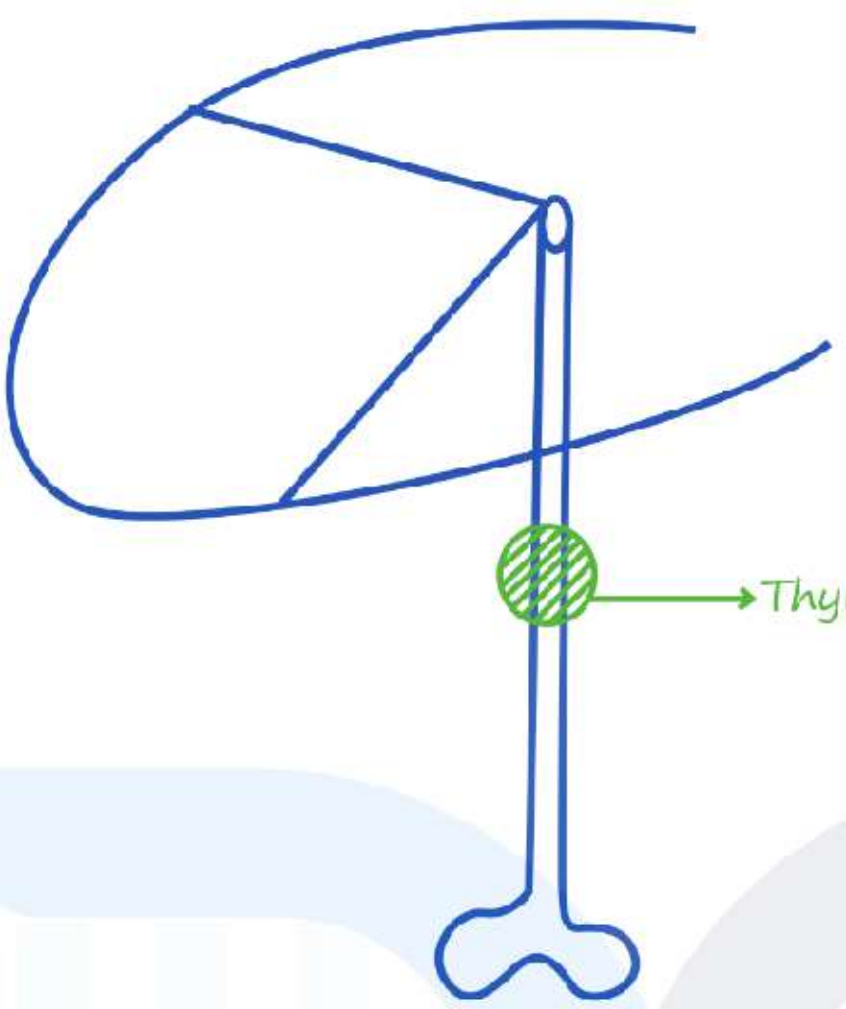

Fig: 1

- Persistance of tract results in Thyroglossal cyst.
- Most common in 6-20 years.
- Most common in females.
- Congenital
- Most common position – subhyoid position
- Moves with protrusion of tongue
- Transillumination – Negative

AfraTafreeh.com
TUTORIALS
LOGIN FOR SUCCESS

Complications

1. Infection – Acquired TG fistula
2. TG fistula – Always acquired
3. Papillary cancer

- IOC – USG neck

AfraTafreeh.com

- Pediatric cases – RAIU study → normally thyroid gland with

Normal functioning gland not seen
↓
will not do excision
(CRETINISM)

thyroglossal cyst
↓
Excision of cyst

- No need of RAIU study in adults.
- Treatment – **Sistrunk operation**

↓

Central part of hyoid bone excised

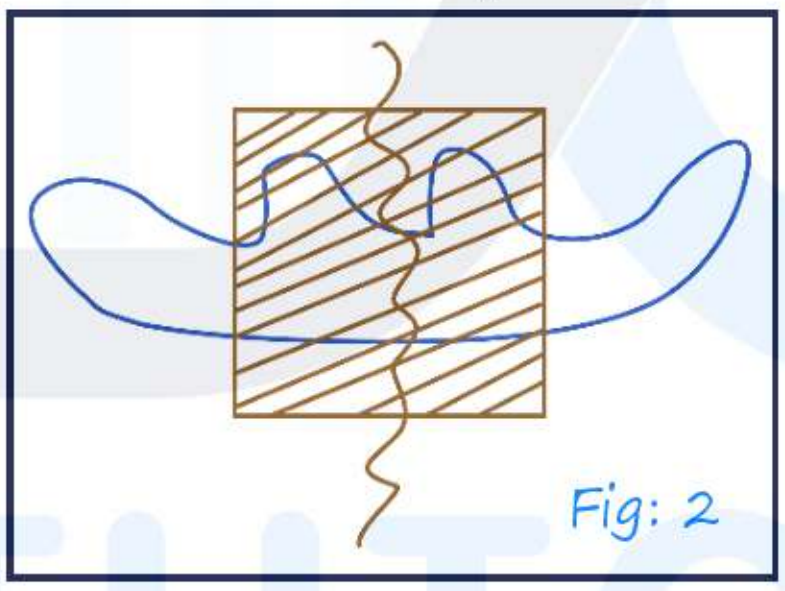

Fig: 2

Thyroid Cyst 00:26:26

- Thy 1c in FNAC
- Complete aspirated and analysis
- Indications for treatment

1.Incomplete disappearance

2.Associated solid components ++

3.Hemorrhage ++

4.Malignant cells ++

5.Reappearing after ≥ 3 times aspiration

6.Size of Cyst > 4cm

THYROID CANCER

Dunhill Classification 00:00:20

Dunhill Classification

- Well differentiated
  ↓
  1. Papillary Ca thyroid (80%)
  2. Follicular (10%)
  3. Hurthle
- Undifferentiated
  ↓
  - Anaplastic Ca (5%)
  - Lymphoma (2.5%)
- Medullary cancer
  ↓
  parafollicular 'C' cells
  ↓
  Ultimobranchial body (2.5%)

AfraTafreeh.com
TUTORIALS
LOGIN FOR SUCCESS

Predisposing Factors -

- Follicular cancer → Long standing multinodular goitre
- Papillary cancer → Irradiation
  Hashimoto's
  Thyroglossal cyst
- Lymphoma → Hashimoto's
- Medullary Ca thyroid → RET oncogene (MEN IIa, IIb)

Genetic Predisposition

- RET oncogene – MCT
- Ras oncogene – Follicular > Papillary
- PTEN mutation – Follicular

Syndromes -

1. Cowden disease
2. FAP

AfraTafreeh.com

3.MEN 2A, 2B

4.Carney's triad

5.Most common cune Albright syndrome

MEN 2A
↓
- 100% - MCT
- 40% - Pheochromocytoma
- 20% HPT
- Hirschsprung ++

↓
Prophylactic total thyroidectomy < 5 years

MEN 2B
↓
- 100% - MCT
- 40% - Pheochromocytoma
- M – Mucosal neuromas
  M – Marfanoid features
  M – Megacolon (ganglioneuromas)

↓
Esophageal dysmotility
↓
Prophylactic total thyroidectomy < 1yr

TNM staging 00:08:10

T_{1a} – < 1cm

T_{1b} – 1-2 cm

- T_2 – 2-4 cm
- T_3 – > 4cm, muscles + soft tissue
- T_{4a} – Removable

  RLN, trachea, larynx, esophagus
- T_{4b} – Non removable

  CCA, mediastinum, prevertebral fascia
- Nodes

  N_{1a} – Level '6' (Delphian)

  N_{1b} – Any other nodes
- M_1 – Mets +

TUTORIALS LOGIN FOR SUCCESS

Papillary cancer	Follicular cancer
• Most common – 80%	• Most common in iodine deficient areas – 10%
• Multifocal & 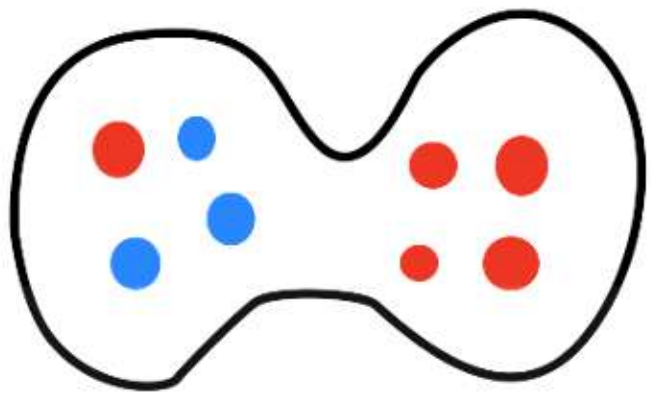 multicentric (B/L)	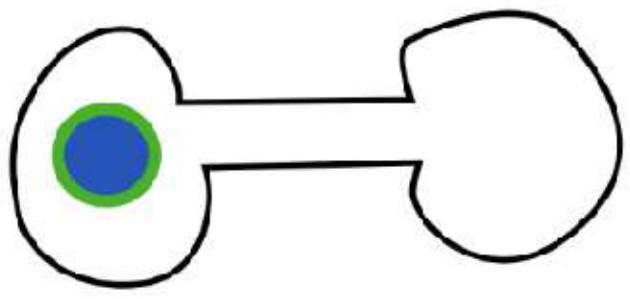 • Solitary lesion
• Capsule +/–	• Capsule +
Properties	
– most common – Lymph nodes + ↓ Lateral aberrant thyroid (metastatic node) ↓ Occult papillary cancer – Distant mets – lungs	– Most common – Hematogenous spread ↓ Distant – skull Pulsatile ++ Osteolytic nature
FNAC	
– – Pale empty orphan annie nuclei	– FNAC is inconclusive If vascular & capsule invasion + → malignancy

AfraTafreeh.com
DOC TUTORIALS
LOGIN FOR SUCCESS

AfraTafreeh.com

 – concentric calcifications k/as Psammoma body – Papillary projections	
Predisposing factors	
• Hashimoto's • Thyroglossal cyst • Irradiation	• Long standing MNG
Prognosis	
• Excellent – 90% - 10 year survival	• Good
Management	
Total thyroidectomy Nodes + → MRND (functional)	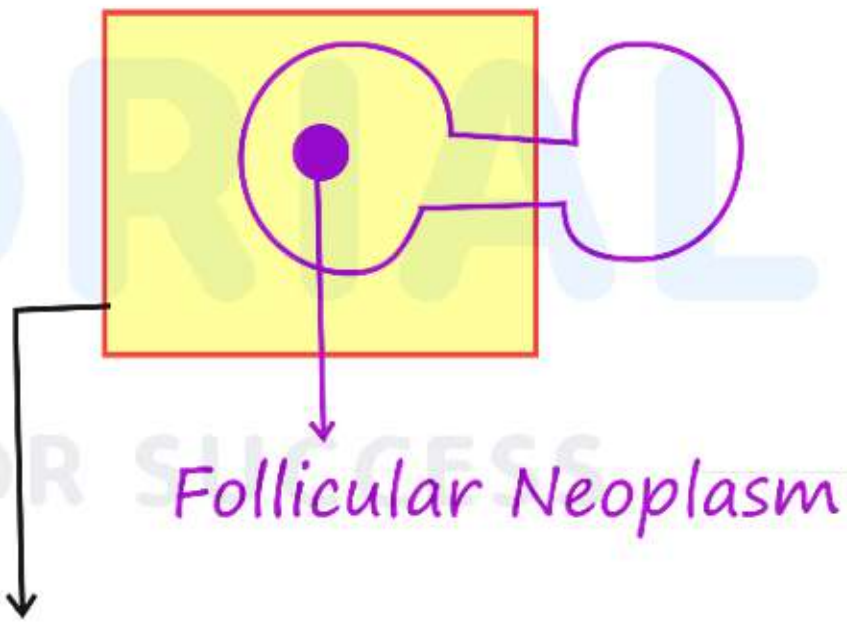 Hemithyroidectomy ↓ HPE ↓ 3 days → Not malignant ↓ ↓ Malignant procedure is over ↓

TUTORIALS
LOGIN FOR SUCCESS

	Complete Total thyroidectomy

Post Op Period

- Look for metastasis – RAIU study – Thyroid scan
  ↓
  Done after total thyroidectomy
  ↓
  METS +
  ↓
  High doses of I-131
- Papillary Ca thyroid → TSH suppression
  ↓
  T. Thyroxine 0.3 mg tablets
- Metastatic work up tumor marker – Thyroglobulin

AfraTafreeh.com

Papillary Cancer Scoring System 00:23:50

AGES

AMES

MACIS

Scoring System	Low risk	High risk
• A – Age	< 40 years	> 40 years
• G – Grade	well differentiated	Poorly differentiated
• E – Extent	confined	Out of capsule +
• S – Size	< 2cm	> 4 cm
• S – Sex	Female	Male

AfraTafreeh.com

• M – Mets	X	✓
• C – Completeness of surgery	Complete removal (Ro section)	R_1 resection + R_2 resection +
• I – Intrathyroidal (vascular +)	X	✓

- R_0 resection – No microscopic evidence of tumor
- R_1 resection – Microscopic evidence of tumor
- R_2 resection – Macroscopic evidence of tumor

Hurthle Cell Cancer 00:28:06

- Rare variant of follicular cancer
- FNAC cannot differentiate
- Malignancy based on capsular invasion
- Clinical features
  - Oxyphil cells in thyroid
  - Not take RAI
  - Multicentric/Multifocal
  - LN mets
  - Bad prognosis (20% mortality in 10 years)
- Treatment
  - Total thyroidectomy + central neck node dissection

↓

Level 6 nodes on both sides

DOC TUTORIALS LOGIN FOR SUCCESS

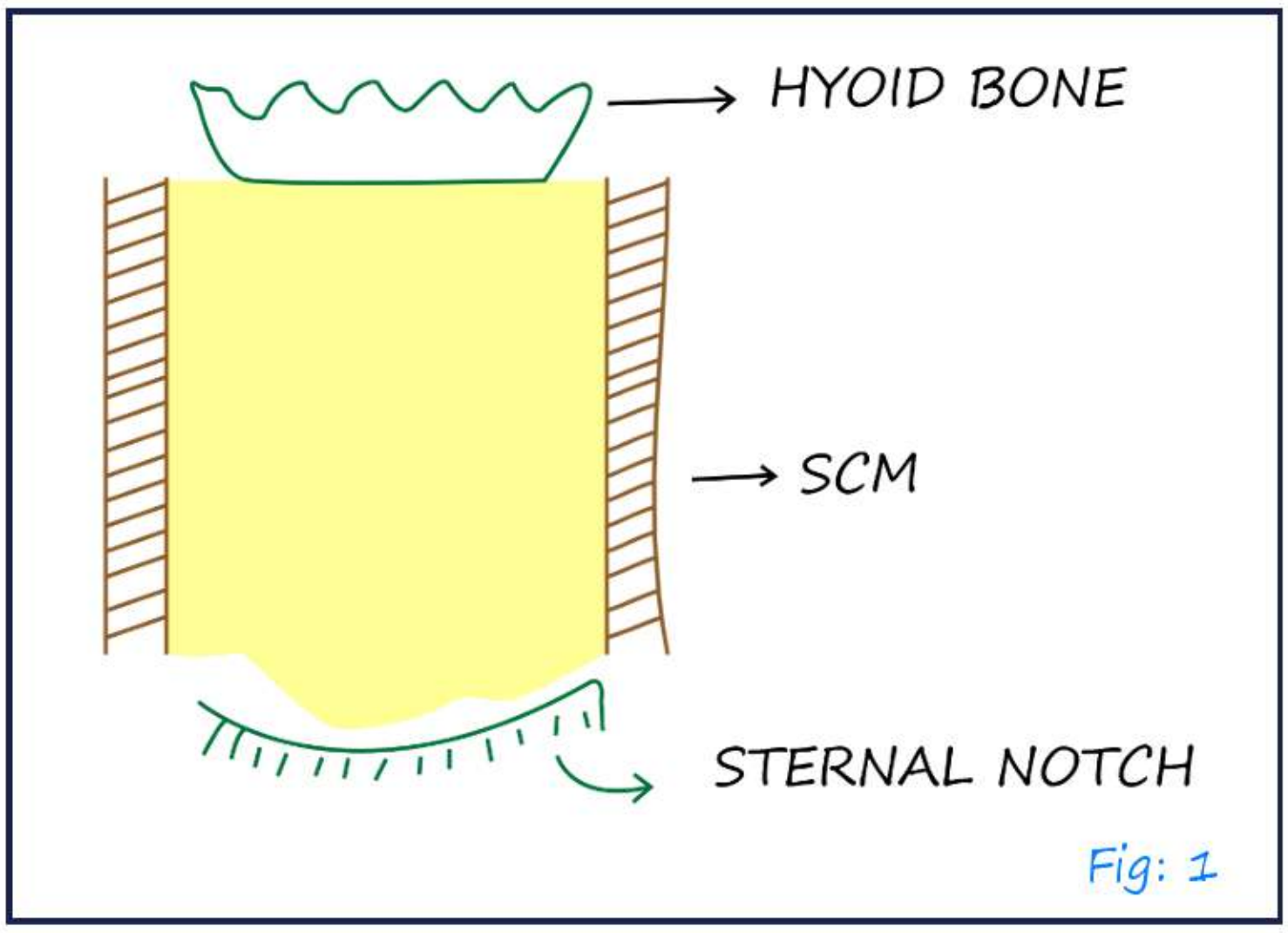

Adjuvant Therapies 00:31:14

a. RAI ablation

↓

mets + → 100 mci

AfraTafreeh.com
TUTORIALS
LOGIN FOR SUCCESS

Indications

1. Mets
2. Extra capsular spread
3. size > 4cm
4. LN mets
5. Papillary cancer
   - Inular
   - Tall cell
   - Columnar

b. External beam radiotherapy (EBRT)

↓

Bony mets

↓

Follicular cancer

AfraTafreeh.com

c. Chemotherapy

↓

Doxorubicin

Paclitaxel

d. TSH suppression

↓

3 tablets 0.3 mg

↓

Papillary cancer

Medullary Cancer 00:33:48

- Incidence – 2.5%
- Originates – Parafollicular 'C' cells

Sporadic (80%)
↓
- Most common
- U/L

Familial (20%)
↓
MEN 2A, 2B
↓
- Multicentric
- Multifocal
- B/L

NET

Calcitonin
↓
Follow up tumor marker
↓
>0.08 ng/ml
↓
recurrence

CEA
↓
Prognosis

ACTH
↓
Cushing syndrome

serotonin
↓
Diarrhea

- PGE_2
- $PEF_{2\alpha}$
- Histamine

Clinical Features

- Look for HTN → R/O pheochromocytoma

↓

24 hrs urinary VMA/ metanephrines

↓

\+

↓

Operate pheochromocytoma first then total thyroidectomy + central neck node dissection

Investigations

FNAC → Amyloid stroma ++

↓

TT + CND ± MRND

- Most common site of distant mets – Liver
- MAB
  - EGFR Ab – Vandetanib
  - Anti CEA Ab – Labetuzumab
- Prophylactic thyroidectomy
  - Men 2A → < 5 years
  - Men 2B → < 1 years

AfraTafreeh.com

Anaplastic Cancer 00:40:26

- P_{53} mutation
- Most common old age
- Most common in female
- Bad prognosis

AfraTafreeh.com

- Aggressive growth
- FNAC not useful
- For diagnosis – TRUCUT BIOPSY
- Clinical Features – Stridor (Biopsy not proven) →26th Edition Bailey

  ↓

  Isthumectomy

  Tracheostomy

- Biopsy proven cases → Die peacefully (27th Edition bailey)

Mets to thyroid

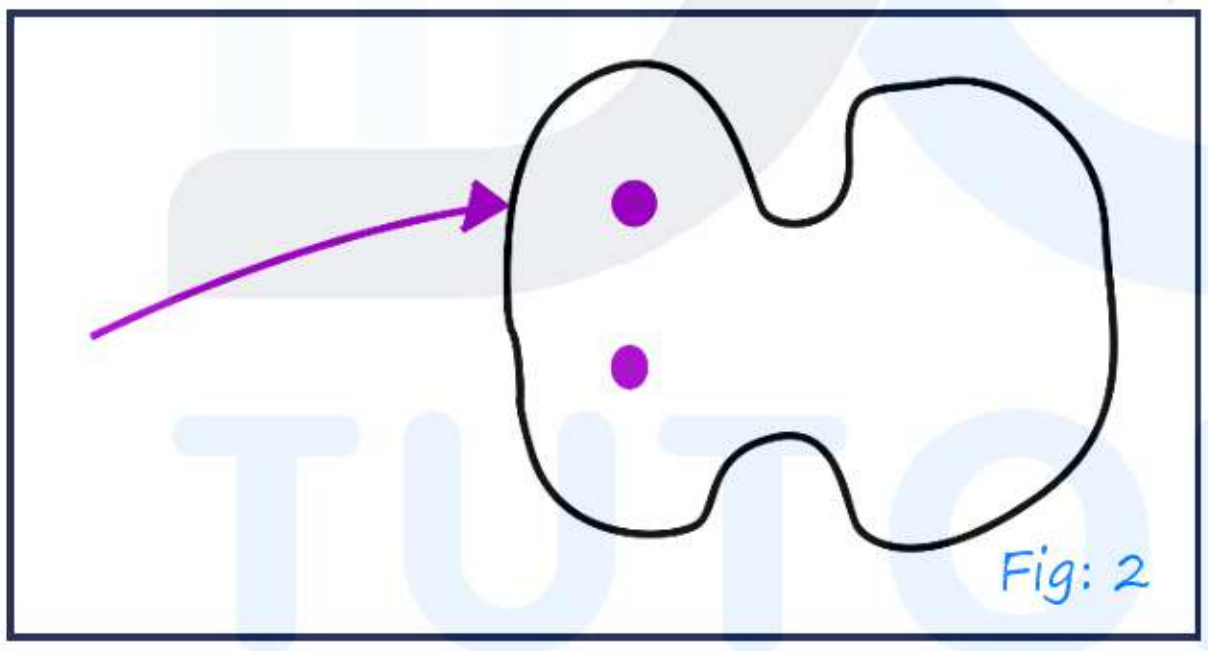

Fig: 2

- Most common primary – Breast cancer

  Males – Lung cancer

- NHL – most common old men

  Chop therapy

  ↓

  - Cyclophosphamide
  - Hydroxyadriamycin
  - Oncovin
  - Prednisolone

TUTORIALS LOOK FOR SUCCESS

Follow up 00:43:56

- Thyroglobulin < 5 ng/mL ⎤
- Calcitonin < 0.08 ng/mL ⎦ 3-6 monthly
- CEA
- USG neck – 6 months once for 1 year
  - 12 months once for 5 years

- If thyroglobulin >15ng/mL

  ↓

  RAI uptake study

  No mets seen

  ↓

  PET CT scan → Indications
  - Increases TG
  - USG N
  - RAIU N

Summary

Cancer	Most common distant mets	Treatment
• Papillary	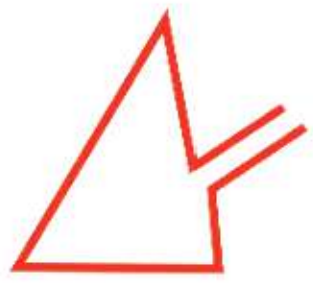	TT ± MRND
• Follicular		Hemi → TT completion

AfraTafreeh.com

AfraTafreeh.com

• Hurthle		Oxyphil cells, high mortality → TT + CND
• Medullary		TT + CND ± MRND
• Anaplastic		B_x proven – No R_x

TUTORIALS
LOGIN FOR SUCCESS

THYROID SURGICAL ASPECTS

Types of Thyroidectomy 00:00:18

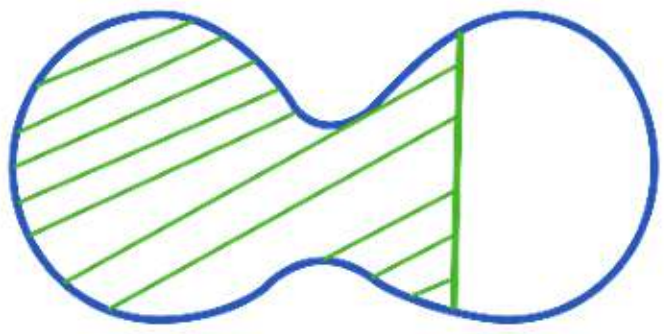

Removal of one lobe of gland with isthmus
↓
Lobectomy
(or)
Hemithyroidectomy

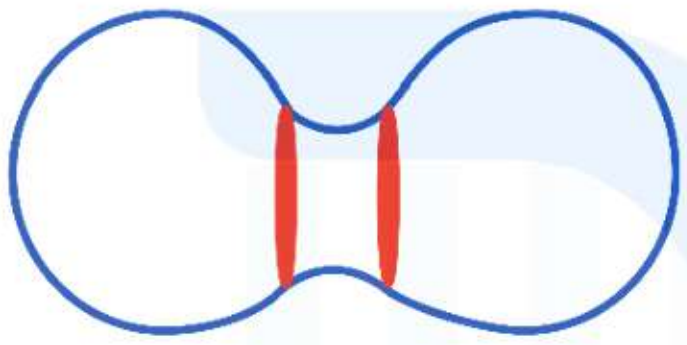

8 grams of tissue left on both sides of tracheoesophageal groove and rest of the gland removed
↓
Subtotal thyroidectomy
↓
To prevent parathyroid gland blood supply (main reason)
↓ incidence of RLN

AfraTafreeh.com

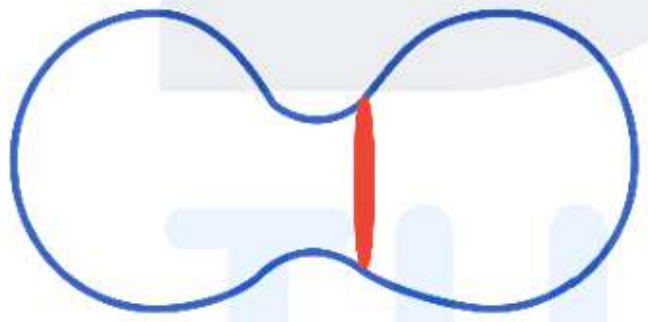

2-4 gram of tissue left on one side
↓
Near total thyroidectomy
↓
Hartley Dunhill Procedure

TUTORIALS
LOGIN FOR SUCCESS



Total thyroidectomy

AfraTafreeh.com

Steps in Thyroidectomy 00:03:00

1.Position

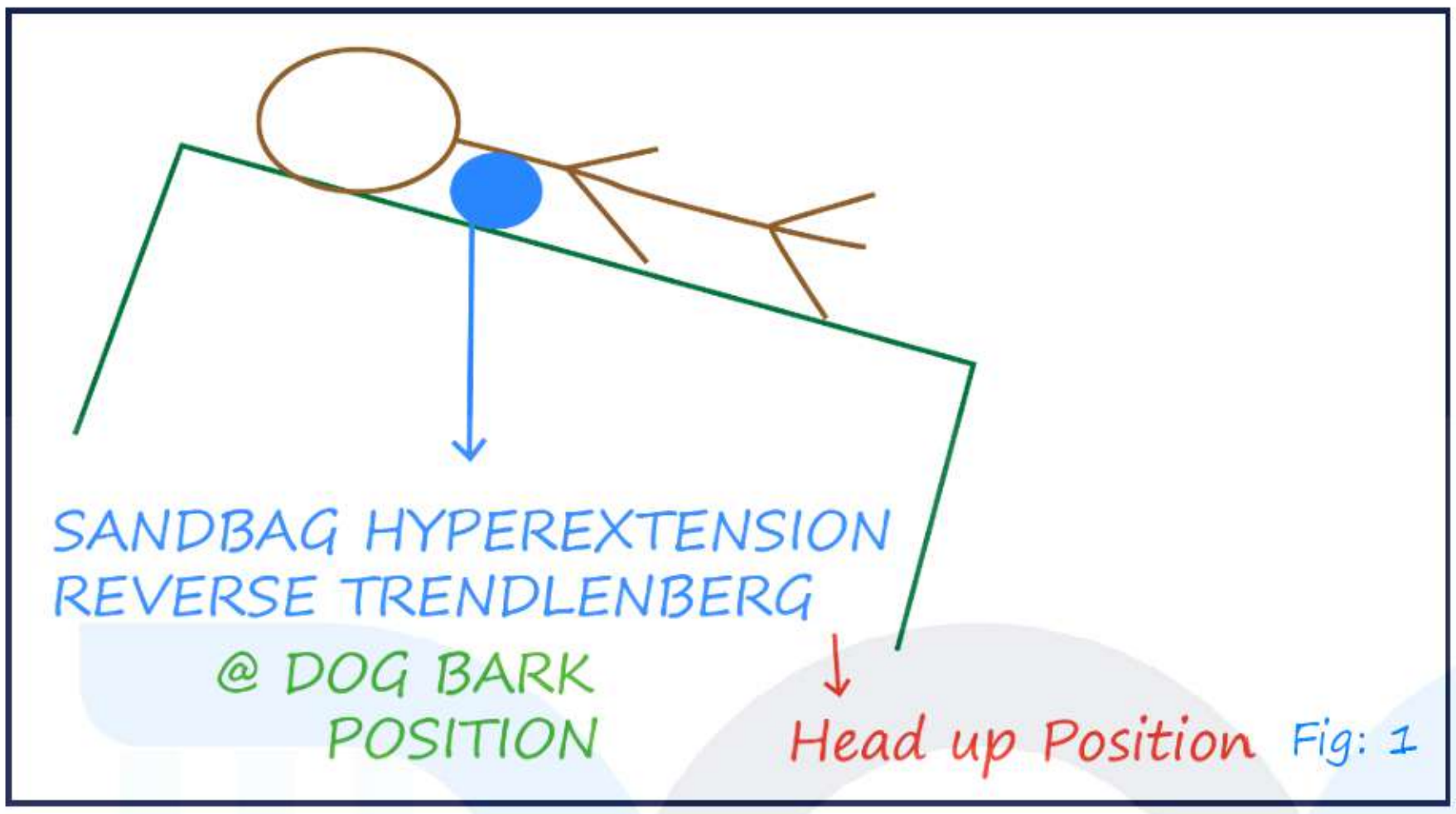

Fig: 1

2.Skin crease raise sub platysma flap

↓

Flap raised above hyoid and below sternal notch

↓

Joules self-retaining retractor

(Skin stiches)

3.Deep fascia (pretracheal fascia)

4.Strap muscles – retract

↓

Cut → Ansa cervicalis nerve may be injured in lateral retraction

5.Ligate

i. Middle thyroid vein

ii. Superior thyroid artery/superior thyroid vein

↓

Close to gland to avoid injury to ELN

iii. Inferior thyroid artery/Inferior thyroid vein

↓

Close to the gland (RLN injured)

↓

To preserve parathyroid supply

iv. Kocher's vein, arteria thyroidee ima

v. Yellow colored solid tissue – If it sinks – PT gland

Saline float test

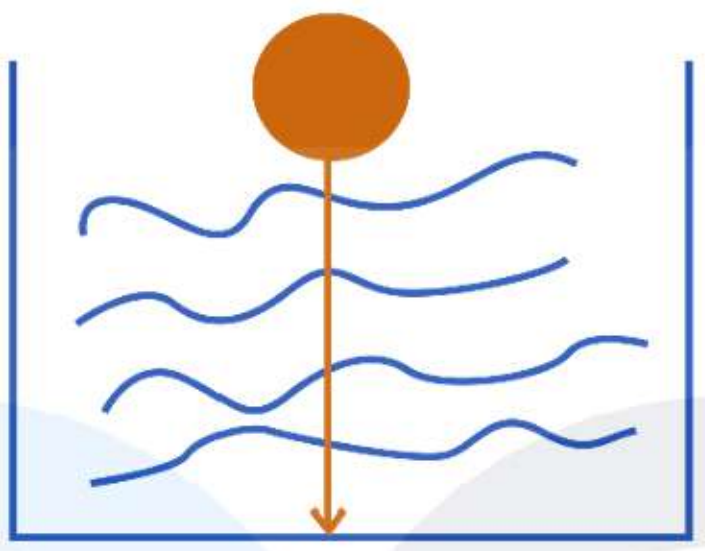

PT gland sinks

↓

Reimplantation in SCM muscle pocket

- PT gland in specimen

  ↓

  inserted in non-dominant hand brachioradialis

vi. Suction drain close the wound → to find bleeding

Post – Op complications 00:11:40

Immediate

1. Stridor – both cords – cadaveric spasm B/L RLN (praxia/injury)

   Reintubation

2. Difficulty in respiration

   ↓

   Hematoma ⊕

   ↓

CRRI – Remove sutures & let out hematoma → Shift to OT

3. Injury to nerves –

   - RLN – Hoarseness

AfraTafreeh.com

- ELN – Huskiness
- ILN – Paroxysmal cough

4.Laryngomalacia – collapse of trachea/larynx

5.Thyroid storm – Respiratory distress

↓

1. Stridor
2. Hematoma
3. Laryngomalacia
4. Laryngismus stridulus (decreases Ca^{++})
5. Edema of Vocal cord

Early complications

1.Hypocalcemia – 2-5th POD (total thyroidectomy)

Early
- Trousseau sign – carpopedal spasm
- Chvostek sign – Facial twitching

late
- Tetany – opisthotonous
- Laryngismus stridulus

- Most common cause of hypocalcemia – loss of blood supply to PTH

Ⓝ calcium → 8-12 mg/dL

Managed based on Symptoms

- Early cases (subclinical) – oral calcium
- Overt cases – IV calcium gluconate
- 2 weeks – permanent hypocalcemia

↓

Oral calcium + vitamin D_3

Late complications

1. Keloid
2. Hypothyroidism

Recent Advances 00:20:56

RLN injury

- Continous monitoring → Electrode on Vagus N. → Prevents injury
- Intermittent monitoring → Electrode near vocal cords (ET tube) → Spasm → It will help you in detecting the injury

Minimal Invasive Thyroidectomy 00:23:48

Minimal Invasive Thyroidectomy

- Axillary approach
- Sub mammary
- Supraclavicular approach
- Breast approach

- Cervical branch of facial nerve can be injured.

AfraTafreeh.com
DOC TUTORIALS
LOGIN FOR SUCCESS

AfraTafreeh.com

CLINICAL EXAMINATION OF BREAST

Anatomy 00:00:22

- Modified sweat glands
- Sitting on pectoralis major

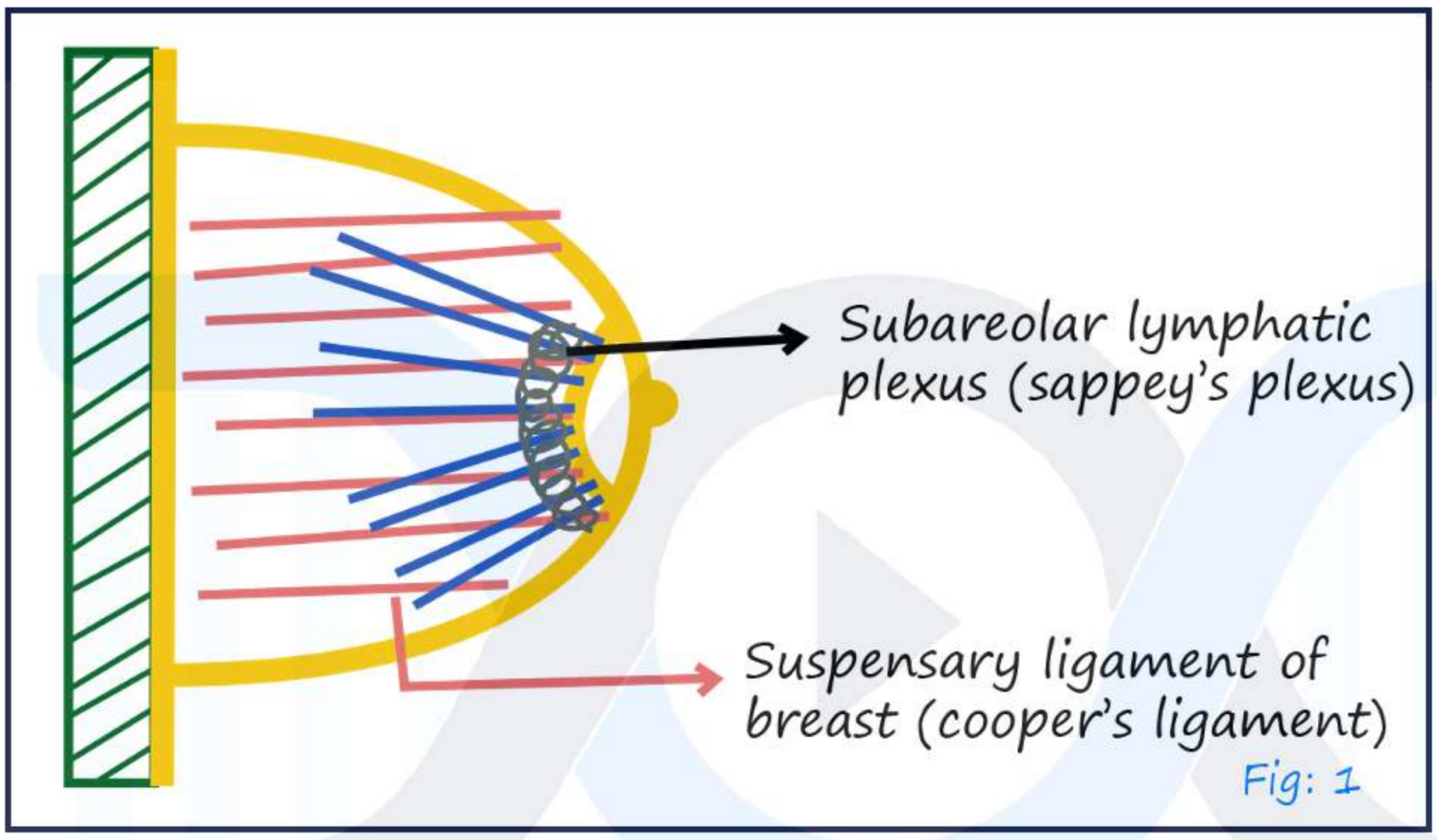

Fig: 1

- 15-20 ducts converge towards nipple
- 10-100 lobules present.
- Held in position by ligament → suspensory ligament of breast.

TUTORIALS LOGIN FOR SUCCESS

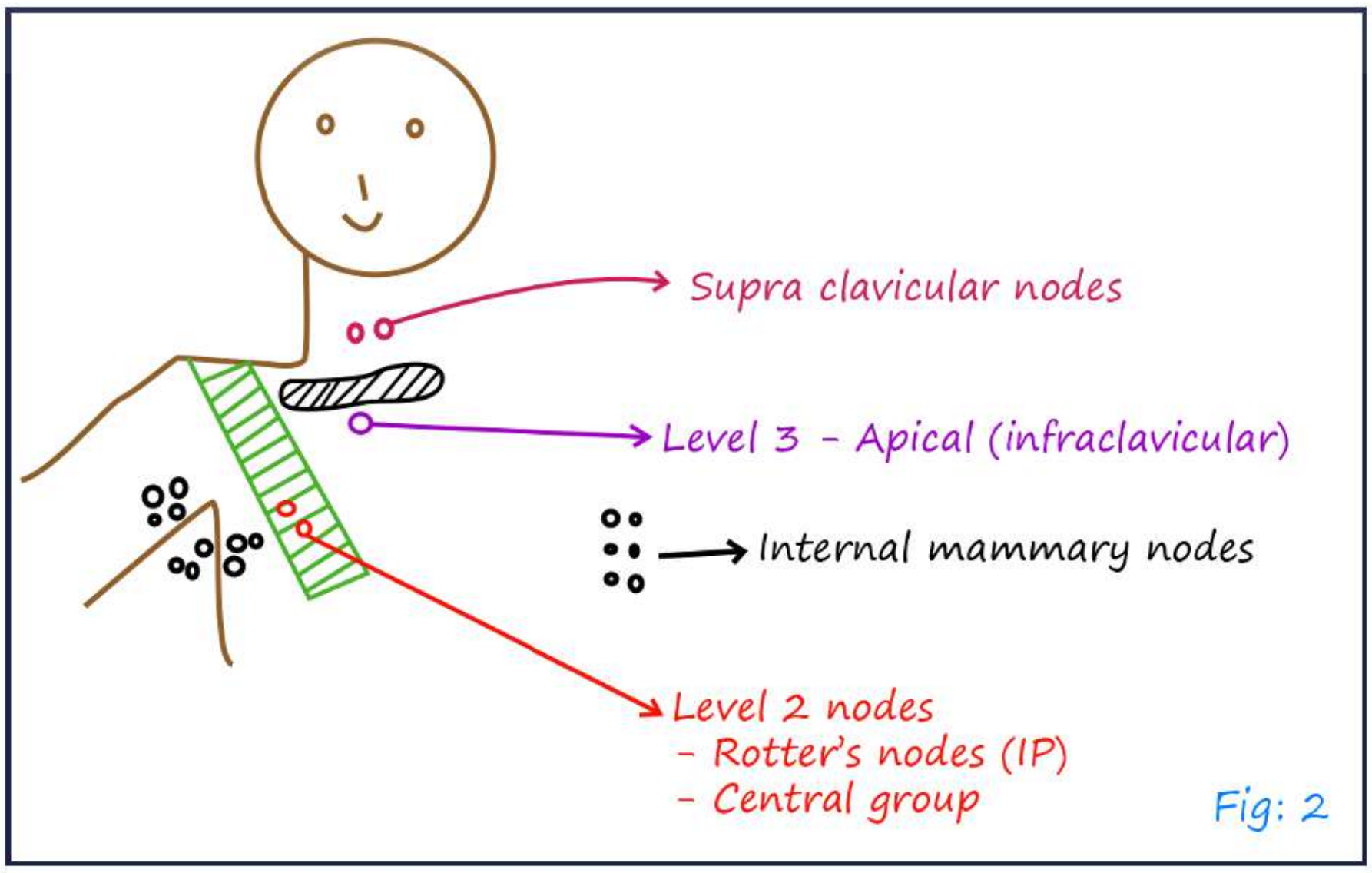

Fig: 2

- Level 1 nodes
  1. Lateral (Humeral)
  2. Anterior (Pectoral)
  3. Posterior (Subscapular)

Cancer Breast 00:05:50

Triple Assessment

- Clinical Examination
- Radiological
- Pathological

- 99.9% PPV to diagnose Ca breast.

Clinical Examination

- Best position: Semirecumbent → fat gets dispersed
- Others → Sitting
  - Leaning forward
  - Arms lifted
  - Arms alternating contracting/relaxing.

Dial clock method (circumferential)



Vertical strip method

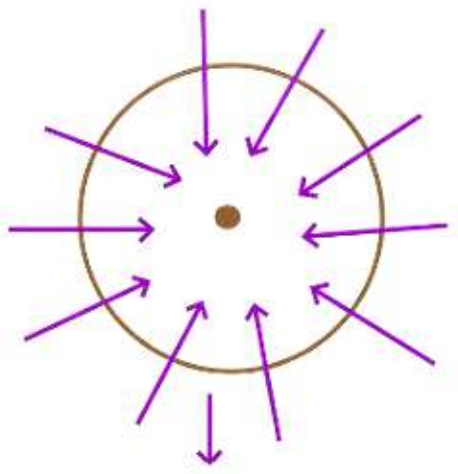

Spoke wheel method

AfraTafresh.com
TUTORIALS
LOGIN FOR SUCCESS

AfraTafreeh.com

Inference of

- Leaning forward → Chest wall fixity + (ribs, IC muscle, serratus anterior)
- Contracting P. major → to look for pectoralis fixity

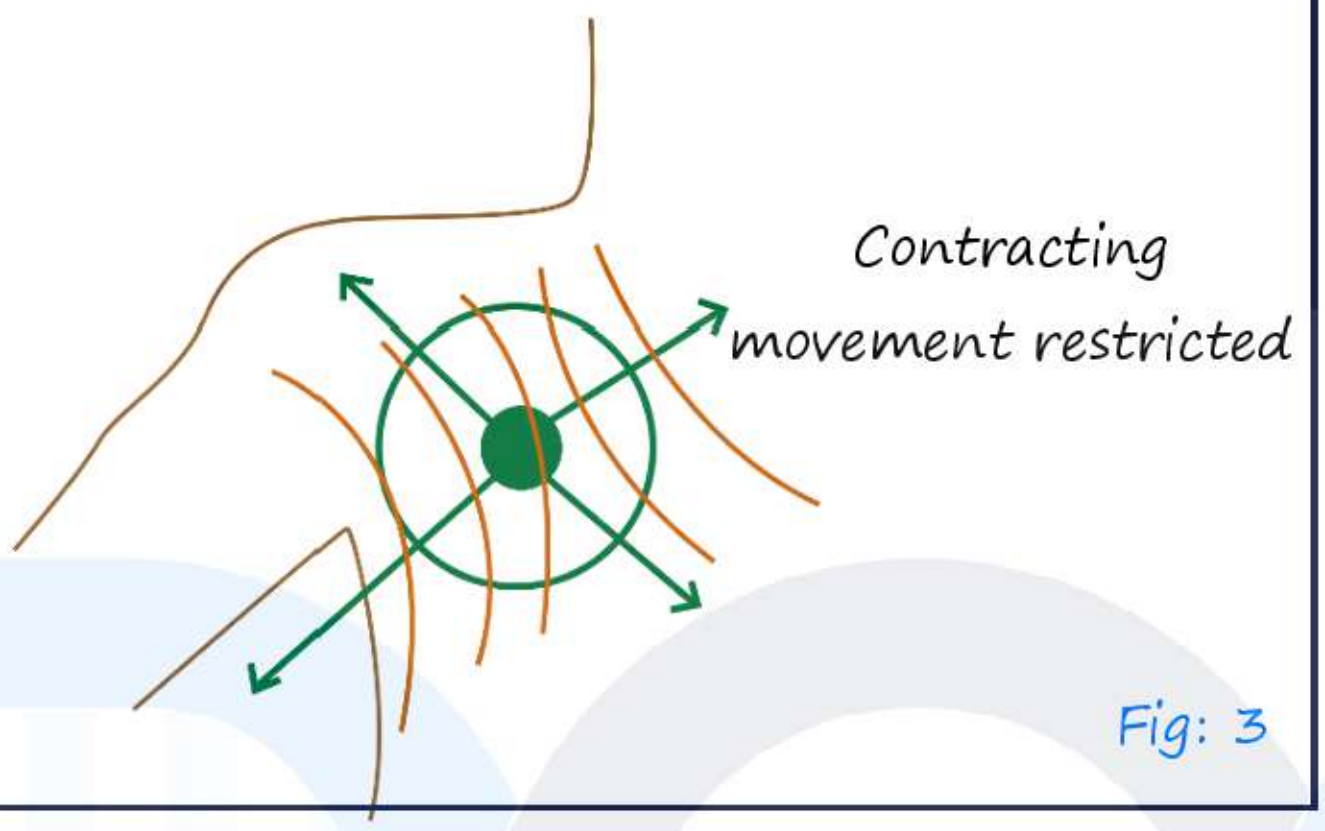

Fig: 3

- Lifting the arm up – Nipple retraction (circumferential)

  – Paeu de orange (lymphatic infiltration of breast)

TUTORIALS
LOGIN FOR SUCCESS

Axillary Examination

- Nodes → Number
  - Consistency
  - Mobility
  - Fixity
  - Level of nodes
  - Opposite SCL/Axilla

c TNM Staging 00:15:30

- y TNM staging → Post neoadjuvant chemotherapy.

- p TNM staging → Pathologist

8th Edition

- Tis – DCIS, Paget's disease (LCIS is not included)
  ↓
  Physiological precursor
- T_1 – < 2 cm diameter
- T_2 – 2-5 cm diameter
- T_3 – > 5 cm diameter
- T_4 → T_{4a} – involvement of chest wall
  (Ribs, IC muscle, Serratous anterior)
  – P. major & P. minor not involved.

  T_{4b} – Skin ++++ → Ulceration, satellite nodules, paeu de orange
  – Not involved are
  - Tethering
  - Dimpling
  - Puckering

  (Tethering, Dimpling, Puckering) – Cooper's ligament present
  - Fixity
  - Nipple retraction

  T_{4c} – Both a & b

  T_{4d} – Inflammatory breast cover

AfraTafreeh.com

N Staging

- N_1 – Mobile axillary nodes present
- N_{2a} – Fixed AN present
- N_{2b} – IM nodes (I/L)
  ↓

AfraTafreeh.com

CT scan

Lymphangiography

- N_{3a} – Infraclavicular (I/L)
- N_{3b} – Both AN + IM nodes
- N_{3c} – Supraclavicular (I/L)

pN Staging

- N_1 – 1-3 +
- N_2 – 4-9 +
- N_3 - $\geq$ 10 nodes present
- Minimum – 10 nodes to be removed.

M Staging

- Most common site: - Lumbar Vertebra
  Liver
  Osteoblastic/Osteolytic
- ? 1. 2 tumors in same quadrant

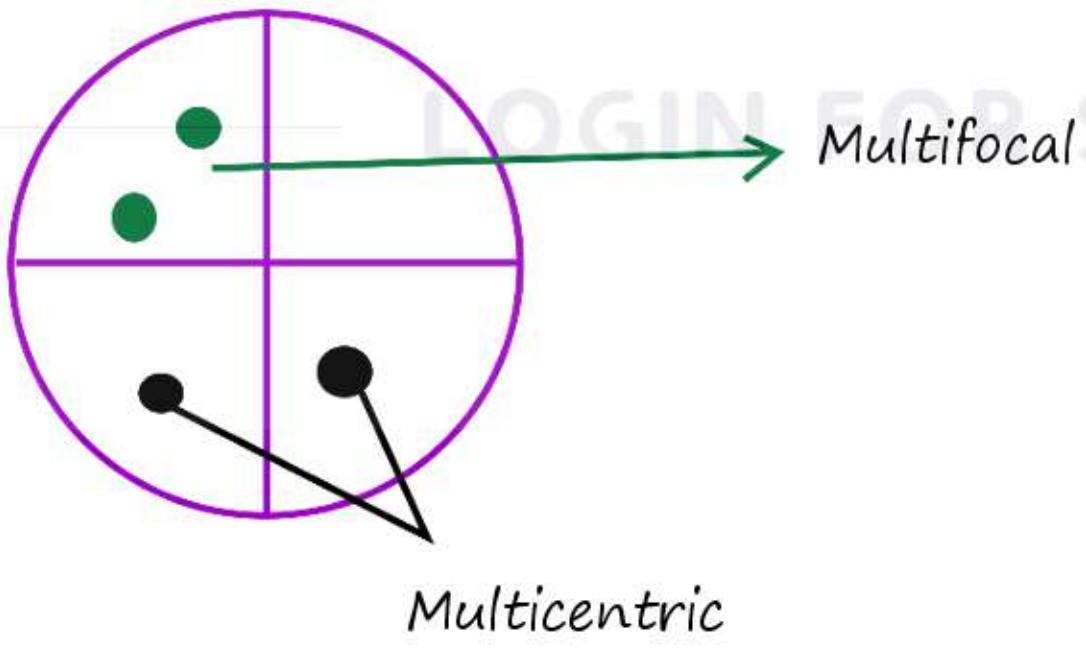

- T staging → Biggest one- T3:5cm or more.

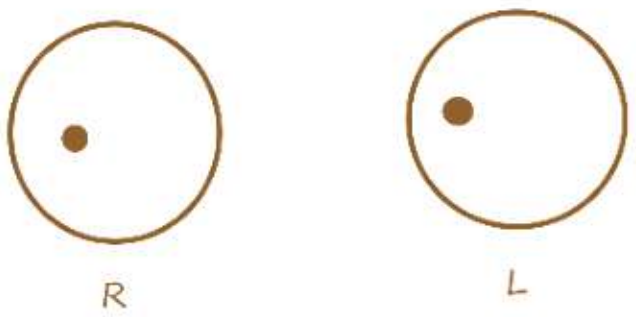

→ Separate TNM staging for R and L breast.

Stage categorization (AJCC 8th edition)

- Stage I – T_1 No
- Stage II_a – T_1N_1

  T_2 N_O
- Stage II_b – T_2N_1

  T_3N_O
- Stage III_a – T_1 N_2 & all others

  III_b – T_4 → T_4N_1, T_4N_2

  III_c – N_3 → T_1 N_3 M_o

  T_2 N_3 M_O
- Stage IV – M_1

Types of Breast Cancer AfraTafreeh.com 00:28:30

Types of Breast Cancer

Early breast
↓
Stage I
IIa
IIb
↓
BCS/MRM
↓
Adjuvant therapy

LABC
↓
Stage III a
III b
III c
↓
Neoadjuvant CT
↓
3 months
↓
MRM
↓
Complete chemotherapy

Stage IV
↓
- Palliative therapy
- Toilet mastectomy

TUTORIALS
LOGIN FOR SUCCESS

AfraTafreeh.com

RADIOLOGICAL EXAMINATION OF BREAST

Radiological Examination of breast 00:00:18

- USG breast → <35years
- Mammography → >35years
- MRI → Silicon implant breast
- Screening IOC → Mammography
  - ≥40 years: - Annual
  - High risk: MRI ≥ 30 years

Mammography 00:03:16

- X-ray
  - Low voltage
  - High amplitude
- Bremsstrahlung X-ray → exposure of 0.1 CGY
- 1 mammography = 4 X-ray
- Not premalignant
- Routine screening with mammography decrease 30% cancer breast deaths
- Always done for both breast
- 2 views

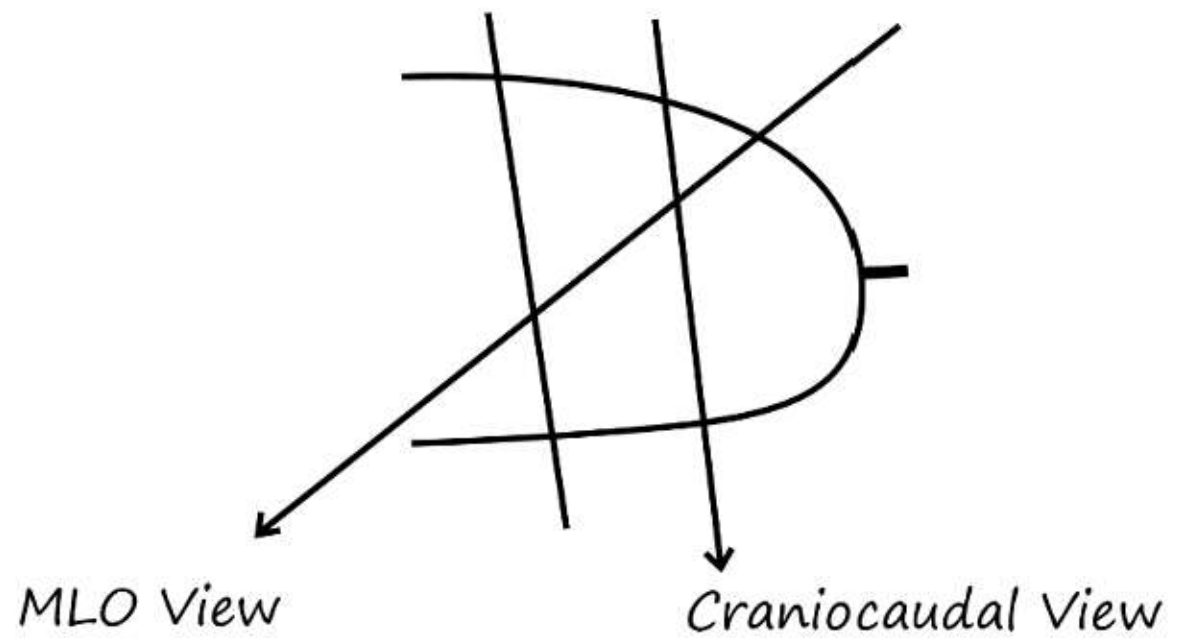

Fig: 1

Findings in cancer breast 00:05:50

1.Micro calcification

2.Architecture distortion

3.Spiculation

4.Mass effect

5.Branching calcification

- Based on finding → BIRADS grading

Other cases

- DCIS
  - Micro calcification
  - Scattered calcification
  - Clustered calcification
  - IOC: - Mammography
- LCIS
  - No radiological abnormality
- LC invasive
  - Neighbouring calcification
- Fibroadenoma
  - Popcorn calcification

BIRADS grading 00:09:15

- Breast imaging reporting and data system
- 6 grades

AfraTafreeh.com
DOC TUTORIALS
LOGIN FOR SUCCESS

AfraTafreeh.com

0 – Inconclusive

1 ↑
2 | Benign lesions → Follow up
3 ↓

4 – Suspicious of malignancy → Biopsy advised

5 - Mostly malignancy → Biopsy must

6 – Biopsy proven malignancy

MRI breast 00:11:45

Indications as screening (≥30 years)

1. High risk cases (Clauss, Gail models)
2. BRCA 1, 2 cases
3. 1st degree relatives (BRCA 1 / 2 mutation)
4. Lifraumeni syndrome

TUTORIALS
LOGIN FOR SUCCESS

Diagnostic IOC

1. Previous scarred breast
2. HPO BCS done – Follow up with MRI
3. Silicone implanted breast →capsule rupture known as "LINGUINE SIGN"

PATHOLOGICAL EXAMINATION OF BREAST

Methods of pathological examination 00:00:30

Methods of pathological examination

- **FNAC** → 22 G needle → Confirm diagnosis
- **Trucut (Corecut biopsy)** → 16 G, 18 G → More tissue → ER study → Best gold standard
- **Excision** → Very small inconclusive lesion

Ductal and lobular carcinoma 00:03:16

AfraTaheeh.com
TUTORIALS
LOGIN FOR SUCCESS

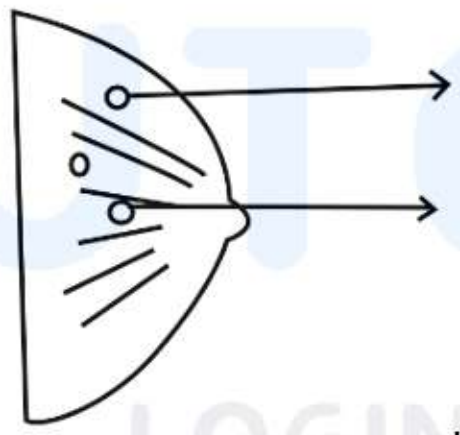

Lobular cancer (10%)

Ductal cancer (90%)

Ductal cancer

- **DCIS** → Anatomical precursor → TIS
- **Invasive** → Most common type → No specific type/ not otherwise specified → Also called seirrous type (80%)

Lobular cancer

- **LCIS** → Physiological precursor (Not staging)
- **LC invasive** →

AfraTafreeh.com

Other cancers of ductal invasive

- Medullary Ca → young, soft, triple negative bad prog
- Tubular Ca
- Colloid/ mucinous Ca → good prognosis

Lobular carcinoma invasive

- < 10%
- Incidence
- B/L
- Multicentric
- Multifocal
- FNAC of opposite breast
- Mammography – neighbouring calcification
- Biopsy: –
  - Indian file pattern arrangement
- Treatment: - B/L MRM

TUTORIALS
LOGIN FOR SUCCESS

DCIS	LCIS
Most common India – Lump West – Found on mammography Anatomical precursor ↓ DCIS → Ductal Ca invasive • Tis • DCIS – microcalcification on mammography	Most common – painless lump LCIS – Ductal invasive > lobular invasive Physiological precusor • Not involved in 'T' staging • XXX • XXX

Types of ductal carcinoma in situ 00:11:20

Types of ductal carcinoma in situ

- Low grade → Papillary, Cribriform
- Hight grade → Solid and Comedo type

Types of LCIS 00:12:01

- Pleomorphic → calcification ⊕
  ↓
  Resection

DCIS	LCIS
Management • Resect – BCS – SM • Tamoxifen 10mg BD f/b surgery • RT also given based on Van Nuys grading	• No resection • Close follow up ↓ T. tamoxifen • B/L simple mastectomy can be done if patient is willing

AfraTafreem.com
TUTORIALS
LOGIN FOR SUCCESS

VAN NUYS grading 00:13:33

- Based on
  - Age
  - Margin
  - Size
  - Grade

AfraTafreeh.com

Molecular classification 00:16:15

- Based on immunohistochemistry
  - ER : +/-
  - PR : +/-
  - HER2:
    1. 0 – negative
    2. +1 – negative
    3. +2 – equivocal – FISH Q AIIMS
    4. +3 – positive

Classification

1. Luminal A: -
   - Most common type
   - ER +
   - PR +
   - HER 2 –
   - Best prognosis
2. Luminal B: -
   - ER +
   - PR +
   - HER 2+

(Luminal A and Luminal B: a/w BRCA-2 mutation)

3. HER 2: -
   - HER 2 +
   - ER -
   - PR –
   - Worst prognosis

4.Basal type: -

- ER -
- PR -
- HER 2 -
- Bad prognosis

} BRCA-1 mutation

q. most common in BRCA 1 mutation – basal type

AfraTafreeh.com
TUTORIALS
LOGIN FOR SUCCESS

AfraTafreeh.com

RISK FACTORS OF CA BREAST

Clinical Features & Risk Factors 00:00:12

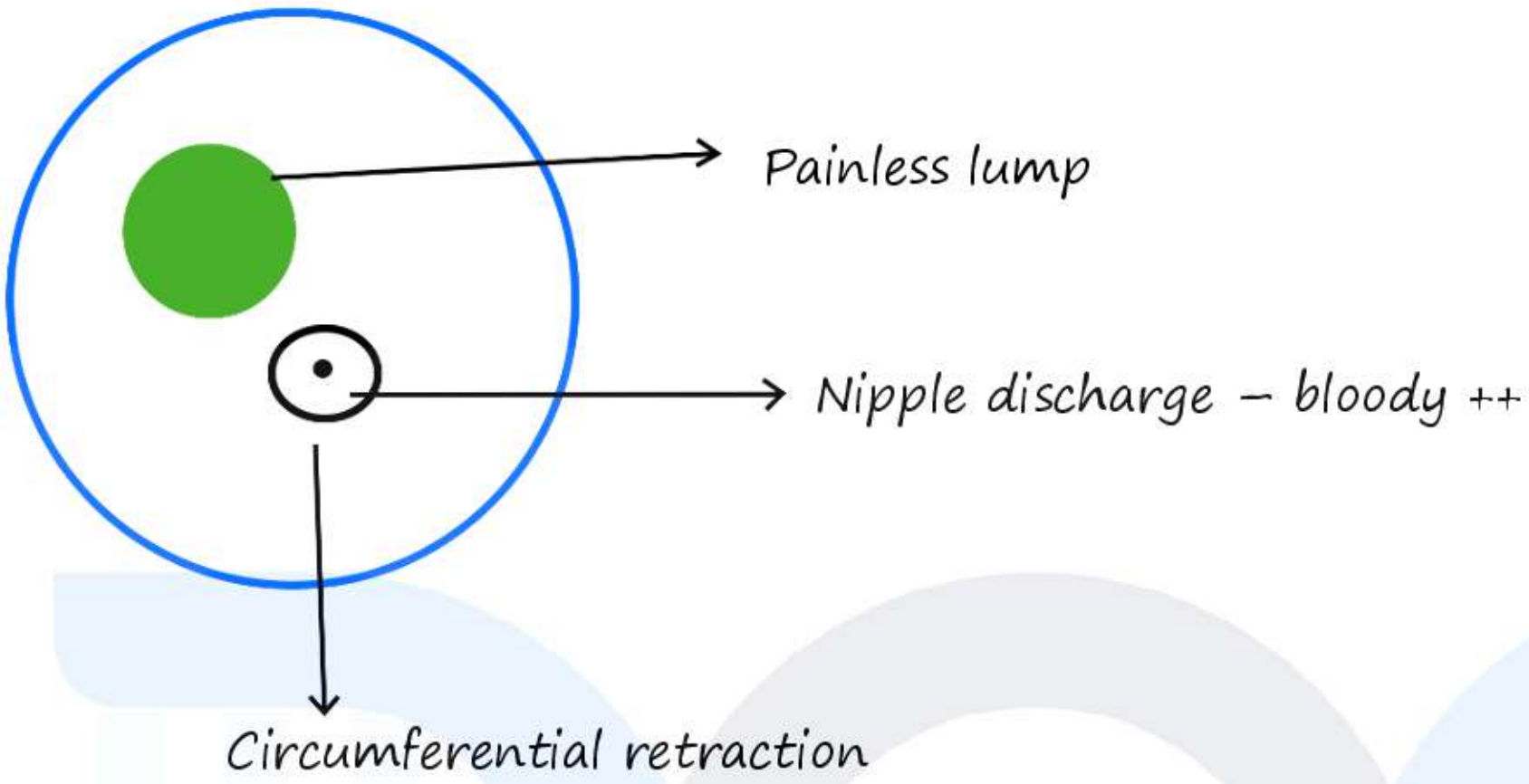

- Most common site → upper outer quadrant

Risk factors

- Non modifiable
- Modifiable
- Histological R/F

1.Non modifiable: -

- Reproductive: - Early menarche (<12 years)
  Late menopause (>55 years)
- Age (increases)
- Female sex
- Family H/O Ca breast
- Genetic (Hereditary)
  - BRCA 1
  - BRCA 2
  - Li Fraumeni

- Cowden disease
- Ataxia Telengiectasia

- H/O irradiation

2.Modifiable

- Nulliparous
- Child birth delayed (>30 years)
- Absent breast feeding
- Alcohol
- Smoking
- Obesity
- Lethargic office activity

Drugs :-

- OCP
- Post-menopausal HRT

Except HRT given in young age who has undergone B/L Salpingo-oophorectomy

3.Histological risk factors

- LCIS
- Atypical Hyperplasia
  - Lobular
  - Ductal
  - Epithelial

AliTafreeh.com
TUTORIALS
LOGIN FOR SUCCESS

Models 00:07:35

- Software models → Gail model
  → Clauss model

AfraTafreeh.com

- Used to assess risk
  - High risk → MRI
  - Low risk → Mammography

Types of Cancer Breast Based on Presentation

00:08:20

- Sporadic 60-70%
- Familial 20-30% → H/O cancer 13%
- Hereditary 5%
  - m/c: BRCA-1 (45%)
  - 2nd: BRCA-2 (35%)
  - Other syndromes <1%

BRCA 1 & BRCA 2 mutation 00:10:20

BRCA 1	BRCA 2
• Chromosome 17q	• Chromosome 13q
• Poorly differentiated	• Well differentiated
• ER-, PR- → most common – Basal type	• ER+, PR+ → Luminal A type
• Bad prognosis	• Good prognosis
• Cancers - Breast – 60% - Ovarian – 40% - Prostate cancer - Colon cancer	• Cancers - Breast (80%) - Ovarian (20%) - Prostate - Colon - Gastric - Pancreatic - Melanoma - Male breast cancer

Prophylactic B/L simple mastectomy

+

B/L BSO

- They should undergo screening: - MRI from age of 30 years

AfraTafreeh.com
TUTORIALS
LOGIN FOR SUCCESS

AfraTafreeh.com

SURGICAL ASPECTS OF CANCER BREAST

Simple mastectomy 00:00:28

- Removal of nipple areola and breast tissue

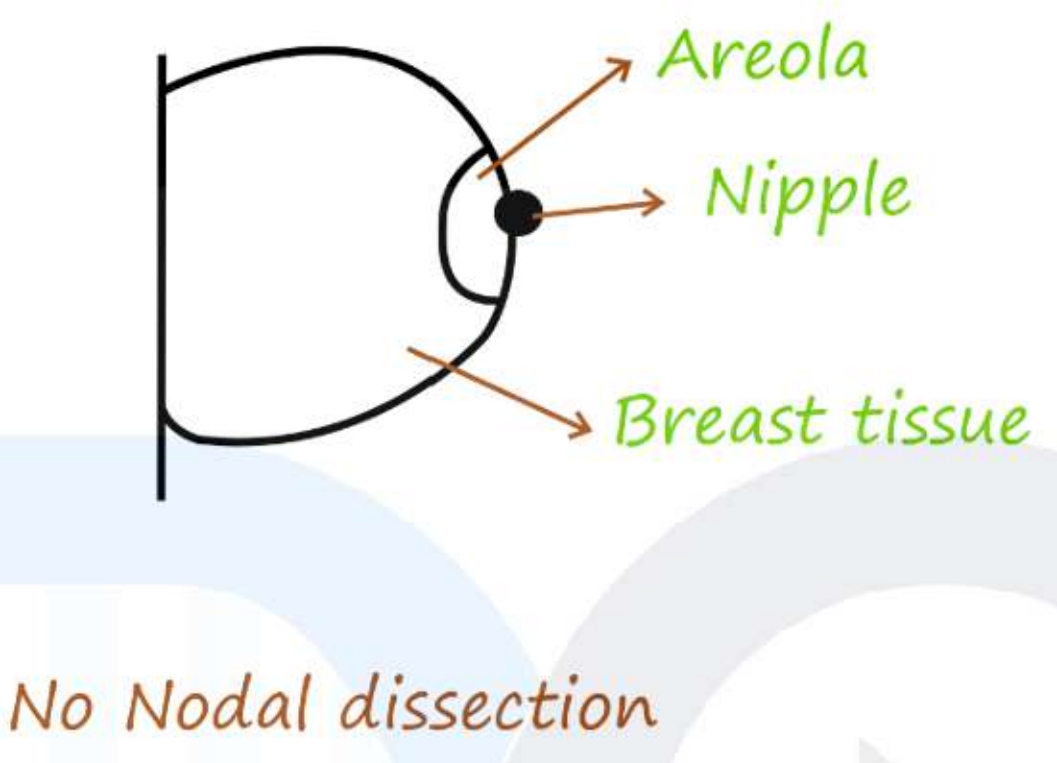

- No nodal dissection

Indications –

1. DCIS
2. BRCA 1,2 mutation →Skin sparing (Nipple sparing)
3. Inoperable Ca breast with fungation
   ↓
   Toilet mastectomy

Extended simple mastectomy 00:03:06

- Simple mastectomy + Removal of level 1nodes

Modified radical mastectomy 00:03:32

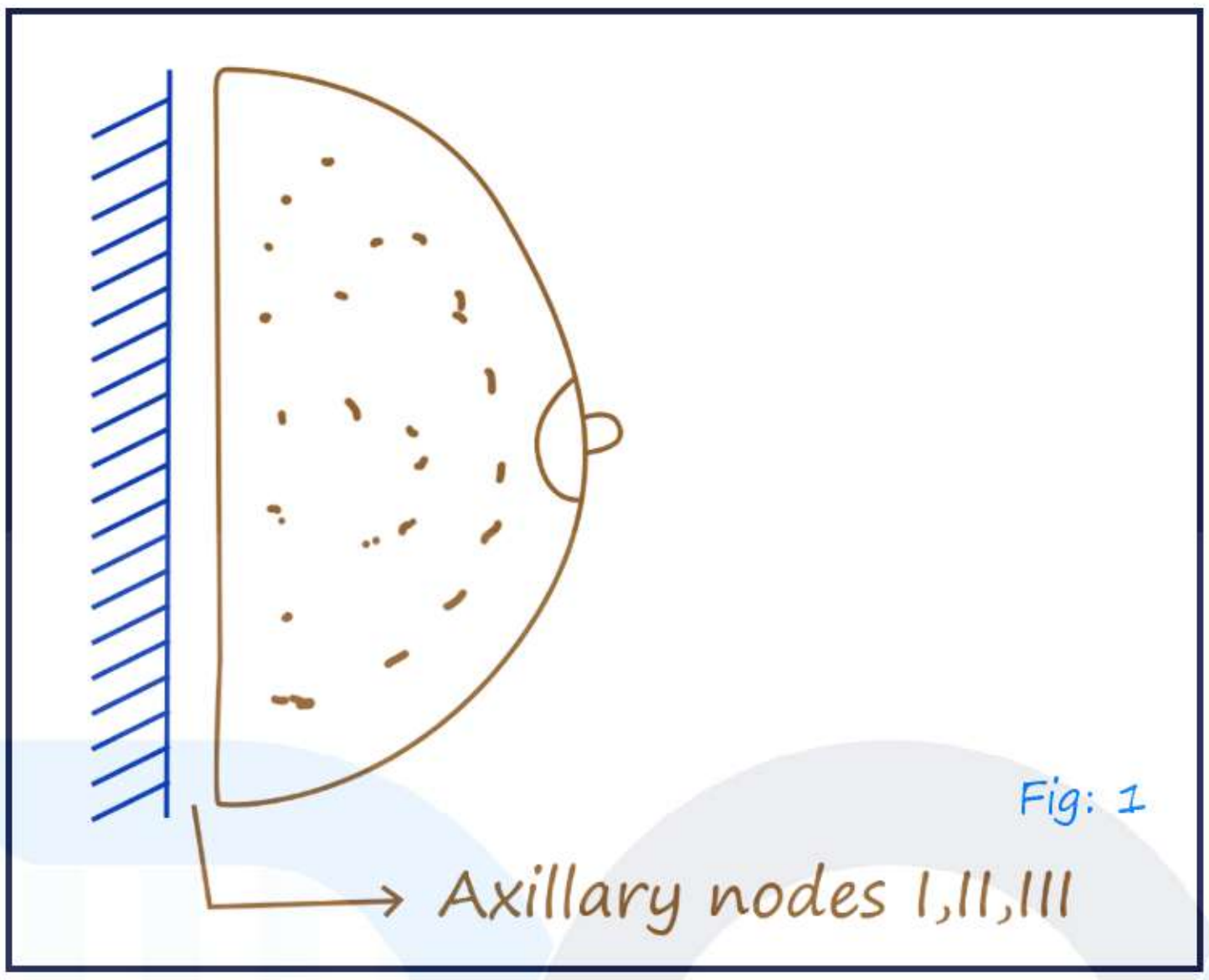

Structures removed

- Pectoralis fascia
- Nipple
- Areola
- Breast tissue
- Muscle preserved – P. major is preserved

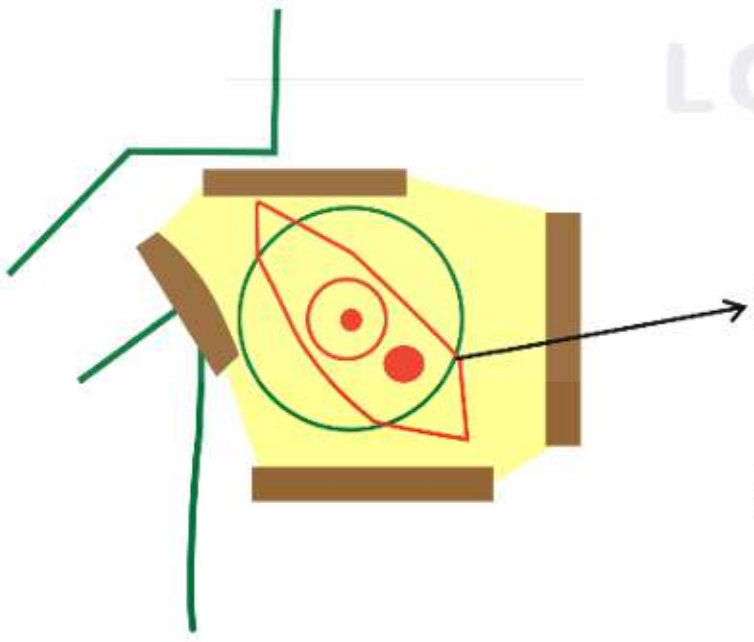

Flap raised up to

- Subclavius superiorly
- Sterum medially
- Sterum medially
- 2cm below the mammary fold
- Latissimus dorsi laterally

AfraTafreeh.com

Axillary dissection:

- Level I, II, III nodes are removed

↓

P. minor muscle

Remove	Retract	Cut and resuture
↓	↓	↓
Patey's MRM	Auchincloss MRM	Scanlon MRM
↓	↓	↓
Level 1,2,3 nodes removed	Only level 1&2	All 3 levels nodes removed

Boundaries of axillary dissection

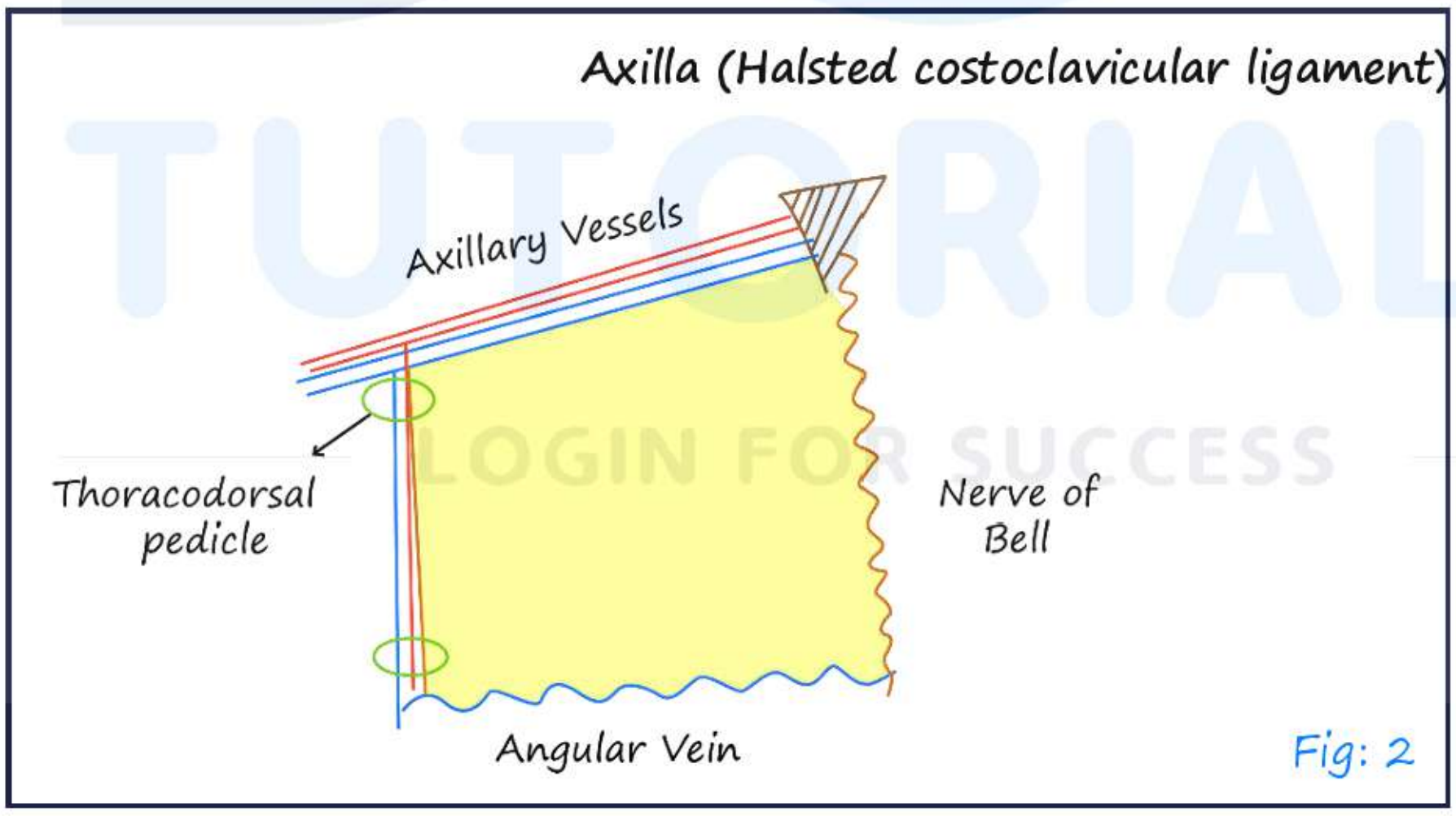

Fig: 2

- Superiorly: Axillary vessels
- Inferiorly: Angular vein
- Laterally: Thoracodorsal pedicle
- Medially: Nerve of bell
- Minimum nodes to be removed – 10nodes

MRM:

- Includes axillary dissection also
- Structures preserved:
  - A: Axillary vessels
  - B: Bell's nerve
  - C: Cephalic vein
  - D: Nerve to latissimus dorsi (Thoracodorsal N)
  - M: Pectoralis major

Halstead's radical mastectomy:

- Skin, nipple areola, breast, P. major, P. minor and serratus anterior are removed
- Structures preserved: Axillary vessels, Bell's nerve, Cephalic vein
- Before closing the wound suction, drain is placed at 2places – Axilla and breast
- Most common complication following MRM – Seroma
- Suction drain falls on 2nd POD → Repeated aspiration & Tight elastocrepe dressing

AfraTafreeh.com

Complications of MRM/AD 00:16:24

Nerve injuries –

- Most common: Intercostobrachial nerve
  ↓
  Cutaneous supply
- Bell's nerve: Winging of scapula

AfraTafreeh.com

- Thoracodorsal nerve: Medial rotation is lost, climbing is lost
- Medial/Lateral pectoral nerve: P. major function lost

Other complication of MRM:

- Flap necrosis: Infection
- Lymphedema (Most common cause of lymphedema in western)
- Lymphangiosarcoma (Stewart Treves syndrome)

↓

Forequarter UL amputation

SENTINEL NODE BIOPSY :- 00:20:46

1ST node → Guilliano node in breast

[Penis → Cabana (superficial inguinal) node

Testis → Para-aortic node]

→ Axillary nodes

If no axillary nodes → no Axillary dissection is needed

Hence, sentinel node biopsy is done

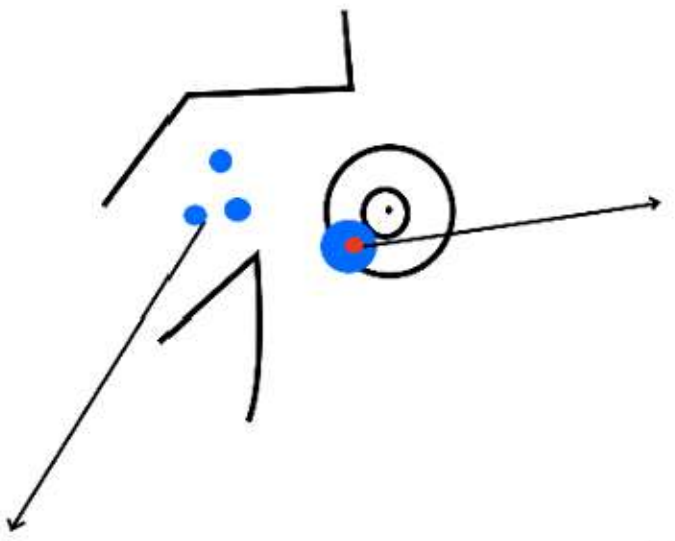

Isosulphan / Methylene blue is injected in peritumoral area on table

↓

Nodes appear blue

Frozen section BX

1. (+) → AD
2. (-) → Post Op RT to axilla

- Radiolabeled colloid (TC 99m) is injected in Peri-areolar area previous day night

↓

In OT – Gamma camera is used

↓

Highest active nodes are taken

↓

Frozen section BX

1. (+) → AD
2. (-) → Post Op RT to axilla

- Best method: Combined method is the best

Indications:

- No cases
- Early breast cancer (I, IIa, IIb)

AfraTafreen.com

Contraindications:

- Palpable node (+)
- T3, T4 cases
- H/O surgery done in breast (Lymphatic pathway is disturbed)
- Pregnancy
- C/I for radiotherapy – Collagen vascular diseases and previous history of RT

TUTORIALS
LOGIN FOR SUCCESS

AfraTafreeh.com

Breast conservative surgery 00:30:15

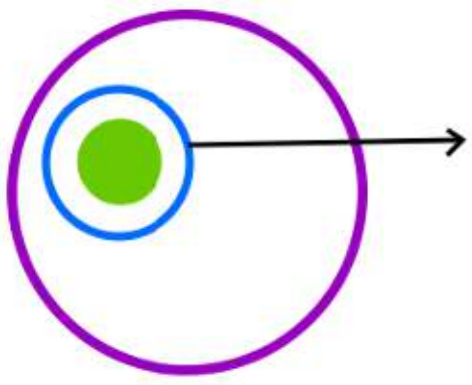

Wide local excision (1mm margin)
Ro-resection

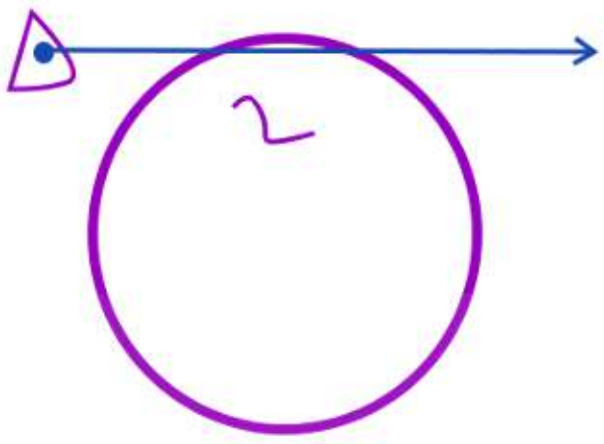

Axillary nodes (+) → (-)
↓ ↓
Axillary dissection SN biopsy

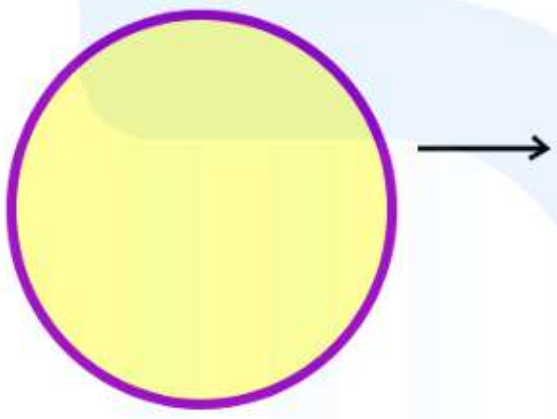

Radiotherapy to breast
↓
Follow up
↓
Recurrence is common

Indication:

- Early breast cancer (I, IIa, IIb)
- DCIS

TUTORIALS
LOGIN FOR SUCCESS

Contraindications:

- Wide local excision not possible/feasible
  - Multifocal/Multicentric
  - LABC (Chest wall and skin involvement)
  - WLE – 2times positive

T2, small breast big tumor

- RT not possible
  - Pregnancy (1&2nd trimester) (3rd trimester not C/I)
  - Collagen vascular disorder
  - Prior to RT
  - Large pendulous breast

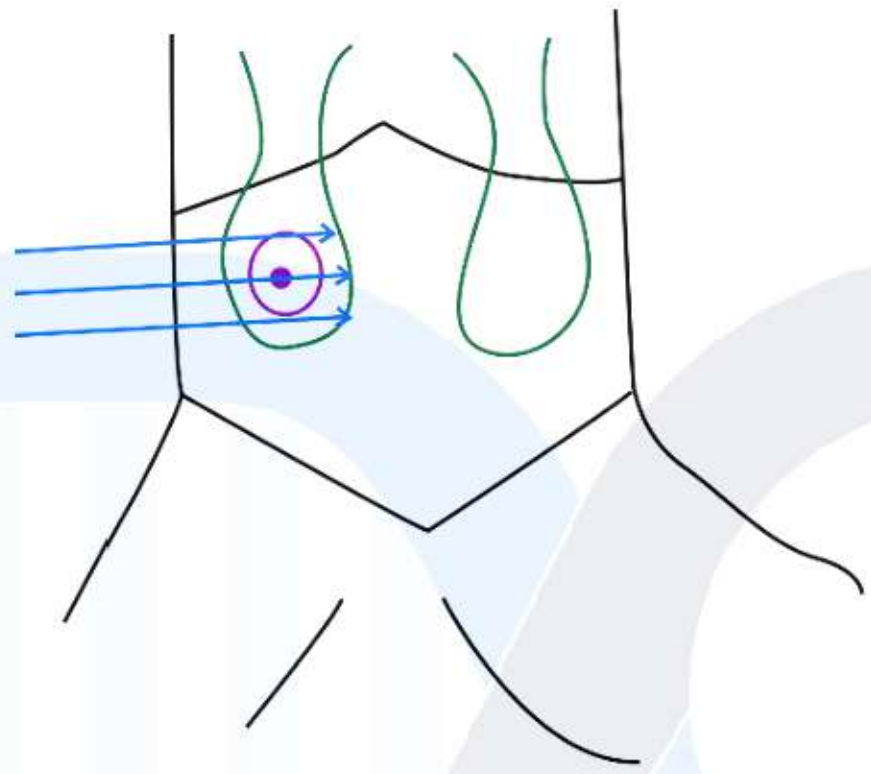

- Follow up not possible
  - Uneducated people
  - Low socioeconomic status
  - Psychiatry patients

AfraTafreeh.com
TUTORIALS
LOGIN FOR SUCCESS

BCS is not C/I:

- Family H/O
- Centrally (Subareolar tumor)
- Nodes (+)

AfraTafreeh.com

Breast reconstructive procedure

Autogenous tissues
↓
- TRAM flap
- DIEP flap
- Others
- LD flop
- Gluteus (Rubin's)

Implants (Silicon)
↓
Indications
- Patient wants augmentation
- B/L reconstruction
- Additional scars not interested

Contraindications –
- Silicon allergy
- Planning RT

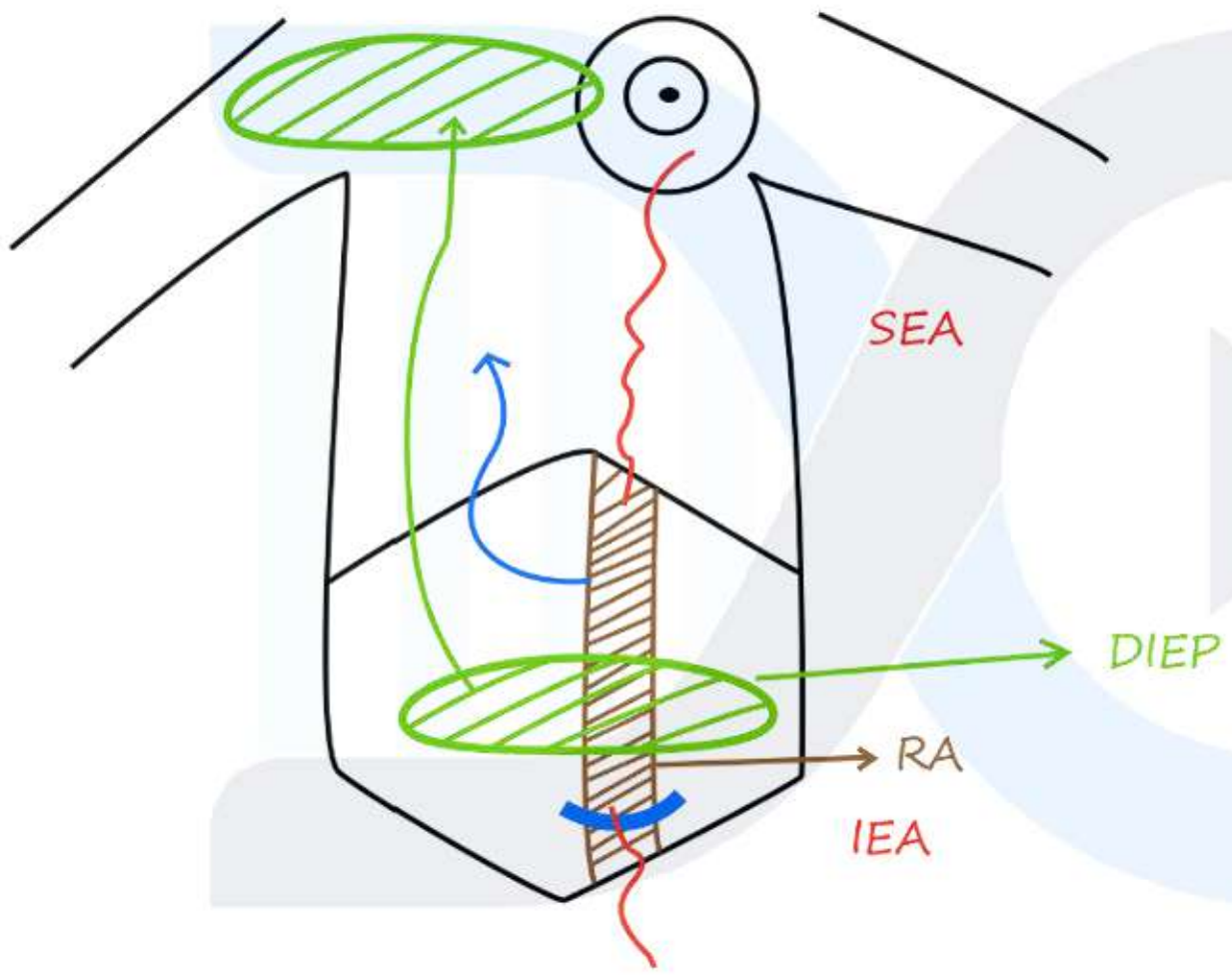

- Pedicle flap: SEA
- Free flap: IEA (microvascular anastomosis)
- DIEP flap: Deep inferior epigastric perforator flap
  - ↓ Most common
  - ↓ Skin + Subcutaneous tissue ↓ Free

ADJUVANT THERAPY OF CANCER BREAST

Adjuvant therapy 00:00:20

- Chemotherapy → To prevent distant mets
- Hormone → ER (+) → To prevent cancer in opposite breast
- Radiotherapy → To prevent local recurrence

Commonly used chemotherapy 00:02:03

- CAF – 6 cycles
  - Cyclophosphamide → can cause hemorrhagic cystitis
  - Adriamycin → can cause cardiotoxic
  - 5-FU → can cause BM suppression
- Indications of chemotherapy :
  - > 1cm
  - Node +

AfraTafreeh.com
TUTORIALS
LOGIN FOR SUCCESS

Commonly used hormone therapy 00:03:30

- Used only for ER positive cases
- Commonly used: – Tamoxifen
  - Anti-estrogen in breast
  - 10mg BD minimum 5 years and maximum 15 years
  - Premenopausal women
- Post-menopausal women
  - Peripheral conversion of androgen → Estrogen

AfraTafreeh.com

↓

Aromatase inhibitors

↓

Anastrozole, letrozole

- Tamoxifen
  - Anti-estrogen → decrease cancer breast in opposite breast
  - Agonist in endometrium → endometrial cancer

Advantages of tamoxifen

- Decrease 40% incidence of opposite breast cancer
- Decrease 30% mortality
- Decreased osteoporosis

Disadvantages of tamoxifen

- Endometrial cancer
- Thromboembolism
- Bone pain
- Cataracts

↓

To prevent these → SERM (Selective Estrogen Receptor Modulators)

i. Raloxifene

ii. Toremifene

TUTORIALS LOGIN FOR SUCCESS

Radiotherapy 00:09:16

- If LABC → radiotherapy is must for chest wall

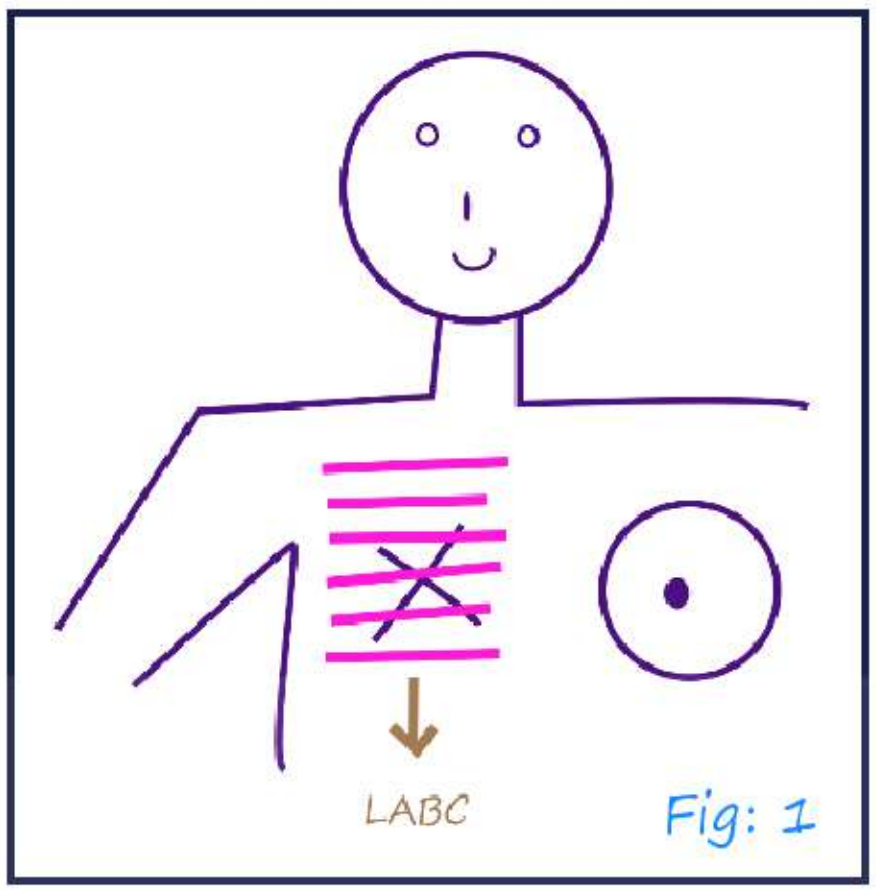

Fig: 1

- Axilla RT:
  - < 10 nodes are removed
  - Extracapsular spread
  - Axillary dissection not done cases

AfraTafreeh.com
TUTORIALS
LOGIN FOR SUCCESS

Newer drugs 00:11:10

- HER 2 ⊕ Trastuzumab – AKA Herceptin (mab – HER 2)
- Psychiatric counselling

Specialists involved 00:12:33

- Surgical oncologist
- Plastic surgeon
- Vascular surgeon
- Medical oncologist
- Medial endocrinologist
- Radiation oncologist
- Psychiatrist
- Nursing care
- Referring physician

AfraTafreeh.com

MISCELLANEOUS LESIONS

Paget's disease 00:00:16

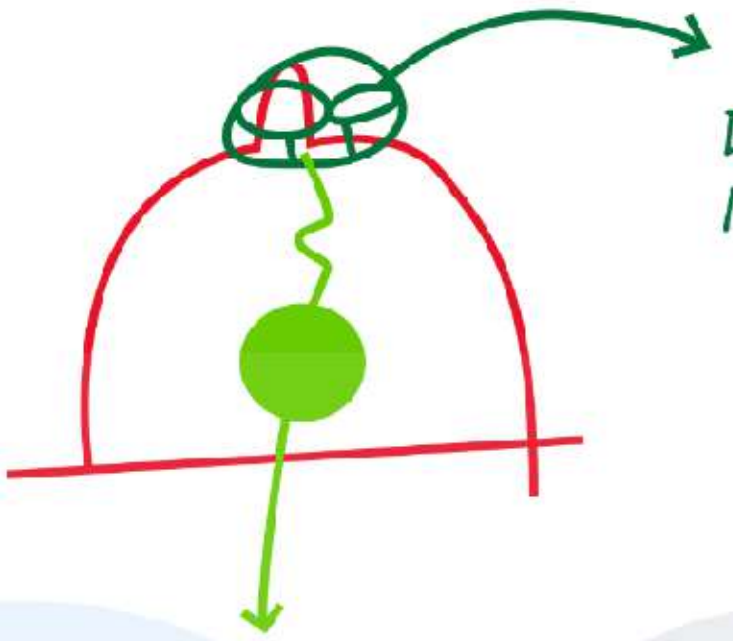

- Nipple will be eroded and discharge present from nipple
- Superficial manifestation of underlying cancer breast (Ductal cancer)
- Many times, lump may be palpable sometimes not palpable also
- Differential diagnosis -
  - Eczema
  - Skin lesion (+)
  - Bilateral
  - Responds to steroids
- Paget's is U/L
- Confirmation by biopsy

↓

Nipple scrap/Punch biopsy

↓

Paget cells (Pale vacuolated cells)

- Tis → 50% underlying lump (TRUCUT)
- Treatment: MRM

Inflammatory breast cancer (T4d) 00:03:24

- On/E: looks like mastitis
- Pain (+)
- Peau de orange
- Redness (+)
- Subdermal lymphatic permeation (+)

↓

Biopsy

↓

Neoadjuvant CT

- Bad prognosis

AfraTafreeh.com
TUTORIALS
LOGIN FOR SUCCESS

Male breast cancer 00:05:00

Predisposing factors -

- BRCA 2 mutation
- Klinefelter syndrome → Gynecomastia
- Testicular feminization syndrome
- Gynecomastia is not a predisposing factor
- Clinical features
- Lump + Discharge
- TNM → Same → T4a: Chest wall (+)
- Investigations:
  - Mammography

AfraTafreeh.com

- TRUCUT biopsy

- Treatment:
  - **MRM**
- Most male breast cancers are ER(+), Tamoxifen also given
- IOC to look for mets : **PET-CT**

Nipple discharges 00:08:34

- Most common – Bloody discharge
  - Young females → Duct papilloma
  - Old age → Caner breast
- Greenish discharge/yellow
  ↓
  Duct ectasia
- Milk discharge
  - Physiological
  - Pathological → Prolactinoma, drugs
- Surface discharge – Serous
  ↓
  Eczema
  Paget's

Duct papilloma Vs Duct ectasia 00:10:54

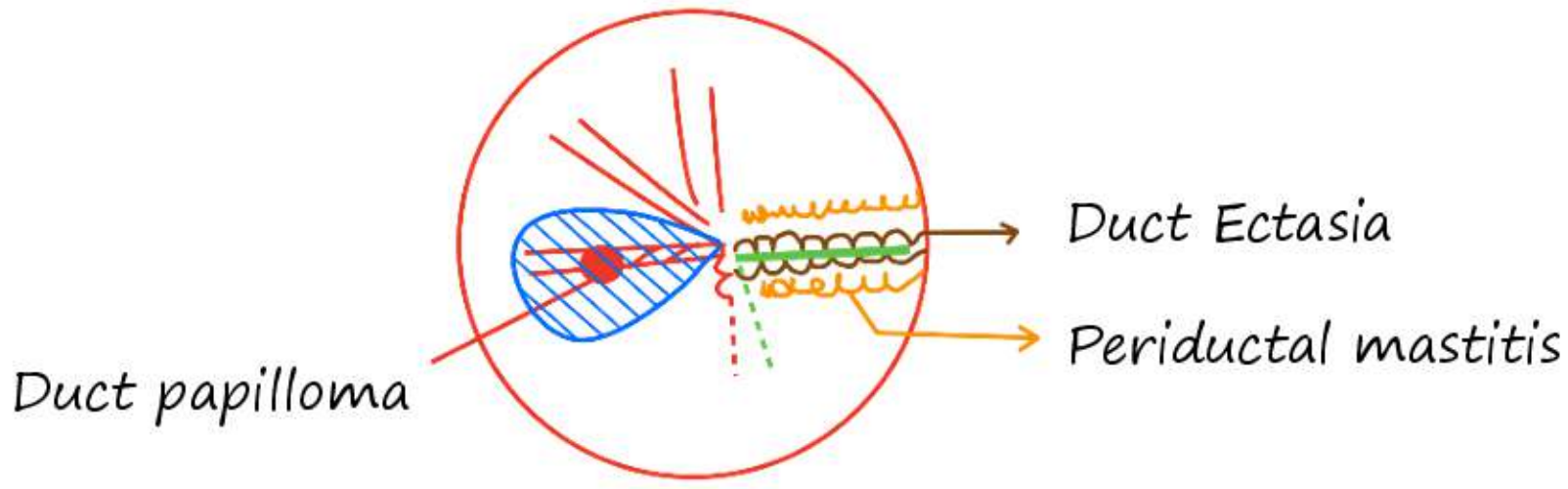

Duct papilloma	Duct ectasia
• Arises from one duct • Bloody discharge • Young females • IOC: Ductography (Filling defect) • Treatment: Tennis racket incision ↓ Microdochectomy	• Dilatation of duct • Greenish discharge • Middle aged, smoking + • Periductal mastitis (+) (Zuska disease) • IOC: Ductography • Treatment: If duct known • Microdochectomy • Unknown duct 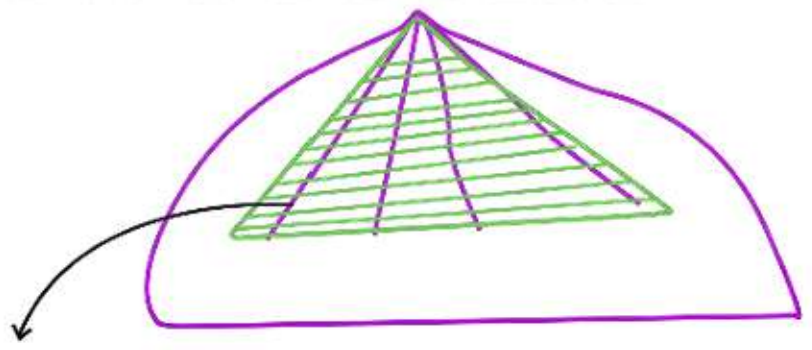 • Conical excision of all ducts • Hadfield operation (Radical approach) • Periductal mastitis

AfraTafreeh.com
DOC TUTORIALS LOGIN FOR SUCCESS

AfraTafreeh.com

ANDI 00:15:50

- ANDI → Aberration of normal development and involution
  - Non proliferative lesions
  - Proliferative lesions

Non proliferative lesions

1. Duct Ectasia
2. Fibroadenosis
3. Cystic disease
4. Apocrine changes

(1–4) — Not premalignant

Proliferative

No risk	Risk
1. Sclerosis	1. Atypical
2. Fibroadenoma	2. Ductal
3. Duct papilloma	3. Lobular
4. Radical scar	4. Epithelial hyperplasia

TUTORIALS LOGIN FOR SUCCESS

Fibroadenosis

- Disease of young females
- C/E: Lumpiness feeling (+); premenstrual fullness (+); painful cyclical mastalgia
- Treatment:
  - Reassurance
  - Danazol

- Tamoxifen
- Oil of evening primrose
- Vitamin E
- No surgery needed

Fibroadenoma 00:20:48

- Most common <30yrs
- Most common benign lesion
- Breast mouse
- No pain
- C/E: Indian rubbery (firm)
- Free movement
- >5cm – Giant

Peri-canalicular

- Most common type
- Most common in young
- Indian rubbery consistency
- Breast mouse
- Slow growing
  ↓
- Observe
- Excision
- Enucleate

Intra-canalicular

- 30-50 years age
- Soft in consistency
- Adherent to nearby tissues
- Rapidly growing
  ↓
- Excision

DOC TUTORIALS
AfraTafreeh.com
LOGIN FOR SUCCESS

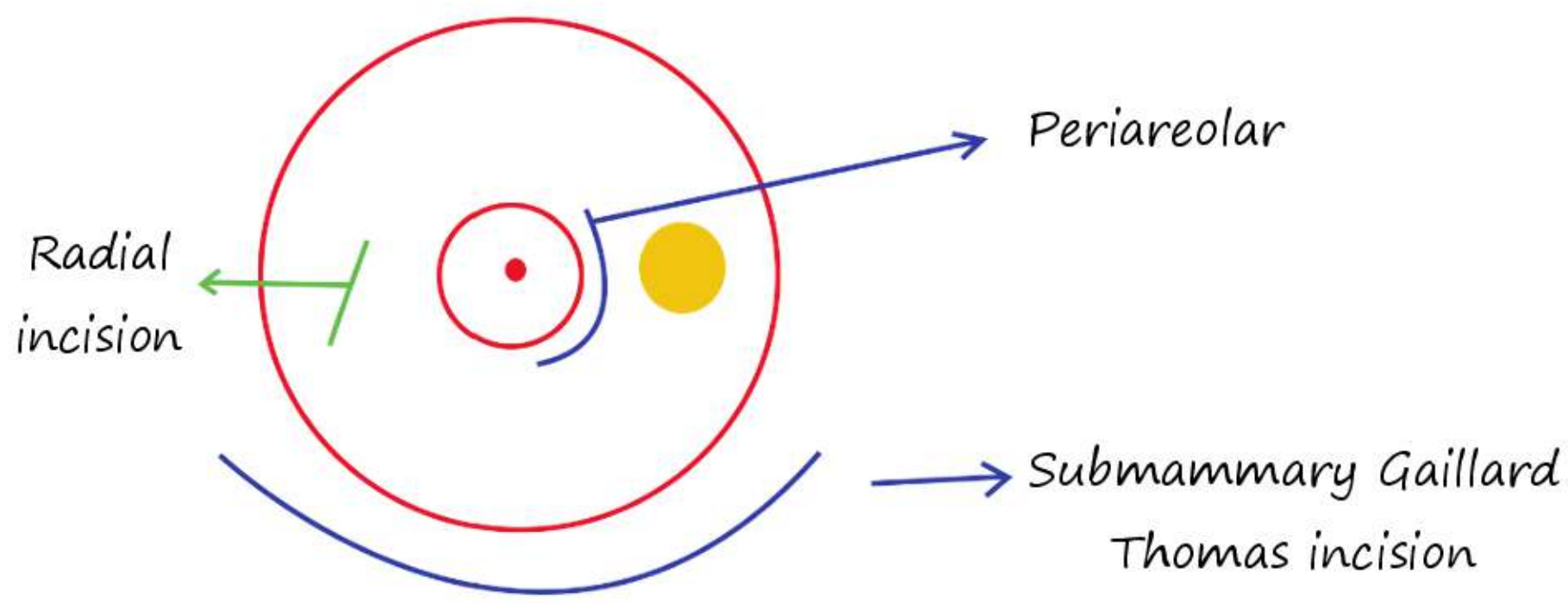

AfraTafreeh.com

- Enucleation > Excision
- Mammography: - Popcorn calcification

Mondor's disease 00:25:36

- Superficial vein thrombophlebitis over chest wall and breast

- Seen in both females and males
- Most common vein involved: Lateral thoracic vein
- Others: Thoracodorsal & Superficial epigastric vein
- C/F: Tender cord like (D/D: malignant infiltration)
- Treatment: Restrict movements

  Excision can be done

TUTORIALS LOGIN FOR SUCCESS

Phyllodes tumor 00:27:25

- Also known as Cystosarcoma phyllodes
- Origin: Intervening supporting tissues



Leaf like appearance

- USG: Cystic spaces (+) (+)
- Benign (m/c)
- Borderline
- Malignant
- No lymph nodes involvement
- No need lymphadenectomy
- Treatment wide local excision
- Simple mastectomy

Gynecomastia 00:29:46

- Enlargement of male breast

Simon's grading

I mild

II moderate

IIa

IIb – skin redundancy

III severe

Ptosis ++

skin redundancy (+)

Causes

- Physiological (m/c)
  - ↓ Puberty
- Pathological
- Drugs

AfraTafreeh.com

AfraTafreeh.com

Pathological

Estrogen ↑	↓ Androgen	Testicular failure
- Testicular tumors	- ACTH deficiency	- Orchitis
- Endocrine	- B/L orchidectomy	- Trauma
- Cirrhosis	- Hypogonadism	- UDT
- Klinefelter		- RT
- Testicular Feminization		

Drugs (DISCKO-FM)

- D: Digitalis
- I: INH
- S: Spironolactone
- C: Cirrhosis
- K: ketoconazole
- O: Estrogen
- F: Flutamide/Frusemide
- M: Metronidazole

TUTORIALS
LOGIN FOR SUCCESS

Management:

- Testosterone
- Danazol
- Treatment of cause
- Surgery: Webster's operation

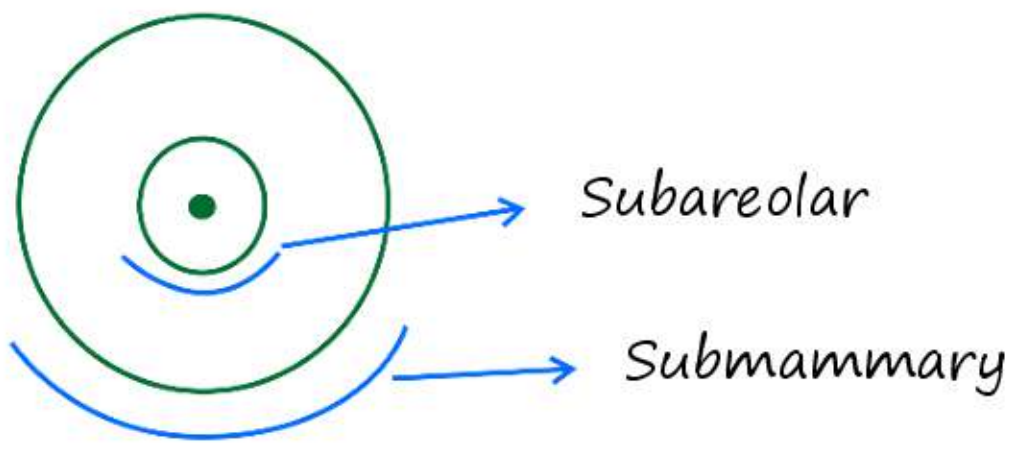

- Liposuction done now a days

Mastitis – Breast abscess 00:36:45

Mastitis	Brest abscess
• Most common cause: Staph. aureus • Lactating women ↓ Treatment: Injection cloxacillin	• Fluctuation (+) • Tenderers (+) • Pain (+) • Fever (+) • Chills/rigors • Treatment: Repeated aspiration under USG • No need I & D

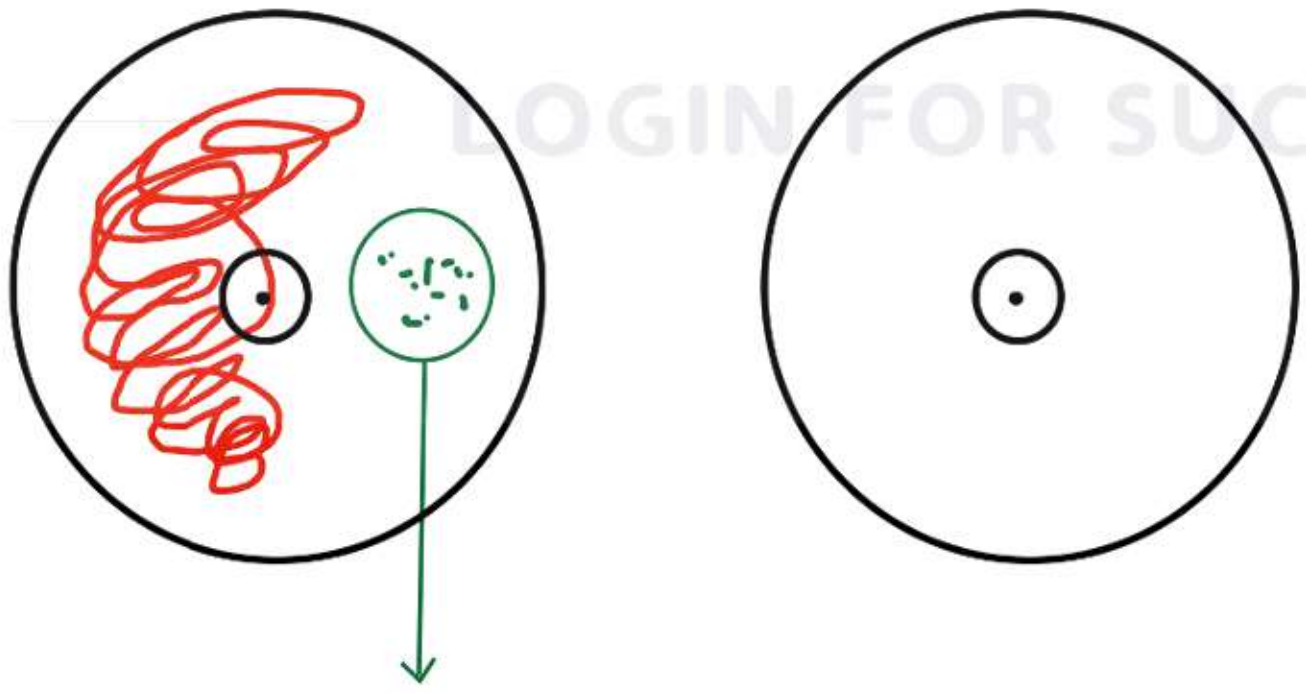

Suck the milk with breast pump
↓
No feeding from infected breast

AfraTafreeh.com
TUTORIALS
LOGIN FOR SUCCESS

AfraTafreeh.com

Summary: 00:39:52

- Tennis racquet incision – Microdiscectomy
- Hadfield operation – Zuska disease
- Webster operation – Gynecomastia
- Fibroadenoma (Peri canalicular) – Enucleation > Excision
- Phyllodes tumor – Simple mastectomy wide local excision
- Mondor's tumor – Most common lateral thoracic vein
- Simon's grading – Gynecomastia

TUTORIALS
LOGIN FOR SUCCESS

HERNIA INTRODUCTION

Basics in Inguinal Hernia 00:00:21

- Inguinal ligament extends from ASIS to pubic tubercle

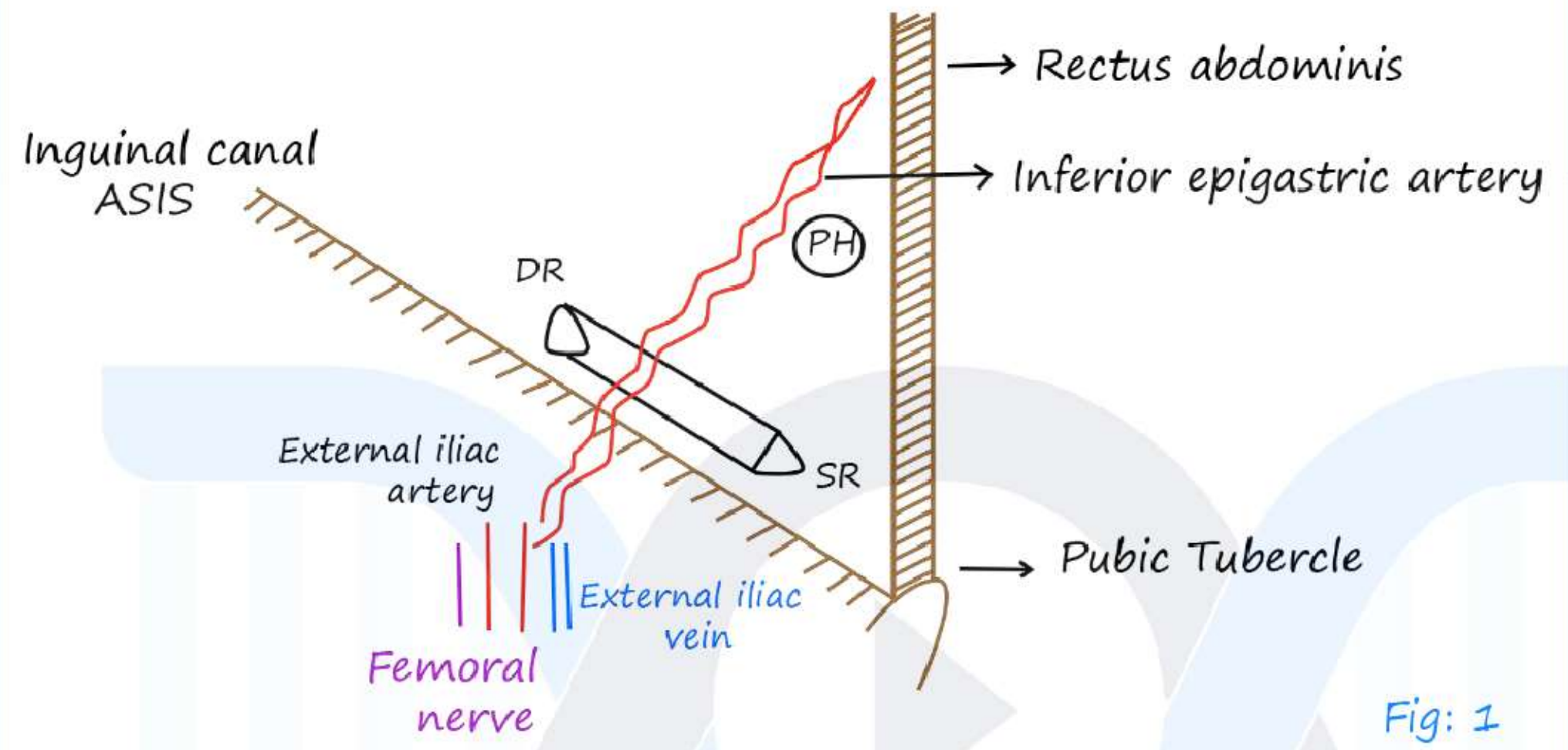

Fig: 1

- The deep ring is a semi oval shaped situated ½ inch above the mid-inguinal point (from ASIS to pubic symphysis) whereas, midpoint of inguinal ligament → B/W ASIS to Pubic tubercle
- Deep ring (semi-oval shaped) is a defect in fascia transversalis layer
- Superficial ring (triangular shaped) is a defect in external oblique aponeurosis. It is seen just above and lateral to the pubic tubercle.
- It is a canal from deep ring to superficial ring called inguinal canal. Inguinal canal length is 3.7 cm it is also called Bassini's house.
- The triangle from which direct hernia comes out is called Hasselbach's triangle boundaries are

AfraTafreeh.com

1.Rectus abdominis medially

2.Inferior epigastric artery laterally

3.Inguinal ligament forming the base.

- Through this only we get direct inguinal hernia.
- The direct hernia – hemi spherical shape/globular shape.
- Indirect inguinal hernia enters through deep ring & comes out through superficial ring. So, it appears in pyriform shape.
- Medial to lateral → VAN

  External iliac vein, external iliac artery, femoral nerve
- Here, there is a femoral sheath engulfing them forming 3 compartments
- **Femoral canal** is formed in medial most compartment.

  ↓

  It has superiorly one opening and inferiorly one opening through this femoral hernia comes.
- Femoral canal is 1.75 cm in length. It is bounded by

  a. Superiorly by femoral ring – Femoral hernia enters through it.

  b. Inferiorly by saphenous opening

  Through which hernia comes out.

  The line which prevents femoral hernia to go further down is called **Holden's line.** So, the femoral hernia turns up and taken the shape of RETORT shaped hernia.

- Holden's line → Attachment of deep membranes layer of superficial fascia with the deep fascia of thigh.
- Boundaries of femoral canal
  - Medially – lacunar ligament
  - Posteriorly – Ilio-pectineal ligament of cooper's
  - Anteriorly – Inguinal ligament
  - Laterally – by femoral vein
- Content of femora canal is Cloquet's L.N/Rosenmuller's L.N → Deep inguinal L.N
- In femoral hernia surgery, we will approximate inguinal ligament with iliopectineal ligament of cooper.
- In inguinal hernia surgery, we approximate inguinal ligament with conjoint tendon above with a mesh. Conjoint tendon is formed by internal oblique and transverse abdominis muscle.

TUTORIALS
LOGIN FOR SUCCESS

Surface landmarks – (of all these openings)

00:11:10

1. Deep inguinal ring → ½ inch above mid inguinal point
2. Superficial inguinal ring → above and lateral to pubic tubercle
3. Saphenous opening → Below and lateral (4cm) to pubic tubercle.

AfraTafreeh.com

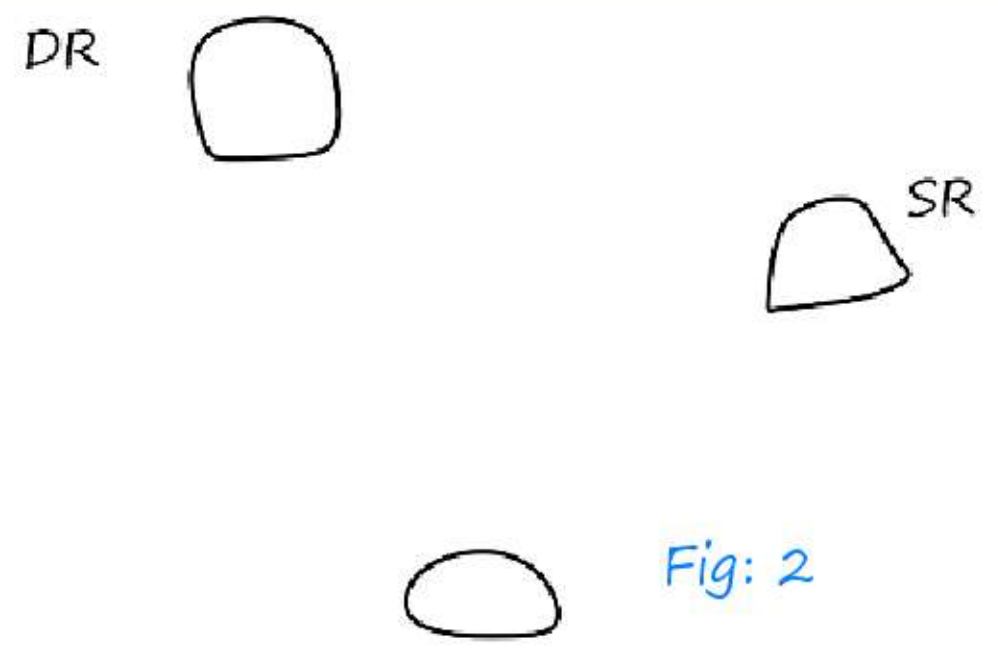

Fig: 2

Saphenous opening

- In 3 finger test (Ziemann's 3 finger test)

  ↓

  place 3 fingers over these and feel for impulse
- If impulse felt at deep inguinal ring – indirect hernia
- If impulse felt at superficial inguinal ring – direct hernia
- If impulse felt at saphenous opening – Femoral hernia

Inguinal Canal 00:13:00

- In the canal, spermatic cord structures enter deep ring then into SR and then into testis.
- Along with spermatic cord, we have ilioinguinal nerve and iliohypogastric nerve.
- Spermatic cord contains 3 arteries, 2 veins, 1 nerve & 1 vas
  - Artery to vas
  - Artery to cremaster
  - Testicular artery
  - Pampiniform plexus of veins
  - veins to vas/cresmaster

- Genital branch of genito-femoral nerve

- Direct hernial sac is seen posterior and medial to the cord structure.
- Anterior and lateral to the cord structures is indirect hernia.
- Medial to inferior epigastric artery, if hernia is + → Direct hernia
- Lateral to inferior epigastric artery → Indirect hernia
- If sac extending on both sides of inferior epigastric artery (medial as well as lateral) this hernia is called **pantaloon hernia** (combined direct and indirect)

DIFFERENCES BETWEEN DIRECT AND INDIRECT INGUINAL HERNIA:

AfraTafreeh.com

Indirect inguinal hernia	Direct inguinal hernia
• common in young age • Can be congenital (or) acquired • Due to preformed sac usually • most common in males	• Common in old age • Acquired only, not congenital (only congenital direct hernia - Ogilvie hernia) • mostly seen in males • Predisposed by some disorders i.e., smoking, increased abdominal pressure (chronic cough, bladder outlet obstruction (BOO), constipation, collagen,

AfraTafreeh.com

	vascular disease, mass in abdomen, ascites)

Note:-

- Obesity is not a predisposing factor of inguinal hernia
- Weight lifting is not a posing factor of inguinal hernia
  - (Previously they were risk factors)

Indirect	Direct
• course – It extends from deep ring to superficial ring, pyriform shape. • sac is seen anterolateral to cord structures • sac is found lateral to inferior epigastric artery • Indirect hernia can be many types 1. Complete – can come upto base of scrotum (called vaginal hernia) 2. Incomplete – can come upto root of scrotum (called funicular hernia) 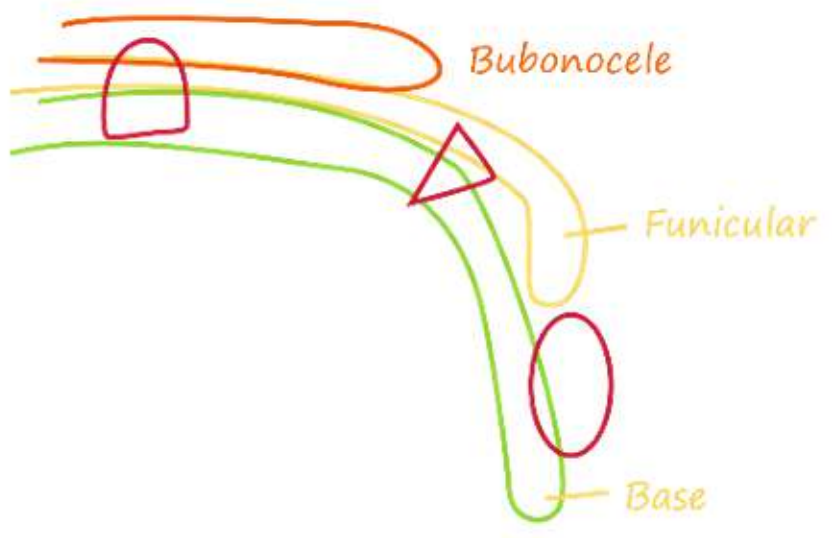	• Extends from Hasselbach's triangle to superficial ring • It is hemispherical/globular shape • Postero-medial to cord structures • sac is found medial to inf. epigastric artery • Direct hernia is usually incomplete hernia • Obstruction is very rare in direct, because Hasselbach triangle is a wide-open canal

- Coming only in the deep ring to superficial ring is called bubonocele (inguinal swelling) - Complications are most common - Irreducibility + obstruction is most common in indirect hernias Treatment – Indirect hernias are treated by herniorrhaphy, hernioplasty (Sac is excised)	Treatment – Direct hernias, we do only hernioplasty (sac is pushed back) into abdomen, not excised.

Anatomy of SAC 00:23:35

- (sac is nothing but the descending peritoneum)
- The peritoneum from abdominal cavity is descending into inguinal canal known as sac
- It has following parts
  - Mouth of sac
  - neck of sac
  - body of sac
  - fundus of sac
- Direct hernia is a neck less hernia. As neck is usually narrowest part, In direct hernia, there is no obstruction seen.
- In indirect hernia, the neck is constricted part and the bowel gets obstructed in this place.

Classification of Inguinal Hernias 00:24:49

1.NYHUS classification

- Type I – indirect hernia, with a normal ring.

AfraTafreeh.com

- Type II – Indirect hernia with a dilated ring
- Type III – Posterior wall weakness. It is divided into
  - a – Direct hernia
  - b – Pantaloon hernia
  - c – Femoral hernia
- Type IV – Recurrent hernia

2.Gilbert classification

- Type 1 – Indirect hernia – small size defect
- Type 2 – Indirect hernia – medium size defect
- Type 3 – Indirect hernia – large size defect
- Type 4 – Posterior wall defect – direct hernia
- Type 5 – Diverticulum type of direct hernia
- Type 6 – Pantaloon hernia
- Type 7 – Femoral hernia

3.European hernia society classification

- 1° hernia/recurrent hernia
- Lateral/Medial/Femoral hernia
- Defect of size should be measured → If defect is allowing on finger, it is 15cm (Defect – 1.5 =1 point)

↓

Defined as PL_2

↓

Primary hernia

Indirect hernia

Allows 2 fingers i.e. defect

Size is 3 cm

Clinical examination of Inguinal hernia 00:29:34

- First we have to know the content, is it bowel (or) omentum
- If content is bowel. It is called Enterocoele
- If content is omentum. It is called Omentocele

Omentocele-



Fig: 3

AfraTafreeh.com

Enterocele	Omentocele
• Feature is reducibility	• Usually omentum has an adhesion with the tip of sac
• Due to narrow neck, there is initially difficult in reducing, later it easily goes in, with a gurgling sound.	• Initially it will be easy to push last part is difficult to go due to adhesion

AfraTafreeh.com

• On percussion, over swelling resonance is found	• Dull on percussion
• Elastic consistency	• doughy consistency
• Visible intestinal peristalsis can be seen	• No peristalsis

Cough Impulse 00:33:28

- It is pathognomonic sign of inguinal hernia
- It is absent in
  1. Irreducible hernia
  2. Obstructed hernia
  3. Hernia with dense adhesions
- Make the patient lie down, keep the finger on dep ring and ask the patient to cough to feel the cough impulse at level of deep ring.
- Sometimes we also test cough impulse by holding the root of scrotum with 2 fingers thumb and index finger and palate. If we can palpate a sac and ask patient to cough, then we can feel the bowel/omentum coming out and pushing the fingers out.
- In hernia, the cough impulse Is projectile and expansile C.I
- In varicocele testis, also we get cough impulse, but it is not expansile. It is a thrill like impulse seen.

- In Saphena varix (varicose veins) also we get thrill like impulse

Named tests 00:35:57

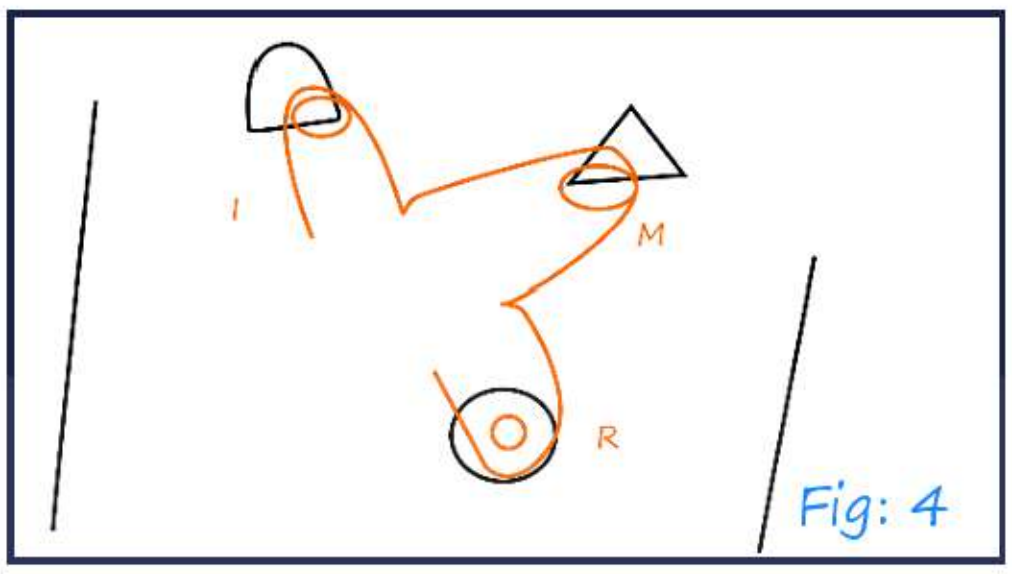

Fig: 4

1.Ziemann's test

- Examine right side with right hand and left side with left hand
- Note the impulse felt at deep ring indirect hernia impulse felt at superficial rim and direct hernia. Impulse felt at saphenous ring → Femoral hernia.

2.Deep ring occlusion test

- Only test done in OPD, in hospital
- After reducing, occlude the deep ring with thumb & ask patient to cough.
- If hernia/swelling Is not appearing, it is indirect hernia.
- If swelling appears, then it is direct hernia.
- It is false positive in cases → even on occluding, hernia/swelling seen.
- Big opening of deep ring, E.g → NYHUS – Type – 2

PL2

AfraTafreeh.com

Pantaloon Hernia

3.Finger Invagination test

- This test is C/I now a days, so don't do.
- It can be done only in males, not in females.
- We have to catch the scrotal skin and put the finger into superficial ring and examine the canal with index finger and now ask patient to cough.
- If we feel the impulse on the pulp of finger, it's coming from Hasselbach's triangle and it is direct hernia
- Here, posterior wall weakness can be tested
- Superficial ring pattern can be tested

  If S.R is lax, noted when the finger is entering

  If S.R is tight, it grips the finger entering
- Finally examine the abdomen for Malgagne's bulges
- These are B/L pyriform shaped bulges seen on lower abdominal wall. It implies there is weakness in abdominal wall muscles and it should be treated by Hernioplasty, don't do herniorrhaphy

27th Edition Bailey updates:

- Lumbar Hernia is the only hernia happening through natural weakness in the body. all other hernias are due to acquired defect.
- Surgical scar will not be a strong scar. It will have only 70% of the original strength (is obtained irrespective of duration of healing)

- Obesity and weight lifting are not risk factors
- The people with
  - collagen vascular disease
  - Elderly people
  - Pregnancy

  } ↑ risk of hernia

AfraTafreeh.com
TUTORIALS
LOGIN FOR SUCCESS

AfraTafreeh.com

HERNIA SURGERIES

Management of Inguinal Hernics: - 00:00:09

1.TRUSS → Old method, Hernia belt, not used now-a-days as it causes other problems. It is a belt which occlude the direct hernia/Indirect Hernia opening so that bowel will not come out. It can cause bowel adhesion erosion of bowel sometime. It can be used only in reducible hernias.

2.Herniotomy →

From deep ring, there is neck of the hernia sac, neck identified by narrowest lumen of sac and with a pre-peritoneal pad of fat.



Fig: 1

LOGIN FOR SUCCESS

At that point we put a trans-fixation suture using Vicryl / polyglatic acid and remove the part of hernia. This alone is sufficient for congenital Inguinal hernia and congenital hydrocoele, here no need to do Herniorrhaphy/mesh repair (only cut and transfix the sac

3.Herniorrhaphy: -

- In adults along with herniotomy + herniorrhaphy.

- Between conjoint tendon and inguinal ligament, there is posterior wall, which is having weakness. And posterior wall is made up of fascia transversalis.
- We have already cut and transfixed the hernial sac at deep ring (Herniotomy done)

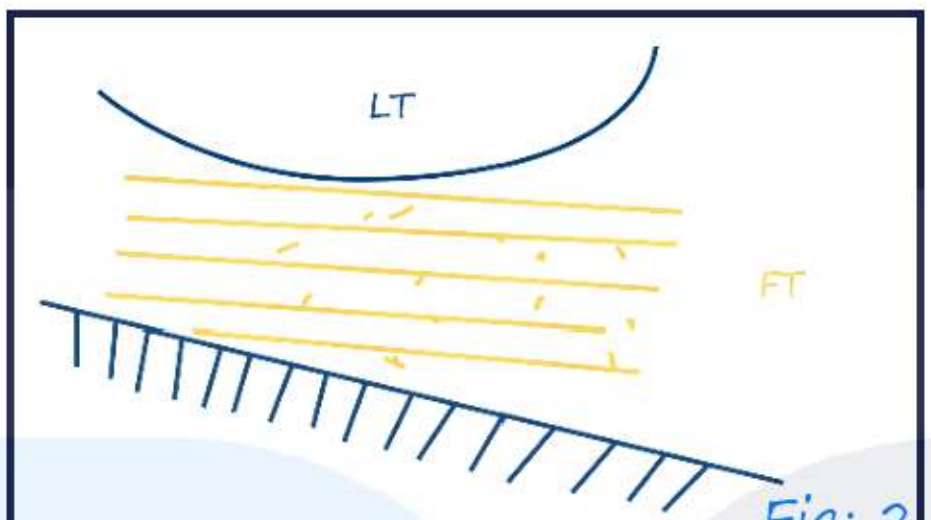

Fig: 2

- Then we will approximate between inguinal ligament and conjoint tendon using 1-0 prolene. It is a tight tension suture.
- It is called as Bassini's Herniorrhaphy.
- In original repair, Bassini's used intermittent sutures and did a layered sutures i.e., he anastomosed conjoint tendon with inguinal ligament, internal oblique with inguinal ligament, transverse abdominis with inguinal ligament, external oblique with inguinal ligament, He used silk.
- Now we are using modified Bassini's procedure where we do continuous prolene sutures for herniorrhaphy.

AfraTafreeh.com

AfraTafreeh.com



Fig: 3

- Now a days, new method called **Maloney's Darning procedure** is done, it has no tension at all. It appears like mesh. It has good benefit like mesh. (With some prolene we do design like thing)
- **Shouldice repair** →He cut the fascia transversalis into two and he did overlapping of fascia transversalis i.e., Double breasting of fascia transversalis.

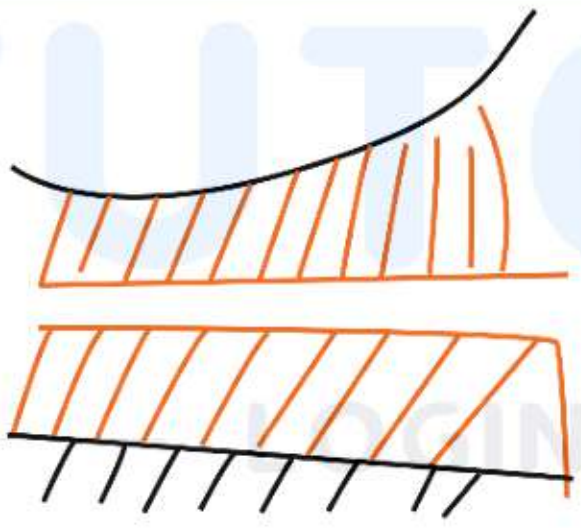

Fig: 4

- Mac vay's repair → Here conjoint tendon is approximated with Iliopectineal of cooper. It is very tight repair. It can treat both inguinal and femoral hernia.
- None of these procedures are done now.
- Now a-days we are using **Lichtenstein's tension free repair hernioplasty.** It is a gold standard surgery.

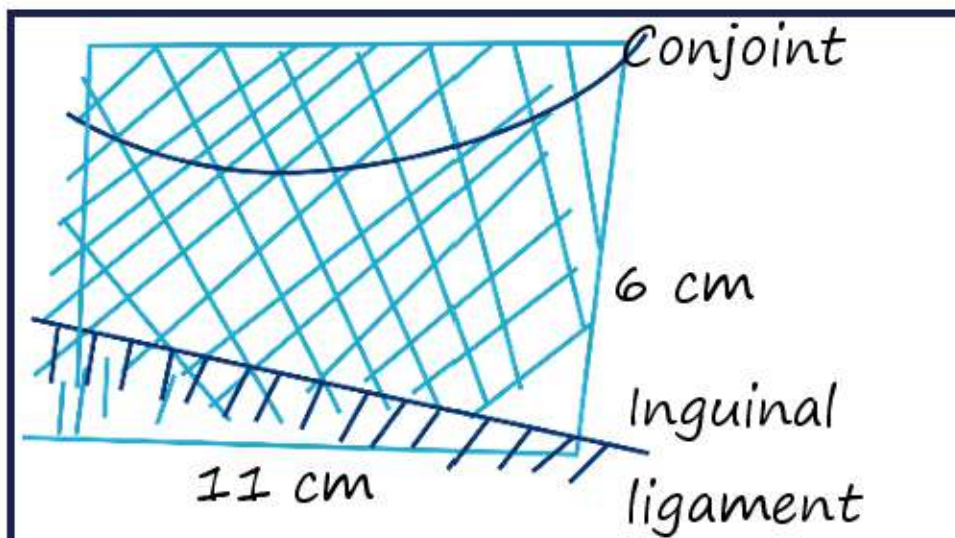

Fig: 5

- Here we place a mesh between conjoint joint and Inguinal ligament. Mesh size depend upon patient, but it should be minimum 6×11cm for Indian patients post wall is strengthened by the mesh.
- Lytle's repair → narrowing of the deep ring
- Lytle's repair →After some cases like Macray's and some old type repairs, there will be severe tension because of approximation of conjoint tendon with Inguinal ligament.
- In such cases, we do incision an anterior reches sheath, so that the tension is relieved. This is called relaxing incision on anterior rectus sheath.

TANNER'S SLIDE

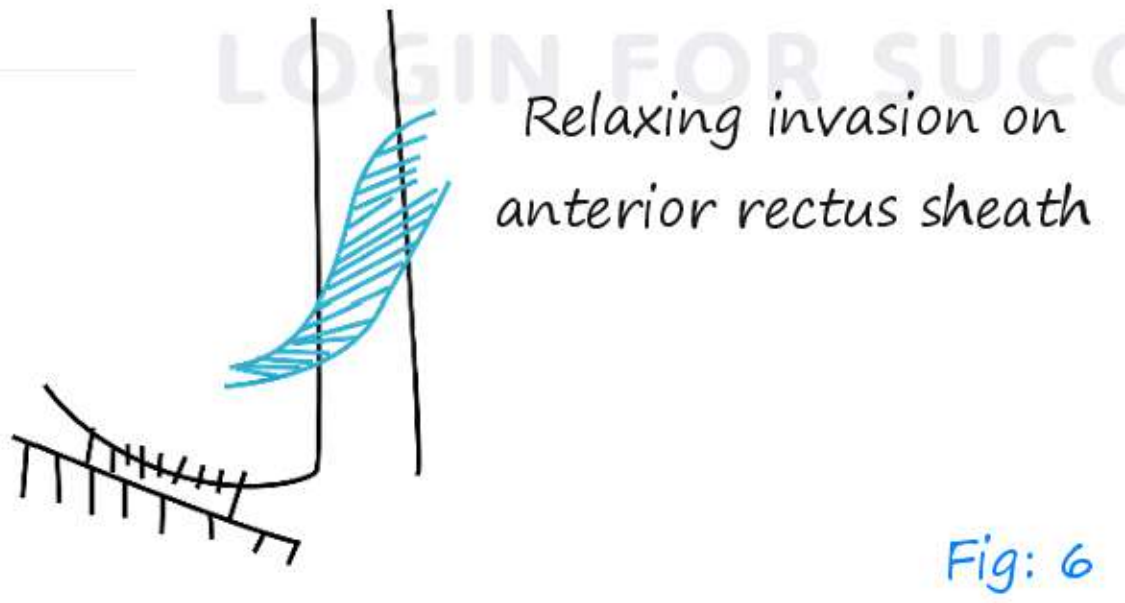

Fig: 6

- Previous due to tension person bends sideways while walking after relaxing incision, he can walk straight.
- <u>Gilbert's Plug Mesh</u>: - Here a mesh plug is kept inside the hernia defect.

AfraTafreeh.com

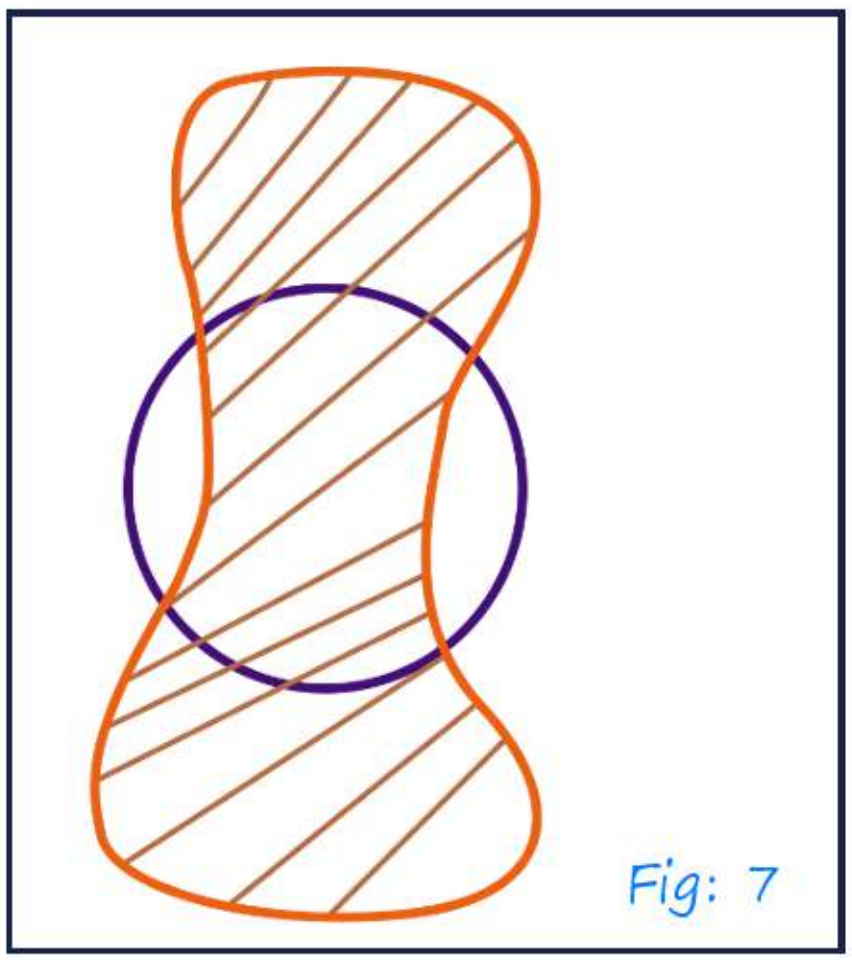

Fig: 7

Femoral Hernia surgeries 00:11:32

- Most common in females
- In females, indirect hernia is most common.
- Operation in femoral hernia is to approximate inguinal ligament with iliopectineal ligament of cooper, by a mesh (or) a suture.

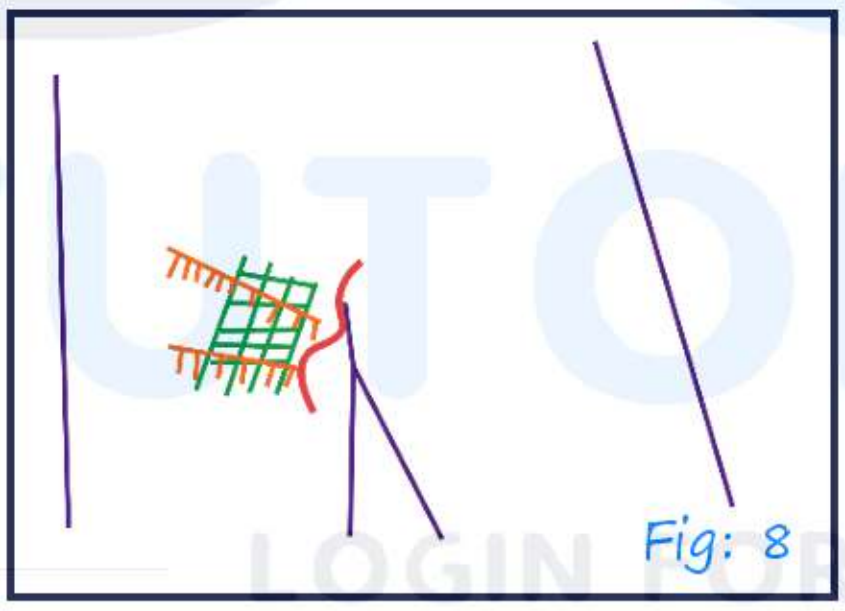

Fig: 8

- We should be very careful in cutting the lacunar ligament b/o an artery running near it called Abnormal obturator artery.
- Many times femoral hernia present with obstruction at that time we have to cut lacunar ligament,
- We have 3 approaches to do this repair/op

  1.High approach of McEvedy

  - We put a vertical incision

- Advantage here is if the bowel is found gangrenous we can do laparotomy and go inside, so it is mainly used for strangulated hernias.

2.Inguinal approach Lothiessen: -

- In obstructed femoral hernia cases, incision is like inguinal canal is put ½ inch above inguinal ligament.

3.Low approach of Lockwood: -

- Is done only for uncomplicated femoral hernia,
- Incision is put along groin crease.

Modified Henry's procedure 00:16:00

- New operation for femoral hernia.

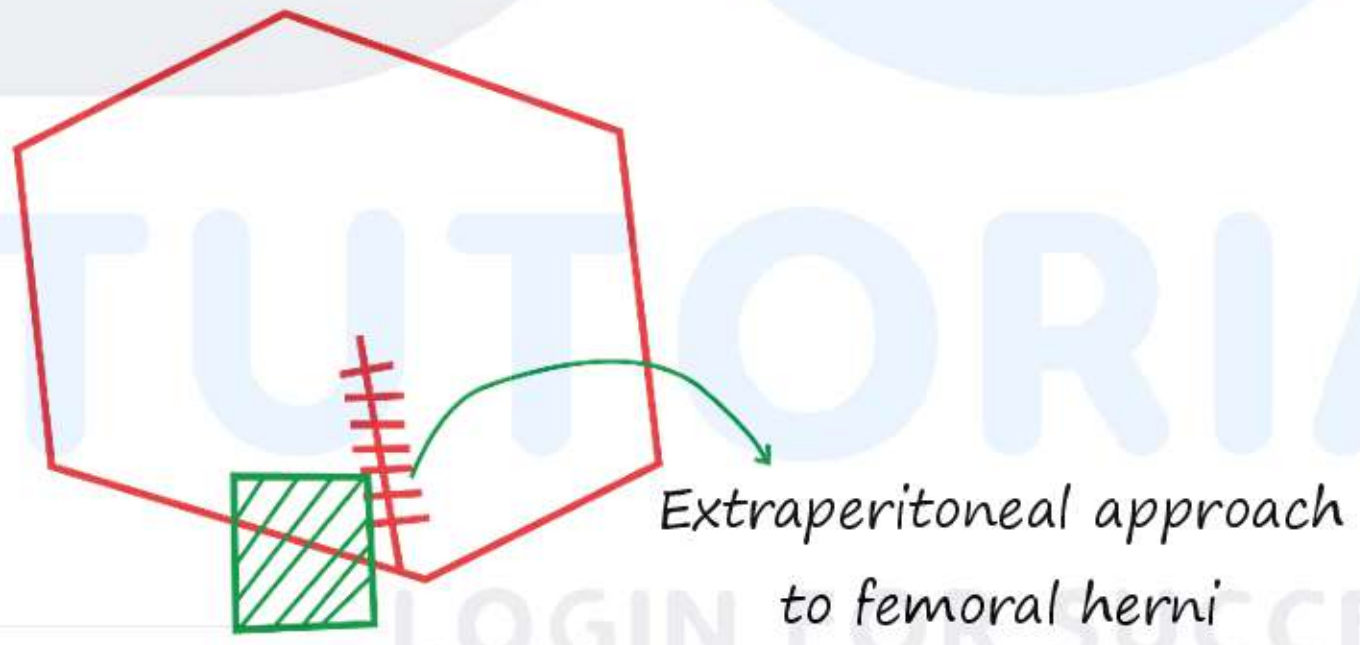

Fig: 9

- Put a midline incision in lower abdomen and approach the femoral hernia by an extra peritoneal approach to femoral hernia and keep a mesh inside
- It is same looking like TEP operation, TEP is a laparoscopic operation.

AfraTafreeh.com

Giant prosthetic reinforcement visceral surgery: - (GPRVS) 00:17:28

- Here we put a pfannenstiel incision and groin side, pre peritoneally and keep a huge mesh in front of pre peritoneum.

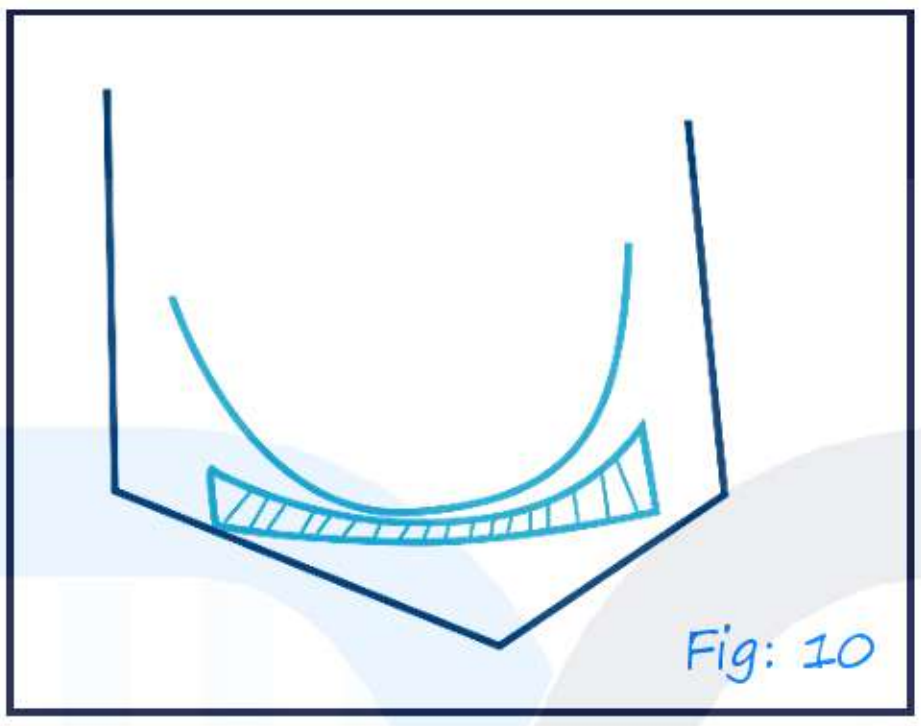

Fig: 10

- Intra-abdominal pressure exerting on it will act as suture (Intraperitoneal pressure prevents hernia from coming out) No suture required.
- This procedure is k/as **STOPPA's procedure**

Hernia operations

Conservative	**Herniotomy**	**Herniorrhaphy**	**Hernioplasty**
↓		↓	↓
TRUSS		- Bassini's	- Lichtenstein
		- Shouldice	- Gilbert
		- Darning	- Stoppa's
		- Macvay	- Henry

- Femoral hernia operations → Most common McEvedy
  Lothiessen
  Low Lockwood

MESH: -

- Mesh can be 1. NET – Knitted mesh (or) woven mesh

  2. Sheet mesh.
- Net mesh is having gaps, so no need of sutures, through these gaps the tissue will in grow and get fixed (adherence)
- Sheet mesh has no gap, so it has to be fixed by sutures, poor adherence.

Materials used in mesh

1. Poly propylene mesh: - Most common used, white in color, knitted mesh usually fixed by 2-0 prolene sutures, poor adherence.
   - Sometimes, Tackers can be used, in case of laparoscopic operation. Tackers are titanium clips/staple pins which fix the mesh with wall.
   - Poly propylene is hydrophobic, not allows bacteria to enter, so, less chance to get infected.
2. Polyester mesh: -
   - It is also non absorbable, but it is hydrophilic. Also knitted mesh.
   - It absorbs water and bacterial growth will be more. Anti-inflammatory cells also infiltrate, they remove bacteria.
3. PTFE Mesh: - poly tetra fluoroethylene

AnuTafreeh.com
TUTORIALS
LOGIN FOR SUCCESS

AfraTafreeh.com

- It is a sheet type mesh. So, there is no tissue ingrowth.
- So, used as non-adhesive barrier between tissues.

4.Polyglycolic acid mesh (Vicryl mesh)

- It is not used alone. It is used as Dual mesh.
- Surface facing abdominal wall is made of prolene.
- Surface facing abdominal cavity is made of Vicryl (or) PTFE, So bowel and all will not adhere.

Weight of mesh: -

1.Light weight mesh < 40 gm/m2

- It has better tissue integration.
- It has large pores.
- It has better comfort for patients.
- Less shrinkage will be seen.
- **Mesh of choice is light weighted mesh.**

2.Heavy weight mesh > 80gm /m2

- Increased contraction.
- Less tissue integration.
- Less pores
- Discomfort to patient.

Biological mesh: -

- Derived from natural material.
- Are used in exposed abdominal wall and places where we need a temporary closure. Neovascular growth and collagen deposition is stimulated in this.

E.g.: - Human/animal dermis is used
Bovine pericardium
Porcine submucosa

- It is used only in non-infective area.
- It is C/I in infective area as it dissolves.
- In tight abdomen closures we do laparostomy, abdomen is opened, but not infected, here we can keep this mesh.
- It is not adherent to bowel; it allows tissue to grow superficially.
- Main use of biological mesh is in open abdomen like burst, laparostomy.

Absorbable mesh → made up of polyglycolic acid/vicryl mesh.

- It can be used for temporary abdominal closure like in burst abdomen.
- It can be used in Dual mesh / tissue separation mesh.
- Inner side(visceral) is made up of prolene and other side(skin) is made up of vicryl
- It can be vicryl / collagen / PTFE /Cellulose.
- These have less bowel adherent property.

AfraTafreeh.com

Mesh Placement Anatomy: - 00:32:04

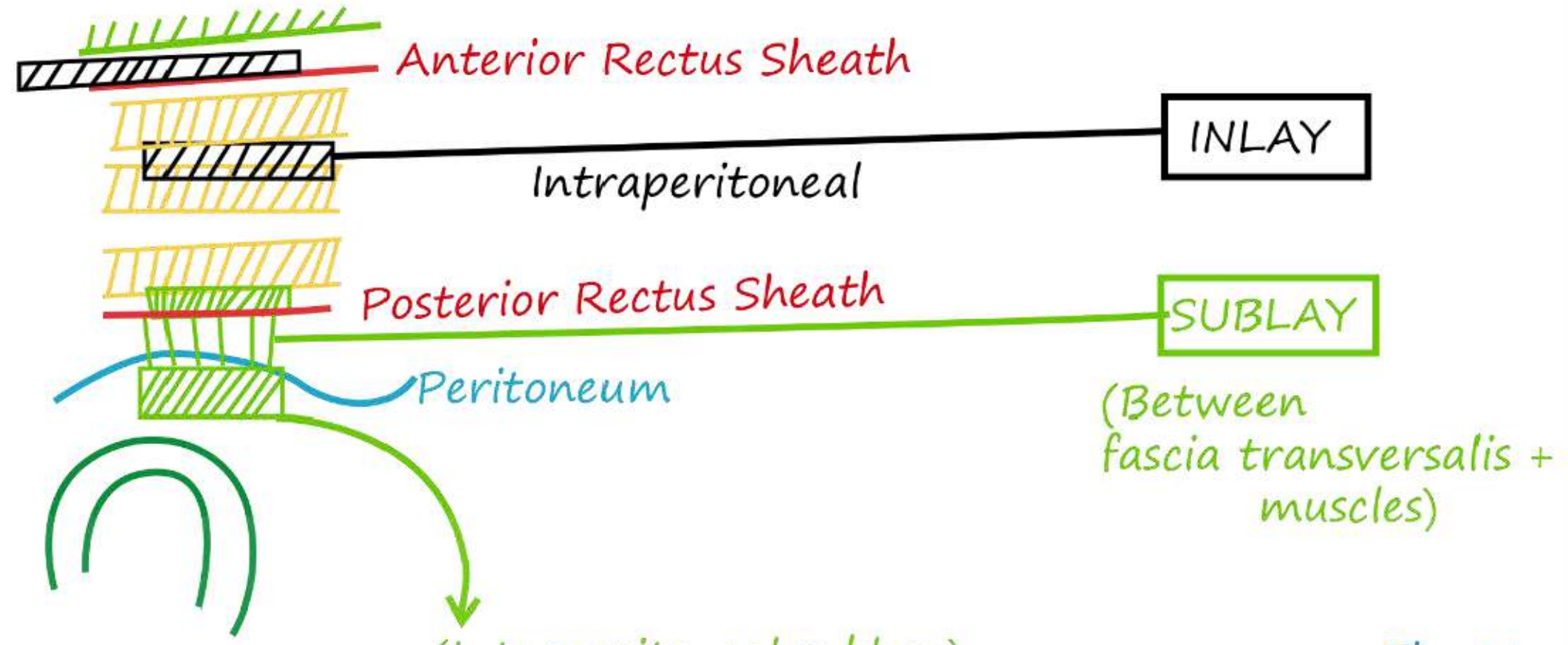

Fig: 11

- **Onlay mesh** → is kept anterior to anterior rectus sheath. It is commonly done.
- **Inlay mesh** → can be two types

a. **Inter parietal mesh** → between the muscles

b. **Sublay mesh** → It is kept between posterior rectus sheath and muscles. It can be two types,
  - Between fascia transversalis and muscles.
  - Intraperitoneal sub lay mesh → one side is exposed to peritoneum.
    - Other side is facing towards abdominal wall. So, this should always be a dual mesh only.

IPOM → Intraperitoneal onlay (sublay) mesh

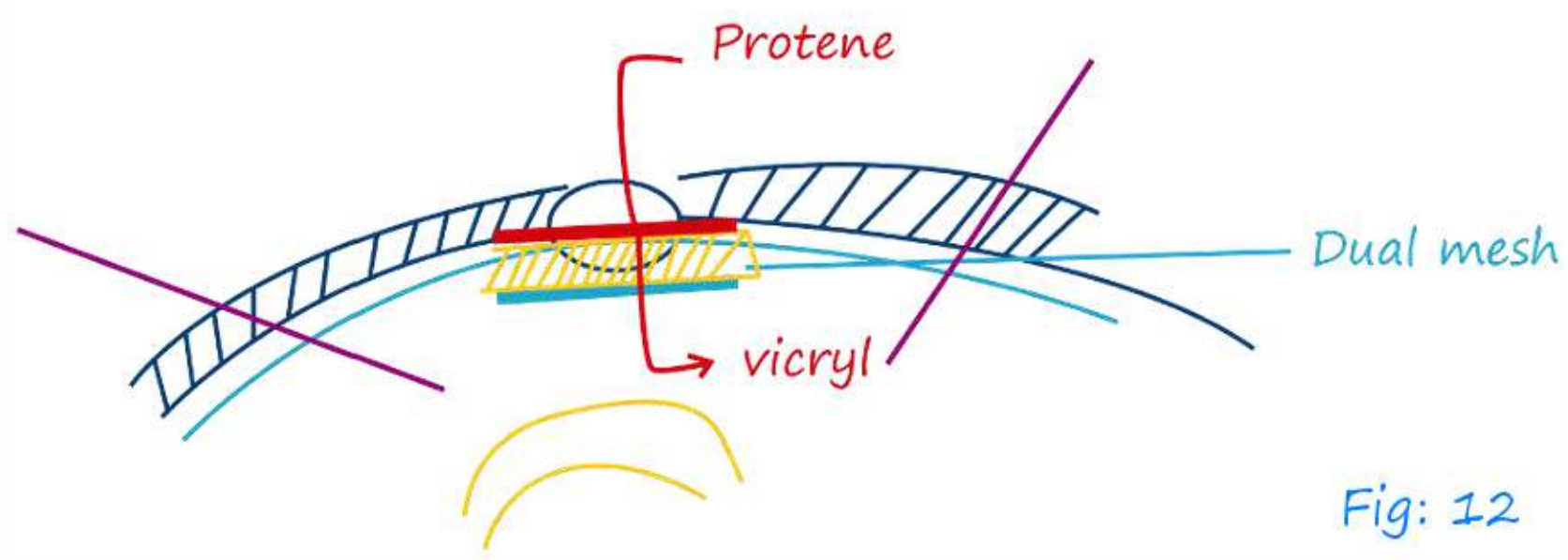

Fig: 12

- We go inside by laparoscopy, resect hernia and keep mesh, one side facing the bowel, other facing towards abdominal wall.
- It is called TPOM.
- It should be done a dual mesh, prolene on outside, vicryl on inside.
- Costly mesh 15000 to 20000.

AfraTafreeh.com

Complications of Hernia Surgery 00:40:50

- Open Hernia Surgery
  - Most common injured nerve – Ilioinguinal nerve. By this, there is paresthesia in anterior 2/3rd of scrotum in males and labia majora in females.
  - Hematoma
  - Infection
  - Neuralgia – nerves can be trapped in the sutures
  - Testicular atrophy

AfraTafreeh.com

- Recurrence are most common in direct hernia repairs. Most common near the floor.

Lap Hernia Operation

- Most common nerve injured – Lateral cutaneous nerve of high

TUTORIALS
LOGIN FOR SUCCESS

TYPES OF HERNIAS

Sliding inguinal hernia 00:00:18

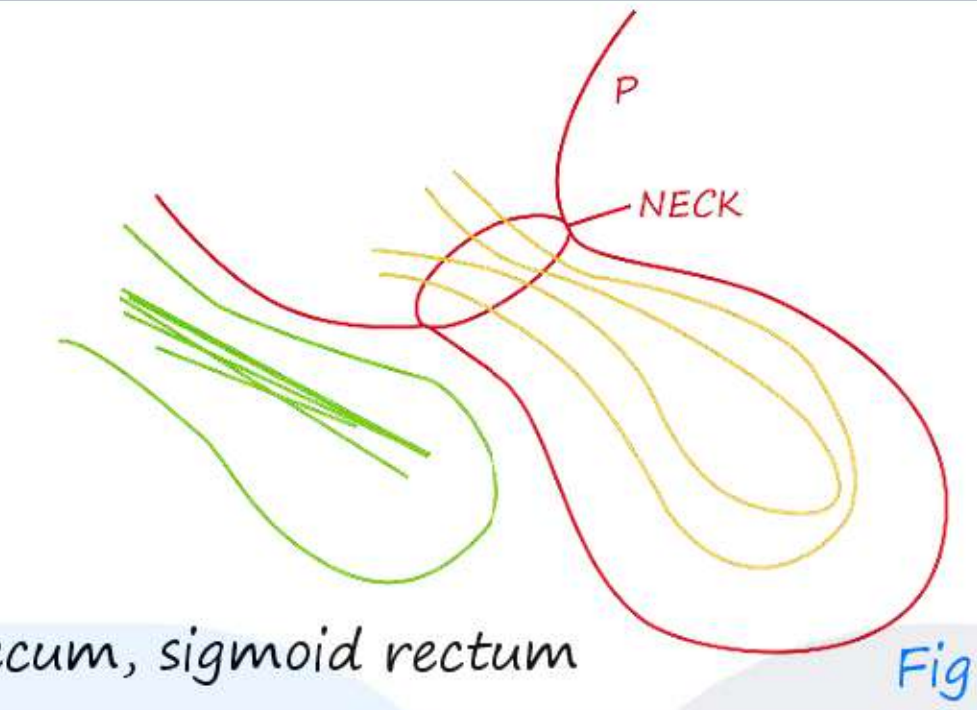

Fig: 1

- It is an indirect hernia, with bowel contents in peritoneal sac
- If some retroperitoneal structures are descending down along with the sac like caecum on (R) side, sigmoid colon on (L) side or rectum – It is called sliding inguinal hernia
- It is most common on (L) side (But indirect inguinal hernia is most common on (R) side)
- Most common content seen here is sigmoid colon
- It is usually a massive hernia
- Treatment: In this case don't dissect, no dissection between sac and retroperitoneal structure because it can injure retroperitoneal structures (Posterior dissection avoided)

AfraTafreeh.com

Maydl's or W shaped hernia 00:02:49

- The bowel in side sac looks like W (As it comes in sac leaves and again comes and leaves)

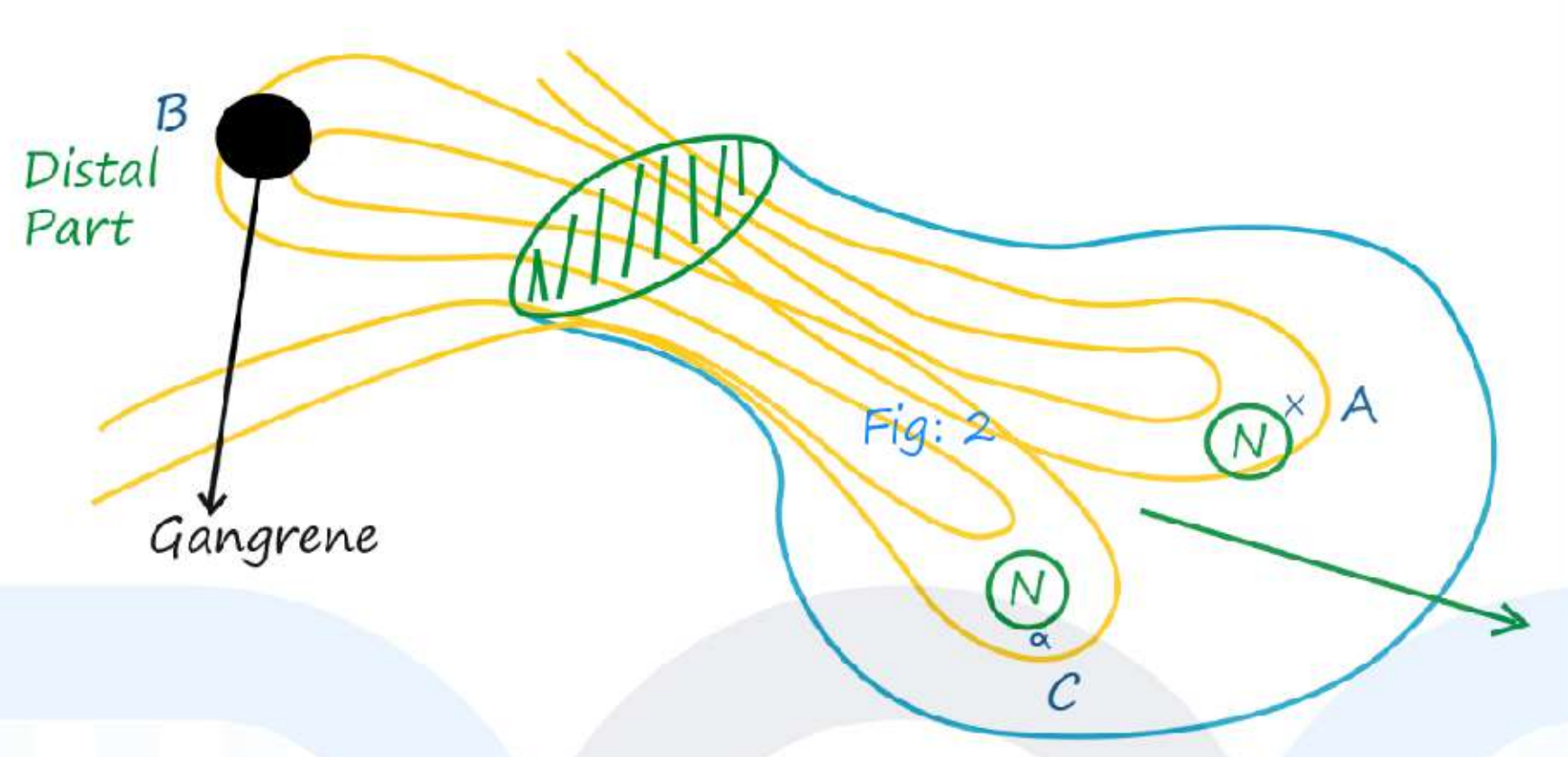

RETROGRADE Strangulation

- For E.g., if there is obstruction at the neck of sac the most distal part which is B, which is inside abdominal cavity
- Generally, on treatment we open sac the bowel in sac if its normal we push it into abdomen and close the abdomen
- In case of Maydl's the inside most dilated part may develop gangrene in case of ischemia so we must pull the entire bowel and see/Check for any gangrene/ischemia (Explore the entire bowel)
- If it is not identified and closed then patient appears again with gangrene in the bowel. This is called **retrograde strangulation.**

Richter's hernia 00:05:33

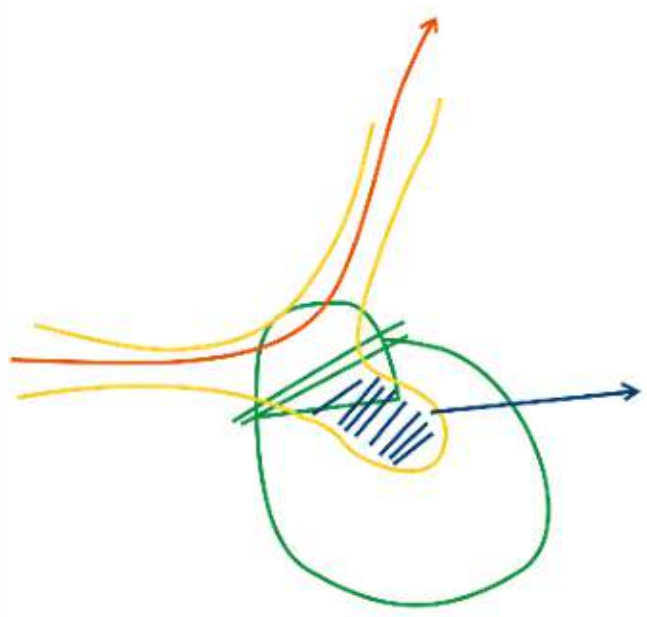

Fig: 3

- In the neck of the sac on part lumen (or) one part of circumference of bowel is obstructed so here there is no obstipation seen
- Clinical features: Diarrhea is seen
- It is most common in femoral hernias

AfraTafreeh.com TUTORIALS LOGIN FOR SUCCESS

Scrotal abdomen 00:06:54

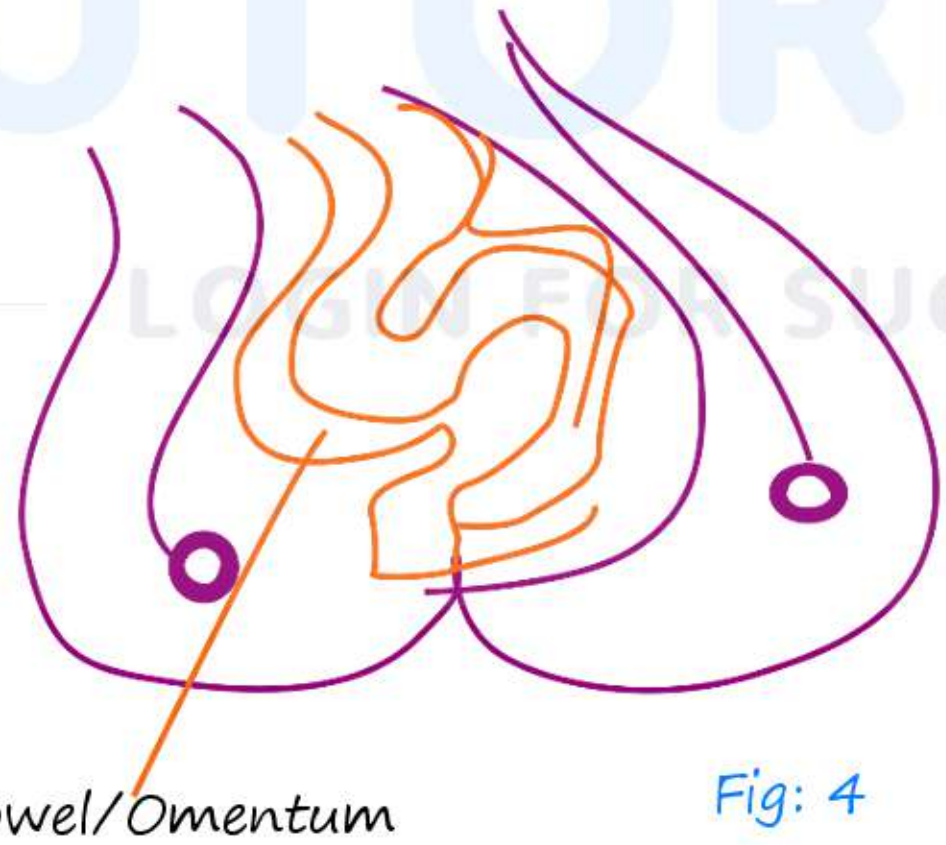

Fig: 4

- Here the scrotum is very much enlarged testis is normal on both sides enormous amount of small bowel is seen in scrotum
- It is usually an indirect hernia a complete hernia

AfraTafreeh.com

- It can be associated with sliding hernia
- Hernias can go for 3 complications

  1.Irreducibility

  2.Obstruction

  3.Strangulation

Irreducibility

- Taxis is a procedure of reducing hernia which is coming out which can be done in children. In adults it is c/I because we can compress the bowel with obstruction inside, so it may lead to gangrene of bowel inside abdomen.
- In Children, we do, ask patient to lie down supine, flex the hip and medial rotation of hip done. Automatically the canal opens up and bowel goes in – It is called Taxis.
- When hernia is not reducible, it is irreducible hernia. irreducible Hernia may be obstructed (or) may not be obstructed.

TUTORIALS LOGIN FOR SUCCESS

Obstruction:

- In obstructed hernias, patient have pain, vomiting, obstipation and abdominal distension are seen.
- Here cough impulse is negative in obstructed bowel.
- Obstructed bowel still has a good blood flow. But if we don't manage in correct time it goes for obstruction

Strangulation:

- Strangulation is loss of blood flow to the bowel, results in gangrene (worst complication)
- It is irreducible obstructed, loss of blood supply.

Management of strangulated / obstructed Hernias –

- Incision is to be inguinoscrotal
- First fundus of sac is opened.
- Let out toxic fluid
- Examine bowel, if it is pink and mesenteric vessel pulsations seen, then bowel is good.



AfraTafreeh.com

- If peristalsis present in bowel means it is a normal bowel and we push back bowel and proceed as usual
- When bowel blue in color

  No peristalsis ⎤ The bowel may be gangrene
  Mesenteric pulsations absent ⎦

- Then first given 100% O2 and keep warm pad over bowel after cutting the superficial/Deep ring and relieve obstructed part
- If blue cover changes into pink then bowel should be resected
- If not turning into pink the n bowel should be resected

Gaps in the inguinal region causing hernias:

- Laguier hernia – A defect in lacunar ligament through which hernia comes out
- O'gilvie hernia – A defect in conjoint tendon ligament it is the only congenital direct hernia
- Beclard hernia – Defect in the saphenous vein opening (Femoral type)
- Norath hernia – A type of femoral hernia occurring in the defect due to congenital dislocation of hip (CDH)
- Berger's hernia – Hernia in to pouch of Douglas, AKA sigmoidocele

Internal hernias 00:17:17

- Peterson hernia
- Hernia of bowel behind the Rouy limb going for obstruction is Peterson hernia

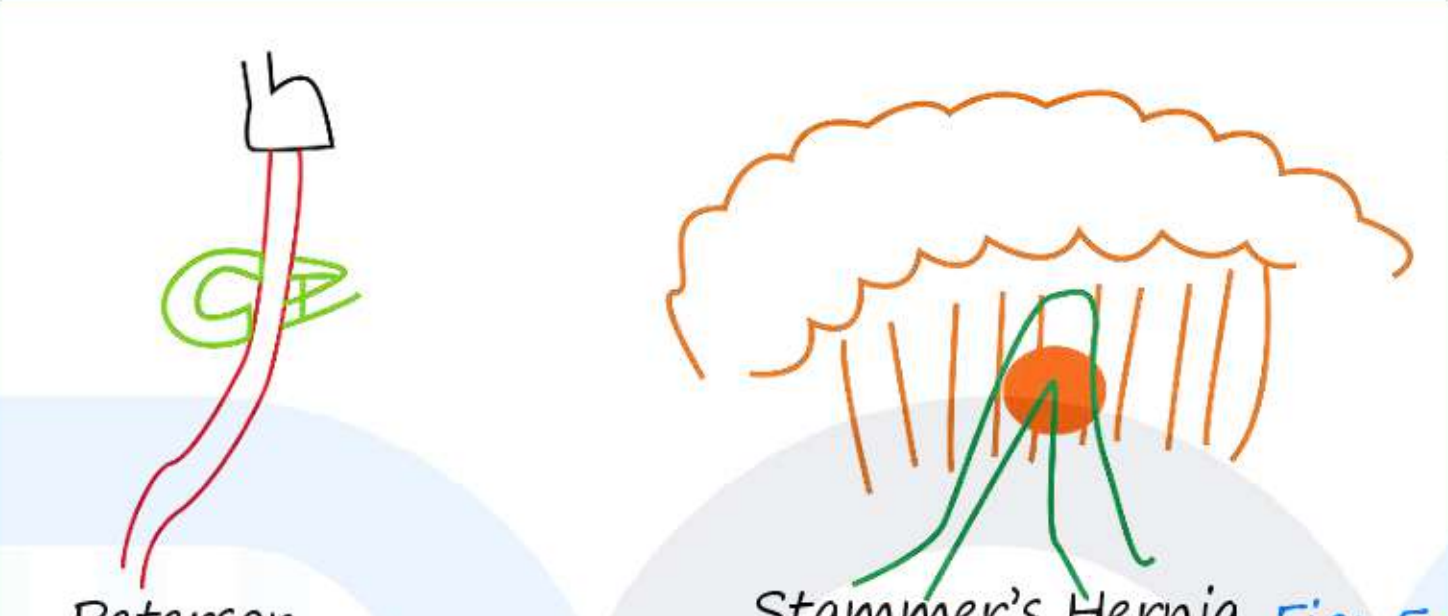

Fig: 5

Stammer's hernia

- Herniation through the defect in the mesentery of transverse mesocolon. The bowel goes inside the defect.
- Through mesenteric defects, we can get Internal hernias
- Through epiploic foramen.
- Para duodenal hernias. 1
- Sportsman Hernia - No swelling seen & No cough impulse seen.
- Patient will complain of pain in the Inguinal region, which radiates to scrotum (or) upper thigh.
- D/D for this is → Gillmore groin (inflammatory pain in inguinal region) Adductor tendon rupture

AfraTafreeh.com

- C/F Young men players. who are Rugby (or) football players?
- At deep sing there is the beginning of Hernia happening. The sac is coming inside, the getting pain. 2014 is
- Latest Toc – MRI
- (Previous Toc Heliography Inject contrast inside abdomen cavity and take a lateral x-ray in which a small hernia sac can be seen entering the deep ging.
- It cannot be found in USG, because only sac is penetrating, there are no contents.
- After sometime, sac become big and contents come.
- Treatment- Laparoscopic repair.

Ventral hernias

- Femoral and Inguinal hernia are not considered (or) not included as Ventral hernia.
- Ventral hernia are:

TUTORIALS LOGIN FOR SUCCESS

1.Epigastric Hernia of Linea alba

2.Umbilical Hernia and paraumbilical hernia

3.Incisional Hernia

4.Parastomal

5.Spigelian

6.Traumatic

7.Lumbar hernias are also included by mistake

Umbilical hernia 00:24:42

- Can be seen in paediatric as well as adults.
- Paediatric umbilical Hermia is m/c. Here, there is a congenital defect in umbilical ring.
- Defect is not fight; no strangulation happens.
- No need to operate immediately, we can wait and watch for 2 years (according to Bailey and love) & Surgery can be done at 2 years
- As per sabiston we can wait for up to 5years
- Pant on vest repair (Mayo's repair) is done for it previously
- Now a days anatomical repair is done
- In adults there are causes of weakness of umbilical ring and hernia starts at this time
- Umbilicus is tight and a bulging is seen → strangulation can happen if tight
- If it is <2cm – we can wait and watch
- If >2cm – better go for surgery – Like mayo repair, open anatomical repair lap repair

Epigastric hernia of Linea ALBA 00:28:23

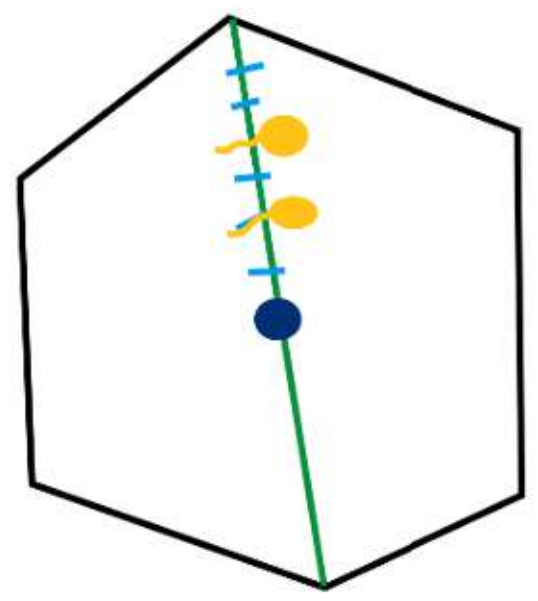

AfraTafreeh.com

- Central decussation of rectus sheath is Linea alba.
- There is a defect in Linea alba, which is usually a transverse detect above the umbilicus.
- Through this defect pare peritoneal pad of fat is going to come out.
- Behind the pad of fat, bowel is there.
- Initially only fat is coming out without a sac – Known as Ghost hernia/ sac less hernia.
- Then later the bowel /contents come out
- These patients will mimic like peptic ulcer. Pain after eating. Always advice endoscopy before surgery to rule out peptic ulcer.
- It is common in young males between age of 25-40 years.
- Cough impulse may /may not be present.
- Many times this fat gets strangulated
- Pain after eating is due to, there is pull of preperitoneal but causing pain.
- Treatment- Open (entire) Linea alba. It can recur. If we don't repair the full Linea alba and all defects in it.
- In Adults, we use non absorbable suture to close it. No need of a mesh.
- In paediatric age, we use absorbable sutures.
- Epigastric hernia of Linea alba is also known as fatty hernia, because most of the time, pare-peritoneal fat is coming out.

Incisional hernia 00:32:26

- It is happening through the incision made on the abdominal wall through that incision Hermia happens.
- Incision hernia are most common with midline incision > Paramedian (or) transverse incision
- Port sire Hermia from laparoscopic ports is also a type of incisional hernia
- Incisional hernia has a wide defect so less chance of strangulation so, elective repair can be done

European hernia society classification:

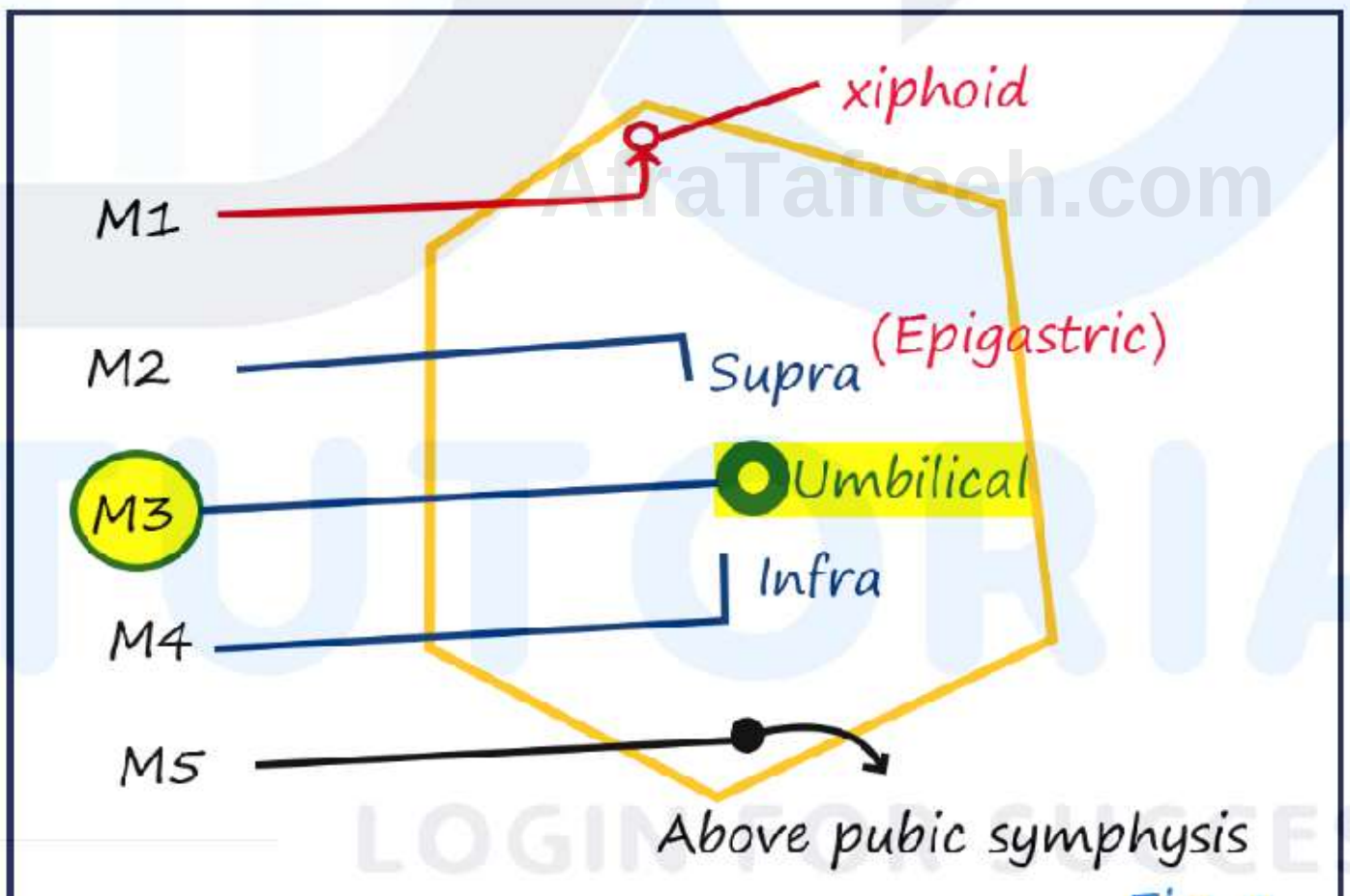

Fig: 6

- M1-Beneath the xiphoid
- M2- Supra umbilical defect, Typical epigastric hernia
- M3 - Detect in umbilical area.
- M4- Infra umbilical
- M5 - Above the pubic symphysis

AfraTafreeh.com

Risk factor of Incisional Hernias

- Incisional hernia has 10-501. incidence
- Even after any surgery, the max strength obtained by the healed wound is only 80%. (Never 100%) after any number of months/ years.
- These risk factors are divided into

a. Surgery related
  - Wound infection
  - Most common in mid line incision is > paramedian
  - Most common in emergency surgery > Elective surgery

b. Surgeon related
  - Poor technique of suturing (not properly following Jenkins rule)
  - Less suture length
  - Absorbable Suture used instead of nonabsorbable prolene
  - Excessive tension suture is done. –

c. Patient factors → are more important
  - Old patient
  - Mal nourished patient
  - Diabetic patient
  - Obesity risk factor for Incisional hernia, (not – Inguinal hernia)
  - Patient on steroids
  - Patient of ascites

DOC TUTORIALS LOGIN FOR SUCCESS

- Patient of smoking
- Patient having continuous cough / vomiting
- Hypoalbuminemia
- Jaundice.

Management of Incisional Hernia

- Open repair technique we open Linea alba, seduce the soc and contents close the defect and keep a mesh, polypropylene. Linea alba is closed with prolene / PPS.
- We use a continuous suture to close, open repair according to Jenkins's rule. In Between continuous sutures we do intermittent sutures to add up to the strength.
- Fox intermittent suturing the gap is B/w then should be <1cm
- If we not do it properly on 6th post op day - Burst abdomen can happen.

AfraTafreeh.com
TUTORIALS
LOGIN FOR SUCCESS

Mesh Repair:

- It is the gold standard treatment for Incisional hernias repair now
- On lay technique - It is usually usually a open technique

AfraTafreeh.com

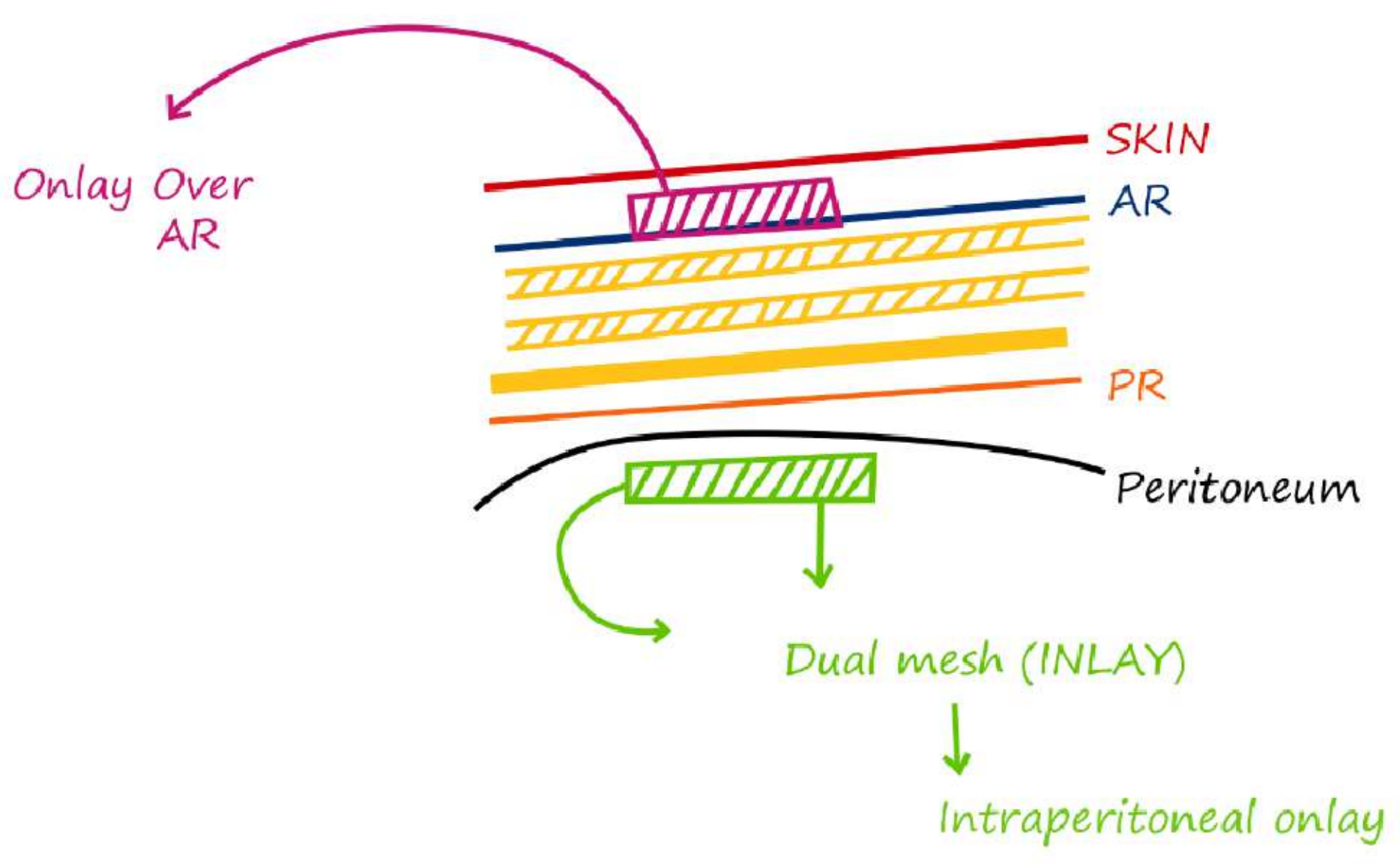

Fig: 7

- Mesh kept on skin surface, on lay by open technique – over the anterior rectus (AR) het technique. sheath.
- we can keep the mesh by laparoscopy also
- The method of keeping mesh over the peritoneum by using a Dual mesh is called Inlay mesh. It is also called Intraperitoneal on lay mesh.
- IPOM – Intraperitoneal on lay mesh
- It should be a dual mesh inner layer should be polyglycolic acid and outer layer should be prolene
- We can also keep a mesh between peritoneum and posterior rectus (PR) sheath called sub lay mesh (between the muscles and the peritoneum) Sub lay mesh is kept by extraperitoneal technique → E-TEP technique extended total extraperitoneal repair.
- In Sub lay mesh we can use prolene mesh because it don't expose abdominal contents.

- In doing laparoscopy operations, we do abdominoplasty is added upon in many cases. It is removal of excess fat.

Spigelian hernia: 00:15:05

- Hernia seen through the arcuate line

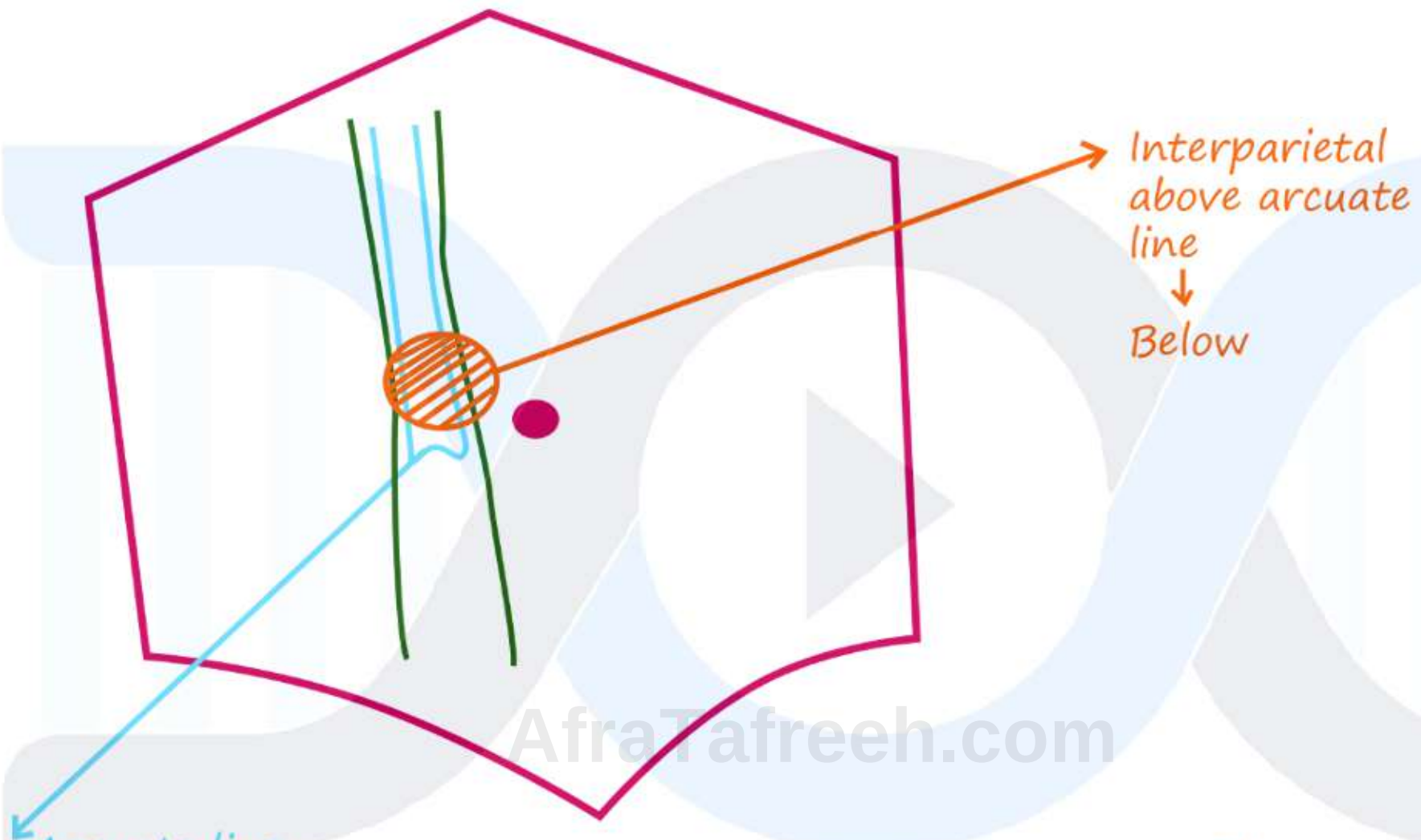

Fig: 8

AfraTafreeh.com
TUTORIALS
LOGIN FOR SUCCESS

- Posterior rectus sheath ends at a point the arcuate line, hear umbilicus.
- The herniation happening through the posterior arcuate line level through the spigelian fascia is known as Spigelian hernia.
- Spigelian Hermia can happen at any age. TE is seen as a lump near umbilicus. Cough impulse may be present.
- we com palpate the defect and lump can be H
- Important D.D here is Rectus sheath hematoma especially when spigelian hernia gets strangulated.

AfraTafreeh.com

- Strangulated spigelian hernia can be presented as Rectus sheath hematoma
- IOC CT Abdomen > USG, to look for inter parietal – hernia
- Intra peritoneal on lay mesh IPOM (or) open method and closure.
- In ventral hernias, increased risk of strangulation is seen with

  1.Spigelian hernia

  2.Umbilical hernia in adults

  3.epigastric hernia

TUTORIALS
LOGIN FOR SUCCESS

NAMED HERNIA – II

Lumbar Hernia 00:00:11

- Seen on dorsum of the body

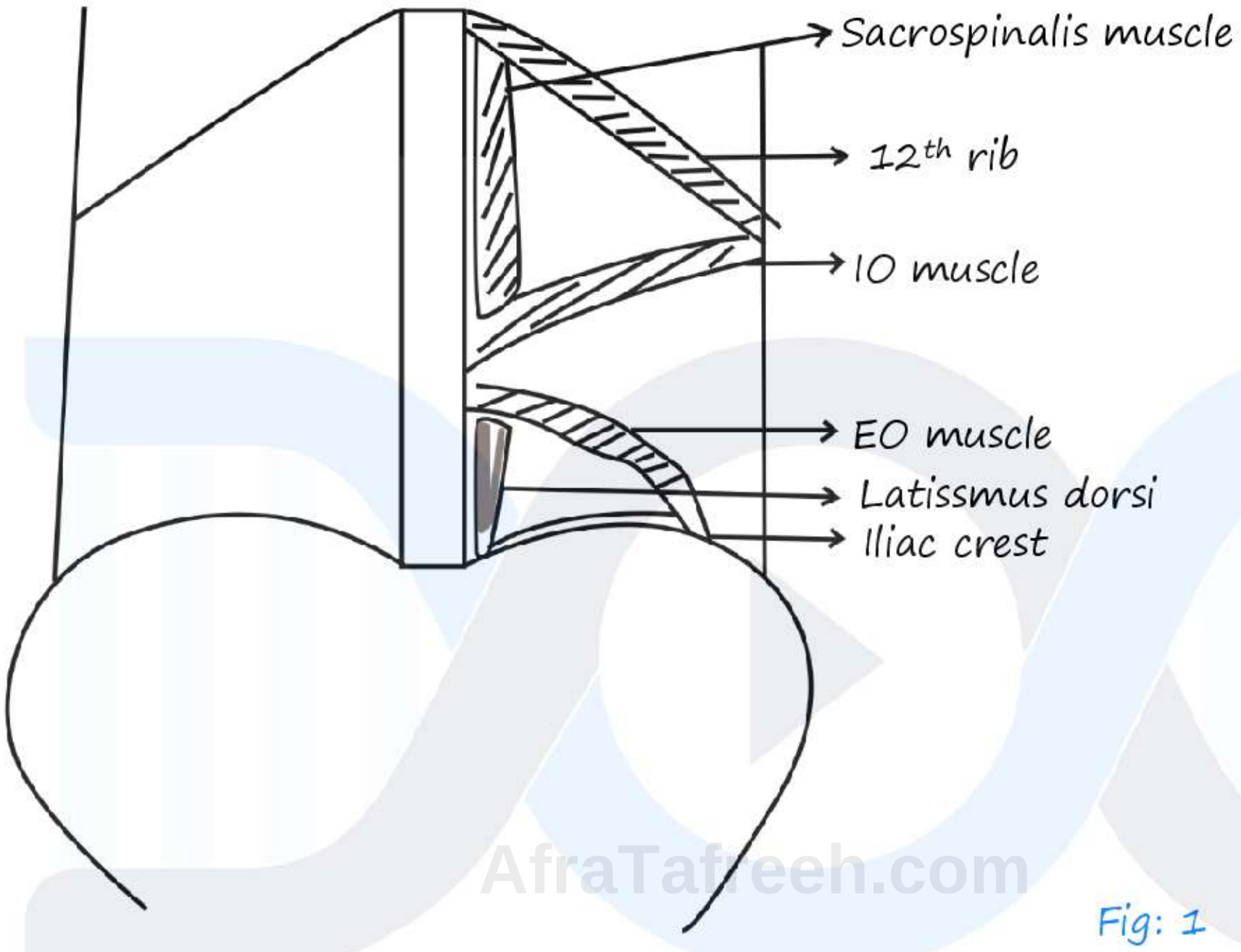

Fig: 1

AfraTafreeh.com

- Superior Lumbar triangle boundaries
  - Supero-laterally: - 12th rib
  - Infero-laterally: - Inferior oblique muscle
  - Medially: - Sacrospinalis muscle
  - Superior lumbar triangle

    ↓

    Hernia – Grynfelt hernia → rare
- Lumbar hernias are due to natural weakness
- Inferior Lumbar triangle boundaries
  - Supero-laterally: - External oblique muscle
  - Infero-laterally: - Iliac crest
  - Medially – Latissmus dorsi

AfraTafreeh.com

- Petit's hernia – most common

- Mesh repair done for lumbar hernia – **DOWD PONKA REPAIR**

Parastomal Hernia 00:05:00

- Most common after colostomy (end>loop)
- Hernia comes out through colostomy defect
- Treatment by double mesh → SUGAR BAKER Procedure

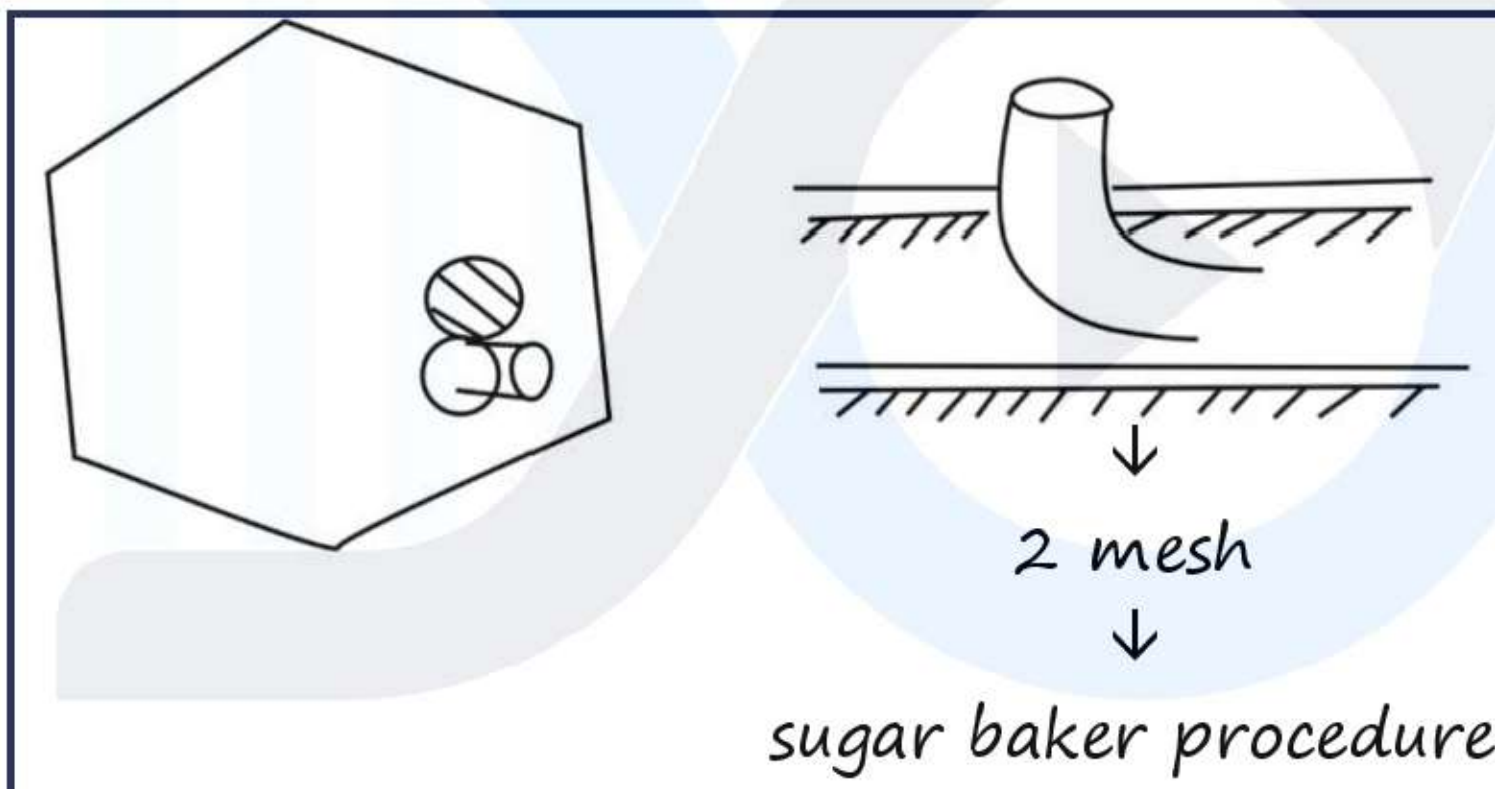

Fig: 2

Obturator Hernia 00:06:23

- Occurs via obturator foramen
- Most common – elderly females
- Clinical features – Swelling seen in Scarpa's triangle of thigh strangulation is the presentation – (presenting feature)
- Flexion, Abduction, External rotation of hip → Swelling becomes more prominent

TUTORIALS LOGIN FOR SUCCESS

- Howship Romberg sign: - Referred pain to knee due to obturator nerve compression
- Hannington kiff sign: - Obturator reflex absent
- Treatment: Mesh kept in obturator foramen through posterior approach.

Summary 00:09:20

Complicated Hernias

- Sliding
- Scrotal
- Richer's
- Mayell's
- Hernia + Hydrocele

AfraTafreeh.com

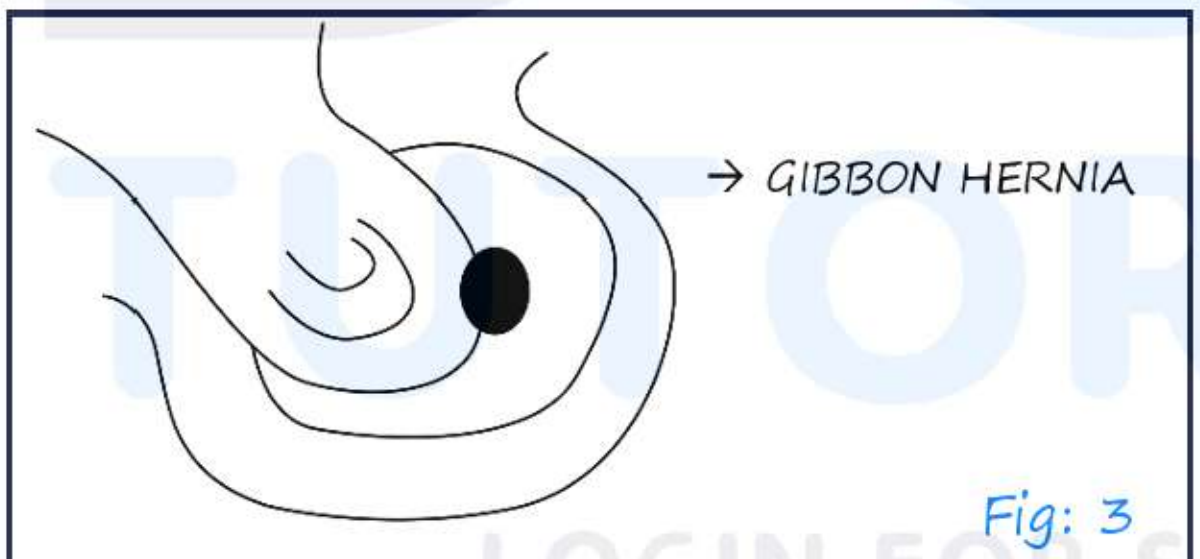

Fig: 3

Gap/Named Hernias

- Laguier's
- Ogilvie
- Beclard
- Narath
- Berger's
- Littre's → Containing Meckel's Diverticulum
- Amyand → Containing appendix

AfraTafreeh.com

Ventral Hernias

- Umbilical
- Epigastric
- Spigelian
- Incisional
- Parastomal
- lumbar

Rare Hernias

- Sportsman
- Obturator

TUTORIALS
LOGIN FOR SUCCESS

LAPAROSCOPIC HERNIA REPAIR

Introduction 00:00:23

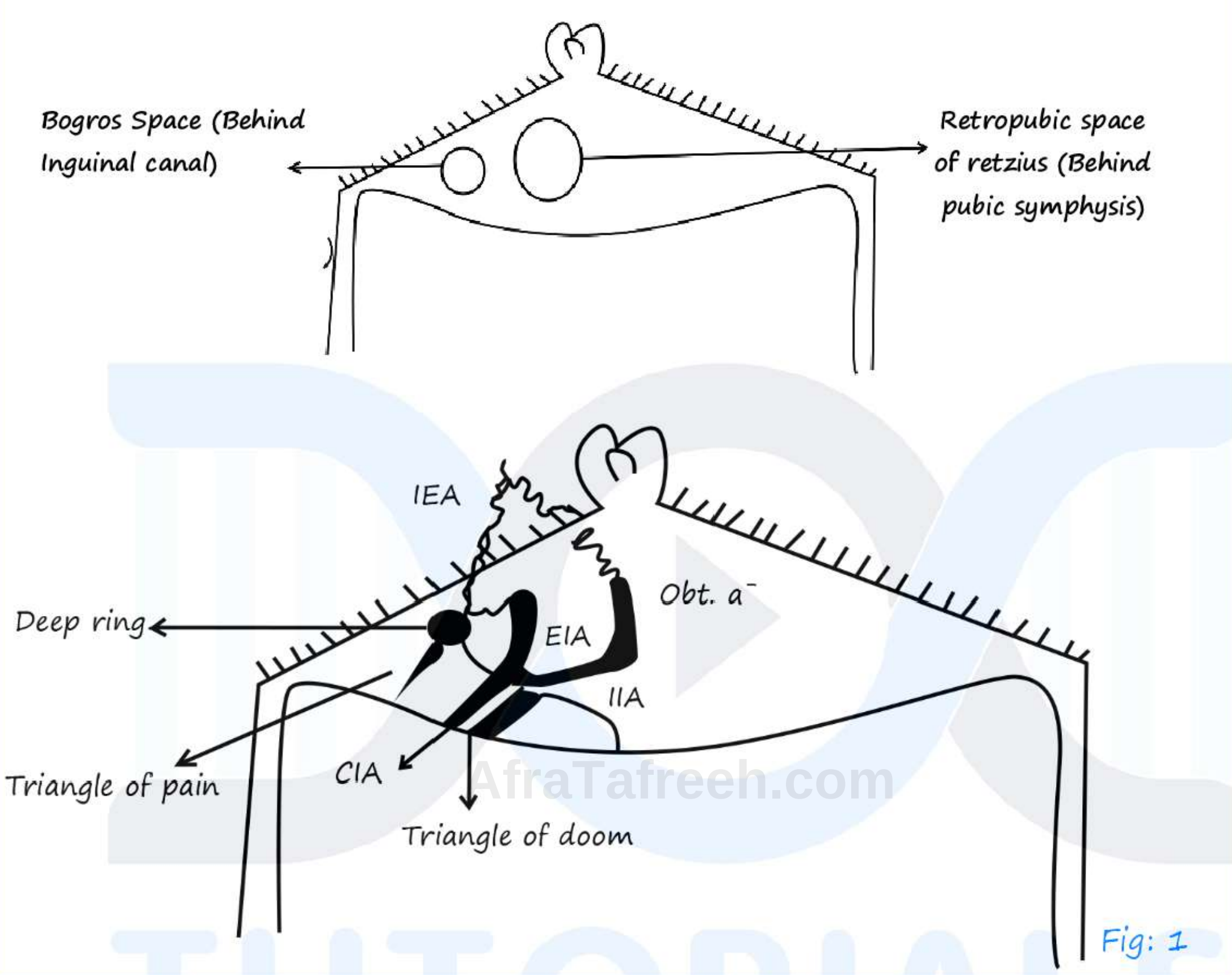

Fig: 1

AfraTafreeh.com
TUTORIALS
LOGIN FOR SUCCESS

Triangle of Doom 00:03:45

- Boundaries
  - Medially: – Vas deferens
  - Laterally: – Gonadal vessels
  - Below (Base): – Reflected peritoneum
  - Contents: – External iliac vein, External iliac artery → Damaged ↓ Torrential bleeding present

AfraTafreeh.com

Triangle of Pain 00:05:17

- Boundaries
  - Medially; - Gondal vessels
  - Base: - Reflected part of peritoneum
  - Lateral: - Iliopubic tract

    ↓

    4 important nerves crossing this triangle

    1.Lateral cutaneous nerve of thigh (most common with injured → Meralgia paresthetica)

    2.Anterior cutaneous nerve of thigh

    3.Femoral br. of Genitofemoral nerve

    4.Femoral nerve

Corona Mortis 00:09:11

- Circle of death
- Formed by
  - External iliac artery
  - Internal iliac artery
  - Obturator artery
  - Inferior epigastric artery
  - Abnormal obturator artery (20-30%)

TUTORIALS
LOGIN FOR SUCCESS

Myopectineal orifice of FRUCHAD 00:12:21

- Medially: - Rectus abdominis
- Superiorly: - Conjoint tendon
- Laterally: - Iliopsoas

- Inferiorly: – Pecten pubis bone

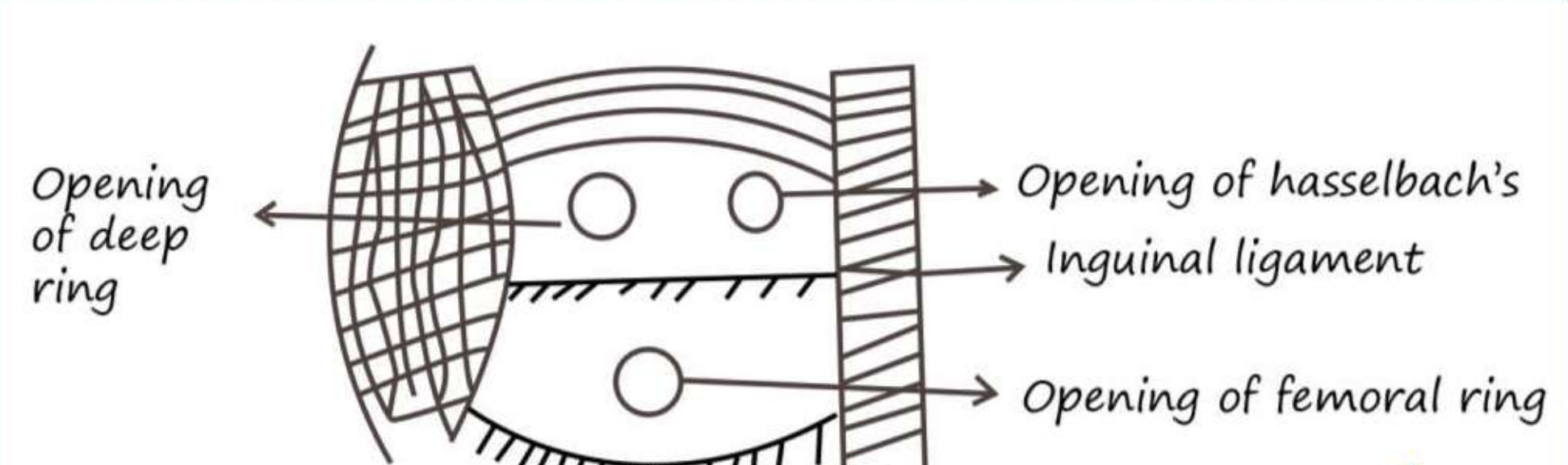

Fig: 2

Surgery 00:15:15

Surgery

(under ↓ G.A.)

Trendelenburg position

TAPP (3 ports) | TEP (2/3 ports)

AfraTafreeh.com

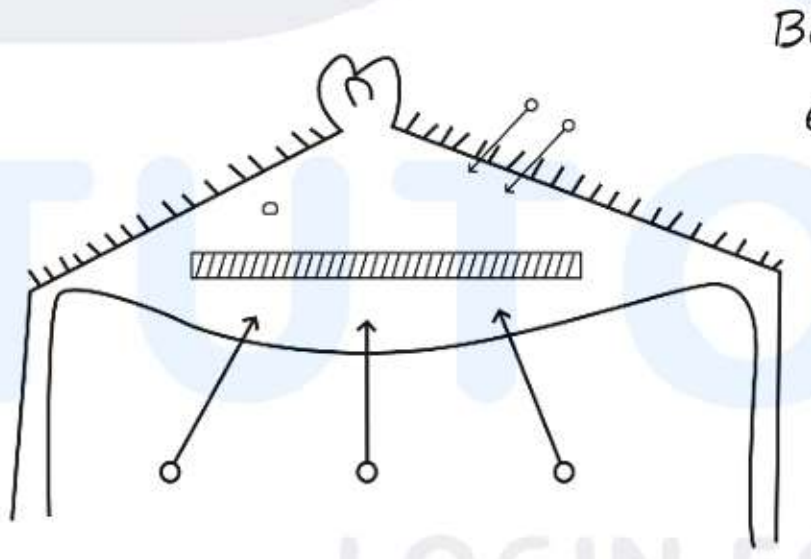

Transabdominal preperitoneal repair
↓
- Easy learning curve
- Easy for surgeons
- Disadvantages
  ↓
  Bowel injury present
  paralytic ileus present

Balloons dissection/Total extraperitoneal repair
↓
- Time taking
- Long learning curve
  ↓
  - No ileus
  - No risk of bowel injury
  - IF peritoneum gets opened → TAPP

AfraTafreeh.com

Complications 00:23:59

- Most common nerve injured – lateral cutaneous nerve of thigh.
- Most worrisome – Mesh infection

TUTORIALS
LOGIN FOR SUCCESS

ESOPHAGUS INTRODUCTION

Esophagus Anatomy 00:00:29

- Length of esophagus – 25cm
- Starts from cricopharynx and up to OG junction
- The narrowest part of entire GIT

  ↓

  Cricopharynx – 13mm in diameter
- Length from incisor to cricopharynx – 15cm
- On endoscopy, OG junction is reached at 40cm.

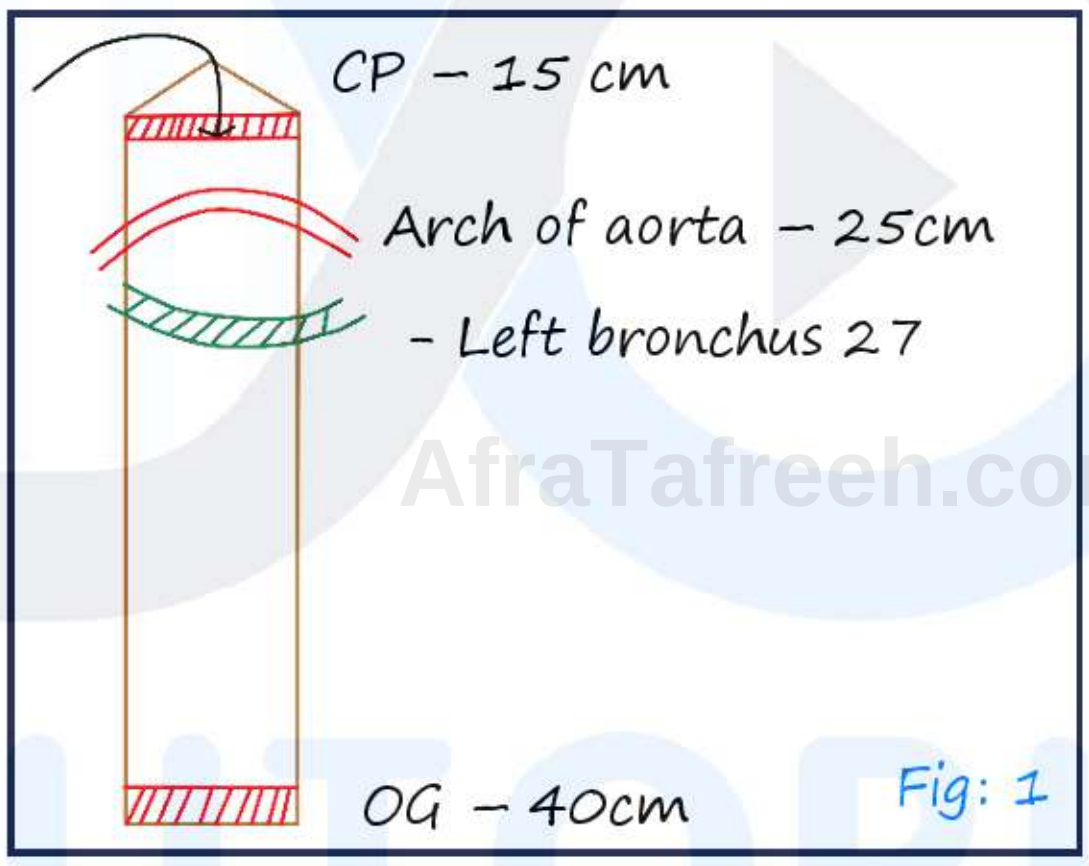

Fig: 1

AfraTafreeh.com
TUTORIALS
LOGIN FOR SUCCESS

Constrictions of esophagus

- At cricopharynx – 15cm
- Arch of aorta – 25cm
- Left bronchus – 27 cm
- OG junction – 40 cm

- Serosa is absent in esophagus
- Submucosa absent in gall bladder
- These structures are seen in high frequency Endoscopic ultrasound

AfraTafreeh.com

Endoscopic ultrasound

- 7-12 mHz probe passed through esophagus and stomach
- On EUS, we will get 5 layers.

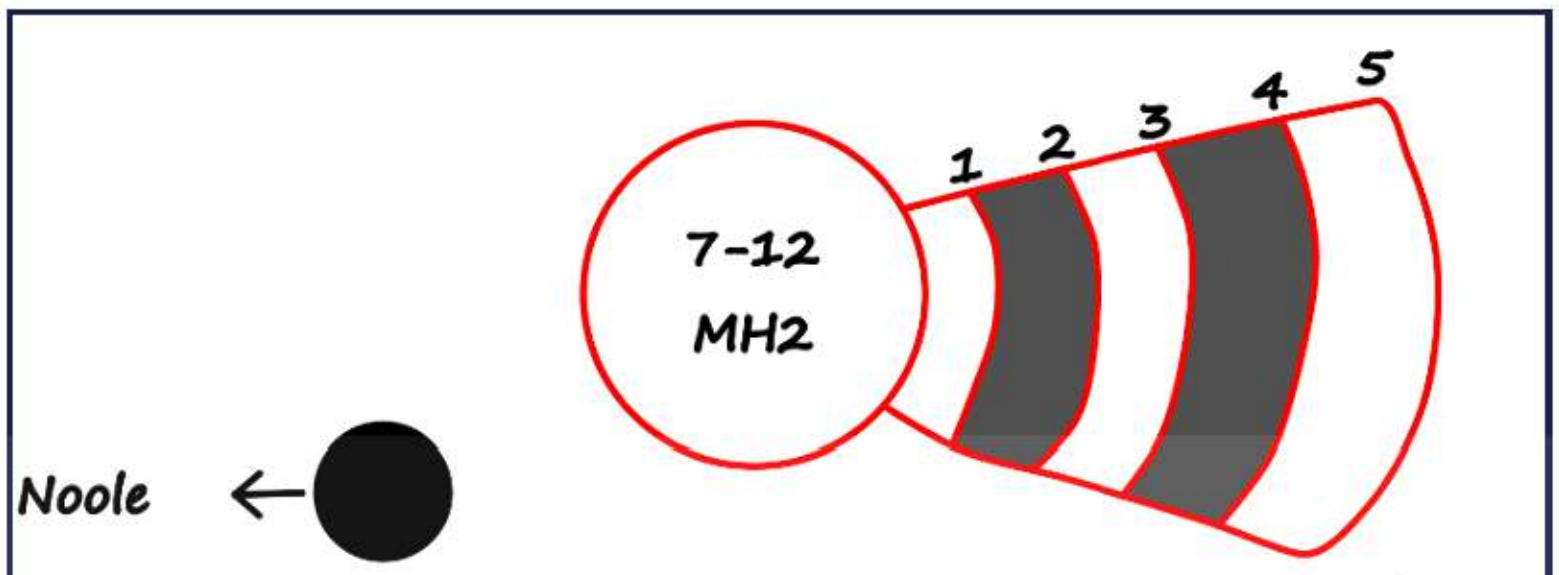

Fig: 2

- Layer 2 – Muscularis mucosa
  4 – Muscularis propria
- Layer 1 – Mucosa
  3 – Submucosa
  5 – adventitia
  } Hyperechoic
- Node – is seen as round with well-defined border
  – Hypodense
  – > 1cm
  → metastatic node
- Endoscopic ultra sound (EUS) – IOC for 'T' and 'N' staging of Ca. esophagus

DOC TUTORIALS LOGIN FOR SUCCESS

Physiology of Esophagus 00:06:48

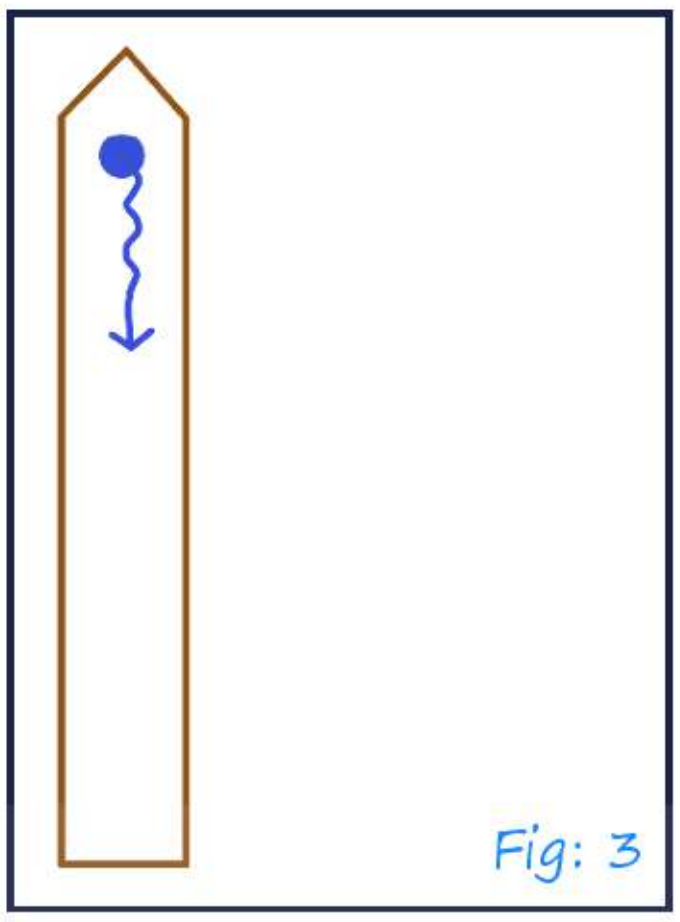

Fig: 3

- Peristalsis seen with swallowing of food

  ↓

  1° peristalsis

- Peristalsis seen with reflex food particles

  ↓

  2° peristalsis

- Peristalsis without stimulus and reflex

  ↓

  3° peristalsis

  ↓

  Associated with – DES

  Nut cracker esophagus

- Amplitude of esophagus pushes the food down

  ↓

  N – 40-60 mmHg

  contracts for 4-6 seconds

  Known as **distal contractile integrity**

  ↓

  amplitude x cm the food moves x seconds

  mmHg x cm x seconds

AfraTafreeh.com
TUTORIALS
LOGIN FOR SUCCESS

AfraTafreeh.com

- DCI < 100 – Achalasia
- DCI > 450 – DES
- DCI > 8000 – Nut cracker esophagus /Jack hammer esophagus

- Last 5 cm of esophagus is lower esophageal sphincter

Opens on swallowing | Usually closed at a resting pressure of 10-26 mmHg

- LES closed tightly and not opening – Achalasia cardia

↓ ↓

Integrated relaxation pressure (IRP)

IRP>15mmHg

↓

After you swallow, IRP < 15 mmHg

High resolution manometry

- 36 sensors all around esophagus

DOC TUTORIALS
LOGIN FOR SUCCESS

Chicago Classification of Motility Disorders

00:17:18

Chicago classification of motility disorders

- Hypomotility disorders (most common)
  - Type I achalasia → most common
  - Type II
  - Type III
- Hypermotility disorders
  - DES
  - Nut cracker esophagus (NCE)

Parameter	Achalasia cardia			DES	NCE
	Type – I Classical	Type – II Vigorous	Type – III Spastic		
• Peristalsis	100% failed	100% failed	100% failed	3°	3°
• DCI	< 100	Difficult To measure Esophageal Pressurization	> 450 sometimes pan esophageal Pressurization	>450	>8000
• IRP		>15mmHg		N	N

- Type II achalasia cardia – Vigorous type
  - Pressurization of esophagus (pan esophageal pressurization)

AfraTafreeh.com
TUTORIALS
LOGIN FOR SUCCESS

AfraTafreeh.com

Isobaric

Contour @ 30mmHg

Achalasia in Evolution 00:24:21

- Also, known as esophagogastric junction obstruction
- Peristalsis – N
- DCI – N
- IRP – > 15 mmHg

TUTORIALS

LOGIN FOR SUCCESS

MOTILITY DISORDERS OF ESOPHAGUS

Achalasia cardia 00:00:11

- Clinical features – Young females

↓

Dysphagia – Slow progressive dysphasia
- Both
- Liquids > solids

- Triad – Dysphagia

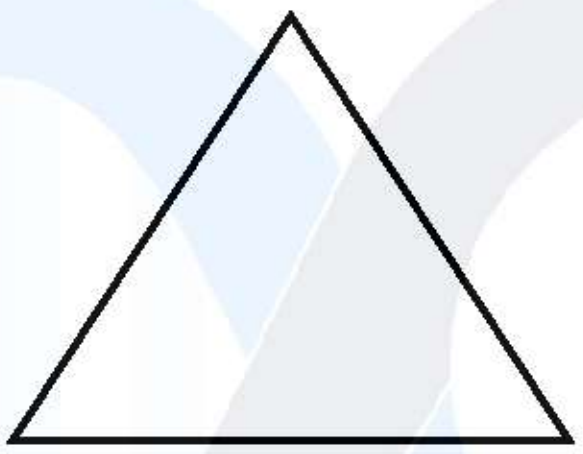

Regurgitation   Wt. loss

AfraTafreeh.com
DOC TUTORIALS
LOGIN FOR SUCCESS

Pathophysiology 00:02:02

- Idiopathic
- LES becomes tight segment above LES is dilated

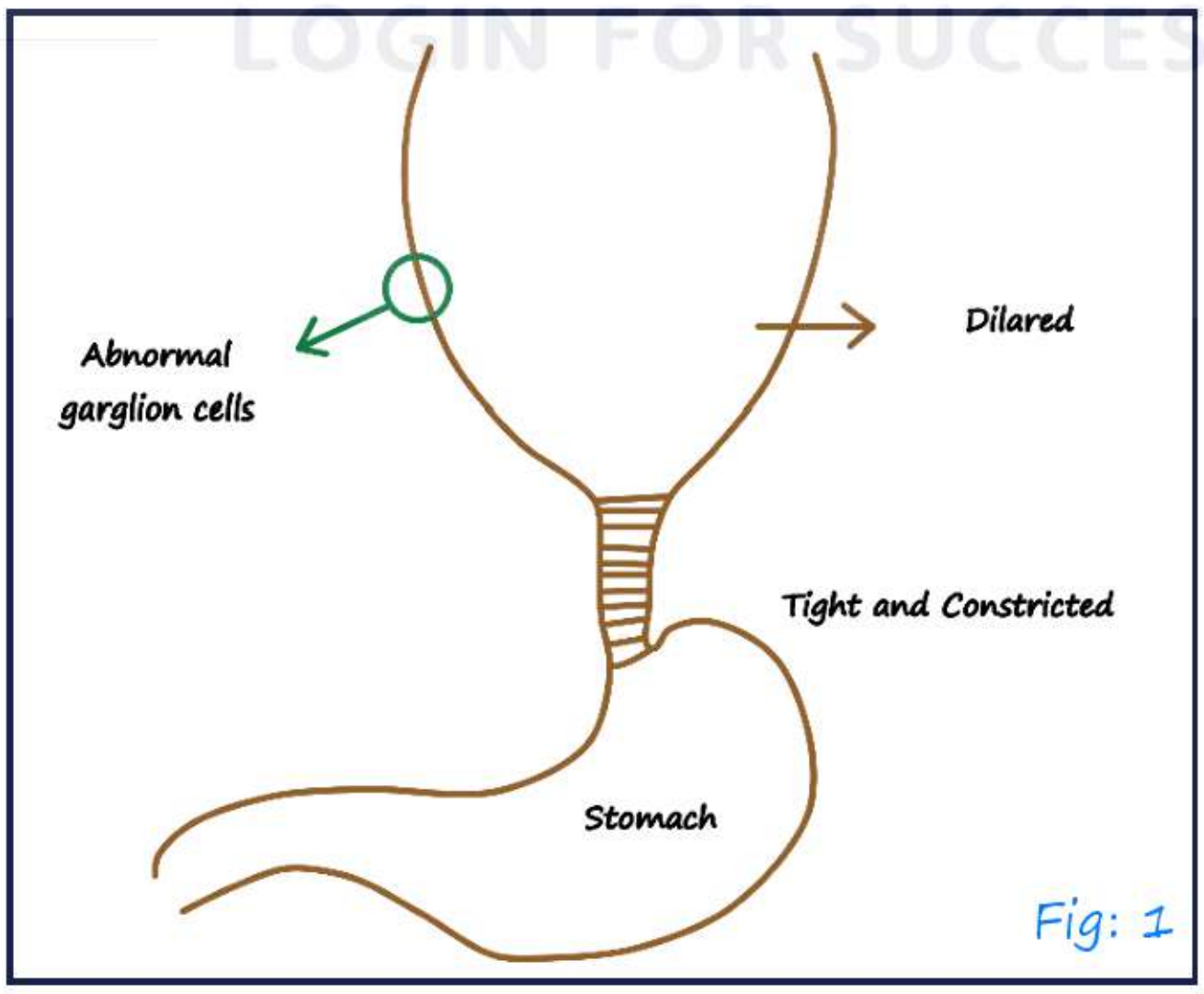

Fig: 1

AfraTafreeh.com

- Absence of ganglion cells in dilated part of achalasia (Old concept) → Not used
- In Hirschsprung's disease → Absence of ganglion cells in Auer Bach and myenteric plexus (Constricted part)
- In high resolution manometry, LES pressure – Closed IRP > 15mmHG

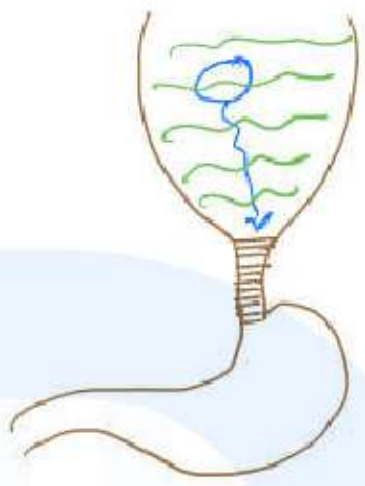

- Dysphagia
- Aspiration → resp, issues
- Reflex

- Fundus gas shadow is absent

Complications of Achalasia 00:07:44

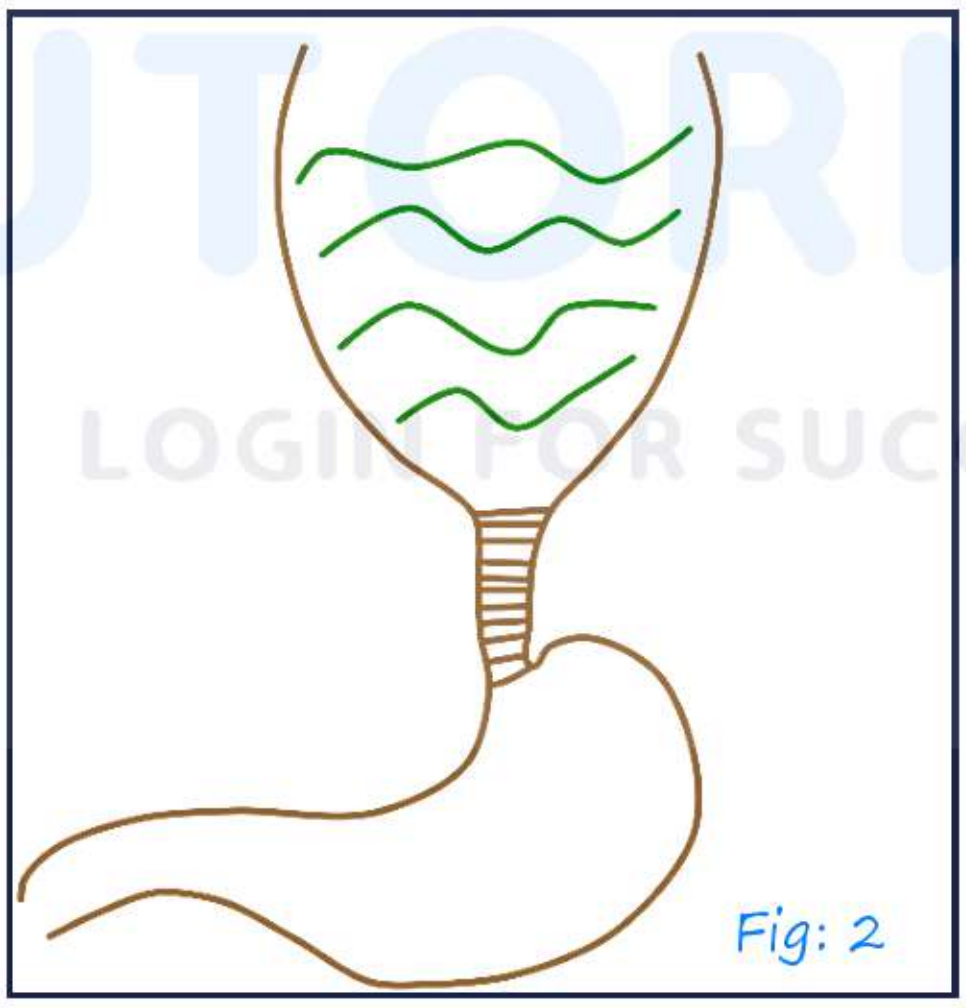

Fig: 2

- Most common – Reflex esophagitis
- Aspiration pneumonitis
- 8% chances of malignancy

Most common squamous cell cancer

- Adenocarcinoma -rare

↓

If happens below air fluid level

- Sigmoid/Mega-esophagus

Investigations 00:10:11

- High resolution manometry – Gold standard
- Ba. swallow → Birds break deformity

Pencil tip deformity

Birds beak-
Abrupt cut off
of contrast

AfraTafreeh.com

Hurst phenomenon

↓

Some amount of
contrast flowing down

DOC TUTORIALS
LOGIN FOR SUCCESS

- X-ray chest → Retro cardiac air fluid level
- X-ray abdomen erect → Fundus gas shadow is absent

AfraTafreeh.com

Management

Medical treatment

- Ca^{+} channel blockers → Nifedipine
- Sildenafil citrate

Endoscopic treatment

Endoscopically balloon is inserted and dilated radially
↓
Tear's muscle
↓
LES opens
↓
Food particles go down
↓
Pneumatic balloon dilatation→ 0.5 – 5% risk of rupture of esophagus → Close the rupture and do myotomy on opposite site

- Endoscopically we can inject botox injection → Eckardt score

DOC TUTORIALS LOGIN FOR SUCCESS

Surgical treatment

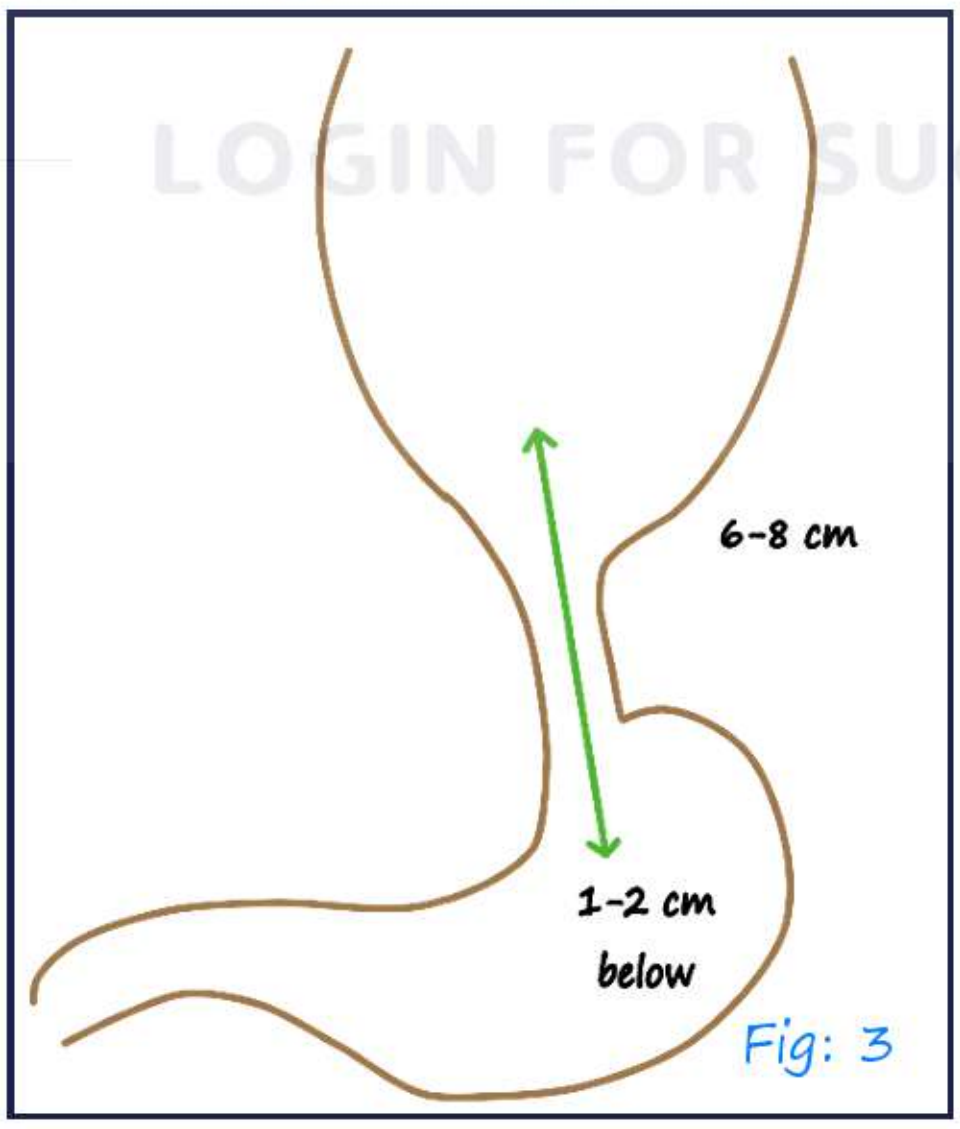

Fig: 3

- Cut the sphincter 1-2 cm below OG junction and 6-8cm above OG junction

↓

Modified hellers cardio myotomy

↓

Muscles will open up

↓

Gerd

↓

To prevent this partial fundoplication procedure is done

- If accidently mucosa is opened

↓

Close the mucosa with 2-0 vicryl & DOR WRAP

Latest procedure

- POEM – per oral endoscopic myotomy
- ADVANTAGE No abdominal scars
- Types of notes (Natural Orifice Transluminal Endoscopic Surgery)

AfroTutorials.com
TUTORIALS
LOGIN FOR SUCCESS

Prognosis of Achlasia

- Type 1: 80% response (Bad prog)
- Type 2: 95% - 100% response (best)
- Type 3: Latest: POEM is best
- Gold standard procedure: Modified heller's cardio myotomy

AfraTafreeh.com

DES

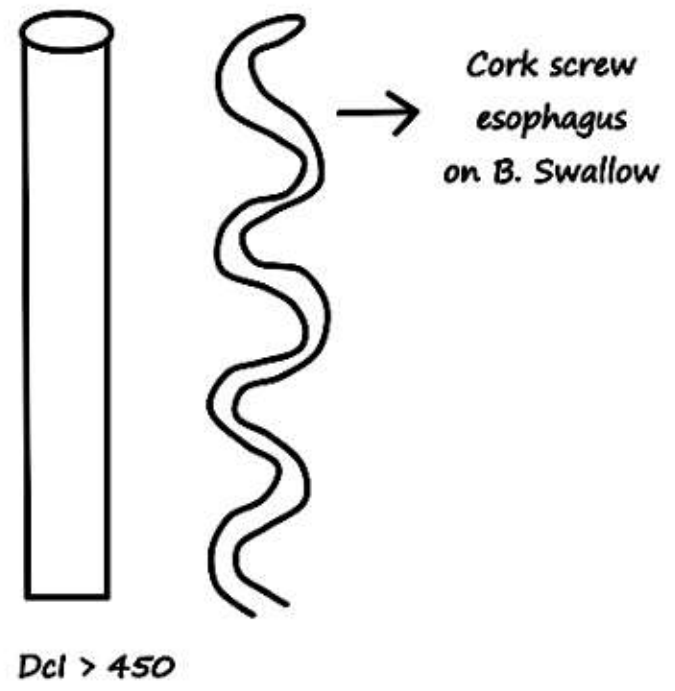

- Clinical features: Middle aged females
- Dysphasia + mild chest pain
- surgery: Long esophago myotomy up to carina
- Latest: POEM

NCE



Mucosa will bulge out

↓

Pulsion diverticulum

↓

Also, known as

- Epiphrenic diverticulum
- False diverticulum
- Any age any sex
- Mimics like MI
- No role of surgery

↓

1st line treatment

CCB

TUTORIALS
LOGIN FOR SUCCESS

DIVERTICULUM IN ESOPHAGUS

Diverticulum 00:00:17

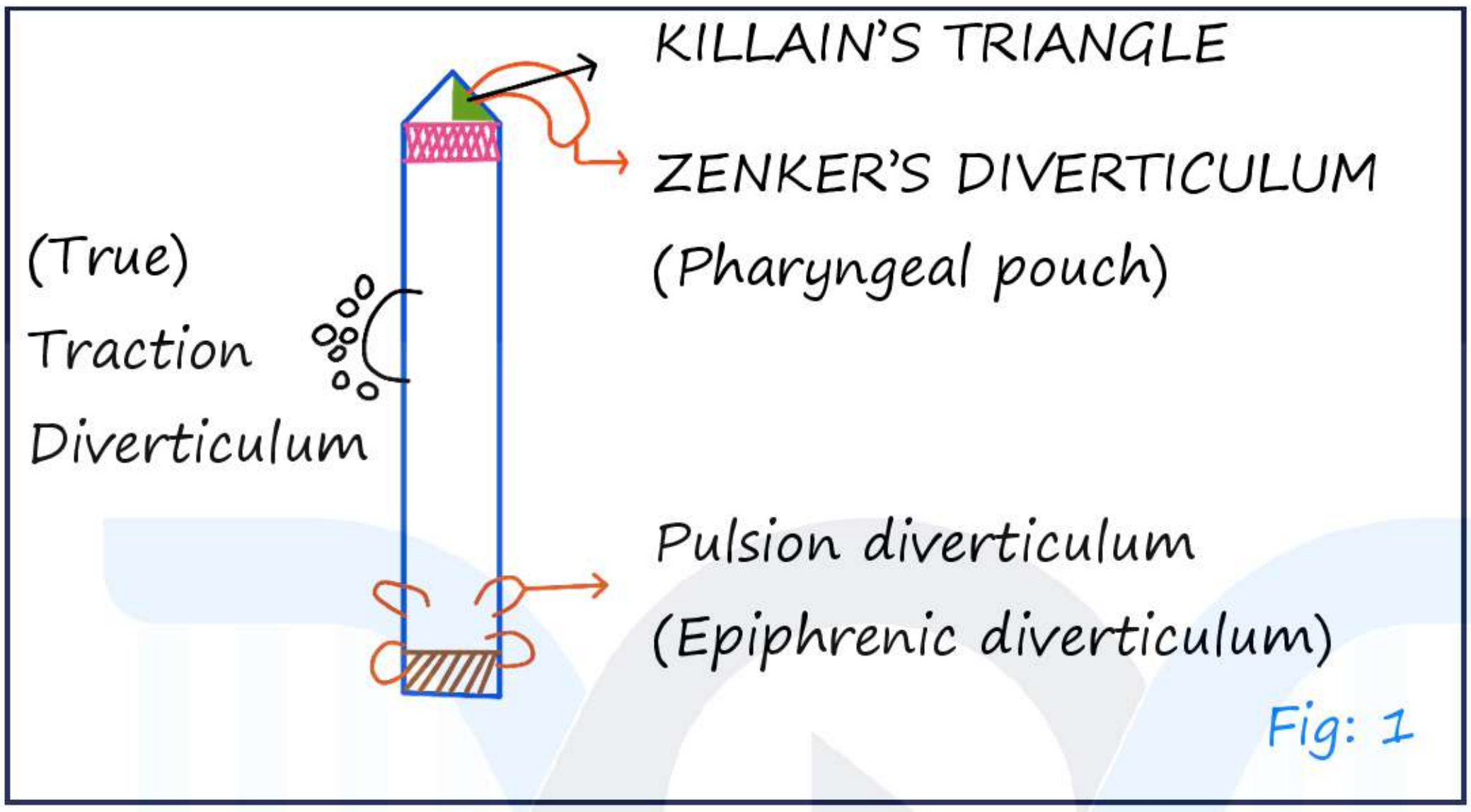

Fig: 1

Killian's Triangle

- Defect in inferior constrictor muscle
- Bounded by – Thyropharyngeus
  - Cricopharyngeus
  - Midline raphe

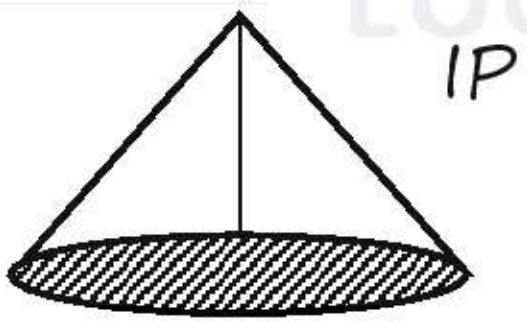

- Because of tight spasm of cricopharyngeus muscle, the patient tries to swallow something and it is not going inside, it is coming out as diverticulum.

↓

Zenker's diverticulum

AfraTafreeh.com
TUTORIALS
LOGIN FOR SUCCESS

AfraTafreeh.com

Zenker's diverticulum

- Old males
- L side
- Presents in posterior triangle of neck
- False diverticulum → muscle layer absent
- Most common diverticulum
- Main etiology: Cricopharyngeal spasm (or) Cricopharyngeal spasm

- In middle of esophagus near vertebra → there is formation of nodes. Those nodes will pull the esophagus and create a diverticulum K/a True/Traction
  ↓
- Seen in – TB
  - Histoplasmosis
- Most common in R side
- In last 10cm of esophagus → a diverticulum can be developed – pulsion
  ↓
  In hypermotility disorders like nut cracker esophagus
  ↓
  The muscle contracts and pushes the mucosa outside
  - Also k/a EPIPHRENIC DIVERTICULUM
  - Most common seen in nut cracker esophagus
  - Seen in middle esophagus also.

TUTORIALS LOGIN FOR SUCCESS

Zenker's Diverticulum 00:06:19

- Cricopharyngeal sphincter is tight & has a pressure of 40mm Hg resting pressure.
- Due to cricopharyngeal spasm, food cannot be swallowed and leads to ZENKER'S DIVERTICULUM
- Clinical Features- 1. Dysphagia
  2. Halitosis
- Complication – Aspiration (most common)
  ↓
  lung abscess
- IOC – Ba swallow (oblique view)
- Treatment –

1.Diverticulectomy: - for any size
↓
Gold standard

AfraTafreeh.com

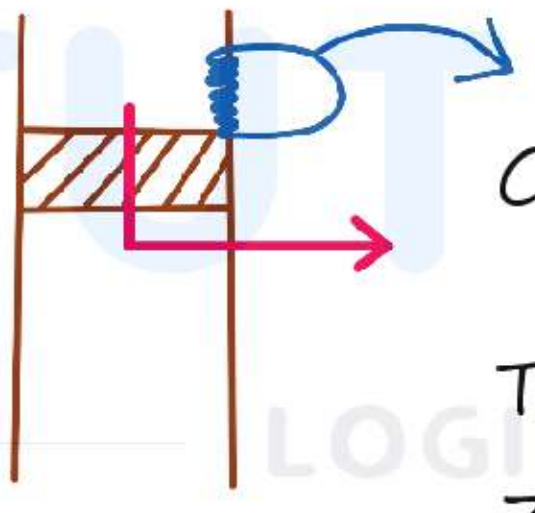

Cricopharyngiomyotomy done
↓
To prevent recurrence of Zenker's Diverticulum.

- If diverticulum is < 2cm – Cricopharyngomyotomy is enough
  ↓
  Risk of leak present

2.Diverticulopexy: -

- Diverticulum is dissected and attached to posterior pharyngeal wall/prevertebral fascia.

AfraTafreeh.com



Fig: 2

- Very old and patient's unfit for surgery
- No complications

3.Dolman's operation

- Endoscopic stapling technique

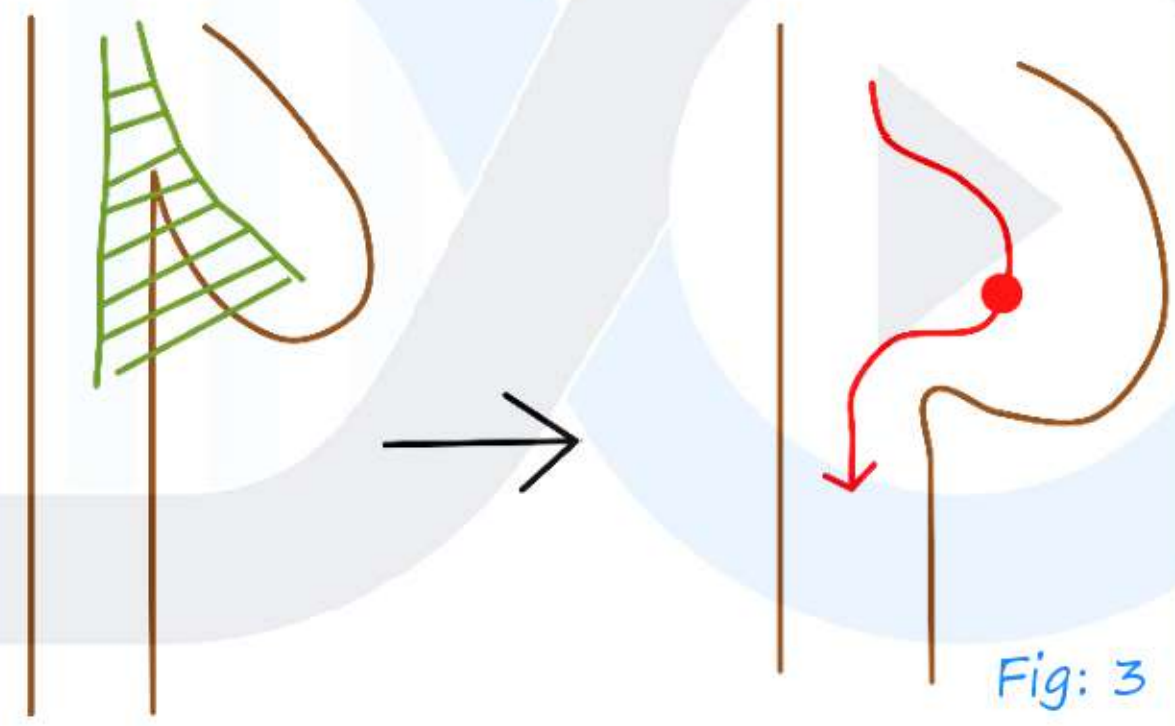

Fig: 3

- > 3cm size

TUTORIALS
LOGIN FOR SUCCESS

GERD

- Most common GI disease

Physiology 00:00:30

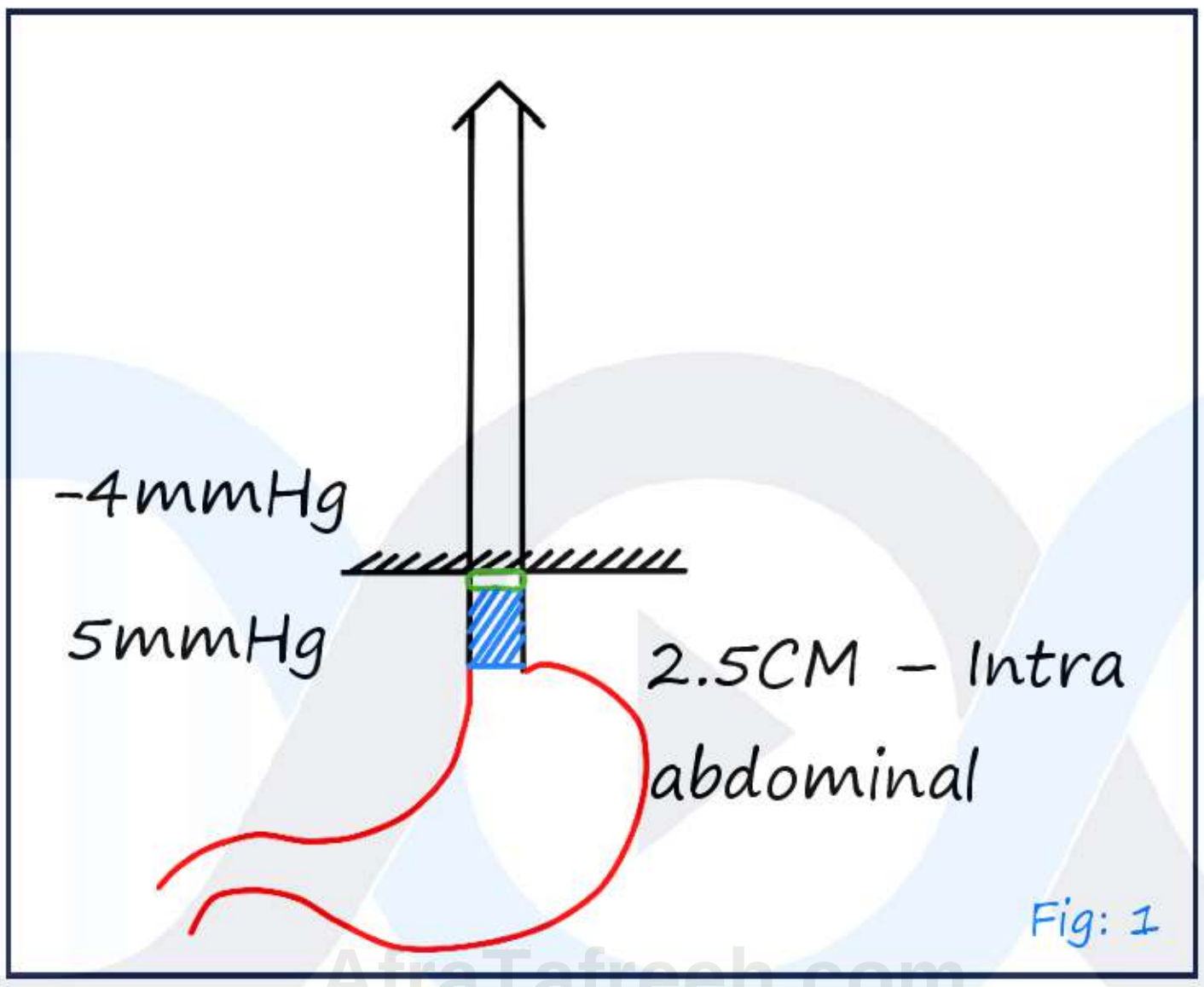

Fig: 1

- ↑ IAP – Sphincter effect
  - If intra-abdominal esophagus <1cm
    ↓
  - Contents from stomach enter esophagus
- Normal LES resting pressure: 10-25mmHg
  ↓
  Decreases <10mmHg
  ↓
  GERD develops
- Most important preventing mechanism – ↑IAP

AfraTafreeh.com

AfraTafreeh.com

Etiological factors 00:04:18

- Tea
- Coffee
- Alcohol
- Smoking
- Peppermint
- Cola drinks
- Fatty foods
- Spicy foods
- Obesity
- Pregnancy
- Sliding hiatus hernia

→ LES opened
↓
A – Anticholinergics
B – Barbiturates
C – CCB
D – Diazepam
E – PgGE1 analogues

Etiological factors 00:04:18

- Most common presentation: Heart burn

Esophagitis
↓
Retrosternal discomfort

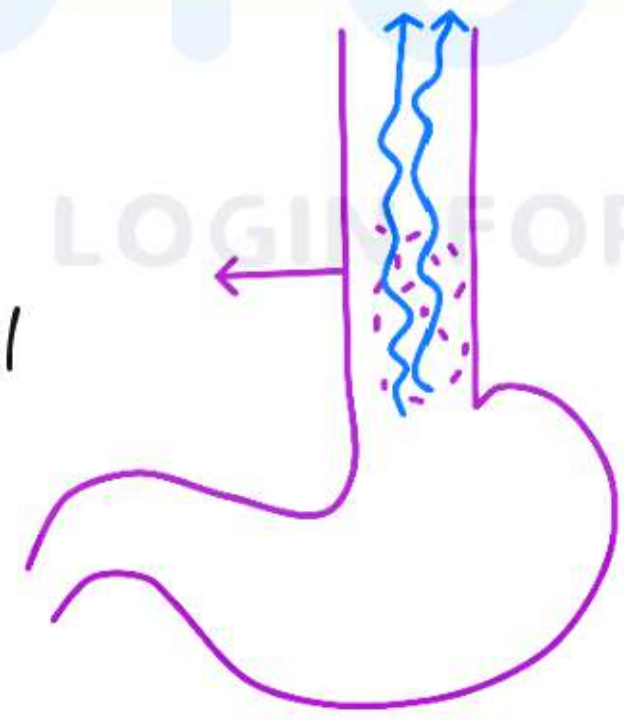

Fig: 2

- LPR: Laryngopharyngeal reflex

↓

Cough (Paroxysmal nocturnal cough)

↓

Nocturnal asthma

Complications 00:08:40

1.Most common reflux esophagitis – IOC – Endoscopy

↓

Los Angeles ⎤ Grading
Savary miller ⎦

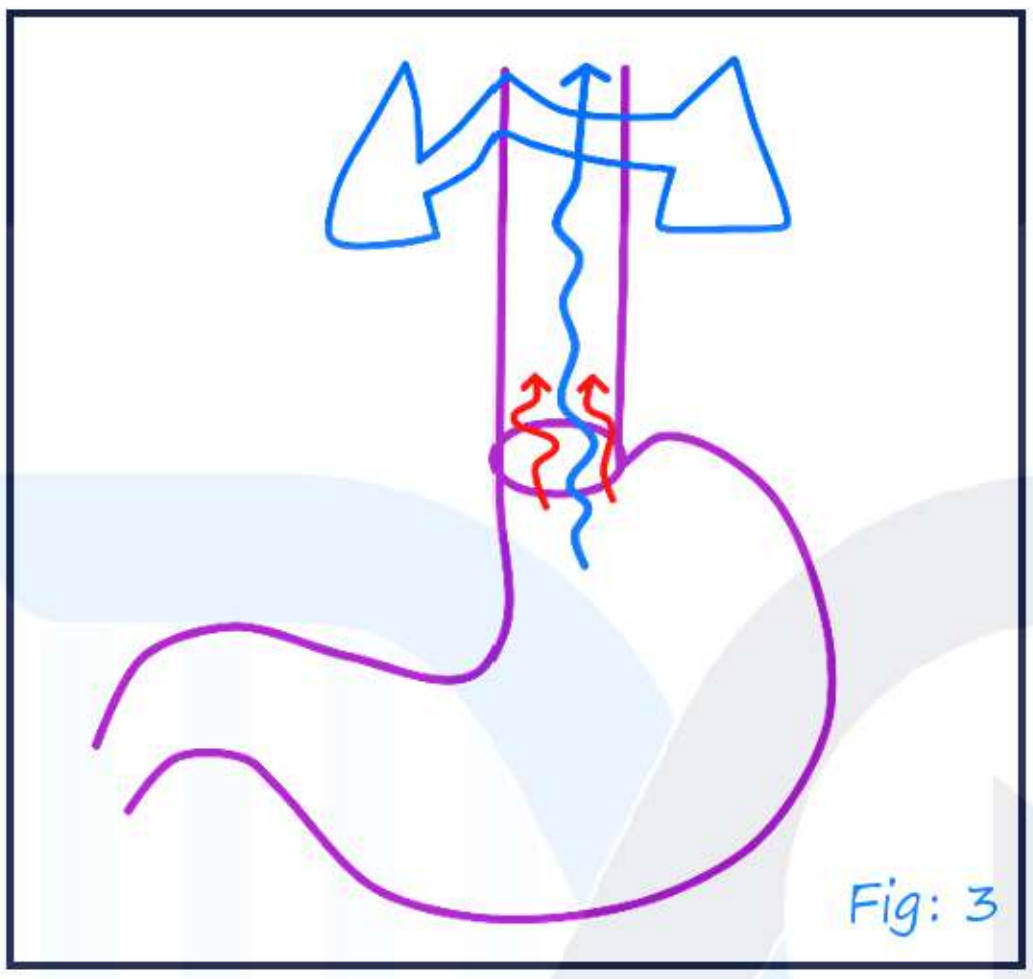

Fig: 3

2.LPR

- Nocturnal cough
- Nocturnal asthma
- **Definitive indication for SX**

AfraTafreeh.com

3.Schatzki's ring

- **Always seen in squamocolumnar junction**
- Submucosal ring
- Treatment – Dilatation

4.Peptic stricture

- Seen anywhere in lower esophagus
- Thick stricture
- Treatment: Resection and jejunal interposition

AfraTafreeh.com

5.Barret's esophagus

- Conversion of squamous epithelium to intestinal type of columnar epithelium -metaplasia
- Bx: Goblet cells (+)
- 40 times risk of adenocancer esophagus

Investigation 00:14:42

- Gold standard: 24hrs ambulatory PH monitoring

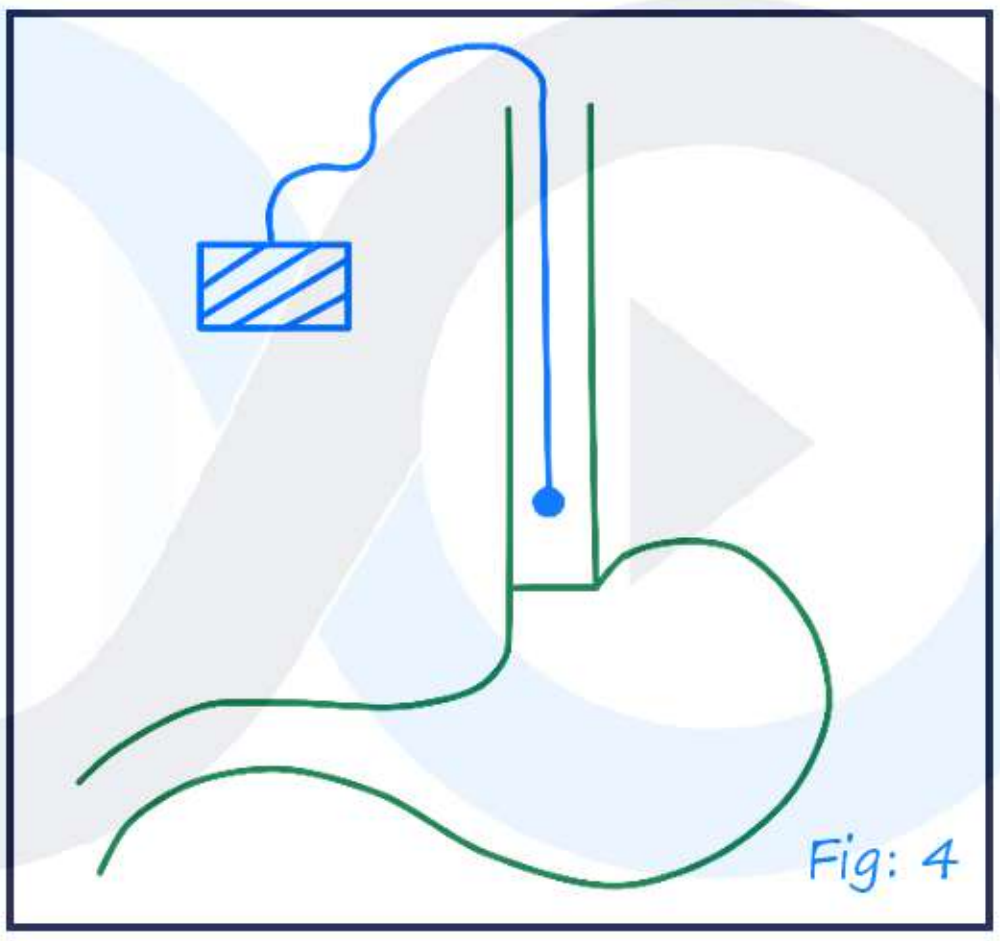

Fig: 4

- Sensor is placed 5cm above OG junction
  ↓
- Passed through nose
- Connected to receiver
- Placed in empty stomach and patient sent home
- PH<4CM
  ↓
  Signal sent to the receiver
- Demeter score >14.7 → GERD
- Avoid
- PPL X 7days
- H2 blockers X 48hrs

TUTORIALS
LOGIN FOR SUCCESS

↓

If the patient C/O pain on stopping medication

↓

Impedance manometry

Impendence manometry

- 2 sensors are placed on lower end of esophagus & connected to a receiver
- Passed through nose

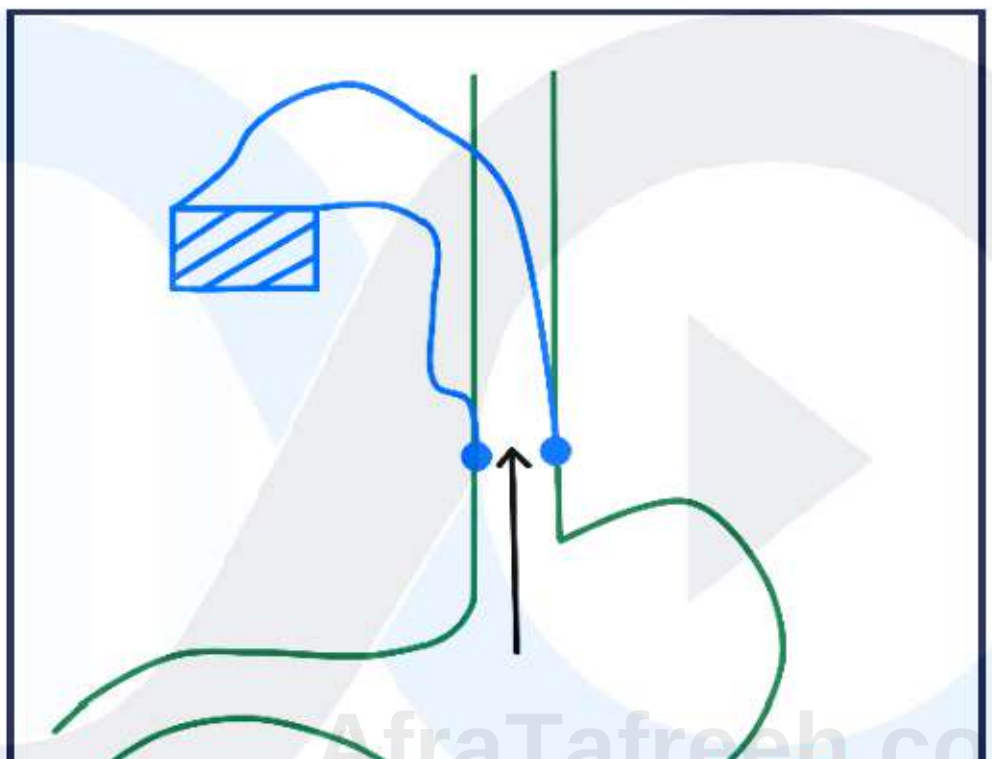

Fig: 5

- Anything which passes through the sensor gives impedance signal

↓

Air -high impedance

Liquid

Solid – Low impendence

- Indications

1.Unable to stop PPI

2.To know Type of reflux

3.Bed ridden – ICU

24 hours dual probe PH monitoring

- 2 sensors - @ Cricopharynx

AfraTafreeh.com TUTORIALS LOGIN FOR SUCCESS

AfraTafreeh.com

- @ 5cm above OG junction

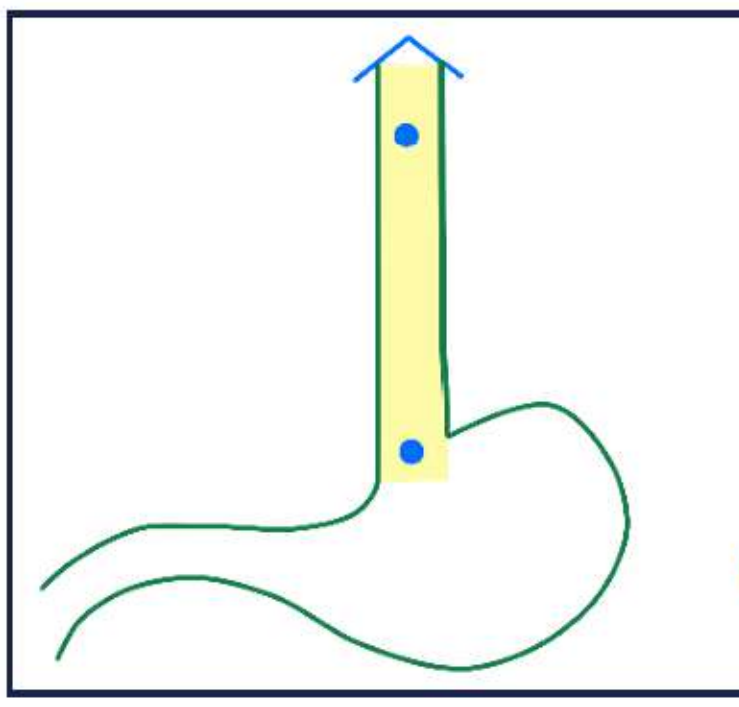

Fig: 6

- Done for **LRP**
- Reflux esophagitis upper GI scopy
- Barret's- Seatle biopsy protocol

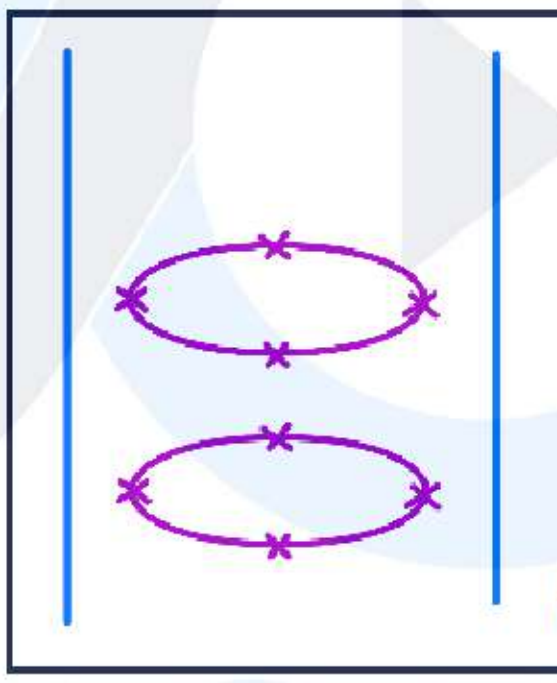

Fig: 7

- For every 1cm biopsy taken from all 4 sides
- Goblet cells
- Sliding hiatus hernia – CT thorax & Upper abdomen with oral contrast

Management 00:22:22

- Medical treatment:

  DOC: PPL X 6-8weeeks + life style modification

  ↓

  Comfortable

  ↓ Not responding

  Continue PPI ↓

  Think of motility disorder

  ↓

  IOC: High resolution manometry

Indication of surgery 00:25:05

1.High volume reflex

2.Patient wants surgery

3.Complications – LPR, peptic stricture, barret's esophagus

4.Complications of PPI – Osteoporosis, lactation, atrophic gastritis, Fundic gland polyp

5.Life Expectancy > 7years

- Contraindications for surgery:

  Failure to respond to PPI

  Psychiatric patients

Principles of surgery 00:28:26

1.**Pull of the esophagus** – Minimum 3cm in abdominal cavity

↓

AiraTafreeh.com
DOC TUTORIALS LOGIN FOR SUCCESS

AfraTafreeh.com

Narrow the hiatus

↓

Fundus part of stomach is wrapped around the esophagus

– **fundoplication**

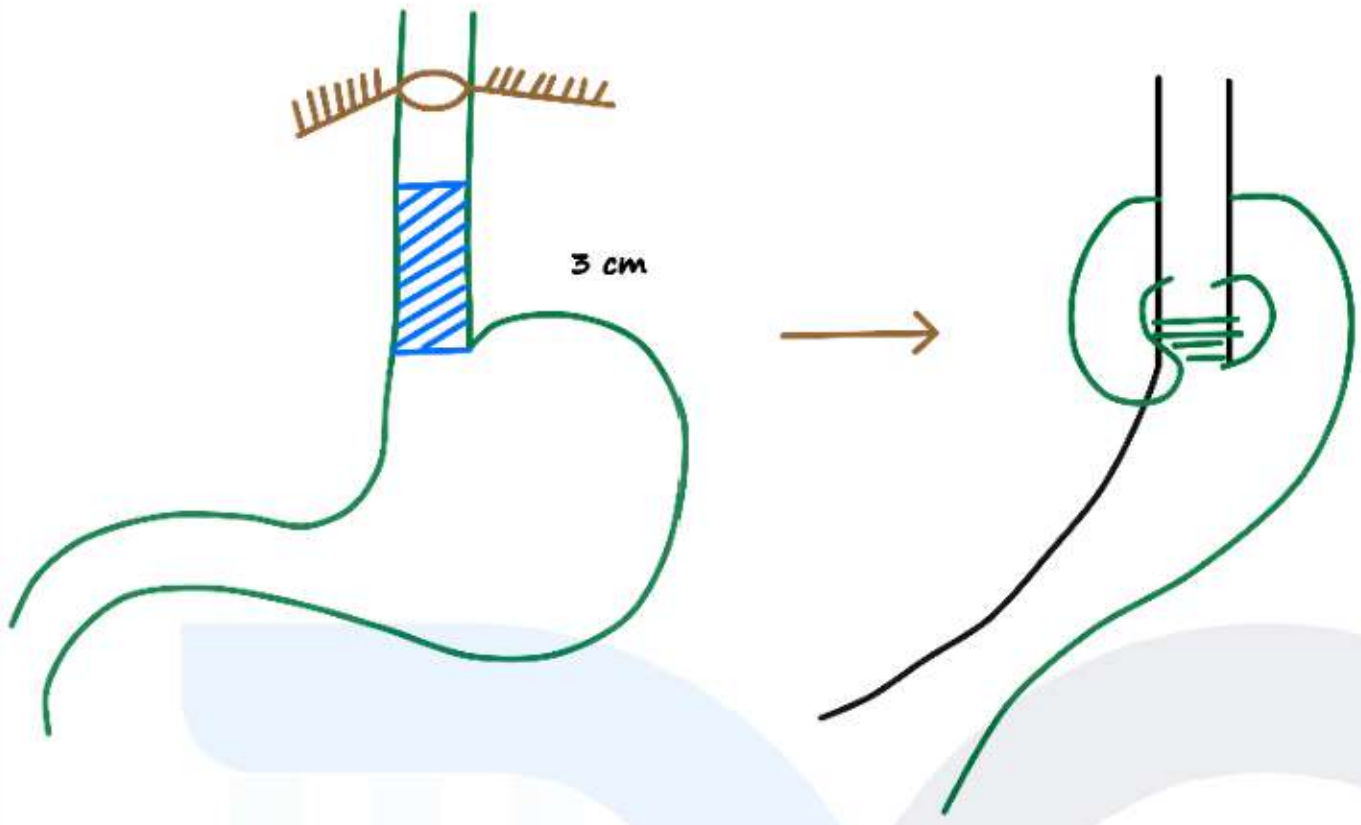

Fundoplication

Fig: 8

- Pars flaccida technique – Cut open the lesser omentum
- Shoe shine maneuver – Fundoplication
- 5 ports laparoscopic technique

TUTORIALS
LOGIN FOR SUCCESS

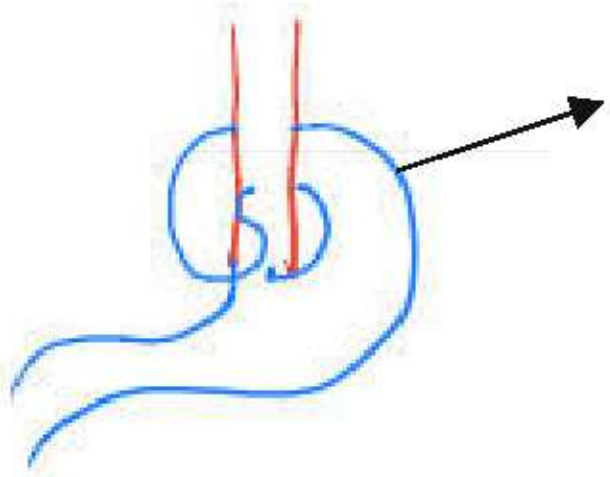

360^{0} Posterior wrap

↓

Nissen fundoplication

↓

Comp: Gas bloat syndrome

↓

Prevent this – Nissen floppy (360^{0})



180 – 270^{0} posterior toupet



DOR-Anterior wrap (180^0)
→ after Modified myotomy
90^0 – Watson fundoplication

VATS – video assisted thoracoscopic surgery-belsey mark IV -270 wrap posteriorly – in obesity, posterior abdominal adhesions

Endoscopic procedures of GREG

- Radio frequency abalation RFA procedure for strengthening LES

  ↓

  RFA – Stretta procedure

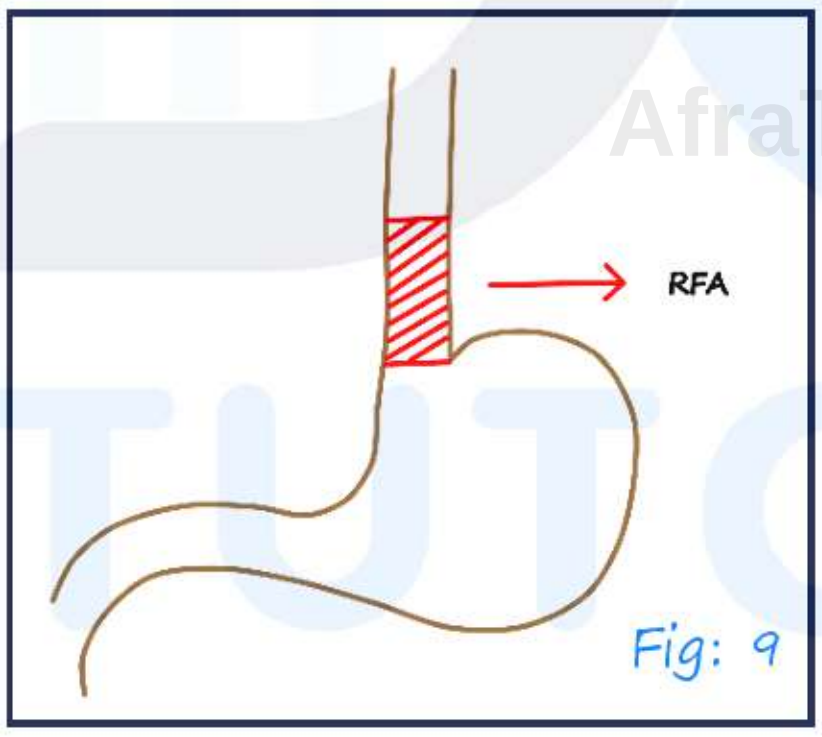

Fig: 9

- Vinyl alcohol/Ethyl alcohol can be injected to strength

  ↓

  Enteryx procedure

- Transoral incisionless fundoplication (TIF) – Esophyx

  ↓

  Prosthesis placed

- **Linx procedure** – Two magnets placed in lower end of esophagus

  – Under trial

AfraTafreeh.com
TUTORIALS
LOGIN FOR SUCCESS

AfraTafreeh.com

- Old procedure – Angeletik prosthesis – stent with valve

  Angeletik prosthesis ↓ Not done nowadays

  stent with valve ↓ Migration risk (+)

TUTORIALS
LOGIN FOR SUCCESS

BARRETT'S ESOPHAGUS

Tissues on biopsy 00:01:55

- Squamous epithelium → Intestinal columnar epithelium
  ↓
  Pinkish red

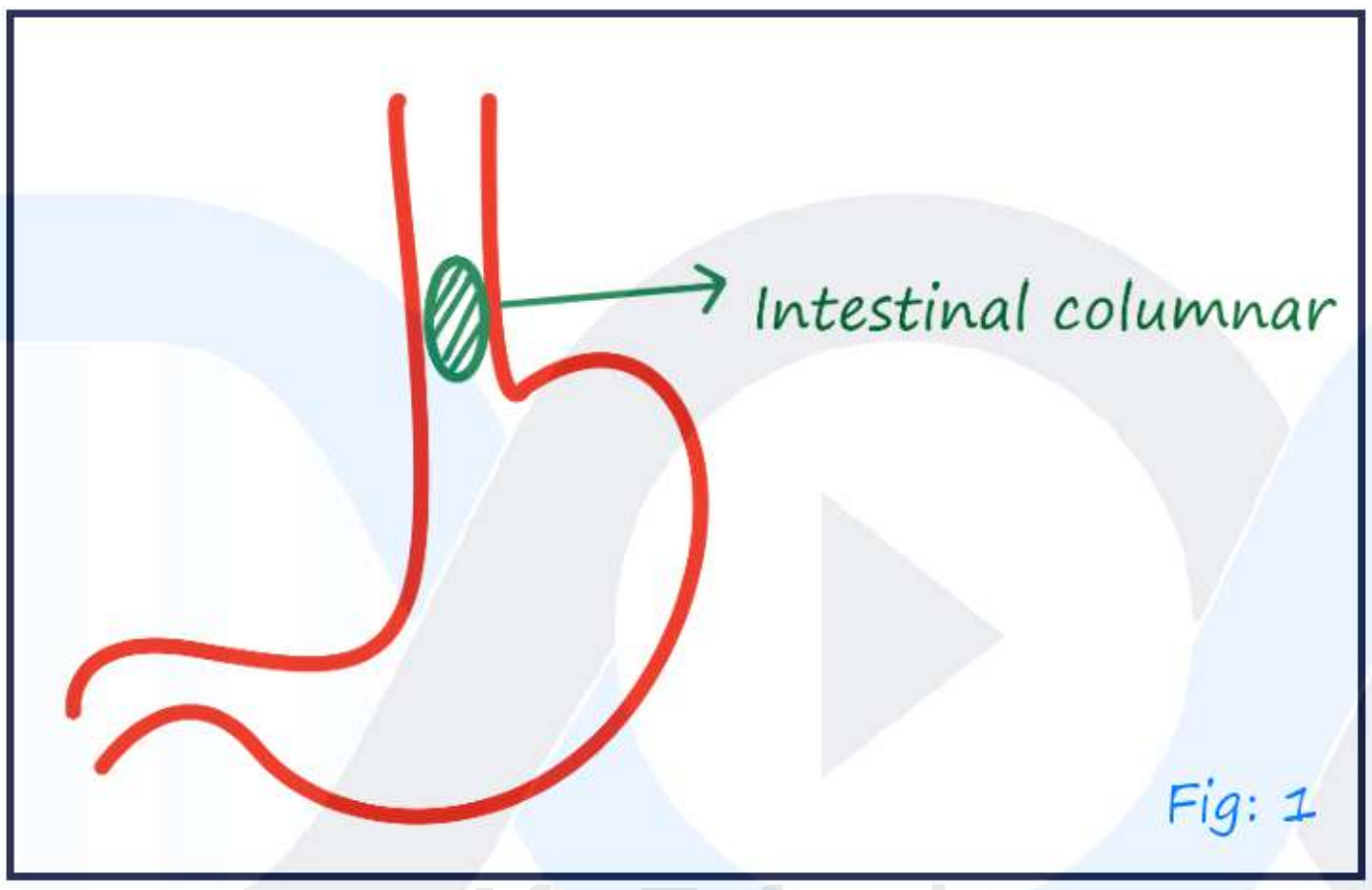

Fig: 1

AfraTafreeh.com
TUTORIALS
LOGIN FOR SUCCESS

- Confirmation is by biopsy
- Biopsy protocol – Seatle biopsy protocol
  ↓
  For every 1cm, 4 side biopsy is done
  ↓
  Goblet cells ⊕ on biopsy

Biopsy

- **No dysplasia** ↓ Follow up after 3 years
- **Low grade** ↓ 6 months ↓ Annual follow up
- **High grade** ↓ 10% risk of malignancy ↓ 3 months ↓ **Eradication**

AfraTafreeh.com

Surgical	Endoscopic
↓	↓
Vagal sparing esophagectomy- for high grade barret's	ESD EMR Laser ablation

- ESD – Endoscopic Submucosal Resection
- EMR – Endoscopic Mucosal Resection

Vagal sparing esophagectomy

- Indicated for premalignant barret's

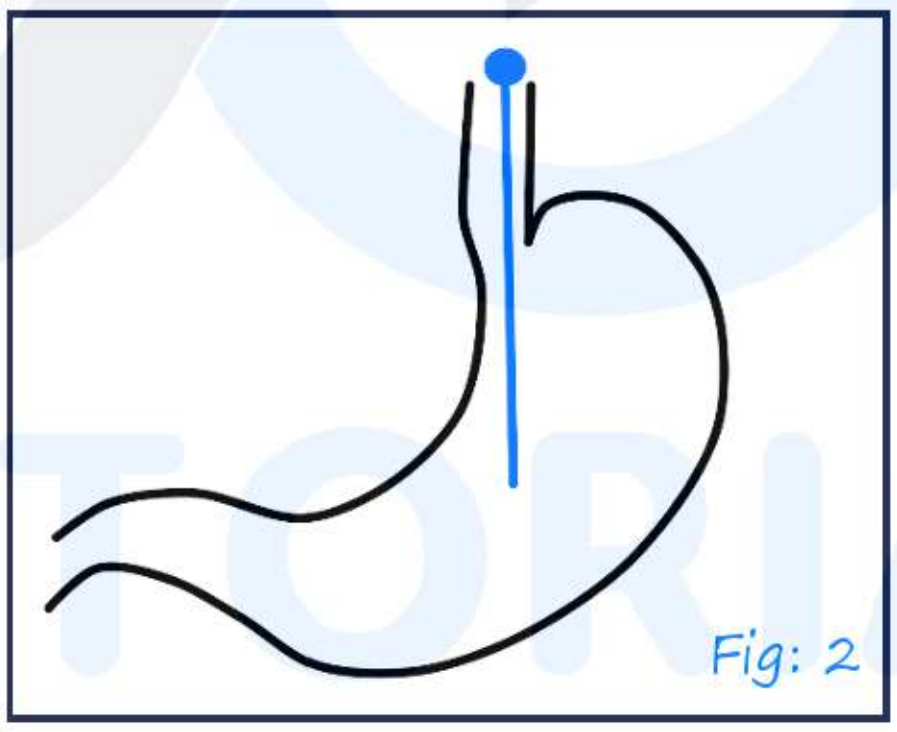

Fig: 2

- Stripper is passed through stomach and tie the mucosa strip the mucosa and submucosa

Barret's irreversibility conditions 00:06:18

- Barret's is irreversible without treatment → reversible on treatment
  - PPI
  - Fundoplication

Classification 00:07:05

1. Prague – CM
   - C_2 – Circumferential metaplasia for how many cm
   - M_5 – most Proximal extension how many cm

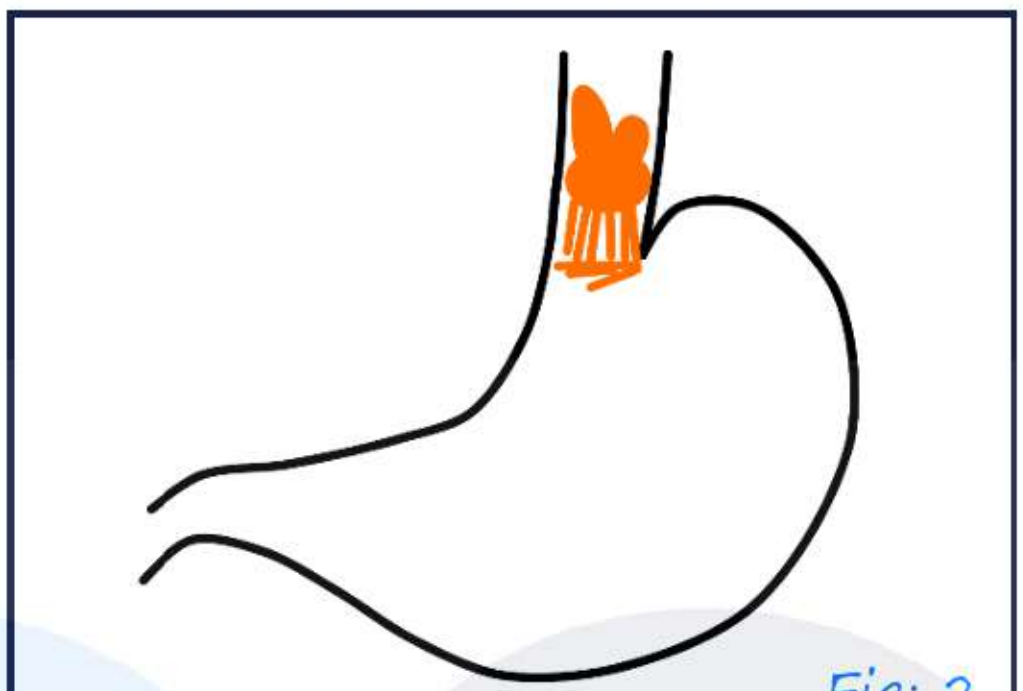

Fig: 2

2. Short segment < 3cm
   - Long segment > 3cm

AfraTafreeh.com

Risk of barret's 00:09:13

- 40 times more risk of adenocarcinoma → most common risk factor – Barret's
- High grade dysplasia – 10% risk of malignancy
- Barret's - <1% per year
- In Asians & Indians – risk of Barret's esophagus is less.

TUTORIALS LOGIN FOR SUCCESS

AfraTafreeh.com

HIATUS HERNIA

Anatomy

- Hiatal opening at 10th vertebra

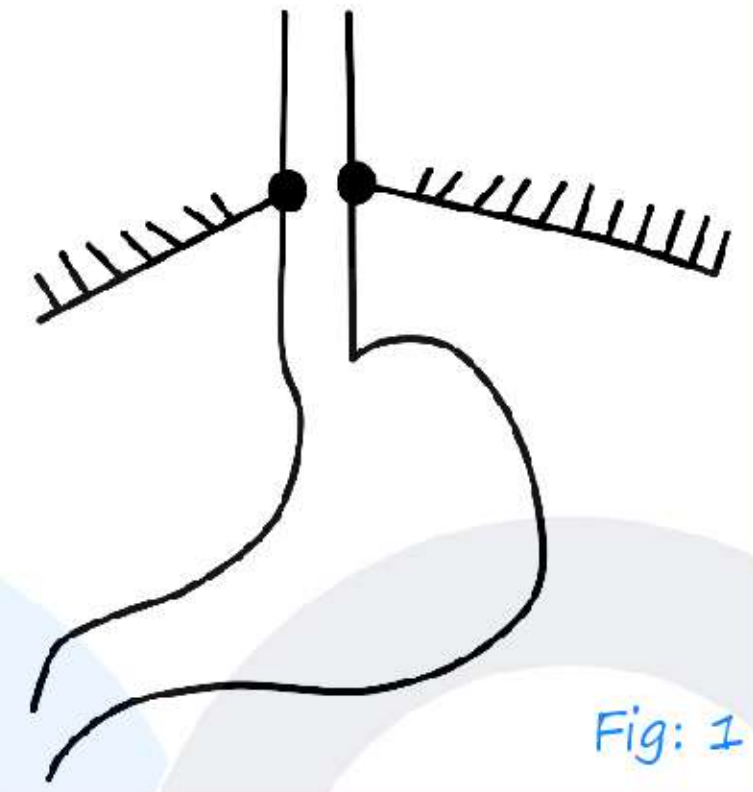

Fig: 1

Types

- Type – I – Reflex of contents

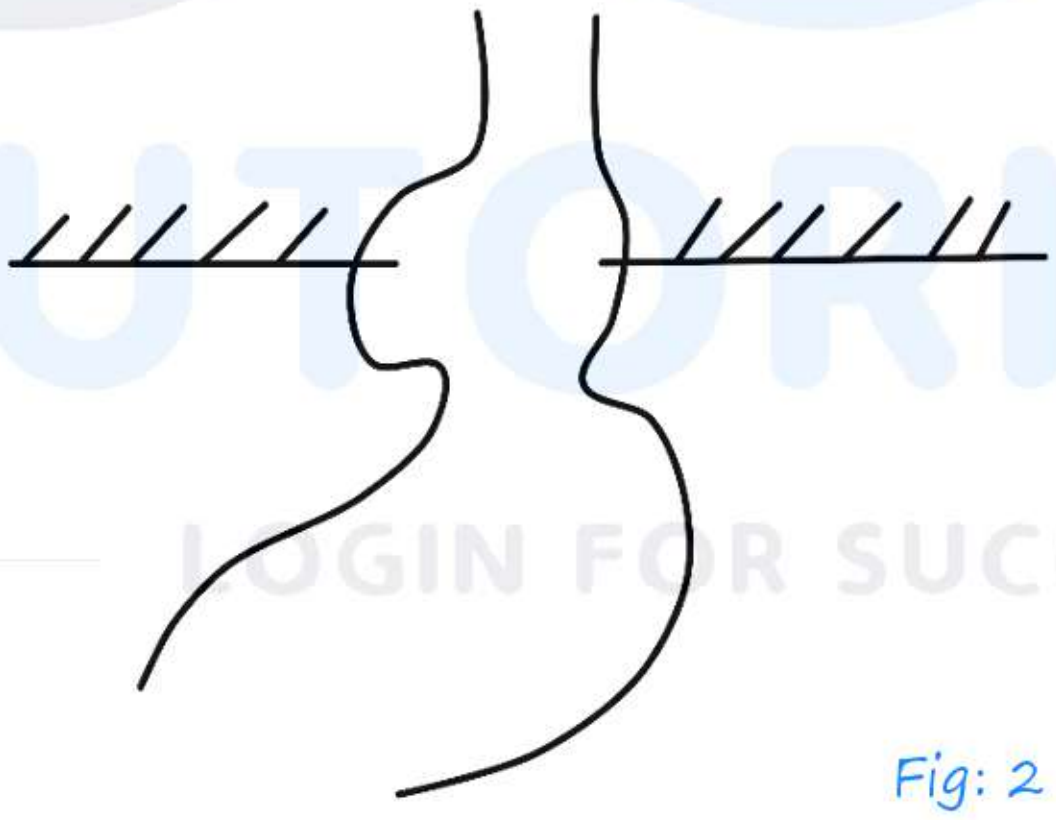

Fig: 2

– OG junction has gone into hiatus

– Sliding hiatus hernia → most common

– Most common presentation: – GERD

- Part of stomach going up and down develops vertical ulcer known as CAMERON's ULCER
- Treatment – Elective fundoplication

- Type – II – Hiatus is weak

  - OG junction remains in position
  - Some part of stomach (fundus) goes into Hiatus opening.
  - Paraesophageal/Rolling hiatus hernia.

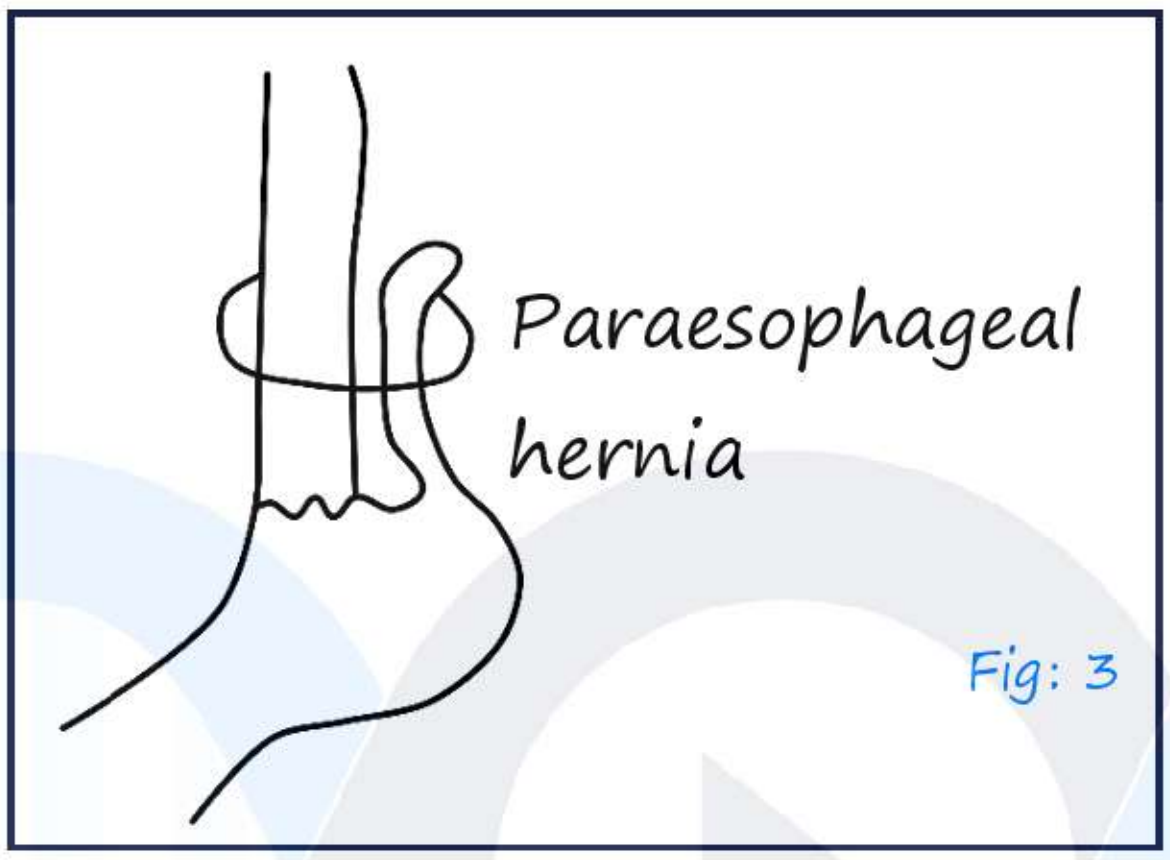

Fig: 3

- Part of stomach which enters gets stuck

↓

- Bleeding
- Peforation

↓

Treatment – emergency antropexy

- Type III: Sliding + paraesophageal

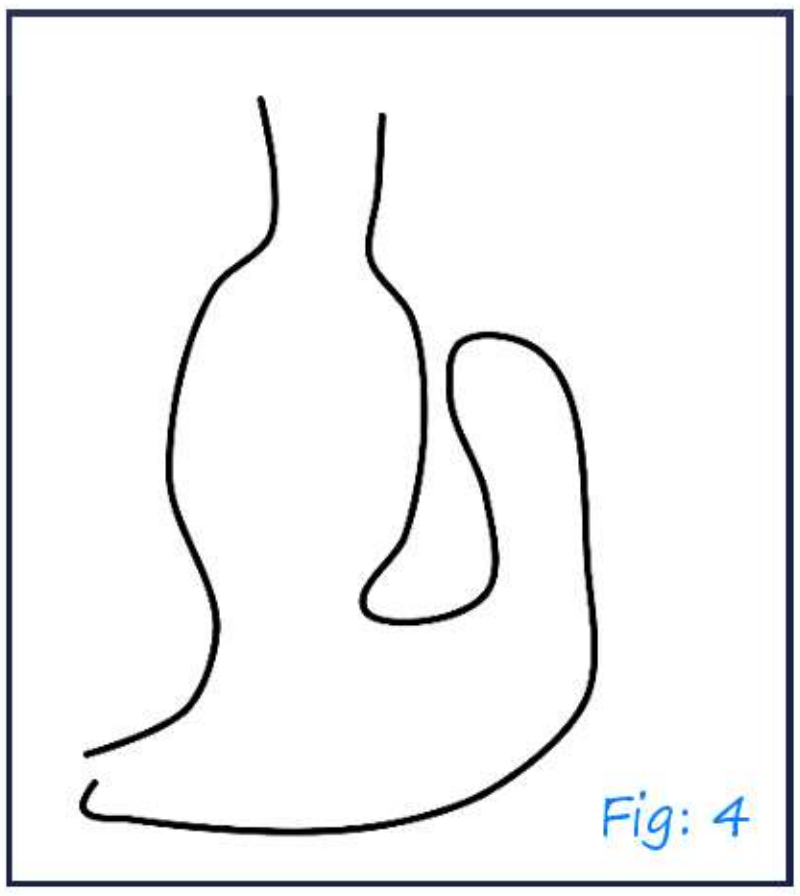

Fig: 4

- Type IV: Massive hiatus hernia

AfraTafreeh.com

- Angle of his not disturbed in paraesophageal hernia type II (maintained)

Investigation of choice

- IOC for all hiatal hernia – CT thorax with upper abdomen (oral contrast)

TUTORIALS
LOGIN FOR SUCCESS

ESOPHAGEAL PERFORATION

Division of Esophagus 00:00:28

- 25 cm in length
- 4 divisions → Cervical esophagus
  → Upper thoracic
  → Middle thoracic
  → Lower thoracic
- Most common perforation – cervical esophageal perforation
  ↓
  Most common cause – Iatrogenic
- Foreign body (coin)
  ↓
  most common site – cricopharynx
- Most common FB in esophagus– food bolus
- If the baby swallows button battery
  ↓
  Esophagus, Stomach – Retrieve by endoscopy
  Small intestine – surgery advised
- Any foreign body which has crossed the cricopharynx will not get trapped anywhere.
- Diameter of cricopharynx – 13mm

AfraTafreeh.com
DOC TUTORIALS LOGIN FOR SUCCESS

AfraTafreeh.com

Boerhaave syndrome — Ramu

Mallory Weiss tear — Somu

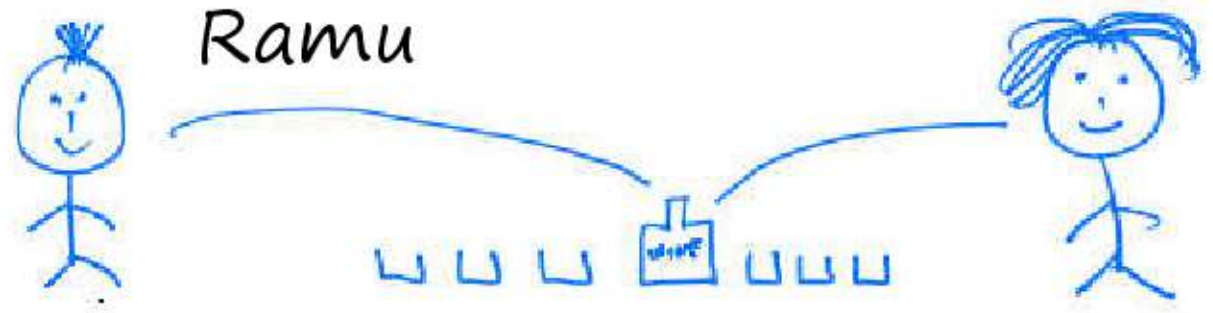

Ramu:

Vomiting

Collapsed

↓

BP?

PR?

Somu:

↓

C/O hematemesis

BP / PR — N

walks to hospital

- As ramu vomited, the cricopharynx (glottis) is a tightly closed, the food particles which are coming are unable to come as vomiting, therefore they created a rent in the left lower posterior esophagus

↓

Mackler's triad

Vomiting

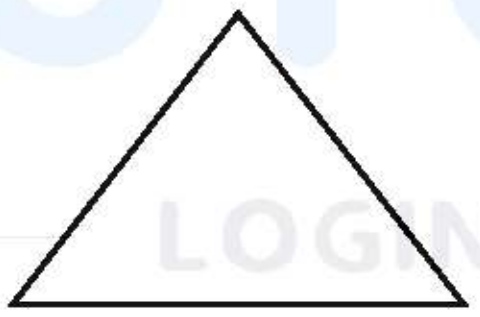

Chest pain **Subcutaneous emphysema**

↓

Golden period <24 hours

↓

Surgery has to be done

DOT TUTORIALS LOGIN FOR SUCCESS

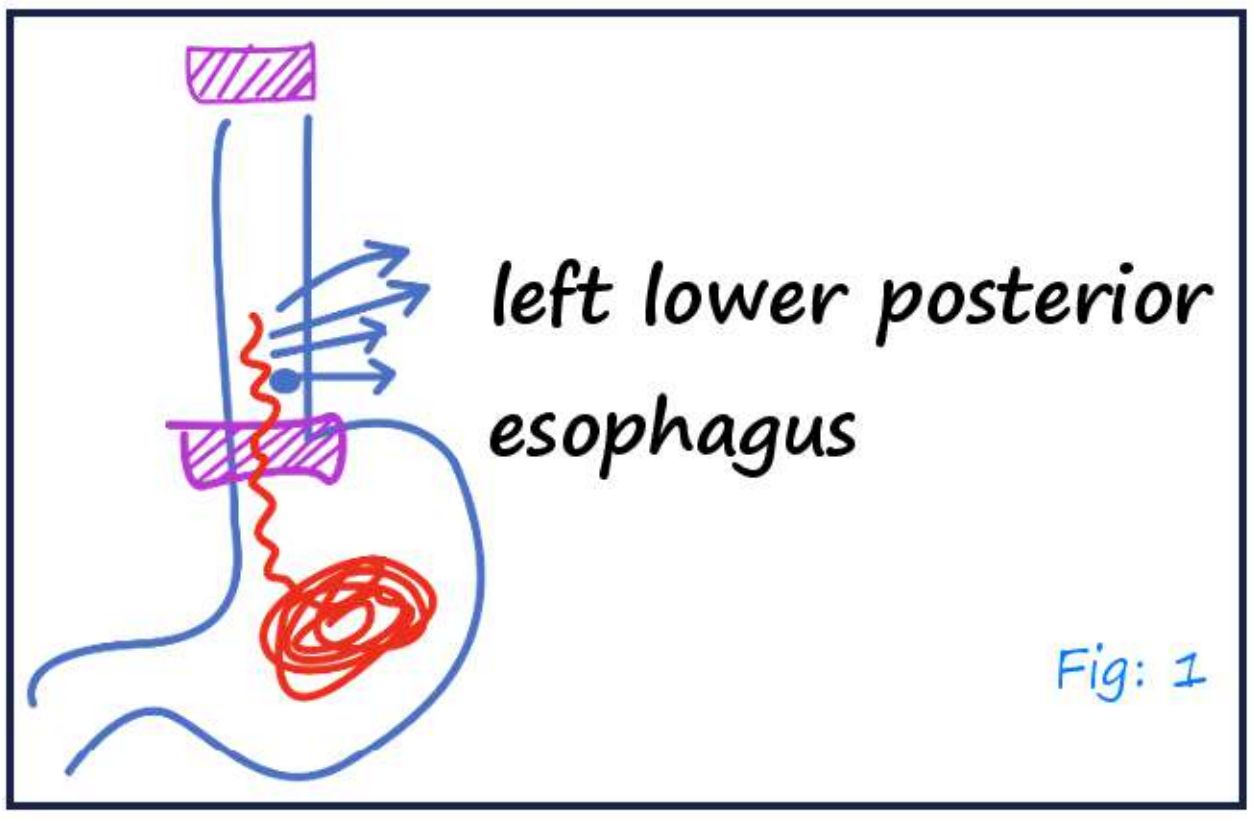

Fig: 1

Mallory Weiss tear

- LES is tightly closed, food particles get accumulated in stomach and create tear at below OG junction at lesser curve

  ↓

  90% bleeding stops

  10% endoscopic coagulation

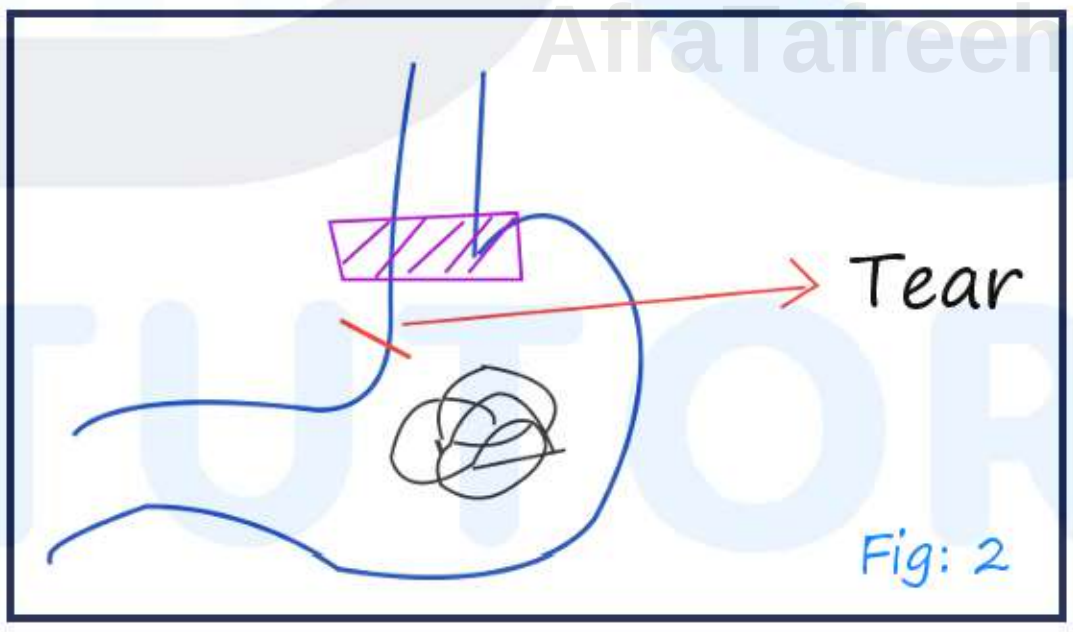

Fig: 2

AfraTafreeh.com
DOC TUTORIALS
LOGIN FOR SUCCESS

AfraTafreeh.com

Management of Boerhaave's syndrome 00:04:15

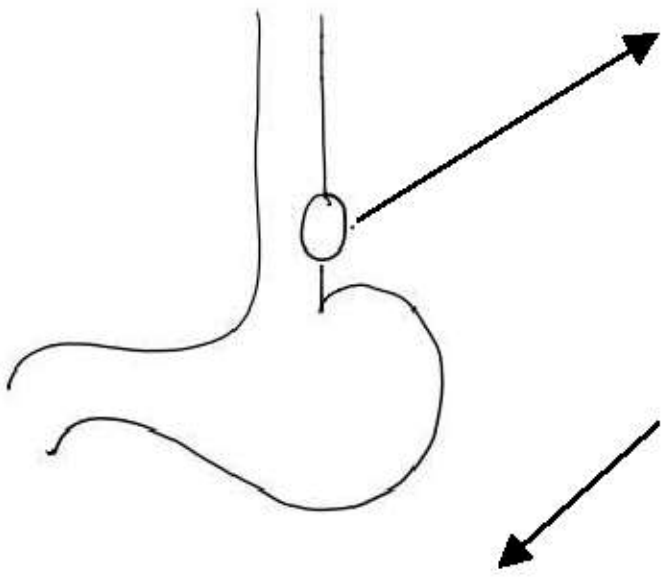

Tear in the lower and of esophagus

↓

Food particles enter into chest and cause mediastinitis

↓

Left thoracotomy

↓

wash and repair the rent

↓

ICD will be kept inside the chest

Done in <24 hours

- After 24 hrs → unhealthy tissue

↓

Bring the tissue out as esophagostomy

ICD inside the chest

↓

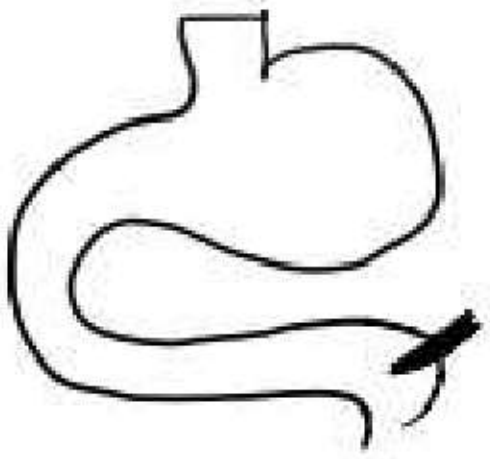

- After 24 hours → If tissue is healthy

↓

Repair

- In esophageal rupture, subcutaneous emphysema seen on CXR

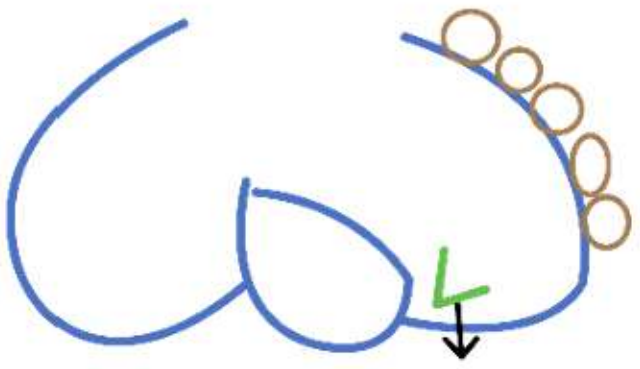

Naclerio V sign
↓
At cardiophrenic angle

Fig: 3

Corrosive Ingestion

Ramu

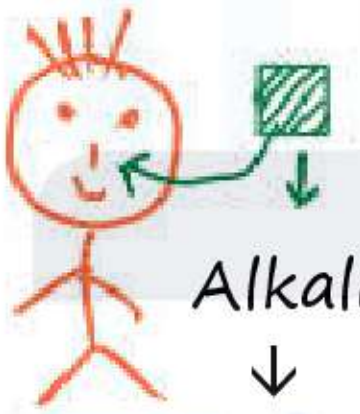

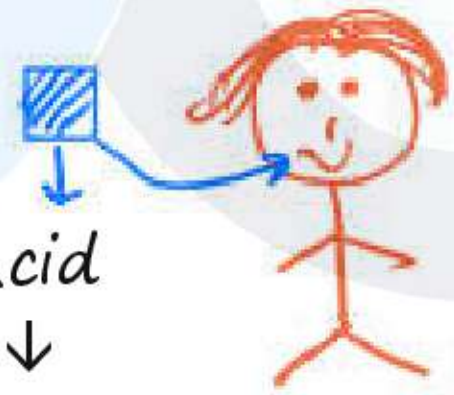

Alkali
↓
Enormous amount
↓
Liquefactive necrosis of esophagus

- perforation increases esophageal damage
  ↓
  - Strictures of esophagus
  - SCC of esophagus (1000 times)

Acid
↓
Little amount
↓
Coagulative necrosis of esophagus (eschar)
↓
No perforation gastric increases damage
↓
Damage 6 months – 1yr
↓
Antral stricture

- Dilation of esophagus – savary gillard dilators
- Coloplasty – colon a substitute

AfraTafreeh.com
TUTORIALS
LOGIN FOR SUCCESS

AfraTafreeh.com

- Score for mortality in esophageal perforation

↓

PITTSBURGH SCORE

Indications of non-operative management of EP

↓

Cameron Criteria

↓

1. Instrumental perforation
2. cervical esophageal perforation
3. Low septic load
4. Draining collection
5. Hemodynamically stable

↓

NPO

RT – NG feeding

feeding jejunostomy

TUTORIALS
LOGIN FOR SUCCESS

Contrasts used in GIT

Non water soluble

↓

$BaSO_4$

↓

- 100% sensitive
- gold standard
- Contrast of choice

↓

Because barium remains in chest & future confusion arises

Water soluble

High osmolar

↓

Gastrograffin K/a Diatrozoule Na

↓

1st used contrast

Disadvantage

1. Less sensitive
2. Pulmonary edema

Low osmolar

↓

IOHEXOL

↓

@ iodine based

mypaque

omnipaque

↓

Safest contrast

↓

- Costly
- IOC for TEF

- IOC to detect early esophageal perforation

  ↓

  CECT thorax with oral contrast

AfraTafreeh.com
TUTORIALS
LOGIN FOR SUCCESS

AfraTafreeh.com

MISCELLANEOUS

Plummer vinson syndrome 00:00:15

- Also known as Paterson Kelley syndrome
  - Sideropenic dysphagia
- Seen in 20-40 years female
- They develop a web at post cricoid region

Fig: 1

- Clinical features: - Dysphagia
- Premalignant to
  - Oral cancers
  - Oropharyngeal cancers
  - Oesophageal cancers
- Treatment: - Laser lysis of web

Schatzki's ring 00:02:49

- Due to GERD
- Seen at squamocolumnar junction
- Above lined by squamous epithelium
- Below lined by columnar epithelium

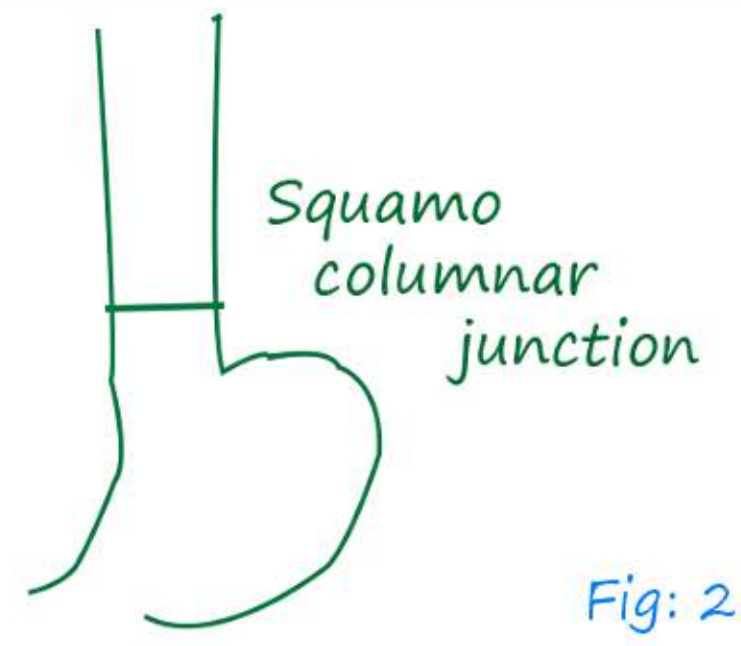

Fig: 2

- Submucosal thin ring
- Treatment: Endoscopic dilatation + fundoplication
- Clinical features: **Episodic intermittent aphagia**
- DD: - **Peptic stricture/ thick**

Dysphagia lusoria 00:05:21

- Oesophagus is compressed by subclavian artery

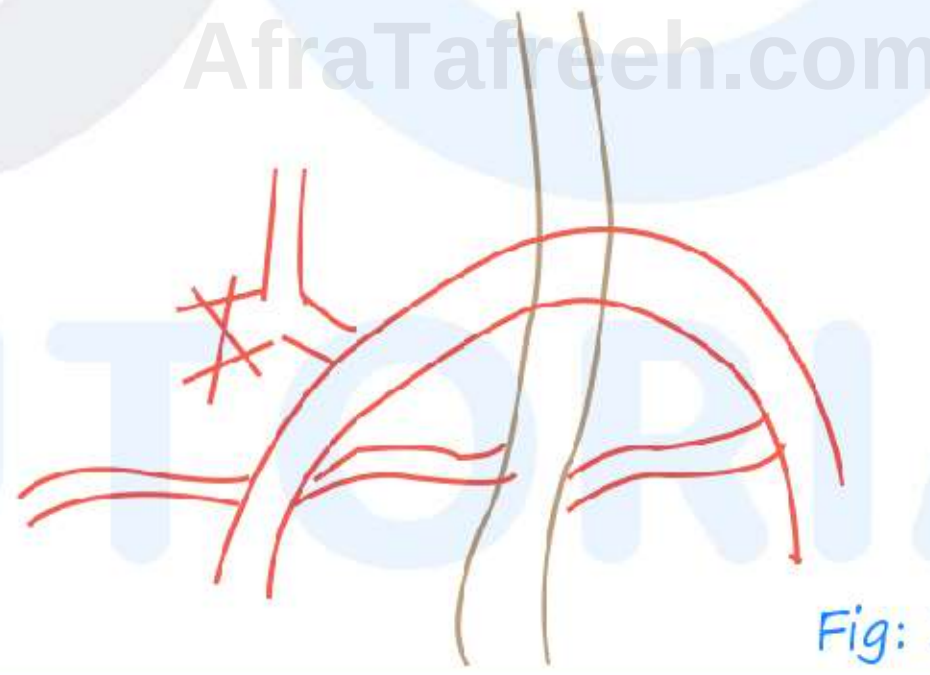
Fig: 3

AfraTafreeh.com

- Most common causes of dysphagia lusoria – Aberrant R subclavian artery from descending aorta
- Features
  - Posterior compression
  - Incomplete ring around oesophagus
  - Asymptomatic – no treatment needed
  - In symptomatic – reimplant the vessel

AfraTafreeh.com

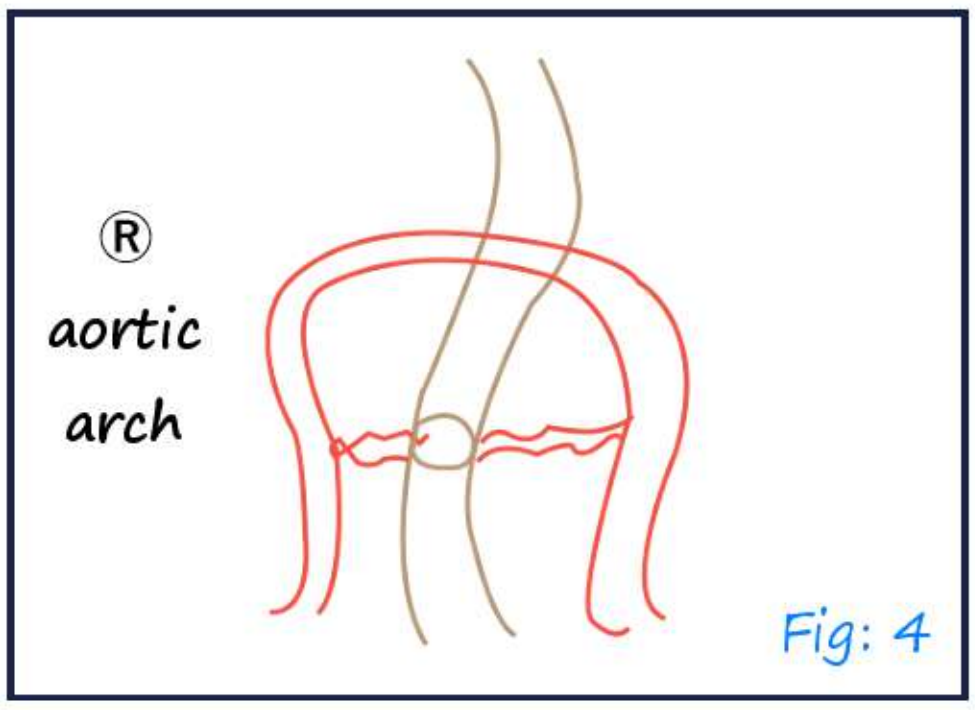

Fig: 4

- Ⓛ subclavian artery arising from descending aorta compresses the oesophagus → forms a complete ring and causes posterior compression of oesophagus
- Right aortic arch forms complete ring around oesophagus

Pulmonary sling: 00:08:34

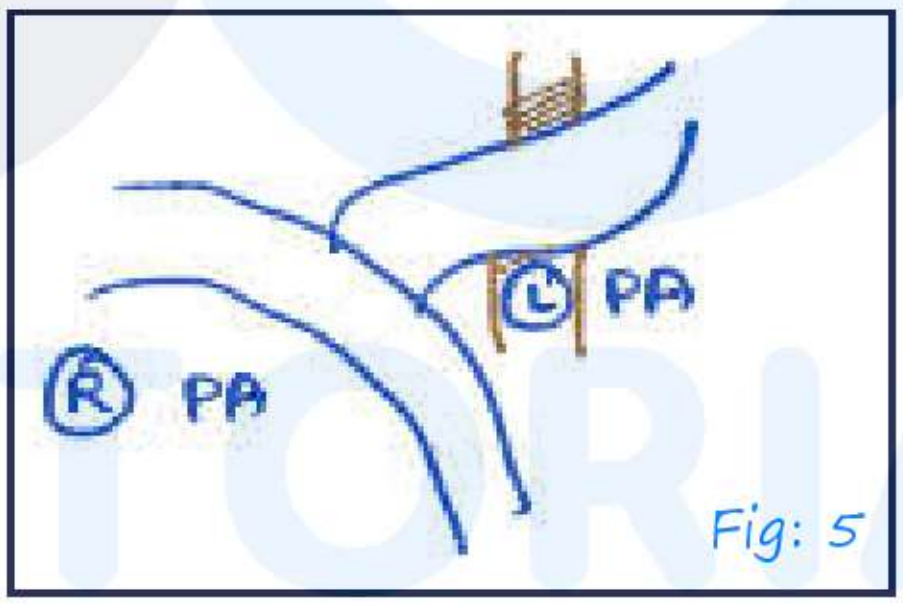

Fig: 5

- Ⓛ pulmonary artery arises from Ⓡ pulmonary artery
- Abnormal Ⓛ pulmonary artery

↓

Causes anterior compression of oesophagus

↓

Tracheal stenosis

- **All patients of pulmonary sling need surgery**

Congenital tracheo esophageal fistula 00:09:40

- Seen in newborn
- Associated with down's syndrome & vacterl syndrome
  - V – Vertebral anomalies
  - A – Anorectal anomalies
  - C – Cardiac
  - T – Tracheo oesophageal
  - R – Radial limb hyperplasia
- 5 types
  - Type A: - Pure oesophageal atresia

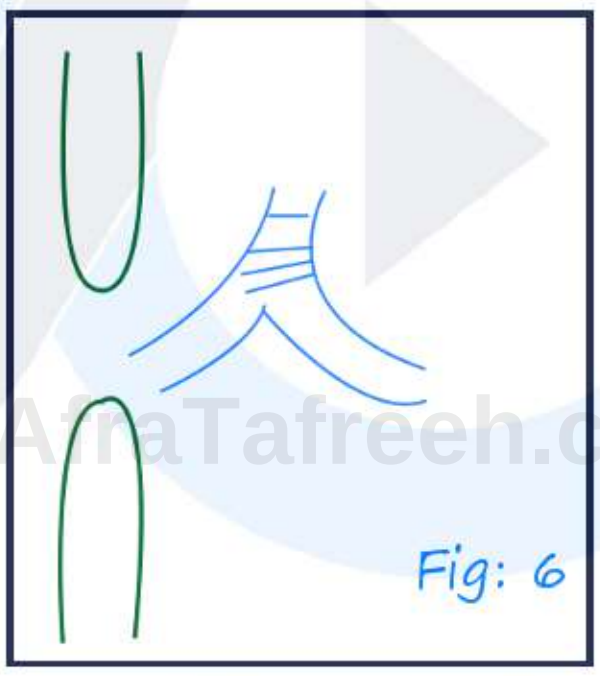

Fig: 6

  - Type B: - Proximal fistula (very dangerous type)

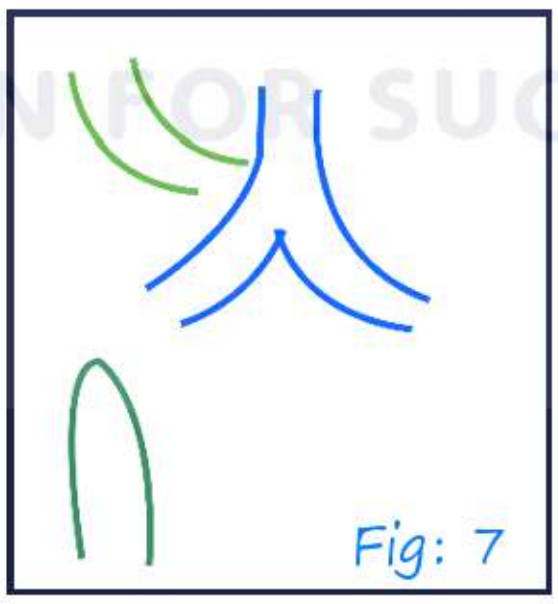

Fig: 7

  - Type C: - Distal fistula



Fig: 8

AfraTafreeh.com

- Type D: - Both proximal and distal (Reverse 'K' fistula)

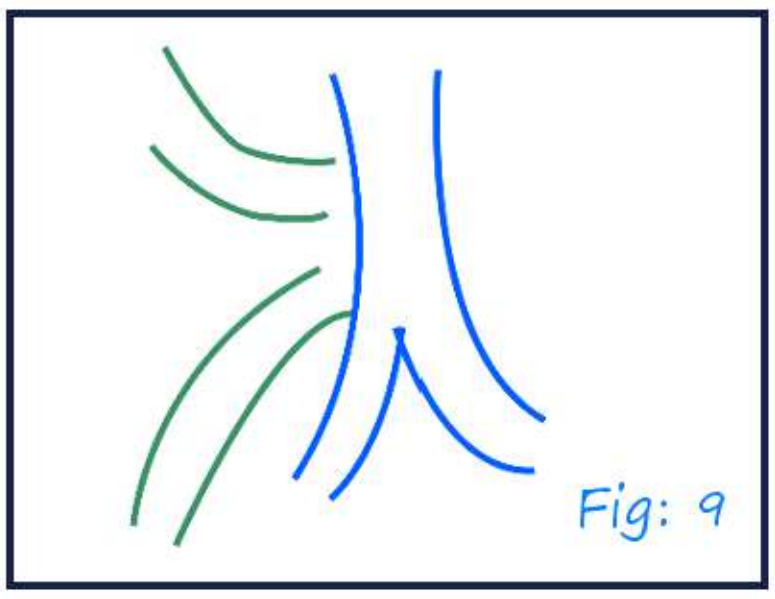

- Type E: - H type fistula → childhood c/o respiratory tract infection

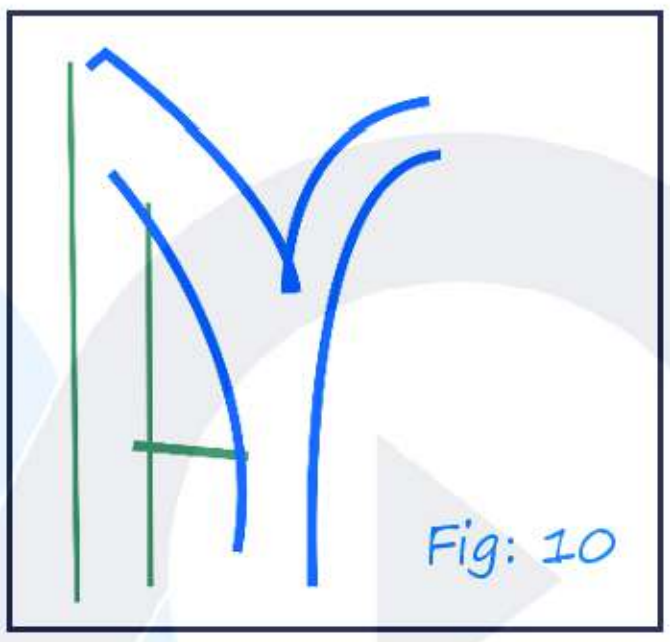

- Q. most common type – Type C (80-85%)
- Q. 2nd most common type – Type A (10%)
- Q. least common – Type B
- Q. late presentation – Type E

• Clinical features: -
  - Drooling of salvia
  - Cyanotic spells ⊕
  - Ryles tube coiling ⊕

• IOC
  - A
  - B
  - C
  - D

  (A–D) **Iohexol swallow**

  - E – Doublescopy

i. Endoscopy

ii. Bronchoscopy

Eosinophilic esophagitis 00:14:43

- Common in middle aged men
- Associated with eosinophilia
- Dysphagia ⊕
- On endoscopy: - Trachea like oesophagus

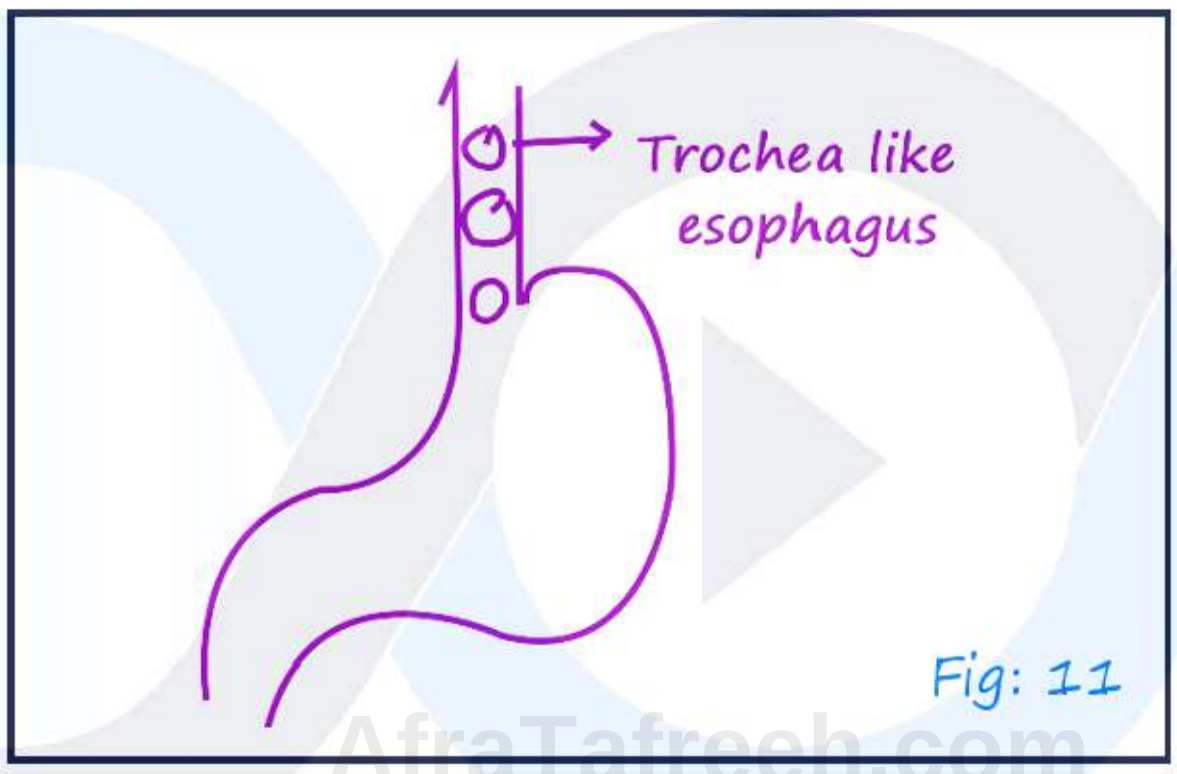

Fig: 11

- On barium swallow – Feline oesophagus

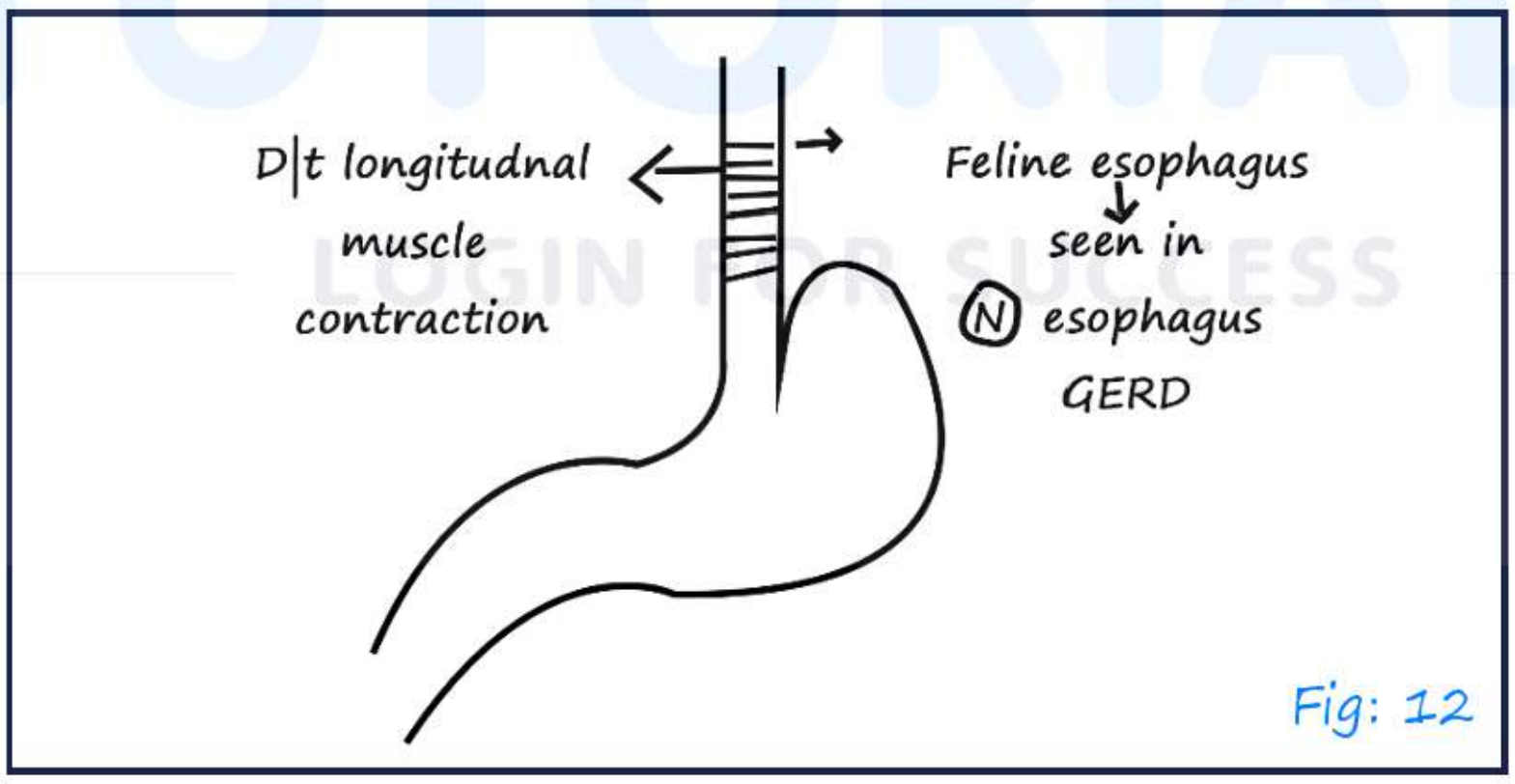

Fig: 12

- Treatment: - Steroids (Inhalational & ingestional)

AfraTafreeh.com
TUTORIALS LOGIN FOR SUCCESS

AfraTafreeh.com

Infections in esophagus 00:17:29

- All infective conditions present with painful dysphagia (odynophagia)

1.Candidiasis: - Seen in

- DM
- HIV
- Immunocompromised

2.HSV: - Seen in

- DM
- Immunocompromised
- Transplantation done patients

3.CMV: - Seen in

- DM
- Immunocompromised
- Transplantation done patients

TUTORIALS
LOGIN FOR SUCCESS

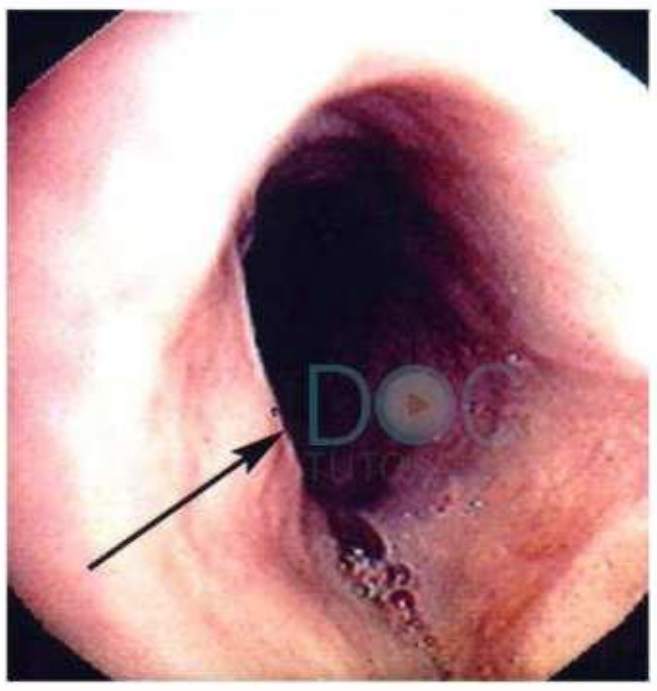

Fig: 13

Fig: 14

Fig 13 and 14: plummer-vinson syndrome

AfraTafreeh.com

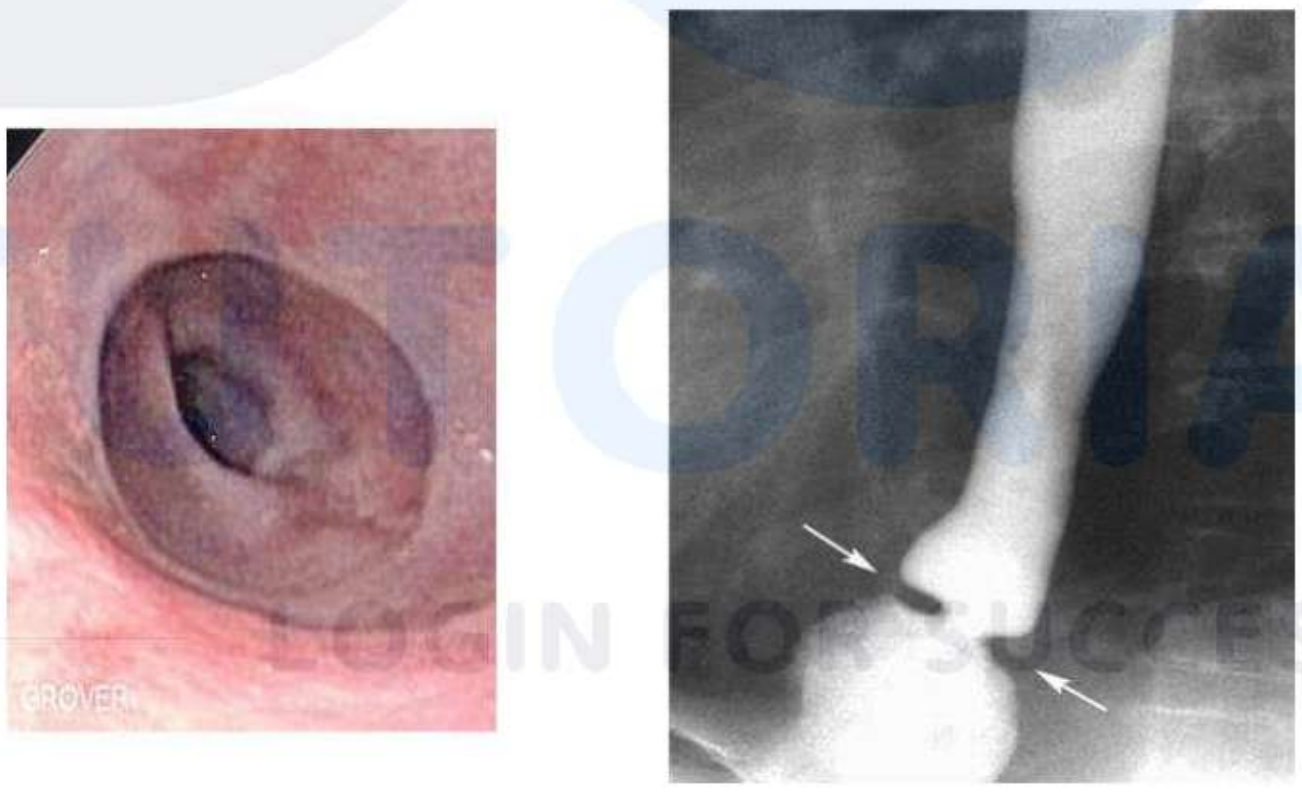

Fig: 15

Fig 15: Schatzki's ring

AfraTafreeh.com

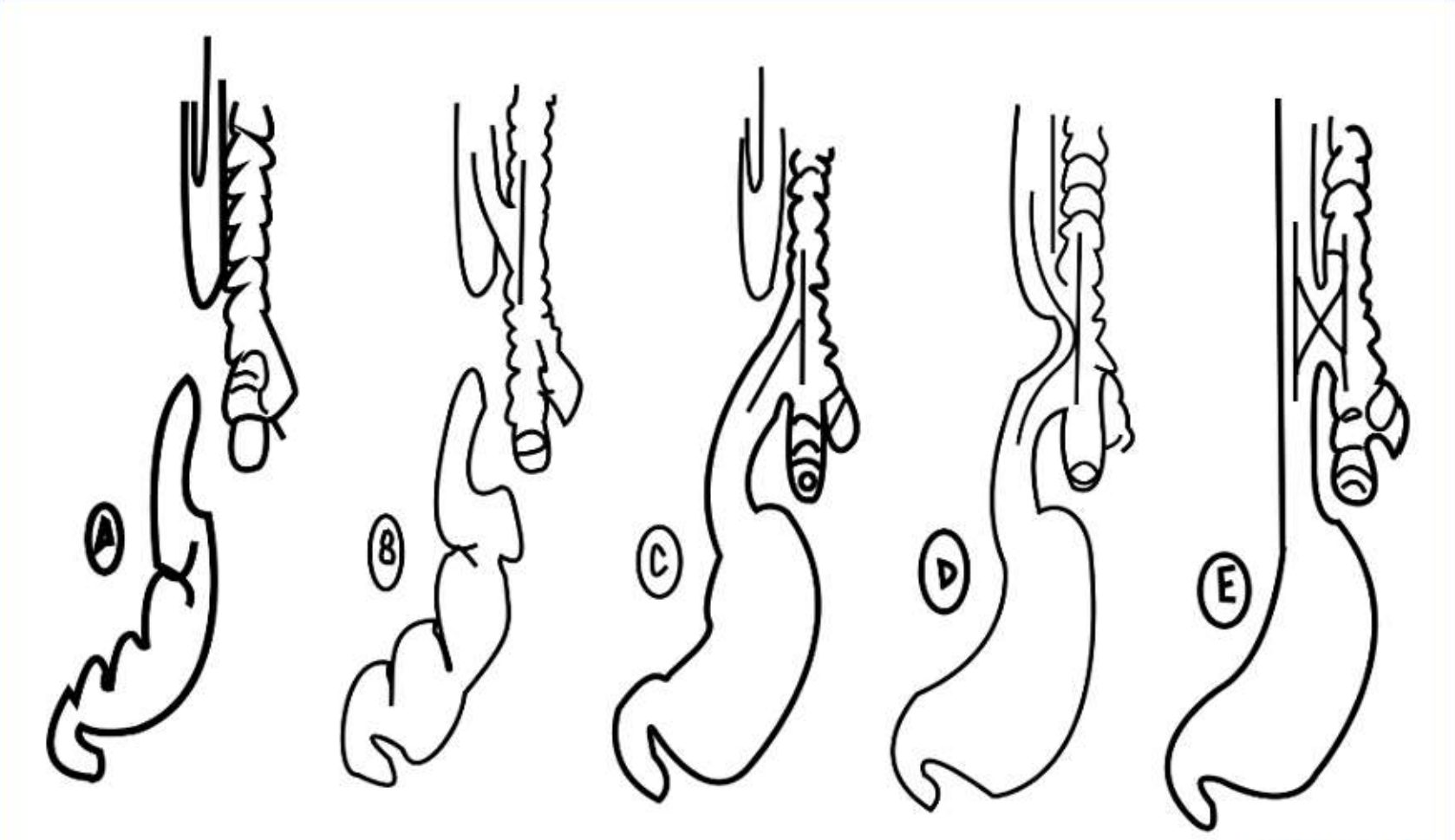

Fig: 16

Fig 16: Congenital trachea-esophageal fistula types

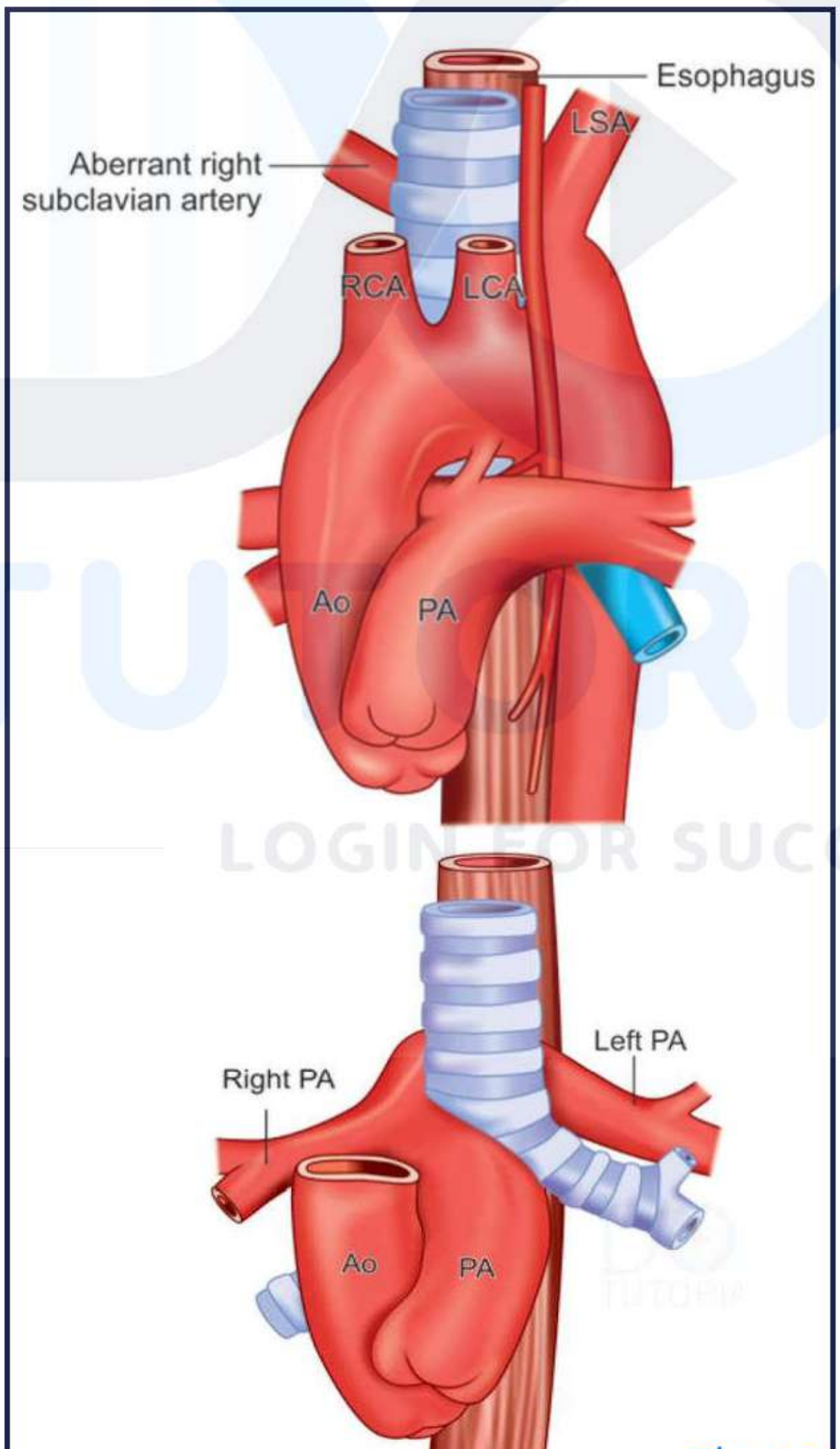

Fig: 17

Fig: 17: dysphagia lusoria

DOC TUTORIALS LOGIN FOR SUCCESS

- Eosinophilic esophagitis (EE) has a characteristic finding often called the "ringed oesophagus" or the "feline oesophagus", as the oesophageal rings are felt to look like the stripes on a housecat.
  - Endoscopy shows multiple oesophageal rings, longitudinally oriented furrows are seen, mimicking like a "Trachea" also known as trachea like oesophagus.

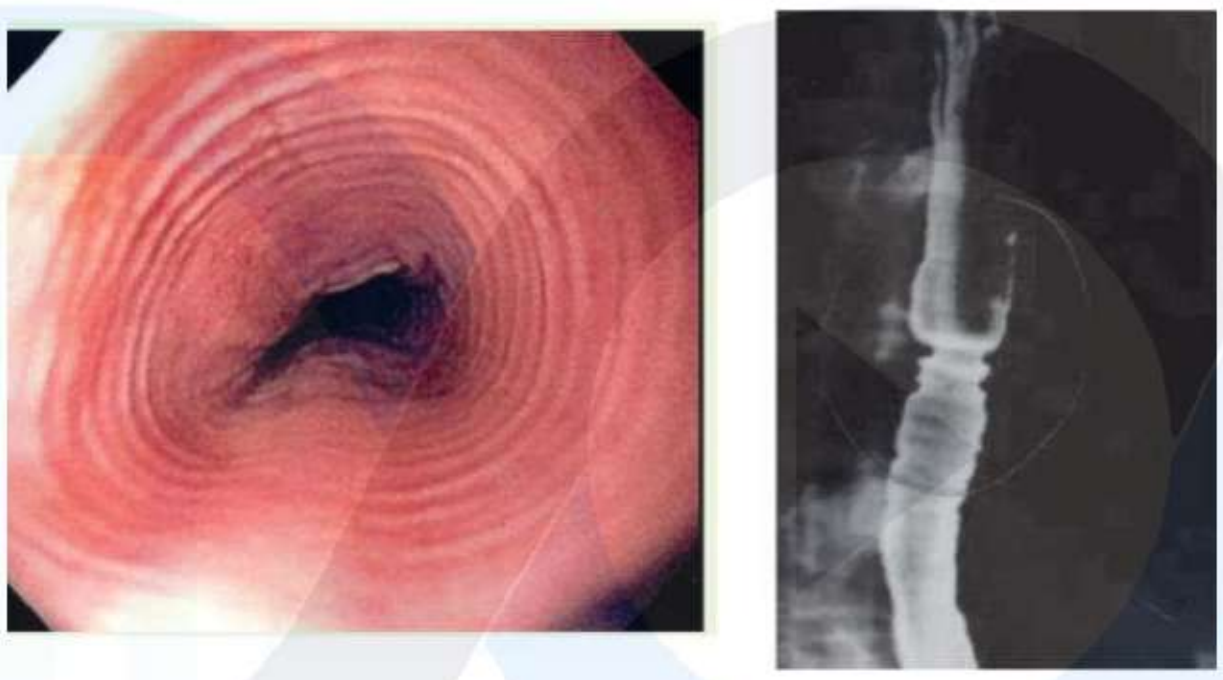

Fig: 18

AfraTafreeh.com

Fig: 18: Eosinophilic esophagitis

TUTORIALS
LOGIN FOR SUCCESS

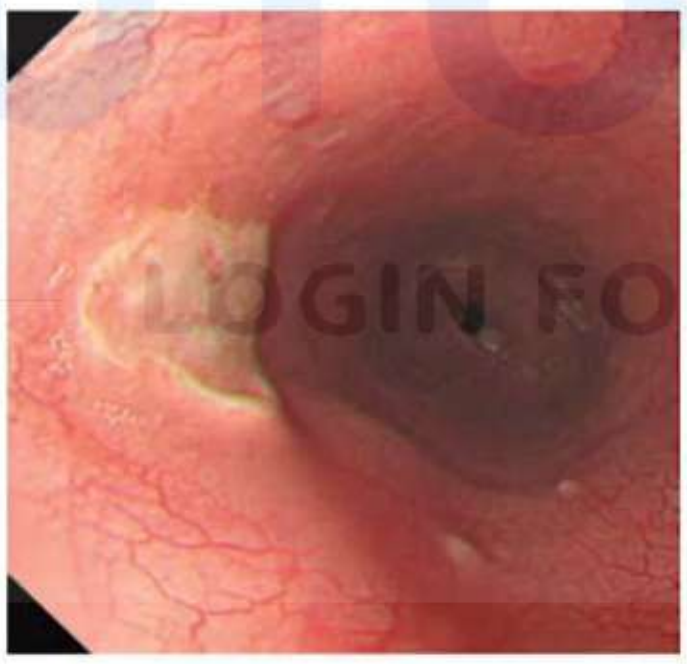

Herpes simplex Esophagitis Fig: 19

CMV esophagitis Fig: 20

AfraTafreeh.com

TUMORS OF ESOPHAGUS

Tumors of esophagus 00:00:13

Benign

↓

Leiomyoma

↓

- Most common in lower part of oesophagus
- Develops on 4th and 2nd layer (most common) – EUS
- Appears as hypodense well-defined lesion on CT

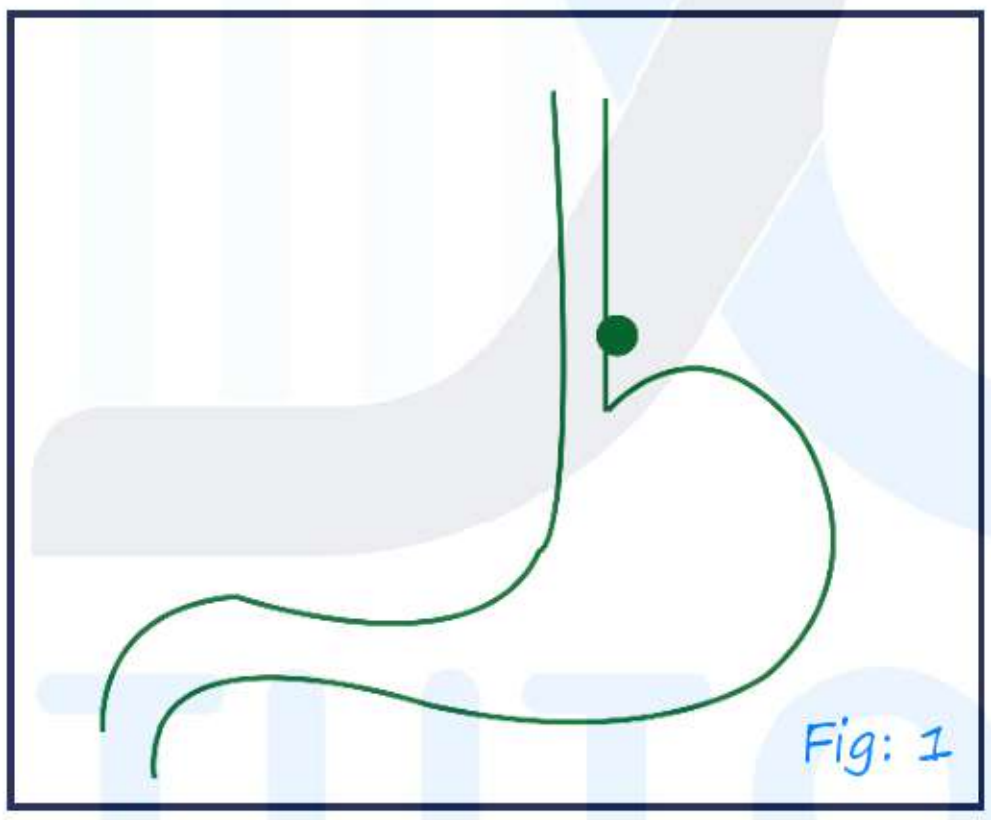

Fig: 1

- Presents with dysphagia → enucleation
- Confirmed EUS guided biopsy

Malignant

- Squamous cell cancer – most common in middle 1/3 (most common in India and world).
- Adenocarcinoma – most common – lower 1/3 (most common in western).

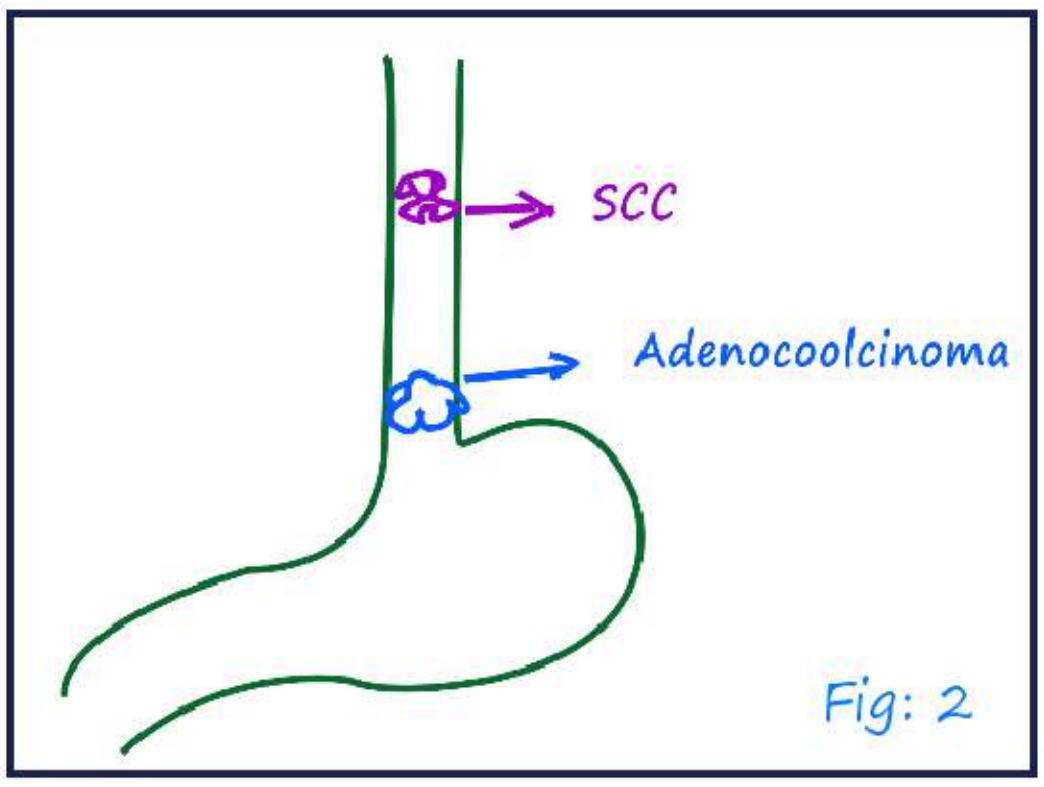

Etiological factors 00:03:10

- SCC
  - Hot tea
  - Smoking
  - Alcohol
  - Tobacco
  - Achalasia cardia
  - Plummer vinson syndrome
  - Corrosive (1000 times)
  - Tylosis palmaris/plantaris
  - Molybdenum deficiency
  - Low SE status
- Adenocarcinoma
  - High SE status
  - GERD
  - Barret's
  - Scleroderma
  - Deficiency of antioxidants
  - Smoking
  - Alcohol has no relation to adenocarcinoma
- Protective factors

AiraTafreeh.com
TUTORIALS
LOGIN FOR SUCCESS

AfraTafreeh.com

- H.pylori – CAG toxin

  ↓

  Decrease barret's esophagus

  Decrease adenoca

- NSAIDS
- Vitamin A,C,E

Clinical features 00:06:55

- Present to hospital only when > 2/3rd circumference involved.
- Dysphasia (most common for solid > liquid)

  ↓

  Rapidly progressive dysphasia



TUTORIALS LOGIN FOR SUCCESS

- TEF
- Hoarseness of voice due to involvement of Ⓛ RLN
- Horner's syndrome

TNM 00:08:50

- T1: – Tumor involving mucosa, submucosa
- T2: – Tumor involving muscularis propria

- T3: - Tumor involving adventitial tissue
- T4 a: - Tumor involving pleura, pericardium, diaphragm
- T4 b: - Tumor involving aorta, IVC, trachea, vertebra (nonresectable)
- N1: - 1-2 Nodes
- N1: - 3-6 nodes
- N1: - ≥ 7 nodes
- M1: - mets
- Most common distant mets – lungs

Investigation 00:11:23

	Oesophageal	Gastric
-IOC to diagnose -T -N -M -Tumor marker	Biopsy (6-8) EUS (CECT Chest) EUS (CECT Chest) PET CT X	Biopsy (6-8) EUS CECT abdomen or D. lap CA 72-4

AfraTafreeh.com
TUTORIALS
LOGIN FOR SUCCESS

Inoperable 00:13:36

- Mets ⊕
- Growth: - 15-20cm on endoscopy (Cervical oesophageal cancer)

AfraTafreeh.com

- T4 b

  ↓

  Aorta

  Vertebra

  TEF

- Poor performance status → 90% → palliative procedures: SEMS, covered SEMS (for TEF), Laser luminisation cryoablation
- In India – feeding jejunostomy.

Operable cases 00:16:38

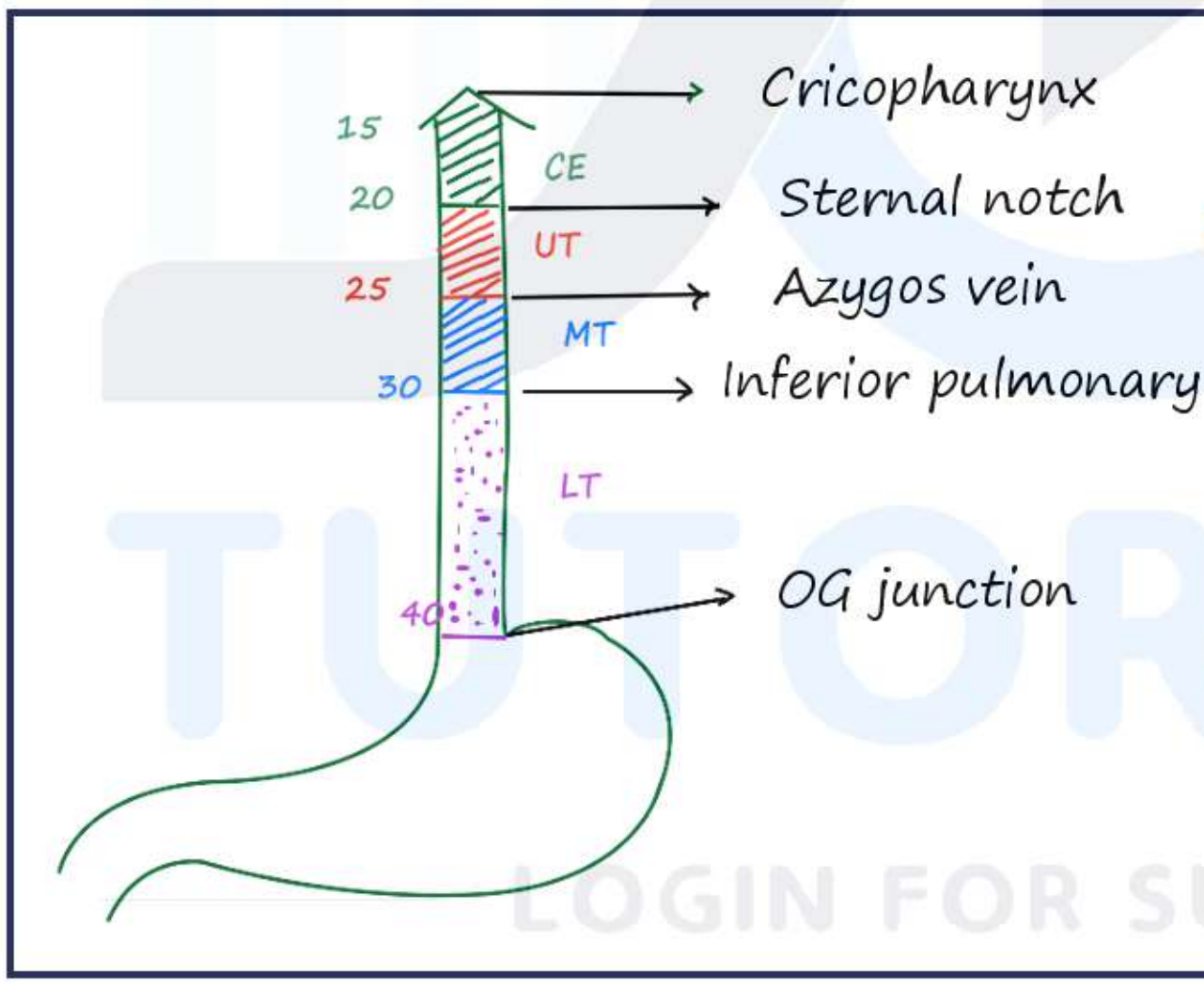

Fig: 3

- Cancer in cervical oesophagus are inoperable.
- Cancers in upper thoracic and middle thoracic are operable

  ↓

  Lower thoracic also

  ↓

  10cm clearance given → submucosal spread ⊕

- 10% only operable.

Transthoracic esophagectomy 00:20:17

IVOR – LEWIS (subtotal) | MC known

↓

Put an incision in abdomen

↓

Remove all nodes

↓

Incision on R thorax

↓

Remove mediastinal nodes

↓

10cm clearance – cut and remove oesophagus

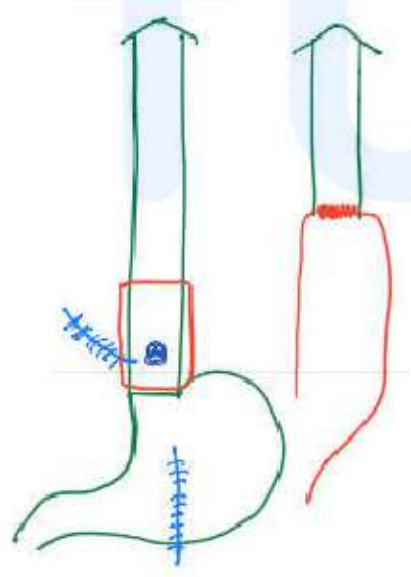

- Lower incision oesophageal cancer
- 2 stages LN
- 2 Incision
- Mediastinal
- If anastomosis leaks → high mortality mediastinitis
- Leak rate is less

AfraTafreeh.com
TUTORIALS
LOGIN FOR SUCCESS

AfraTafreeh.com

Mc keown (Total esophasectomy)

- Do for upper thoracic /middle thoracic

  Put an incision in abdomen

  ↓

  Remove all nodes

  ↓

  Incision on Ⓡ thorax

  ↓

  Remove mediastinal nodes

  ↓

  Ⓛ neck incision

  ↓

  Remove nodes

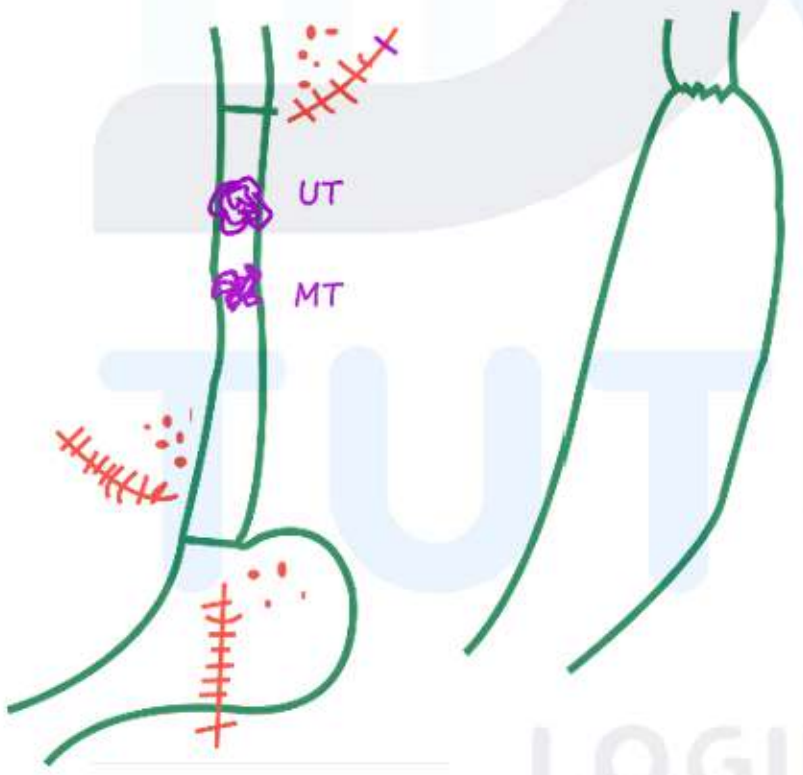

TUTORIALS
LOGIN FOR SUCCESS

- 3 stage LN nodes
- 3 incisions
- Anastomosis at neck level – esophasogastric anastomosis
- Leak is less dangerous
- Leak rate is most common
  - Usually – Orringer transhiatal esophagectomy

↓

Incision at abdomen

↓

Put hand to remove esophasus

↓

Incision at L thorax

↓

Put hand to remove

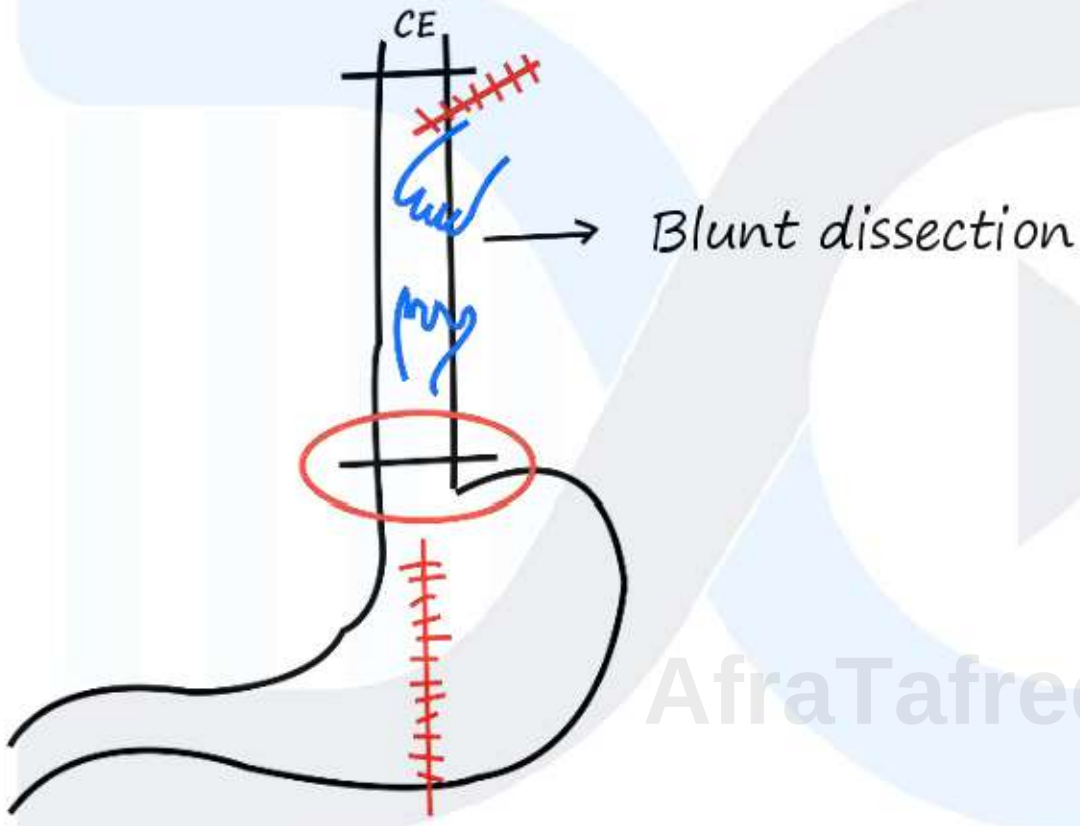

AfraTafreeh.com
TUTORIALS
LOGIN FOR SUCCESS

- Mediastinal nodes are not removed → postoperative radiotherapy

- All these esophasectomy are now done by VATS

  ↓

  Video assisted thoracoscopic surgery.

AfraTafreeh.com

Conduits 00:30:11



Most commonly used as it has extensive blood supply and nearby available -one anastomosis needed

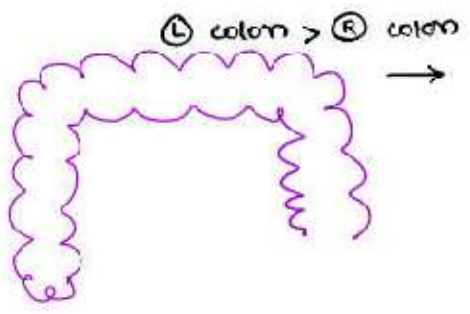

→ Corrosive ingestion and long replacement

→ Peptic stricture
→ Short segment

- Gastric conduit is based on Ⓡ gastroepiploic artery and Ⓡ gastric artery

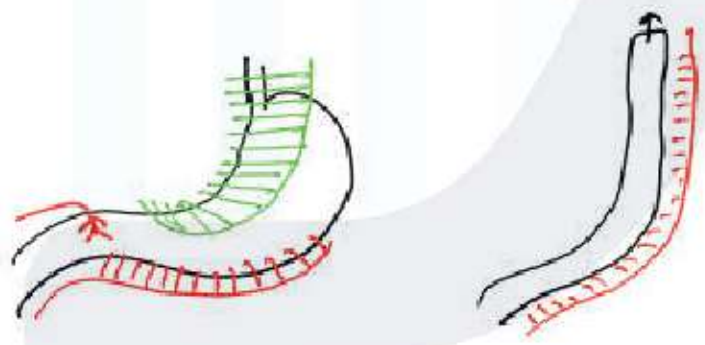

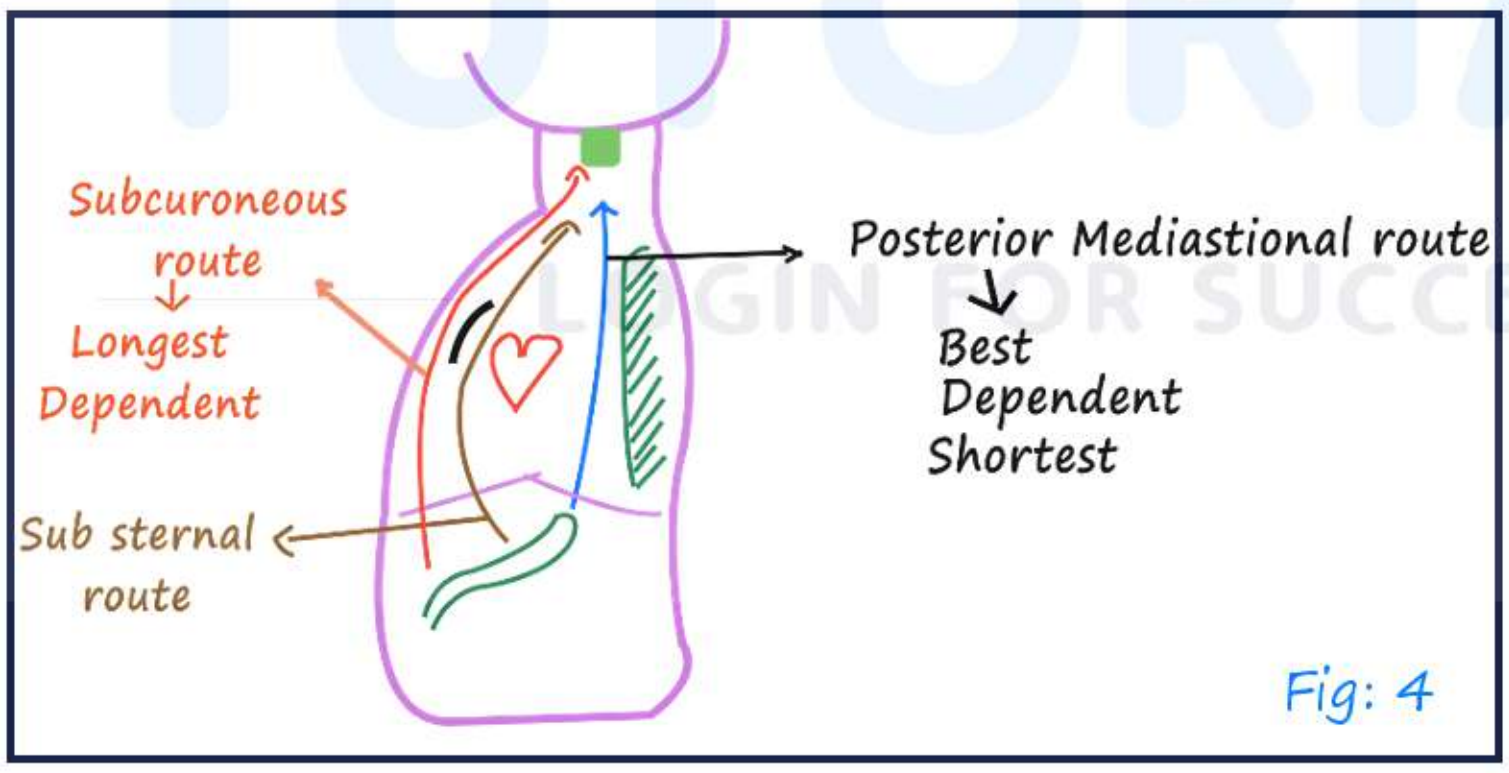

Fig: 4

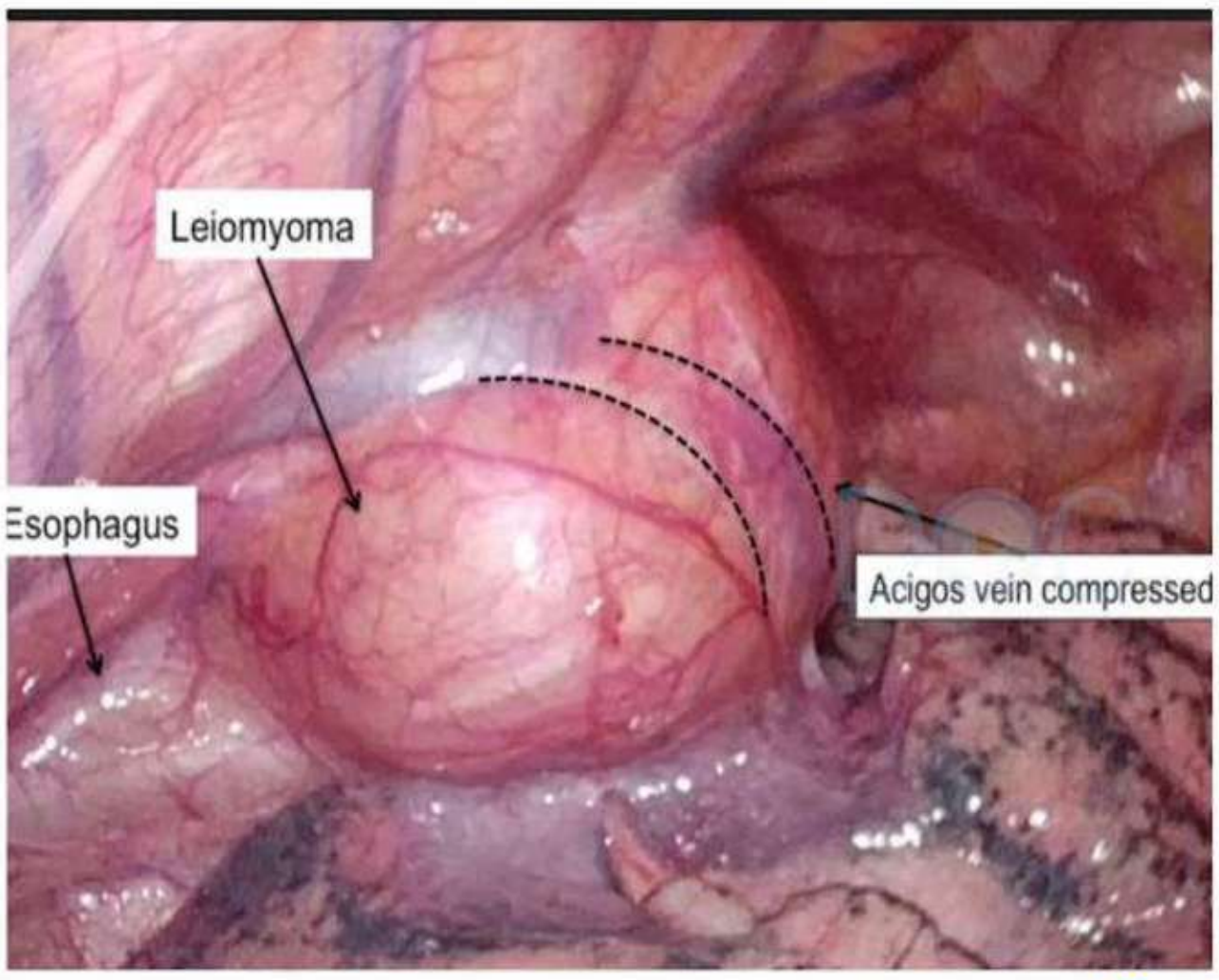

Fig: 5

Fig: 6

Site of tumors	Extent by Endoscopy from incisor teeth	Anatomical land mark
Cervical Esophagus	15-20 cm	Hypopharynx to Thoracic Inlet (sternal notch)

AfraTafreeh.com

Upper thoracic	20-25 cm	Thoracic inlet to Azygous vein
Middle thoracic	25-30 cm	Azygous vein to inferior Pulmonary vein
Lower thoracic	More than 30 cm	Inferior pulmonary vein to GE junction

	Adeno Carcinoma	Squamous Cell Carcinoma
Alcohol	-	Increased risk
White race	Increased risk	Decreased risk
H/O previous cholecystectomy	Increased risk	-
Fruits and Vegetables	Decreased risk	Decreased risk
GERD, Barret	Increased risk	-
H. Pylori infection	Decreased risk	?? (no clear evidence)
NSAIDS like aspirin	Decreased risk	Decreased risk
Tobacco	Increased risk	Increased risk
Obesity	Increased risk	Decreased risk

T staging	N staging	M staging
• T1a – Muscularis mucosa • T1b – Submucosa • T2 – Upto muscularis propria • T3 – Invades adventita • T4a – resectable adjacent structures like pericardium and diaphragm	N1 – 1-2 nodes N2 – 3-6 nodes N3 - > 7 nodes	M1 – Distant mets
• T4b – Unresectable structures like trachea, bronchus, aorta, vertebra		

AfraTafreeh.com
TUTORIALS
LOGIN FOR SUCCESS

AfraTafreeh.com

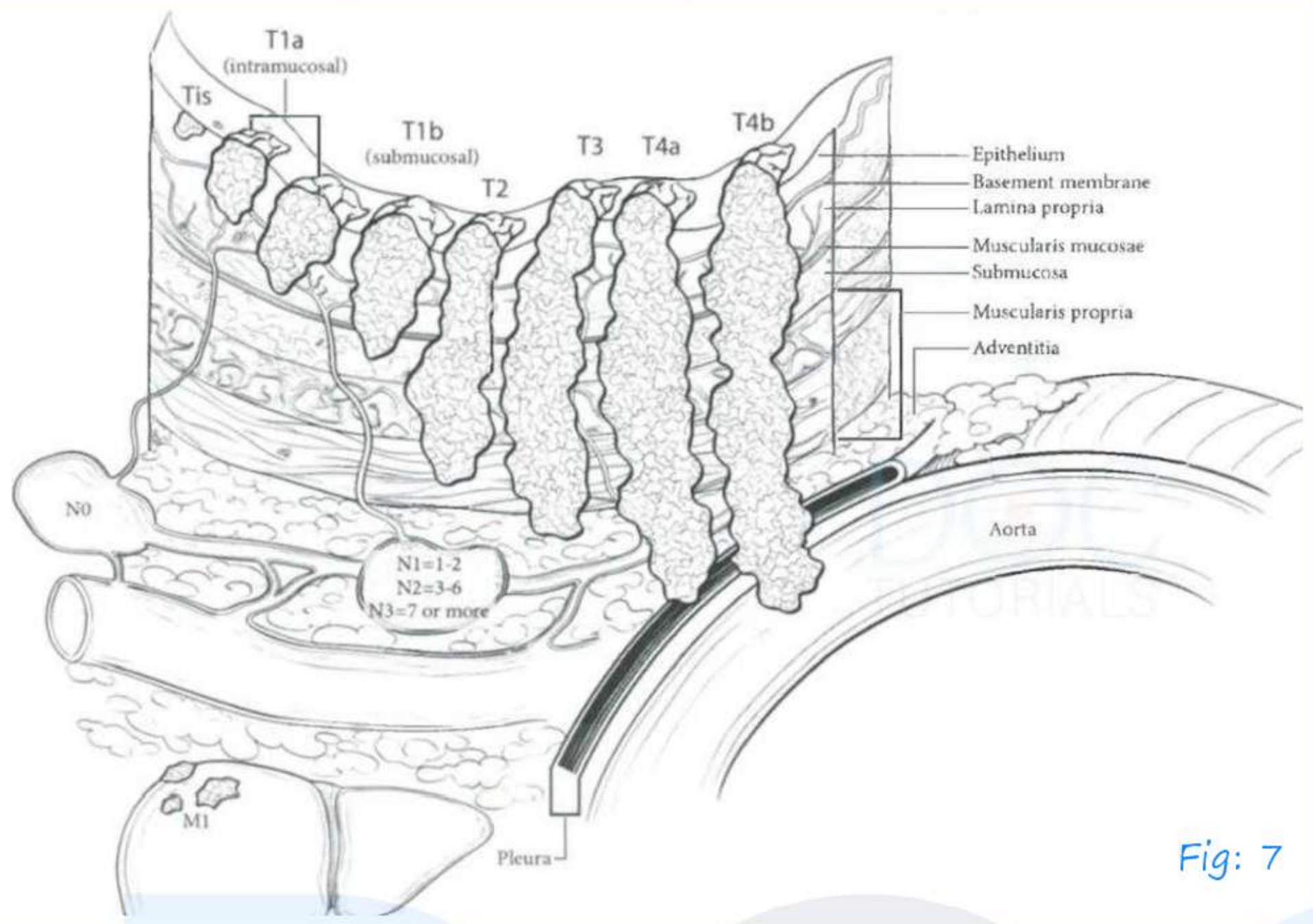

Fig: 7

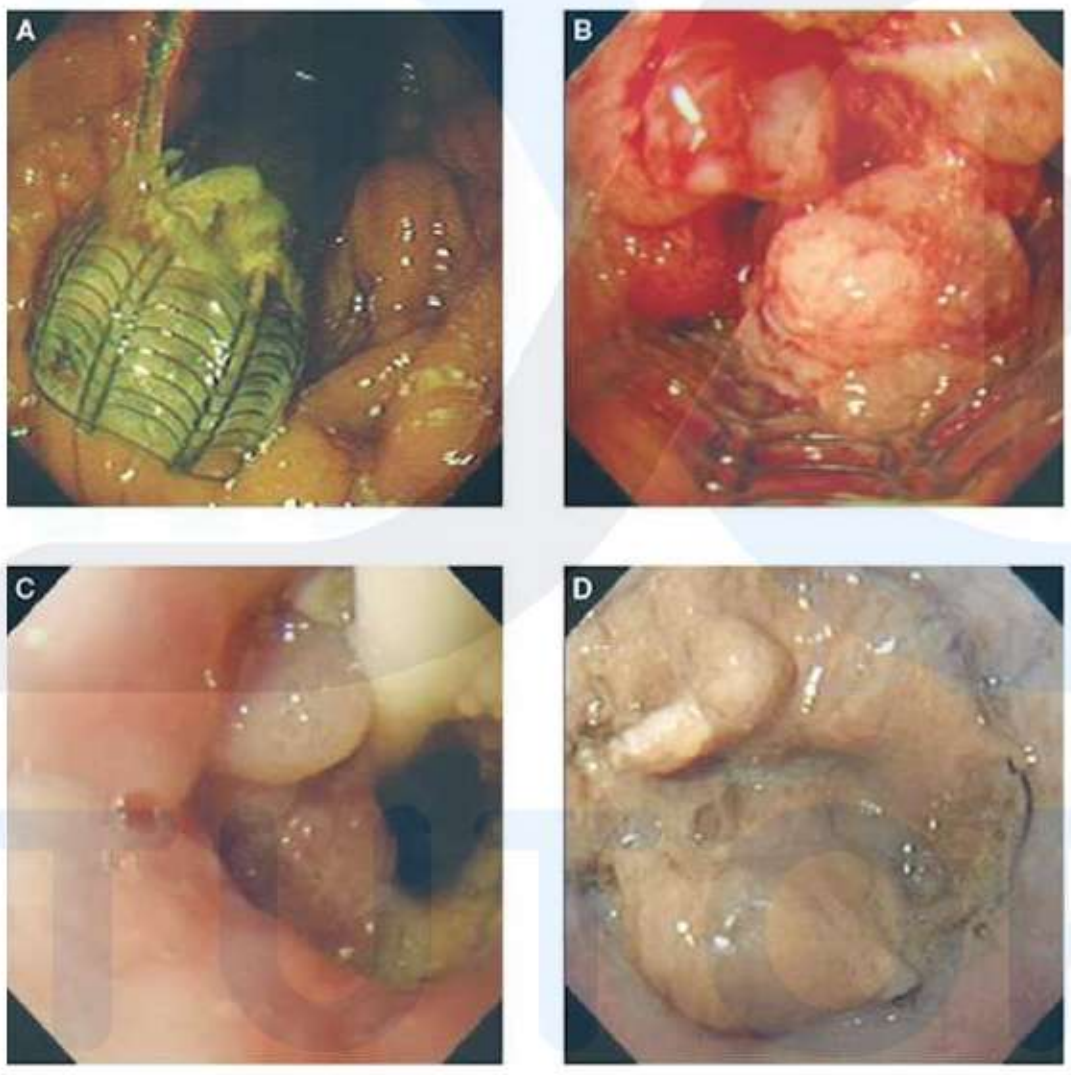

Fig: 8

Fig: 9

Rat tail appearance in Ca esophagus

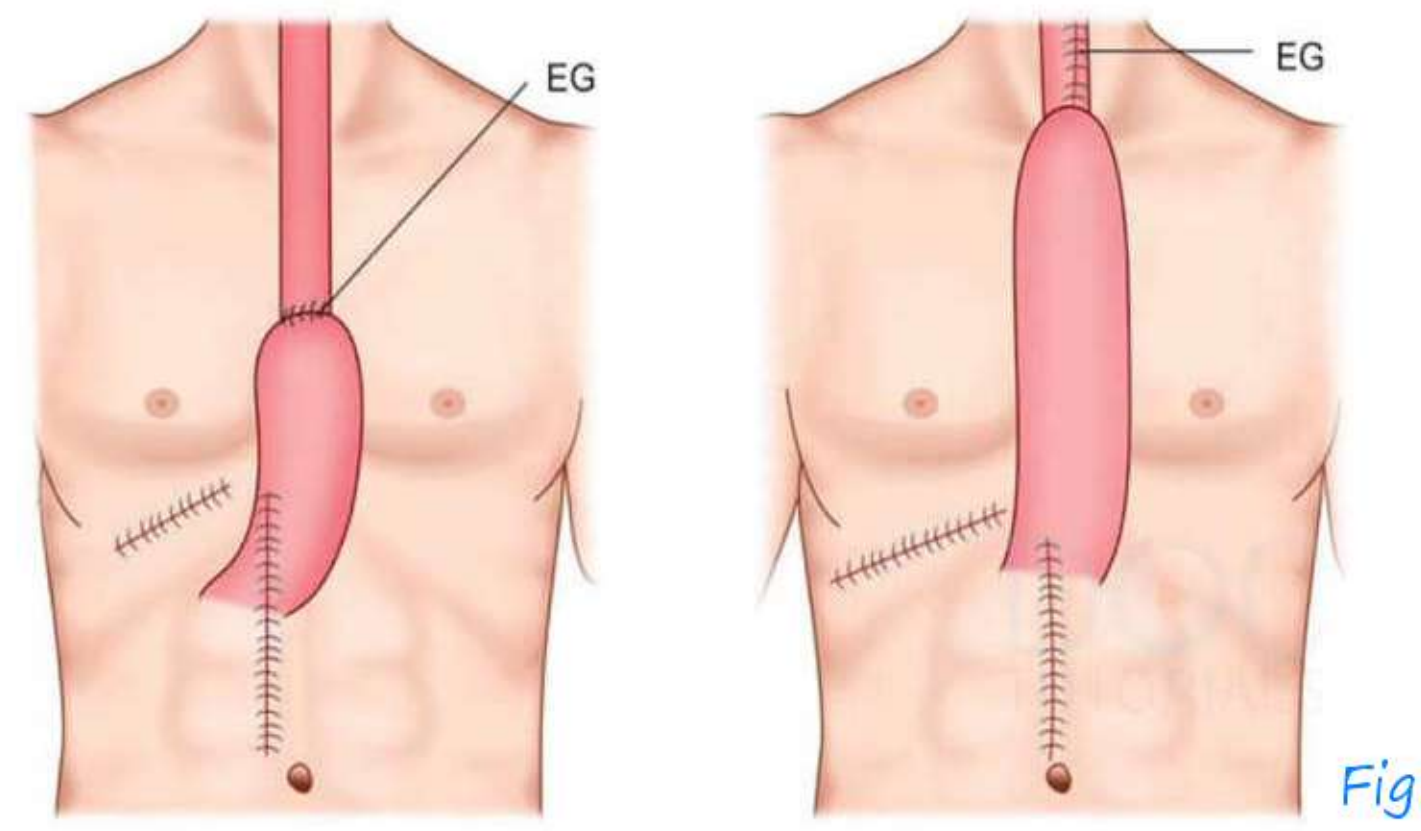

Fig: 10

Ivor lewis
- 2 incisions
- Thoracic anastomosis

Mckeown
- 3 incisions
- Neck anastomosis

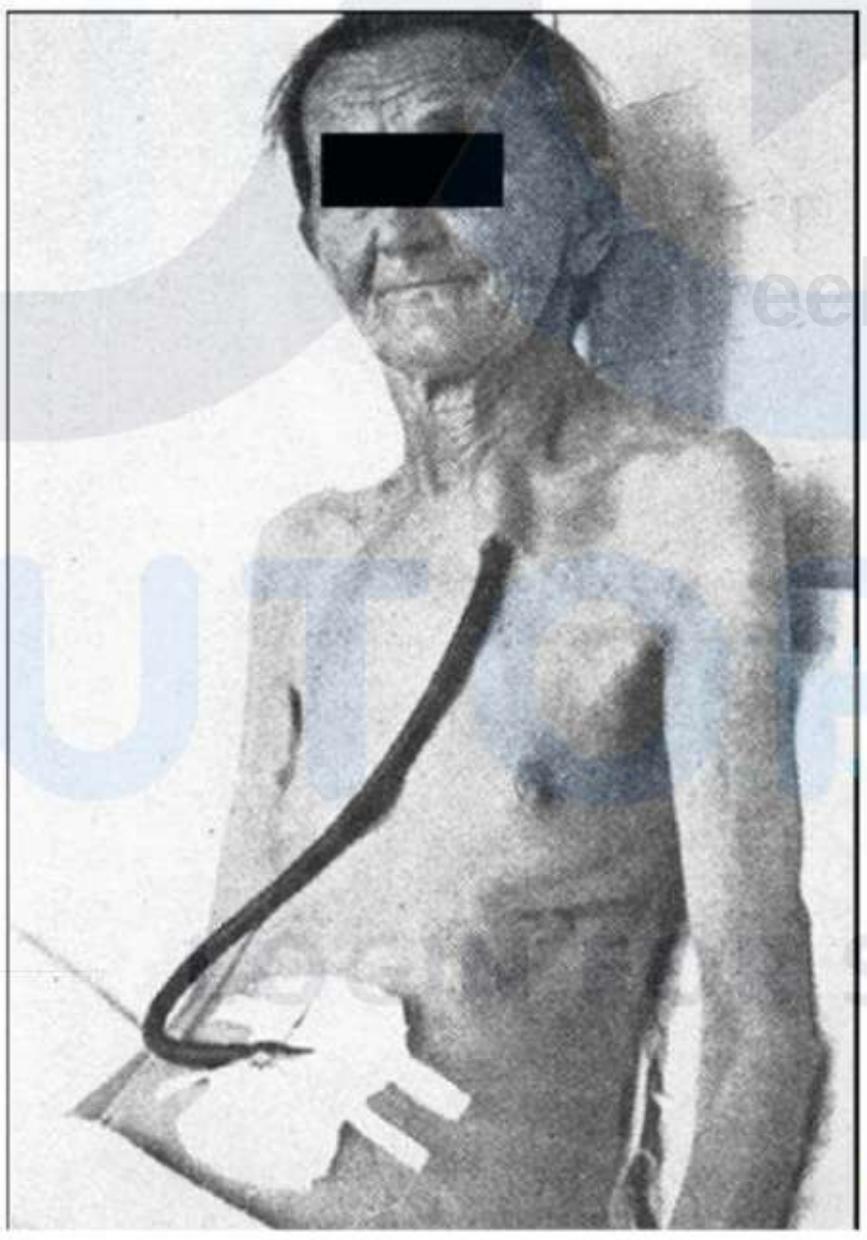

Fig: 11

TUTORIALS

AfraTafreeh.com

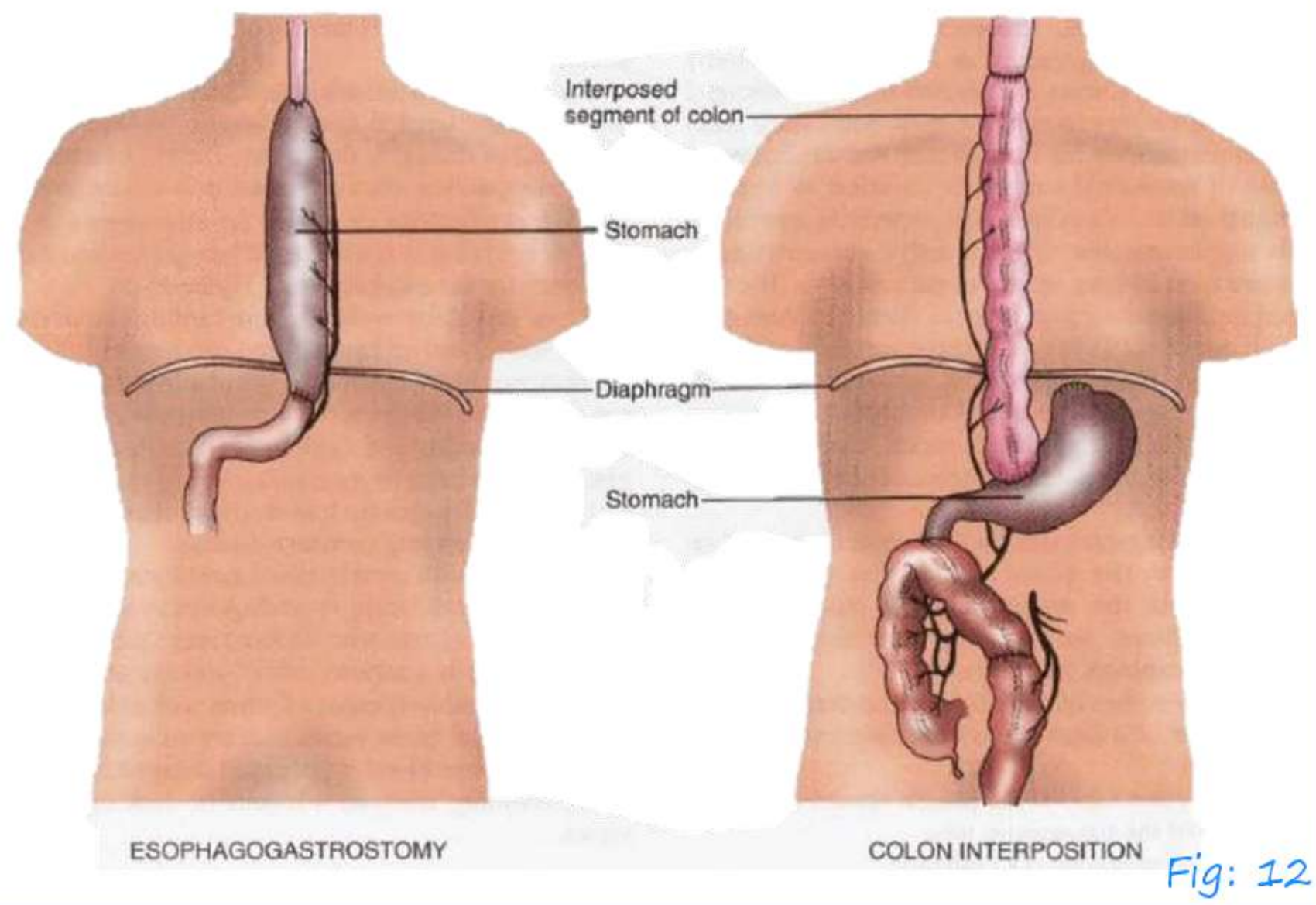

Fig: 12

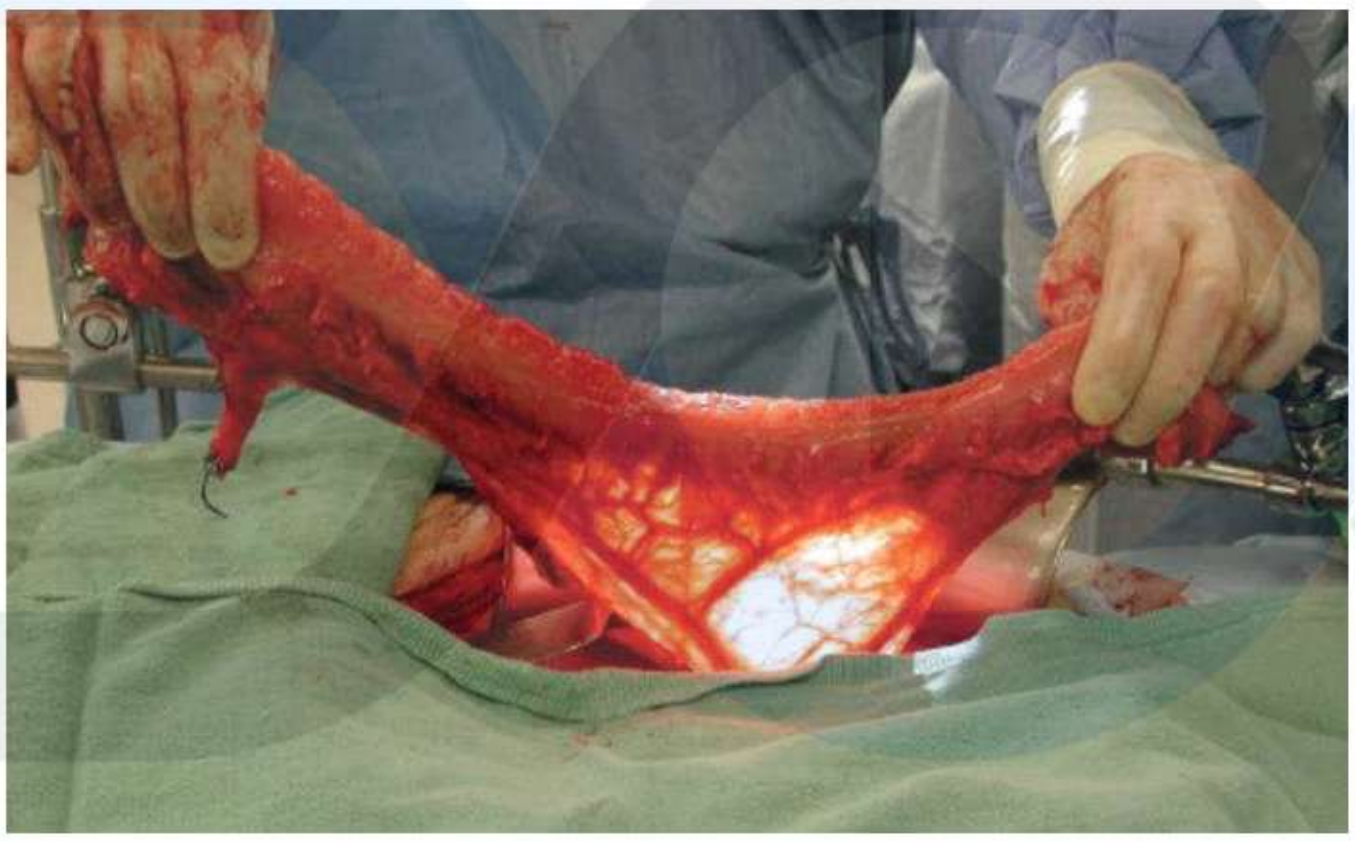

Fig: 13

Fig: 14

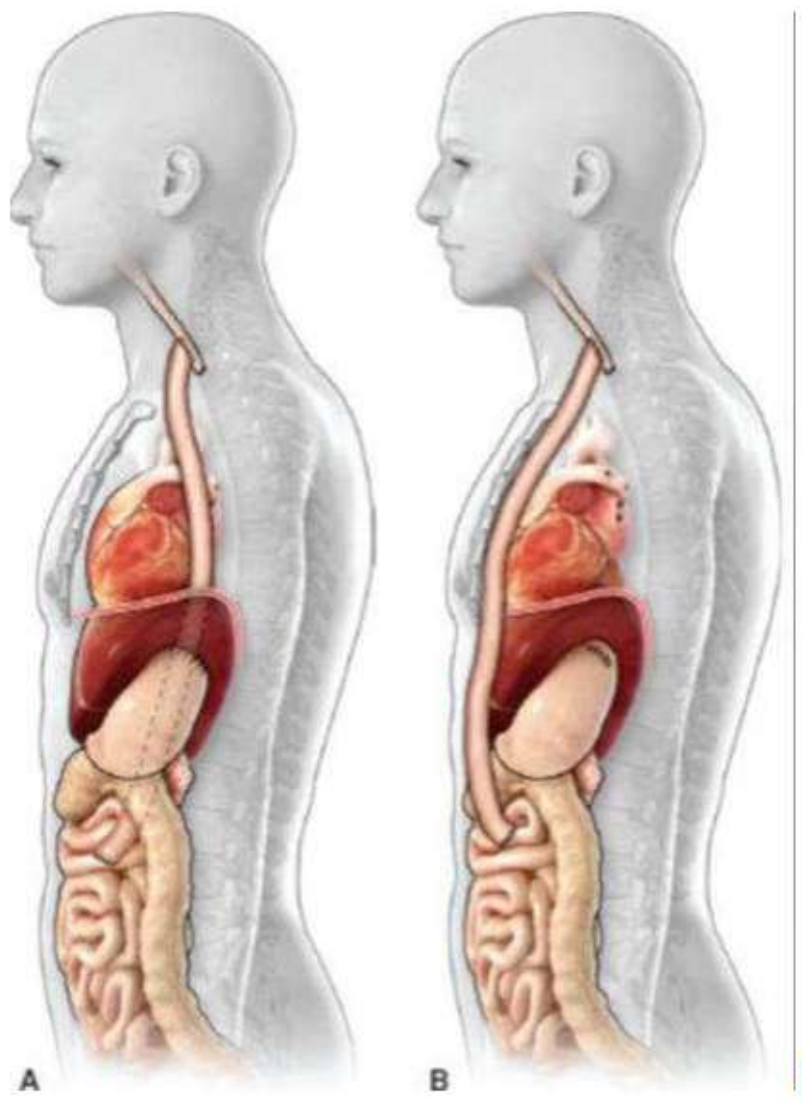

Fig: 15

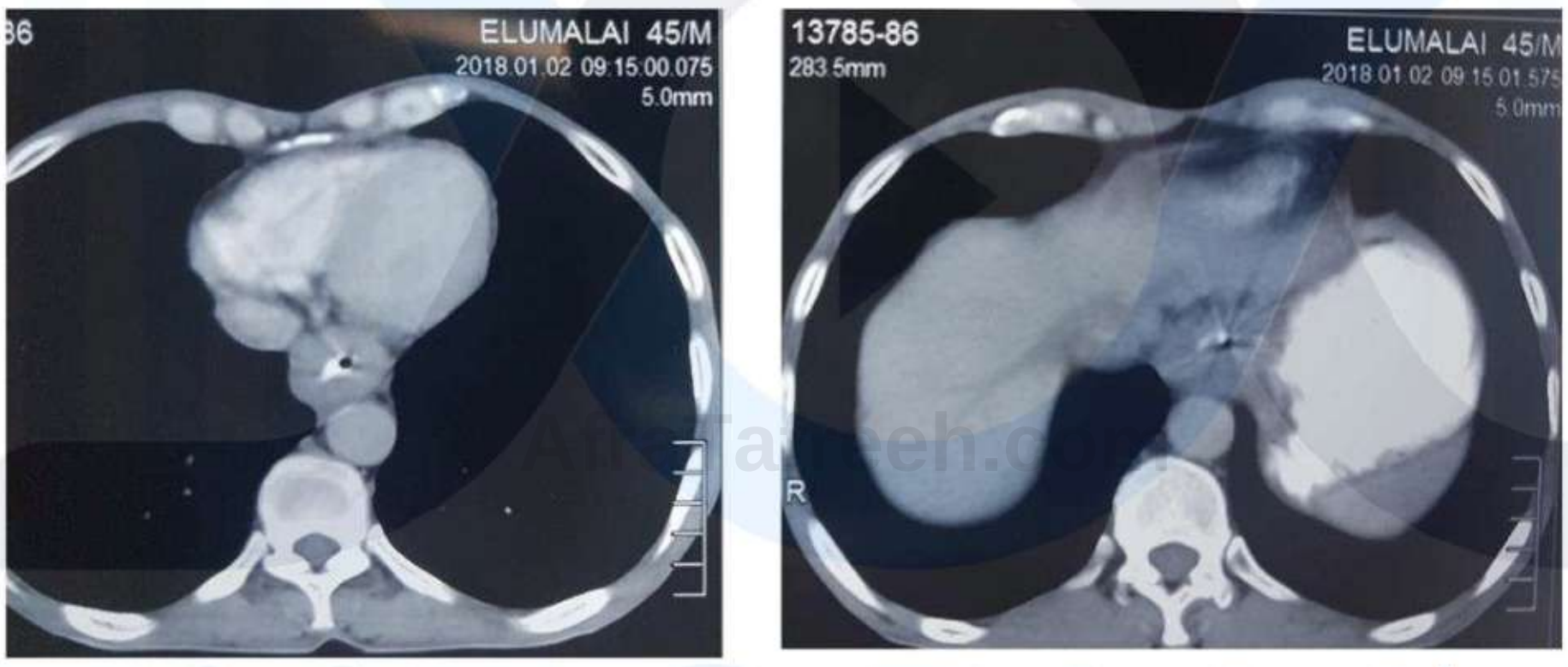

Fig: 16

TUTORIALS
LOGIN FOR SUCCESS

AfraTafreeh.com

VAGUS NERVE ANATOMY.

Introduction 00:00:20

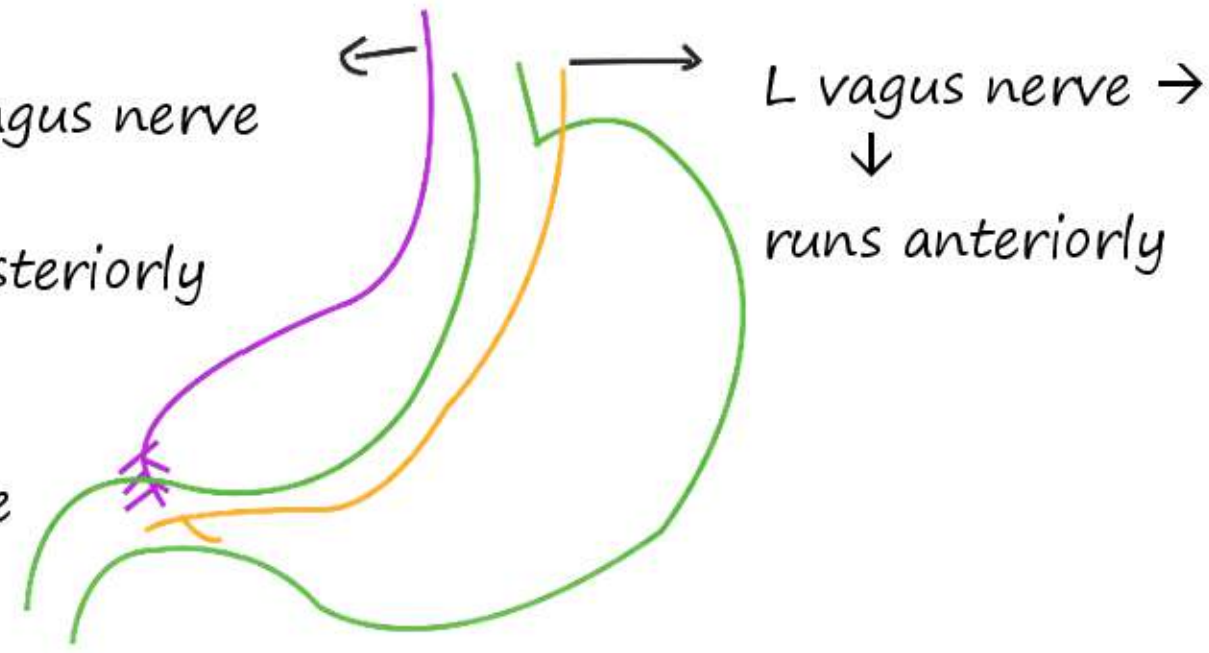

Fig: 1

Left vagus nerve

- Gives gastric branches to parietal cells.
- Ends on pylorus as N. of laterjet (crow's foot).
- Hepatic branches.

Right vagus nerve

- Gastric branches
- N. of laterjet
- Coeliac branch
- Criminal nerve of grassi [may be missed on vagotomy- reccurence]

- Major function of vagus is – gastric production
- Hepatic nerve – bile flow regulated
- Coeliac branch – Intestinal peristalsis
- Crow's foot – pylorus opening (relaxation)
  - To reduce acid secretion – Truncal Vagotomy

Truncal vagotomy 00:05:42

- Destroy gastric branch – decreases acid
- N. of laterjet – pylorospasm
- Coeliac branches– post vagotomy diarrhea
- Hepatic branches – Bile stasis & gall stones

↓

To prevent all these complications.

↓

Highly selective vagotomy (parietal cell vagotomy)

↓

Gastric branches cut

S/E: - 10% recurrence

In high selective vagotomy – all branches entering the stomach are cut **leaving last 7cm from pylorus**

- All truncal vagotomy need drainage procedures

↓

Commonly done – gastrojejunostomy

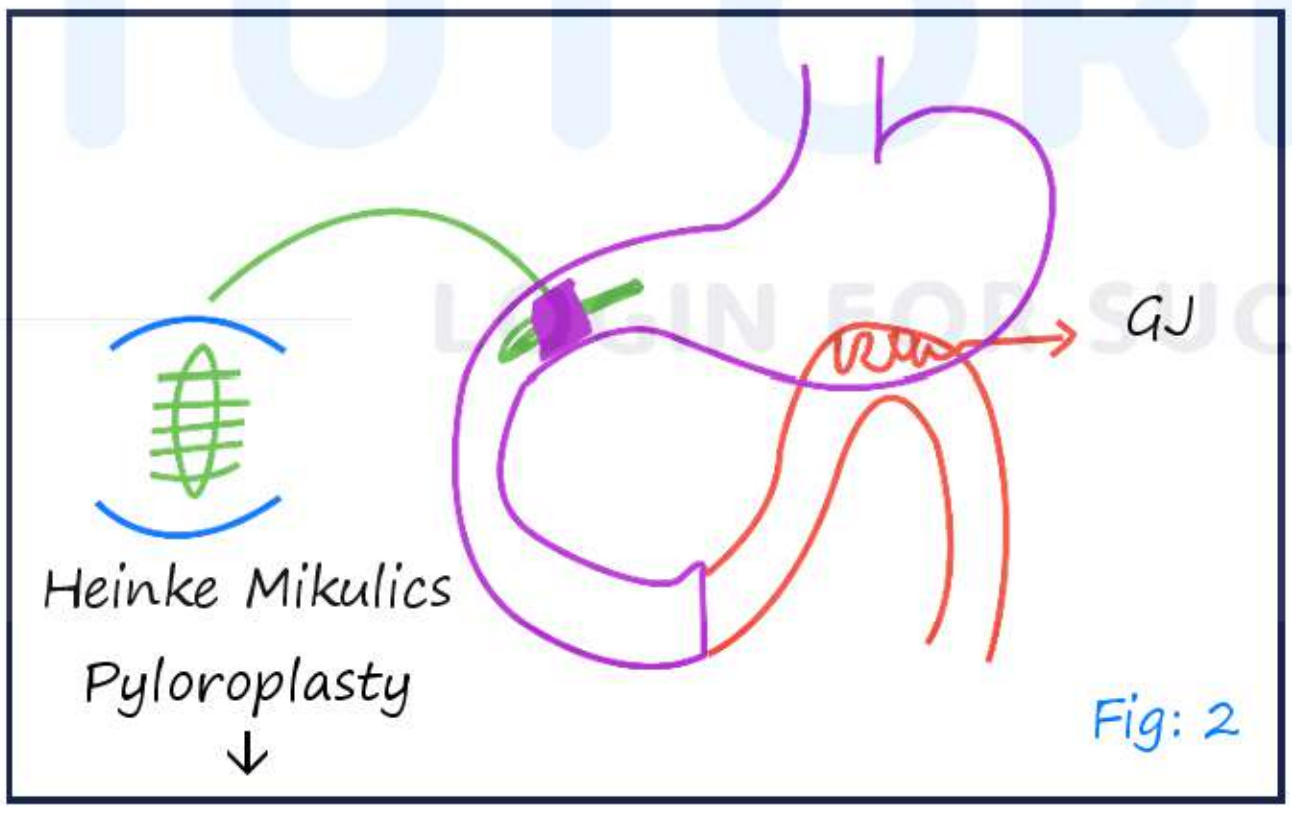

Fig: 2

↓

open it horizontally and close it vertically

- In high selective vagotomy, drainage procedures are not needed

AfraTafreeh.com

AfraTafreeh.com

Complications of Truncal Vagotomy with GJ

00:11:30

I. Complications of vagotomy (TRUNK)

1. Post vagotomy diarrhea.
2. Gall stones.
3. Pylorospasm.
4. Gastric atony.

II. Complications of GJ

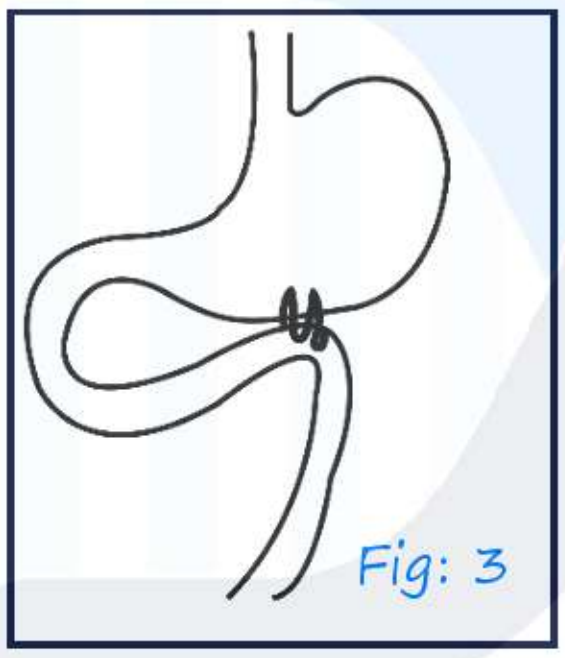
Fig: 3

- Afferent/Efferent loop syndrome
- Dumping syndrome
- Malabsorption syndromes

- Malabsorption syndromes

1. Iron deficiency (most common)
2. Hypocalcemia
3. Osteoporosis
4. B_{12} deficiency

TUTORIALS
LOGIN FOR SUCCESS

- Afferent/Efferent loop syndrome

↓

Obstruction of loops

- Dumping syndrome

Eating of heavy foods

- Afferent limb goes towards stomach, anastomose and come out as efferent limb

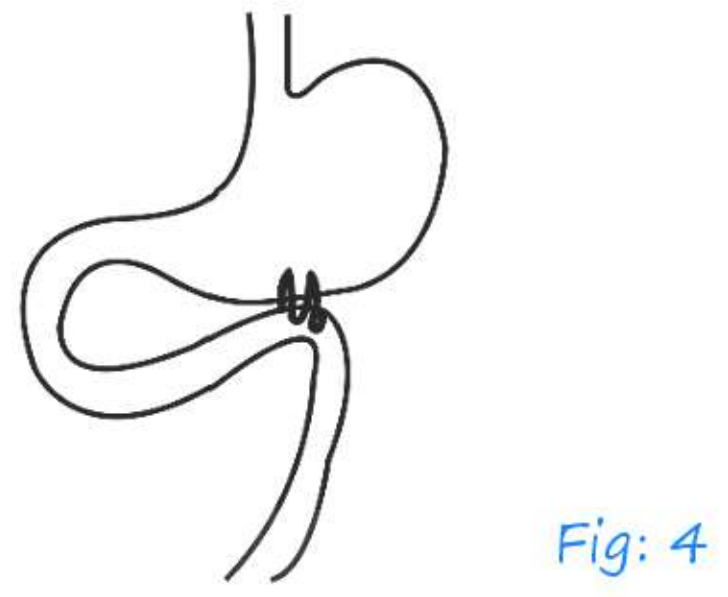

Fig: 4

Afferent loop syndrome

- Obstruction occurred due to kinking, twisting and adhesions
- Most common than efferent loop syndrome
- Most common cause-long afferent limb left after surgery
- Clinical features – **Bilious vomiting with no food**
- IOC to confirm – Radionucleotide contrasts gets stagnated in afferent limb ↑ HIDA
- Wait and watch – recover mostly
- In Recurrent afferent limb synd cases – Revisional surgery needed

AfraTafreeh.com
TUTORIALS LOGIN FOR SUCCESS

Efferent loop syndrome

- Clinical features – **Bile + food vomiting** (similar to Intestinal obstruction)
  ↓
  Treatment – Emergency laparotomy

Dumping Syndrome 00:21:21

Early dumping (within ½ hr. of intake)

- Post cibal syndrome
- Massive fluid shift
  ↓
  Hypovolemia
- Clinical features: Giddiness after eating
- Diagnosis – PCV (Hemoconcentration)
- Management – Just lie down

Late Dumping

- > 2 hours
  ↓
  Food eaten releases sugar
  ↓
  Enormous insulin
  ↓
  Neutralizes sugar back
  ↓
  Reactive hypoglycemia
  ↓
- Clinical features – Sweating
  Palpitation
  Tremors
- Diagnosis: – PPBS (decreased Blood Sugar)
- Take some chocolate/sugars

Advice

i. Small frequent meals

ii. High fat diet

iii. Low carbohydrate diet

iv. Dry meals

TUTORIALS LOGIC FOR SUCCESS

- Doc – Inj. Octreotide
  ↓
  Revisional surgery
  ↓
  Insert Reverse Roux limb

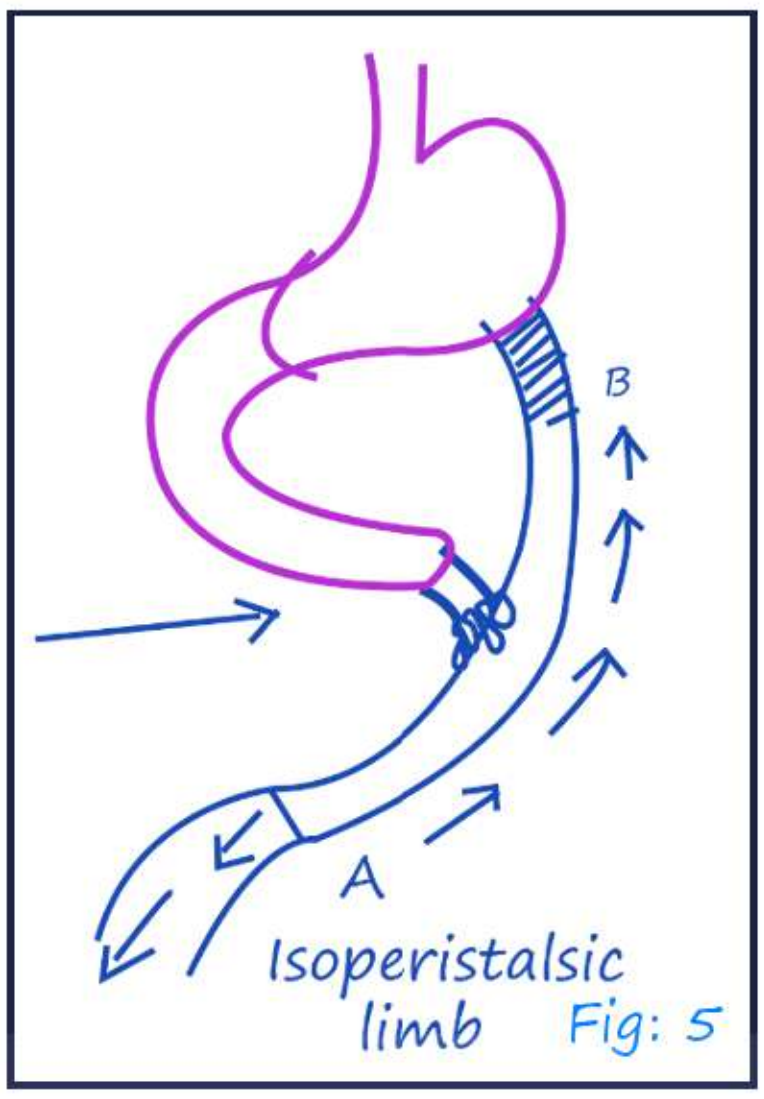

AfraTafreeh.com
TUTORIALS
LOGIN FOR SUCCESS

AfraTafreeh.com

H PYLORI

Introduction 00:00:16

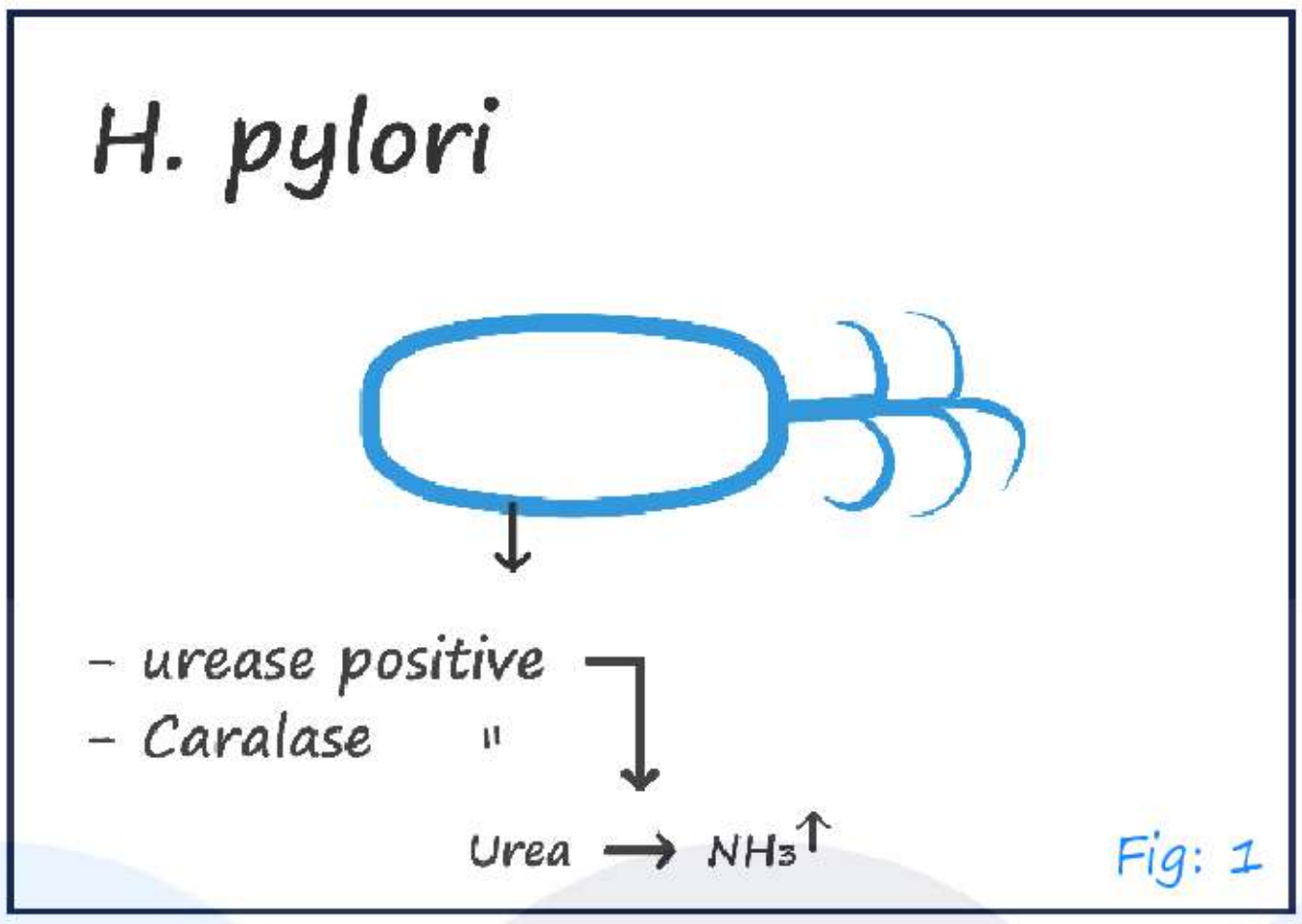

Fig: 1

- Gram negative
- Cocco bacilli
- Lophotrichous flagella
- Motile organism → live only in gastric type epithelium

  i. Stomach

  ii. Duodenum (metaplasia)

  iii. Meckel's diverticulum

  - Not seen in barret's esophagus

TUTORIALS
LOGIN FOR SUCCESS

- 2 toxins

2 toxins

Cag A Toxin ↓ Carcinogenic

Vac A toxin ↓ Gastritis (inflammatory)

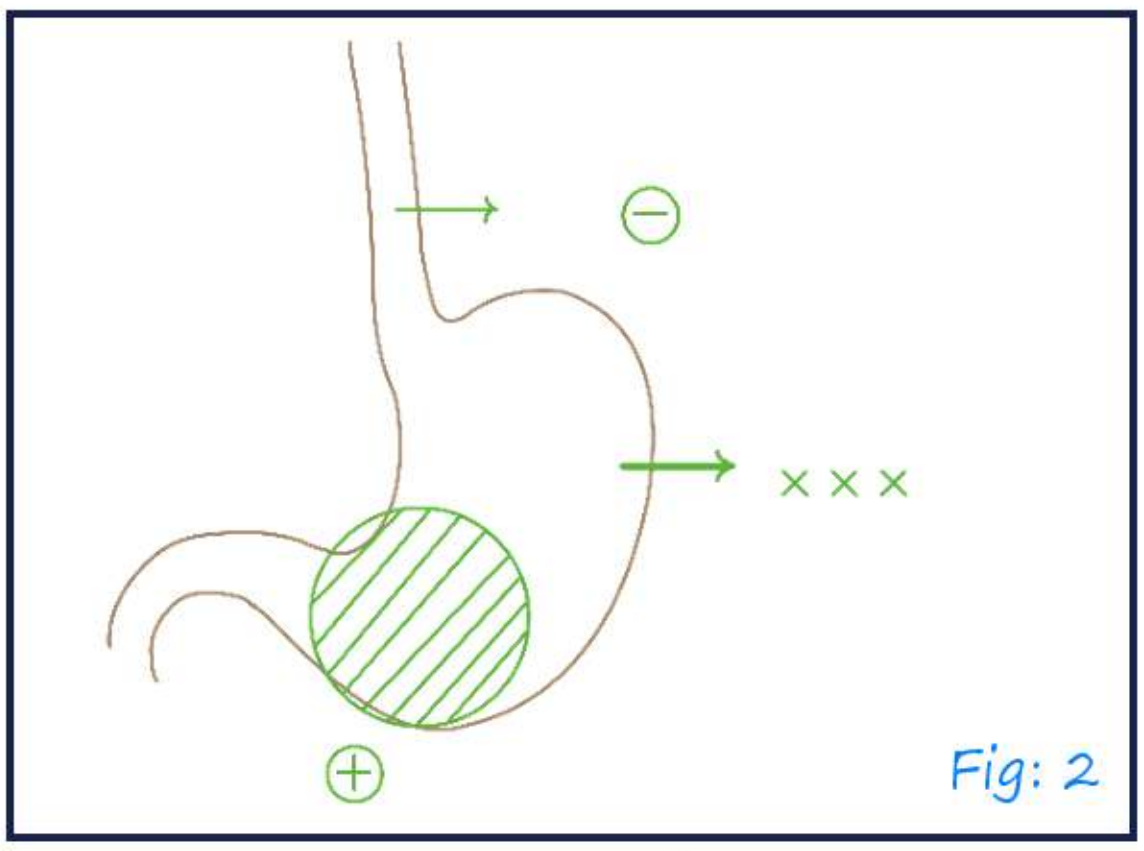

Cag A toxin

- Inhibits adeno ca of oesophagus
- No relation to OG junction and proximal cancer
- Stimulation antral cancer

Strains used 00:04:50

1.Giemsa stain

2.Warthin starry

3.Silver stain

- Culture medium: Gold standard (100%) → Skirrow's medium

AfraTafreeh.com

LOGIN FOR SUCCESS

Diseases caused by H pylori 00:06:05

1.Duodenal ulcer (90%)

2.Gastric ulcer (70%)

3.MALToma (100%)

4.Distal gastric cancer

5.Type B gastritis

AfraTafreeh.com

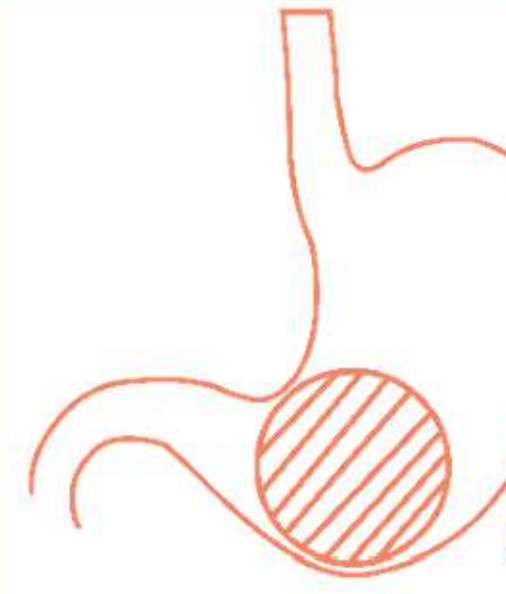
Fig: 3

- Attacks antrum
- Not premalignant

- Type A gastritis seen in pernicious anemia
  - No antrum involved
  - Premalignant
  - Involves proximal stomach

6. Menetrier's disease
7. Non ulcer dyspepsia

- H pylori not associated with
  - Proximal gastric cancer
  - Type A – autoimmune
  - Lauren's – Diffuse gastric cancer
- H pylori is protective against
  - Barrett's oesophagus } by CAG A toxin
  - Adenocarcinoma oesophagus } by CAG A toxin

↑

- H pylori produces atrophic gastritis in such a way that no more acid is produced in the stomach

Investigation 00:11:18

- Non-invasive → ELISA for H pylori Ag
- Invasive (endoscopy) → IOC: Rapid urease test

Rapid urease test

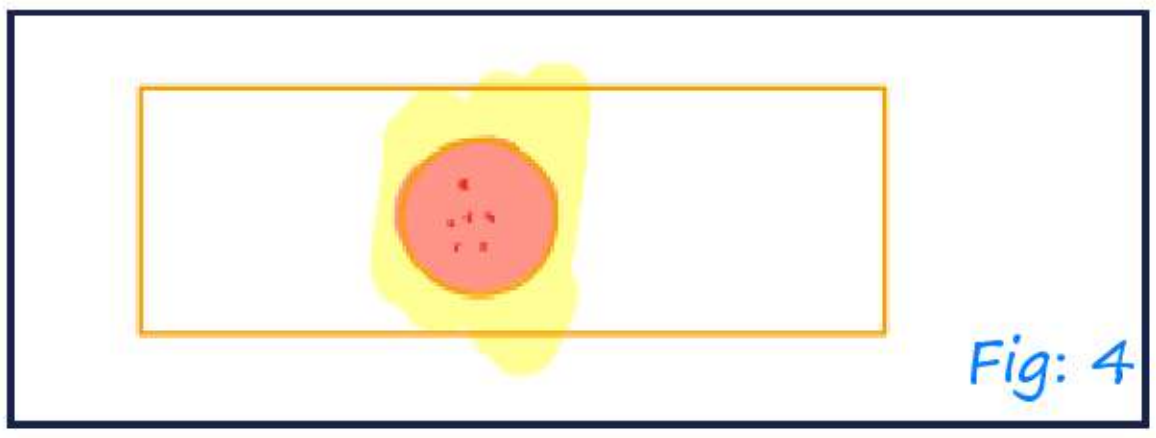
Fig: 4

- Small amount of tissue is placed in kit and distilled water is poured → centre turns pink → positive

Treatment 00:13:33

H pylori positive

↓

Triple drug x 2 weeks

Indian	**US FDA**
↓	↓
OAM	LAC
• Omeprazole	• Lansoprazole
• Amoxycillin	• Amoxycillin
• Metrogyl	• Clarithromycin

Look for eradication

↓

C_{13} – C_{14} urea breath test

Newer – stool for H Pylori Ag

↓

Positive

↓

Resistant H pylori

↓

LAC + Bismuth subcitrate

(2weeks) (detach the attachment)

AfraTafreeh.com
DOC TUTORIALS LOGIN FOR SUCCESS

AfraTafreeh.com

PEPTIC ULCER BASICS

Introduction and Types 00:00:18

- Break in epithelium

Duodenal Type

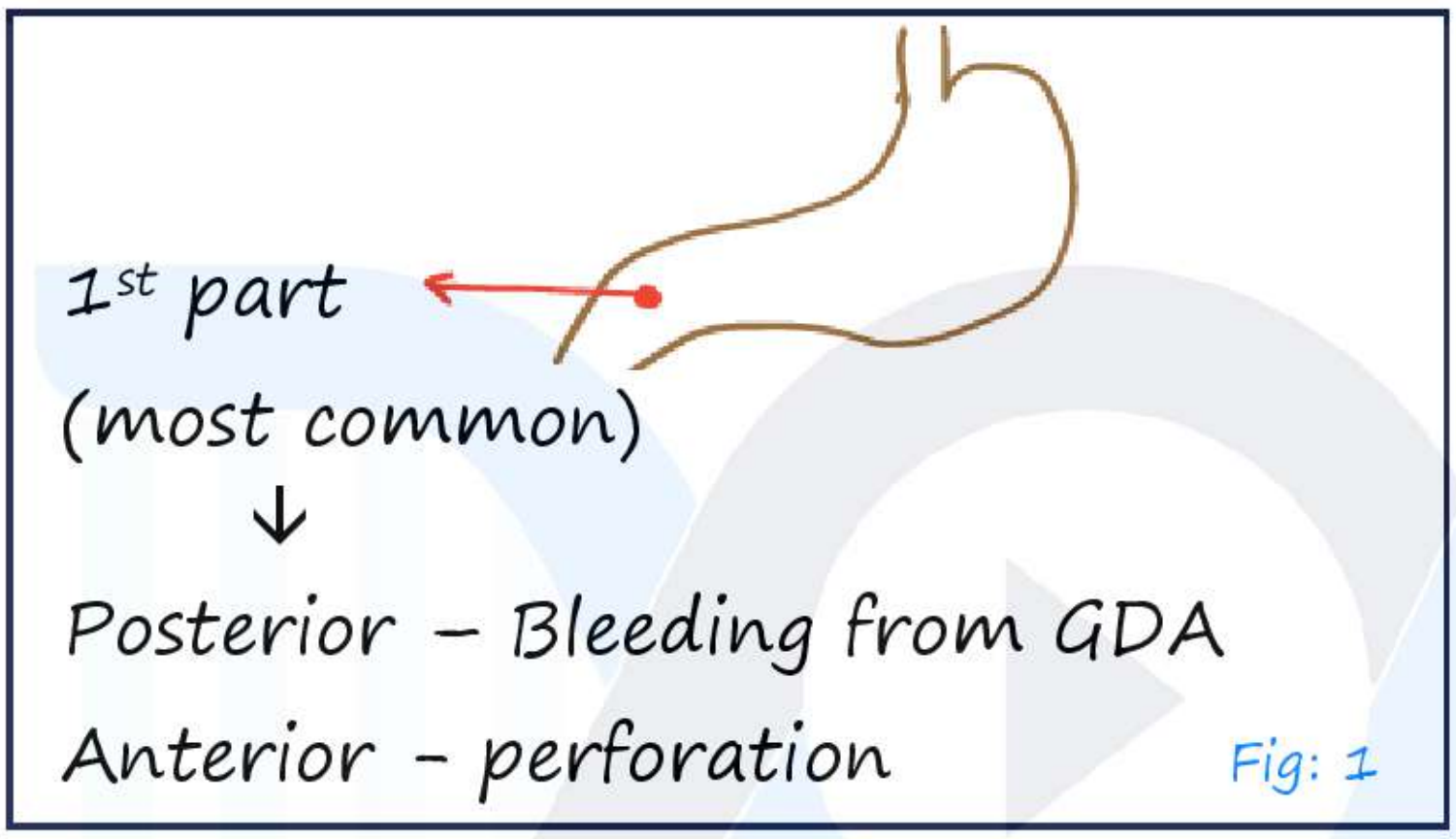

Fig: 1

Gastric Type

Modified Johnson Classification

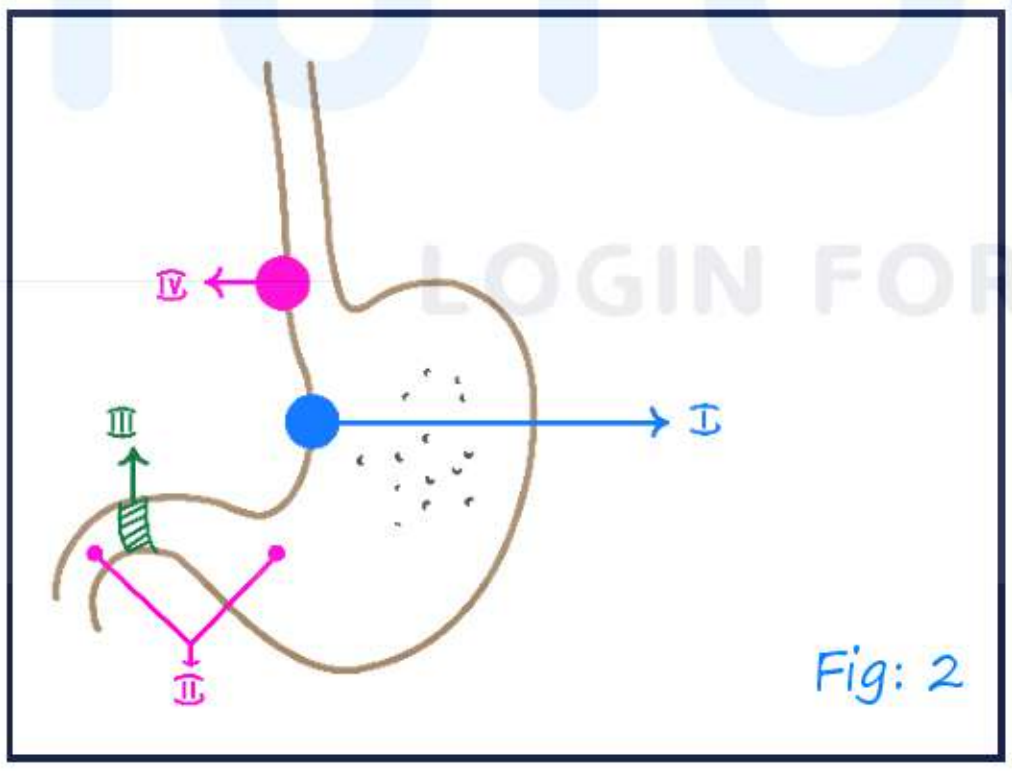

Fig: 2

- I – Incisura at lesser curvature (most common)
- II – Dual ulcers
- III – prepyloric ulcers
- IV – lesser curvature at (proximal cardia)
- V – NSAID induced. (anywhere)

Duodenal ulcers	Named gastric ulcers
• D_2, D_3, D_4 → ZES	• Cushing – Head injury ↓ Most common in proximal stomach-perforation • Curling – Burns (stress) - most common site: stomach > duodenum • Cameron ulcer: vertical ulcers M/C sliding hiatus hernia 
Etiopathogenesis	
Duodenal • Increases acid ↓ Damage duodenum	Gastric • Loss of mucosal barrier • **Decreases/ N acid production.**

AfraTafreeh.com
TUTORIALS
LOGIN FOR SUCCESS

AfraTafreeh.com

Clinical Features 00:07:50

Duodenal ulcer	Gastric ulcer
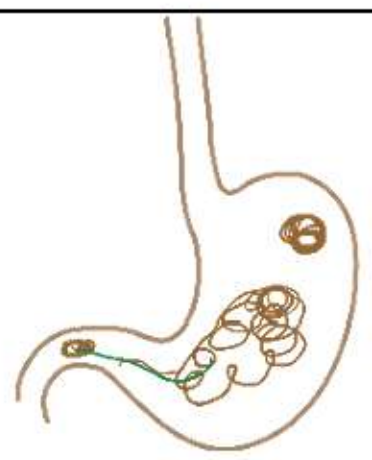 • Eating decrease pain ↓ Food intake → obese • Most common – young • Periodicity of pain seen in duodenal ulcer-in winters	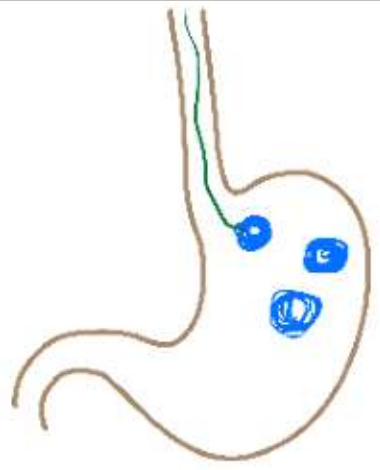 • Food → increases pain (food fear) • Most common – old age • slim/malnourished • Pain relief on vomiting

Investigations and Management 00:10:56

- IOC: – Upper G.I endoscopy

Duodenal ulcer	Gastric ulcer
• Management: – – Medial treatment DOC – PPI > H_2 blocker > Antacids LAC (x 2 weeks.) 6-8 weeks -PPI ↓	• DOC: – Sucralfate + Treat the etiology ↓ 6 weeks ↓ Intractable gastric ulcer

Intractable duodenal ulcer	
Indications for Surgery	
Truncal vagotomy – India High selective vagotomy – TOC	Resect the ulcer

Essential Points about Gastric Ulcer 00:13:50

- N/decreases acid

  ↓

  Type I

  Type IV

  Type V

  (loss of mucosal barrier)

- Type II ┐ Behave like duodenal ulcer
- Type III ┘

  ↓

  Increases Acid

  ↓

  Benefit from PPI

AfraTafreeh.com
TUTORIALS
LOGIN FOR SUCCESS

AfraTafreeh.com

Gastric Ulcer Surgeries 00:15:53

I.

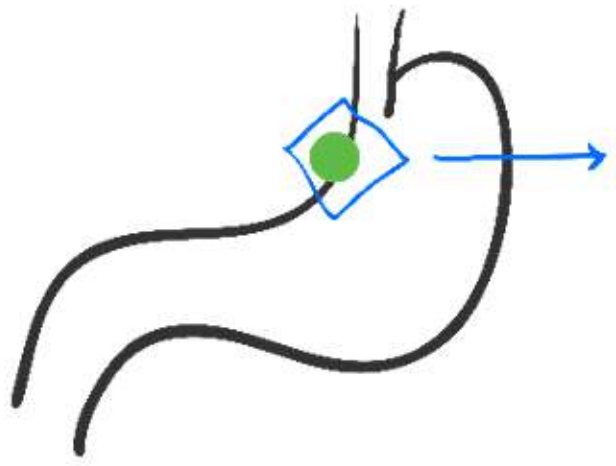

Wedge resection of ulcer

II.



Truncal vagotomy + distal gastrectomy

III.

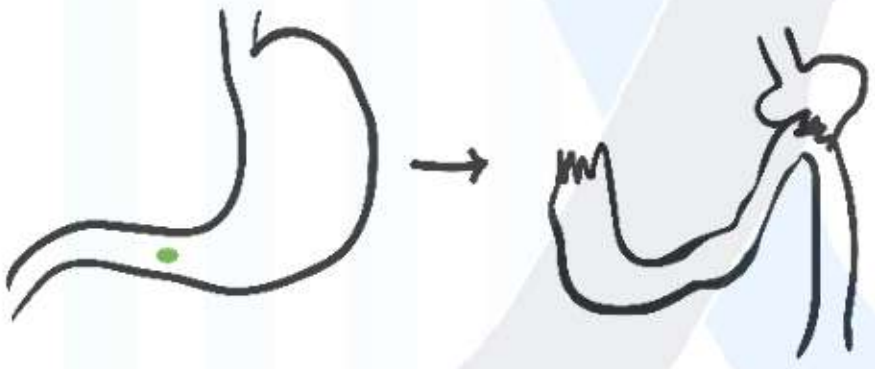

GJ done Billroth II

IV.

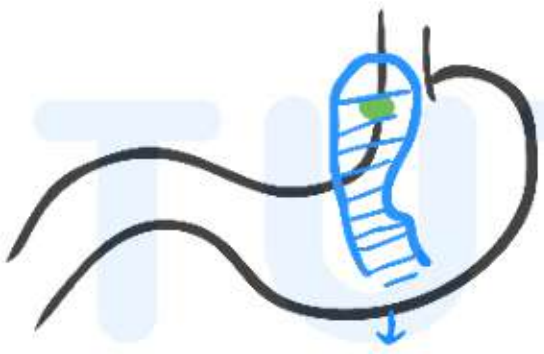

Pouchet procedure

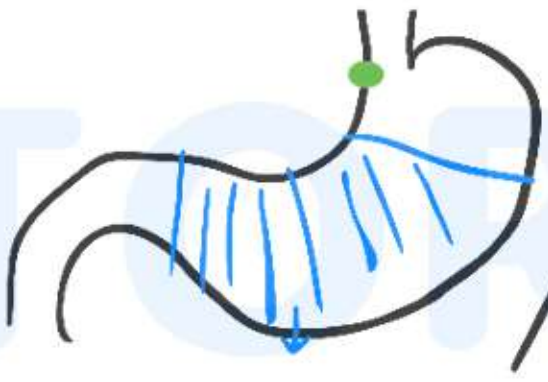

Kelling Madlener procedure

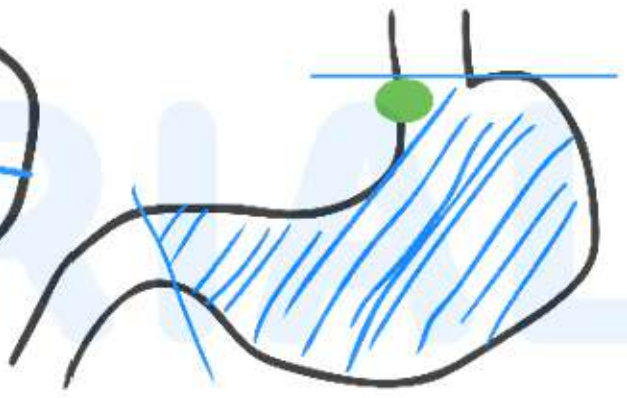

Csendes procedure

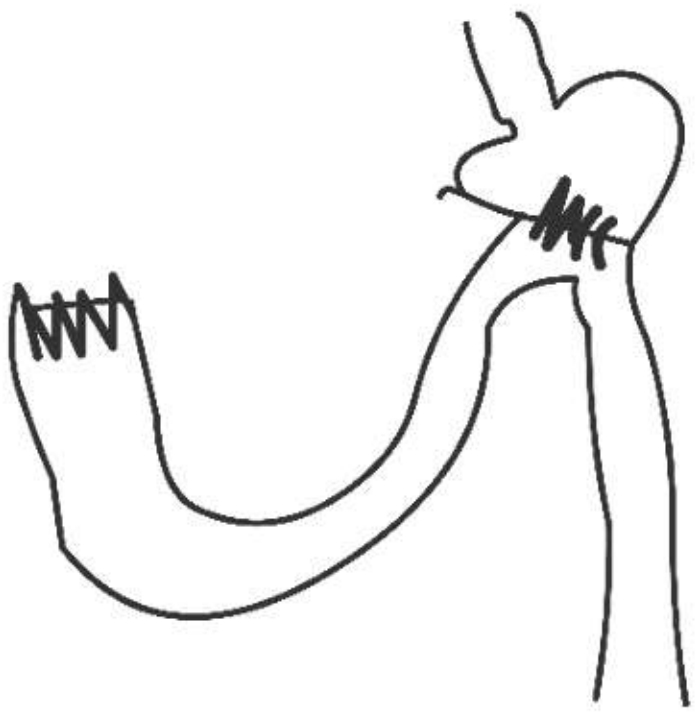

Billroth II Reconstruction

Fig: 3

Complications of Peptic Ulcer 00:21:12

Complications of peptic ulcer	
Duodenal ↓	Gastric ulcer ↓
1.Intractable →	1. Intractable
2.Bleeding (most common) → posterior →	2.Bleeding → posterior
3.Perforation - Anterior →	3.Perforation - Anterior (most common)
4.Gastric outlet obstruction →	4.Gastric outlet obstruction

AfraTafreeh.com

Note: most common cause of death - bleeding ⎤ In duodenal
Highest mortality rate - perforation ⎦ ulcer

0.5% Incidence of malignancy → in gastric ulcer.

TUTORIALS
LOGIN FOR SUCCESS

AfraTafreeh.com

COMPLICATIONS OF PEPTIC ULCER

Bleeding 00:00:13

- Most common complication and most common cause of death in duodenal ulcer.

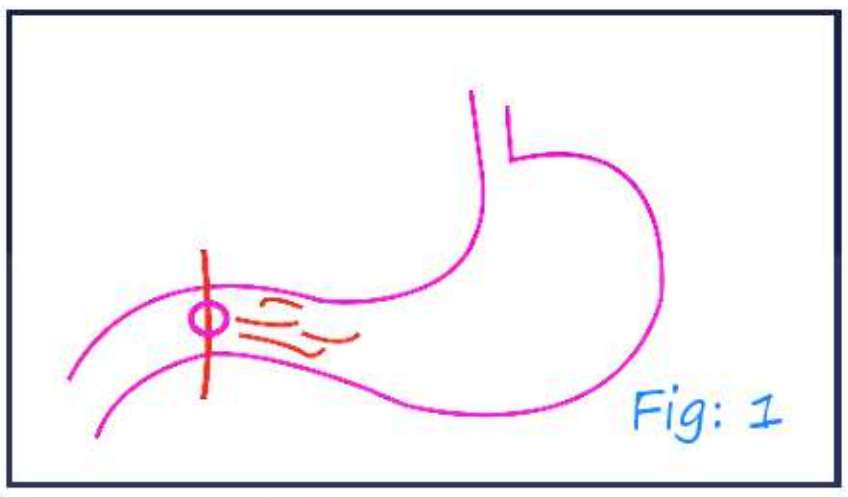

- Ulcer is situated exactly on the gastroduodenal artery.
- If the ulcer is active and penetrates, then gastroduodenal artery will bleed into duodenum
- Clinical Feature
  - Most common – hematemesis (60%)
    melena (40%)
- Usually present with massive hematemesis
  ↓
  - IVF started
  - DOC – Inj. PPI
  - Ryles tube aspiration
  - Blood transfusion
  ↓
  IOC – Upper GI scopy
  ↓
  FORREST classification
  'Bleeding duodenal ulcers'

I – Active Bleeding DU
IIa – Visible Vessel
b – Clot
c – Dot (Black dot)
III – Healed DU

(I, IIa) → Endoscopic therapy
↓
i. Epinephrine injection
ii. Coagulation
iii. Clipping

- Most common vessel – Gastroduodenal artery (artery of He)
- Indication of surgery
  1. ≥ 6 units transfused on day of admission
  2. ≥ 3 units/daily
  3. > 2 attempts of endoscopy failed
  4. Hemodynamic unstable
  5. Rare blood groups

     ↓

     Laparotomy

     Duodenotomy

AfraTafreeh.com
TUTORIALS
LOGIN FOR SUCCESS

Unstable –

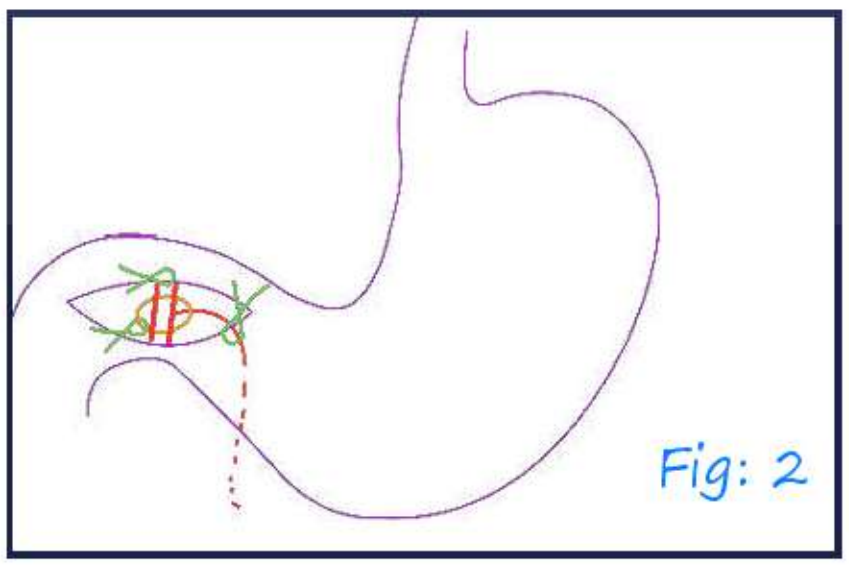

Fig: 2

3 point 'U' suture done

Stable – Truneal vagotomy with Heinke Mikulicz pyloroplasty

AfraTafreeh.com


Fig: 3

Bleeding gastric ulcer

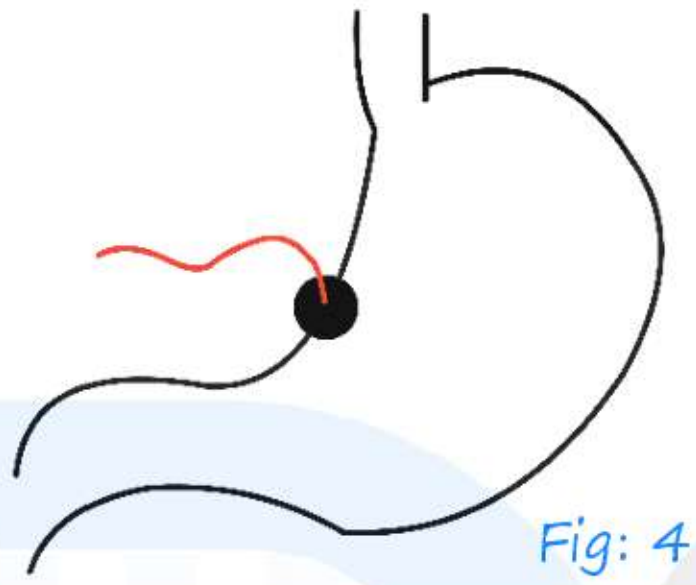
Fig: 4

- Most common presentation – malena (60%)
  hematemesis (40%)

- Most common vessel – left gastric artery

Stable → Distal Gastroectomy + Billroth II

Unstable → Laparotomy & oversew the ulcer

Perforation Peritonitis 00:12:18

- Duodenal ulcer perforation
  ↓
  Most common in anteriorly located ulcers
  ↓
  Perforate into free peritoneal cavity



Fig: 5

- Clinical feature – chemical peritonitis

  Epigastric pain

  O/E – Guarding → Voluntary

  Rigidity → Involuntary

  Obliteration of liver dullness ⊕

  Bacterial peritonitis

  ↓

  Shock

  Increases PR, Decreases BP, Increases temp

  Hippocratic facies

AfraTafreeh.com
TUTORIALS
LOGIN FOR SUCCESS

- Bile goes to Right iliac fossa → Pain in RIF

  ↓

  Mimics appendicitis

  ↓

  Appendix normal

  ↓

  Valentino syndrome

  ↓

  Treatment – Laparotomy + omental patch closure + Appendicectomy

- 1st done – X-ray abdomen erect including the diaphragm

AfraTafreeh.com

↓

1ml air → Pneumoperitoneum (70% cases)

Fig: 6

X-ray left lateral view – 5-10 ml air needed

↓

Gas seen in upper part right hypochondrial area

X-ray Abdomen Erect

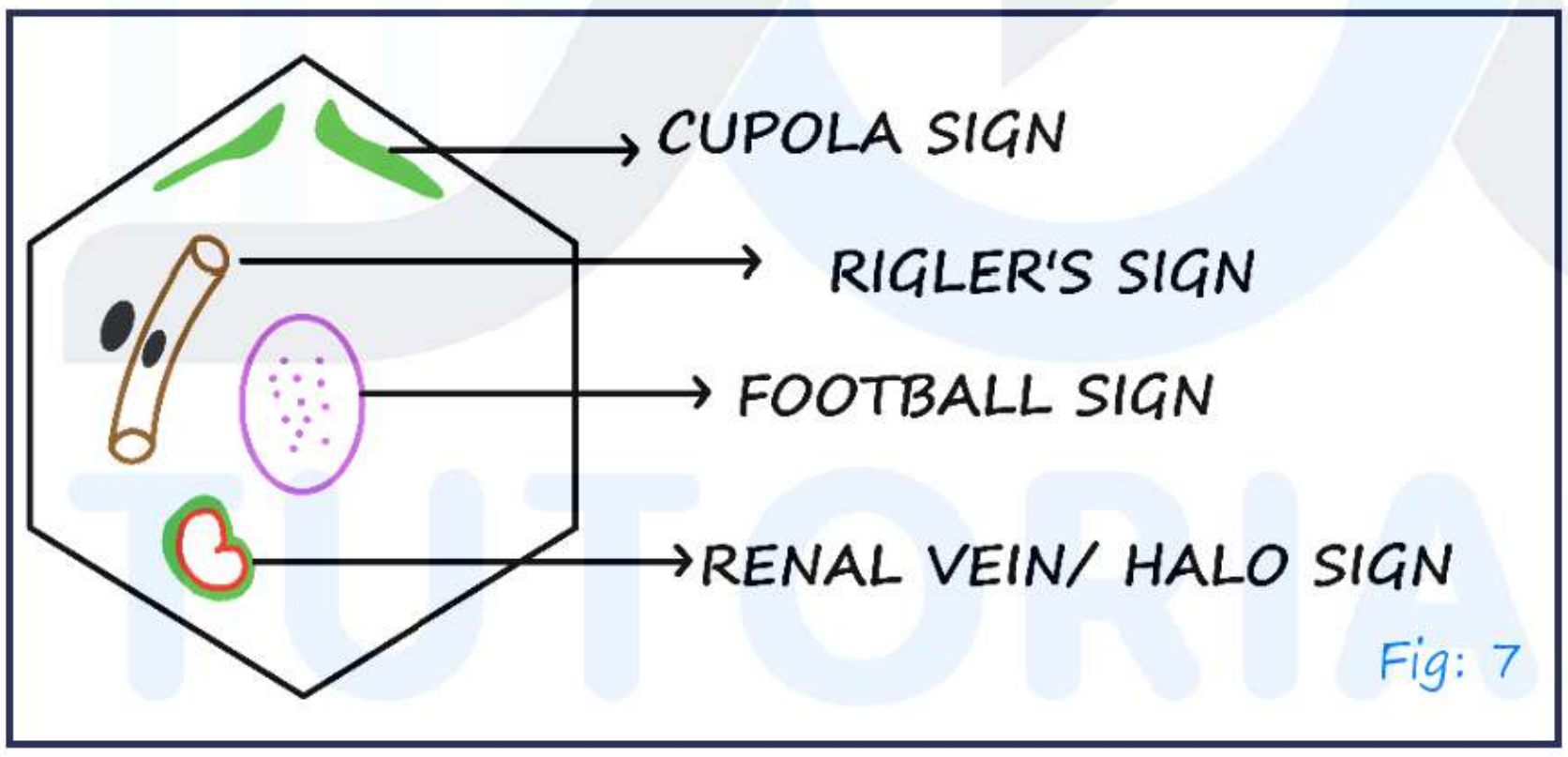

Fig: 7

Cupola sign – Air seen on either side of xiphisternum like moustache

- Football sign – Presence of huge gas in abdomen
- Double wall sign (Rigler's sign) – presence of gas inside and outside intestine
- Renal vein/Halo sign – Presence of perinephric gas in posterior perforation.

Chiladitis sign

- Gas shadow above due to colon gas interposition.

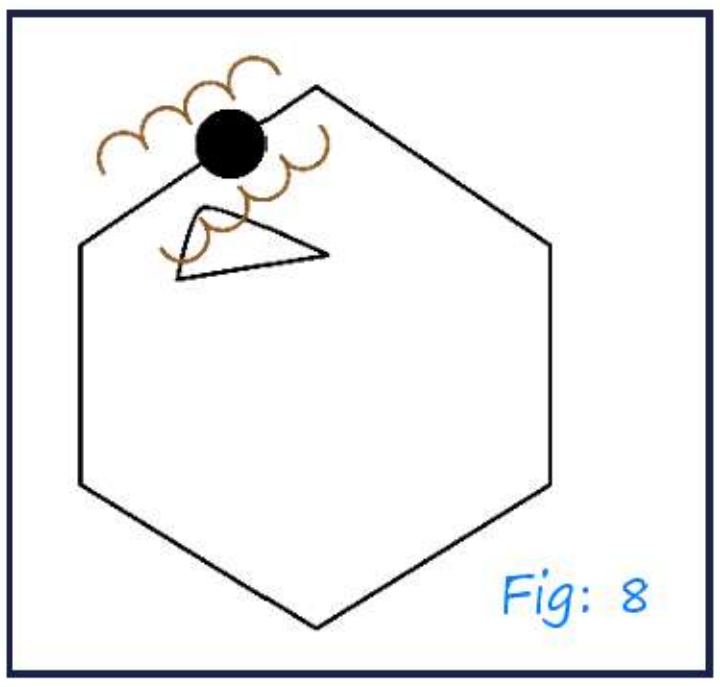
Fig: 8

- Mimics like air under diaphragm
- IOC – CT abdomen (oral gastrograffin)

  (Barium is C/I as it causes barium peritonitis.

  ↓

  Contrast of choice – Esophageal perforation

AfraTafreeh.com
TUTORIALS
LOGIN FOR SUCCESS

- Treatment – IVF

  Ryles tube aspiration

  Higher antibiotics

  ↓

  Emergency laparotomy

  ↓

  Complete lavage the peritoneal cavity

  ↓

  < 1 cm – Direct closure

  1-3 cm – Modified Graham's omental fap closure

  > 3 cm – Giant ulcers → risk of EC fistula

  +

  Jejunal serosal patch closure

AfraTafreeh.com

↓

Patch closure + GJ

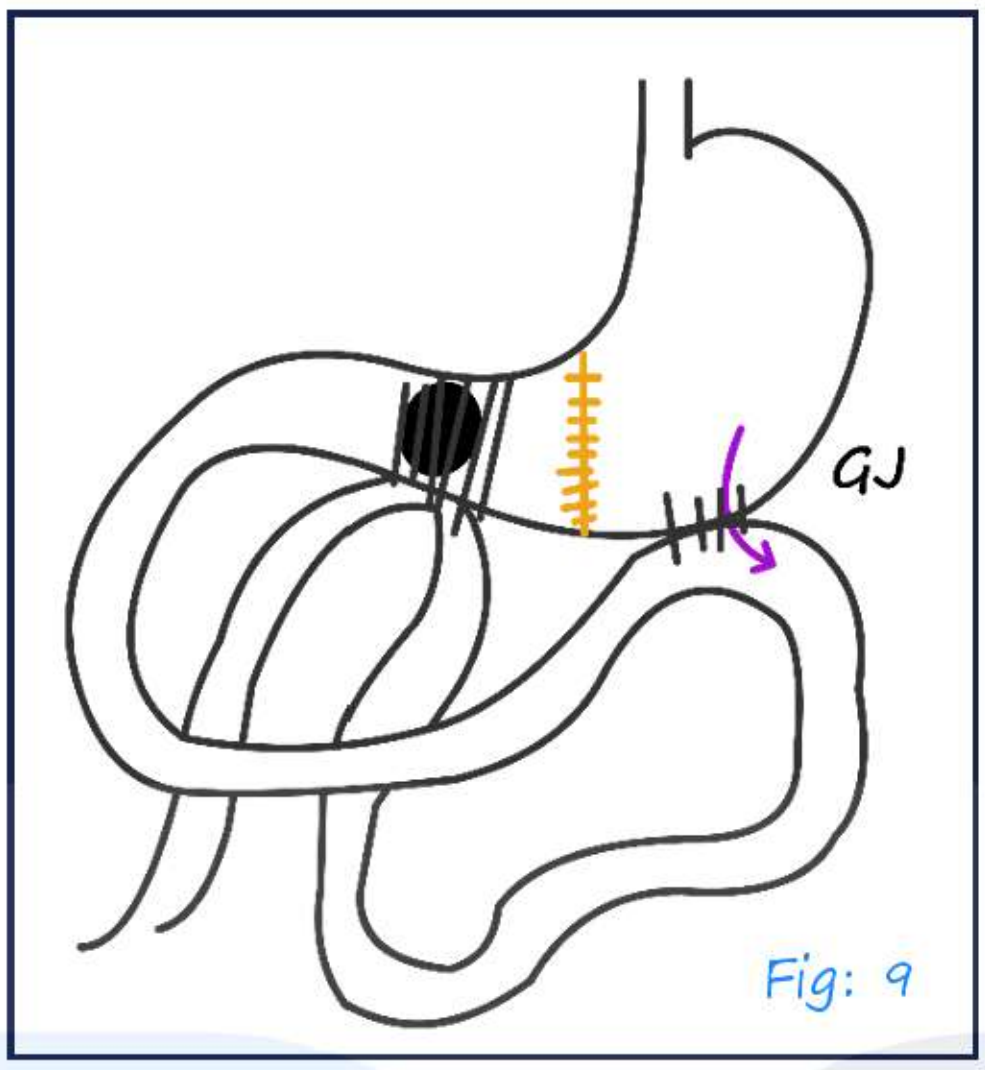

Fig: 9

- If Omentum not available → falciparum ligament can be used.
- Stable
  Early case
  Less contamination
  } – TV with GJ also done + omental patch

Perforated Gastric Ulcer

Stable	**Unstable**
↓	↓
Distal gastrectomy + Billroth II	Omental patch closure (+ Bx from ulcer)

Gastric Outlet Obstruction 00:30:00

- Most common cause – Ca stomach
- Long standing duodenal ulcer → cicaltrisation – Goo

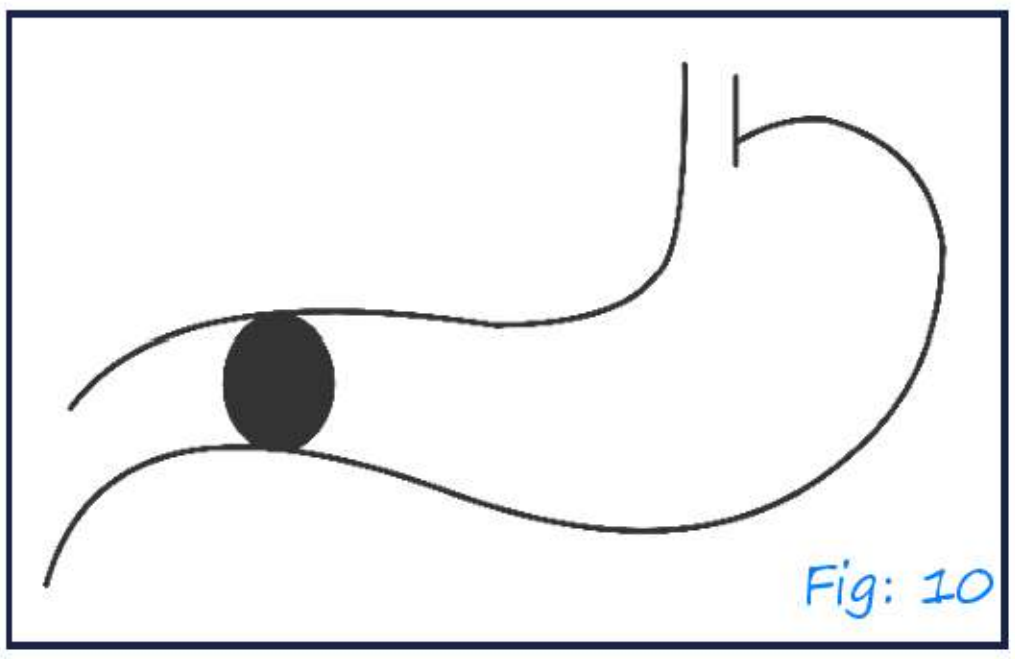

Fig: 10

- Clinical feature – Projectile vomiting of undigested food particles visible gastric peristalsis present → left to right peristalsis seen.
- Electrolyte imbalance

  HCL → Decreases Cl^- metabolic alkalosis

  ↓

  Convulated tubules reabsorb HCO^-_3 → excrete Na^+

  ↓

  - Hyponatremia
  - Hypokalemia
  - Hypocalcemia
  - H^+ Secreted in urine (Paradoxical renal aciduria)
- IVF – NS + Kcl (RL C/I)
- Stomach wash → IOC Endoscopy to find the cause
- Ba. meal – TRIFOLIATE DEFORMITY → Deformed duodenal bulb

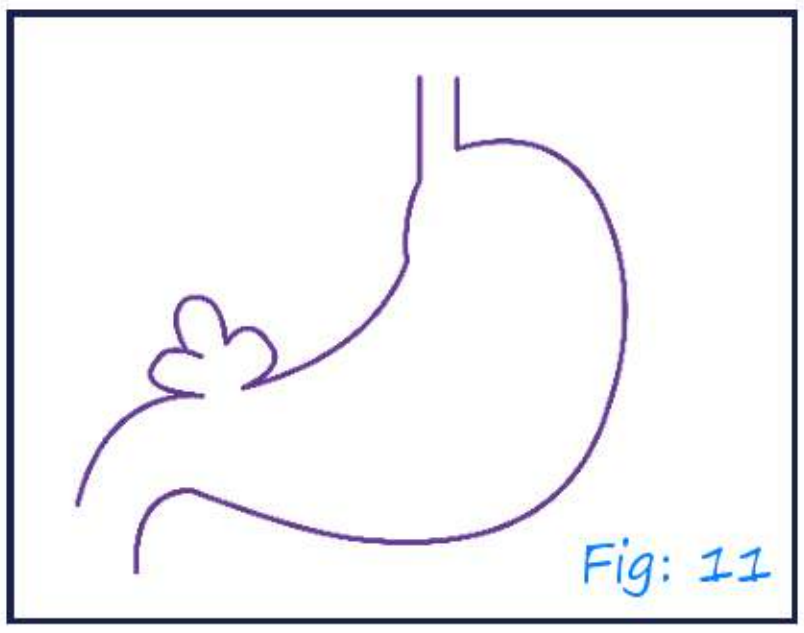

Fig: 11

AfraTafreeh.com
DOC TUTORIALS
LOGIN FOR SUCCESS

AfraTafreeh.com

- Treatment of choice – TV with GJ

  ↓

  MGE – Endoscopic balloon dilation

- Chronic GU → Cicatrisation

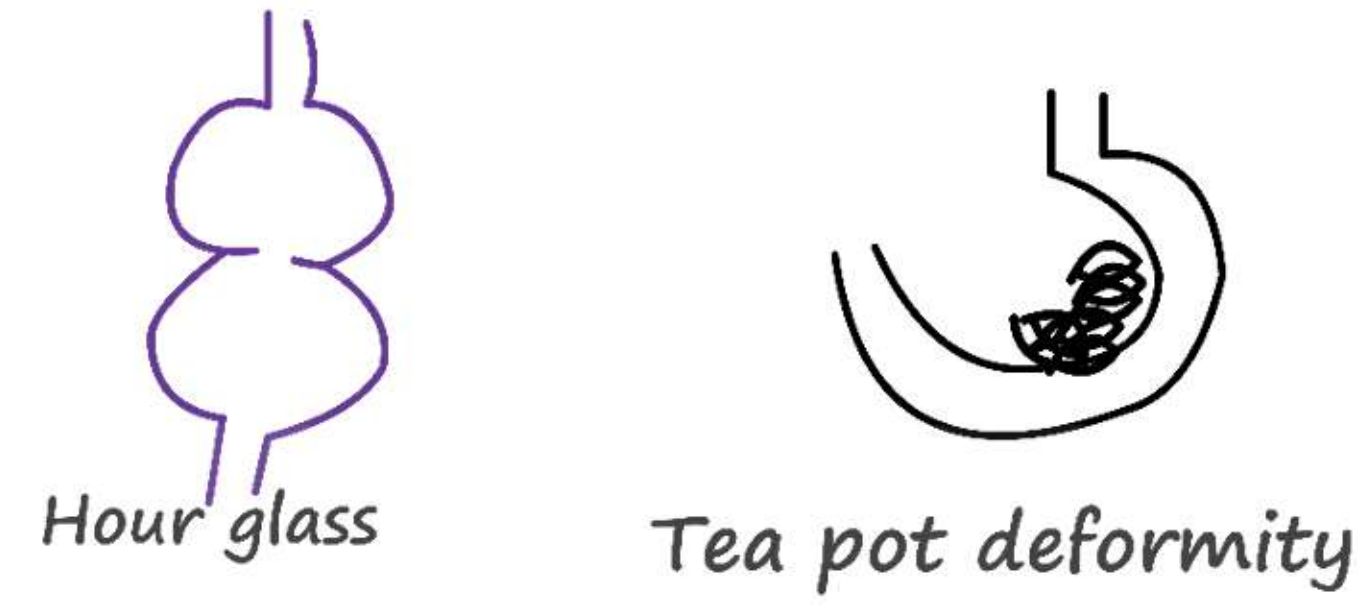

Fig: 12

- Treatment – Distal Gastrectomy + Bilroth II

	DU	GU
1. Intractable	HSV > TV + GJ	I – Wedge II/III – DG + TV + Billroth II IV – Pouchet, kelling, Csendes
2. Bleeding	3-point U suture + TV	Oversew the ulcer stable – DG
3. Perforation	Modified Graham's patch	Unstable – Omental patch Stable – DG
4. GOO	TV + GJ	DG + Bilroth II

CANCER STOMACH INTRO

Introduction 00:00:19

- Cancer stomach – m/c cancer in entire GIT
- Most common site of cancer (India/Asia) – Antrum (Incisura)
- Most common site of cancer (western) – Proximal cardia + fundus

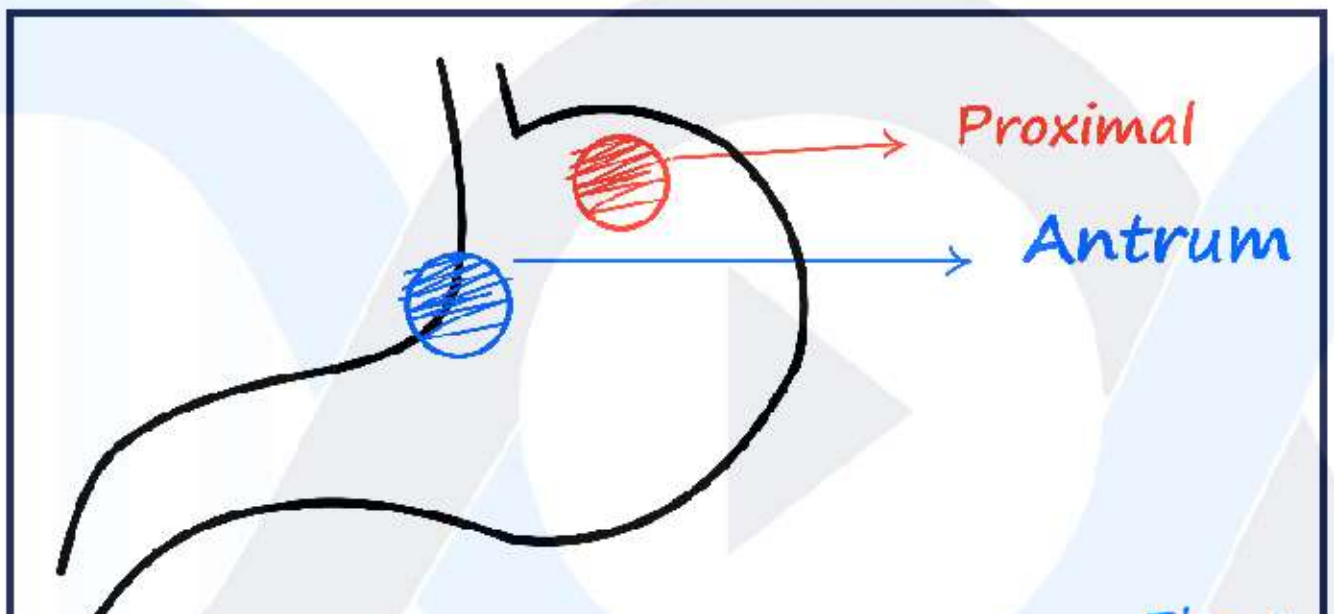

Fig: 1

AfraTafreeh.com

- Most common histological type Adenocarcinomas

TUTORIALS
LOGIN FOR SUCCESS

Predisposing factors

(6S):

- spirit
- Smoking
- Spicy food
- Salted food
- Smoked food
- Improperly Stored food

Note: Refrigerators has decreased Ca. Stomach incidence

AfraTafreeh.com

(4A):

↓

- Adenomatous polyps
- Atrophic gastritis
- Anemia (pernicious)
- A Blood group

Others

- Menetrier's disease
- H. pylori - Cag A toxin

Genetic

- E-cadherin Mutation-Prophylactic total gastrectomy
- Li-Fraumeni syndrome
- Lynch II
- FAP syndrome

TUTORIALS
LOGIN FOR SUCCESS

Clinical features 00:05:38

- S - Silent
- T - Tumour
- O-GOO
- M – Melena +
- A - Anaemia
- C - Cachexia
- H - Hematemesis

Early satiety → Linitis plastica

Loss of weight

Pain unrelated to food

Back pain → pancreas infiltrated

METASTASIS

1. Krukenberg tumour
   - B/L ovarian
   - premenopausal women
   - superficial deposit
   - trans-coelomic spread
2. Blumer's shelf
   - Trans-coelomic Spread
   - Pouch of Douglas deposit
3. Sister Mary Joseph Nodule:
   - Umbilical deposit
   - Trans-coelomic spread

Lymphatic spread

- Ⓛ Supraclavicular node
  Virchow's node
  ↓
  Troisier sign
- Ⓛ axillary node
  ↓
  IRISH NODE

TUTORIALS
LOGIN FOR SUCCESS

AfraTafreeh.com

Spreads of ca Stomach

Direct	lymphatic	Trans coelomic	Haematogenous
↓	↓	↓	↓
Pancreas	16 Stations nodes	Blumer's	liver m/c
Liver	↓	Sister May	Lung
Oesophagus	Virchow's	Krukenberg	
Duodenum	Irish	Peritoneal mets	
Colon		Ascites	
Spleen			

Note: Oesophagus, Duodenum, Colon, Spleen → only operable cancers all others are inoperable

Investigation 00:14:47

- IOC to
  - Diagnose - Endoscopic biopsy (6-8)
  - T ⌉ EUS
  - N ⌋
  - M -CECT Abdomen
  - Tumor marker -CA 72-4

TNM staging 00:16:21

- T_1: involves mucosa submucosa only
- T_2: upto muscle only

- T_3: Sub serosa
- T_4: Serosa and adjacent structures
  - liver, pancreas, spleen (except duodenum, oesophagus)

  M – Metastasis

- N_1: 1–2⊕
- N_2: 3–6⊕
- N_3a: 7–15⊕
- N_3b: ≥16⊕

Q. minimum nodes to be removed

- Oesophagus: – 15 nodes
- stomach: 16 nodes
- Colon: 12 nodes
- Rectum: 12 nodes
- Breast: 10 nodes

Early Gastric cancer

- Routine screening upper GI scopy

  ↓

  Confocal endoscopy

  Narrow band imaging

  ↓

  involves mucosa / submucosa only

  ± nodes

  ↓

  JAPANESE CLASSIFICATION

- Treatment: EMR & ESD

AfraTafreeh.com
TUTORIALS
LOGIN FOR SUCCESS

AfraTafreeh.com

- EMR – Endoscopic mucosal resection
- ESD – Endoscopic submucosal dissection

Classifications 00:22:20

1. **Borrmann:** – Morphologic

i.  – Polypoidal

ii.  – ulceroproliferative (crateriform)

iii. – ulcerative

iv.  – Linitis plastica (Diffuse)

2. LAUREN'S – microscopic classification

Intestinal	**Diffuse**
Sporadic (m/c)	Familial (L/C)
m/c old males	Young females
Environmental	Genetic
↓	↓
Gs, H. pylori	E-cadherin mutation + pernicious 'A' group

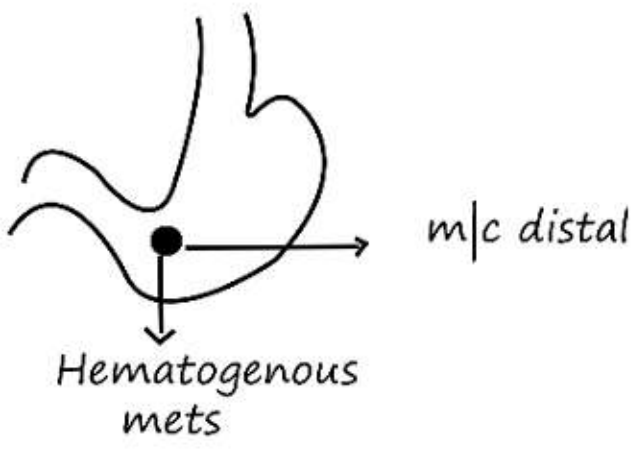

nodular mets in liver

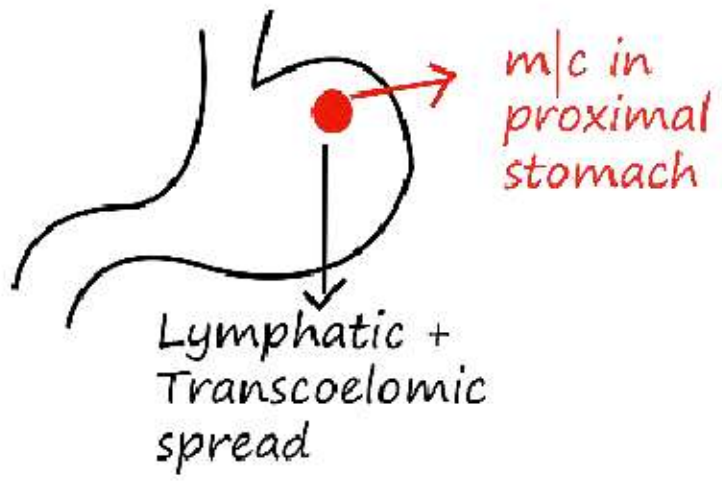

Good prognosis.

↓

well differentiated

↓

- APC mutation
- P53 mutation
- P16 mutation

Diffuse mets in liver

Bad prognosis.

↓

poorly differentiated

↓

signet ring cell

↓

- E cadherin mutation
- P53 ++
- P 16 +

3.SIEWART's

AfraTafreeh.com

- Classification of OG junction cancer (Adeno cancers)

TUTORIALS
LOGIN FOR SUCCESS

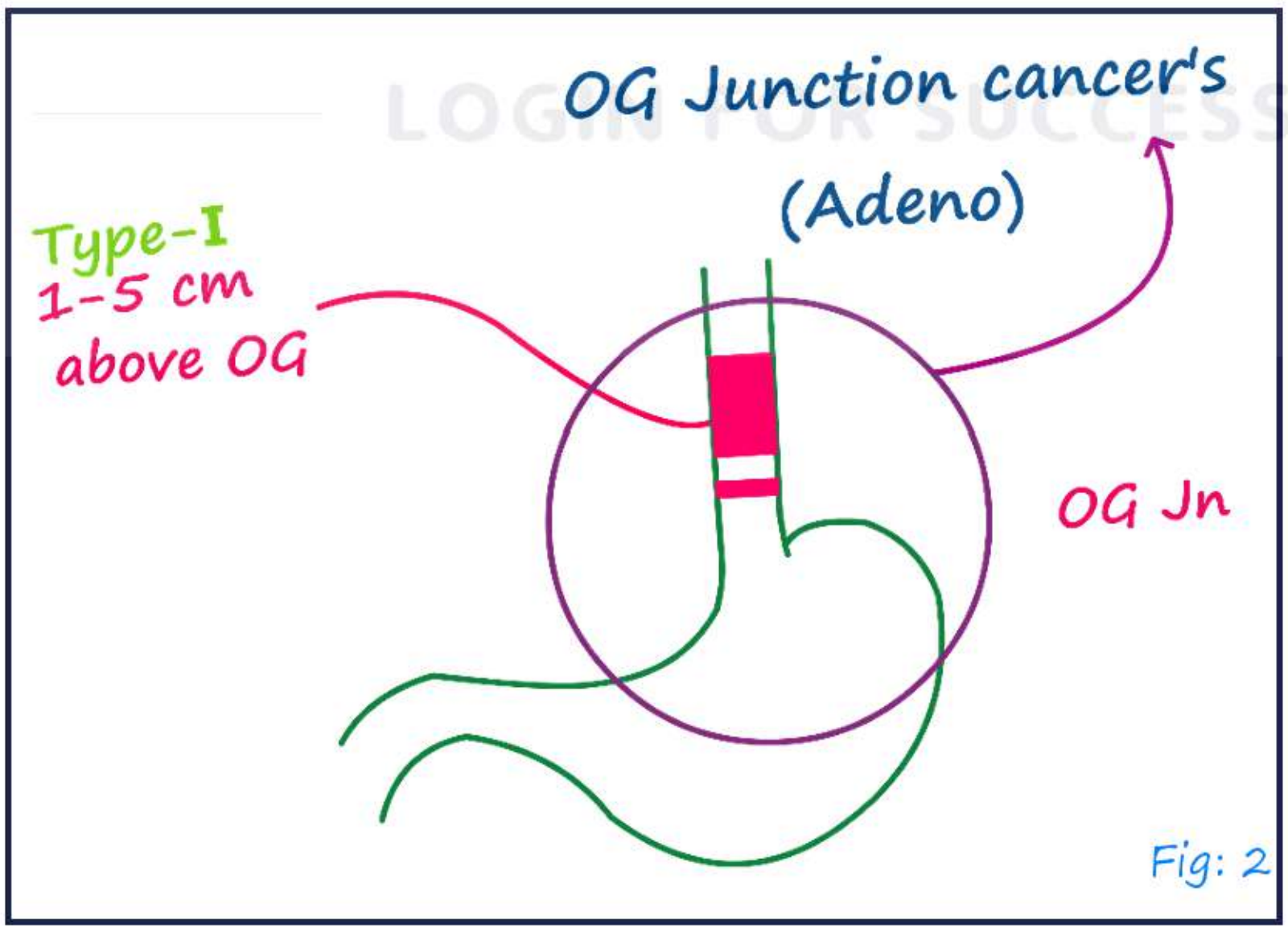

Fig: 2

AfraTafreeh.com

- Cancer above 1-5 cm. from OG junction - Type I Siewart's
  - Cancer 1cm above and 2cm below of junction - Type II

- Cancer seen 2-5 cm below OG junction - Type III

↓

Gastric cancer

↓

Total gastrectomy

- Type I - II - Oesophageal Adeno cancers

↓

Trans hiatal Oesophagectomy

4.MING STAGING - Chinese

5.JAPANESE Classification - Early gastric cancer.

TUTORIALS
LOGIN FOR SUCCESS

STOMACH CANCER MANAGEMENT

Outline 00:00:17

Ca stomach

- Primary
  - 1.Distal gastric cancer
    - Proximal clearance of 4-6 cm
- Nodes
  - 3 level (16 station)
- Adjuvant chemotherapy

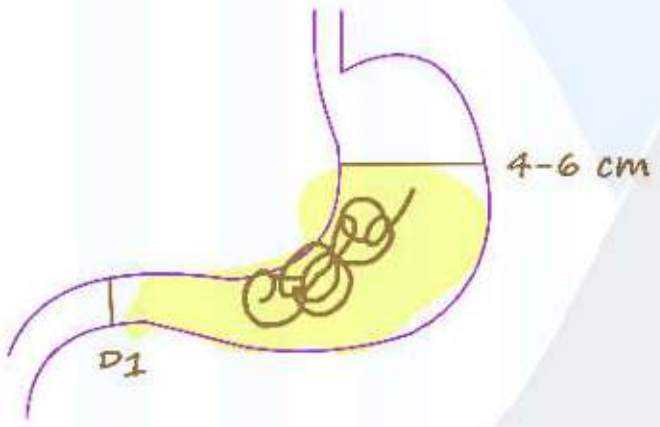

AfraTafreeh.com

2.Proximal gastric cancer
↓
Total gastrectomy

Nodal Stations 00:02:32

16 stations – 3 level

- Level-1

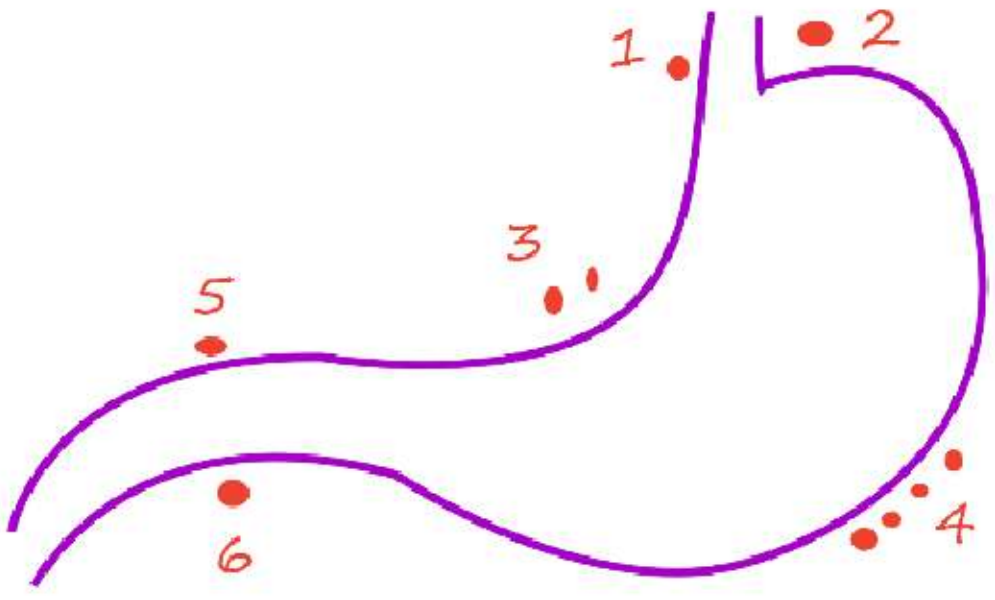

1.Right cardiac
2.Left cardiac
3.Lesser curvature
4.Greater curvature
5.Suprapyloric
6.Infrapyloric

AfraTafreeh.com

- Level 1 nodes are < 3cm from growth & perigastric nodes
- If all these nodes are removed – D_1 lymphadenectomy

- Level 2
  - Along major vessels

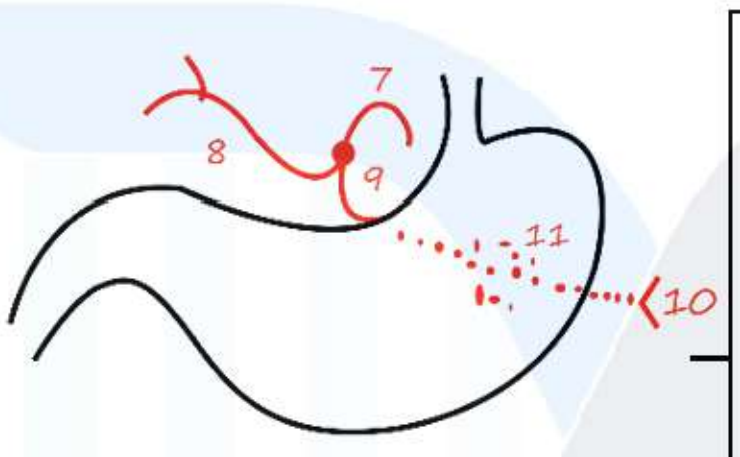

7. Left gastric artery nodes
8. Common hepatic artery nodes
9. Coeliac
10. Splenic hilum

- Removal of nodes 1-6 + 7-11 → D_2 gastrectomy

- Level 3

12 – Hepatoduodenal

13 – Retro pancreatic

14 – Superior mesenteric vessels

15 – Middle colic vessels

16 – Para aortic nodes

- Removal of all 16 nodes – D_3 lymphadenectomy

↓

Done only in Japan

TUTORIALS LOGIN FOR SUCCESS

- Gold standard – D_2 lymphadenectomy
  - D_1
  - D_2 } LN clearance
  - D_3

- 'R' resection
  - R_0 – No microscopic residue → gold standard
  - R_1 – Microscopic residue
  - R_2 – Macroscopic residue

Tumor Resection 00:09:59

- Surgical resection → Subtotal gastrectomy + D_2 lymphadenectomy } for distal cancers

AfraTafreeh.com
TUTORIALS
LOGIN FOR SUCCESS

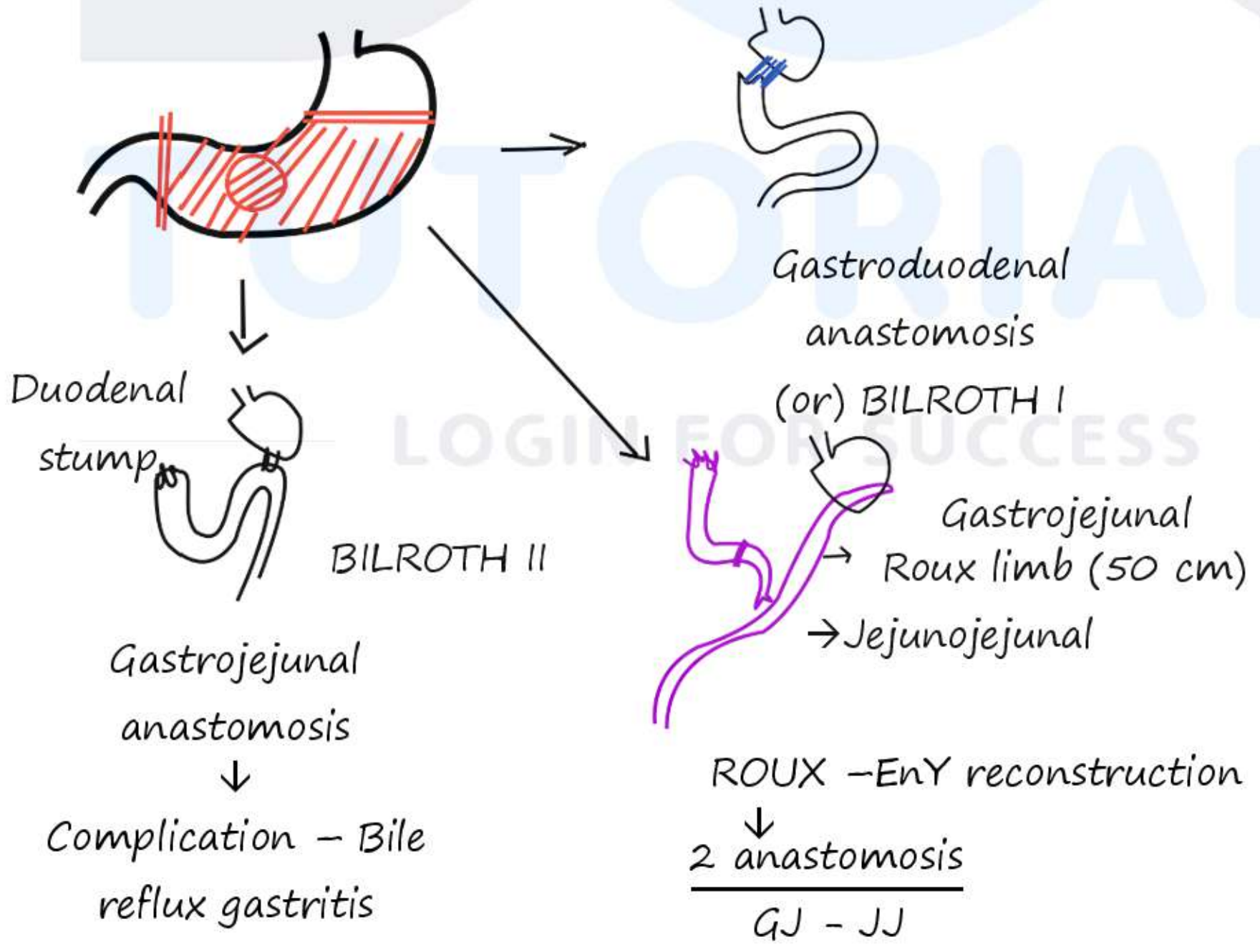

Duodenal Stump Blow Out 00:15:02

- Most common after bill Routh II
- 4–5th POD

AfraTafreeh.com

- Bile leaks → USG abdomen
- Treatment – USG guided percutaneous drainage tube-no surgery needed

Peterson's Hernia 00:16:48

- Internal hernia behind roux limb – Peterson's hernia

Total gastrectomy 00:17:35

For proximal cancers – Total gastrectomy

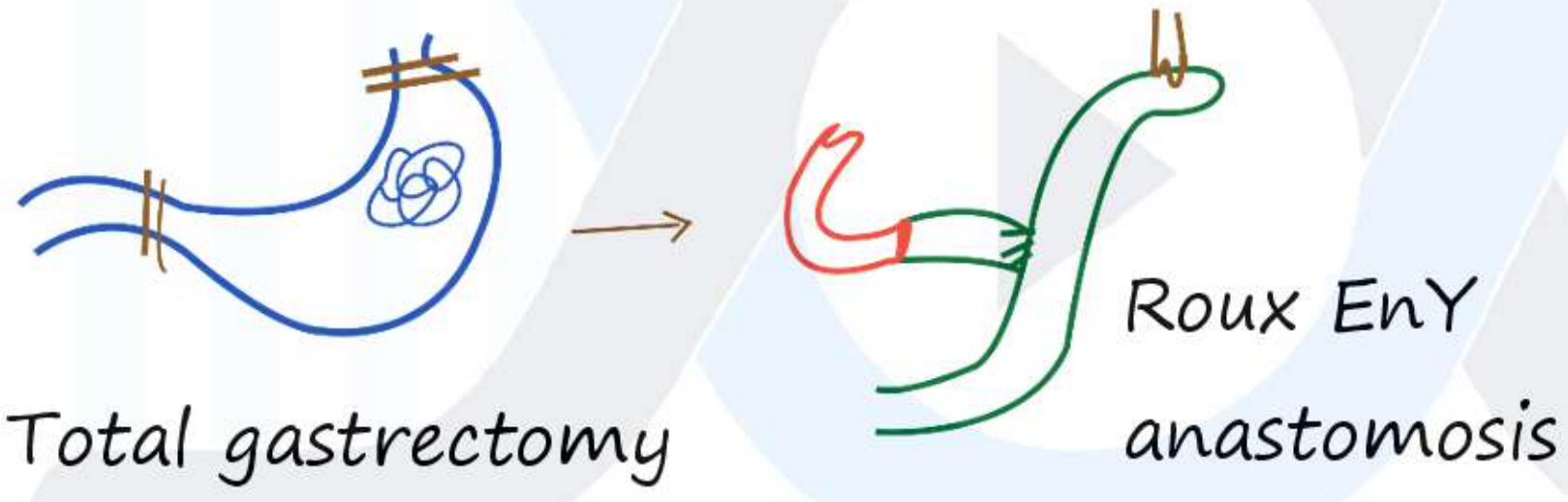

Inoperable Patients 00:18:06

Palliative procedures

- for GOO → Endoscopic stenting
  → Palliative GJ

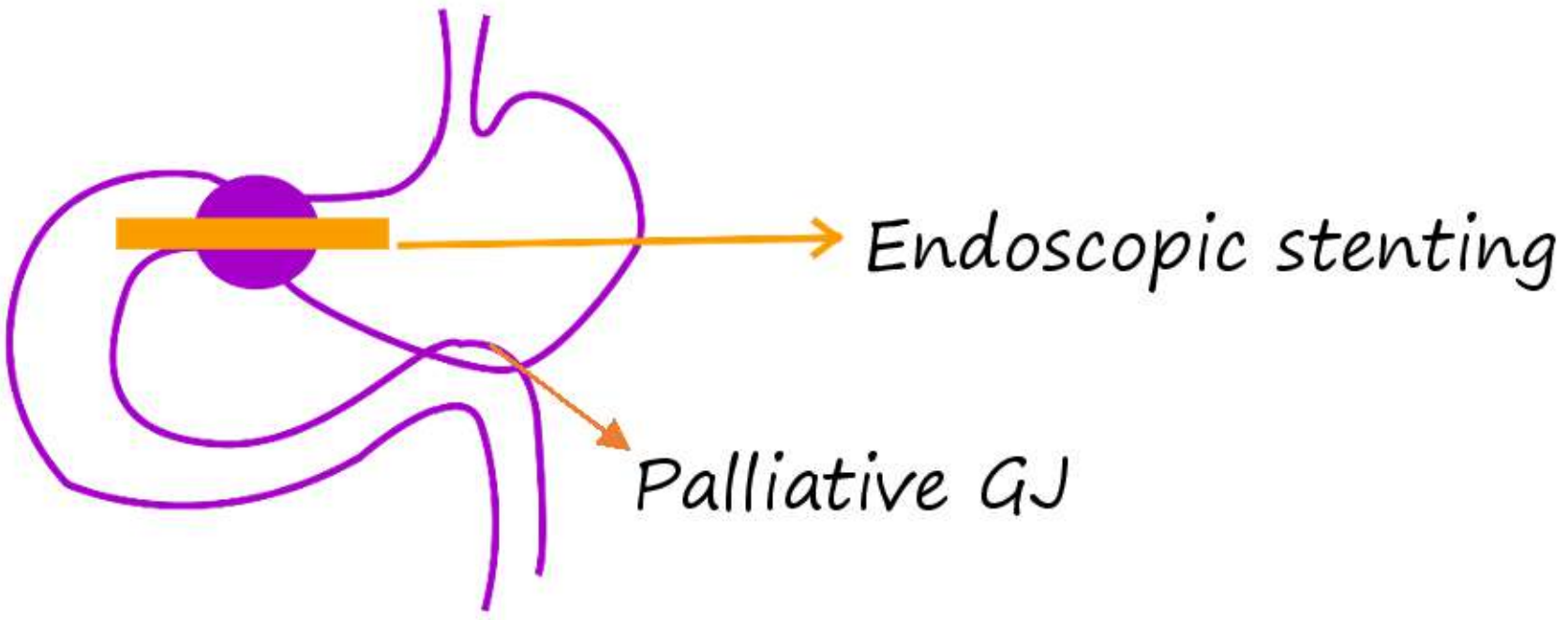

Dysphagia



Self-expanding metallic stents
(or)
Laser luminisation

Bleeding growth

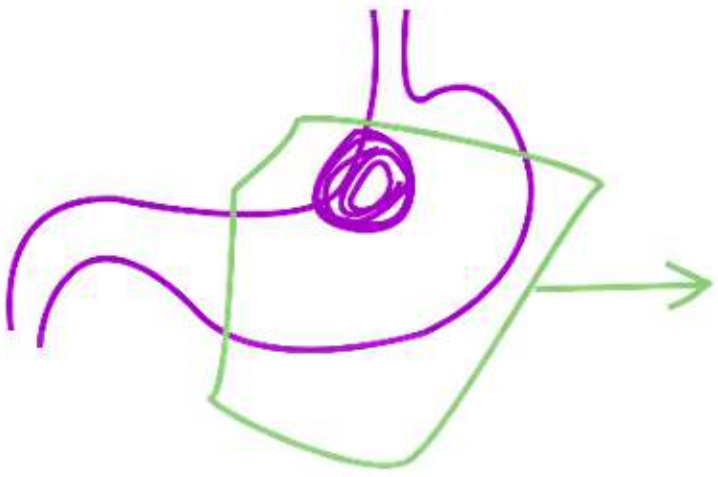

Resection of growth as a palliative procedure

New procedure

i. Embolization of left GA

ii. Cryoablation of tumor

Chemotherapy AfraTafreeh.com 00:21:52

- 5FU based chemotherapy x 6 cycles.

TUTORIALS
LOGIN FOR SUCCESS

AfraTafreeh.com

OTHER TUMORS

Miscellaneous tumors of GIT 00:00:10

Miscellaneous tumors of GIT

Adenocarcinoma
↓
most common site: Stomach

Carcinoid
↓
NET of GIT origin from
- Entero chromaffin cells/Argentaffin cells
- Most common in appendix

NHL of GIT
↓
1° GI lymphoma **(DAWSON'S criteria)**
- No generalized LN
- No hepatomegaly
- No splenomegaly
- No bone marrow involvement
- GI organs + (Regional nodes)
- Most common – stomach

GIST
↓
Leiomyoma/ Leiomyosarcoma
Origin: Cells of cajal
Most common in stomach

TUTORIALS
LOGIN FOR SUCCESS

NHL of GIT and gist of GIT 00:04:45

NHL of GIT	Gist of GIT
• Most common – antrum 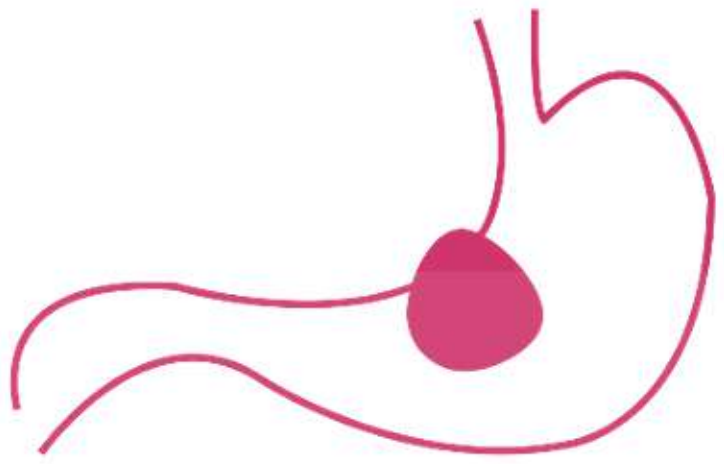 • Burkitts – proximal • Types of NHL • Most common: diffuse large cell type • MALToma • Mantle cell • Burkitt lymphoma • Origin: lymphatics of bowel wall • C/O: Pain bleeding GOO	 • Types • (N) Gist – Tumor marker +ve • CD117+ • CD34+ • Wild gist – tumor markers (-) • Cells of cajal (Pacemaker cells) • Bleeding is most common is gist • Pain • Goo

- IOC: Endoscopy – Mucosa looks (N)
- Latest: EUS guided biopsy

↓

NHL & Gist

AfraTafreen.com

AfraTafreeh.com

Tumor markers of Gist

- CD117: Tyrosine kinase receptor mutation at C-KIT
  90% + ve
- CD34 – 40% +ve
- PDGRA mutation
- Latest: DOG – 1 (Discovered on Gist-1)

Primary GI lymphoma

- Cotswold staging
- Ann arbor staging
- Lugano staging (for 1 GI lymphoma)

Treatment 00:12:29

- CHOP therapy – TOC for lymphoma
- Resection: TOC for gist

Lymphoma	Gist
- Maltomas (H. Pylori) → Early cases → LAC therapy (2-4 weeks) - R-CHOP - C – Cyclophosphamide - H – Hydroxyadriamycin - O – Oncovin - P – Prednisolone - R – Rituximab **Indications of surgery:** - Bleeding	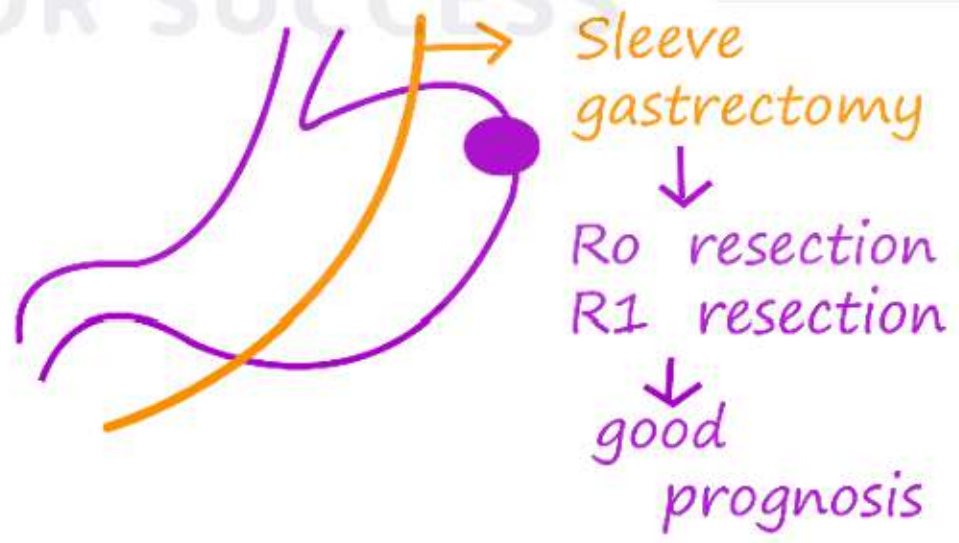 No LN dissection needed **Modified Joensuu criteria (prognosis)** • Size (>10cm-Bad)

DOC TUTORIALS LOGIN FOR SUCCESS

- Intractable pain - Obstruction - Perforation - Not responding to CHOP - For small & large bowel lymphomas – 1st line → Surgery followed by CHOP	• Mitotic index (>5/50 HPF-Bad) • Site (Extra gastric – Bad) (Gastric – good) High risk cases – treated with Tyrosine kinase (-) k/s Imatinib mesylate (or) Sunitinib

AfraTafreeh.com
TUTORIALS
LOGIN FOR SUCCESS

AfraTafreeh.com

MISCELLANEOUS LESIONS

Congenital Hypertrophic Pyloric Stenosis 00:00:21



- Circular muscle of pylorus hypertrophy
- Acquired condition
  ↓
  1st born male child – 4 weeks
- 1 in 3000 live births
- Clinical features
  - Non bilious vomiting
  - Mass appearing & disappearing in epigastric region – pyloric mass
- O/E: – Healthy baby

Inspection during Feeding
↓
Visible gastric Peristalsis ⊕

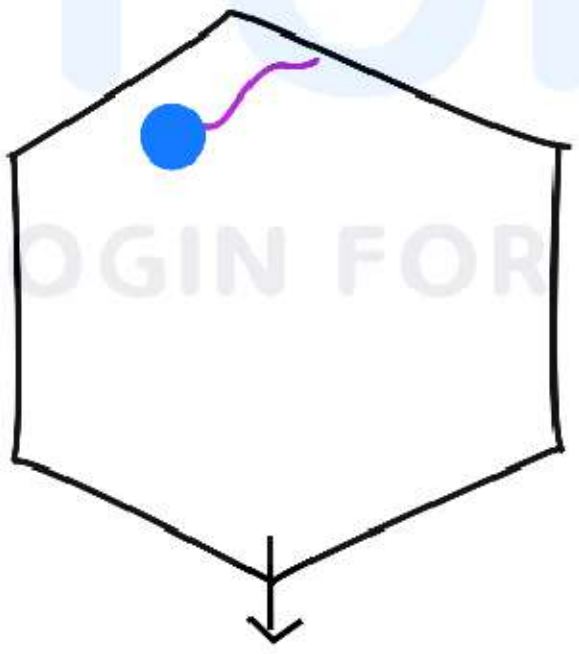

Palpation done during non-feeding time
↓
Olive shaped mass ⊕
(R) hypochondrium

Electrolyte imbalance
↓
Hypochloremic
Hyponatremic
Hypokalemic
Metabolic alkalosis

- No further investigations needed i6 baby has mass with VGP
- IOC: - USG of abdomen

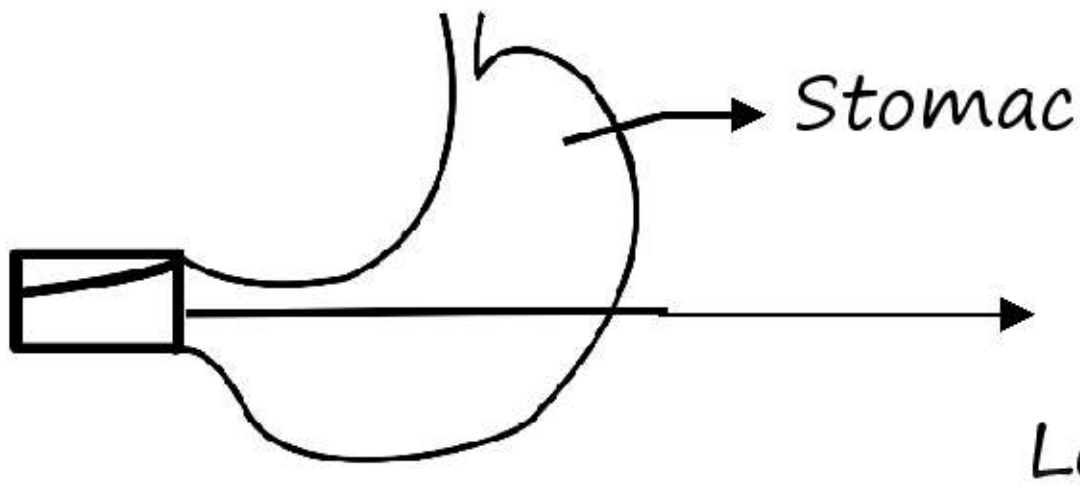

Stomach empty

Pylorus

Length → 16 mm thickened

Breadth → 4 mm thickened

- Barium meal: - String sign/Double track sign
- Gold standard Treatment: - Surgery

↓



RAMSTED'S PYLOMYOTOMY

↓

Mucosa not opened.

↓

Of successful → feeding can be given in 6 hours.

Q If pyloric mucosa opened

↓

resuture only mucosa with 3-0/4-0 vicryl

↓

NPO for 24-48 hours with Ryle's tube inside.

AfraTafreeh.com
DOC TUTORIALS
LOGIN FOR SUCCESS

AfraTafreeh.com

Intestinal Atresia 00:09:34

Intestinal Atresia

- Duodenal (m/c type)

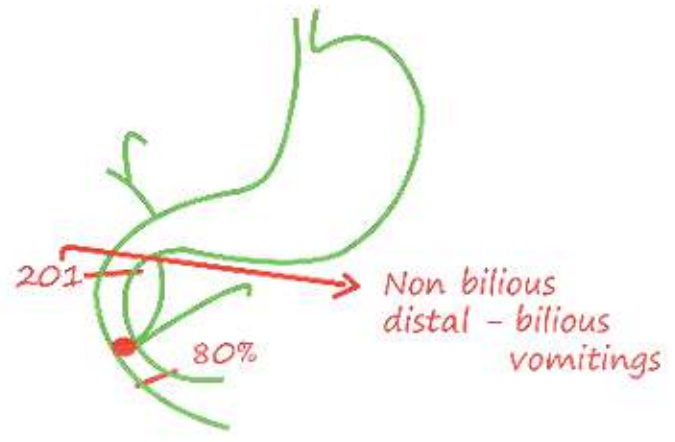

- x-ray – Double bubble appearance
- Treatment- Duodenoduodenostomy

- Jejunal ↓ Triple bubble Appearance

- ileal atresia ↓
  - Mesenteric Ischemia (midgut Volvulus)
  - intravascular Uterine ischemia Can cause ileal atresia

– Intestinal atresias are associated with Gastroschisis

Bezoars 00:12:52

- Foreign body in stomach
- Presence of hair-Trichobezoar →most common - psychiatric
- Hair going up to the Ileum-Rapunzel syndrome

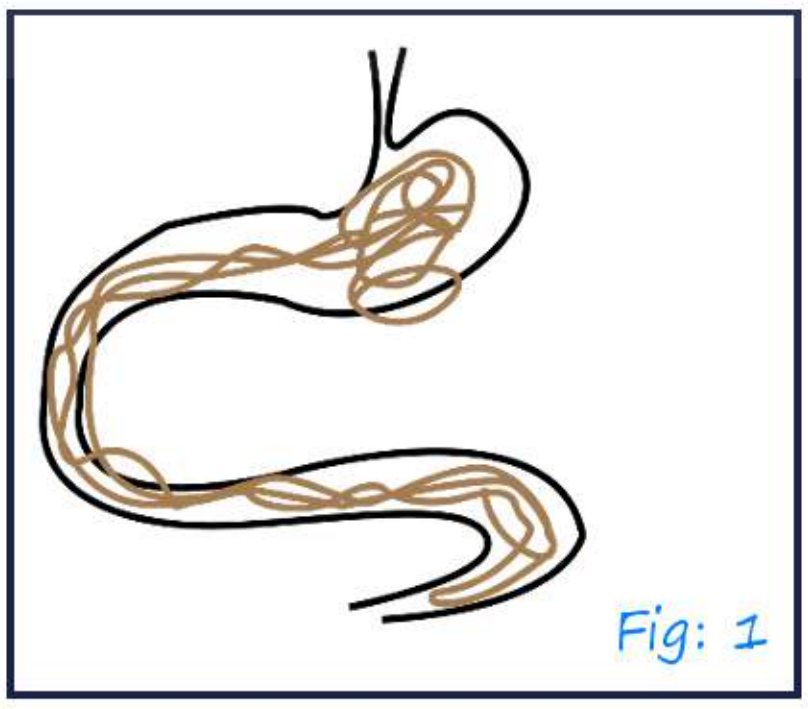

Fig: 1

- Presence of vegetable – Phytobezoar
  ↓

Most Common-Psychiatric

DM (gastroparesis)

Gastric Volvulus 00:14:47



organoaxial volvulus

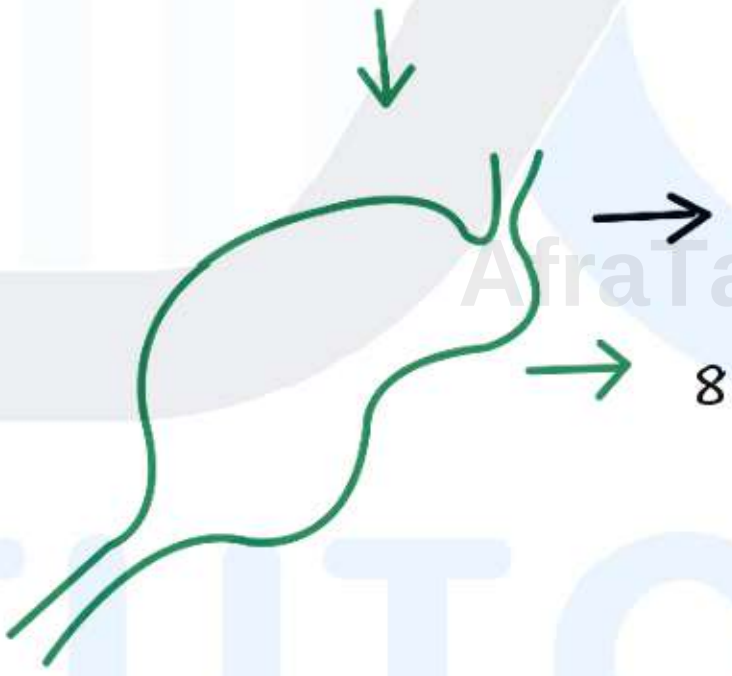

→ Most common associated congenital diaphragmatic hernia

→ 80% of patients

DOC TUTORIALS LOGIN FOR SUCCESS AfraTafreen.com

- Clinical Features: - Borchart's triad



- Retching pain ⊕
- Unable to vomit (no vomiting)
- Coiling of Ryles

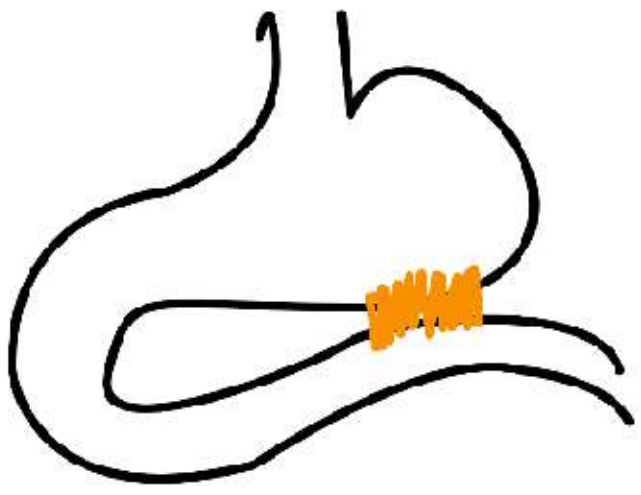

→ Immediate surgery needed
↓
Seromuscular GJ
↓
Can be done Laparoscopically also

AfraTafreeh.com

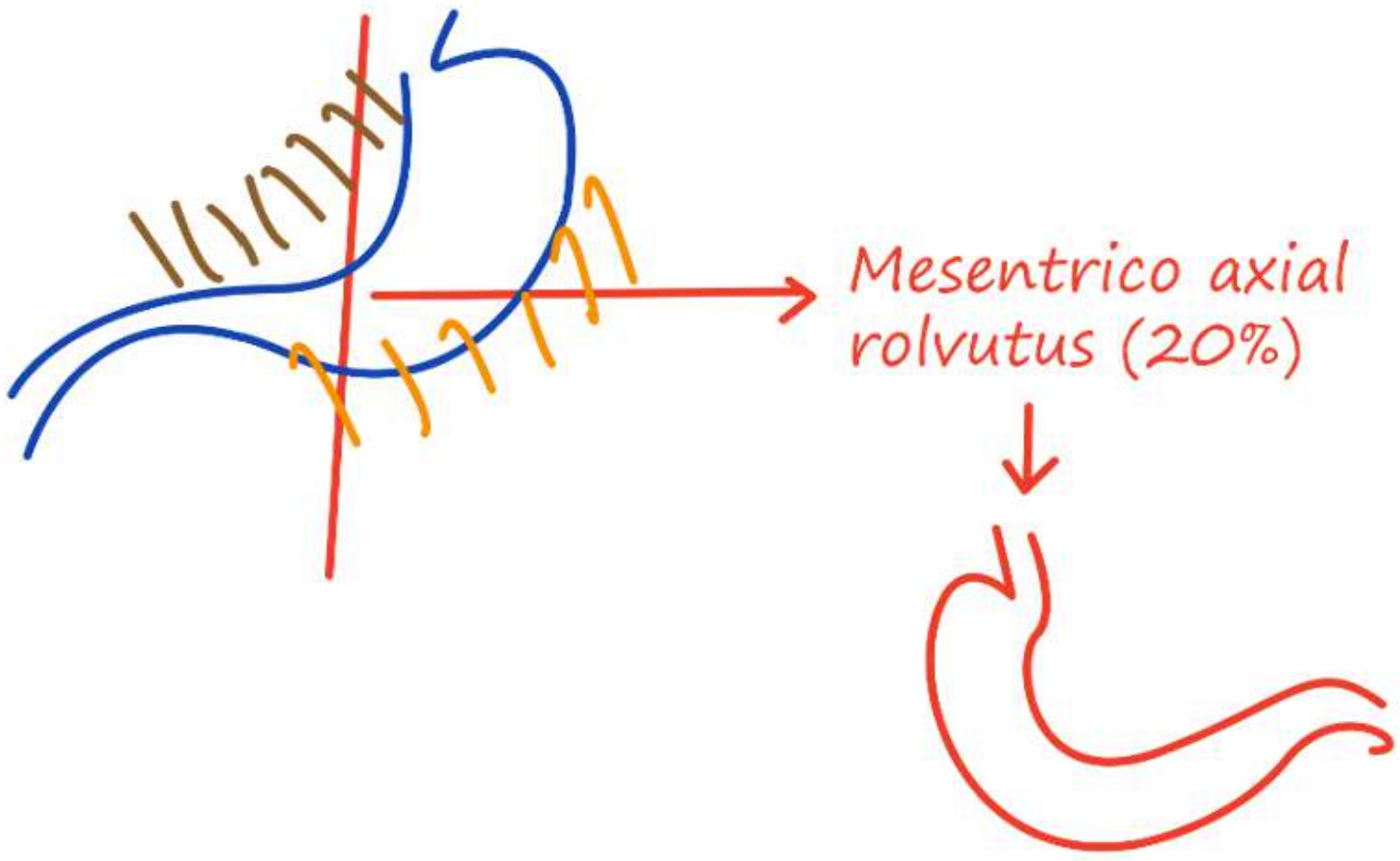

Vascular Lesions 00:19:28

Vascular Lesions

- Gave
- Dieulafoy's Lesion

Gave

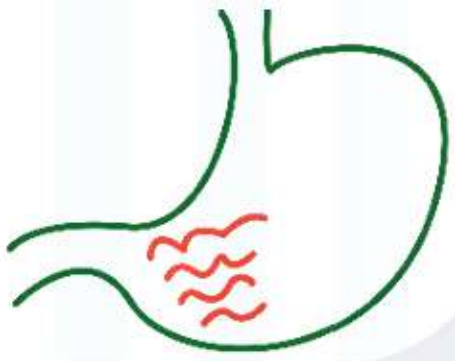

- Old females
- Dilated antral vessels
- Clinical Features
  - Malena
  - IDA
- Endoscopy
  - Watermelon Stomach
- Treatment
  - Argon plasma laser Coagulation

Dieulafoy's Lesion

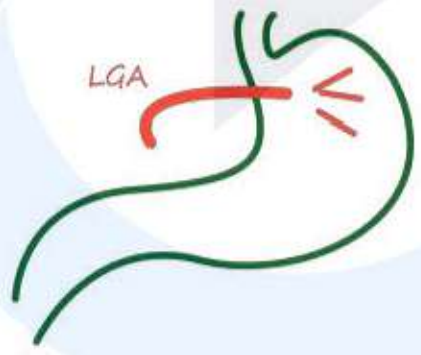

Submucosal artery
↓
Bleeding

- Abnormal dilated artery seen 6cm below OG junction on the lesser curve
- Clinical Features: - Hematemesis
- Treatment: - Endoscopic clipping (Tattoo)
  ↓
  Coil Embolization of LGA
  ↓
  Surgical suturing of Bleeding site done

Menetrier's Disease 00:24:14

- Also known as protein losing enteropathy.
- Parietal cells of stomach are replaced by mucus secreting cells

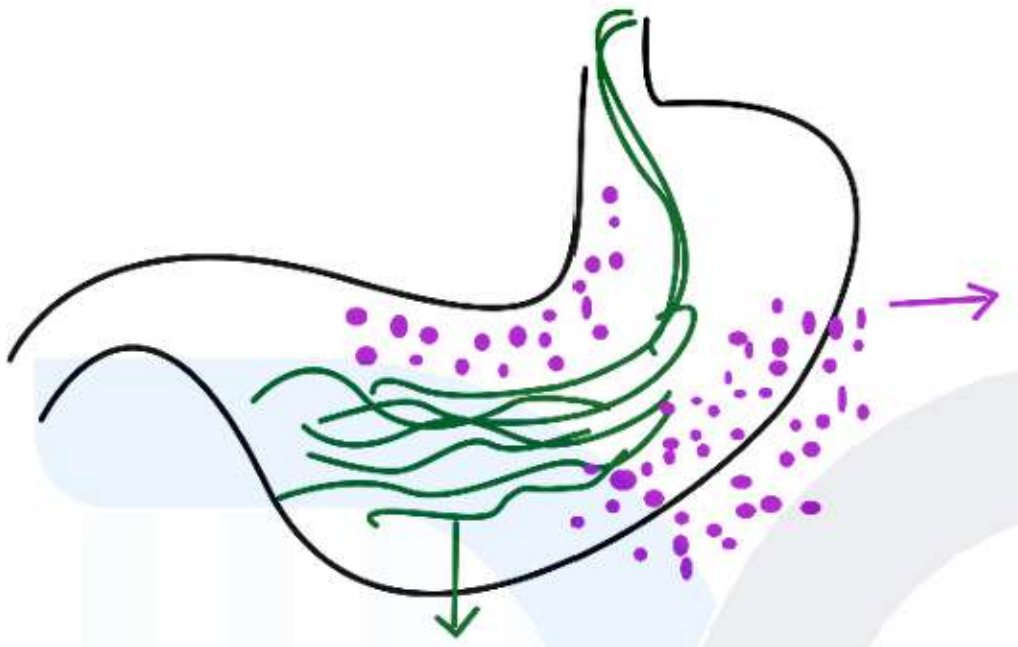

Mucous secreting cells
↓
Mucus
↓
Protein loss
↓
Hyperproteinemia

Cerebriform pattern
↓
Hypertrophied mucosa

- Associated with H. pylon in adults
- Associated with CMS in children
- Increases TGF – α
- Treatment: - Conservative treatment -total gastrectomy

TUTORIALS
LOGIN FOR SUCCESS

AfraTafreeh.com

WILKIE'S DISEASE 00:27:19

- Also known as SMA syndrome

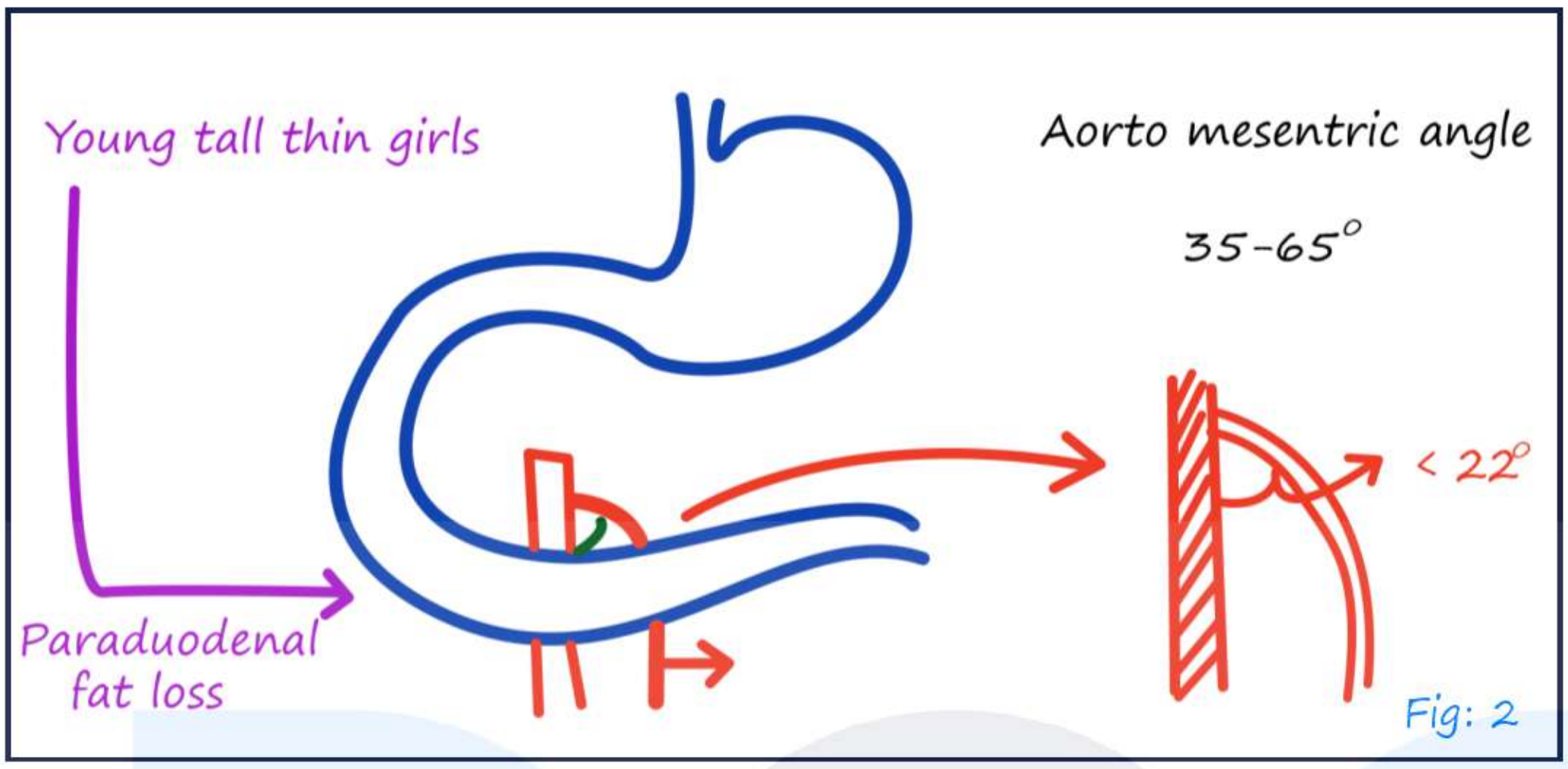

Fig: 2

Etiology:

Sudden weight loss – loss of peri-duodenal fat – compression of SMA on duodenum

Application of tight casts (spine Immobilization cast)

Chronic immobilization +

- C/F: - GOO
- Treatment: - →Body weight – conservative treatment.

LOGIN FOR SUCCESS

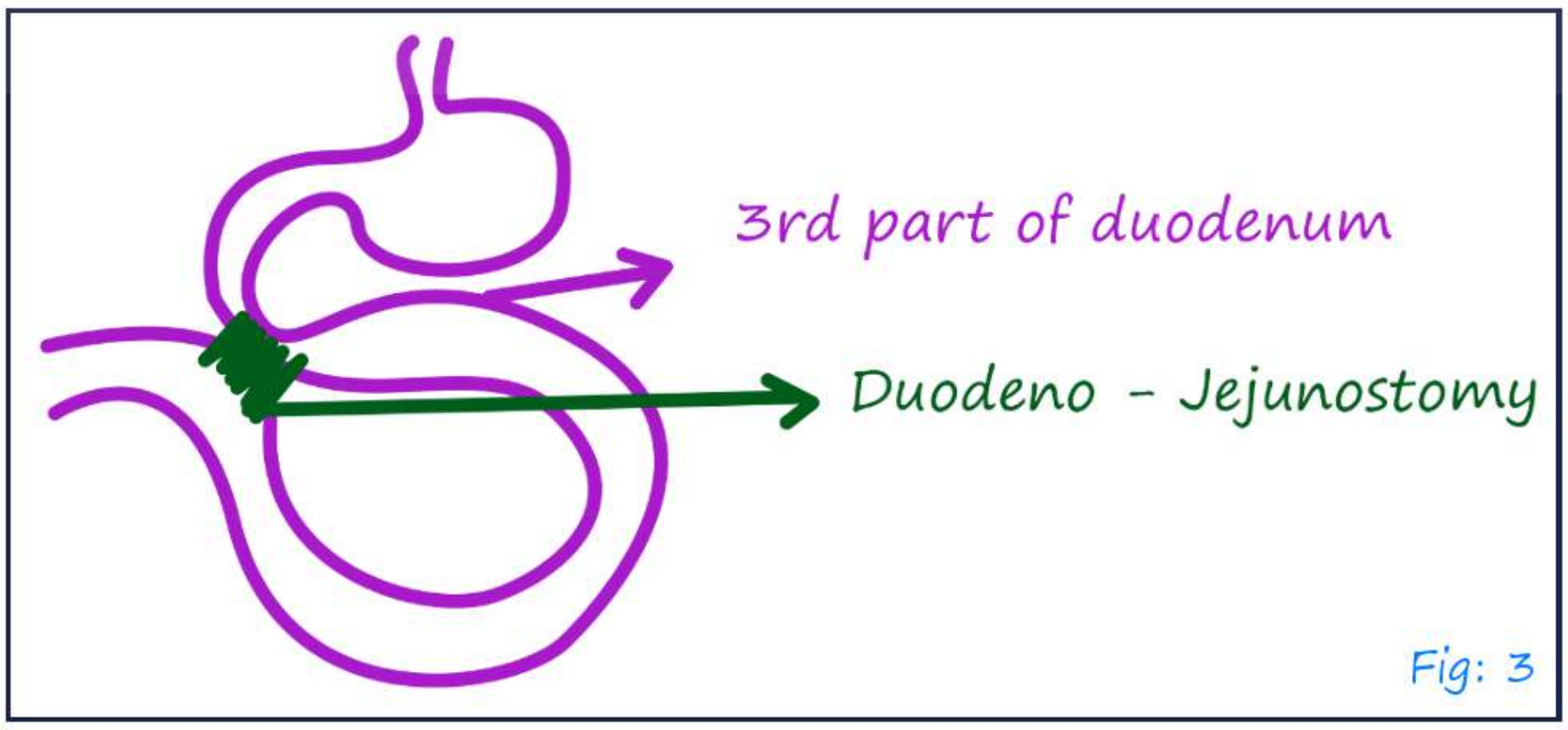

Fig: 3

- Latest: - STRONG PROCEDURE

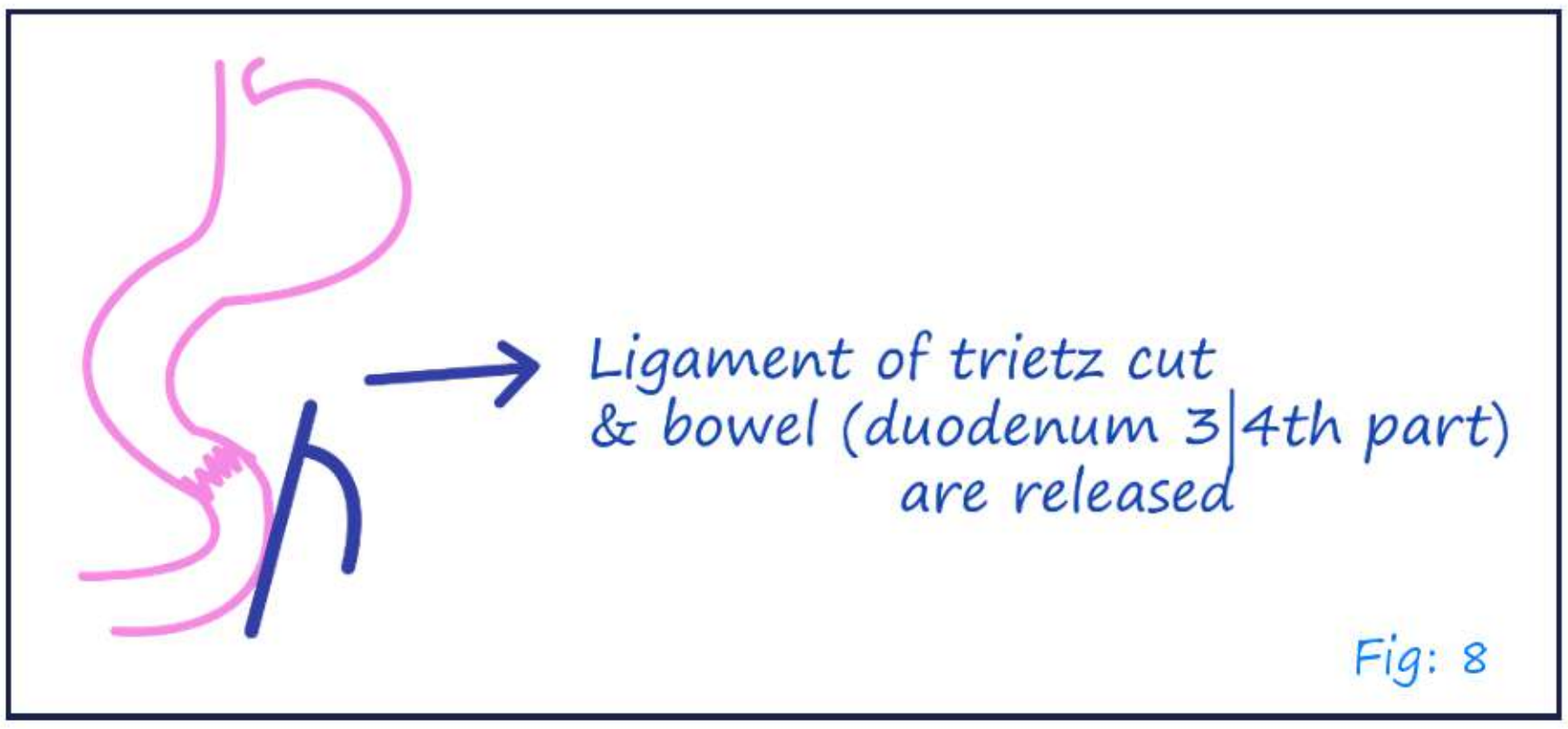

Fig: 8

AfraTafreeh.com
TUTORIALS
LOGIN FOR SUCCESS

AfraTafreeh.com

UPPER G.I BLEED PROTOCOL

Introduction 00:00:17

- Upper G.I bleed happens from esophagus up to DJ flexure.

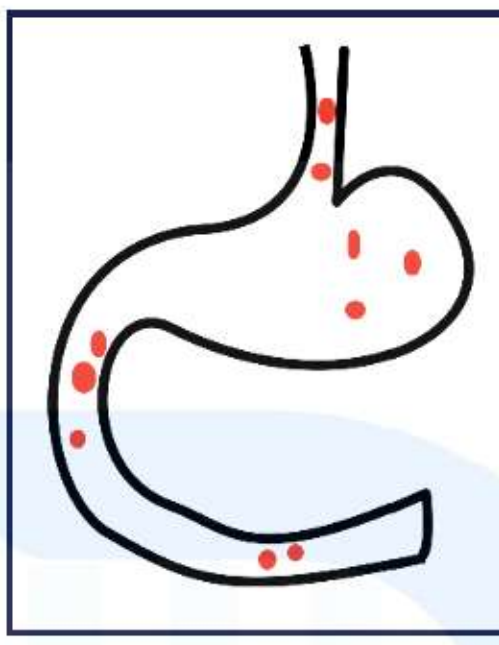

Fig: 1

- If Upper GI bleed is <60 ml → melena
  - > 60ml → Hematochezia
  - Hematemesis

Causes 00:01:40

Causes

Non variceal 80%
↓
- Duodenal ulcer & duodenitis/60% → most common cause (overall)
- Gastritis
- Mallory Weiss tear
- GIST, Lymphoma, Carcinoma
- AV malformation

Variceal (portal HTN 20%)
↓
- Most common – Esophageal varices
- Gastric varices
- Portal Hypertensive gastropathy

Clinical Scenario 00:04:13

- Hematemesis → IV line

  1st drug – PPI (omeprazole inj.)

  Ryles tube decompression (to prevent aspiration)

  Blood transfusion if available

  ↓

  IOC: - Upper GI scopy

  ↓

  Medical Gastroenterologist

  ↙

  Duodenal ulcer

  ↓

  Inj. Epinephrine

  Coagulation

  Clipping

Forrest Classification

↓

I – Active Bleeding ulcer ⎤
IIa – Visible vessel ⎦ Endoscopy

b – Clot

C – Dot

III – Headed ulcer

AfraTafreeh.com

Scoring Systems 00:08:25

Scoring systems

Blatchford score

(screening score)

↓

- BUN
- Hb%
- PR
- BP
- C/F – Melena
  Syncope
  Liver dysfunction
  Cardiac dysfunction
- No endoscopy

Rockall score

(Management score)

↓

- Age
- Comorbidities
- Magnitude of blood loss (BP/PR)
- Transfusion requirement
- Endoscopy findings included
- Stigmata of recent bleed included

TUTORIALS LOGIN FOR SUCCESS

AfraTafreeh.com

Management 00:11:45

Based on Etiology

- Duodenal ulcer bleeding: – Endotherapy (TOC)

  ↓

  Surgery indications

  ↓

  - ≥ 6 units transfused
  - ≥ 3 units/day
  - > 2 times failed endoscopy
  - Rare blood group
  - Hemodynamic unstable

    ↓

    Duodenotomy

    ↓

    Horizontal

    (3 point 'u' structure)
  - Stable: – Truncal vagotomy with pyloroplasty

- Gastric Ulcer bleeding
  - Unstable → Over siew the ulcer
  - Stable → Distal gastrectomy

- Mallory Weiss tear
  - 90% stops
  - 10% Endoscopic coagulation

TUTORIALS
LOGIN FOR SUCCESS

- Dieulafoy's lesion: – Endoscopic clipping → angioembolization → Surgical suturing
- Tumor bleeding – operable – resect

  inoperable – Ca stomach

  ↓

  LGA embolization

  Cryotherapy

  LGA ligation

  Palliative resection
- Variceal bleed: – Gold standard

  ↓

  EV: – Endoscopic banding

  GV: – Endoscopic glue (cyanoacrylate glue)

AfraTafreeh.com
TUTORIALS
LOGIN FOR SUCCESS

AfraTafreeh.com

INTRODUCTION TO INTESTINE

Small Bowel 00:00:34

Small bowel length -6cm 	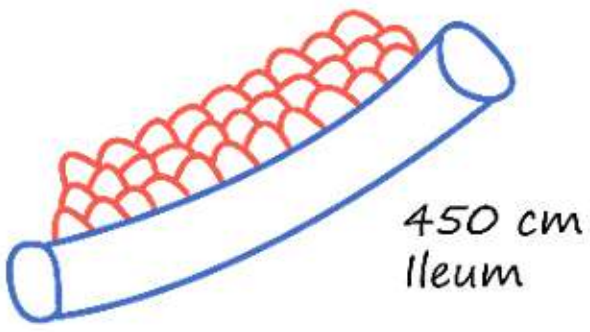
long and few vascular arcades	Short and many vascular
Mucosal folds in jejunum ↓ Valvulae conniventes (or) kerckring valve → x-ray	Feature less – X-ray
Wide diameter	Narrow diameter

Entire small bowel is supplied by superior mesenteric artery

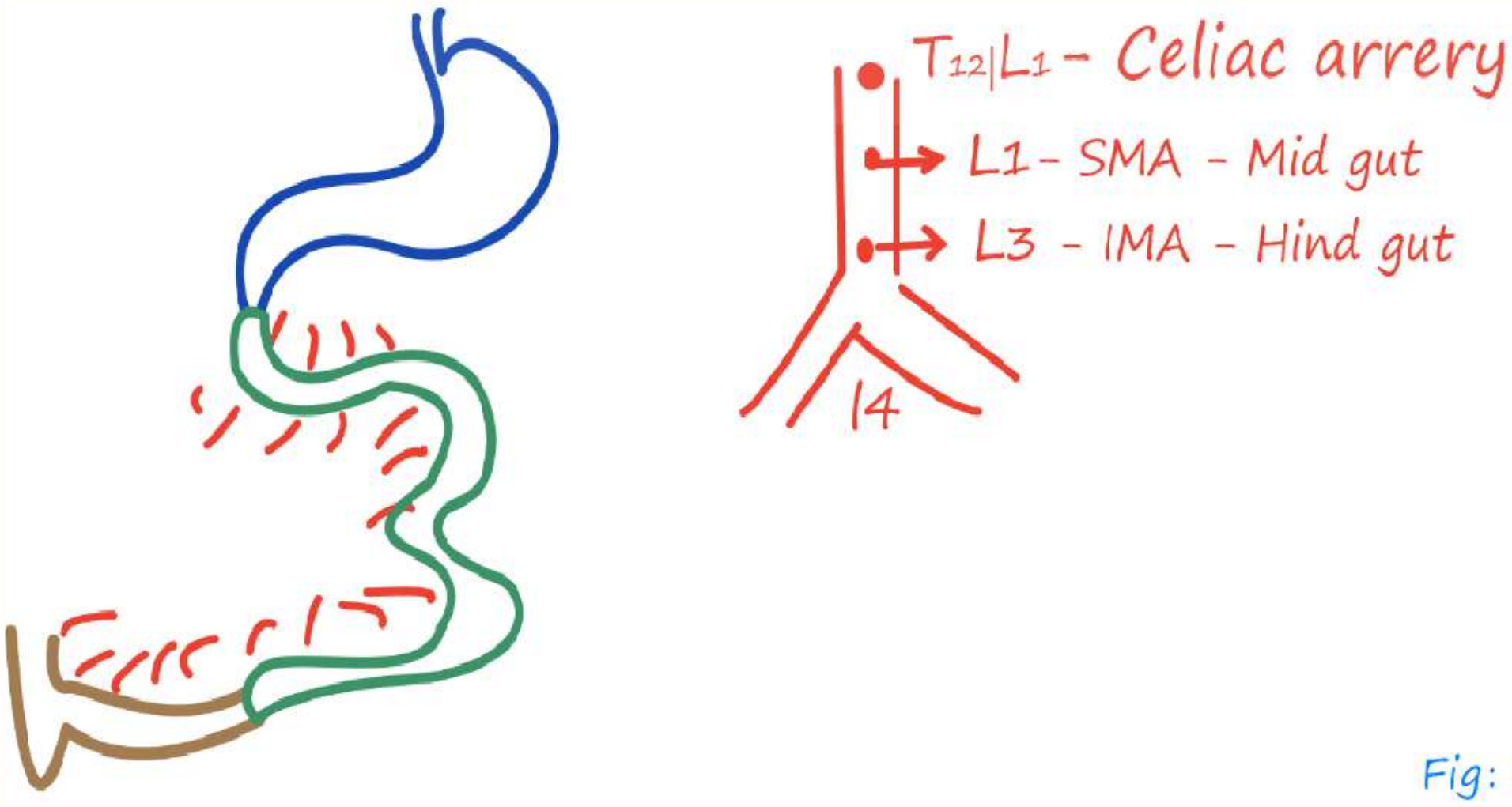

Fig: 1

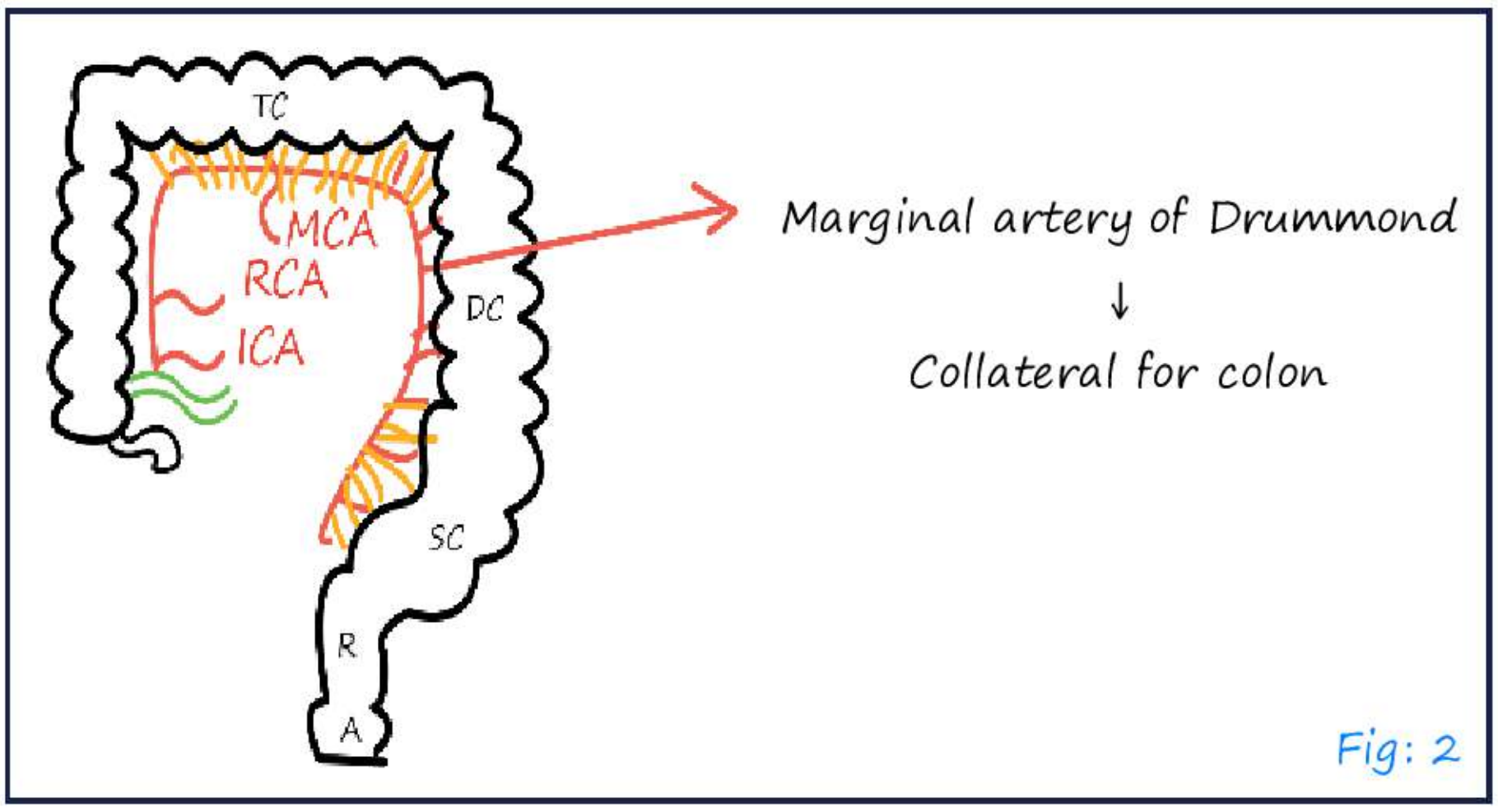

Fig: 2

- Sigmoid colon and Transverse colon are mobile as they have mesocolon.
- SMA – 3 branches → MCA
  RCA
  ICA
- IMA – 2 Branches → LCA
  Sigmoid artery

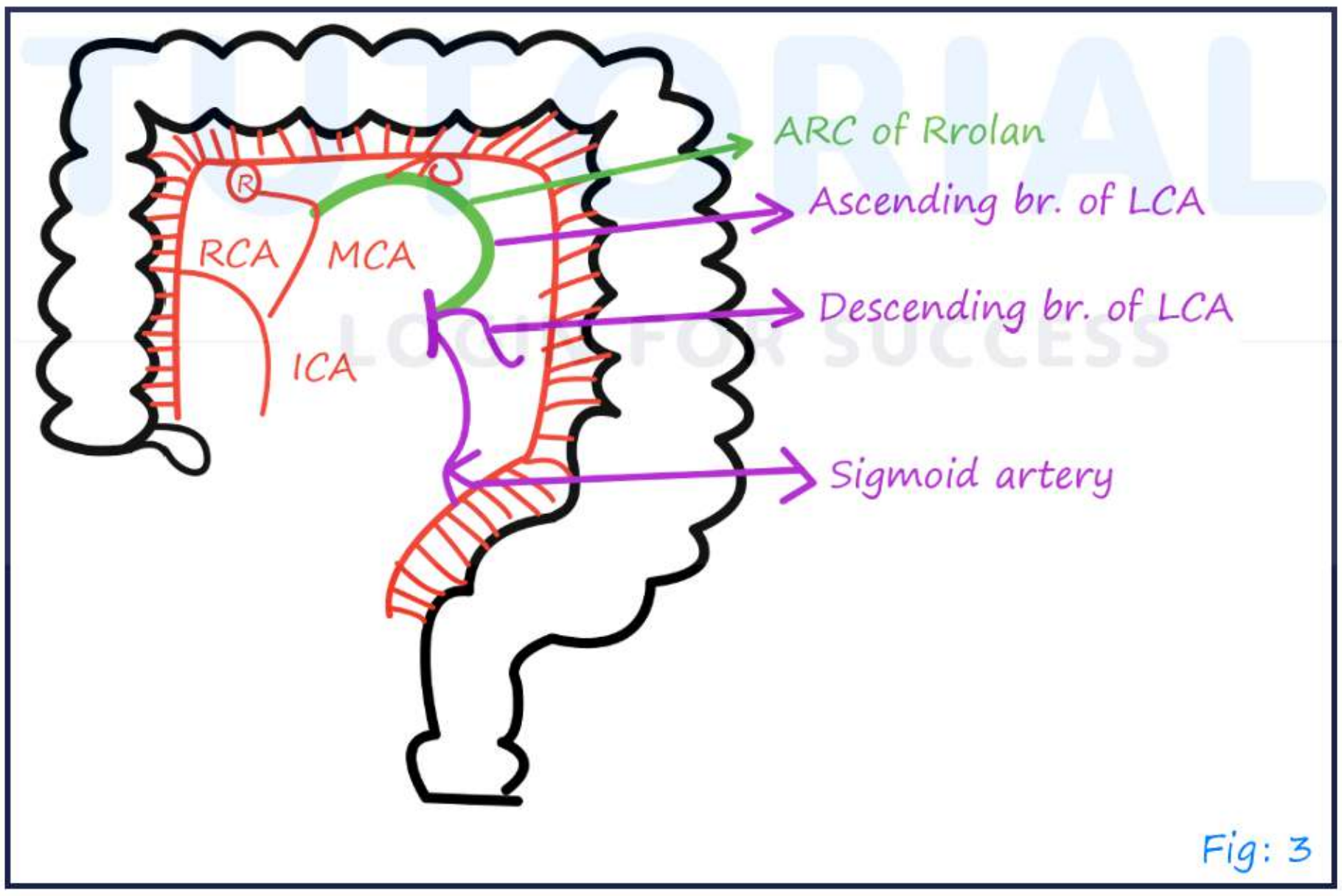

Fig: 3

- Q Arc of RIOLAN is a communication between L br. Of MCA and A br of LCA
- Collaterals: – 1. Marginal artery of Drummond
  2. arc of riolan

AfraTafreeh.com

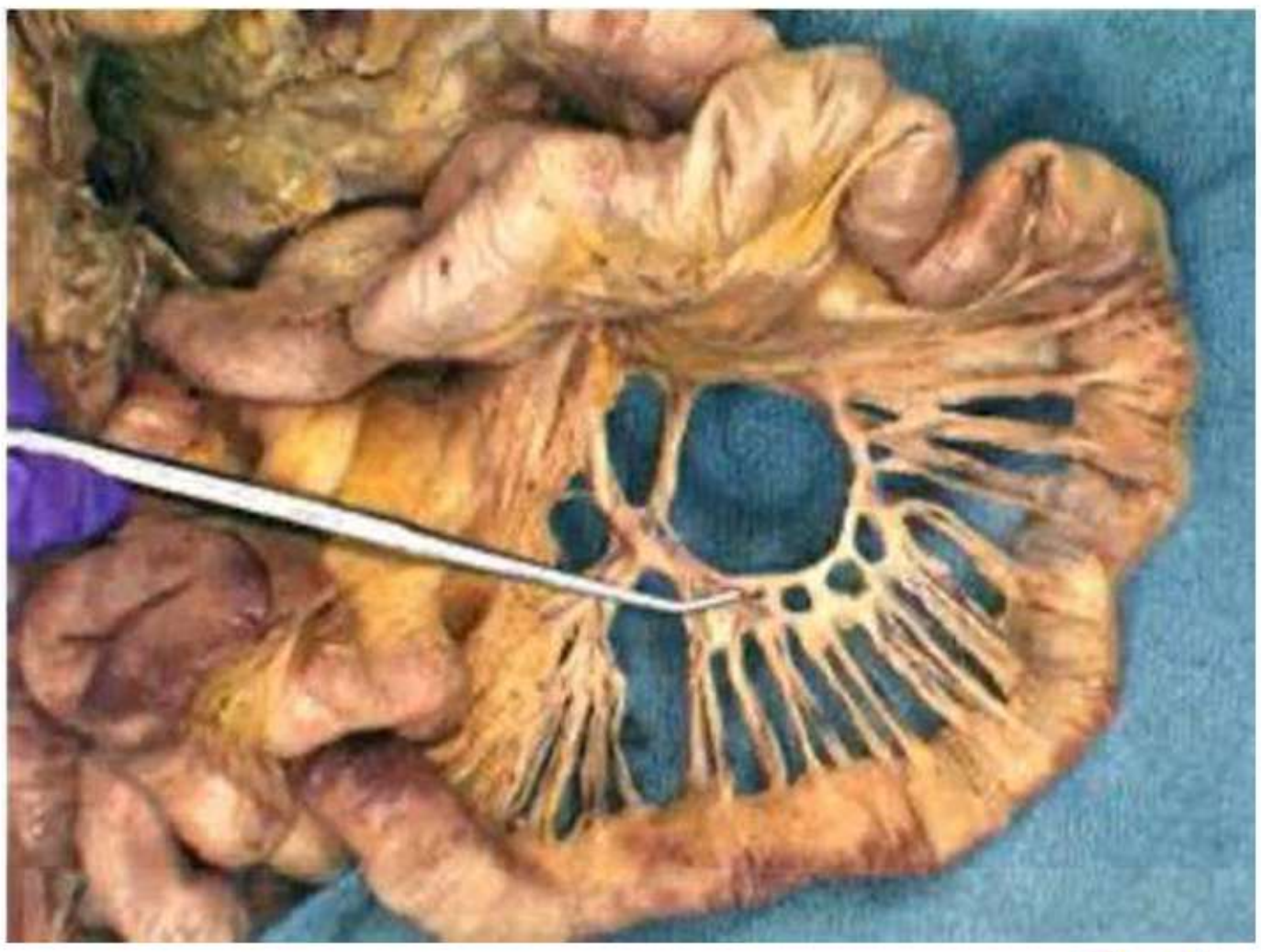

Fig: 4

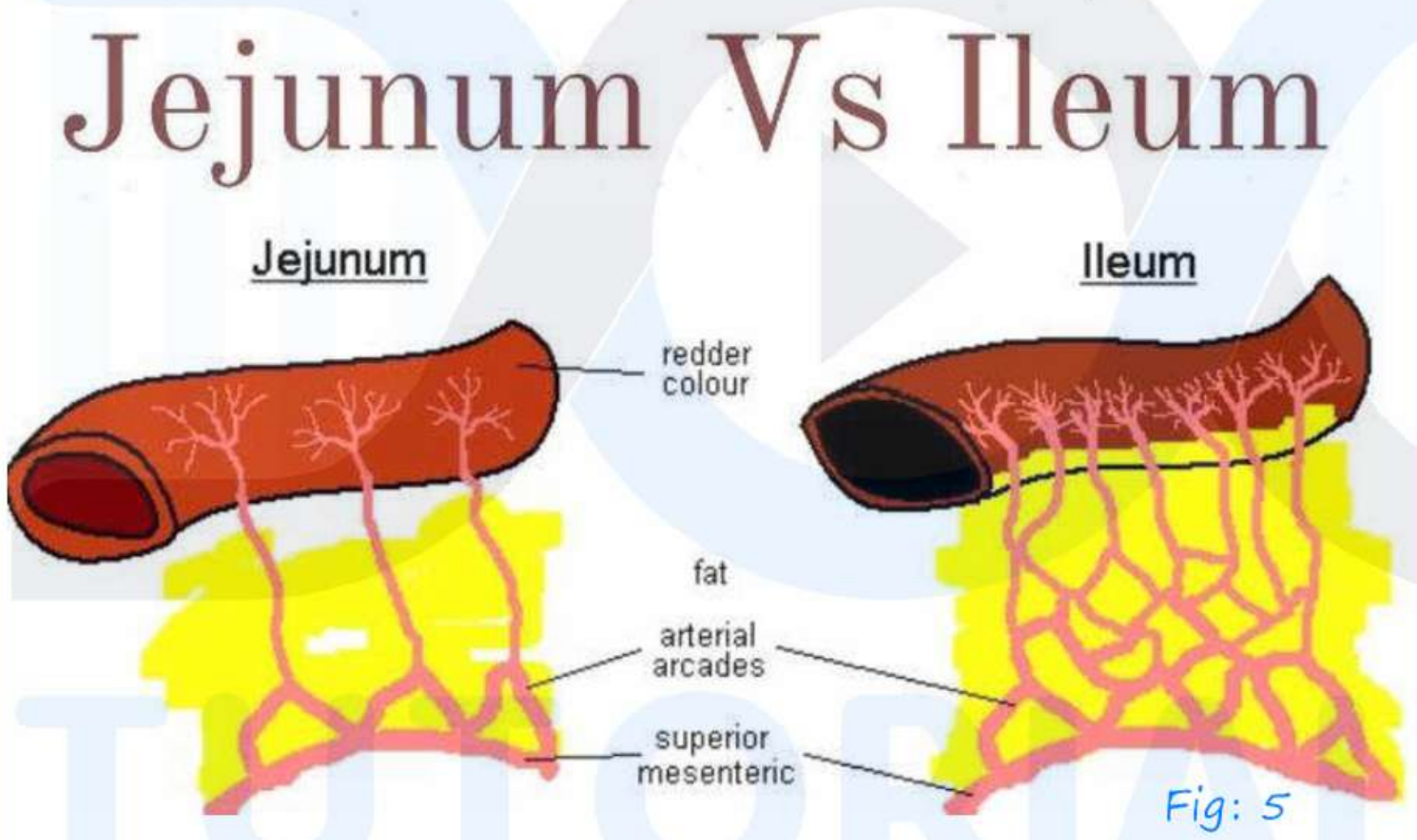

Fig: 5

LOGIN FOR SUCCESS

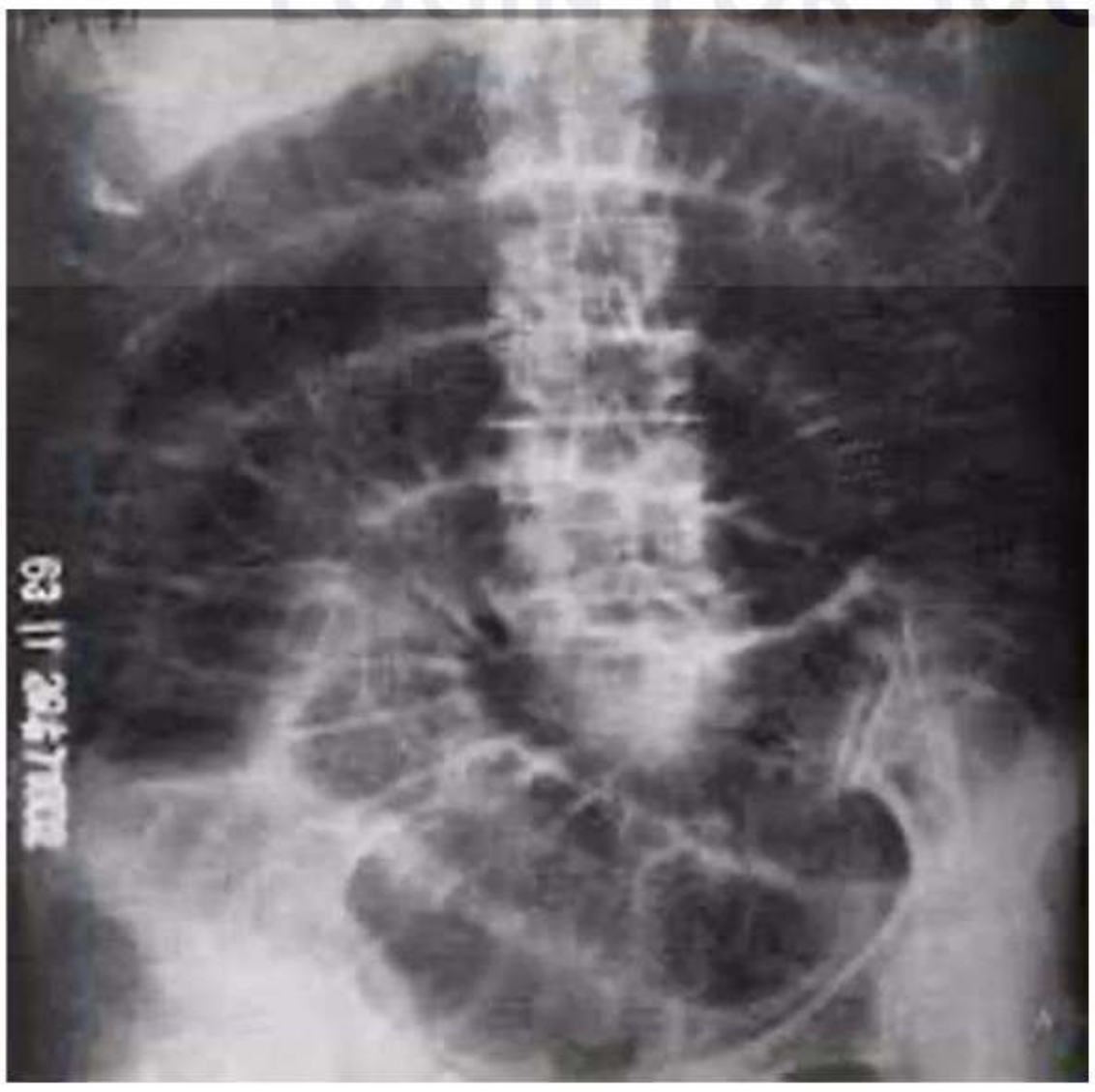

Valves of Kerckring

Fig: 6

Colon Haustrations Fig: 7

Barium image 00:11:59

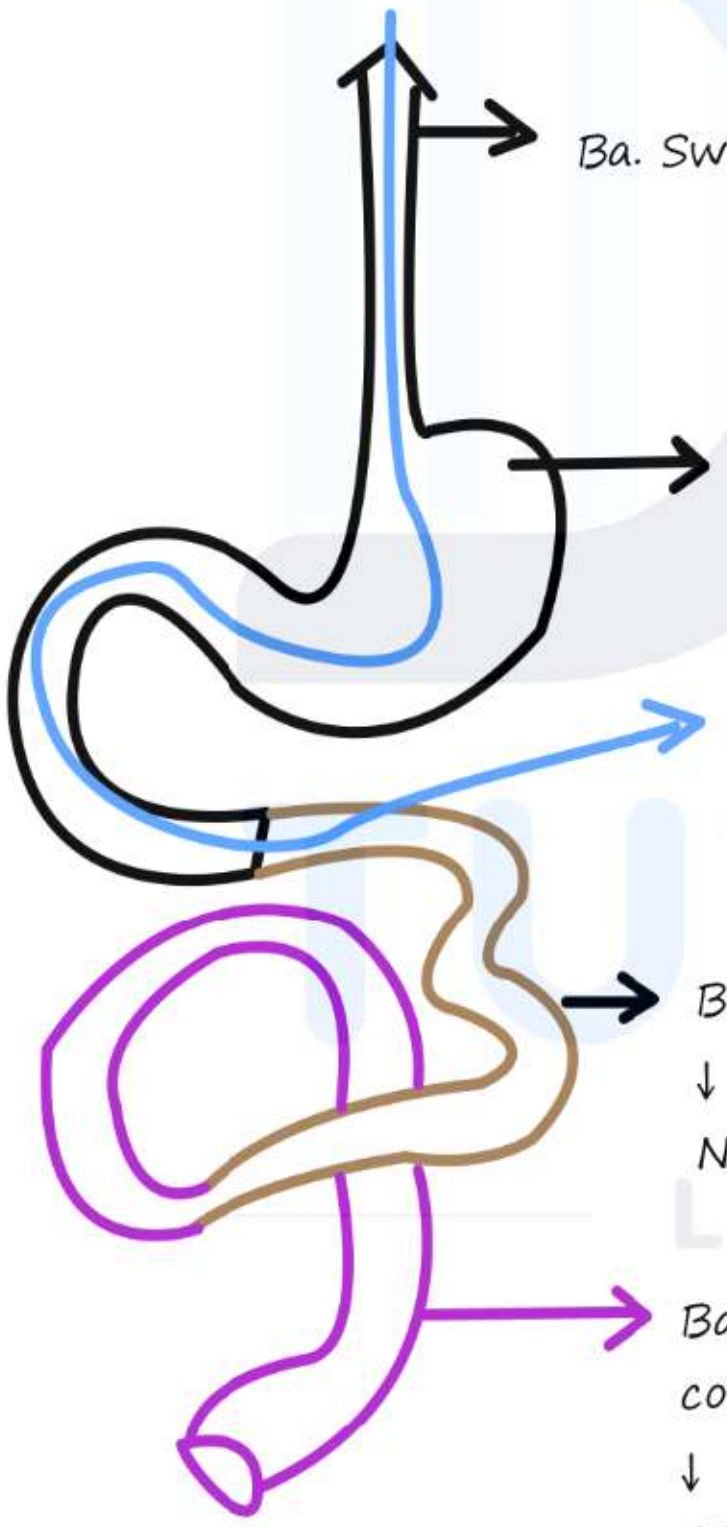

Ba. Swallow: - esophagus

Ba. meal: - stomach/Duodenum

NG tube passed – contrast used
↓
Gastrograffin

(Small bowel enema)
entero-clysis – **invasive**
(Gold standard)

Ba. Meal follows through-x-ray taken @ 2,4,6,8 hours
↓
Noninvasive, time taking images not clear

Ba. Enema → now a days double contrast Ba. Enema used
↓
AIR or CO2

AfraTafreeh.com
DOCTUTORIALS LOGIN FOR SUCCESS

Small bowel enema

- Invasive (NJ tube)

  ↓

  Radiologist

  MGE

AfraTafreeh.com

↓

Immediately image

↓

Gold standard IOC for small bowel

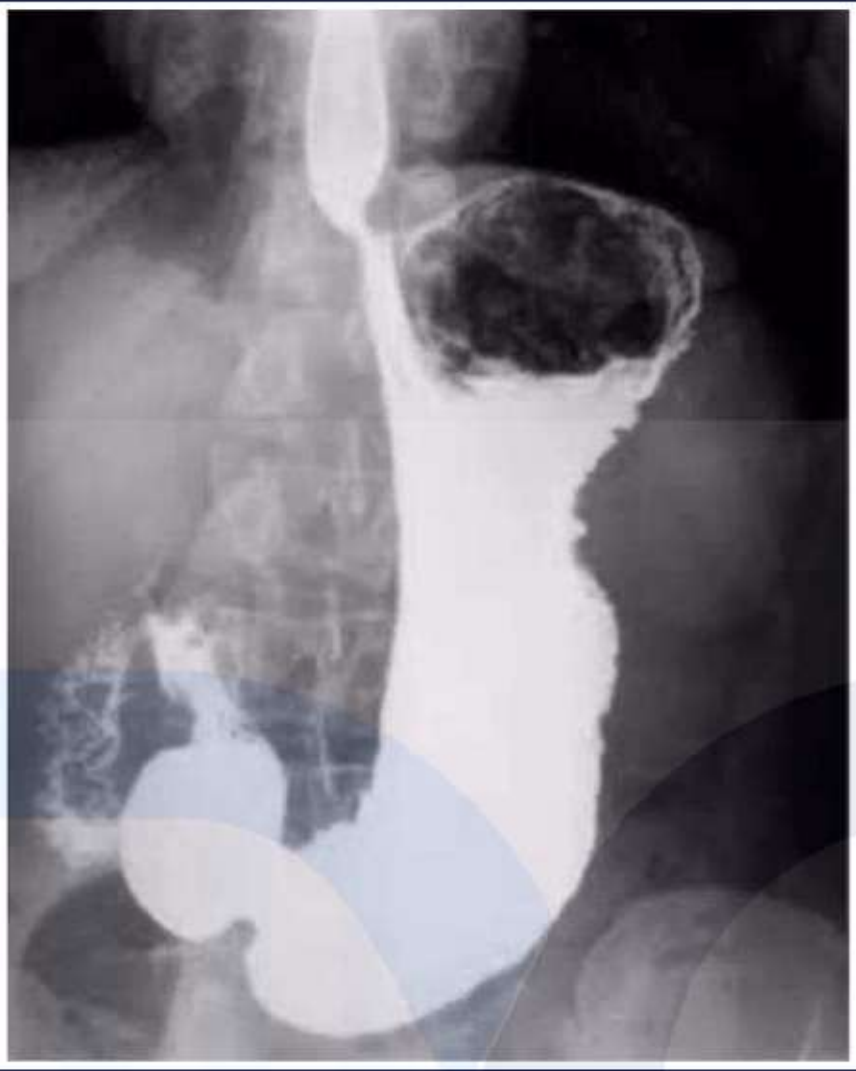

Fig: 8

Image showing duodenal cap and stomach (X-ray barium meal)

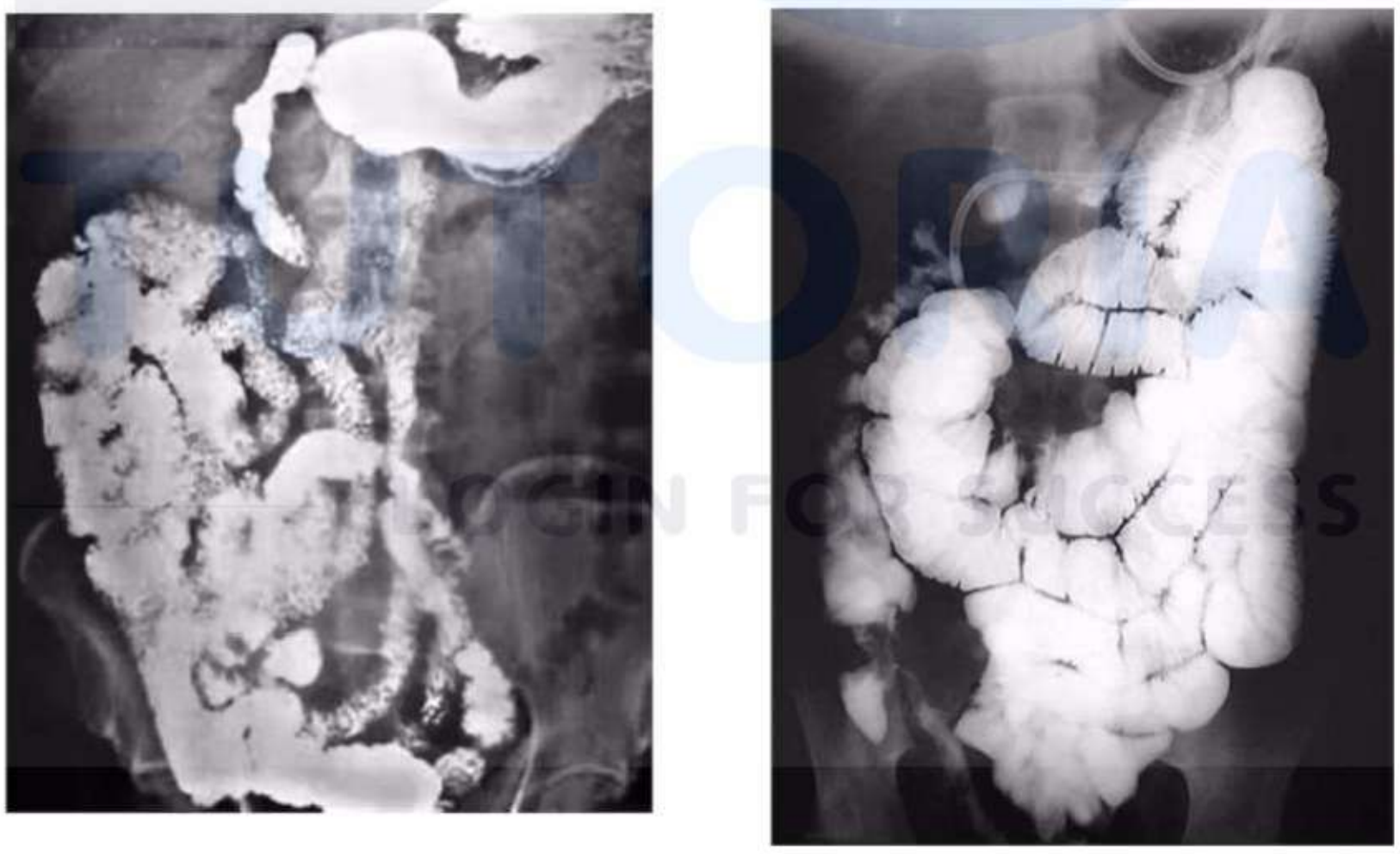

Fig: 9

X-ray entero-clysis showing bird feather and valve of kercking of jejunum and featureless ileum

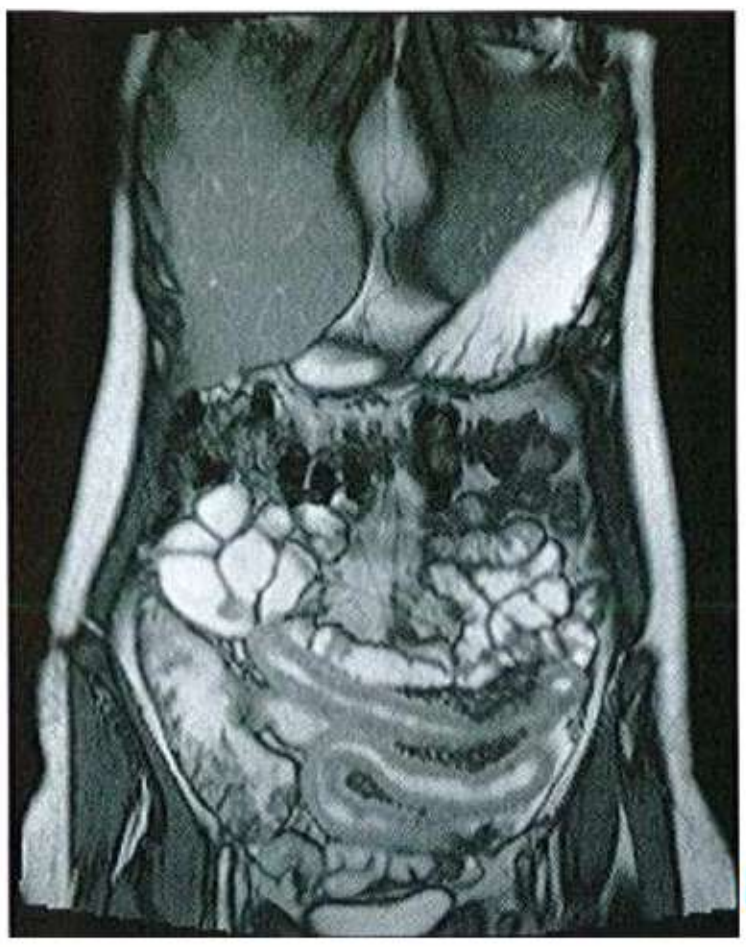

Fig: 10

MR enteroclysis showing crohn's disease

Barium Enema findings

→ Claw sign/pincer sign → intussusception

→ Question mark colon → Hirschsprung d/s total Aganglionosis type

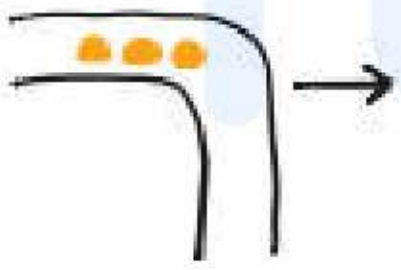

→ Thumb print → Ischemic colitis

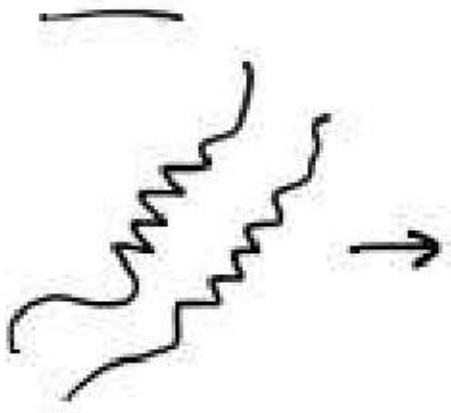

→ Saw tooth appearance → diverticulosis

Horse pipe appearance – CD

AfraTafreen.com
DOC TUTORIALS
LOGIN FOR SUCCESS

AfraTafreeh.com

Ace of spade → sigmoid volvulus
(Birds beak)

Apple core appearance – ca colon

French hat - polyp

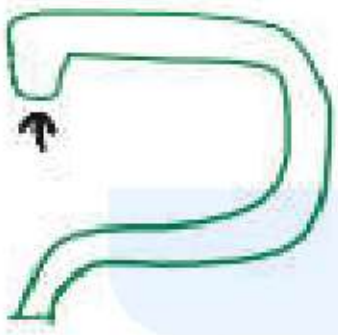

→ Pulled up caecum - TB



Lead pipe appearance: - UC
(Pipe stem)
↓
Loss of haustration

Thumb Print Fig: 11

Capsule endoscopy

- New investigation
- Capsule is 26 mm long
  11 mm broad

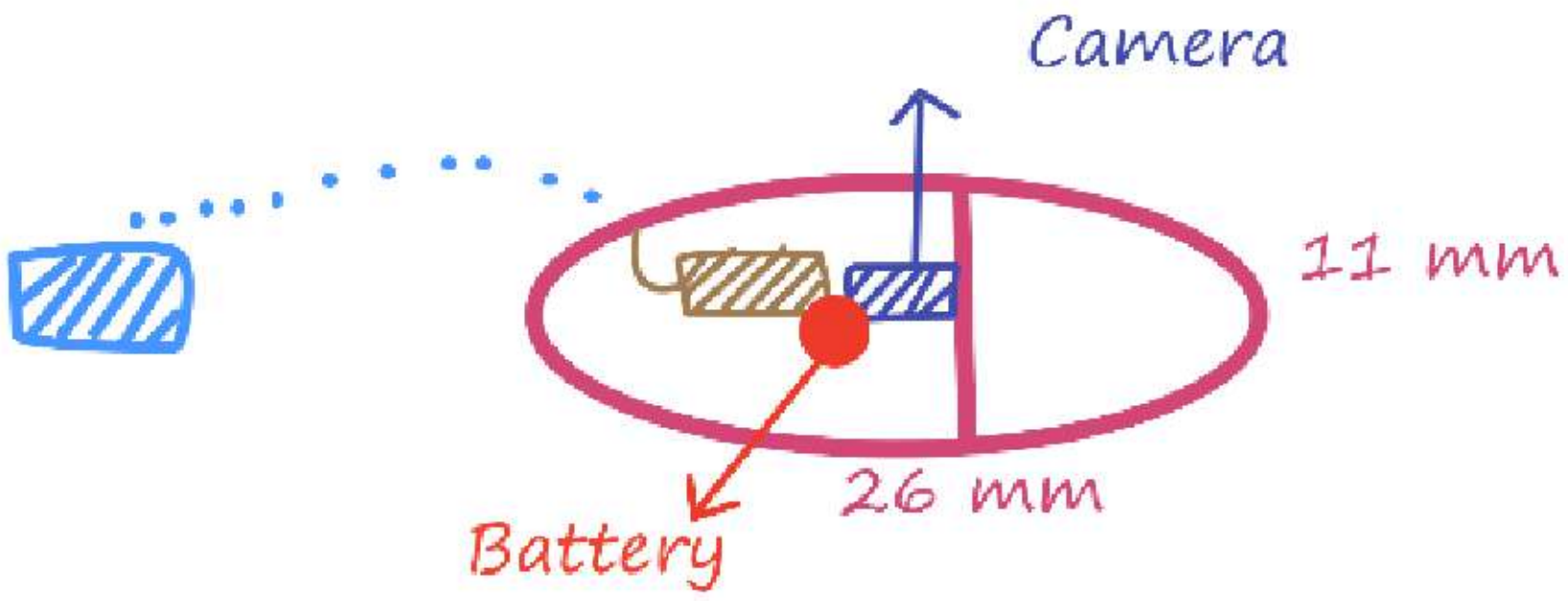

- Capsule is having a camera, battery, processor, light source → 8hours
  →2 images/sec – 50000 images
  ↓
  2 hours to study the image.
- Patient comes in empty stomach → swallow the capsule
  - No sedation needed
  - Capsule moves by peristalsis
  - Start liquid diet → 24-48 hours → stools → processor.

AfraTafreeh.com

Indications

- Small bowel crohn's d/s – IOC
- Small bowel bleeding – IOC
- Small bowel polyps – IOC
- Angiodysplasia

Contraindications:

- Small bowel obstruction
- Small bowel stricture
- Gastroparesis → get help of upper GI scopy
- Unable to swallow

AfraTafreeh.com

Limitation

- Incomplete study
- Locate the lesion is difficult
- Biopsy cannot be taken

Complications

- Retention (13%) → most common crohn's stricture

↓

To prevent – dummy capsule

↓

Not excreted in 48 hours → C/I

Double balloon endoscopy – small bowel (enteroscopy) – 240cm-360cm.

Conventional colonoscopy	Virtual colonoscopy
160 cm → invasive	3D CT/MRI – Non invasive
0.5% risk of perforation (sigmoid)	No risk of perforation
Time taking	Short time
Discomfort	No discomfort
Miss small lesions	Small lesions can be identified
Biopsy is possible	Extraluminal pathology can be found.

TUTORIALS
LOGIN FOR SUCCESS

VASCULAR DISEASE OF BOWEL

Introduction 00:00:06

Introduction

- Mesenteric ischemia
- Lower GI bleeding

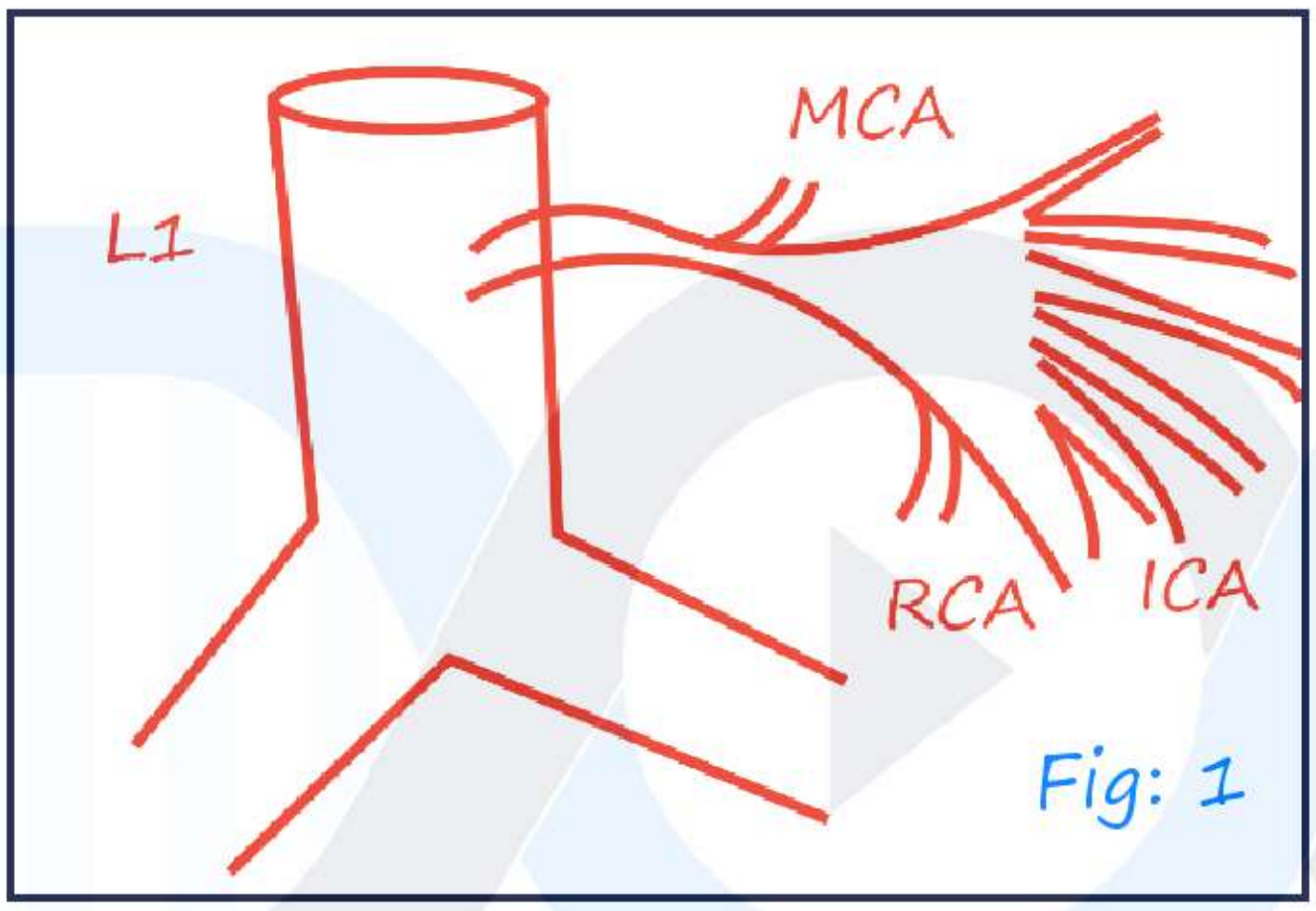

Fig: 1

AfraTafreeh.com

Acute SMA ischemia 00:01:24

Acute SMA ischemia

- Thrombus → Origin of vessels → massive gangrene
- Embolus (most common) → Occludes branch vessels → minimal gangrene

AfraTafreeh.com



→ Sever pain +
O/E – soft, no guarding
↓ next day
→ O/E – Abdominal distended guarding + tenderness lying silent



] signs out of proportion to symptoms

- IOC: Diagnostic laparoscopy
  ↓
  Laparotomy
- Treatment – Resect the gangerous bowel



Fig: 2

- High mortality
- Poor prognosis due to short bowel syndrome

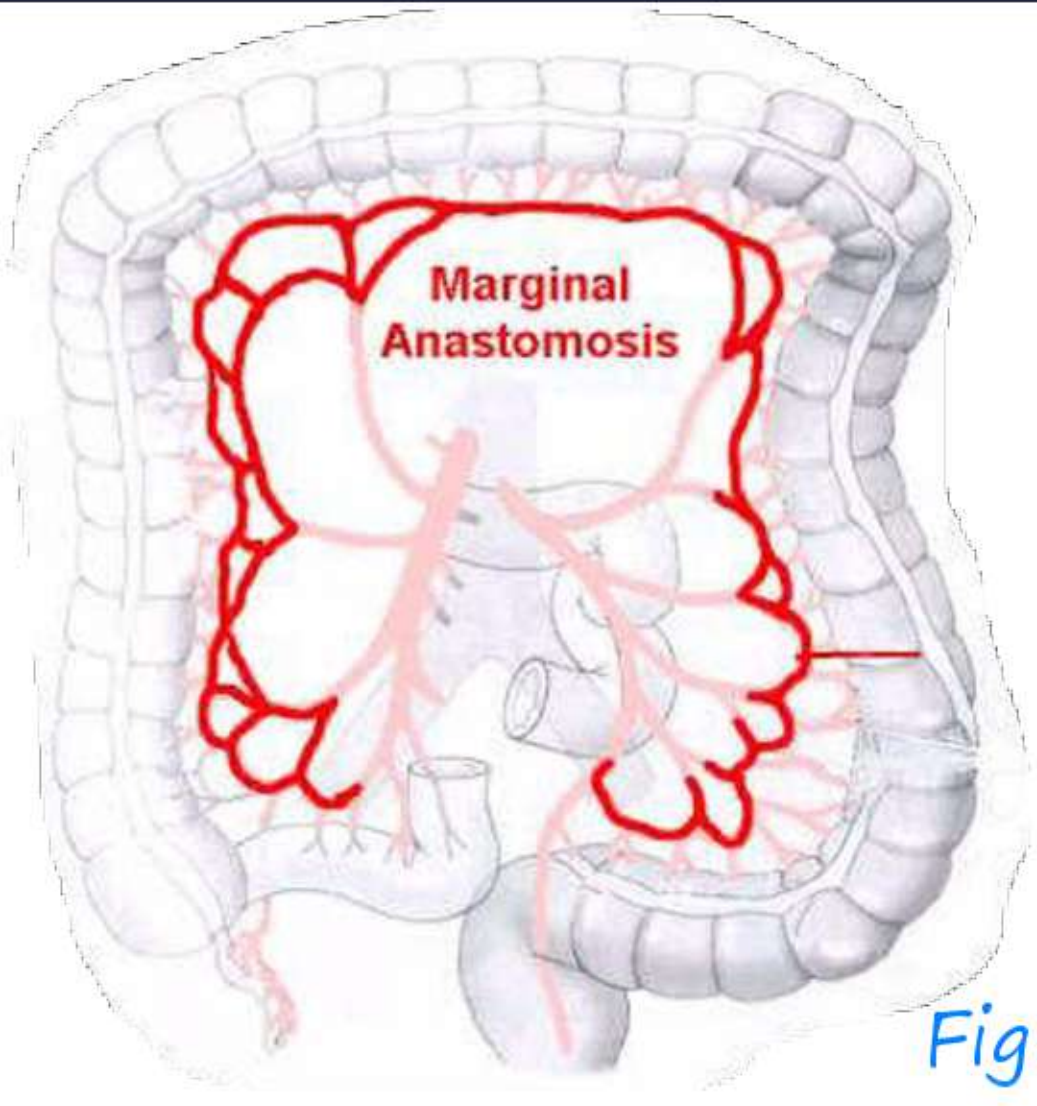

Fig: 3

Chronic SMA ischemia 00:09:12

- Slow forming thrombus


Fig: 4

- Clinical features – Intestinal angia triad

↓

1.pain abdomen after eating

2.Weight loss

3.Chronic SMA thrombus

- IOC – CT angiography
- TOC – Radiologist – angiography

Vascular surgery – Bypass with grafts

AfraTafreeh.com

Mesentric vein thrombosis 00:12:05

- All small venules join together and join into superior mesenteric vein → joins with splenic vein and enters into portal vein.

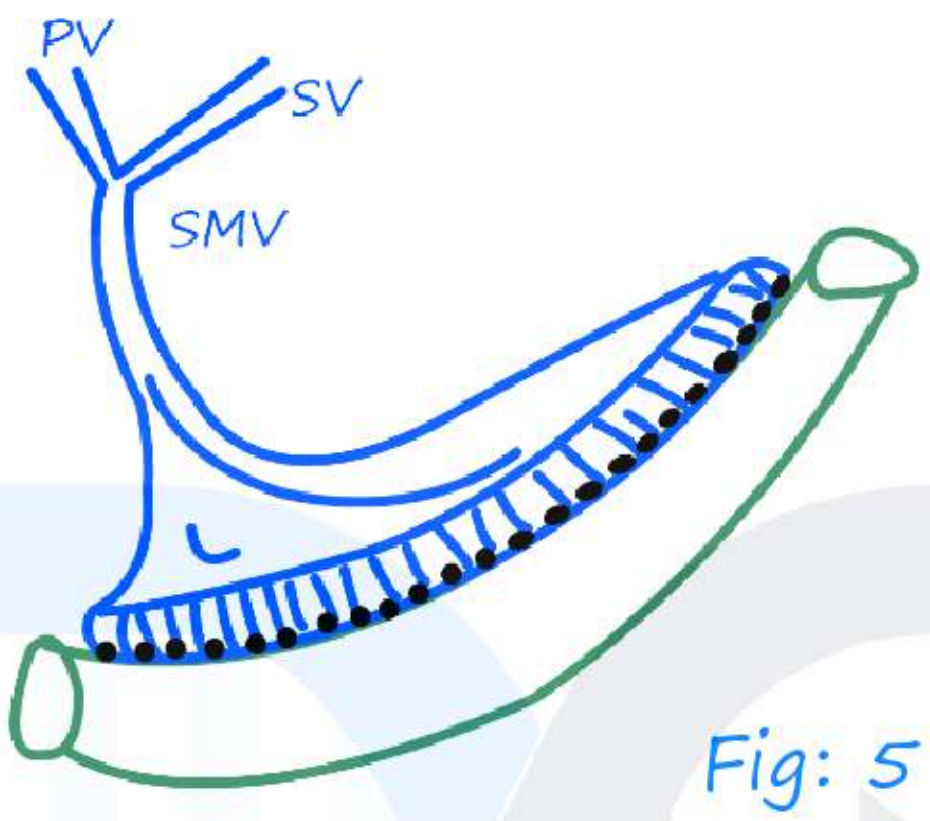

Fig: 5

Causes

- Dehydration
- Diarrhea
- Pregnant
- Protein C/s deficiency
- Hypercoagulability

- Immediately the bowel becomes edematous
  ↓ not treated
  venous gangrene
- IOC: – CT scan abdomen
  Bowel edema
- TOC: – Rehydrate
  Inj. Heparin
- No need of thrombolytic agents

- Surgery indicated if bowel has gone for gangrene

SQUID – Super quantum interference device

↓

Non invasive

↓

Mesenteric ischemia

Bowel gangrene

Lower GI Bleeding 00:16:30

- Bleeding from distal to ligament of trietz

Source- colon/rectum/anus

Massive
- most common
  - diverticulum of colon
- Angio dysplasia
- Ulcerative colitis
- Radiation colitis
- Mesentric ischemia

Minor
- Most common
  - Hemmoroids
- Fissure
- Fistula
- SRUS
- Polyps
- Colon Ca

Small bowel

↓

- most common angiodysplasia (jejunum)
- polyps
- Cancer
- Crohn's disease

Melena Hematochexia

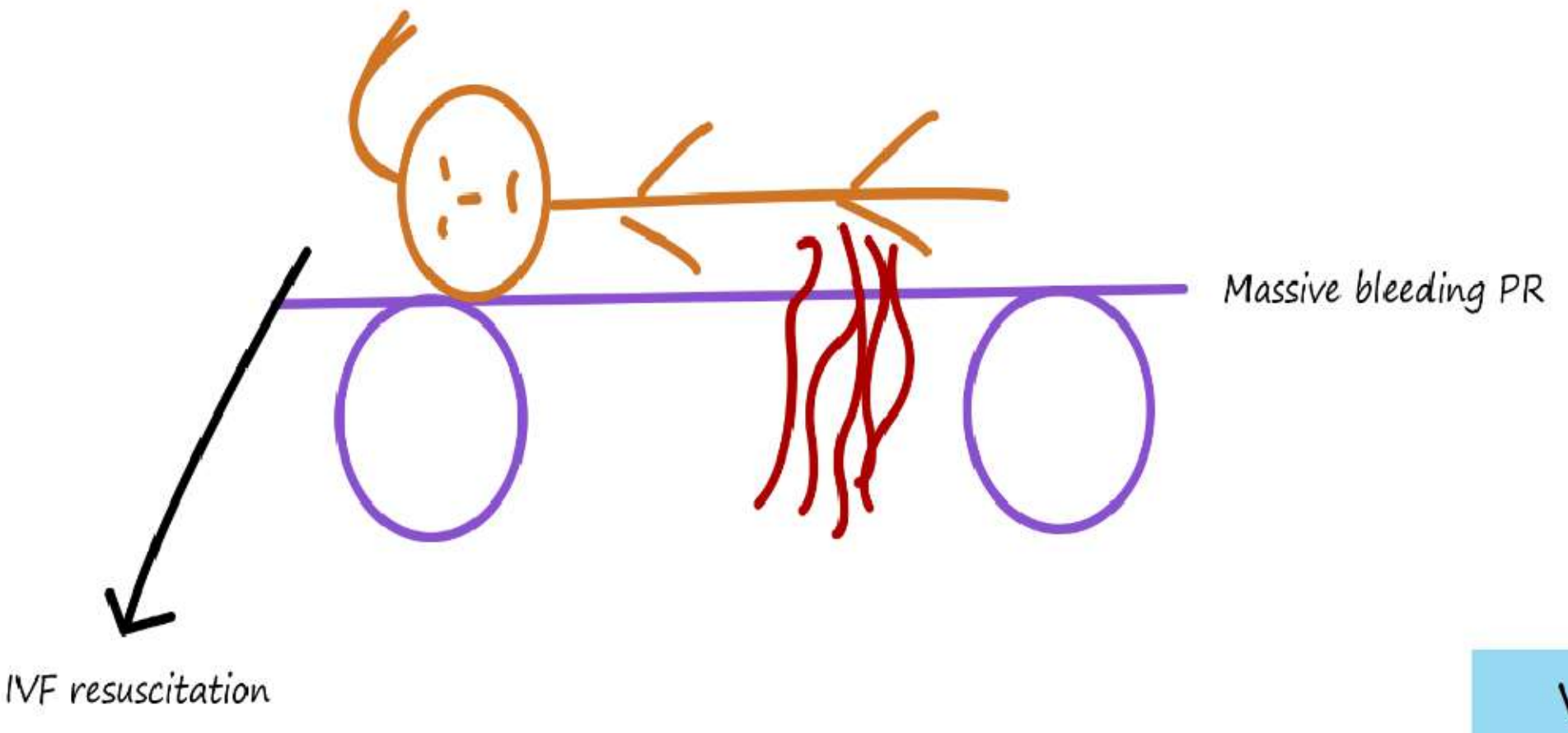

AfraTafreeh.com
TUTORIALS
LOGIN FOR SUCCESS

AfraTafreeh.com

- 1st scopy → proctoscopy/PR

↓

Ryle's tube → Bleeding → Think of upper GI bleed

↓

Bile

↓

Medical gastroenterologist

↓

1st scopy – Upper Gi scopy (upto DJ flexure)

IOC for lower GI bleed → Colonoscopy

↙

N → Obscure GI bleed

- Obscure GI bleed → Bleeding from small bowel

↓

IOC – Capsule endoscopy

Angiodysplasia – Jejunum

↓

N

Active blood ⊕

TC99 RBC pertechnate scan

(0.1 ml/min)

Disadvantage – Not locate the site of bleeding

↓

Selective mesenteric angiogram

↓

0.5 ml/min

↓

locate the lesion

↓

Treat – Angioembolisation

- Blind right hemicotectomy was advised in those days

Angiodysplasia 00:27:51

- most common – Caecum, ascending colon
- 2nd – Rectum

↓

Massive bleeding

↓

stop

↓

colonoscopy – N

- IOC – colonoscopic coagulation
- Troublesome lower G.I bleed seen in angiodysplasia of colon

Heydes Syndrome 00:29:31

- Type II VWD associated with angiodysplasia + valvular aortic stenosis

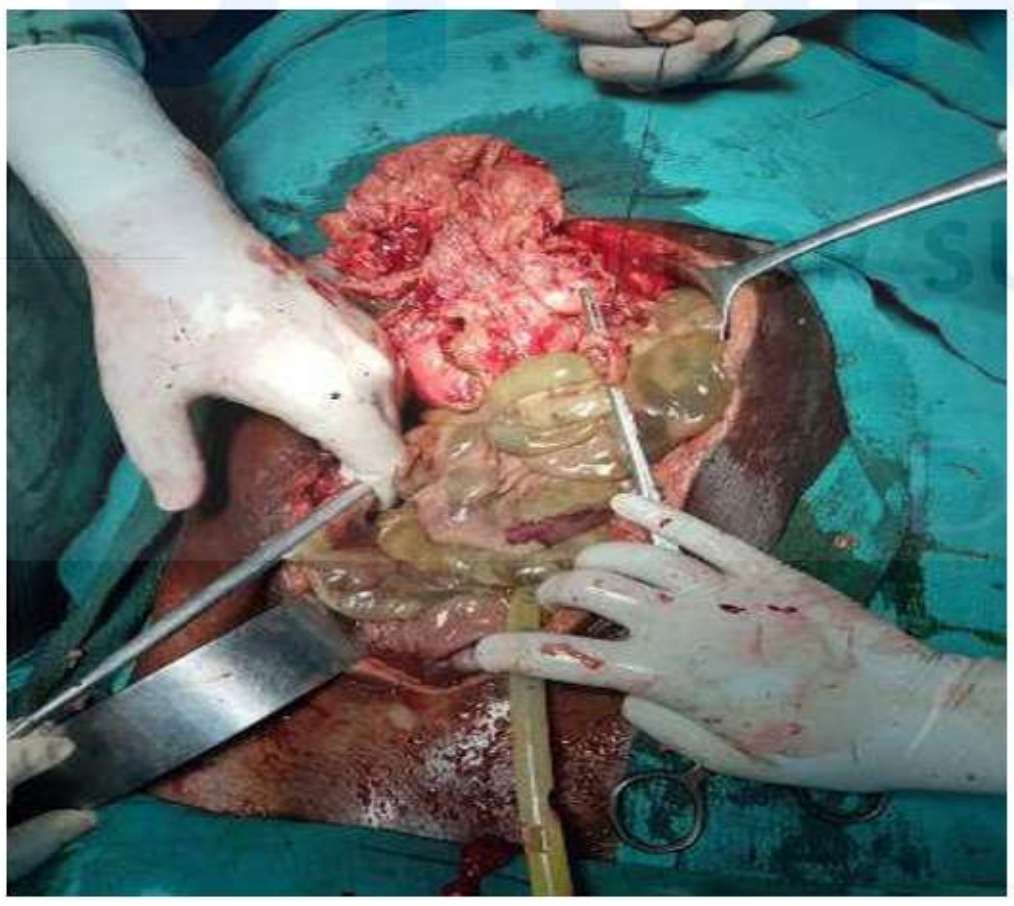

Fig: 6

AfraTafreeh.com

Ischemia of Colon

Partial colonic
↓
mucosa,
submucosa only

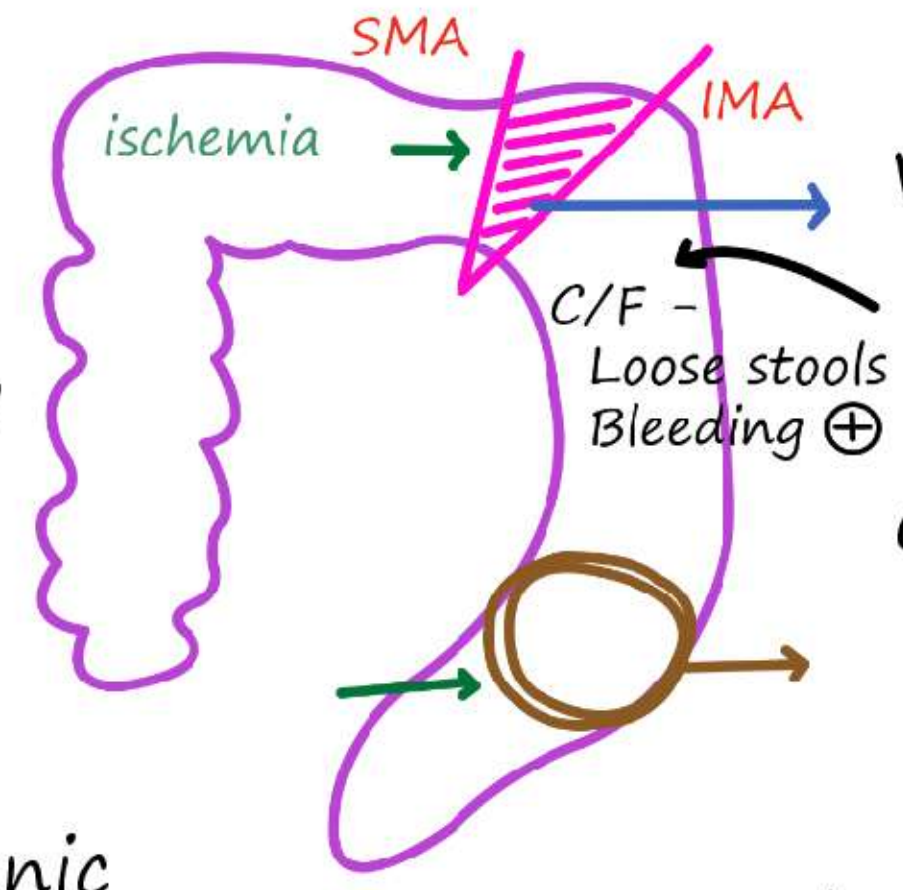

Watershed area

ischemic colitis
↓
GRIFFITH point
↓
Thumb point

Total colonic
ischemia
↓
Full thickness

Ischemic strictures
most common-
sigmoid colon
↓
Sunsek's point

Clinical features –
Intestinal obstruction

TUTORIALS
LOGIN FOR SUCCESS

DIVERTICULUM

Diverticulum

- Congenital
  - (m/c) → 2% Meckel's Diverticulum
  - → Only true Diverticulum
  - → Seen an antimesentric Border



  - → Excise – Incidental

- Acquired
  - Small Bowel → m/c Duodenum
  - Large bowel → m/c- sigmoid colon (m/c)
  - → False diverticulum
  - → Mesenteric border

  - Incidental-Do not resect

AfraTafreen.com

Meckel's Diverticulum 00:03:38

- Persistence of proximal vitello-intestinal duct

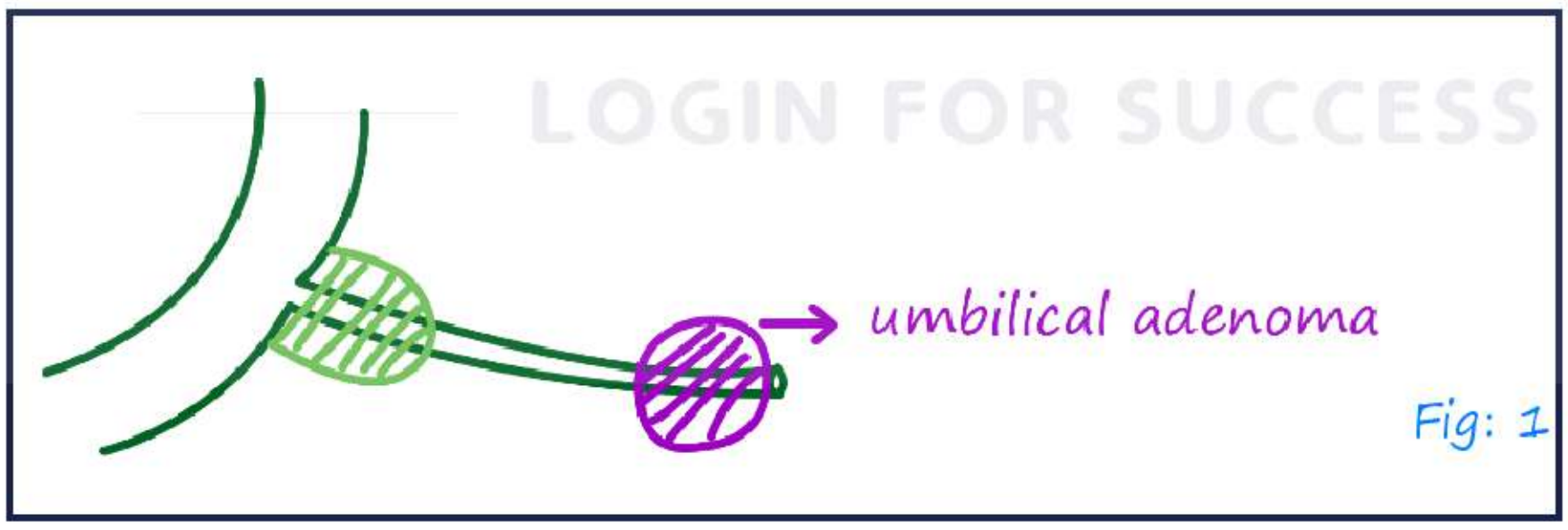

Fig: 1

- Persistence of distal vitello-intestinal duct-umbilical adenoma (Raspberry tumor)
- If the vitelline duct is fully persistent

↓

Feculent discharge

DOC TUTORIALS LOGIN FOR SUCCESS

AfraTafreeh.com

- Allantoic duct remnant ⟶ Urachus
  ↓
  Persistent ⟶ urinary discharge

Rule of 2 (Adults)

- < 2%
- < 2 inch in length (5cm)
- < 2 feet proximal to IC Junction

Children
↓
Ectopic gastric mucosa
↓
- Pancreatic
- Brunner's
- Colonic mucosa

↓
Infected with H. pylori
↓
peptic ulcer
↓
Bleeding
(most common presentation)
(overall)

Adults
↓
Disappears
↓
No bleeding
↓
most common obstruction
↓
- Kinking
- Diverticulitis
- Intussusception

- IOC in adults
  ↓
  Enteroclysis
- TOC – Wedge resection

pre-op investigation

TC^{99M} pertechnate scan children
– IOC
↓
Inj. cimetidine
Inj. Glucagon
TOC – Resection and anastomosis

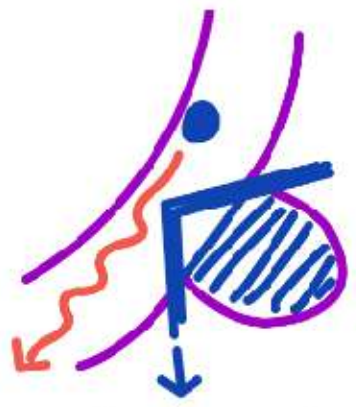

Wedge resection

- Complications
  1. Bleeding (most common)
  2. Obstruction – kinking intussuception
  3. Diverticulitis
  4. Hernia – Littre's (Amyand – Appendix)
  5. Most common tumor – carcinoid

↓

SABISTON – 20th ed, incidentally – resect the MD

27th Edition Bailey

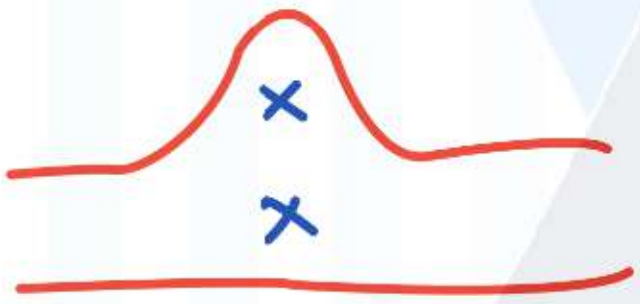

Short/wide based no nodularity → leave



Narrow nodularity (+)
↓
Resect

AfraTafreeh.com
TUTORIALS
LOGIN FOR SUCCESS

AfraTafreeh.com

Acquired Diverticulum 00:16:46

Small bowel

Most common duodenum



- Most common – periampullary region
- Clinical features – most common: bleeding, pancreatitis/cholangitis

Jejunum



multiple big size

Most common – Diverticulitis

Blind Loop syndrome

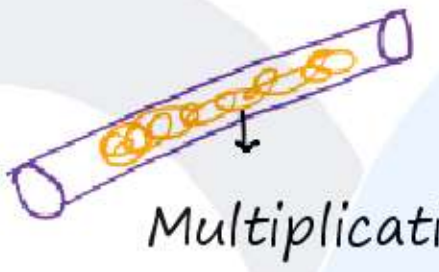

Multiplication +++ bacteria (Bacterial overgrowth syndrome)

↓

B_{12} deficiency malabsorption

↓

Schilling test positive

Inj. B_{12}

TOC: Antibiotics

TUTORIALS
LOGIN FOR SUCCESS

Sigmoid Diverticulum 00:22:27

- Most common acquired diverticulum
- Pressure in sigmoid colon is very high
  Through blood vessel entering area – protrusion of mucosa and results in false diverticulum.
- Multiple diverticulum – diverticulosis

↓

Inflammation + perforation → Barium enema is C/I

- IOC – CT scan

  IV contrast

Hinchey's classification 00:25:09

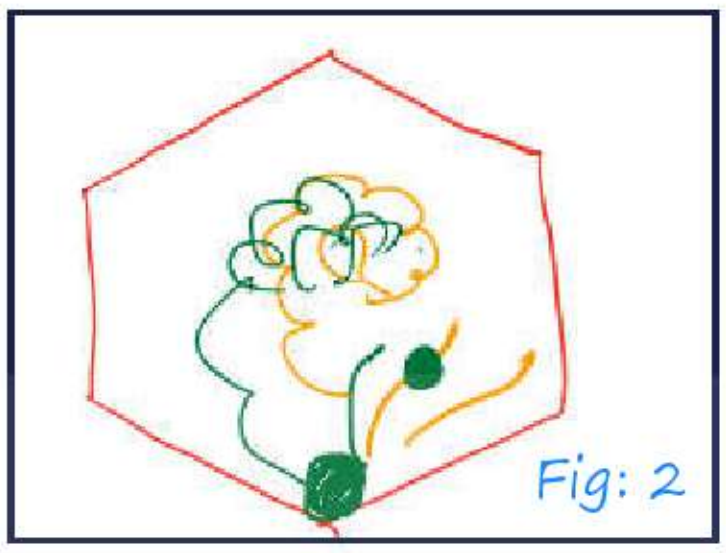

Fig: 2

- Stage I – Pericolic abscess
- Stage II – Pelvic abscess

→ USG guided drainage of abscess

- Stage III – Diffuse peritonitis
- Stage IV – Fecal peritonitis

→ Laparotomy + lavage
↓
Hartmann's operation
1. Removal of pathological segment
2. Proximal bowel colostomy
3. Close the distal end as Hartman's pouch closure
↓
Reversal of Hartman's after 6 weeks

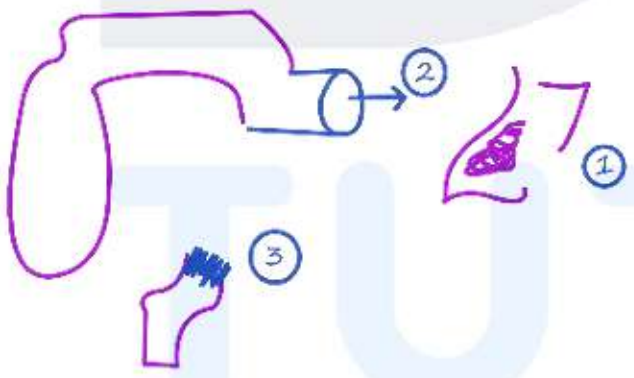

AfraTafreeh.com
TUTORIALS
LOGIN FOR SUCCESS

Other Complications 00:29:02

1. Bleeding – most common in right colon > left colon (most common bleeding massive P/R in old age)
2. Diverticulitis (most common)
3. Fistulas → Vesicocolic

AfraTafreeh.com

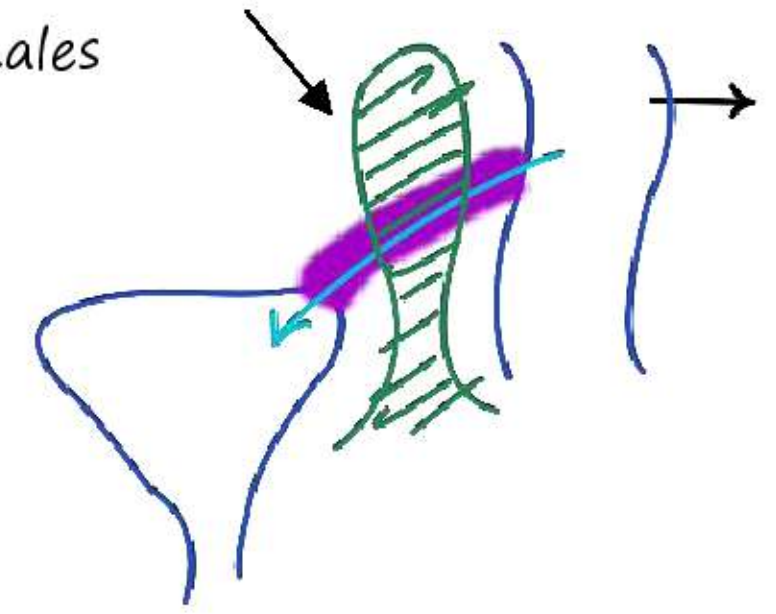

- Clinical features
  - Pneumaturia
  - Fecaluria
  - UTI

- IOC
  - Barium enema
  - CECT abdomen
  - Cystoscopy

TUTORIALS
LOGIN FOR SUCCESS

SMALL BOWEL DISEASE

Abdominal tuberculosis 00:00:11

Two types – peritoneal TB and intestinal TB

peritoneal TB (Most common)

↓

clinical: - Ascites Peritoneal Nodules

↓

-Ascitic fluid analysis:

increase protein (Exudate)

SAAG decreased

ascitic ADA positive.

-IOC: - D. Lap and peritoneal biopsy

AfraTafreeh.com

Intestinal TB

- Most common site: - Terminal ileum
  Ileocecal junction + food accumulates] Because enormous payer's patches
- Two types → hyperplastic TB and ulcerative TB

TUTORIALS LOGIN FOR SUCCESS

Hyperplastic TB	Ulcerative TB
Healthy person drinks raw cow milk containing M.Bovis ↓ Attacks terminal ileum ↓	Already a TB patient, swallows his own saliva containing M. TB bacilli ↓ Attacks terminal ileum ↓

AfraTafreeh.com

T. ileum goes hyperplasia/hypertrophy ↓ -pulled up caecum -string sign of Kantor Fleschneir sign Umbrella sign Goose neck deformity	Ulcers are formed in T. ileum ↓ Transverse ulcers ↓ As they heal, forms strictures

Also known as primary TB → Intestinal obstruction (Subacute)

Also known as 2° TB → Intestinal obstruction (Subacute)

Surgery → Intestinal obstruction (Subacute)

Surgery
↓
HPE
↓
TB

Intestinal obstruction (Subacute)
↓
Ileocolonoscopic biopsy (Gold standard)
↓
To start ATT
↓
>2 weeks – limited resection of involved bowel

Short bowel syndrome 00:10:13

- Length of small bowel – 6m

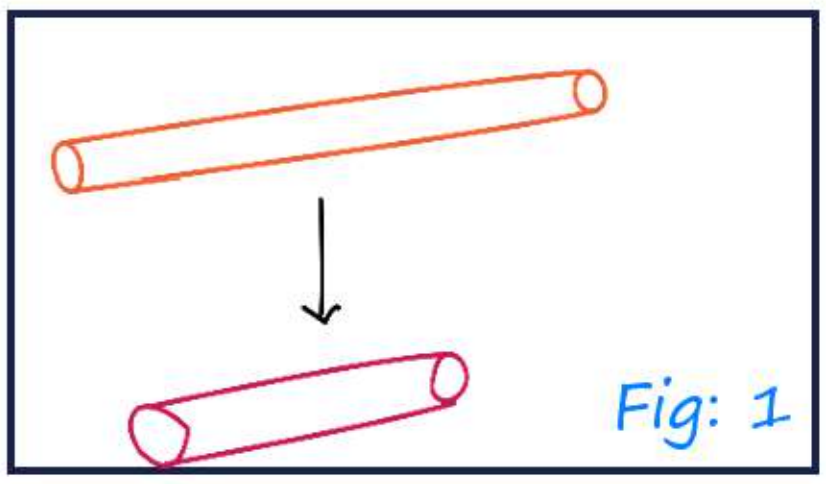

Fig: 1

- Etiological factors
  - Most common: - mesenteric ischemia
  - Second: - crohn's disease
  - Third: - trauma
- Pediatric causes
  - Gastroschisis.
  - Volvulus (midgut)
  - Necrotizing enterocolitis

Clinical:

1. Diarrhea (Watery)
2. Malabsorption (vitamin B12 def)-as terminal ileum Is resected.
3. Reabsorption of the bile salts – enterohepatic circulation

   ↓

   Decrease bile salts

   Decrease A, D, E, K

   Deficient steatorrhea

   

   Decrease bile salts → increase cholesterol (cholesterol gall stones)

   Unabsorbed bile salts forms -Ca. oxalate kidney stones.
4. As the stomach produces acid, there is feedback inhibition from small bowel.

   ↓

AfraTafreeh.com

Feedback inhibition is absent in short bowel syndrome

↓

Increase acid (increase gastrin).

Types 00:06:14

- Type I – presents with end jejunostomy

- Ileum and colon are gangrenous → removed

- Type II – Jejunocolic anastomosis

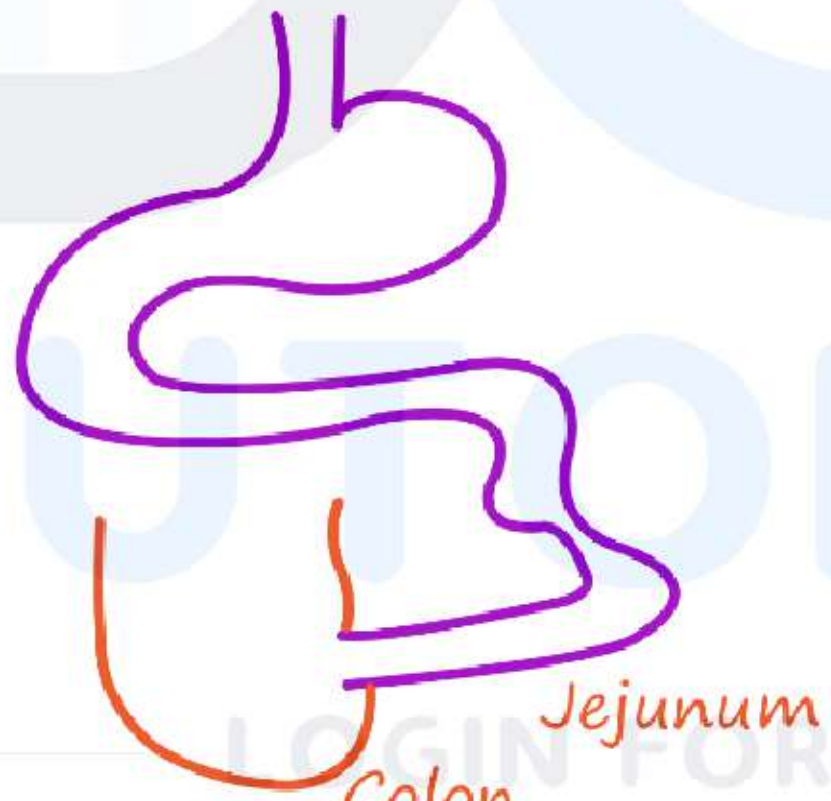

Fig: 2

-Only Ileum removed

- Type III – Jejunoileac anastomosis – good prognosis

-Only few areas of jejunum/ Ileum removed

Fig: 3

DOC TUTORIALS LOGIN FOR SUCCESS

- To prevent lifelong TPN

Type I	Type II	Type III
↓	↓	↓
100cm jejunum	65cm of jejunum	30cm of jejunum

Management 00:20:30

Medical treatment: -

1. Loperamide – Antimotility
2. H2 blockers – Famotidine
3. Octreotide
4. Correct fluid electrolyte imbalance
5. Enteral nutrition

↓

TPN Started

Type I: - < 100 cm

Type II: - < 60 cm

Type III: - < 30 cm

- Latest drug: - GLP 2 analogue – TEDUGLUTIDE (helps in bowel growth)
- Surgical treatment

AfraTafreeh.com
DX TUTORIALS LOGIN FOR SUCCESS

AfraTafreeh.com

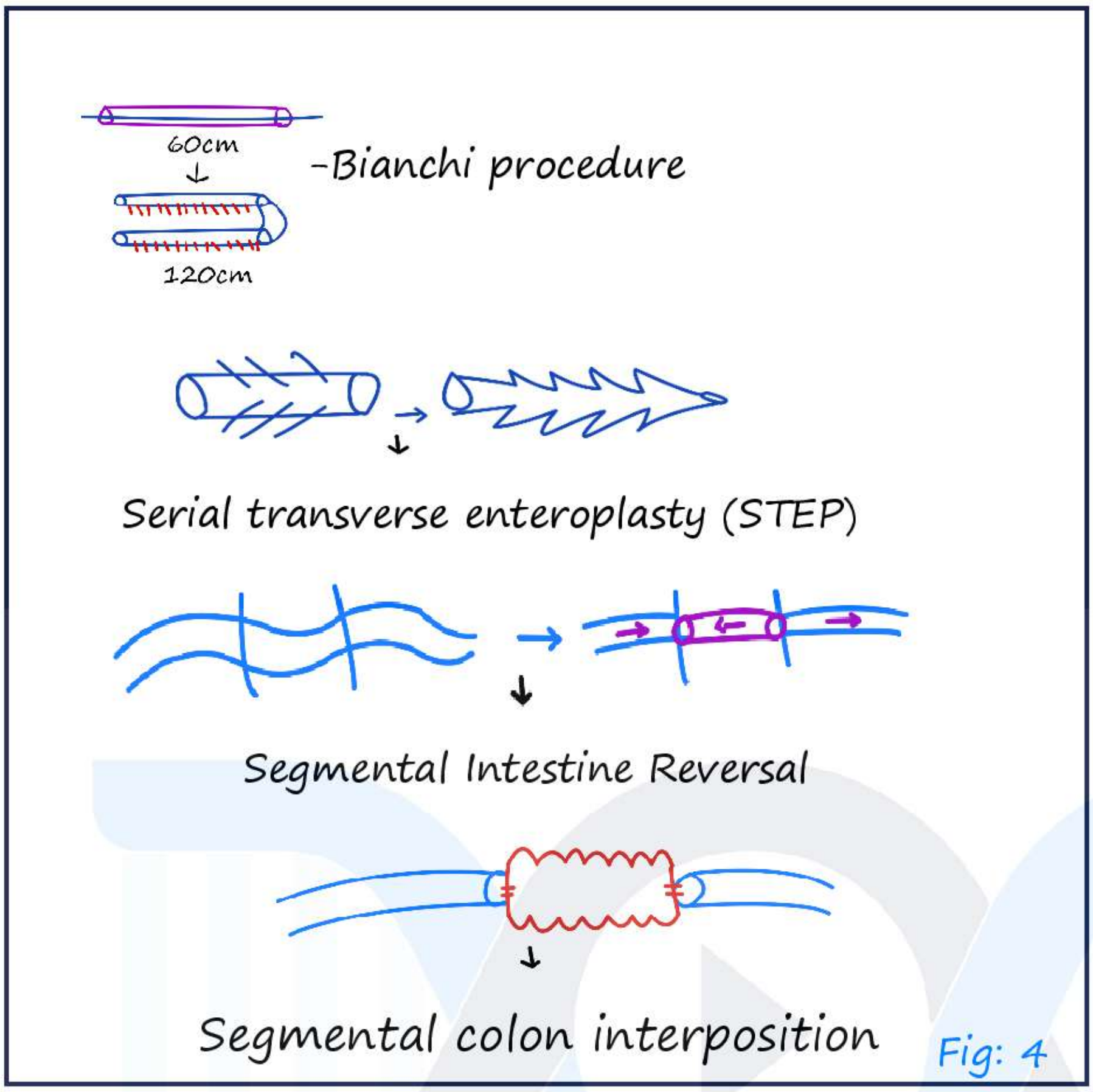

Fig: 4

- Last option – small bowel transplant

↓

Indications → TPN Failure

TPN induced CV thrombus

Liver failure on TPN.

DOC TUTORIALS LOGIN FOR SUCCESS

Enterocutaneous fistula 00:27:57

- Connection between bowel and skin.

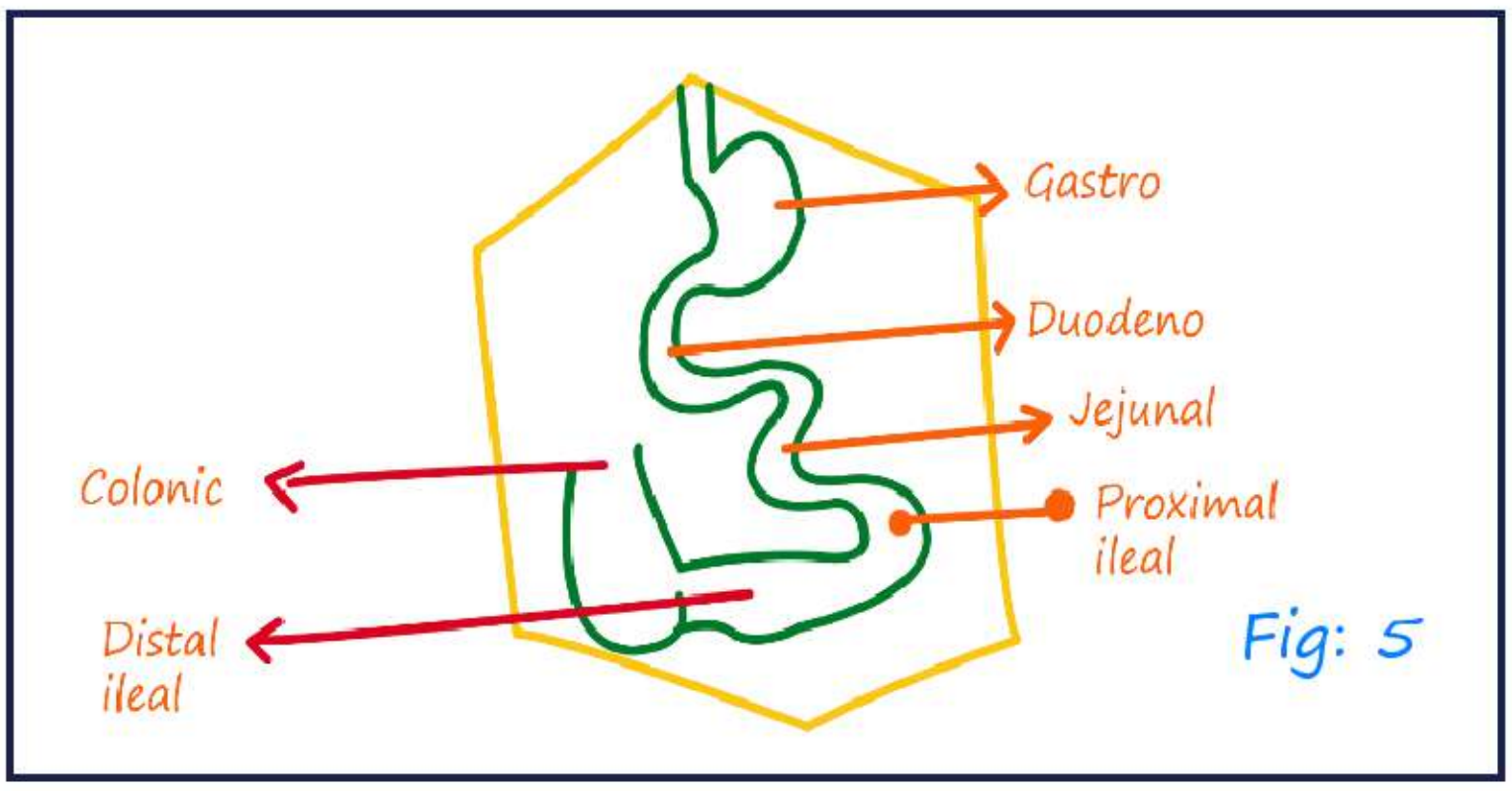

Fig: 5

- Most common cause: - Iatrogenic
- Types: - Gastrocutaneous, Duodenocutaneous, Jejunal cutaneous } High output >500ml/day
  - Proximal ileal cutaneous
  - Distal ileal cutaneous, Colonic cutaneous } Low output <200ml/day
- Complications

  High output → 1. fluid loss

  2. electrolyte
  3. skin excoriation (most common)
  4. sepsis due to infection
  5. mortality.
- Highest electrolyte imbalance and fluid loss seen in duodenocutaneous fistula.

  Low output → 1. Infection

  2. sepsis.

TUTORIALS
LOGIN FOR SUCCESS

Principles in management

- S – Sepsis elimination
- N – Nutrition (TPN)
- A – Anatomical assessment
- P – Plan > 6 weeks surgery

Factors preventing healing of EC fistula

- F– FB in tract
- R – RT to bowel

AfraTafreeh.com

- I – IBD
- E – Epithelization of tract
- N - Neoplasia
- D – Distal obstruction
- S – Short tract < 2.5cm
- High output > 500ml/day also fails to heal.
- Entero atmospheric fistula – poor prognosis.

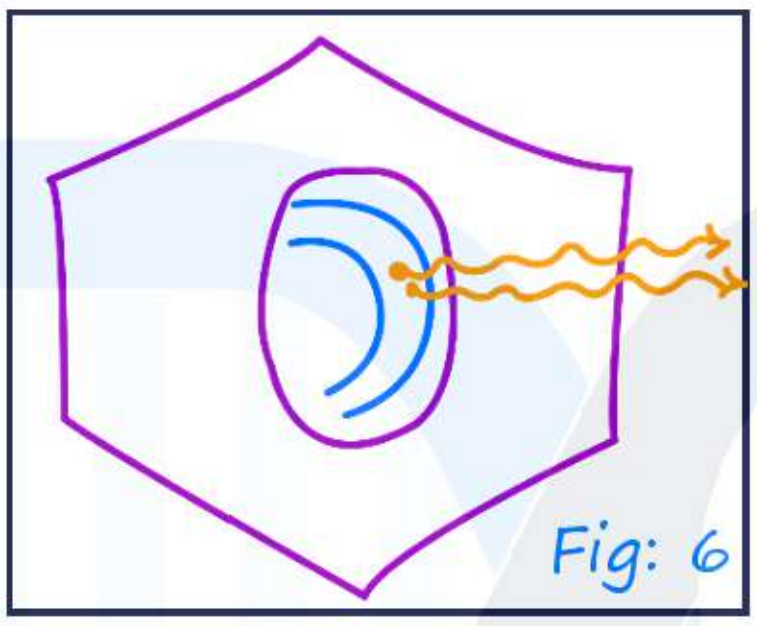
Fig: 6

Extra Mile 00:37:52

Barium Findings in Intestinal TB:

- Earliest features: Spasm and hypermotility with edema of valve
- Thickening and widening of the valve with narrow terminal ileum – Fleischner sign/Umbrella sign
- Loss of ileocecal angle and terminal ileum becomes dilated imparting – goose neck deformity
- Narrowing of terminal ileum due to irritability along with shortened rigid cecum is called as "stierlin sign"
- Persistent narrow stream of barium in bowel indicates stenosis and is known as "string sign"
- Remember: Stierlin and string sign of kantor are also seen in Crohn's disease.

HIRSCHRPUNG'S DISEASE

Introduction 00:00:10

- Congenital megacolon or HIRCHSPRUNG DISEASE
  - Due to RET oncogene mutation (MEN 2A)

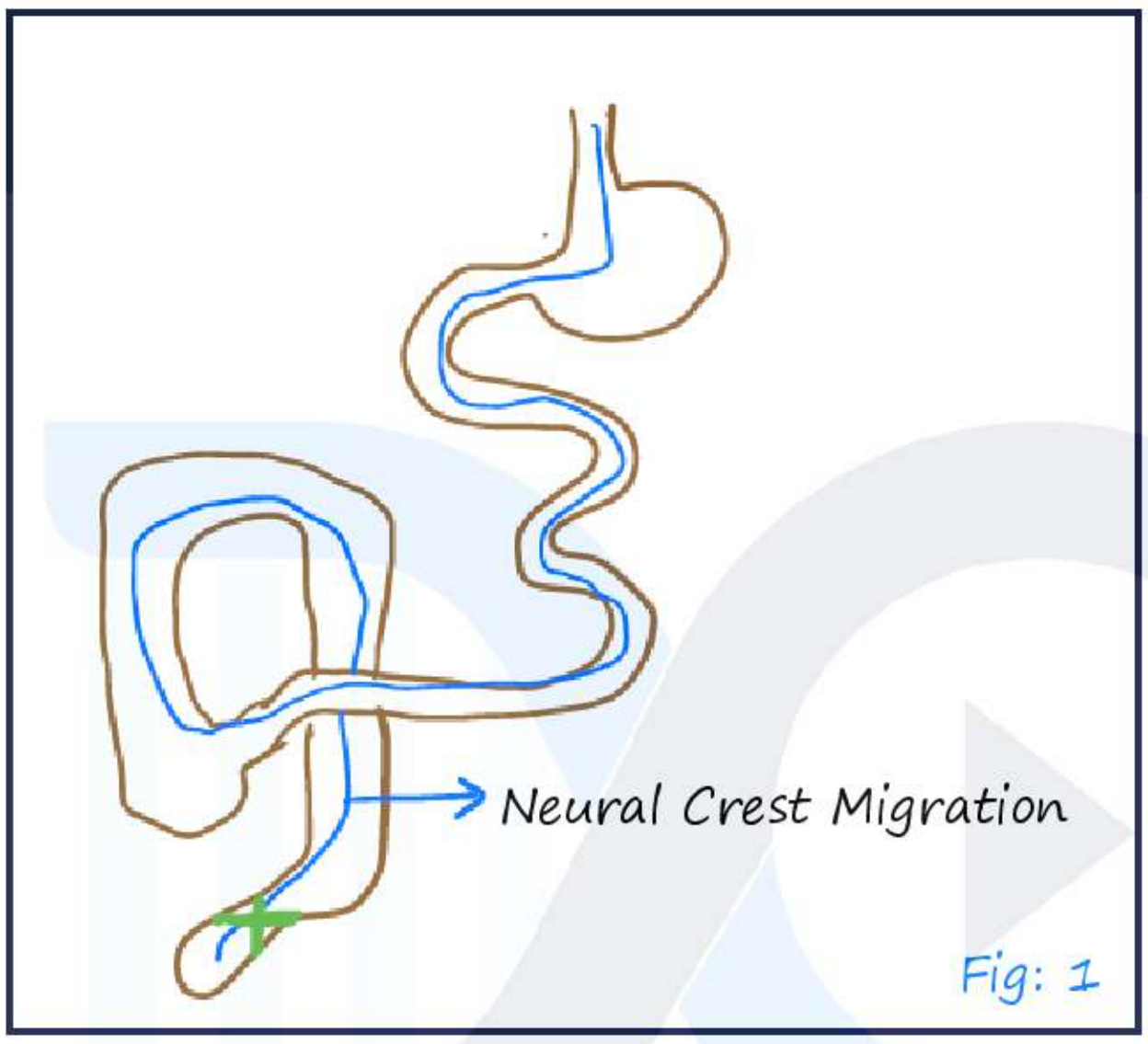

Fig: 1

AfraTafreeh.com
TUTORIALS
LOGIN FOR SUCCESS

- Neural crest migration supplies

Auerbach plexus
↓
Myenteric plexus
between circulatory and
longitudinal m/s of GIT

Meissner's plexus
↓
Submucosal plexus

- Dilated colon will be seen with constrictions at rectum

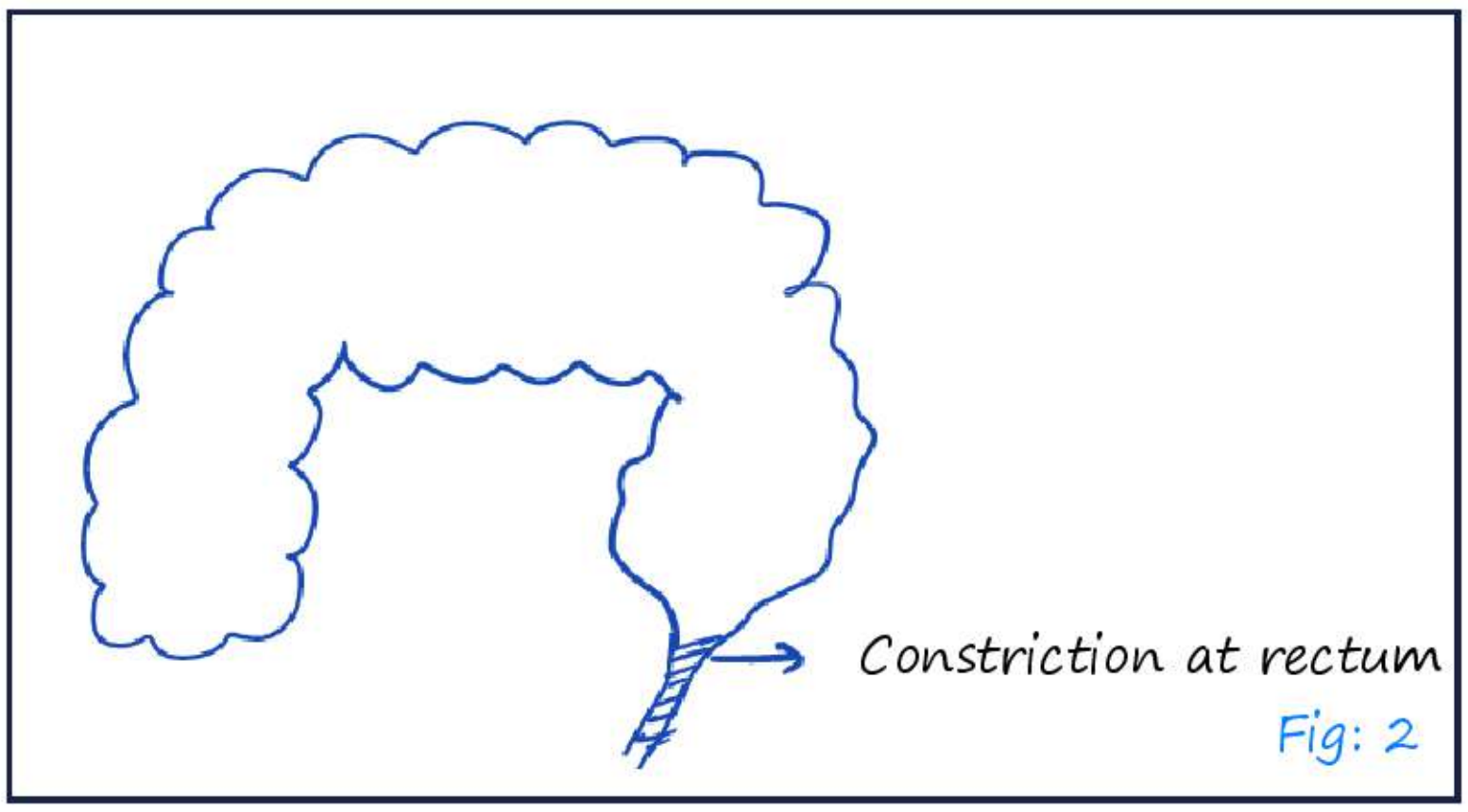

Fig: 2

AfraTafreeh.com

- Absence of
  - i. Meissner's plexus
  - ii. Auerbach plexus

  } @ Constriction at rectum

- Confirmation by full thickness rectal biopsy

  ↓

  1. Absence of 1. Meissner's plexus, 2. Auerbach plexus } @ Constriction at rectum
  2. Hypertrophied nerve trunk
  3. IHC: - Acetylcholinesterase staining present

Clinical Features 00:07:10

 Clinical features – Delayed passage of meconium	Constipation absence of fecal soiling	Habitual constipation → s/w Enema	Constipation → self-enema practiced.

Aganglionic segment

- most common in rectum
- Entire L colon can be aganglionic
- Entire colon can be aganglionic
- 8% extends to small intestine also

Question mark colon

Investigations 00:11:58

- Newborn/Infants – suction biopsy kit
- Children/Adults – Full thickness biopsy above dentate line

↓

IMC – Increases Ach staining

Anal Manometry 00:13:32

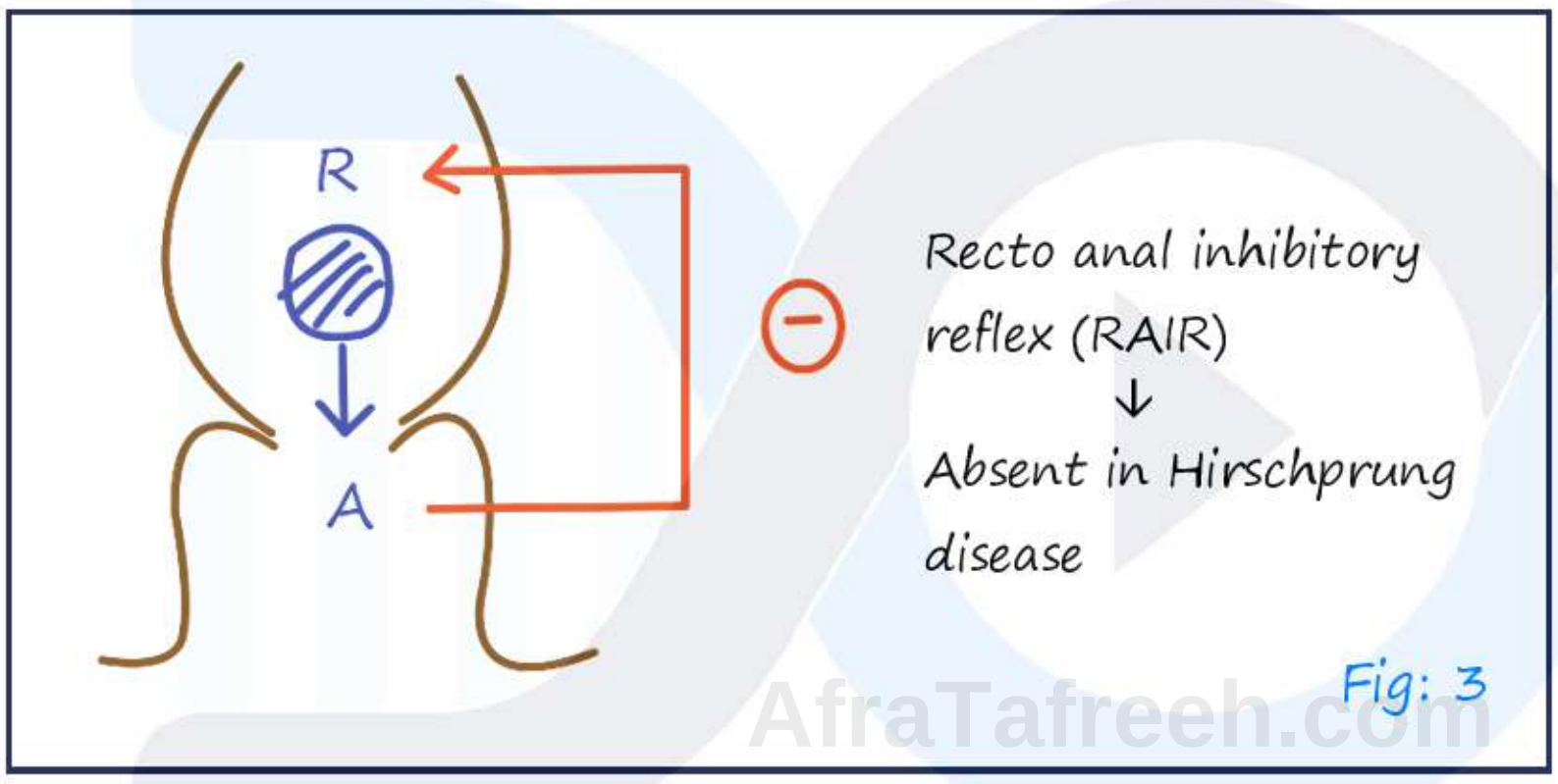

Fig: 3

AfraTafreeh.com
TUTORIALS
LOGIN FOR SUCCESS

Management 00:14:48

- Pull through operations
  - DUHAMEL
  - SWENSEN
  - SOAVE

AfraTafreeh.com

CARCINOID TUMOR

Small Bowel Tumors 00:00:11

- Incidence <2%

  ↓

  Reason?

  1. Rapid transit of food
  2. Payer's patches
  3. Epithelial turnover is more.

Classification of SB Tumors 00:01:23

Classification of SB tumors

- Benign
  - Adenoma
    ↓
    Most common overall benign (asymptomatic)
  - leiomyoma
    ↓
    Most common symptomatic benign tumor
- Malignant
  ↓
  Metastasis most common
  ↓
  Most common – GIT primaries
  Extra GIT – melanoma skin

Primary malignant:

1. Adeno cancers most common → most common in duodenum
2. NET (carcinoid) → second most common (most common in appendix)
3. GIST

4.NHL – most common in children and in Ileum.

Adenocarcinoma 00:05:08

- Etiology: - CD and FAP
  - Most common duodenum – second part
  - Crohn's – most common terminal ileum
  - Most common: - old men > 70 years

↓

METS is the most common presentation

- Clinical features: - pain abdomen
  obscure GI bleed
  intussusception

- IOC: - CECT Abdomen
  (Capsule endoscopy)
  CEA increases

AfraTafreeh.com
TUTORIALS
LOGIN FOR SUCCESS

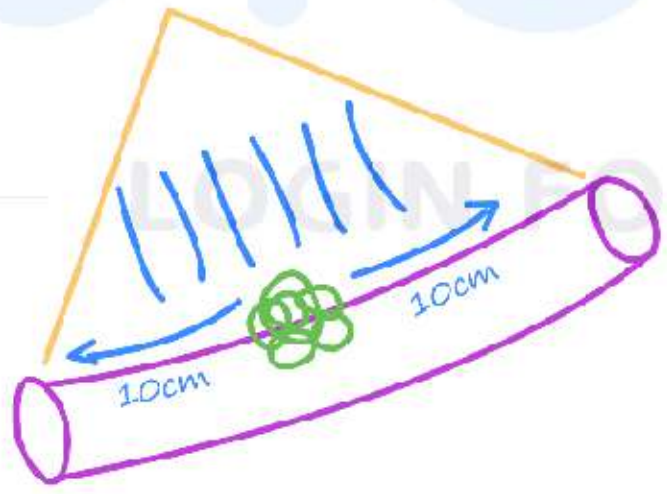

- In jejunal adenocarcinoma, 10 cm clearance should be given, resected along with mesentery including nodes.
- According NCCN guidelines: - 6 nodes removed and 10cm margin
- Usually, palliative resection is only done.

AfraTafreeh.com

- Adjuvant treatment: - FOLFOX regimen x 6 cycles

  ↓

  FOL-Folinic acid (Leucoverin)

  F-5-FU

  OX-Oxaliplatin.

Neuroendocrine tumor (NET) of human 00:10:04

- APUD omas (Amine precursor uptake deuptake omas).
- All these tumors somatostatin receptor positive
- CNS → brain: - medulloblastoma

  PNS; - Neuroblastoma
- Lungs → small cell cancer
- Thyroid → medullary cancer
- Adrenal →pheochromocytoma
- Pancreas → insulinoma, gastrinoma, somatostatinoma, glucagonoma.
- GIT → Carcinoid tumors.
  - Only tumor which is somatostatin receptor negative is insulinoma.
- All tumors can be picked by somatograffin scintigraphy except insulinoma.

Carcinoid tumor 00:13:24

- Arise form enterochromaffin like cells (or) argeantaffin cells (or) kulchisky cells

Divided into

- **FOREGUT** → At bronchus esophagus → ACTH, 5HT → Cushing syndrome
- **MIDGUT** → At stomach S.I R 2/3 colon → Serotonin, histamine tryptophan → Cushing syndrome
- **HINDGUT** → At L 1/3 colon rectum → Somatostatin

- Most common – bronchus.
- Second – appendix.
- Third – ileum.

AfraTafreeh.com
TUTORIALS
LOGIN FOR SUCCESS

AfraTafreeh.com

Types of carcinoids 00:17:01.

Types of carcinoids

1°

↓

- Tumor only in small bowel
- No liver mets



- releases serotonin histamine

↓

Taken up by liver and detoxified

↓

5 hydroxy indole acetic acid

↓

Asymptomatic

↓

Most common: - diarrhea (Harrison)

Most common: - pain abdomen (Sabiston)

2°

↓

-carcinoid in small bowel/with liver mets seen.

-serotonin 2 histamines from mets

↓

Malignant carcinoid syndrome

Malignant carcinoid syndrome 00:17:01

- Most common – flushing (due to serotonin) vasomotor symptoms – 80%

  ↓

  - Diffuse erythematous
  - Violaceous

- Prolonged
- Bright red patchy → gastric carcinoids

- Bronchospasm
- Explosive watery diarrhea
- Pellagra

↓

Dementia, diarrhea, dermatitis.

(60mg Tryptophan → 1mg niacin)

↓

Serotonin pathway.

- CVS Symptoms
  - Most common – R heart
  - Most common – tricuspid valve
  - Right heart failure.

AiraTafreeh.com

Lesions

- Most common: - pulmonary stenosis (90%)

  Tricuspid regurgitation (45%)

  Tricuspid stenosis (40%)

TUTORIALS LOGIN FOR SUCCESS

- Pulmonary regurgitation not seen.

Investigation 00:24:42

- First done/IOC: - 24 hours urinary 5 HIAA +
- Tumor marker: - chromogranin A

AfraTafreeh.com

Synaptophysin

Lsocate

↓

Somatostatin receptor scintigraphy

↓

IOC – olden days

Replaced by

gadolinium 68%

dotatate ct – 95% sensitive

Metastasis work up

↓

PET CT < 30% sensitive

FDG PET

↓

High ki 67 index

↓

NET → low ki 67

-dotatate ct

- IOC for liver mets in NET: - MRI
- METS in NET: - DOTATATE CT

Extra edge 00:28:39

- Without liver mets, carcinoid syndrome seen in
  1. RP carcinoids
  2. Ovarian carcinoids
  3. Bronchus carcinoids
- Second most common tumor: - colorectal carcinomas
- MEN syndromes: - carcinoids can be multicentric.

Management: - Resection 1°/2° 00:30:40

- Management: - Resection 1°/2°

  Aim at Ro resection

Ro resection – no microscopic residue
R1 resection – microscopic residue
R2 resection – macroscopic residue
} all are advised

- If liver mets + → resection of mets advised

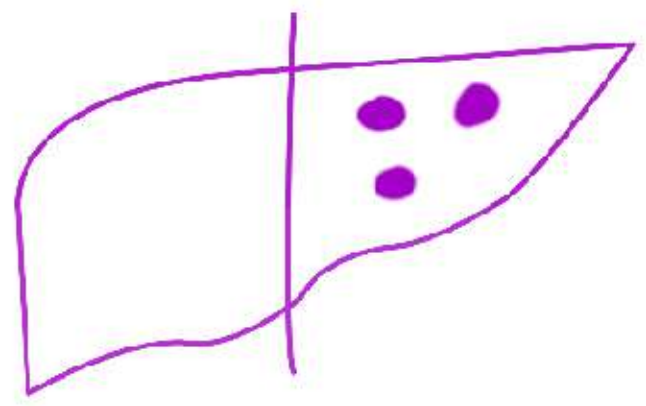

- Best prognosis of all → NET Mets

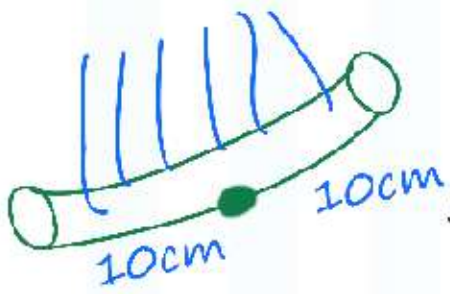

→Small bowel carcinoid – 10cm margin given and resected along with mesentery.

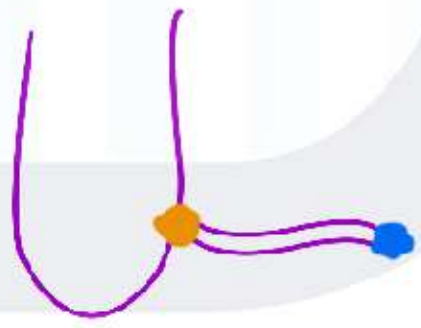

AfraTafreeh.com
TUTORIALS
LOGIN FOR SUCCESS

- In appendix carcinoid
  - Carcinoid at tip <1cm; - appendectomy is enough
  - Carcinoid at base – R hemicolectomy
  - Carcinoid at tip >2cm: - R hemicolectomy
  - Carcinoid at tip 1-2cm – see for mesoappendix infiltration
    - Infiltrated ↓ R hemicolectomy
    - Not Infiltrated ↓ appendectomy

AfraTafreeh.com

Prognostic factors 00:34:48

Metastasis in carcinoids

1.SITE: - Ileal > Appendix

2.SIZE: - < 1CM: - 10% mets .1cm -90%mets

3.Ki 67 index low is good

4.Grade of tumor

Recent advances 00:35:34

- R1 still resect

R2 ↓

Lanreotide: - long-acting somatostatin analogue

pasireotide

SMART BOMB: - Radio labelled somatostatin analog



LOGIN FOR SUCCESS

Summary

- Most common site – bronchus > appendix
- Bright red patchy – gastric carcinoids
- Most common – flushing
- Most common valve effected – tricuspid value
- Most common lesion: - Pulmonary stenosis
- IOC: - 24 hours urinary 5 HIAA
- Location/mets: - DOTATATAE CT

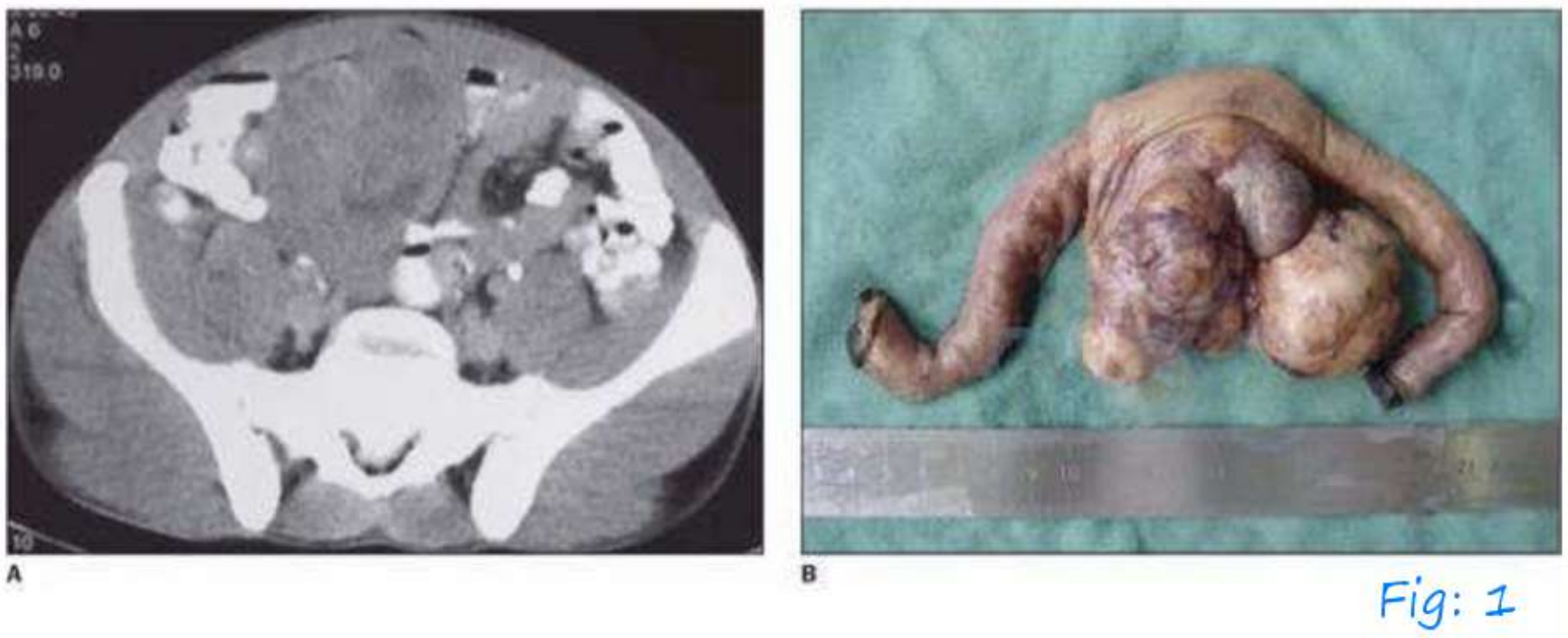

Fig: 1

AfraTafreeh.com
TUTORIALS
LOGIN FOR SUCCESS

AfraTafreeh.com

INFLAMMATORY BOWEL DISEASE

IBD

Crohn's disease

- Incurable
- Bimodal age of distribution
- Associated with IBD-1 mutation (IBD-1/CARD/NOD gene)
- It is associated with crohn's 16q mutation (Chromosome 17q: BRCA 1)
- Protecting factors for CD
- Smoking +++++
- Involvement of disease
- Crohn's involves from mouth to anus-**rectum is spared**
- **Most common involved area is terminal ileum (Called regional enteritis)**

Ulcerative colitis

- Curable disease
- Bimodal age of distribution
- Associated with IBD-2 mutation
- It is chromosome 12q mutation (Chromosome 13q-BRCA2 mutation)
- Protective factors for UC
- Smoking ----
- Appendectomy -----
- It starts in rectum & comes retrogrades up to caecum
- **Anus is not involved spared**
- **Most common involved area is rectum**

- Anal lesions common are fistula (In CD, lateral wall is common) ← Fissure (Usually fissure is common on part wall)
- Fissures in CD are multiple and on lateral wall

- Can also involve terminal ileum called **back wash ileitis**

AlfaTanbeh.com

Classification of Crohn's & UC

- Vienna classification: for crohn's
- It is based on 3 factors
- Age of the patient → < 40yr (or) > 40yr
- Behavior of the lesion → It is a stricture (or) fistula
- Site of the lesion → It involves terminal ileum, colon, upper GT
- Based on these, we have 24 types of crohn's disease
- In U.C, we have 3 types
  1. It only involves rectum called proctitis
  2. It involves entire (L) colon – (L) colitis
  3. It involves entire colon Pan colitis

DOT TUTORIALS LOGIN FOR SUCCESS

Clinical features of crohn's

- Most common is pain abdomen
- Diarrhea
- Bleeding

AfraTafreeh.com

- Earliest presentation of Crohn's is Aphthous ulcer.
- Pain abdomen is due to strictures causing partial Obstruction
- due to the Inflammation colicky type of pain.

Clinical features of UC

- M/C C/F – Diarrhea
- Pain abdomen is not common
- Bleeding is common
- Many times, present as emergency → Toxic megacolon (or) as perforation.

External features in both disease 00:11:47

In crohn's

- Most common extraintestinal skin manifestation (In Crohn's) → Erythema Nodosum
- Apart from skin, Crohns have bone & stone problems.
- Bone - Ankylosing spondylitis, peripheral arthritis
- Stone - Cholesterol gall stones, kidney stones usually it is ca-oxalate kidney stone

In U.C

- Most common extraintestinal feature of U.C – Fatty liver

DOC TUTORIALS LOGIN FOR SUCCESS

- Most common skin manifestation in UC - Pyoderma gangrenosum
- → Apart from these above. UC also have
- Primary sclerosing cholangitis
- Uveitis
- Scleritis
- The above 3 are common in UC, but also seen in crohn's also
- All the features can be seen on both diseases, but the discussed are common under the headings provided.
- All the extraintestinal manifestations reverses on & only one which is irreversible is Primary sclerosing cholangitis > Ankylosing spondylitis

TUTORIALS LOGIN FOR SUCCESS

Pathological features 00:15:35

Crohn's disease:

- Serpentine ulcer/ Bear claw ulcer
- Aphthous ulcer
- Transmural involvement
- Skip lesions
- Enters into adjacent bowel → Fistula & strictures
- Non-caseating granuloma
- Mesenteric fat wrapping
- Cobblestone appearance

AfraTafreeh.com

Ulcerative colitis

- Ulcer is collar button (type of) ulcer
- There is only partial thickness involvement (Mucosa & Submucosa)
- There is no skip lesion, only continuous involvement
- There is no stricture / fistula. If we see a stricture in UC, then rule out cancer.
- There is no granuloma
- There is no mesenteric fat wrap
- There is no cobblestone appearance
- UC have crypt abscesses and pseudo polyps are seen. The pseudo polyps are the uninvolved areas
- If cancer happens, it occurs in involved area only. pseudo polyps are not premalignant
- Both crypt and abscess and pseudo polyps can be seen in crohns also but m/c in UC

TUTORIALS LOGIN FOR SUCCESS

Complication: 00:21:18

Chron's	UC
• Intractable pian • Malabsorption/Weight loss • Strictures • Abscess • Bleeding • Intestinal obstruction	• Bleeding PR • Toxic megacolon – Full thickness of colon is involved • perforation • Cancer – It is equally

• Cancer → Most common site is terminal Ileum	• Distributed in ascending colon transverse colon descending colon

Investigations 00:23:46

Crohns

- IOE / Gold Standard - capsule endoscopy (shows ≥ 3 ulcers in the absence of NSAID) even without biopsy we can confirm
- Push endoscopy → can go for 90-150 cm in ileum
- Double balloon endoscopy → con go for 240-360 um in ileum
- Ileal colon scopey - From back side, we Ileal colonoscopy can go up to 60 cm maximum into the terminal Ileum
- These endoscopes are used to take biopsy.
- In olden days, we **used barium meal follow through** It shows **string sign of kantor, stierlin sign**
- **Ba enema shows Hose pipe colon, CECT abdomen** in Acute phase → Bowel looks edematous and blood vessels on contrast look like **Comb sign.**
- **Anti-saccharomyces cerevisiae antibody test** → ASCA is positive in 95.%. cases.
- Stool for lactiferrin and calprotectin are positive
- Fissures are present in crohn's they are multiple, lateral in position and they don't obey goodsall's rule

AfraTafreen.com
TUTORIALS
LOGIN FOR SUCCESS

AfraTafreeh.com

- As per bailey – For fistulas don't do surgery and advice just to put setons

Ulcerative colitis

- IOC → Colonascopic biopsy – It also rules out dysplasia in colon
- In colon, on colonoscopy on every 5cm, we take 4 quadrant biopsies anterior, lateral, posterior- Around 36 biopsies are taken
- Barium enema → Pipe stem/Lead pipe appearance we should not use barium enemas as barium aggravates UC so we advise instant enema
- Here Pt comes to hospital without preparation we immediately push gastrograffin and take an X-ray (Done in unprepared colon)
- Actual problem is loss of haustrations which we can see on barium enema
- Anti-neutrophil cytoplasmic antibody → (P-ANCA) it is positive in 90% of patients
- If we have to investigate about anal disease, they are very rare here in UC
- Mostly common problem in ulcerative colitis is proctitis (Other problems are rare)

Management 00:32:46

- Indications of surgery in a case of crohn's

- Most common India – Intestinal obstruction (most common cause of intestinal obstruction – structure)
- Fistulas
- Abscess
- Caner
- Bleeding
- Intractable pain

- We don't do surgery for crohn's other than these causes

Treatment of structure

- If it is a single stricture → resect it with a normal mucosa and anastomose
- If multiple short strictures present, with in 10cm of bowel, we can do resection
- If multiple short strictures present in distant places go for heineke mikulicz stricturoplasty
- If there are multiple long strictures are present, > 10 cm long, we go for a Finney's stricturoplasty. Here stricture to stricture anastomose is done side to side.

Indications of surgery in case of UC

- 20% of the patients will go for colectomy (problem is in colon So, knock out colon)

AfraTafreeh.com

Elective Indications of colectomy

- Steroid Related include
  - Resistant to steroid
  - Developing steroid Related complications steroid dependency happens i.e., stop steroid then recurs
- Intractability – not responds to medicine / steroid
- Dysplasia in colon
- For pan colitis patients → 8 years after onset of d/s
  - For (L) colitis patients → 12 years after onset of d/s
  - In elective cases we do **TPC + IPAA is gold standard**
  - TPC – Total proctocolectomy
  - IPAA – Ileal pouch anal anastomosis
  - As per bailey most of the patients with ulcerative colitis with in 1year undergo surgery

TUTORIALS
LOGIN FOR SUCCESS

Emergency indications of colectomy

- Toxic megacolon
- Bleeding
- Perforation
- Fulminant colitis
- Here we do total colectomy because PT is very sick, we do total colectomy + Ileostomy now a days

Medical management

- Can be divided into induction phase and maintenance phase

Indications of remission is started first

- DOC-Steroids
- 1st line anti-inflammatory drugs used are: ASA (Amino salicylic acid compounds) like
  - Sulphasalazine
  - Balsalozin
  - Olsalazine

  They induce remission
- New drugs in ASA compounds called mesalamines are used
- They are capsules to be time based and released after 8hours it is called PENTASA
- PH based in ASACIL & LIALDA
- If it is enema formulation → ROWASA
- Suppository → CANASA

TUTORIALS
LOGIN FOR SUCCESS

Maintenance of Remission

- Is by mesalamine compounds
- 2nd line drugs are immune suppressants used in post-transplant azathioprine, Mercaptopurine

Monoclonal Antibodies 00:45:29

- TNF α inhibitors Infliximab - used to heal the fistula

AfraTafreeh.com

- Natalizumab - it is α 4 integrin antibody, withdrawn from market due to dangerous side effect - progressive multifocal leukoencephalopathy
- Vedolizumab it is a Mad CAM antibody - - address in cell adhesion molecule antibody mucosal It is the only antibody which is directly acting on the mucosa.
- All cases of crohns and ulcerative colitis, we will start immediately on medical treatment
- But we can advise UC pts, they have a life time cure by undergoing total proctocolectomy + IPAA (Gold standard treatment)
- Many patients will not come for surgery, they opt medical management
- In this surgery. - we remove entire colon, Ascending colon , appendix, T.C, DC, sigmoid colon and rectum, we leave only anus
- we anastomose anus to terminal ileum in a J pouch like fashion, i.e., lost 30cm of T.I is made into 15cm + 15cm fold and anastomose called J pouch
- J pouch (IPAA) - Ileal pouch anal anastomosis
- J pouch is made because the stool has to come and remain here sometime (otherwise there will be no reservoir capacity and the patient will keep on passing motion 20-30 times per day After J pouch, they will pass motion 7-8 times a day.)
- we have many other pouches like 's' pouch, 'w' pouch
- W pouch has max capacity and is made up of 4 limbs

DX TUTORIALS LOGIN FOR SUCCESS

- S pouch made up of 3 limbs
- Best in terms of long function is still J pouch
- After surgery, patient passes stool 6-8 times/day. It slowly decreases to 3-4 times per day.
- But once on follow-up, if patient has sudden increase Stool frequency - This complication is called pouchitis.
- Most common cause of pouchitis is bacterial altered in colon (altered colonic bacteria) → Bacteria multiply in the pouch
- Treatment 1st line treatment is to start probiotics VSL-3 is commonly used. Bifilac
- 2nd line treatment drugs - For patients of Infective colitis T ciprofloxacin + Metrogyl
- 3rd line drug → Sulphasalazine compounds
- If all above, patient not responding, then do pouchectomy and permanent ileostomy.
- Most common complication - Immediate post op period is Intestinal obstruction followed by pouchitis

LOGIN FOR SUCCESS

U.C going to cancer

- It is equally distributed in colon, A.C, T.C. & D.C.
- A patient has UC + PSC → they have caner most common on Ⓡ side colon
- Always cancer arises from polyps. It is the adenoma, Carcinoma sequence but in UC patients, cancer can arise from flat dysplasia
- (L) side colitis < pancolitis (more chance of cancer)

AfraTafreeh.com

- In pan colitis + risk of developing cancer starts by 8 yrs.
- In L colitis risk of developing cancer starts by 12 yrs.
- Type of cancer- multicentric (synchronous)
- Mucinous type -adenocarcinoma are seen.
- They are poorly differentiated cancers
- There is a delay in diagnosis of cancer in colon, because of overlapping of symptoms.

TUTORIALS
LOGIN FOR SUCCESS

POLYPS IN INTESTINES

- Divided into Hamartomatous polyp (<1% risk of malignancy)

  Hyperplastic poly (2% risk)

  Adenomatous polyp

  - Tabular adenoma → 5-10% risk of malignancy
  - Tabular villous → 10%-20% risk
  - Sessile villous → 40% risk

Syndromes A/W Hamartomatous polyps

AfraTafreeh.com

00:02:14

1.Peutz Jeugher's syndrome:

- STK -11 mutation is seen associated with chromosome 19.P
- They develop more and more polyps in jejunum, seen in children
- They can go for 1. Bleeding 2. Intussusception
- Intussusception causes pain abdomen.
- These polyps have no risk of malignancy (But recently few cases of malignancy are deposited)
- We have a cutaneous marker to find out the case the oral / lip pigmentation.
- P-J syndrome is a pre-malignant syndrome.

AfraTafreeh.com

- Pancreatic cancer risk is 100 times
- bile duct cancer seen
- Colon cancer seen
- Breast, thyroid, ovarian cancers can happen

2.JPS: Juvenile polyposis Syndrome

- It is associated with SMAD-4 mutation, chromosome 10q
- It has > 10 polyps in colon
- For single polyp - Advice polypectomy
- Multiple polyp – Advice colectomy-increased risk of colonic & pancreatic cancer.
- They have associated other findings like
  - Hydrocephalus
  - Meckel's diverticulum
  - Malrotation of gut

3.Cowden disease

- It is a syndrome of breast cancer and thyroid cancer

  ↓ 50%. patients   ↓ 40% pts develops it

- It is associated with chromosome 10q mutation
- It can form hamartomatous polyps in stomach & colon.

TUTORIALS LOGIN FOR SUCCESS

4.Banayan Ruvalcaba syndrome

- Associated with chromo 10q mutation → AD (All cases discussed are autosomal dominant)
- Hamartomatous polyp in colon
- They have polyps in colon + pigmentation of glans penis +macrocephaly+ dysmorphic faces

5.Cronkhite-Canada Syndrome

- Hamartomatous polyps in colon
- Adenomatous polyps and sessile polyps have high malignancy risk.
- Criteria for the infiltration of polyp by malignancy called Haggit's criteria.
- According to Haggit's criteria, we have various levels of cancer involvement.
- For tubular adenomas → Head, Neck, stalk, base
- Level 1 – Infiltrating in tubular adenoma **head** of polyp up to submucosa
- Level 2 – Involvement of **neck** up to submucosa
- Level 3 – It has gone to the **stalk** up to submucosa
- Level 4 – Gone up to the **base**
- In sessile villous polyp → There is only one level → 4

LOGIN FOR SUCCESS

AfraTafreeh.com

Tubular adenoma related syndrome

- 5-10% risk of malignancy

Familial adenomatous polyposis syndrome (FAP)	HNPCC – Hereditary Non polyposis colorectal cancer syndrome
• >100 polyps in colon • Associated with 5q mutation in APC gene • AD disease • Incidence of FAP – 1% • H/O FAP • Boy born with FAP he is normal up to 10yrs he starts developing polyps at 10 yrs- by around 20yrs he starts developing cancer most of them die of cancer by 40yrs (Without any intervention) Gene study:	• Misnomer • <100 polyps • Associated with MSI (Micro satellite instability) it is a mutation of mismatch repair gene (MMR) - MLH-1, MSH-2, MSH-6 • 5% Colorectal cancers are HNPCC • HPO HNPCC • A girl born with HNPCC normal at birth by 20yrs develops polyps
• Most common mutation seen is **APC truncation mutation**	• By 25years she develops endometrial cancers • Develops colorectal cancers by 40-50yrs

- It is used in screening APC truncation mutation
- We confirm it by DNA sequencing

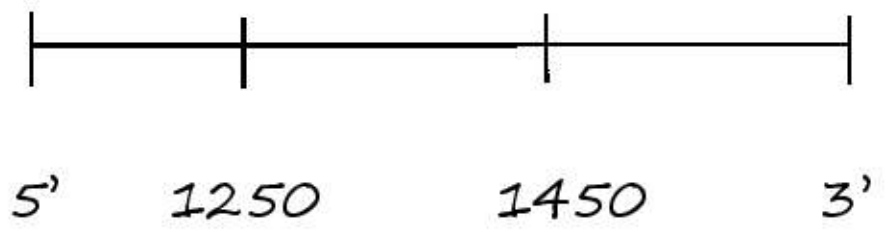

- In colon from 5 to 3 end – the classical mutation is seen from 1250 codon to 1450 codon (In classical FAP it is has >100 polyps)
- Any mutations proximal to 1250 and distal to 1450 are called attenuated FAP. they will have <100 polyps in colon
- Any mutation proximal to 1250 codon will have "No rectal polyps"

AfraTafreeh.com
TUTORIALS
LOGIN FOR SUCCESS

AfraTafreeh.com

Criteria's for HNPCC:

1.Amsterdam criteria:

- If in one family, 3members are affected with colorectal cancer 2members are 1st degree relatives and one member is aged <50yrs and we excluded FAP then the person has chance of developing HNPCC

2.Modified Amsterdam's criteria

- Along with colorectal they added other cancers like
- C – Colorectal
- E – Endometrial
- S – Stomach, SI
- U – Urinary tract
- R – Rectal

3.Bethesda criteria

- It includes cancer + also polyps

TUTORIALS
LOGIN FOR SUCCESS

Surveillance of FAP:

- Colonoscopy screening
- In FAP it should start by 10yrs onwards
- On surveillance we go for prophylactic total proctocolectomy before < 20 years. Even after doing surgery, the boy is @ risk of developing - Duodenal and periampullary cancers.
- For this we should do upper GI endoscopy from 20 years onwards. If there is polyp seen in duodenum

there is a classification known as Spiegelman Classification of duodenal polyps in FAP patients on surveillance.

- Upper GI endoscopy in how many months we should do once is based on Spiegelman's criteria.

Surveillance of HNPCC:

- Colonoscopy should be started by 20 years.
- TVS/D&C should be started by 25 years) Transvaginal sonogram / Dilatation and curettage)
- Prophylactic colectomy is not needed.
- We keep them on follow up once they develop colon cancer at that time we do total colectomy (generally at 40-50yrs) until then keep them under follow up colonoscopy.

AnyTaArooshi.com TUTORIALS LOGIN FOR SUCCESS

FAP	HNPCC
• Most common (L) colon • >100 polyps in colon • By 20yrs they start developing cancer • Prophylactic total proctocolectomy + IPAA (Ileal pouch anal anastomosis)	• Most common on (R) side colon • <100 polyps • Thye have synchronous & metachronous cancers • 40-50yrs –cancer • Total colectomy +IRA

AfraTafreeh.com

Syndromes associated with FAP

1. Gardner's syndrome → FAP associated with
   - CHRPE – seen in 80% cases- congenital hypertrophy of retinal pigmental epithelium
   - Exostosis
   - Sebaceous cyst
   - Desmoid tumors
   - It is AD

2. Turcot's syndrome - FAP +
   - Brain tumor (Medulloblastoma)
   - AR

Syndromes associated with HNPCC

- Lynch I syndrome →will have only Colo-rectal cancer
- Lynch II syndrome will have CRC and other cancers also (EGO-SP TUB)
- E - Endometrial
- G - Gastric
- O – Ovarian
- S - S.I.
- P - Pancreas
- T - Thyroid
- U – Urinary tract
- B - Brain tumor - m/c-Glioblastoma

- MUIR TORRE syndrome – HNPCC + multiple sebaceous cysts

Extra mile points

- TPC+ IPAA @ < 20 years → so before 20 years if we remove rectum, we can injure hypogastric nerve & these young patients can have lifelong sexual disturbance So, we should try to preserve rectum.
- Most important criteria to preserve rectum are if mutation proximal to 1250 codon we can preserve rectum because these patients won't develop rectal cancer and no rectal polyps, we go for total colectomy + IRA in FAP pts

AfraTafreeh.com
TUTORIALS
LOGIN FOR SUCCESS

AfraTafreeh.com

COLON CANCER

Incidence

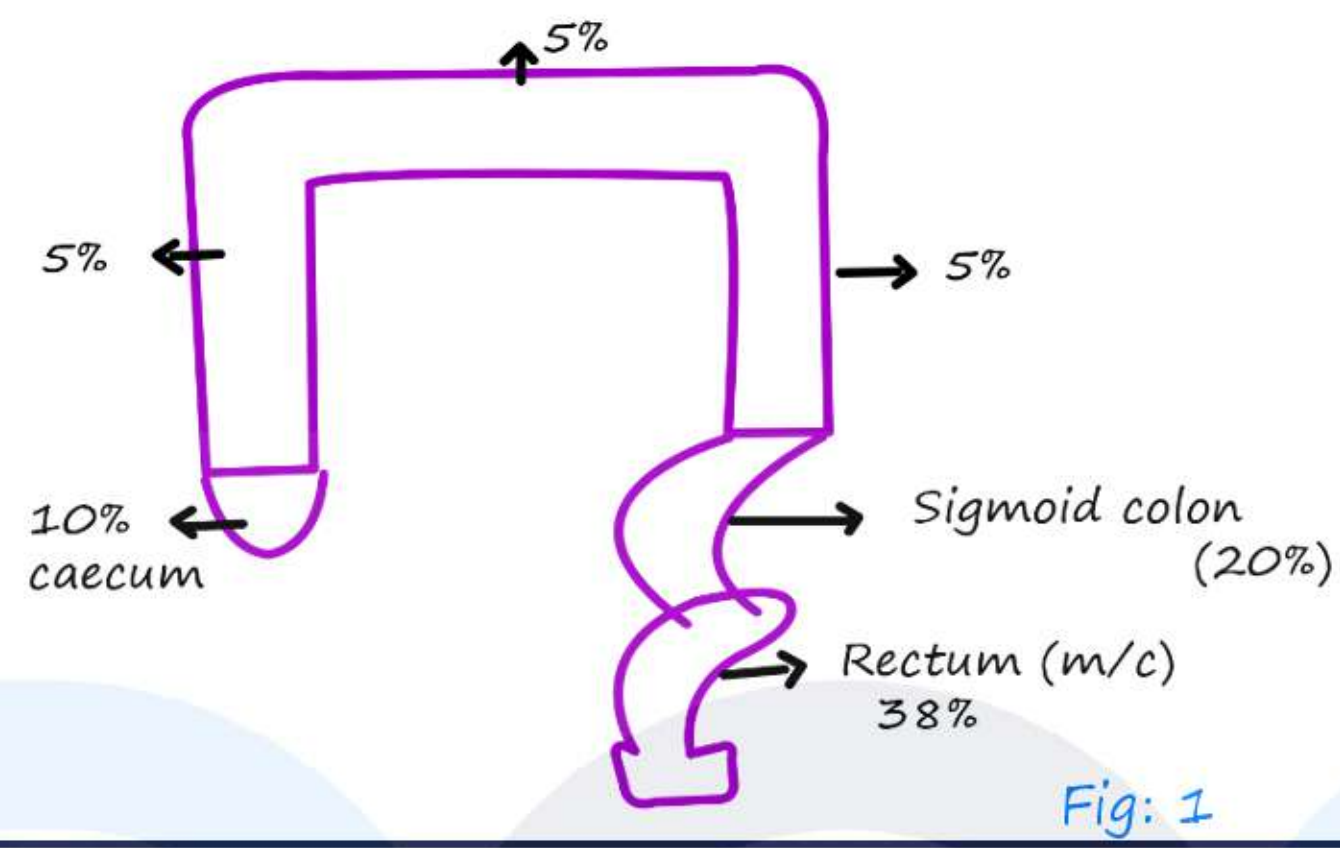

Fig: 1

Ⓡ Cauliflower	Ⓛ Colon
- Cauliflower (or) fungating - Mass, melena, anaemia	- Stricture (annular) - Haematochezia, altered bowel habits - Emergency with colon obstruction

Fearon – Vogelstein sequency (adenoma-carcinoma)

Fig: 2

- Initiation is by APC gene 5q mutation
- Promotion – HNPCC – microsatellite instability
- Last hit – P_{53} mutation (17P)

- In between
  - APC
  - HNPCC

    ↓

    DCC (18q)

    DMAD-9 (12p)

    Kras

Risk factors

i. Dietary
- High animal fat
- Low carbohydrate
- Low fibre
- Lack of antioxidants

AfraTafreeh.com
TUTORIALS
LOGIN FOR SUCCESS

ii. IBD
- UC
- CD

iii. Iatrogenic
- Radiotherapy
- Uretero-sigmoid anastomosis

iv. Genetic
- FAP
- HNPCC

AfraTafreeh.com

Investigations 00:09:21

- Diagnose → colonoscopic biopsy (6-8)
- T, N staging → CECT abdomen
- M staging → liver (most common) → CECT abdomen
- Tumour markers → CEA → N <5ng/ml

TNM staging 00:09:21

AJCC 8th edition

- T_1 – mucosa and submucosa
- T_2 – muscularis propria
- T_3 – Pericolic tissues, serosa only
- T_4 – Adjacent structures
- N_1 – 1-3 nodes
- N_2 – 4/more
- M_1 – mets ⊕
- Stage
  - I – T_1 T_2
  - II – T_3 T_4
  - III – Node +
  - IV – Mets +

TUTORIALS LOGIN FOR SUCCESS

Other staging 00:13:51

Modified Astler coller staging

- A – upto mucosa
- B_1 – upto muscularis propria
- B_2 – beyond muscularis
- B_3 – infiltrated adjacent structure.
- C_1 – B_1 + nodes
- C_2 – B_2 + nodes
- C_3 – B_3 + nodes
- D – Distant mets
  - Best prognostic factor – Depth of infiltration

Surgical treatment 00:16:47

i. Ⓡ hemicortectomy

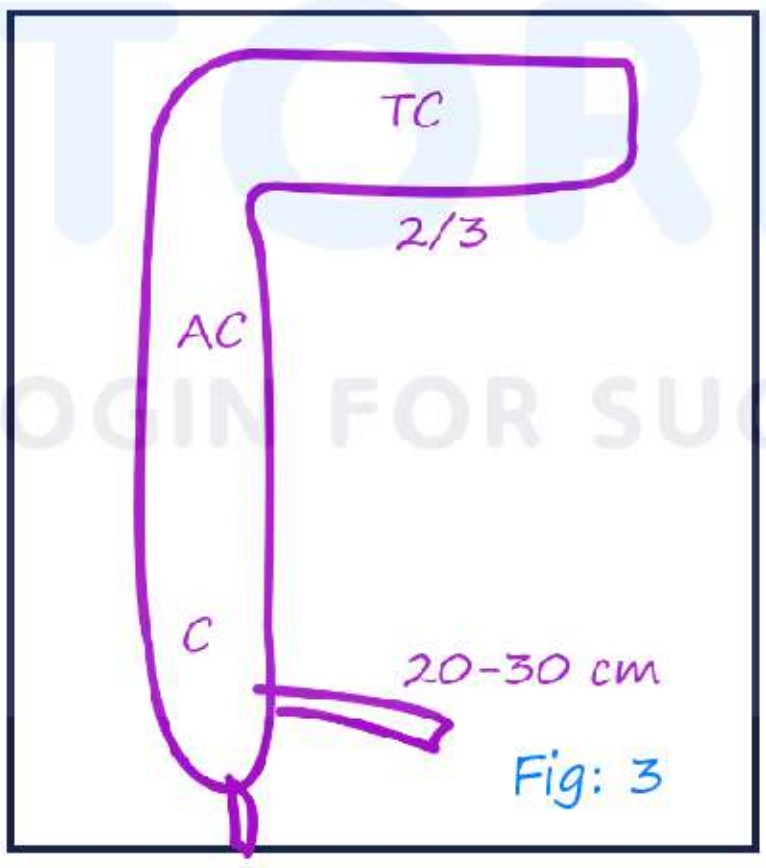

Fig: 3

- Vessels ligated
  - Ileocolic ã
  - Middle colic ã
  - Ⓡ colic ã
- Indications

AfraTafreeh.com

AfraTafreeh.com

- Caecal ca
- Ascending colon ca

ii. Extended Ⓡ hemicolectomy

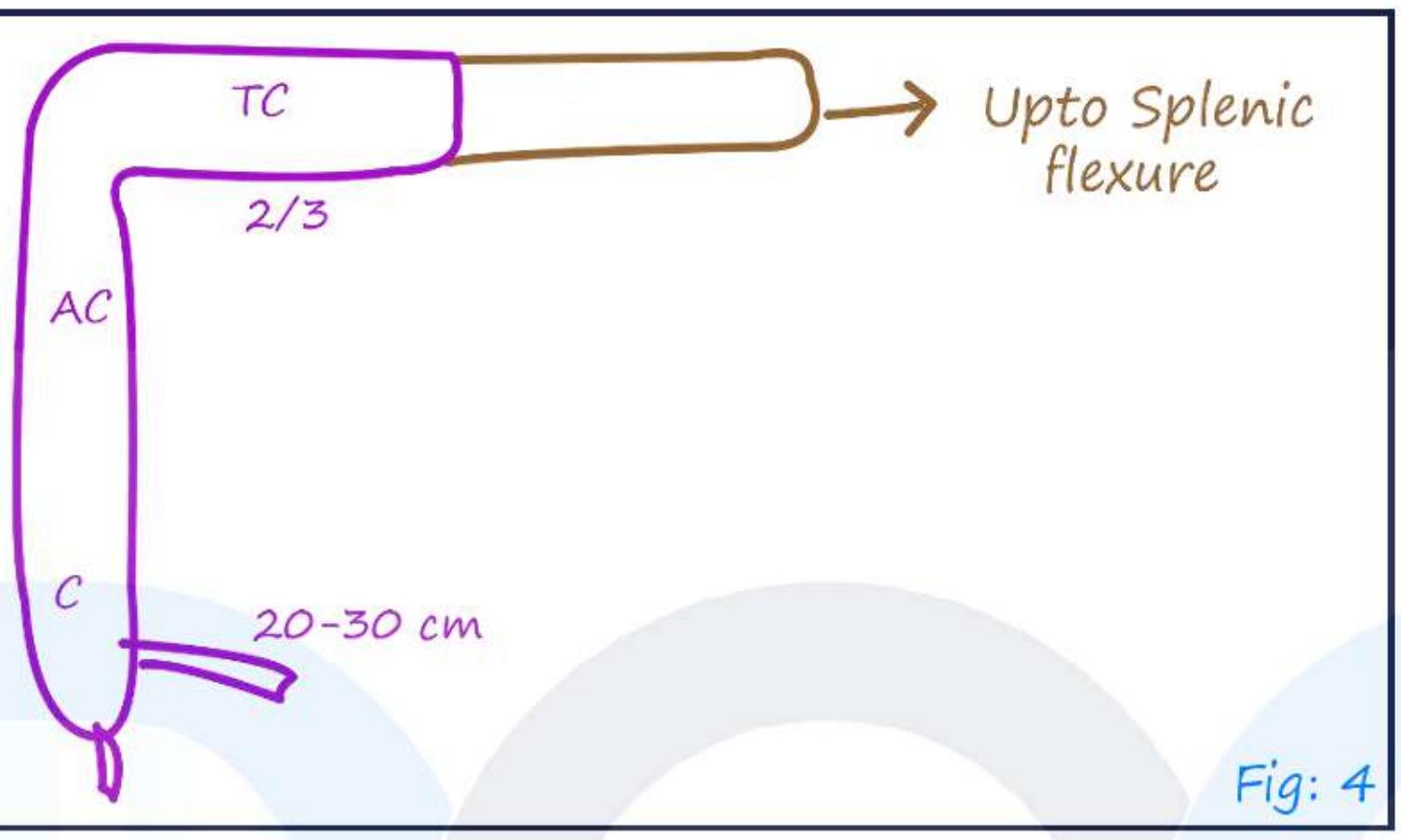

Fig: 4

- Indications
  - Transverse colon growth
  - Hepatic flexure growth
  - Splenic flexure growth

iii. Hemicolectomy

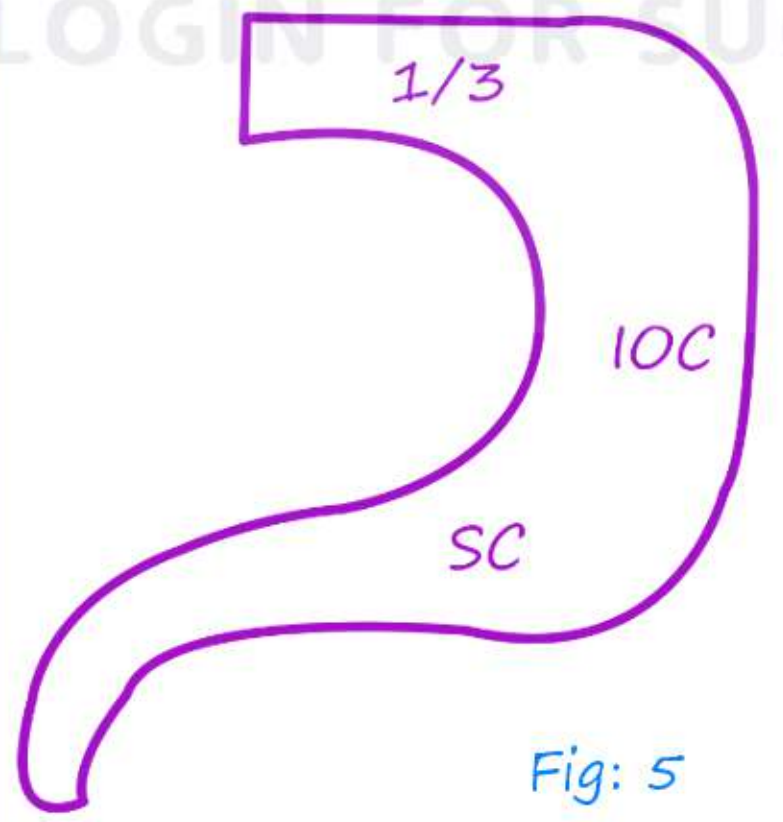

Fig: 5

- Indications
  - Splenic flexure growth
  - Descending colon growth

TUTORIALS
LOGIN FOR SUCCESS

- Sigmoid colon growth
  a. Inferior mesenteric artery is ligated at its origin (old)
  b. Ⓛ colic and sigmoid artery are ligated

Nodes

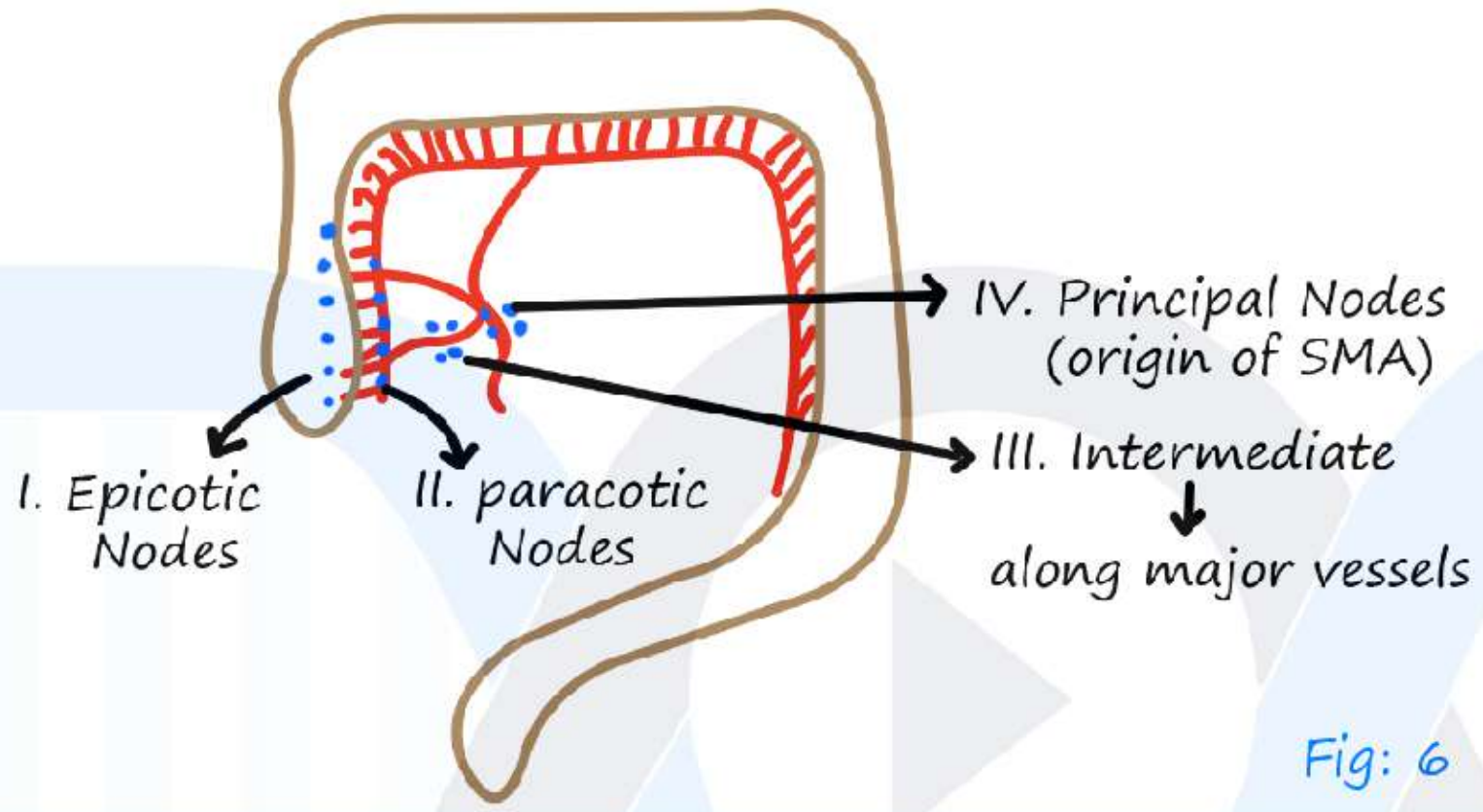

Fig: 6

- Minimum nodes to be removed -12

AnaTalfeen.com

Adjuvant therapy 00:24:00

- Adjuvant chemotherapy only available
- No role for adjuvant RT/ neoadjuvant chemo → tried only for non-obstructive colorectal cancer + liver mets

Staging	Adjuvant treatment
- Stage I (T_1 T_2) - Stage II (T_3 T_4)	- No adjuvant treatment needed

AfraTafreeh.com

- Stage II high risk cases
  - T_4 patients
  - Perforated/obstructed cancers
  - Poorly differentiated
  - <12 nodes removed

  (all of the above) → **FOLFOX 6 cycles**

- Stage III
  - Fol fox regimen 6 cycles
    a. Folinic acid
    b. 5-FU
    c. Oxaliplatin

- Stage IV
  - Liver mets → <3 number: Resection
  - Lung mets → <3 number: Resection

    FOLFIRI x 6 cycles - Folinic acid
    5-FU
    Irinotecan

DOC TUTORIALS LOGIN FOR SUCCESS

- K-ras mutation is tested for all stage IV cases

  ↓

- K-ras ⊖: wild K ras

  ↓

- Monoclonal antibodies
  - Cetuximab: EGFR ⊖
  - Panitumab EGFR ⊖
  - Bevacizumab: VEGF ⊖

On follow up 00:31:21

- CEA:
  - 3 monthly (2 years)
  - 6 monthly (5 years)
- Colonoscopy: Annually (5 years)
- CECT abduction: Annually (3 years)

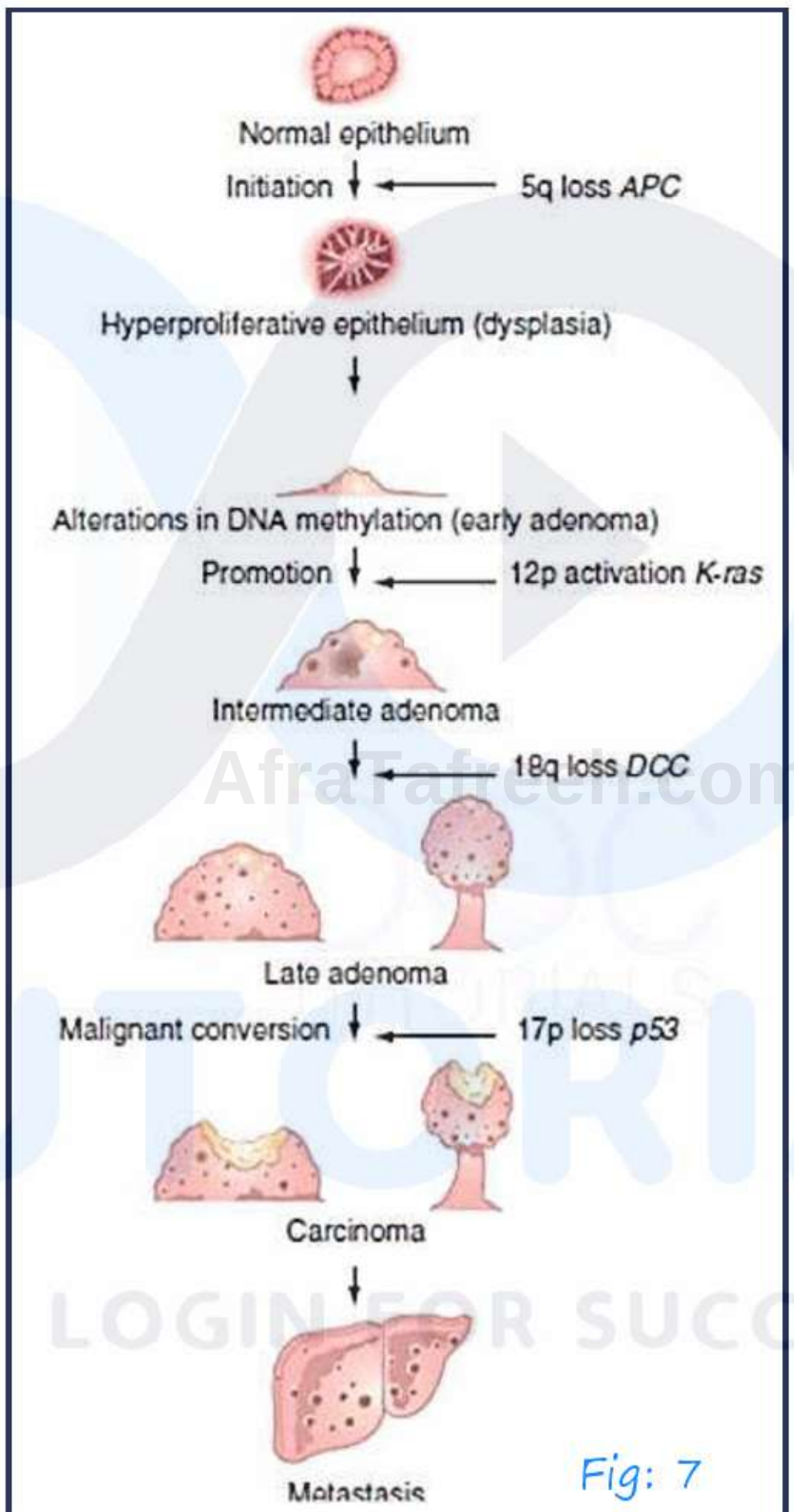

Fig: 7

Risk factors

1. Dietary risk factors:
   - High animal fat
   - Low fibre
   - Alcohol

AfraTafreeh.com

2.Hereditary syndromes:

- FAP
- HNPCC

3.Inflammatory bowel disease (Both UC and CD)

4.Streptococcus bovis bacteraemia

5.Uretero sigmoidostomy

6.Smoking

7.Acromegaly

8.Pelvic irradiation

- Q. In ulcerative colitis ca can arise from flat dysplasia without adenoma carcinoma sequence
- Q. most common mutation in colorectal cancers – p53 mutation
- Q. most common syndrome causing cancer – HNPCC 5%

  FAP 1%

TUTORIALS
LOGIN FOR SUCCESS

APPENDIX

- It is a vestigial organ

Mitrofanoff procedure


Fig: 1

- After radical removal of bladder (or) some other bladder problems, if patient cannot be catheterised chronically(or) a part of urethra is removed (or) continuity is not there. Then we will remove appendix connect the bladder to skin by appendix. This is called (appendicostomy) appendico-vesicostomy
- We can cannulate through it and can drain urine, instead of cannulation from urethra

Malone procedure

- We bring appendix to the skin same like appendicostomy and through appendix we give enema called as antegrade enema

AfraTafreeh.com

Position of appendix

- Most common is lying behind the caecum – retrocaecal position (60% of patients)
- 2nd – facing towards pelvis – pelvic position (25-30% of patients)

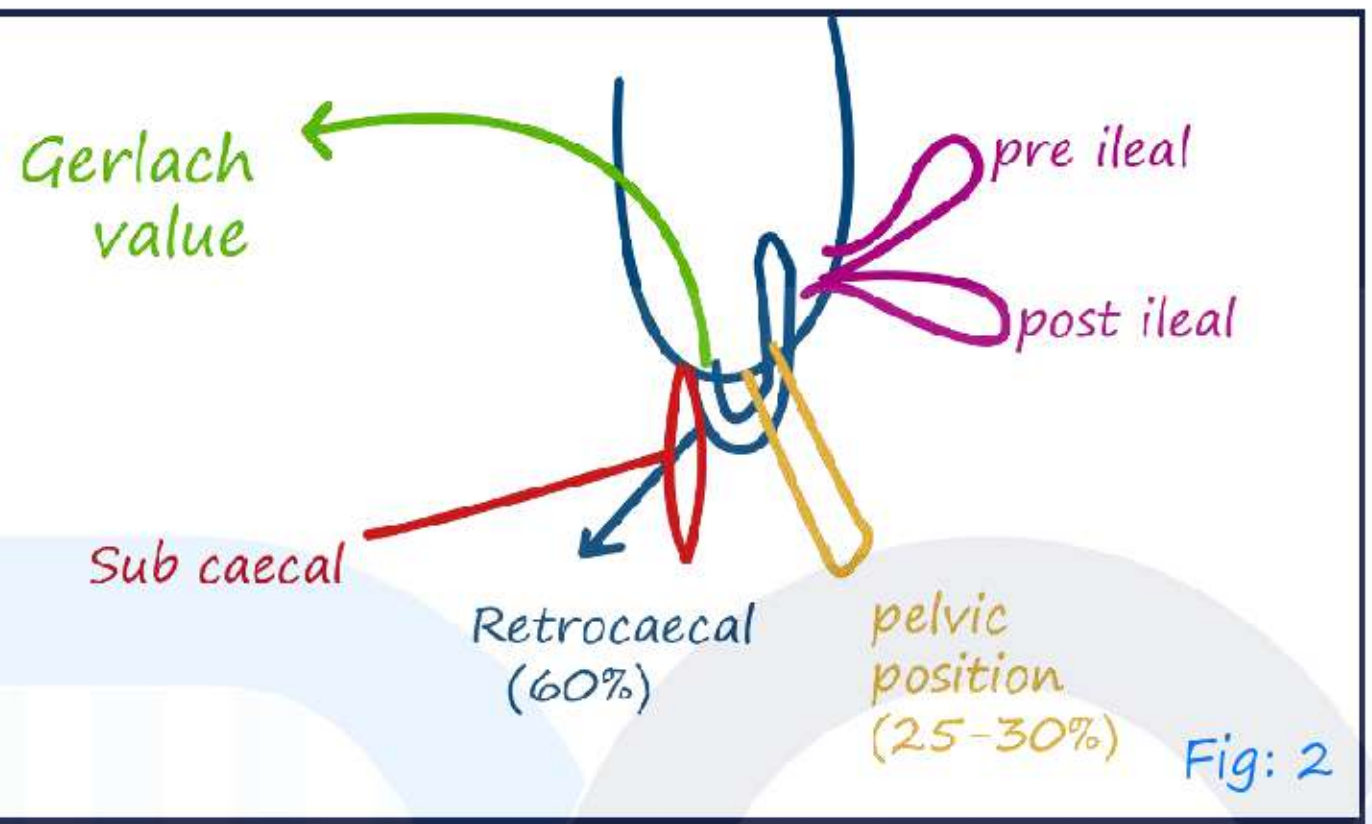

Fig: 2

- Other positions like pre ileal, post ileal, sub caecal are rare
- There is a value present in the appendix called gerlach value. It presents the entry of faecal matter into appendix which can cause faecolith and appendicitis

LOGIN FOR SUCCESS

Various values in surgery

- Heister value – cystic duct
- Gerlach value – appendix
- Bauhin value – ileocecal value
- Kerkring value – Jejunum

  ↓

  aka valvulae connivences
- Houston value – Rectum

↓

Functionless value

Acute appendicitis 00:05:34

- Clinical features: Patient comes with pain, vomiting, fever-murphy's triad
- Pain is migratory pain starts in umbilical area – shifts to right Iliac fossa
- Emergency appendicectomy – most common done emergency surgery world wide
- Line joining umbilicus and ASIS on this line, the junction between medial 2/3 and lateral 1/3 the point is called Mc Burney's point. If there is tenderness at this point when compressed, is called Mc Burney's tenderness
- If we press the Mc Burney's point and remove hand, there is tenderness called rebound tenderness – called Blumberg sign
- If we press in the left iliac fossa, and pain felt on right iliac fossa, it is called shifting tenderness – called rovsing sign
- Klein's sign – is shifting tenderness. Eg: A 10 months girl is coming to us. Palpate in RIF, there is tenderness, immediately turn girl to left side, again compress in RIF, there is no tenderness. Tenderness now moved towards left side

DOCTUTORIALS LOGIN FOR SUCCESS

AfraTafreeh.com

- This test is done to differentiate acute mesenteric adenitis. They mimic pain like appendicitis. If it is mesenteric adenitis as the mesentery moves, the tenderness also moves

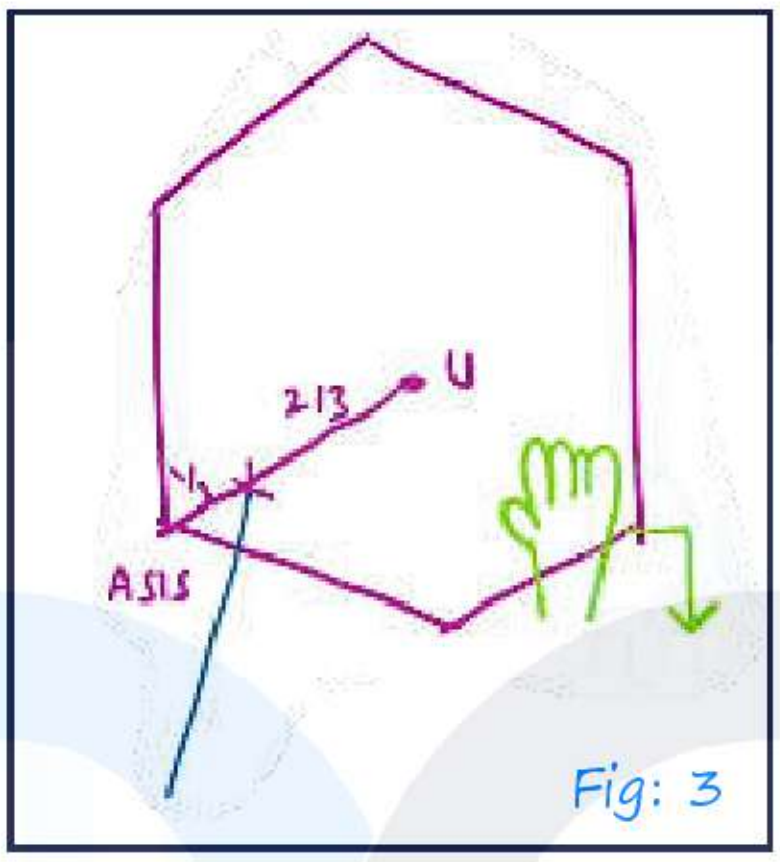

Fig: 3

- The triangle formed from spino umbilical line to umbilicus, midline and right iliac fossa. The triangle is known as sherren's triangle of hyperaesthesia, because of the irritation of abdominal nerves

Tests for retrocaecal appendicitis

- As the patients to lie down in a lateral position & ask to hyperextend the leg backwards, otherwise put the psoas muscle to function on doing this pain is happening called copes psoas test

Tests for pelvic appendicitis

- Ask the patient to lie down supine and ask him to flux the hip and knee and medially rotate the limb.

So, obturator muscle is put into function. It is called copes obturator test

- Hyper extending hip is known as copes psoas test
- Medial rotation of hip is known as copes obturator test

Uncommon named signs

- Aaron sign – We compress the RIF for long period, then patient will tell there is pain in epigastric region (on chronic compression of RIF, there is pain in epigastrium)
- Tenhorn sign – Pull the right testis down, causes pain in appendicitis area
- Bastede sign – Gas inside rectum causes pain in RIF
- Dunphys sign – pain on cough in RIF
- Dasiler sign- If we palpate deep in the appendix, over the iliac crest, if we roll hand, there will be pain in case of chronic appendicitis

LOGIN FOR SUCCESS

Alvardo score 00:16:08

- M – Migratory pain–1
- A – Anorexia–1
- N – Nausea-1
- T – Tenderness – 1+1
- R – Rebound tenderness-1
- E – Elevated temperature-1

AfraTafreeh.com

- L – Leucocytosis 1+1
- S – Shift of neutrophils to left-1 (means there is more of immature neutrophils seen)
  - Give one point to each factor
  - Add one more point to 2 factor T&L i.e., tenderness and leucocytosis
  - So, the total score-10
  - If score ≥7. It is acute appendicitis (in above 90% patients)
  - 1st done investigation if we suspect appendicitis → USG abdomen
  - It shows >7mm thickness, aperistaltic, non-compressible, blind ending loop in RIF is diagnostic of appendicitis
  - IOC: CECT abdomen (Since, USG is 70-80% sensitive only)

    1. It is 90-95% sensitive
    2. It is advised in all patients with extremes of age (children & old age)
    3. In case of doubtful cases, go for CECT
    4. In patient with 2nd and 3rd trimester pregnancy, if MRI is not available, we can go for CT (MRI is IOC)

TUTORIALS
LOGIN FOR SUCCESS

Etiology of appendicitis

- Cause
  - Most commonly known cause is faecolith
  - Ascaris lumbricoides
- Most common organism isolated is bacteroides fragilis
- Most common aerobe – E. coli

Complications of acute appendicitis 00:21:55

Rupture of acute appendicitis – Appendicular perforation

- Most common in extremes of age
  - Important predisposing factors of rupture are immunocompromised status like HIV, diabetes
  - It is most common at tip - antimesenteric border (meso appendix)
  - Pelvic appendicitis will commonly rupture
  - If rupture happens in 24 hours, more dangerous, because omentum Would not have reached this area, so diffuse peritonitis is seen. If it ruptures >24hours, there will be localised peritonitis as it is covered by omentum
  - Early antibiotics will not prevent rupture
  - Surgery is the best, prevents rupture
  - No air under diaphragm seen

AfraTafreeh.com

- T/T of choice – Emergency lap/ open appendectomy is done at the earliest

Appendicular abscess

- It can form pelvic abscess and retroperitoneal abscess. Because of inflammed appendix
- Abscess can cause symptoms like fever with chills & rigor
- Immediately do USG guided drainage
  - i. Retrocaecal abscess – drained by retroperitoneal way
  - ii. Pelvic abscess – drained by pervaginal (or) per rectal route
    - After draining of abscess, we have to do appendicectomy in same admission, known as index appendectomy

TUTORIALS
LOGIN FOR SUCCESS

Appendicular mass

- The inflamed appendix is sealed with omentum and surrounding small bowel and fat and form a mass which is protective
- We can not do surgery now because we may damage bowel and cause enterocutaneous fistula
- So, we do **ochsner sherren** conservative regimen
  - Ryles tube aspiration
  - Bladder drainage
  - I.V.F

- Antibiotics
- NPO

- Charts – pulse temperature chart
  - BP chart
  - Input/ output chart
  - Size of mass chart
- Indication to abandon conservative treatment and go for surgery
  - If increase pulse rate
  - Increase temperature
  - Chills/ rigor
  - Increase ryles tube aspiration/ vomiting
  - Increase mass
- Suspiciousness of cancer
- If everything is fine, we ask patient to go home and come back after 6 weeks for an **interval appendectomy**

Surgical aspect of appendectomy 00:31:43

Open appendectomy

- Conventionally done, not done now a days

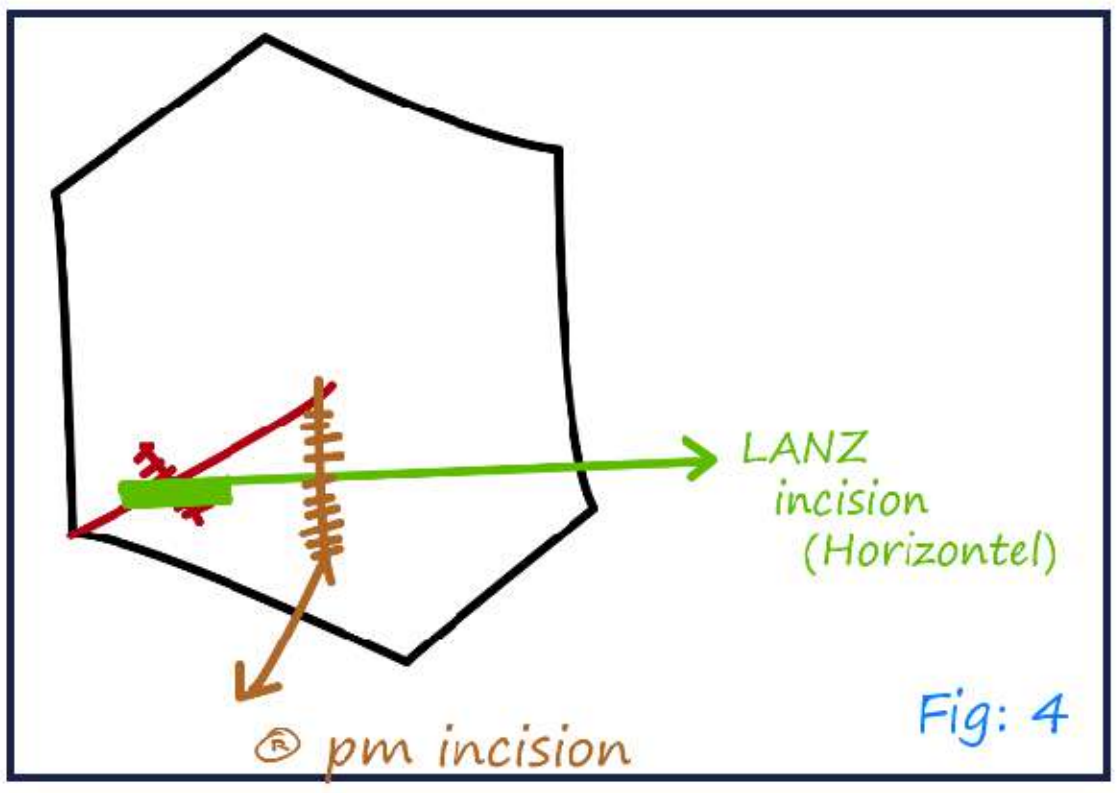

Fig: 4

AfraTafreeh.com

- Incision is made perpendicular to Mc Burney's point known as Mc Arthur (or) grid iron incision
- Through this we go inside and remove appendix
- Lanz incision is put when we need a cosmetic scar. It is a horizontal cosmetic incision
- If appendix is difficult to deliver (or) if we suspect a mass, they another incision called right paramedian incision is given
- While removing appendix we ligate appendicular vessels and we will crush the base and put a trans-fixation suture at that point

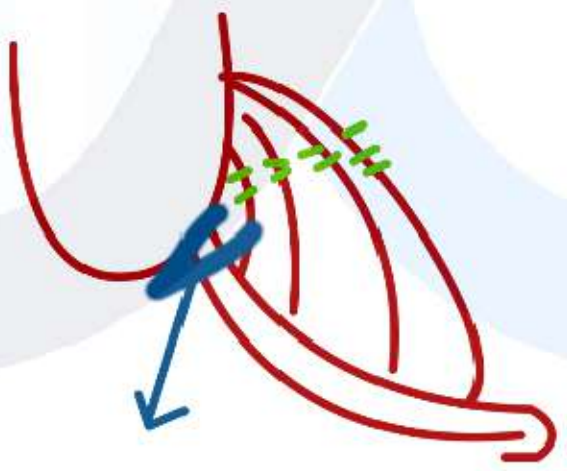

Fig: 5

- Will crush the base and put a trans-fixation suture at that point
- Crushing of appendix is nor advised in cases (avoided in)
  - Severe inflammed appendix base
  - Crohn's disease in caecum
  - Because it may lead to enterocutaneous fistula
- Most common nerve injured in grid iron incision
  - Iliohypogastric nerve – most common injured > then ilio inguinal nerve

- Rutherford Morrison incision is a muscle cutting incision. All others are muscle splitting incisions
- Now a days we use lap by 3 ports
  - One is camera port (10mm), other two are 5mm ports
  - Appendix is removed by 3 port technique
- First lap appendicectomy is done by kurt semm (Gynaecologist). As he was doing hysteroscopy, he has done appendectomy
- On lap – we have some scenarios found inside

i. Normal looking appendix
  - Then we look for other pathologies like Meckel, ovarian pathology, ureteric stone etc.
  - If everything is found normal, we have to do appendectomy, to avoid future confusion

ii. On putting port inside – we see active crohns in terminal ileum and appendix looks normal appendicectomy is done

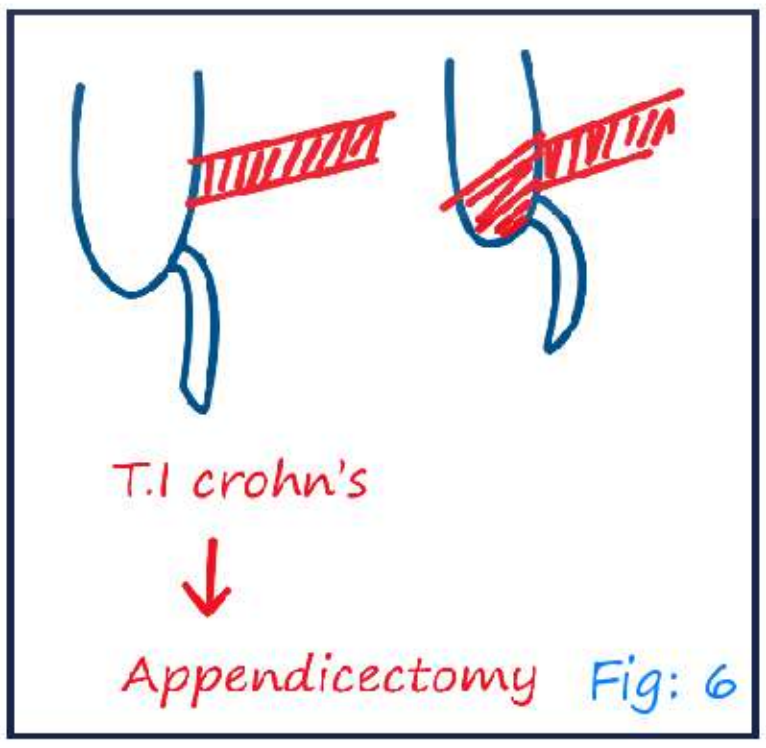

Fig: 6

iii. On putting port – Appendix looks normal, but there is inflammation of terminal ileum and base of caecum i.e., active crohns at base of appendix

AfraTafreeh.com

- Then don't do appendicectomy, leave it to avoid enterocutaneous fistula

iv. Put a port – we see inflamed ileum, inflamed caecum and inflamed appendix (crohns + appendicitis)

- Remove it, but don't crush the base

v. Normal appendix, while we are doing some other surgery i.e., incidental appendicectomy – should not be done. Not advised in any patient

- Non operative treatment of acute appendicitis is not advised, unless the patient has a risk of surgery

Pregnancy and appendicitis 00:41:12

- In pregnancy, the most common non obstetric surgical emergency is this
- Most common in 2nd trimester and IOC is MRI
- USG – first done investigation
- CT scan – can be done in 2nd and 3rd trimester
- Problem here is many symptoms are overlapping, preg. Patient may vomit, fever → there is difficulty in clinical diagnosis
- B/O uterus MC Burney's point is also shifted up.
- There is high risk of miscarriage seen
- We can do lap appendicectomy, but don't put veress needle, but go for open method of gas insufflation

DOT TUTORIALS LOGIN FOR SUCCESS

- No role of conservative management in pregnancy, when confirm appendicitis, surgery is the gold standard

Overview tumours in appendix 00:44:00

Tumours in appendix

- **NET (Neuroendocrine tumor)**
  - ↓ Carcinoid tumor
  - ↓ It is overall most common tumor of appendix. It has 0.9 in incidence of G.I tumors
- **Epithelial tumors**

Epithelial tumors

- **Benign**
  - ↓ Adenomas
  - ↓ Tubular, Tubulovillous, Villous
- **Malignant**
  - ↓ Incidence is <0.5%
    - **Mucinous adenocarcinoma**
    - **Signet ring cell adeno ca**

AfraTafreeh.com
DOC TUTORIALS LOGIN FOR SUCCESS

- Low grade appendiceal mucinous neoplasm (LAMN)
- High grade appendiceal mucinous neoplasm (HAMN)

AfraTafreeh.com

- Mucinous adenocarcinoma
  - The major problem with mucinous neoplasms is they may rupture and produce **pseudomyxoma peritonei**
  - If LAMN is detected, watch it closely and keep patient on follow up
  - HAMN – has high risk of rupture, so, do right hemicolectomy + peritonectomy + bilateral salpingo oophorectomy
  - For case of mucinous adeno carcinoma, the same surgery is treatment of choice
  - If it is an established pseudomyxoma peritonei case, i.e., abdomen full of mucinous tissue, then do CRS-cyto reductive surgery
  - Most common cause of pseudomyxoma peritonei
    i. Mucinous neoplasm of appendix
    ii. Mucinous neoplasm of ovary

TUTORIALS
LOGIN FOR SUCCESS

CRS

- Remove lot of organs
- Right hemicolectomy + B.S.O + cholecystectomy + splenectomy + omentectomy + peritonectomy + Gastrectomy + left hemicolectomy + renal resection
- Surgery takes around 10 hours
- After surgery, we do HIPEC (Hyperthermia Intraperitoneal Chemotherapy)

- In spite of CRS and HIPEC, patients have poor prognosis

Risk factors for perforation of appendix

- Extremes of age
- Immune suppression
- Diabetes mellites
- Faecolith obstruction
- Pelvic appendix
- Previous abdominal surgery
- Carcinoid tumor in the tip of appendix
  - If it is <1cm, at the tip → go for appendicectomy
  - >2cm, at tip → go for right hemicortectomy
  - If 1-2cm with infiltration towards mesoappendix, go for right hemicolectomy
- Modified delphi classification of appendiceal tumours

TUTORIALS
LOGIN FOR SUCCESS

AfraTafreeh.com

INTESTINAL OBSTRUCTION

- The 4 cardinal features of intestinal obstruction
  i. Colicky abdominal pain
  ii. Distension of abdomen
  iii. Patient will have bilious vomiting
  iv. Obstipation patient will not pass motion, flatus
- If colicky abdominal pain becomes a dull aching pain, it is a very bad sign i.e., bowel has gone for gangrene
- Most common cause of distension abdomen is swallowed gas GI secretions
- Following bilious vomiting, distension decrease and pain decrease
- Immediately we put ryles tube in intestinal obstruction cases is to decompress the stomach, so that G.I secretions will come up through tube and there is less pain
- Obstipation means absolute constipation → patient don't pass flatus/ faeces
- In spite of intestinal obstruction, there is no obstipation in following cases
  - Richter's hernia → circumference of the bowel is obstructed. So, they will have diarrhoea instead of obstipation
  - Gall stone ileus – Gall stone occluding the bowel
  - Acute superior mesenteric artery ischemia

TUTORIALS
LOGIN FOR SUCCESS

- On opening abdomen, whether it is S.I obstruction (or) large intestine obstruction. We can tell by seeing on organ caecum
- In large bowel obstruction – caecum is distended
- In small bowel obstruction – caecum will be collapsed
- Exception: In case of L.B.O caecum is not distended; it is due to incompetent ileocecal valve caecum is not distended and patient will have feculent vomiting
- The name of the valve is bauhin's valve
- If the caecum is distended and ileocecal valve is patient, there results in obstruction in which food particles enter colon and cannot go further, at the same time cannot go back. This results in closed loop obstruction
- Closed loop obstruction is dangerous. Here contents enter colon and cannot move forward/backward can lead to rupture
- Competent ileocecal valve results in closed loop obstruction

AfraTafreeh.com
TUTORIALS
LOGIN FOR SUCCESS

Classification of intestinal obstruction

- **Pediatric**
  - New born
  - Children
- **Adult**
  - Small bowel obstruction
  - Large bowel obstruction

AfraTafreeh.com

New born

- Most common causes – Duodenal atresia
- Other causes
  - Jejunal atresia
  - Ileal atresia
  - Annular pancreas
  - Midgut volvulus
  - Meconium ileus

Children

- Most common causes – Intussusception
  - Hernia
  - Stricture
  - Benign tumors

Small bowel obstruction

- **Dynamic** SBO
  ↓
  Most common causes are adhesion
  - Hernia
  - Stricture
  - Tumors
- **Non dynamic** SBO
  ↓
  Paralytic ileus

DOC TUTORIALS LOGIN FOR SUCCESS

Large bowel obstruction

Dynamic LBO

↓

Most common cause
- cancer colon
- Volvulus
- Strictures

Non dynamic LBO

↓

Due to ogilvie syndrome (similar to paralytic ileus) (pseudo obstruction of colon is the another name of non-dynamic LBO)

Paralytic ileus

- Physiological phenomenon
- Most common after abdominal surgery
- After opening abdomen bowels will go for ileus & they recover one by one
- 1st structure to recover is small intestine. It recovers in 24hours
- 2nd structure to recover is colon. It recovers in 48 – 72hours
- 3rd structure to recover is stomach – It can take 5 days
- Most common cause of prolonged ileus is electrolyte imbalance

↓

Most common – Hypokalaemia

DOC TUTORIALS
LOGIN FOR SUCCESS
AfraTafreeh.com

AfraTafreeh.com

Intussusception

- It is the most common causes of intestinal obstruction in children
- It is most common in 6months to 1year age
  - Most common type of it is Ileo-colic (Ileum into colon)
  - Most common aetiology in children 6months – 1year is due to hypertrophied payer's patches
  - Hypertrophied payer's patches are most common following respiratory viral infection -occurs during weaning time. Most common respiratory virus causing it is rhino virus (not rotavirus)

Intussusception in infants

- In infants the hypertrophied payer's patches pull the ileum into colon
- The outer tube is known as intussucipien
- Inner tube is known as intussusceptum
- There is lead point (or) apex
- Ileocolic intussusception is most common type
- Clinical features → Baby presents with
  - Red currant jelly stools
  - Vomiting
  - Abdominal pain
- O/E – Baby right iliac fossa is empty called Ledance sign

TUTORIALS
LOGIN FOR SUCCESS

- There is sausage shaped mass palpable towards the umbilicus

- IOC → USG abdomen → It will show target sign/bull's eye sign/pseudo kidney sign
- Ba enema show
  - Claw sign s
  - Coiled spring sign
- T/T of choice → under USG guidance – give saline/air enema
  - It can happen in children, adults, old age people also
    i. Children → Most common causes – Meckel's diverticulum
    ii. Adults → Most common causes – Benign tumors
    iii. Old age → Most common causes – Tumors
    ↓
    Most common type is colo-colic type
- In these people, we do surgical reduction. We should not pull it, but we have to milk it from above downwards
- After reducing look for any pathology, probably it is a tumor resected/Meckel's resected → Accordingly, we can manage

AiraTaleem.com
TUTORIALS
LOGIN FOR SUCCESS

AfraTafreeh.com

Meconium ileus 00:22:40

- Usually meconium is passed within 48hours
- If it is not passed >48hours → call it meconium ileus
- Most common causes of meconium ileus – cystic fibrosis/mucoviscidosis
- Early presentation of cystic fibrosis is obstruction of the terminal ileum by the dark, thick pebbled out meconium
- On X-ray → No air fluid level is seen
- If not treated, meconium ruptures into peritoneal cavity and causes M-peritonitis
- IOC: Gastrograffin G.I contrast study

Treatment

- 1st line – We give mypaque enema. It is low osmolar enema
  - Gastrograffin – High osmolar → will go and dissolve the meconium in terminal ileum & pass meconium
- 2nd line – If baby not respond to enema, then do Bishop koop operation
  - In this OP – cut the ileum and bring one end out and do ileo ileal anastomosis. That one end is brought out as ileostomy

DOC TUTORIALS LOGIN FOR SUCCESS

- Through this, ileostomy, whatever meconium getting obstructed, we can give wash through this ileum. It is a chimney shaped ileostomy

Mal rotation of gut 00:27:00

- By 6th week of intrauterine life, entire midgut comes out based on superior mesenteric artery and lie in amniotic cavity
- By 10th week, they will go back and assembled inside abdomen
- As they going back, following anomalies may happen

i. Non rotation of gut
  - It will go inside as such without rotation. It is due to a bond extending from duodenum to ascending colon called LADD's band
  - It is totally non rotated gut

AfraTafreeh.com
TUTORIALS
LOGIN FOR SUCCESS

ii. Mid gut volvulus
  - Midgut go for torsion, volvulus is seen (hollow viscous is volvulus)
  - Torsion is around S.M artery axis. It goes for a clockwise rotation, so there is obstruction happened in the bowel. It is more dangerous Ladds band is seen in these cases also

AfraTafreeh.com

iii. Partial malrotations of gut

- All these will have bilious vomiting because of Ladd's band obstructing
- A new born baby with bilious vomiting, should be taken serious
- Causes of bilious vomiting
  - Duodenal atresia
  - Jejunal atresia
  - ileal atresia
  - Malrotation
  - Midgut volvulus
- IOC: Gastrograffin contrast study
- On CECT abdomen – whirlpool sign is seen (in any volvulus)

↓

This sign is due to mesentery is rotating around the SMA

TUTORIALS
LOGIN FOR SUCCESS

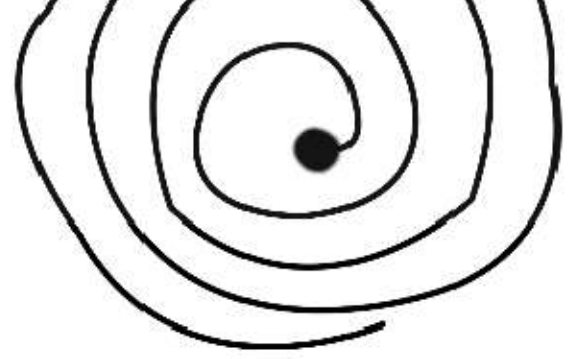

- The moment we diagnose – shift them for surgery and do ladd's procedure
- It has 4 steps
  - Step 1: Derotate the volvulus

- Step 2: Look for ladds band and remove ladd's band (or) any other band
- Step 3: Keep small bowel duodenum, jejunum and ileum on right side and large bowel
- AL, TC, DC will keep on left side

- Since we keep large bowel on left side, the caecum & appendix will be there on left side & cause future confusion
  - Step 4: we do appendectomy
- Ladd's procedure is classical treatment of midgut volvulus

Adult causes of intestinal obstruction

- Small bowel obstruction: causes
- Findings on x-ray → previously we used to do x-ray abdomen erect
- As per bailey, now-a-days, x-ray supine view is enough for the diagnosis of intestinal obstruction
- On x-ray abdomen erect → classical findings – the normal air fluid levels are 3-5 (minimum)
- If more than 5 fluids levels, it is pathological
- In supine view – we cannot see typical step ladder pattern, which is seen in the erect x-ray (on obstruction)
- On erect view x-ray → step ladder pattern is seen >5 fluid level seen

AfraTafreeh.com

- In x-ray supine view → in the air fluid level, the air column is >2.5cm, it is pathological
- On x-ray, if there is more fluid and less air then we get string of pearls appearance
- In dynamic SBO obstruction colonic gas and rectal gas are absent
- IOC: CT scan with oral gastrograffin

SBO causes

Dynamic obstruction	Non-dynamic obstruction
- Obstruction by means of a pathology - Patient has colicky pain, vomiting, abdominal distension, obstipation - Bowel sounds are exaggerated - X-ray abdominal erect ↓ Shows classical stepladder pattern with no gas in colon & rectum Causes: Most common is adhesions due to previous surgery Other – Hernia, cancer, stricture **Treatment:** - NPO - IVF - Electrolyte correction - For adhesion ↓ Wait & watch for 24-48 hours – to resolve on its own	- Due to paralytic ileus - Patient has no pain, abdominal distension⊕. May have vomiting - Sometimes flatus may pass - Bowel sounds absent - We have multiple air fluid levels with presence of gas in colon and rectum - Most common causes is post op electrolyte imbalance (most common-hypokalaemia)

TUTORIALS LOGIN FOR SUCCESS

- For other causes of dynamic obstruction – sun should never set (or) rise like hernia
  - The more you delay – there will be bowel gangrene (for other cases)

Treatment for non-dynamic/paralytic ileus

- With all the NPO, IVF, electrolyte correction, we can wait for 48-72 hours
- If they pass flatus – no problem
- If they don't pass flatus after 48-72 hours, we should ensure dynamic obstruction is not there
- Then give Inj. neostigmine (catch pole regimen)
- If given in presence of obstruction – immediately bowel rupture and patient will die
- In adhesion, obstruction after 48hours, we should go for laparoscopic adhesiolysis
  - Repeated lap adhesiolysis can be done

TUTORIALS LOGIN FOR SUCCESS

Large bowel obstruction 00:47:29

- Causes → most common causes is Ⓛ colonic cancer
- 2nd most common – sigmoid volvulus

AfraTafreeh.com

Volvulus

- 2 types → caecal volvulus, sigmoid volvulus
- Sigmoid colon – most common to develop volvulus, because it has long mesocolon, so more chances
- Important predisposing factors of sigmoid volvulus are

  i. High fibre diet

  ii. Long redundant sigmoid colon

  iii. Most common is males (old males)
- This part of sigmoid colon goes to rotation in anti-clockwise than clockwise

Caecal volvulus

- It is a misnomer because caecum alone is not rotating caecum + ascending colon are rotating together, so called caeco colic volvulus
- Most common in females
- Predispose due to repeated pregnancy
- CV is most common in young female
- Sigmoid volvulus is most common in old males
- In caecum bascule, caecum alone can rotate Antero-posteriorly
- All the volvulus rotates clockwise except sigmoid volvulus – Anticlockwise
- X-ray of caecal volvulus show comma shaped colon

  - Sigmoid volvulus – bent inner tube appearance/coffee bean appearance

- On Ba enema → sigmoid volvulus → bird beak (or) ace of spade appearance

Management of caecal volvulus

- Right hemicolectomy
- Caecopexy is contraindicated

Management of sigmoid volvulus

- Step I → sigmoidoscopic reduction (or) rectal tube & plan for elective sigmoid colectomy
- Definitive treatment – sigmoid colectomy

Pseudo-obstruction of colon

Acute
↓
Called Ogilvie syndrome
↓
Patient present with c/o abdominal distension

Chronic
↓
Causes – Neurological
– Parkinson's CVA
– Laxative abuse
– Self-enema
– Narcotics

AfraTafreeh.com

- In pseudo-obstruction of colon, there is no organic obstruction. Bowel is not moving due to various causes
- Clinical features: for these patients
  - Severe abdominal distension
  - Constipation ⊕

AfraTafreeh.com

- No vomiting
- No pain
- Flatus passage⊕
- These patients should be closely monitored

- If caecum becomes >14cm dilated → it is serious & we have to attend to him immediately

Step in management of acute pseudo-obstruction of colon

i. Colonoscopic decompression
   - Patient is made to sit on commode
   - Inj. atropine should be ready and constant ECG monitoring done

ii. Inj. neostigmine 1mg stat is given
   - Immediately patient passes stools, because colon contracts vigorously and pass stool
   - Totally maximum 2 doses of neostigmine can be given

iii. Even with the above, the patient not pass stools then we go for subtotal colectomy with ileo-rectal anastomosis

- 2 emergency procedures on colon

a. Hartman's operation:
   - In colon, if there is a pathological segment (cancer/diverticulum etc causing acute obstruction)

LOGIN FOR SUCCESS

- Here, we remove the pathological segment, we bring the proximal colon as colostomy. We close the rectum and leave it as rectal stump known as Hartman's pouch
- Harlman's reversal is made after 6 weeks

b. Paul Mikulicz operation:

- Done if there is no time to even resect the lesion/patient is very sick for resection we bring the proximal bowel (colon) as colostomy
- Distal bowel is also brought out as colostomy called mucus fistula, pathological segment is not removed (or) we can bring the colon as loop colostomy the motion & mucus both come out, known as loop colostomy. It is an emergency decompression procedure (Done if even Paul Mikulicz is also can't be done)

TUTORIALS
LOGIN FOR SUCCESS

AfraTafreeh.com

STOMAS

Introduction and Types 00:00:11

Ileostomy	Colostomy
• Usually created in right iliac fossa	• Usually in epigastric region (or) left iliac fossa
• Protruding out as contents are more of liquid	• done with transverse or sigmoid colon
• Brooke's ileostomy	• flushed to surface
• Kock's Ileostomy ↓ Continent	• Non continent

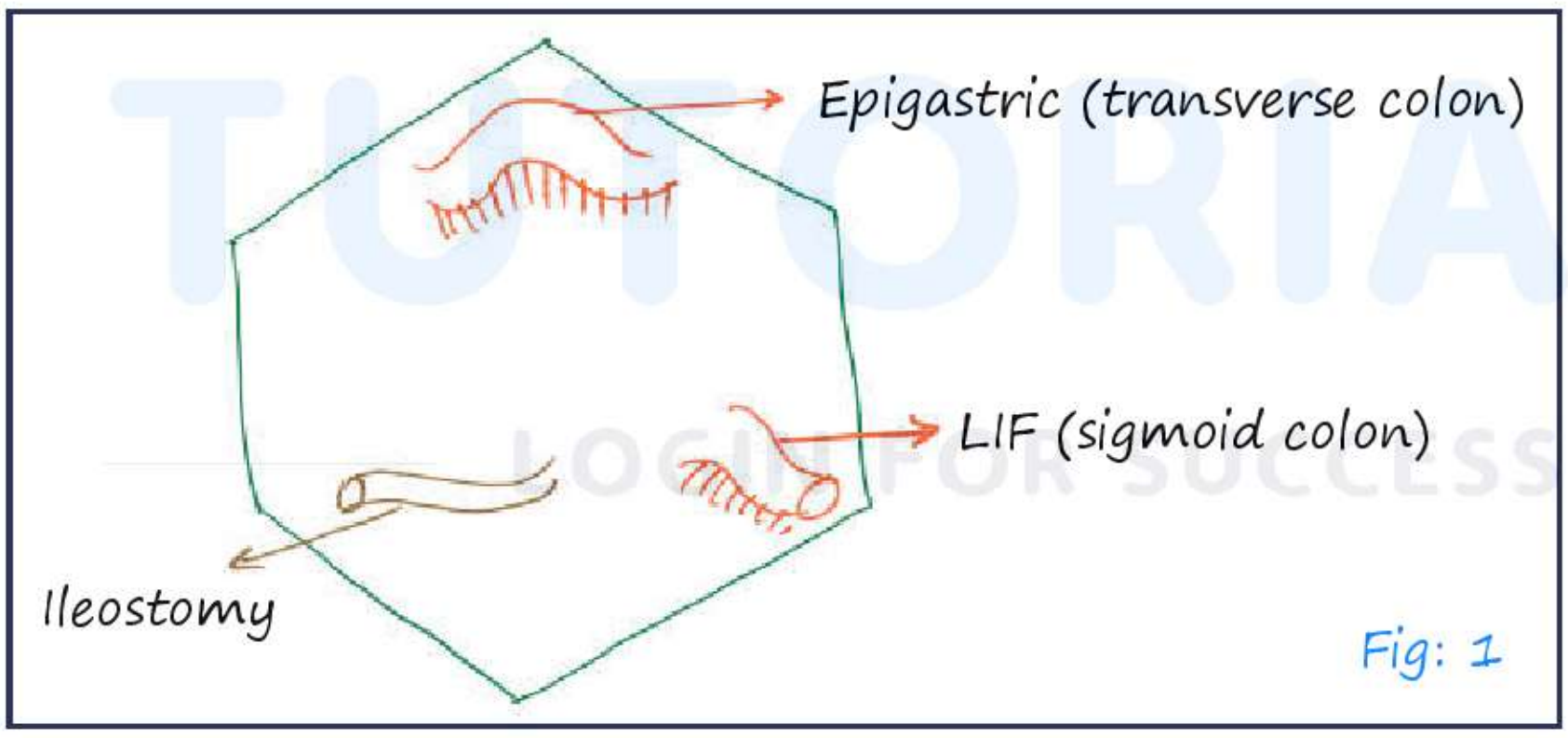

Fig: 1

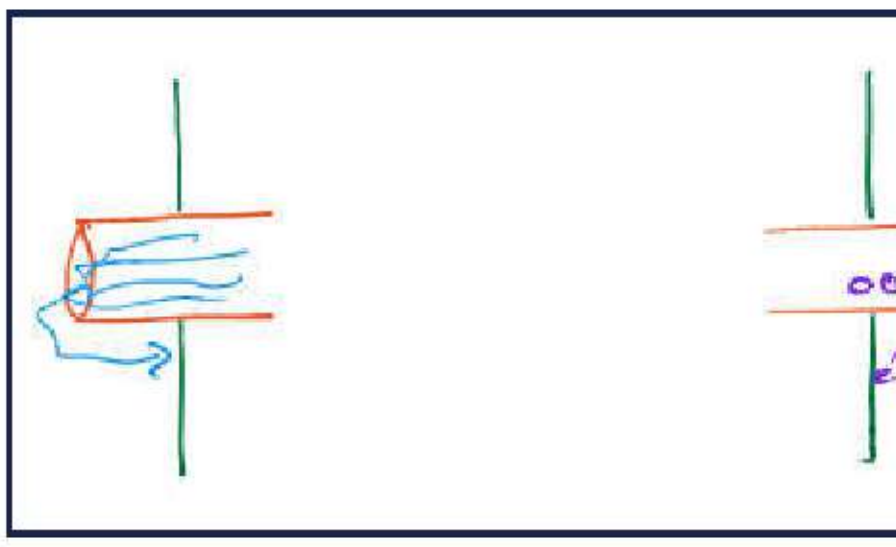

Fig: 2

Complications 00:03:44

Ileostomy	Colostomy
• Skin excoriation (most common) • Fluid/electrolyte imbalance • Ileostomy necrosis (earliest) • Stomal prolapse • Parastomal hernia 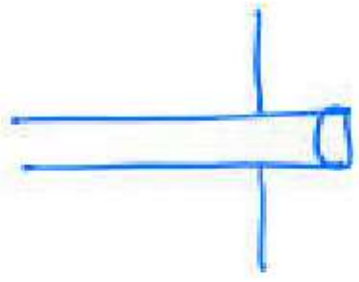 End Ileostomy 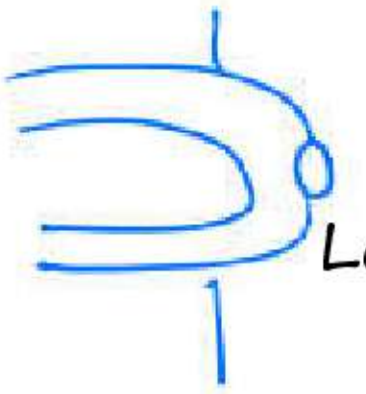 Loop Ileostomy	• most common comp – parastomal hernia  Parastomal hernia ↓ Nearby stoma there is weakness and bowel comes out • Colostomy itself can come and protrude itself ↓ Stomal prolapse • Most common indication for re-do-surgery – parastomal hernia  End Colostomy Loop Colostomy

AfraTafreem.com
TUTORIALS
LOGIN FOR SUCCESS

AfraTafreeh.com

- Q. Parastomal hernia – most common after end colostomy
- Stomal prolapse – common after loop colostomy

↓

Distal loop is more common to prolapse.

Surgeries of Parastomal Hernia 00:08:40

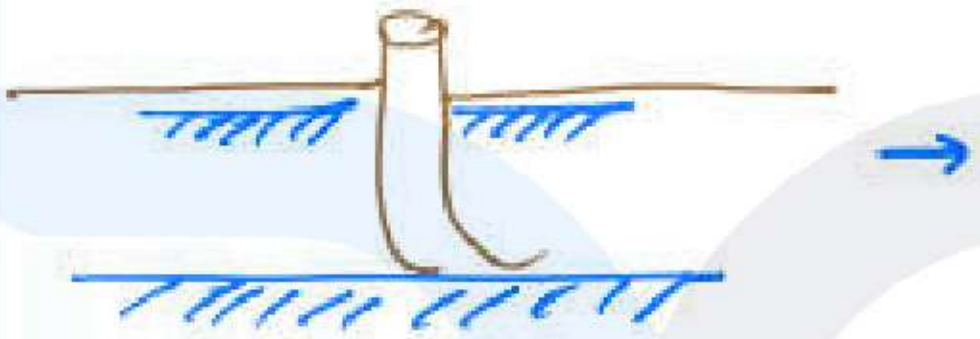

Sugar baker procedure

Fig: 3

Indications of Colostomy 00:09:43

Indications of colostomy

Elective

↓

1. Diversion procedure for a distal anastomosis to heel.

Temporary diversion ileostomy

Emergency

↓

1. Hartman's operation
2. Paul Mikulicz
3. Diversion loop colostomy for a distal obstruction
4. Trauma (clip & drop method)

Permanent Stoma 00:12:05

1. Ulcerative colitis + Anus involvement

   FAP ↓ + Anus involvement

   Total procto-colectomy + Anus

   ↓

   Permanent colostomy

2. Ca rectum in lower 1/3 + Anal adenocarcinoma

   Abdominal perineal resection → permanent colostomy

Fig: 4

LOGIN FOR SUCCESS

AfraTafreeh.com

BENIGN – RECTUM & ANUS

- Haemorrhoid → Haemorrhoid is a prolapsed anal cushion. It usually presents with painless bleeding per rectum (most/common)
  - Grade I – Present only, they don't come out
  - Grade II – They come out and go in by themselves
  - Grade III – They come out and pt has to push them inside
  - Grade IV – Prolapsed haemorrhoids not going in

Treatment

- Grade I can be treated by injection sclerotherapy by a Gabriel syringe we use 5% phenol in almond oil
- Grade II – Can be treated by rubber band application
- Grade III – and grade IV needs surgery
- Open haemorrhoidectomy is called Milligan Morgan Haermoridectomy – Here 3°, 7°, 11° haemorrhoids are removed after the removal the anus should look like a clover. If it looks like clover the problem is over
- If it looks Dahlia, it will go for stricture
- Closed method of Ferguson → of the raw area is closed by the sutures, it is closed method
- Most common complication of hemorrhoidectomy is urinary retention, due to pain and spinal anesthesia
- Next complication is bleeding
- Latest method used is circular stapler method, we do hemarroidopexy. We push the prolapsed anal

cushion upwards known as LONGO procedure.
Longo operation of stapled haemoroidopexy

Fistula in ANO 00:04:50

- Classified by park's classification
  - Type I – Inter sphincteric fistula
  - Fistula tract running
  - Most common type
  - Between external & Internal sphincter
  - Type II – Trans sphincteric fistula
  - Fistula tract going between 2 muscles
  - Type III – Supra sphincteric
  - Type IV – Passing above the levator ani, aka extra levator fistula
- Tran sphincteric and inter sphincteric are known as low fistula
- Supra sphincteric and extra levator fistula are known as High fistula
  - IOC: MRI pelvis (Fistulogram)
  - Most common causes of fistula in Ano are cryptoglandular abscess
  - There is connection with outsides and it connects into anus (or) rectum
  - To find out where its connected is found out by a rule called Good sall rule
  - Anterior fistulas are straight and opens in anus
  - If posterior fistulas have a horse shoe tract & drain only in mid line at 6 o clock position

AfraTafreeh.com
TUTORIALS
LOGIN FOR SUCCESS

AfraTafreeh.com

- In anterior, if fistula is > 3.5 cm away it forms a long horse shoe tract and open posteriorly. It is exception to Good salls rule
- Treatment: Fistulectomy (or) Fistulotomy – lay open the tract
  1. VAFT Excision → Video assisted fistula tract excision
  2. LIFT → Ligation of Internal opening of fistula tract
  3. SiS plug → Small intestine submucosa of pig is used to plug

Jeeper's Bottom / Pilonidal Sinus

- Common in people who are continuously sitting and in drivers, because of continuous vibration the air will go inside and produce an abscess and it will come out as fistula / sinus / Opening
  - We have air inside the sinus opening
  - Tl is treated by excision of sinus tract
  - It recurrence – Do rhomboidal flap called limberg flap (or) Bascom technique flap
  - Here, we make the gluteal cleft completely disappear, no gluteal line

DOC TUTORIALS LOGIN FOR SUCCESS

Rectal prolapse 00:11:00

- Common in females due to repeated pregnancy, the pelvic floor weakens and they develop rectal prolapse
- 2 methods of treatment
  i. Perineal repair
  ii. Abdominal procedures
- Peripheral repair procedures are

i. Thiersch wiring – No more done
↓
Previously done for children and unfit patient
ii. Altemeier's → Trans anally, we do proctosigmoidectomy
↓
Rectum and redundant sigmoid colon removed
iii. Delorme's – it is plication of mucosa inside

NOTE: all these perineal procedures have 20-30% recurrence

AfraTafreeh.com
DOC TUTORIALS LOGIN FOR SUCCESS

Abdominal Procedures

i. The prolapsed rectum is pulled up and fixed to the sacrum, if we mix with mesh only on posterior well's posterior rectopexy
ii. If we encircle the mesh anteriorly and fix it, called Ripstein anterior rectopexy. It can result in constipation. Not done now a day
iii. If sigmoid colon is redundant, we will do resection rectopexy. This is called Frykman and Goldberg operation

Invertogram

- In a new born baby, we keep a coin at level of anus and take x – Ray called invertogram. Usually done after 24 hours. Done for babies born with imperforate anus
- The swallowed gas is seen as it reaches terminal part of bowel make the baby lie in prone position & back side little elevated. Based on pelvic floor, we

AfraTafreeh.com

name it as low imperforate (or) high imperforate anus

- If end bowel is above the pelvic floor, it is high imperforate anus. If it is coming below the pelvic floor called low imperforate anus
- For low imperforate anus, we can do one stage operation. We can directly bring proximal rectum & anastomose with anus
- For high imperforate anus, we have to do colostomy first and 2nd stage, we have to do connection
- Operation involving rectal area is PSARP (PENA) Operation (Posterior sagittal anorectoplasty)

Anatomy of Rectum & Anus 00:16:20

- Anus is 4 cm
- Dentate line, above the line is lined by columnar epithelium
  below the line is lined by Squamous Epithelium
- The muscle between the anus rectum is puborectalis muscle
- Above this muscle, we have 3 posits, which are 4cm, 4cm, 4 cm
  - In a dissected rectum, we have 16 cm
  - In this rectum we can see peritoneal selection
  - Some part of it is intraperitoneal and some is extraperitoneal
- In Rectum commonest cancer is adeno cancer in upper 1/3 of rectum, if there is adeno cancer – we Should give 2cm clearance below and at the Rectum Then remaining bowel is brought down &

anastomosed here. This is possible only for upper & middle rectum and some part of lower rectum

- If the cancer is above the puborectalis muscle and give 2cm clearance, then puborectalis which is important sphincter is gone so, we have to go for permanent colostomy in such patients-APR -abdominoperineal resection of miles' operation
- If we not damage sphincter and use do reconstruction above, then it is called anterior resection in Anterior resection operation, we need circular staplers to do reconstruction and colorectal anastomosis is done
- The patient will prefer to go for anterior resection, (then go for permanent lifelong colostomy)
- If the patient has a cancer, 8 cm from the anal verge, we can give 2cm clearance (also for 10cm, 12 cm etc). But if cancer is <6cm from anal verge, we cannot do anterior resection, we should go for APR
- Indication of anterior resection – the cancer is > 6cm from anal verge
- Margin clearance given for Ca rectum → the lumen → 2cm
- post neoadjuvant we should give chemo (CRT) we have to give 1 cm clearance
- Mesorectum is attachment to rectum Mesorectum excision is must in cancer because it harbours all the nodes Mesorectal clearance is 5 cm
- Circumferential resection margin (CRM) should be atleast 1mm
- Gold standard Investigation for Ca rectum → MRI, for T&N staying

DOCTUTORIALS
LOGIN FOR SUCCESS

AfraTafreeh.com

- In anterior resection, we remove the growth with 2cm clearance distally and we do colorectal anastomosis
- Anterior resection can be divided into
  a. High Anterior Resection
  b. Low anterior resection
  c. Ultra-low anterior resection
- Anterior resection is done for growth which is in peritoneal covering (P. reflection) Aka high anterior resection anastomosis done in abdominal cavity
- If anastomosis done very low, at level of (Dentate line) coloanal anastomosis called ultra-low anterior resection.

For cancer Anal Canal

- Most common is the squamous cell cancer anal canal
- It is treated by chemo RT → 5 FU + Cisplatin + R.T
- It is called NIGRO regimen (Only for squamous cell Ca of anal canal)
- If columnar Ca of anal canal → we go for APR

TUTORIALS LOGIN FOR SUCCESS

STOMA – Bringing the bowel our 00:26:00

- Ileostomy → Ileum being brought out
  - Ileostomy is usually created in right iliac fossa with terminal ileum
  - It will be protruding out for few cm
  - The content coming out is liquid and if falls on skin, then excoriation can happen
  - The protruding Ileostomy is called Brook's Ileostomy

- It can be end (or) loop ileostomy (usually created in RIF)

- Colostomy: It is usually in left iliac fossa using transverse colon (or) sigmoid colon only. Because they are the colons which are mobile. Transverse colon is brought out in epigastric region, segment colon is brought out in left iliac fossa

Complication

i. Prolapse of colostomy
ii. Patient can develop a hernia in the gap which brings colostomy called parasternal hernia
   - Most complication of DE ostomy → Skin excoriation
   - Earliest complication of De ostomy → Ileostomy necrosis
   - Most complication of colostomy → Parastomal hernia
   - Parastomal hernia – most common indication for redo surgery and keep a mesh underneath

AfraTafreen.com



TUTORIALS
LOGIN FOR SUCCESS

   - We keep 2 mesh as shown, so that it won's go for another herniation. It is done as sugar baker like procedure

- Stomal prolapse is common after procedures like look colostomy
- Parastomal Hernia – most common after end colostomy

AfraTafreeh.com

MALIGNANT CANCERS OF RECTUM AND ANUS

Malignant cancers of rectum and anus 00:00:11

Malignant cancers of rectum and anus

- **Rectal**
  - ↓ **adenocancer (most common)**
- **Anus**
  - Columnar
    1. Adenocancer
    2. Epidermoid ca
    3. Melanoma

    ↓ (most common skin > eyes > anus)

    ↓ Anal canal tumors
  - Squamous
    1. SCC (most common)
    2. BCC
    3. Verrucous
    4. Bowen's disease

    ↓ Anal margin tumors

DOC TUTORIALS
LOGIN FOR SUCCESS

Rectal adeno cancers 00:02:36

- Most common presentation: Bleeding per rectum
- If growth seen at ampulla of rectum, overnight collection of mucous discharge in rectum

↓

Early morning spurious diarrhoea

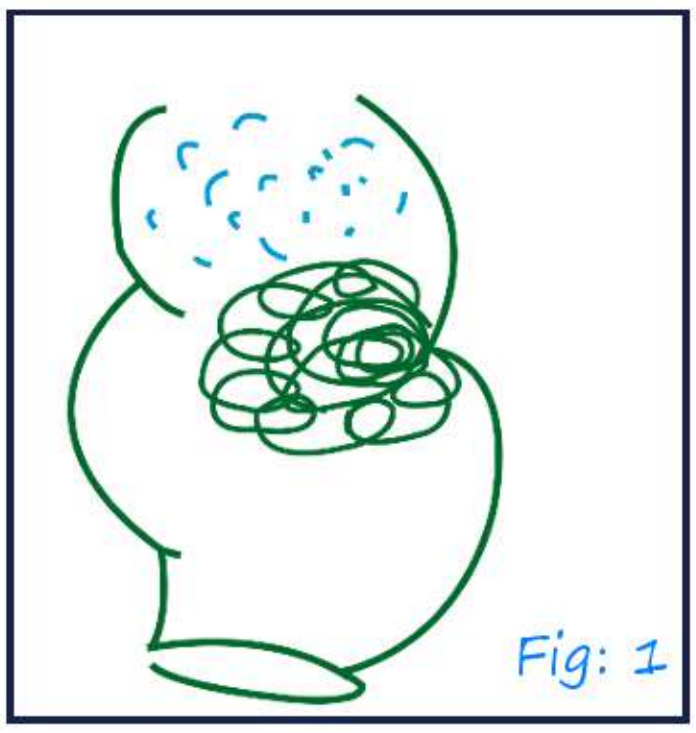

Fig: 1

- IOC: Sigmoidoscopic biopsy
- T staging ┐– MRI pelvis (surface coil)
- N staging ┘
- M staging – CECT abdomen (mets to liver)
- Tumor marker: CEA

Anatomy of Rectum and Surgeries

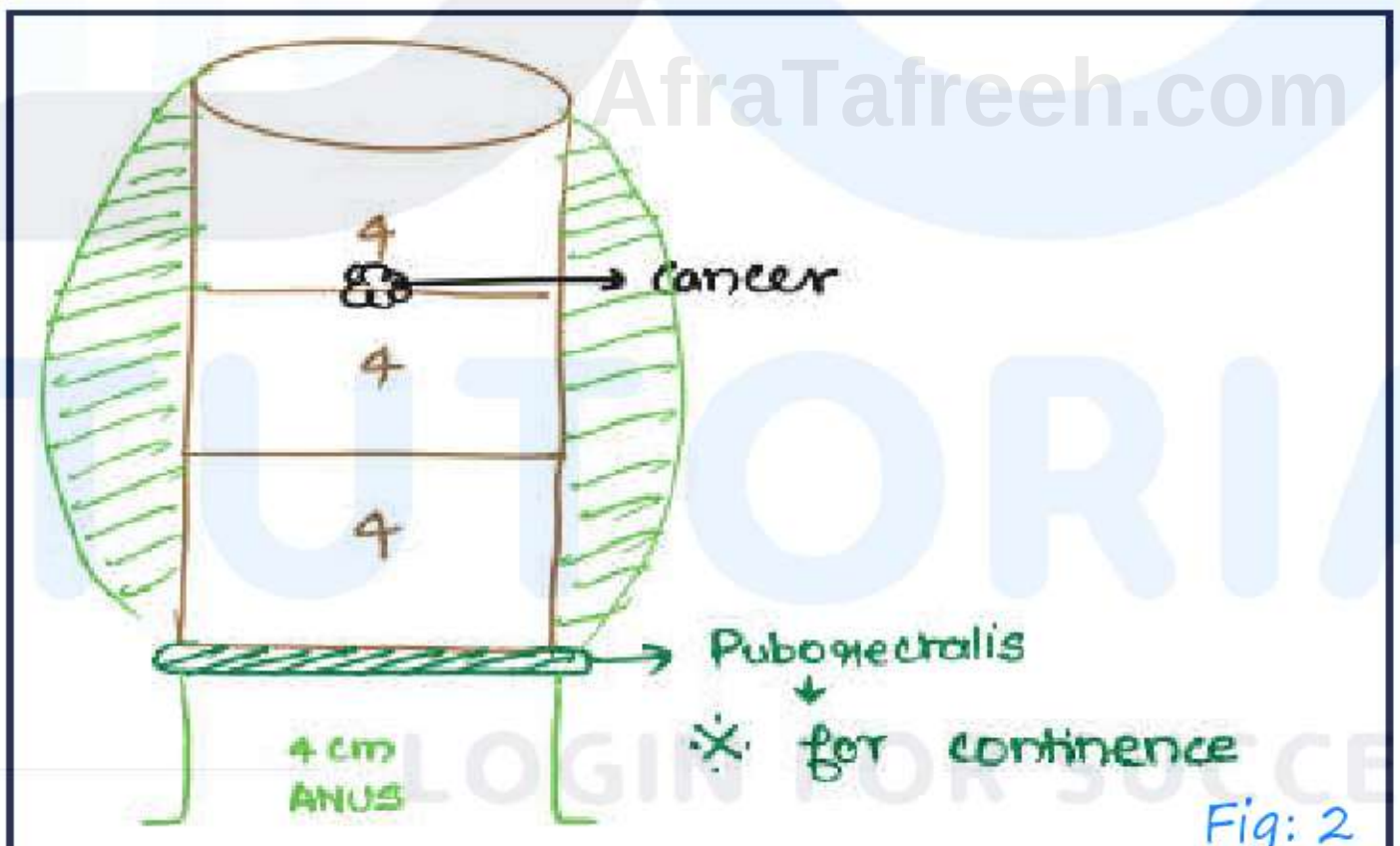

Fig: 2

- For a cancer rectum, we give 2 cm distal clearance
- If neoadjuvant RT given before surgery → 1 cm clearance given.
- Proximally, resection done upto sigmoid colon.
- Mesorectal clearance – 5 cm
- If cancer is in lower rectum → Total excision of mesorectum (TME)

AfraTafreeh.com

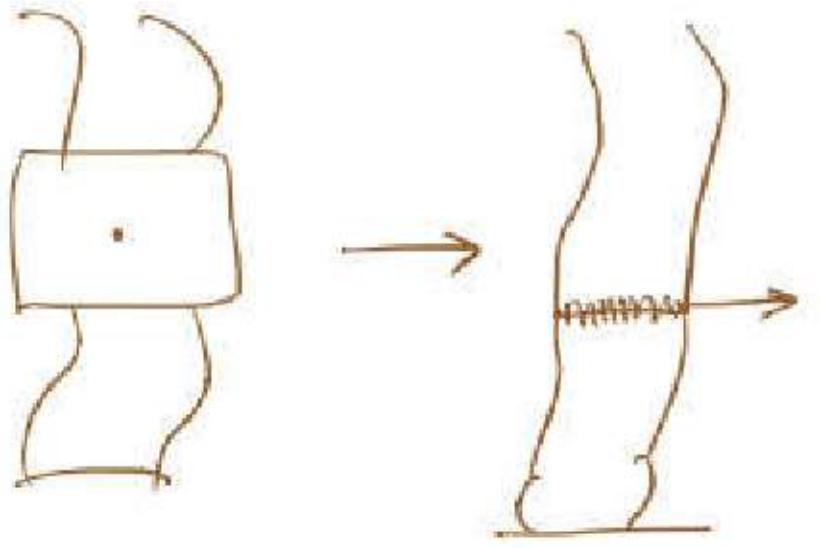

Anterior resection
↓
Motion passed via anus

- If cancer is in lower rectum, if 2 cm margin is given, puborectalis is affected.

  ↓

  Removal of distal bowel completely including anus and rectum → proximal permanent colostomy k/a abdominal perineal resection.

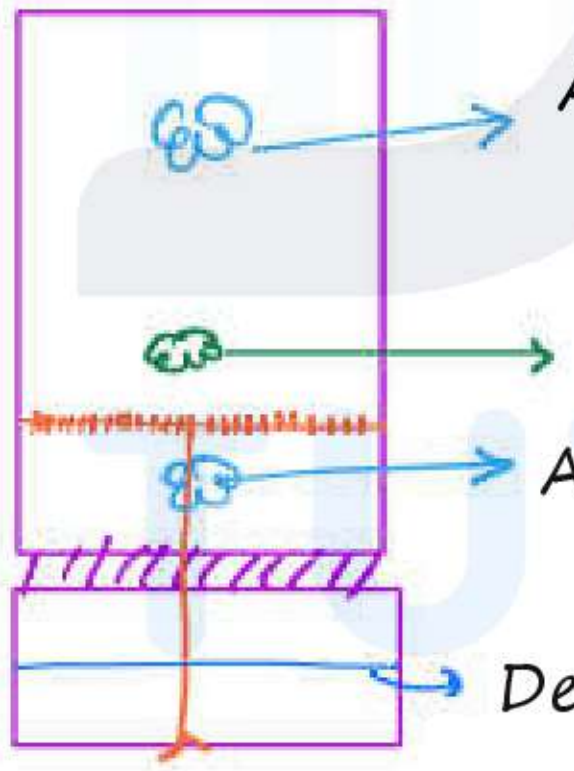

AR
> 6cm from anal verge →
AR → Colorectal anastomosis

APR
> < 6 cm from anal verge → APR

Dentate line

TUTORIALS
LOGIN FOR SUCCESS

- Distance within 4 cm from dentate line

  ↓

  APR
- > 4cm from dentate line → AR
- In APR – Total mesorectal excision
- In AR – 5 cm clearance of mesorectum

Anterior Resection

Low AR
↓
Anastomosis done distal to peritoneal reflection

High AR
↓
Anastomosis done within peritoneal reflection

- Ultralow AR
  ↓
  anastomosis done at pelvic floor

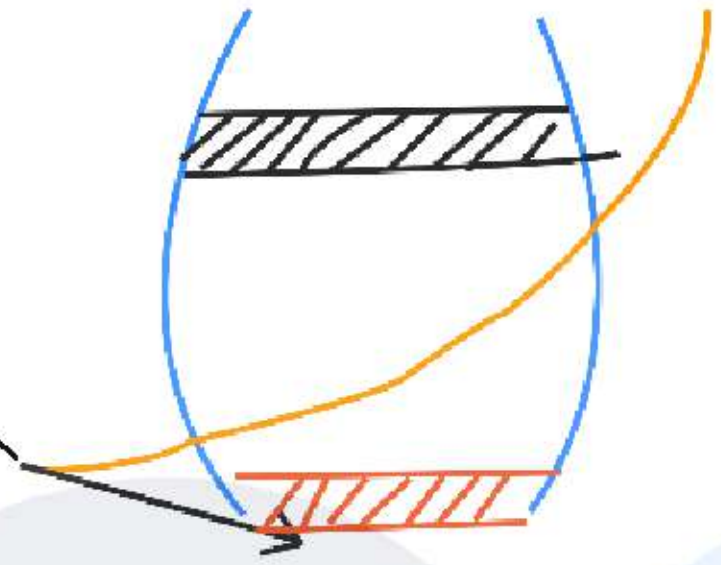

- Sometimes, covering ileostomy done for LAR, ULAR
  ↓
  Temporary procedure

AfraTafreeh.com

Indications of APR (MILES)

1. Growth < 6cm from anal verge
   < 4cm from dentate line
2. Infiltration of puborectalis
3. Anal Incontinence
   ↓
   Lifelong colostomy →

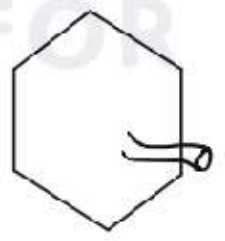

DOC TUTORIALS LOGIN FOR SUCCESS

AfraTafreeh.com

Cancer Colon and Cancer Rectum

Management 00:12:19

Cancer Rectum	Cancer Colon
• AR • APR ↓ Neoadjuvant chemoRT ↓ • Long course RT → 6 wks RT surgery after 6 weeks • Short course RT → 5 days operate • Papillion technique → Intracavity Rt	• R Hemicolectomy • L Hemicolectomy • Extended R Hemicolectomy

- Previously done surgery for Ca rectum – pelvic exenteration operation → Brunschwig operation
- Adjuvant Chemotherapy is same for both Ca rectum and Ca colon.
  ↓
  FOLFOX regimen x 6 cycles.

TUTORIALS
LOGIN FOR SUCCESS

Trans Anal Excision of Ca Rectum 00:15:50

Trans anal excision of Ca rectum

- **Trans anal endoscopic surgery (TEMS)**
- **Trans anal minimally invasive surgery (TAMIS)**

Indications of Trans Anal Surgery 00:16:56

1. T_1 (involving mucosa, submucosa)
2. Mobile tumors
3. < 3cm tumor
4. <30% circumference of lumen involved.
5. Tumor (4-8 cm) from anal verge
6. No nodal mets.
7. Well-moderately differentiated

AfraTafreeh.com
TUTORIALS
LOGIN FOR SUCCESS

Cancer Anal Canal 00:18:28

Cancer anal canal

- **Squamous cell cancer** → Chemoradiation → NIGRO REGIMEN → 5FU based CT → RT
- **Melanoma** → Wide local excision/APR
- **Adenocarcinoma** → APR

AfraTafreeh.com

MISCELLANEOUS TOPICS IN GIT

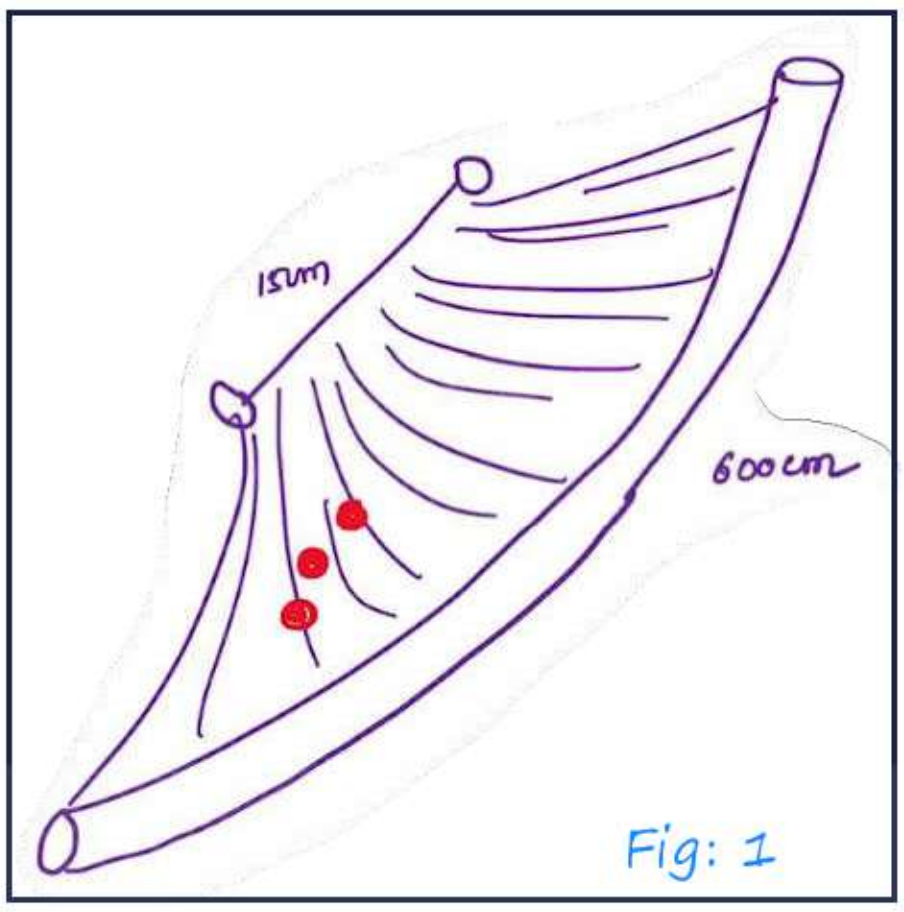

Fig: 1

- There 15cm root of mesentery fans out which gives attachment to 6metres of small bowel
- Infective nodes can develop in mesentery called as acute mesenteric adenitis

Pathologies in mesentery 00:01:00

Acute mesenteric adenitises:

- Most common organism causing this infection is yersinia
- Usually this follows respiratory infection
- They mimic like appendicitis (Fever, pain, vomiting)
- Classical features are central abdominal pain with vomiting is seen

Klein's sign

- If we palpate in ® iliac fossa there is pain and ask patient to turn with laterally and the nodes will move away so the tenderness
- It is a self-limiting case they become normal by themselves
- Diagnosis laparoscopy can be done only if we have doubt
- No need to remove benign pathology

Misty mesentery: (Benign)

- There is pathological increase in fat attenuation seen on CT scan
- Seen on patients like mesenteric an edema, inflammation, even with neoplastic infiltration, patient with hemorrhage

Mesenteric panniculitis: (Benign)

- It is the term used for: Weber Christian disease
Lipodystrophy
Lipogranuloma
- If mesentery is involved in these cases the term mesenteric panniculitis is given

AfraTafreeh.com

Mesenteric cyst: 00:06:08

- The cyst presents in mesentery. It can be seen towards umbilicus
- The classical sign is tillaux sign → The cyst can be moved perpendicular to the mesentery

Tillaux triad

- Movement to mesentery
- Central dullness
- Resonance surrounding

Types

- Most common type is cycloaliphatic cyst
- Enterogenous cyst
- Urogenital remnants can form cyst
- Dermoid cyst can also form in mesentery

Chylolymphatic | Enterogenous

Sequestrated lymphatics

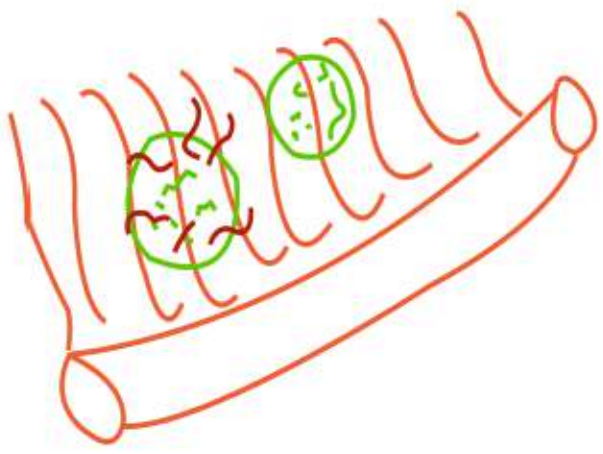

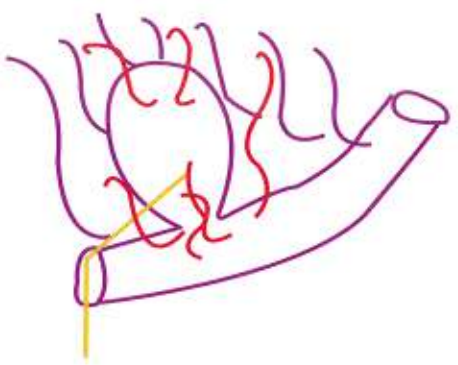

Sequestrated bowel

Chylolymphatic cyst	Entrerogenous cyst
The most common cyst	The less common cyst
Seen along mesentery they are derived from lymphatic remnants/sequestrated lymphatics	Formed in mesentery by the duplication of bowel (Like a diverticulum) (Sequestrated bowel)
They have separate blood supply independent blood supply	They have blood supply same as intestine common/combined blood flow to bowel and e. cyst
Thin-walled cyst with clear fluid	Thick-walled cyst with mucinous fluid
Treatment - by enucleation	Treatment: Resection and anastomosis

Complications of mesenteric cysts 00:12:08

- This cyst can go for torsion of mesentery
- Rupture of cyst
- Hemorrhage into cyst
- Infection

AfraTafreeh.com

Retroperitoneum 00:13:38

- Structures behind the posterior peritoneum
- They are kidney, ureter, adrenal, 2nd, 3rd, 4th, part pf duodenum up to DJ flexure, Aorta, IVC, Posterior part of ascending colon and descending colon

Retroperitoneal fibrosis: 00:14:31

- Fibrosis usually starts below the aortic bifurcation area and it spreads and extends proximally to renal artery level (Usually don't go up to duodenum)
- 2types

  1.Primary retroperitoneal fibrosis → Unknown etiology called Ormand's disease

  2.Secondary RPF – Due to

a. Inflammation

↓

1.Chronic pancreatitis

2.TB

3.Histoplasmosis

4.Actinomycosis

b. Drugs

↓

1.Methysergide

2.α – Methyldopa

3.β – Blocker

4.Hydralazine

(Most of chemotherapy drugs

c. Malignancy

↓

1.Prostate CA

2.NHL

3.Sarcoma

4.Gastric Ca

5.Carcinoid

d.Radiotherapy

e. Auto immune disease like ankylosing spondylitis SLE, PAN

Salient features of RPF 00:18:37

AfraTafreeh.com

- Most common in men
- Dull acting pain
- Nausea
- Structures M/C involved are ureter aorta, IVC
- When ureter is involved hydronephrosis and pain related to hydronephrosis will be happening

TUTORIALS LOGIN FOR SUCCESS

IOC: CECT abdomen

- IN case of obstructed ureter patient may have elevated urea creatine values in such cases MRI is done
- Ureter involved is found out by IVP

AfraTafreeh.com

- On IVP there will be lateral deviation of both ureters with occlusion of ureter mostly seen in lower part so we can see a hydroureteronephrosis (HUN) can be seen (Lateral deviation of ureter + HUN) is the finding
- In secondary cases surgery – Ureterolysis (Dissect the ureter) should be sone ureter should be released from the adhesion fibrosis and we have to put a omental flap

Peritoneum

Peritonitis

Spontaneous bacterial peritonitis

↓

- Peritoneum gets infected by bacteria through trans gut inflammation
- 1° causes most by E.coli in adults
- 2nd most common klebsiella
- Most common in peds streptococci

- Most common cause – 2° bacterial peritonitis
- 2° to perforation of bowel
- Most common organism isolated is E. coli and also Bacteroides

- 1° pneumococcal peritonitis
- Particularly associated with nephrotic syndrome

Spontaneous bacterial peritonitis: 00:26:05

Pathophysiology

- Here there is no perforation but there is a bacterial translocation from the gut
- From intestine it comes outside and into mesenteric lymph nodes and then it goes into fluid in the abdominal cavity then gives to peritoneal covering
- Mainly it is due to seeding of bacteria into the fluid present in patients

Predisposing factors for bacterial translocation

- Cirrhosis with ascites patient
- Dehydration patient
- Bowel preparation
- Hypoproteinemia patients
- It is most common in patient associated with GI hemorrhage especially DCLD patients – Decompensated liver disease
- Diagnosis if > 250 polymorphonuclear cells present
- Culture of fluid can be alone → Only one organism should be positive in culture
- If >2 organisms seen rule out bowel perforation
- Rx: Cefotaxime + Albumin infusion in spite of treatment, mortality is 20% in these patients
- S. B. P – cirrhotic patients → Is a bad prognosis then it is <20% survival with in next 2years

AfraTafreeh.com

AfraTafreeh.com

- So, to prevent SBP they will give tab norflox whenever there is a GI bleed hemorrhage done in patient with DCLD + Ascites

Primary pneumococcal peritonitis 00:32:06

- Seen only in children especially who are having nephrotic syndrome with ascites (Imp. predisposing factor)
- Can also happen in girls of 3-9 years' infection via vagina and fallopian tube
- In mole children it is blood borne infection following a respiratory infection (Pneumococcal) or middle ear infection
- Diagnosed by WBC count >30000/ul
- Early laparotomy is advised if we suspect it
- The exudate fluid seen during surgery is odorless and sticky – diagnostic of pneumococci infection

LOGIN FOR SUCCESS

Periodic peritonitis 00:34:35

- Familial Mediterranean fever peritonitis
- Not seen in India
- Seen in Arab, Iran
- Most common in children > adults
- Duration of attack remains 24-72 hours and attack disappear

- Most common of them would have H/O appendicectomy in many case
- If at all there is peritoneal inflammation it is seen in spleen area and gall bladder area
- R1 to prevent recurrent attacks is colchicine therapy
- Primary peritonitis → Pneumococcal nephrotic syndrome

  → Spontaneous – Cirrhotic bacterial

  → Periodic – FMF
- Secondary peritonitis → It is most common bowel/Bite duct/GB/Perforation peritonitis → Multiple organisms

Ascites 00:38:46

AfraTafreeh.com

Transudate ascites	Exudate ascites
• Less protein contents • SAAG – Serum ascites albumin gradient • High SAAG > 1.1gm/dl • Most related to liver pathologies, cirrhosis Budd Chiari syndrome, DCLD,	• High protein content • Low SAAG < 1.1gm/dl • Coming from bowel tumor and some important structures like pancreatic ascites nephrotic syndrome biliary ascites bowel obstruction bowel perforation T.B lymph leaks

AfraTafreeh.com

Liver mets, Portal vein thrombosis, Sinusoid obstruction fatty liver • rarely in cardiac ascites	• Serositis in connective tissue disorders • Malignant deposits causing ascites in high protein ascites with low SAAG component

Pseudo myoma peritonei 00:43:26

- It is mucinous neoplasms which spread into peritoneal cavity
- Most common – Appendiceal mucinous neoplasm
- 2nd – Ovarian adenocarcinoma colonic mucinous adenocarcinoma
- Clinical features – Peritoneum gets filled with mucinous secreting tumor which will be having semisolid mucus material
- It forms the cystic loculated materials filled with mucin

TUTORIALS LOGIN FOR SUCCESS

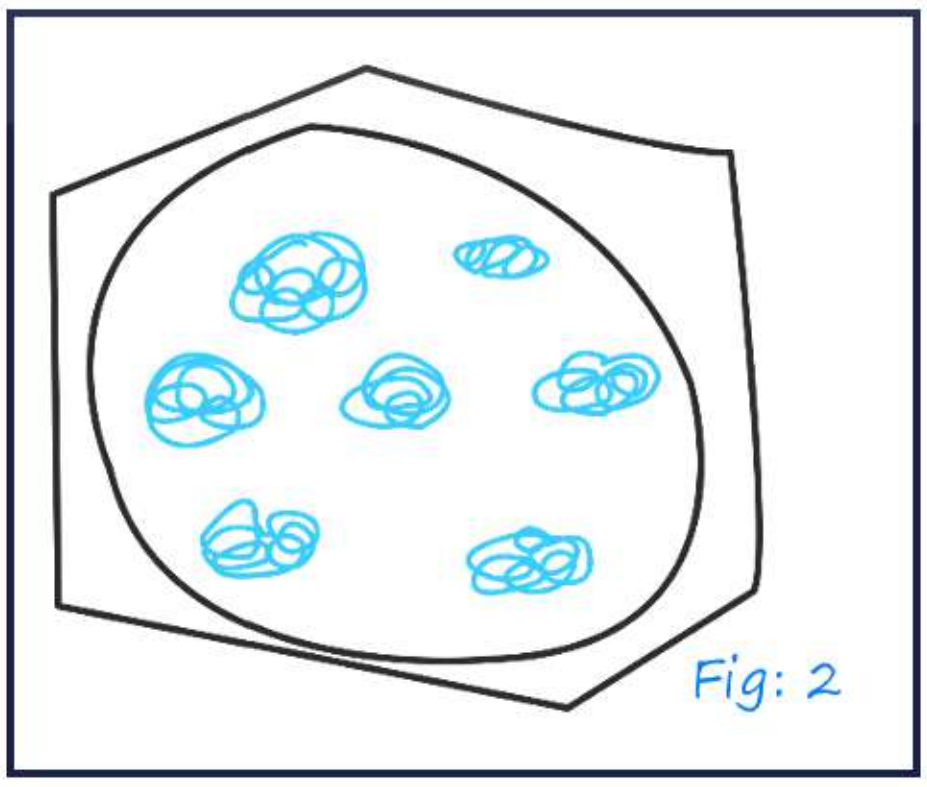

Fig: 2

- Most common in 40-50 years

- Equal in male and female (M=F)
- Most come asymptomatically
- Usually come with non-specific pain abdominal distension
- These patients are initially normal gradually become ill
- On examining abdomen → Non shifting dullness seen it presents as an mass abdomen
- IOC: CECT abdomen
- Plan for
  - Colonoscopy → Colonic mucinous adenocarcinoma should be ruled out
  - Tumor marker of ovarian tumor will be locked out

AfraTafreeh.com

Treatment

- If it is found operable than major surgery called cytoreductive surgery (Takes 10-12hrs) is done
- Remove omentum, spleen, GB, B/L salpingo-oopherectomy, Uterus, appendix, R Hemi colon strip the peritoneum, remove any involved organ also
- After the surgery we infuse intraperitoneal hyperthermic chemotherapy to avoid recurrence (HIPRC)
- In spite of this recurrence happens
- Best prognosis is with appendiceal mucinous neoplasm (Better than ovarian colonic)

AfraTafreeh.com

Intra-abdominal access 00:51:11

- When patient is having chills and fever and we search everywhere and could not find anything then look under diaphragm, there will be subphrenic abscess
- Pus somewhere, pus nowhere, pus under diaphragm
- If patient is operated most common site of abscess collection is subhepatic space aka Rutherford – Morrison pouch (Morrison subhepatic pouch) in post op patient lying supine

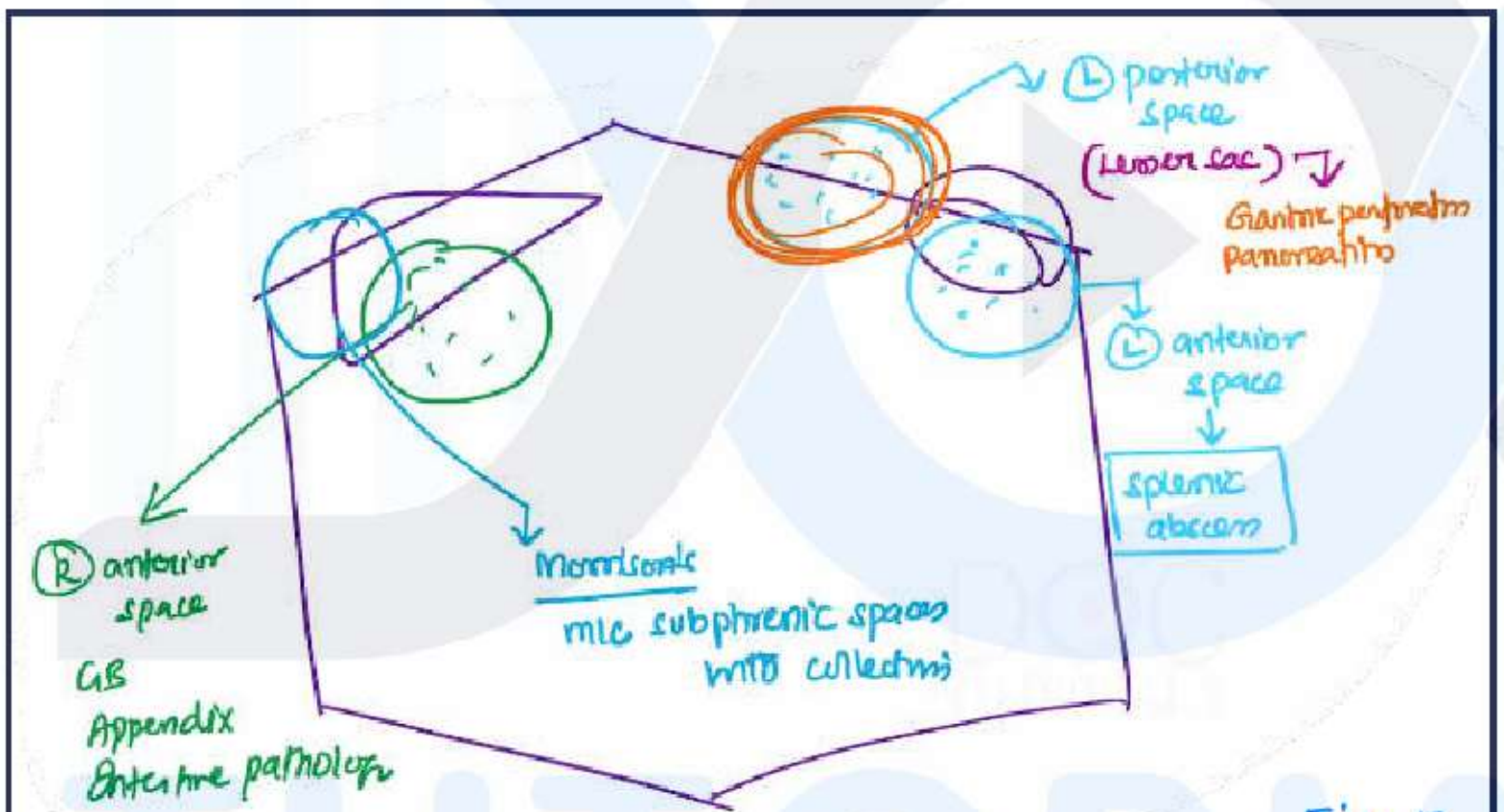

Fig: 3

- If patient is ambulatory/Mobile patient the pus collects in pelvic cavity the pouch of Douglas and sitting

Subphrenic spaces/abscess:

- (L) anterior space → Splenic abscess gets collected
- (L) posterior space/Lesser sac space/Collection
- Ⓡ anterior space → Pus in case of gall bladder, appendix, intestinal pathology

- ® posterior space → Morrisons pouch it is most common space of subphrenic abscess

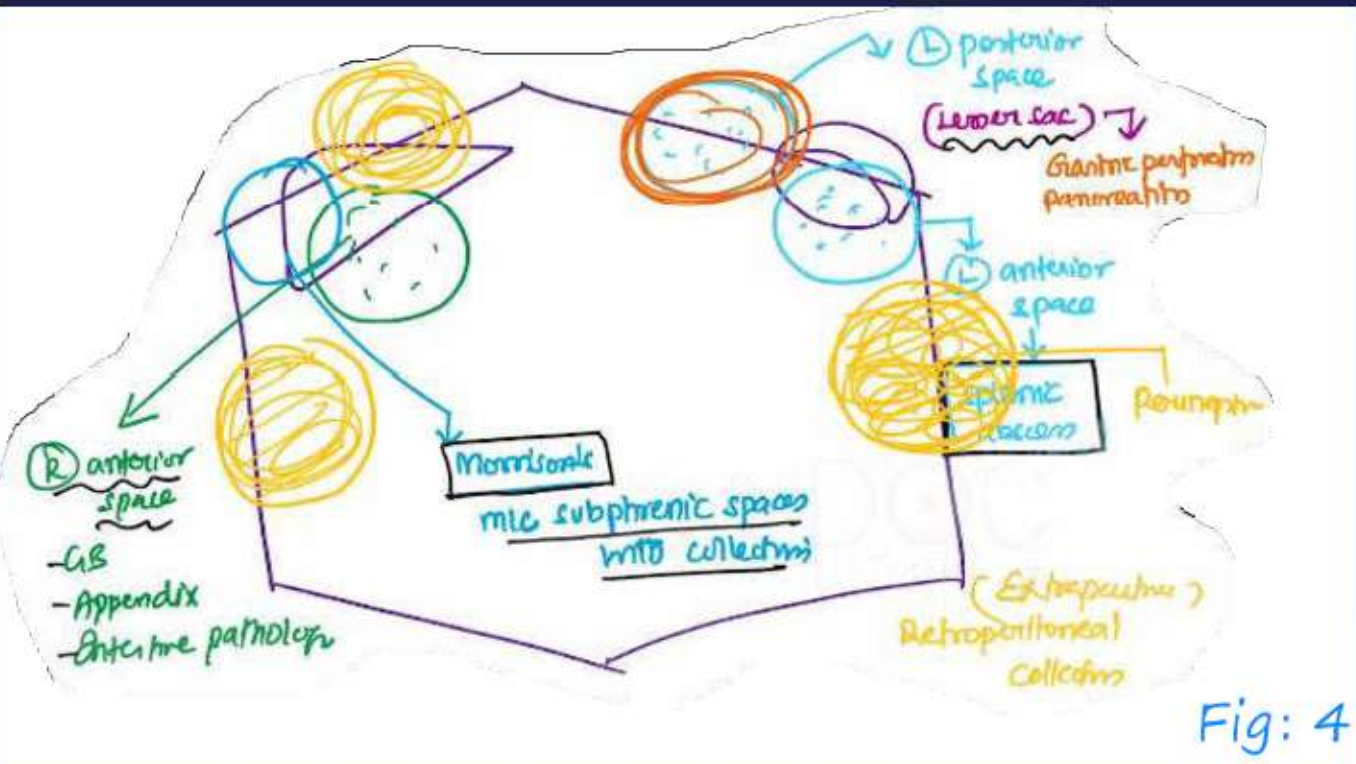

Fig: 4

- We can also have extra peritoneal spaces/collections (or) retroperitoneal collection on ® side and (L) side around the kidney and bare area of liver
- Abscess around kidney are perinephric abscess very common at (L) supra renal area (L) perinephric abscess on ® side – bare area of liver
- On lying supine position – most common site pus collection is Morrisons pouch in ambulatory patient, common site of keeping drain is pelvis

AllaTafreen.com
DOC TUTORIALS
LOGIN FOR SUCCESS

AfraTafreeh.com

GALL BLADDER AND BILE DUCT

- Right hepatic duct has less biliary course than left hepatic duct

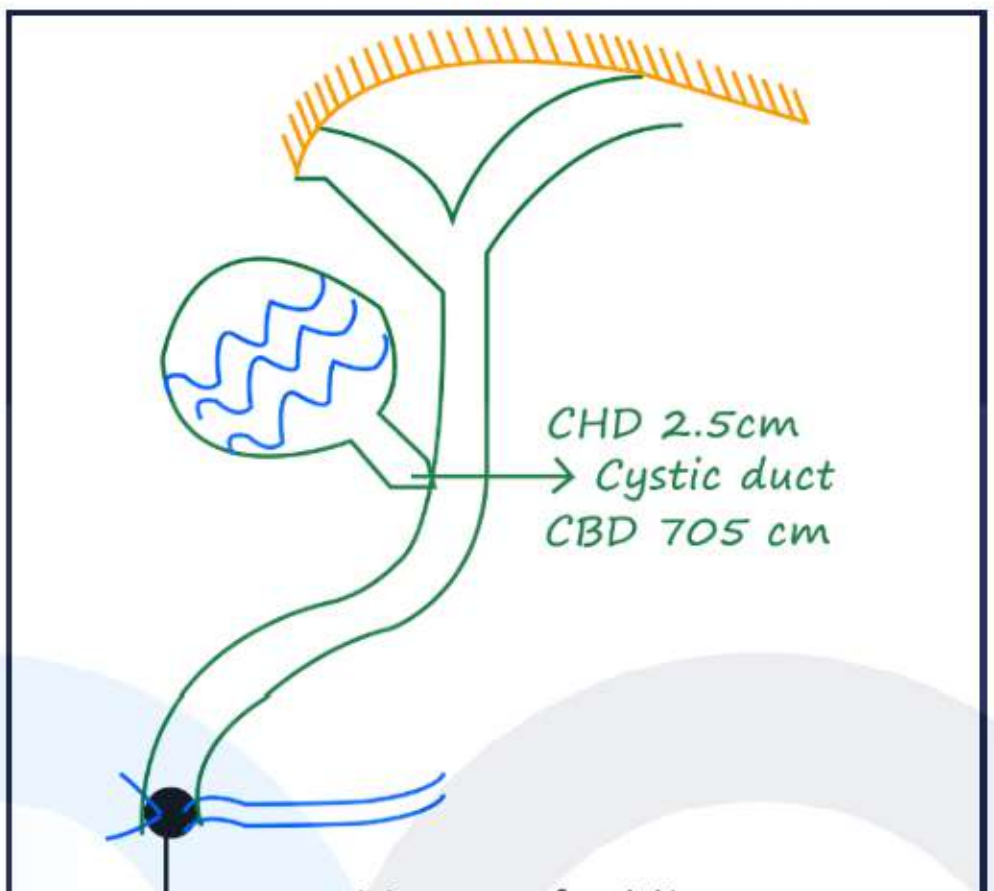

Fig: 1

- Valves of heister present in cystic duct and neck of gall bladder
- Mucosal folds in gall bladder are known as crypts of luschka
- Bile secreted in liver comes through the hepatic duct, concentrated in gall bladder and they go out through common bile duct
- Common bile duct joins with major duct of wirsung
- Gall bladder is supplied by cystic artery-branch of right hepatic artery

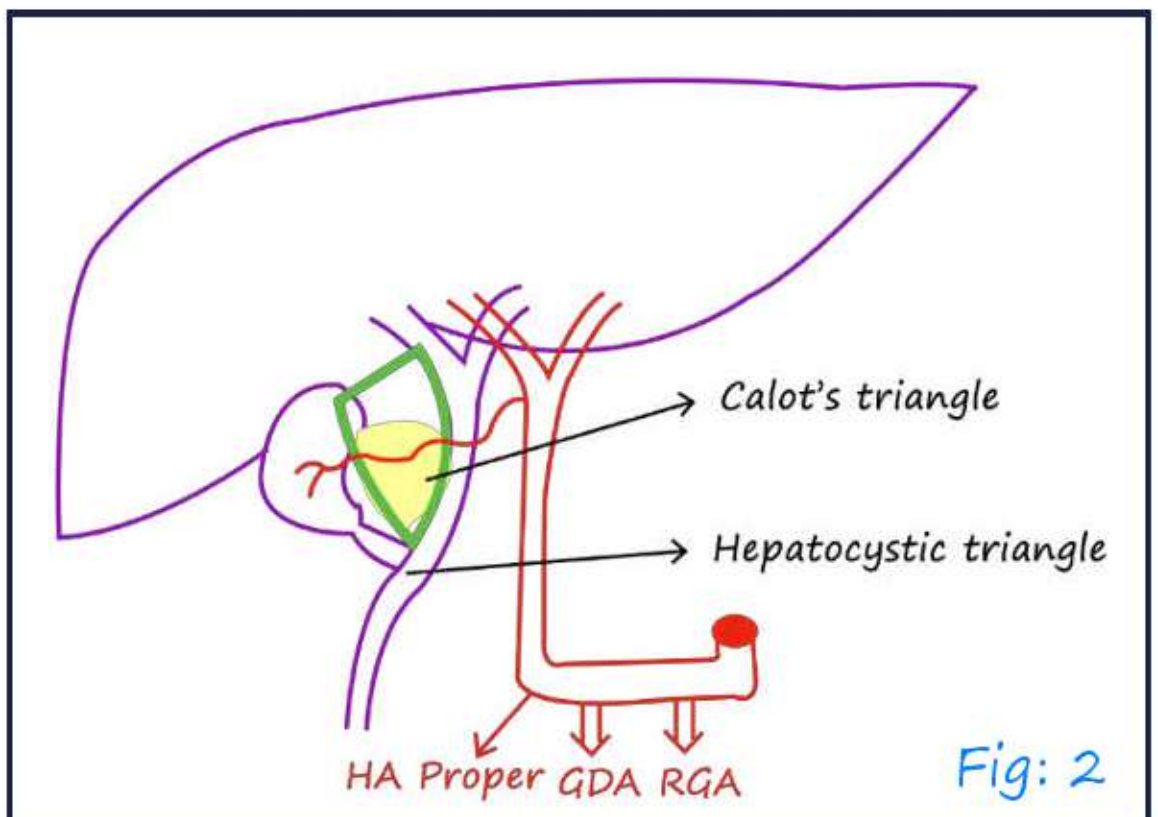

Fig: 2

- Right hepatic artery sometimes takes tortuous course and gives branch to gall bladder and cystic duct
- Tortuous course of right hepatic artery into the calot's triangle is moynihan's hump/caterpillar turn

Sphincter of ODDI 00:07:59

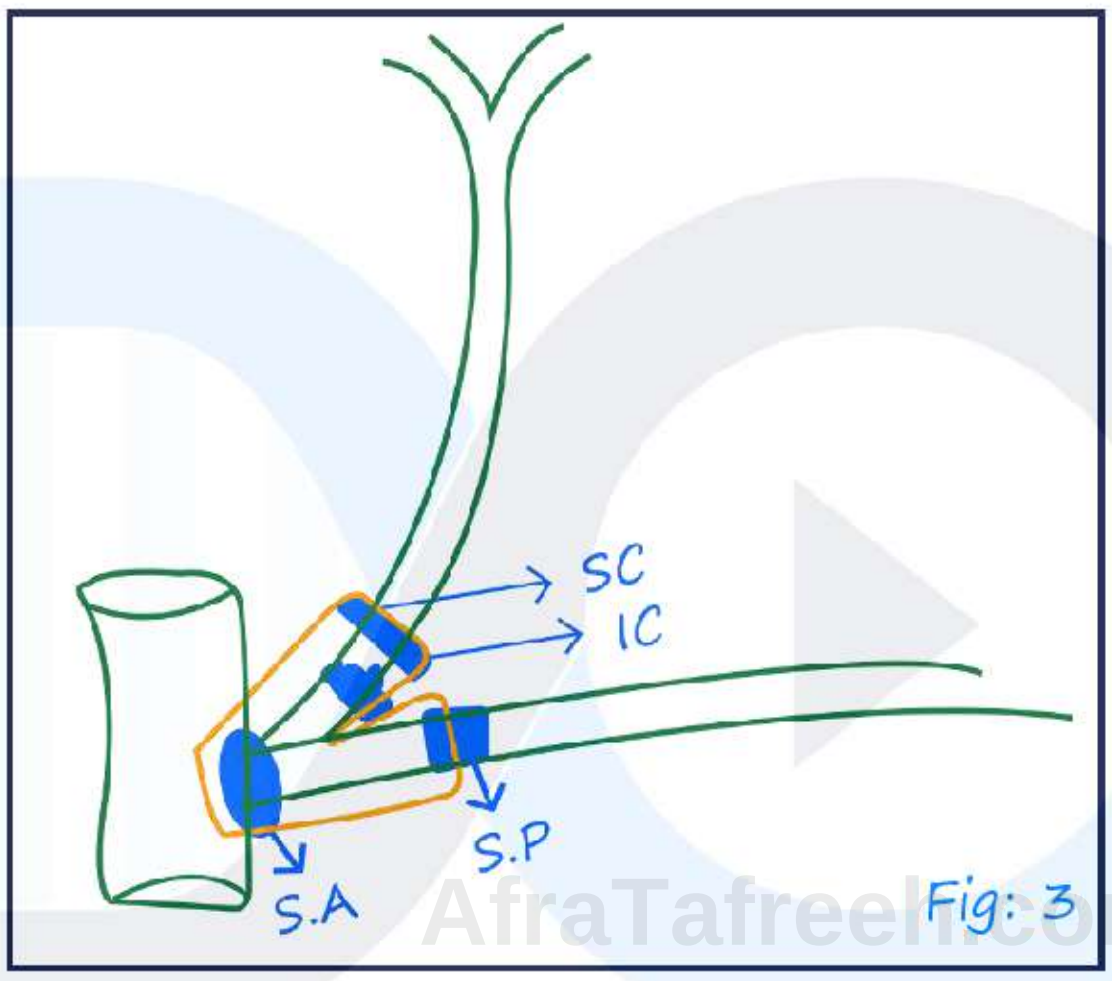

- Common bile duct joins with pancreatic duct of wirsung and opens into ampulla of duodenum on posterior wall
- SOD complex made up of 4 sphincters
  - Superior choledochal sphincter
  - Inferior choledochal sphincter
  - Sphincter pancreaticus
  - Sphincter ampullae
- SOD complex → closed at a resting pressure of 13-120mmHg
  - Opens on cholecystokinin (CCK)

AfraTafreeh.com

- Fatty food inside duodenum stimulates CCK

↓

Gall bladder contracts and SOD relax

↓

Bile flows inside duodenum

- CCK – acts on pancreatic enzymes, lipase, amylase

↓

Digest fatty food

- Fatty food → CCK

CCK

GB	Ampulla
contracted	not opened

Biliary colicky pain, pancreatic pain

↓

Sphincter of oddi dyskinesia

↓

Milkwauke classification

↓

Treatment: ERCP + Sphincterotomy

ERCP: Endoscopic Retrograde Cholangio Pancreatography 00:13:46

- With a side viewing scope, we cannulate the ampulla and push the contrast to bile duct and pancreatic duct
- Diagnostic



- MRCP has replaced ERCP for diagnostic purposes now
- ERCP → Therapeutic

↓

Cut the sphincter of oddi → sphincterotomy

↓

↓

Cut @ 1'o clock/11'o clock position

Therapeutic uses of ERCP

- Biliary system
  i. Removal of CBD stone
  ii. Stent in CBD
  iii. Bile duct leak → stenting/diagnostic
  iv. Biopsy
  v. Gall stone pancreatitis
- Pancreatic system
  i. Pancreatic head stone
  ii. Stenting

Diagnostic purpose

i. Bile leak (INICET 2020)

- Gold standard

AfraTafreeh.com

- Most sensitive
- Strasberg classification
- Stenting can be done

ii. Primary sclerosing cholangitis

- Prune tree appearance
- Beaded appearance

iii. Chronic pancreatitis → Cambridge criteria

↓

Chain of lakes appearance

– Gold standard for investigation/treatment for CBD stones → ERCP + Sphincterotomy

Pancreas divisum 00:20:44

- Minor duct draining the entire pancreas
- Major duct draining head of pancreas
- Bile duct joining the major duct
- Minor duct has strictures and narrowing

↓

Recurrent pancreatitis

- ERCP → Cannulate minor duct

↓

Minor duct papillotomy → Treatment of pancreas divisum

+

Stenting inside

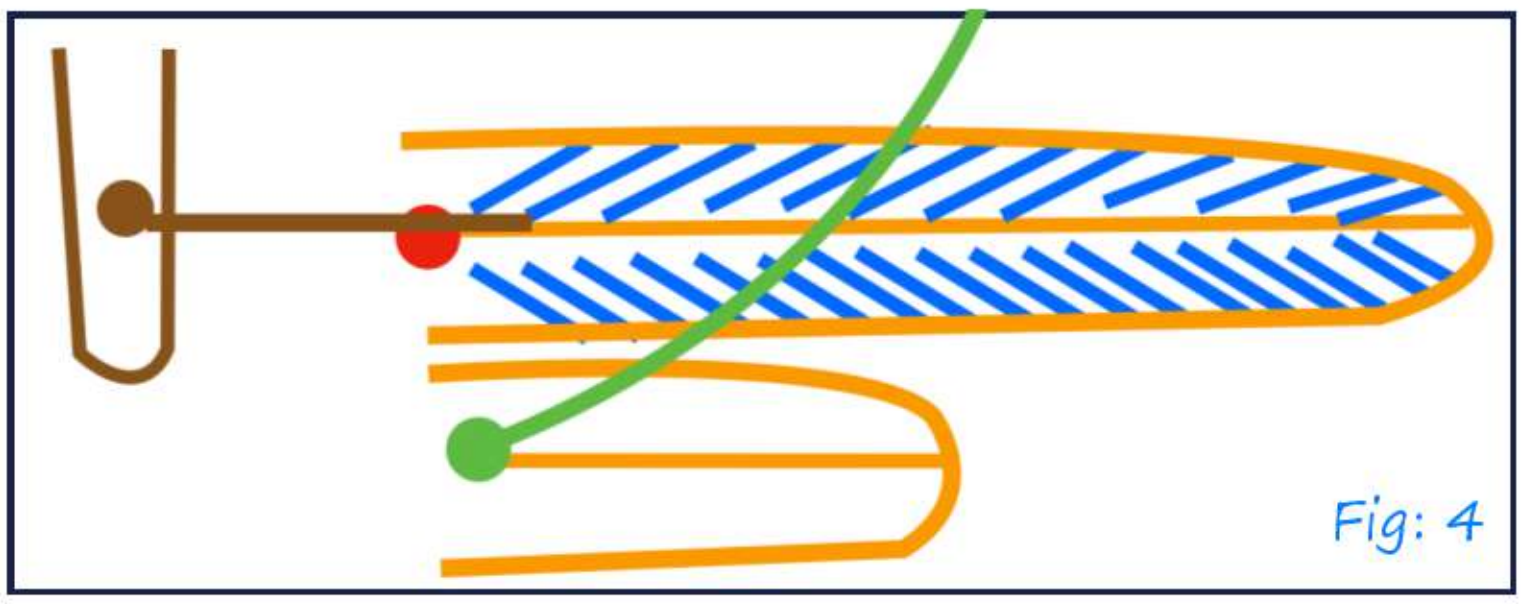

Fig: 4

Complications of ERCP 00:22:16

- Most common – Gall stone pancreatitis (5%) → analgesics can prevent gall stone pancreatitis
- Cholangitis
- Bleeding
- Duodenal perforation (posterior)
- Mortality 0.1%

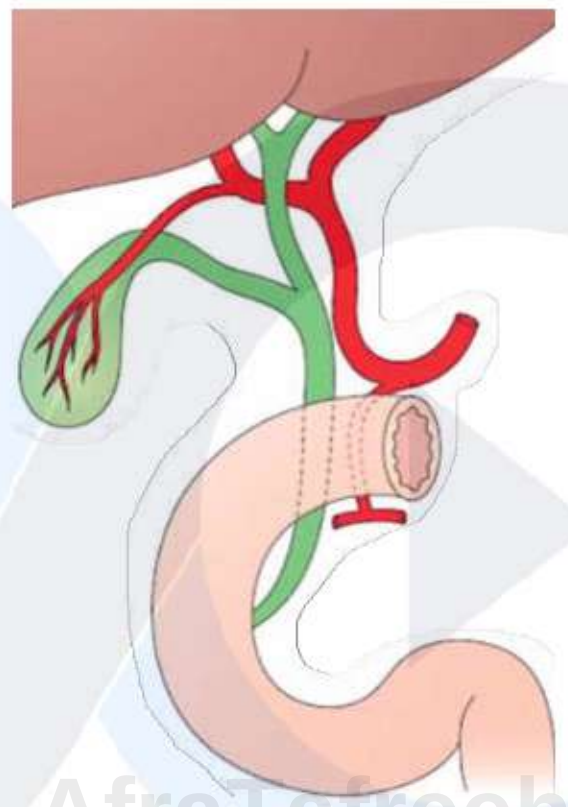

Moynihan's hump Fig: 5

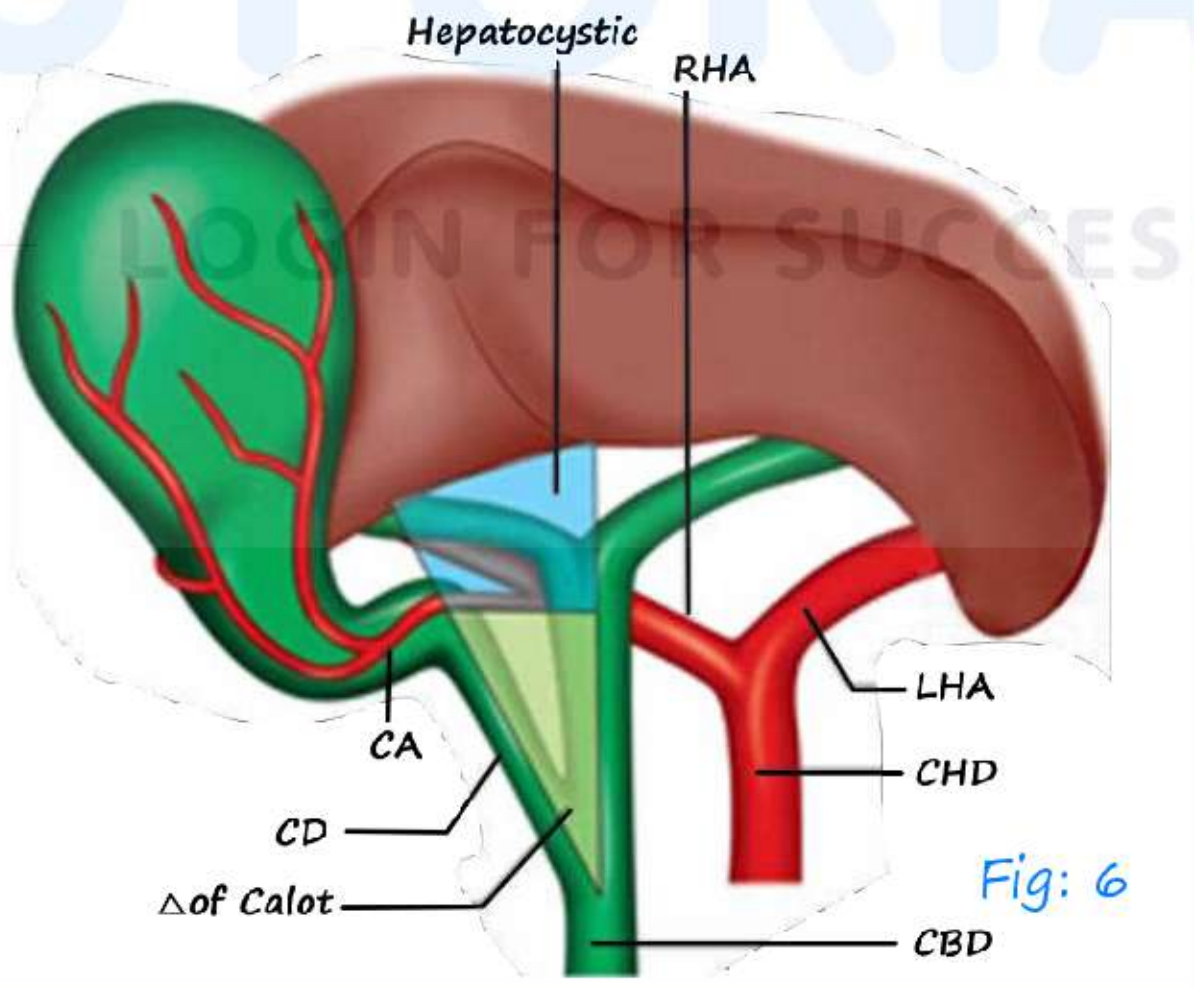

Fig: 6

AfraTafreeh.com
TUTORIALS
LOGIN FOR SUCCESS

AfraTafreeh.com

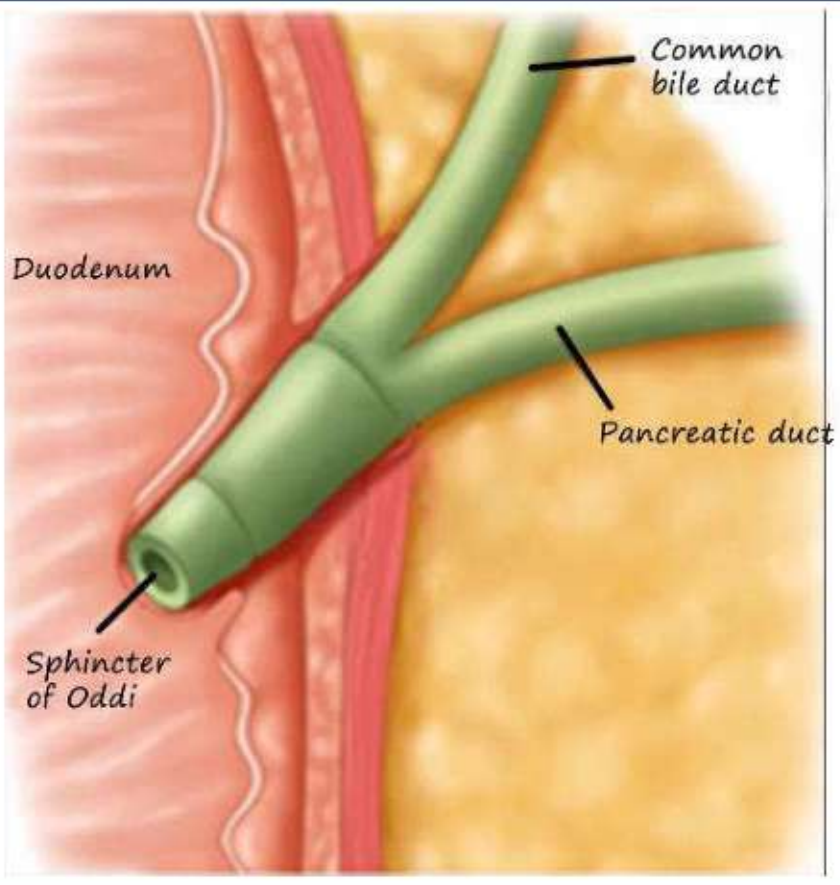

Fig: 7

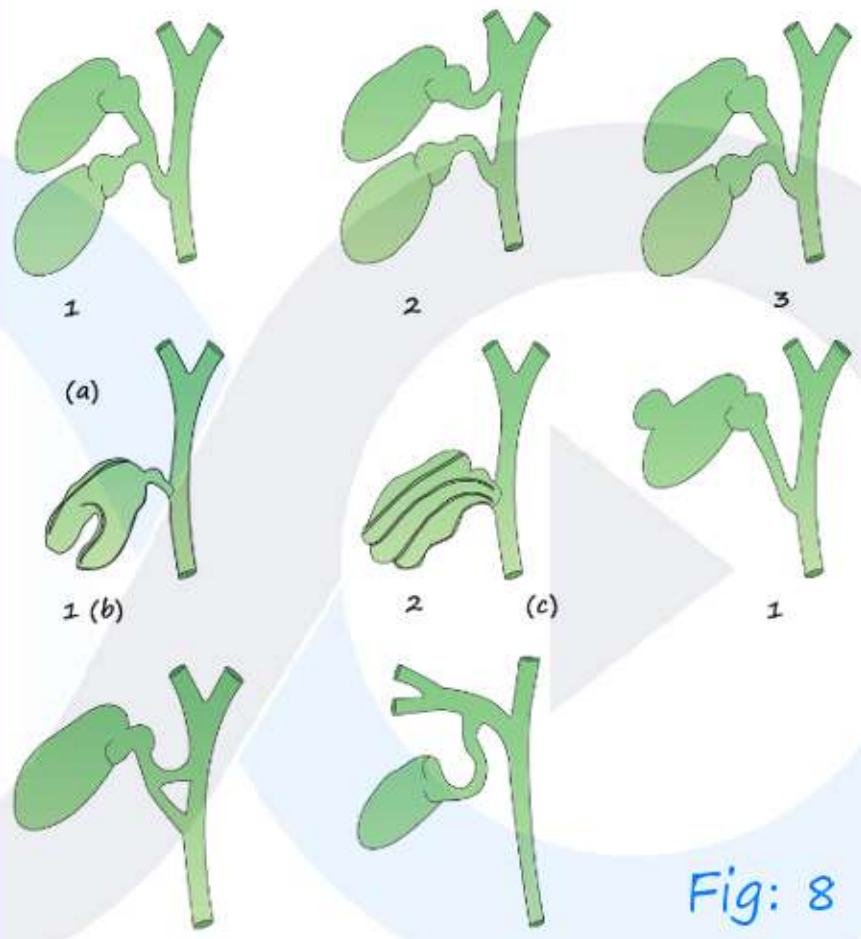

Fig: 8

Anomaly of GB

↓

Most common – Phrygian gap

↓

Fundus of gall bladder is folded upon itself

Fig: 9

10% of gall stones are seen on x-ray

Fig: 10

Porcelain gall bladder

↓

Premalignant

Fig: 11

- Limey bile
  - Tooth paste like material in gall bladder
  - Seen in patients with chronic pancreatitis

Side viewing scope Fig: 12

AfraTafreeh.com

HIDA scan 00:29:16

- Hidroxyimunodiacetic scan
- Uses
  - Detect physiological flow of bile
  - Gold standard to detect acute cholecystitis

↓

Non visualisation of gall bladder
because of edema of cystic duct

- To detect bile leak → not locate the leak exactly
- SOD dyskinesia → bile not enters duodenum

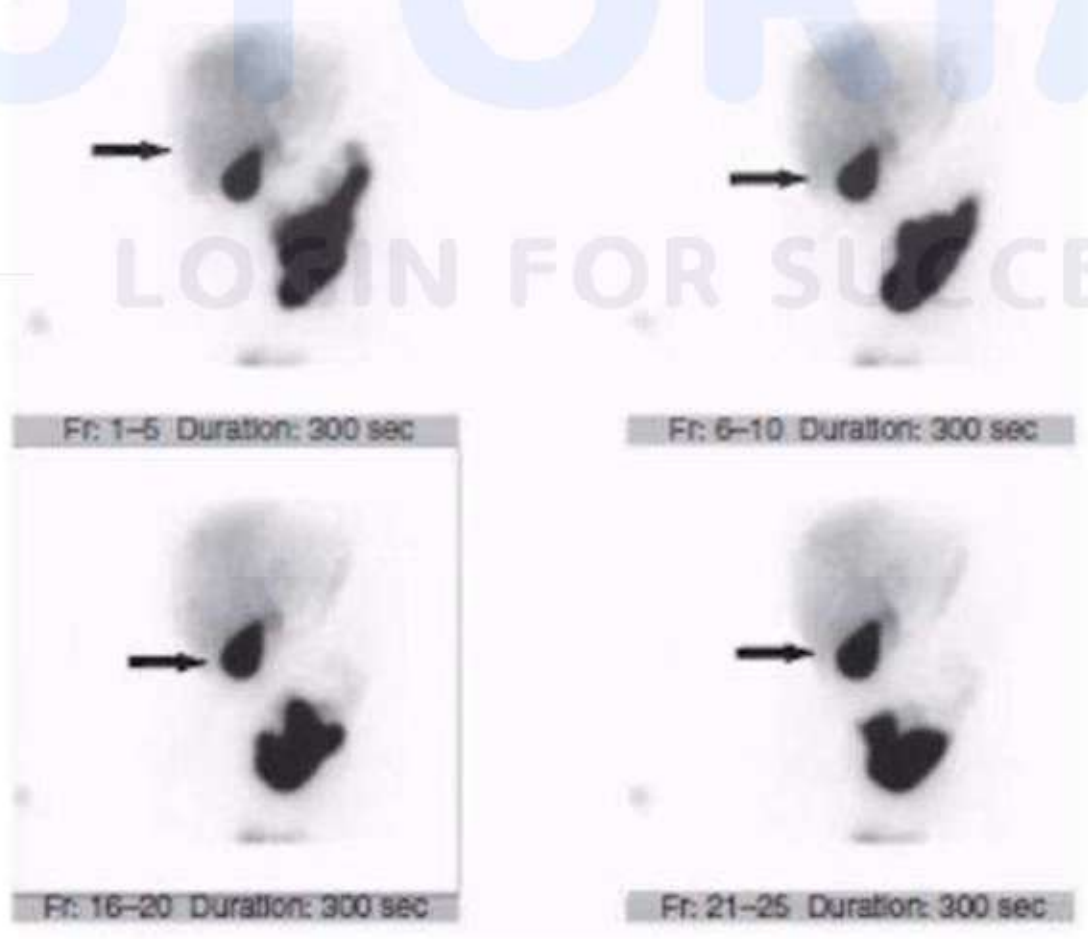

Fig: 13

ERCP Fig: 14

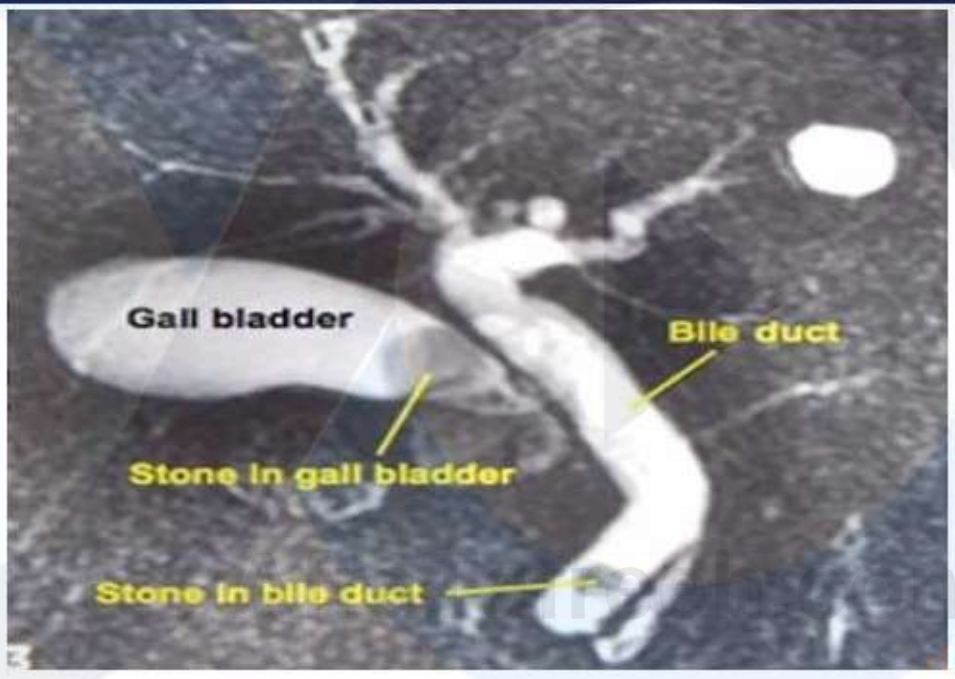

Fig: 15

MRCP

(MRI of biliary and pancreatic system)

- No contrast
- Bile juice and pancreatic juice acts as contrast
- IOC for –
  - CBD pathologies
    i. Hilar cholangiocarcinomas
    ii. Periampullary/distal CBD
  - Pancreas divisum

TUTORIALS LOGIN FOR SUCCESS

AfraTafreeh.com

Fig: 16

Percutaneous transhepatic cholangiogram

↓

Diagnostic + therapeutic



Caroli's disease

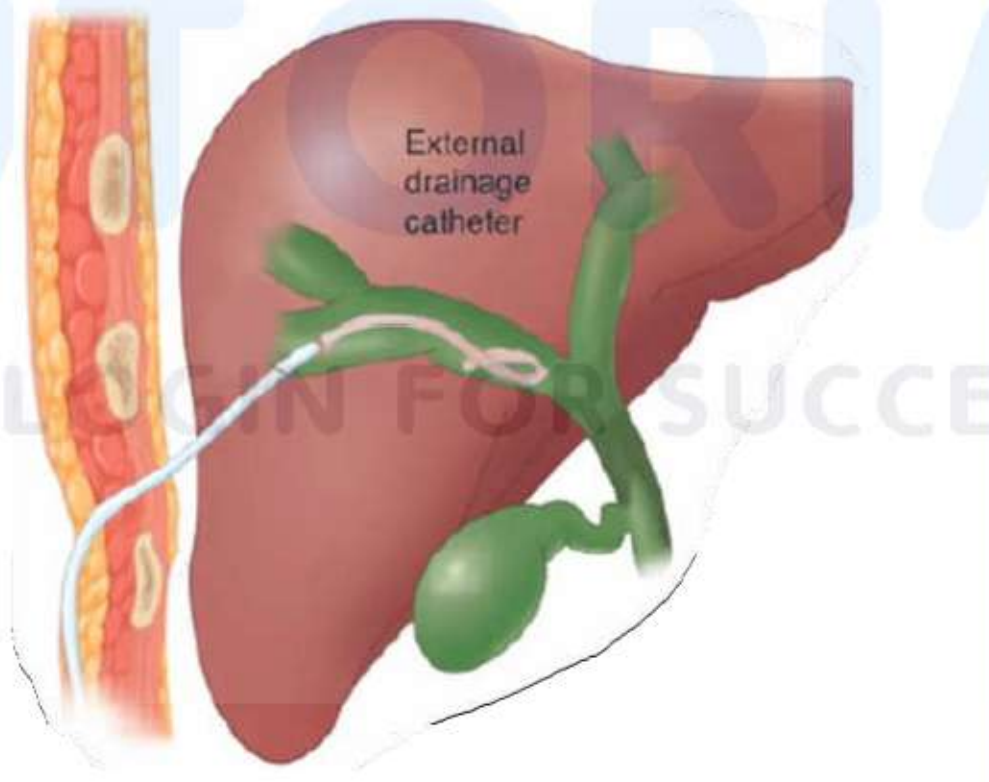

PCT drainage Fig: 17

IOC to study proximal bile duct (Jipmer Q)

Fig: 18

- Mercedes Benz sign
- Seagull sign

} **Findings of gall stones**

Investigations in biliary system 00:36:43

- 1st done – USG abdomen

i. Gall stone

- Posterior acoustic shadow

AfraTafreeh.com

- Mobile stone
- Mercedes Benz sign
- Seagull sign
- 95% of stones detected by USG

ii. Acute cholecystitis (IOC-USG)

↓

Gall bladder wall thickened with pericolic inflammation



AfraTafreeh.com

↓

Gold standard – HIDA scan

iii. Suspected bile duct stone → IOC to see CBD-MRCP



- Confirm stone → ERCP
  - MRCP acts as a road map for ERCP

iv. CBD stone → gold standard → ERCP

v. Gall bladder cancer → Triple phase CT scan

- Hilar cholangiocancer → MPCP + MRA

Old investigation

- Oral Cholecystogram → Iopanoic acid to see radiolucent stones

↓

Graham cole test

- X-ray not used for stones
  - Gas in gall bladder → Pneumobilia
    i. Emphysematous cholecystitis
    ii. ERCP
    iii. Cholecystoduodenal fistula

- USG abdomen

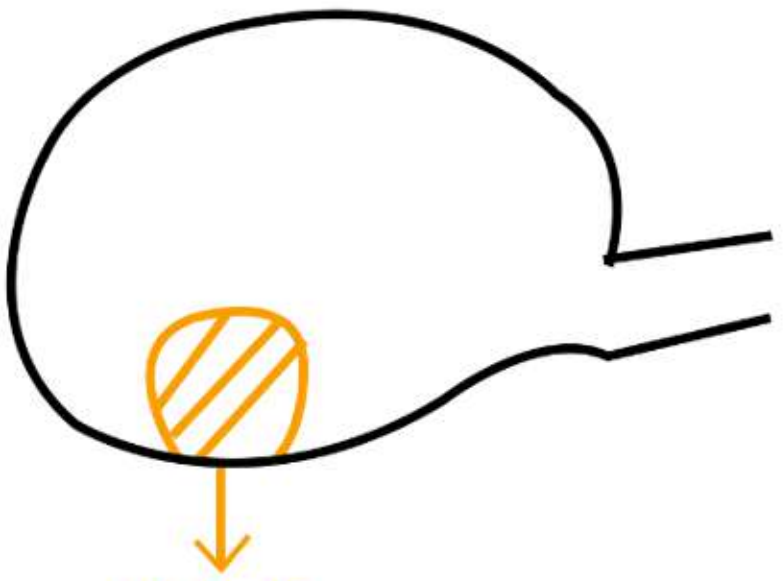

- No posterior acoustic shadow
- Not mobile → Gall bladder polyp

One liners 00:43:33

- Values of heister – cystic duct values
- Moynihan's hump – abnormal right hepatic artery course
- Phrygian cap – most common anomaly
- Von meyenburg complex – Biliary hamartomas

AfraTafreeh.com

Premalignant
↓
Cholangiocarcinoma
↓
IOC-MRCP

Remnants of embryological bile duct
Associated with PCKD

TUTORIALS LOGIN FOR SUCCESS

AfraTafreeh.com

Fig: 19

Meniscus sign (CBD stone)

Pneumobilia Fig: 20

Benign disease in GB and bile duct

i. Cholesterosis/strawberry gall bladder
- Multiple cholesterol stones seen inside gall bladder
- Inflammatory pathology

ii. Adenomyomatosis

iii. Diverticulosis

iv. Polyps
- Most common – cholesterol polyp
- Adenomatous polyp → premalignant

Risk factors for malignancy

- Age > 60years
- Size > 10mm (1cm)
- Polyp + stones
- Serial increases in size
- Family H/o GB cancer

→ **Cholecystectomy**

  - Lap/open → Informed consent for re-do surgery if malignant

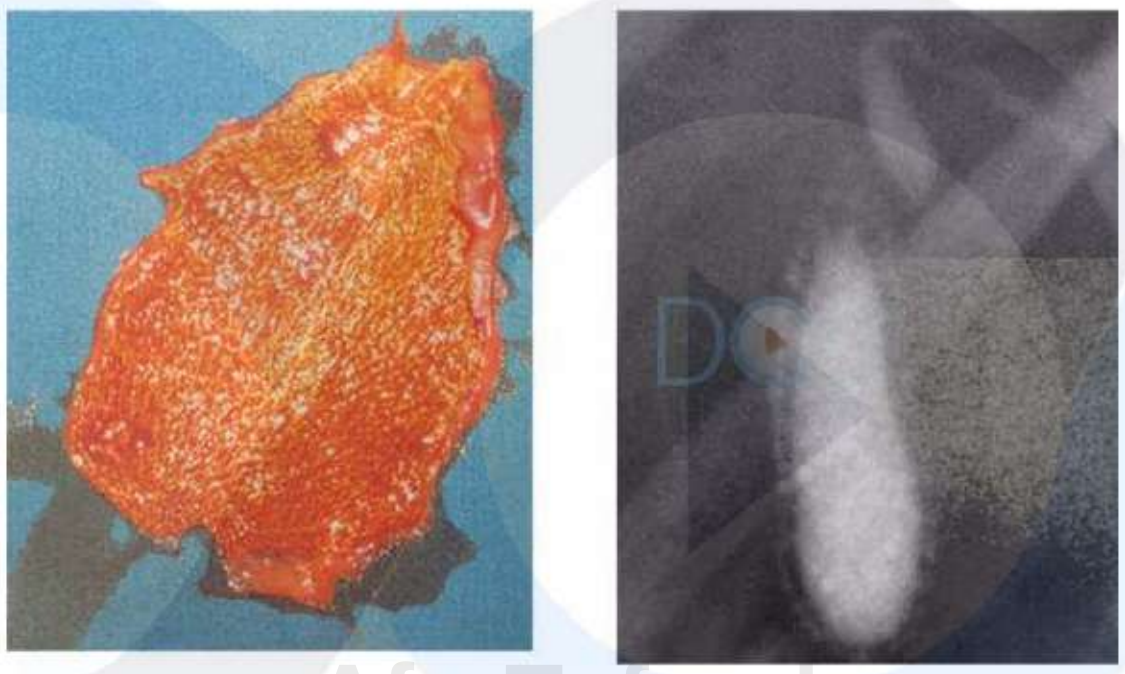

Strawberry gall bladder Fig: 21

AfraTafreeh.com
TUTORIALS
LOGIN FOR SUCCESS

AfraTafreeh.com

GALL STONES

Types of gall stones 00:00:10

Types of gall stones

Cholesterol	**Mixed**	**Pigment stones**
(pure) ↓ Made of cholesterol monohydrate crystals ↓ Most common in western ↓ 15% of radiopaque	↓ >30% cholesterol ↓ Most common world wide	(<30% cholesterol) i. Brown ↓ Most common in Asians Indians ↓ 100% radiolucent; ii. Black ↓ Most common seen in children ↓ >50% radiopaque

Cholesterol 00:03:41

- Most common in western
- Most common in obesity → 5F
  - Fat
  - Fertile
  - Flatulent
  - Female
  - Forty
- Due to cholesterol monohydrate crystalline

↓

Golden yellow colour stones

- Cholesterol: Bile salts (phospholipids)
- 1: 20 → No super saturation of cholesterol
- Increase 1: 20 decreases

  Super saturation of cholesterol

  - < 1:13 → critical ratio for formation of cholesterol stones

Increase cholesterol	**Decrease bile salts**
↓	↓
Obesity	Enterohepatic circulation
Cholesterol rich diet	↓
Clofibrate drugs therapy	Short bowel syndrome
Fasting	Ileal resection
TPN	Chron's disease
Pregnancy	Decrease bile salt production
OCP	↓
Octreotide	Cirrhosis
Somatostatinoma	7-α hydroxylase deficiency

AfraTafreeh.com
TUTORIALS
LOGIN FOR SUCCESS

- Cholesterol stones associated with SAINT's triad
  - Gall stones
  - Diverticulosis of colon
  - Hiatus hernia

Brown pigment stones 00:09:32

- Composition

AfraTafreeh.com

- <30% cholesterol +
- Calcium bilirubinate +
- Calcium sterate +

} **100% radiolucent stone**

- Mainly due to stasis + infection
- Most common stone
  - E.coli
  - Ascaris lumbricoides
  - Cl. Sinensis
- Most common stone
  - FB
  - Clips in bile duct
- Most common stone in oriental cholangiohepatitis → Hepatolithiasis
- 2° bile duct stones
- 1° bile duct → most common – brown stone

Fig: 1

- If patient undergoes laparoscopic cholecystectomy

↓

Within 2years, patient comes with a stone in CBD

↓

Retained/missed stone

>2 years – recurrent stone (Brown pigment stone)

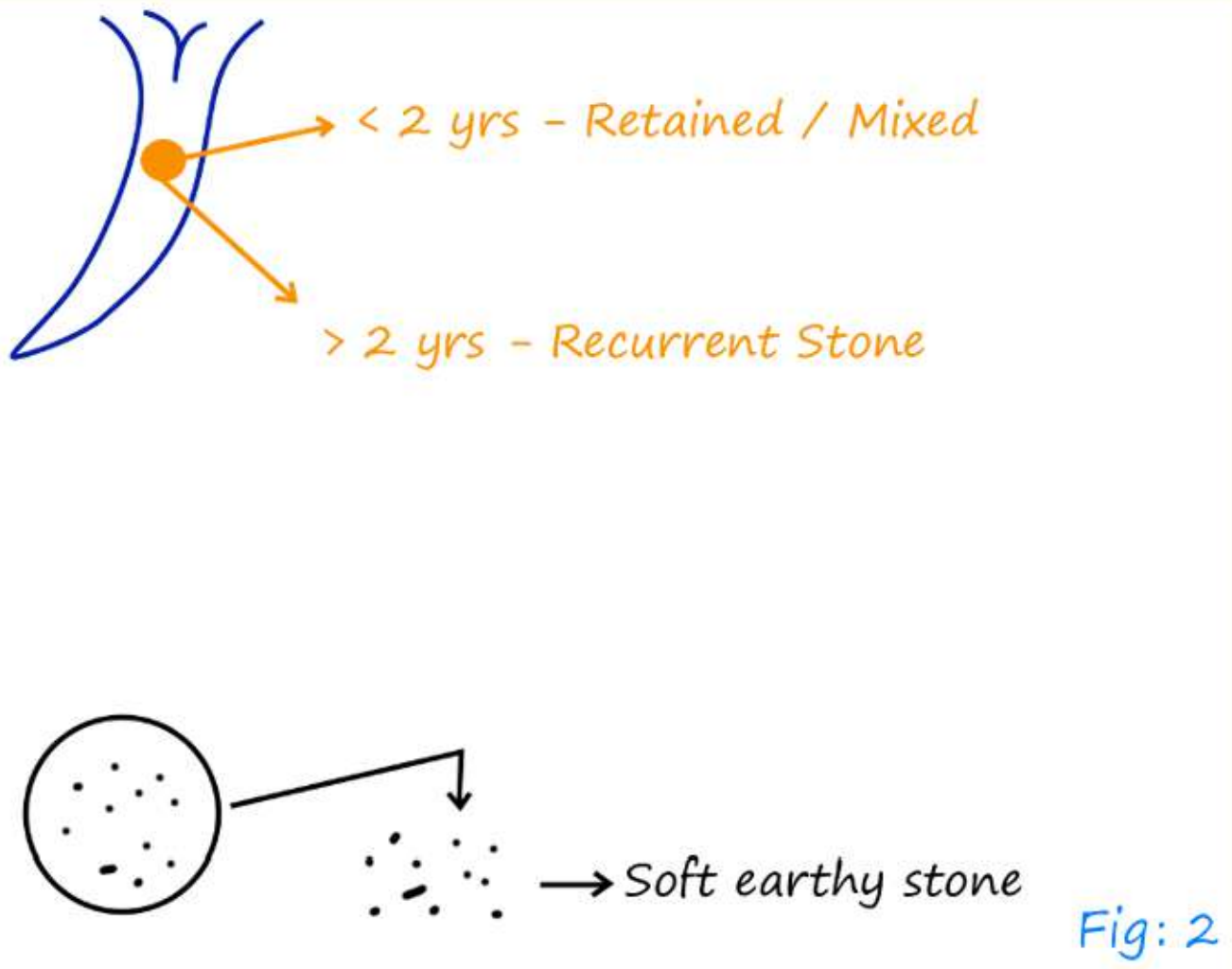

Fig: 2

Black pigment stones 00:14:42

- Composition:
  - Insoluble pigment bilirubin polymer +
  - Calcium phosphate +
  - Calcium carbonate

  (Calcium phosphate + Calcium carbonate) → **>50% radiopaque**
- Most common in haemolytic anaemias (children)
  - Hereditary spherocytosis
  - Sickle cell anaemia
  - Autoimmune
- Other causes
  - Cirrhosis
  - Mechanical heart valves
  - Gilbert syndrome
  - Cystic fibrosis
  - Ileal resection (most common brown stones)

AfraTafreeh.com

Clinical features of gall stones 00:17:19

- Mostly asymptomatic (90%)

As soon as the patient takes oily food

↓

Gall bladder contracts

↓

One stone occluded @ cystic duct

↓

Pain starts slowly and increases → Biliary colicky pain

↓

Stone either goes to gall bladder (or) CBD

↓

Pain relieved

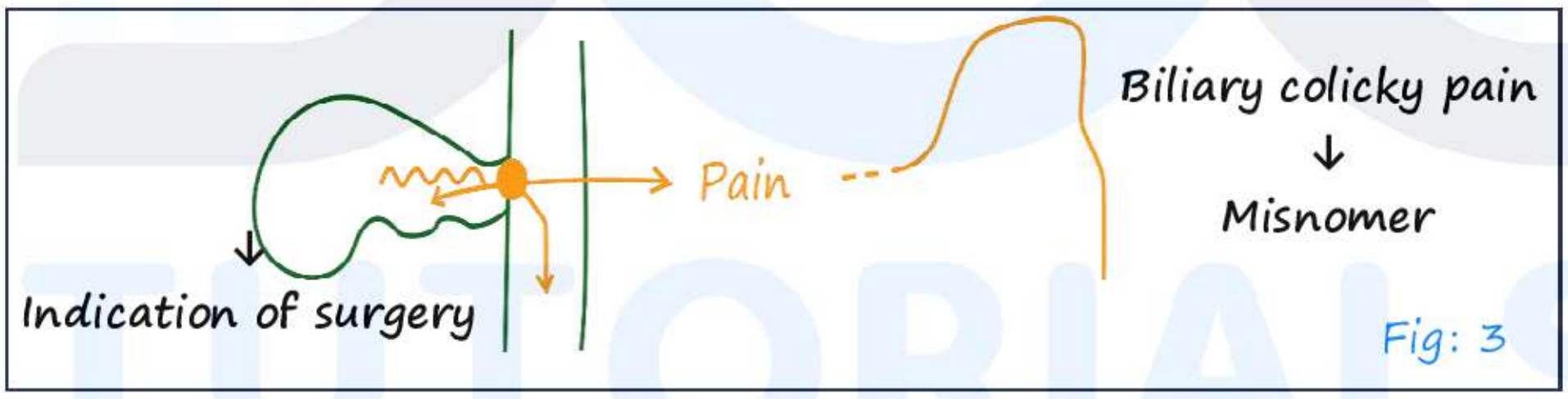

Fig: 3

TUTORIALS
LOGIN FOR SUCCESS

Complications

- Most common – Acute cholecystitis

Pain @ right hypochondrium

Fever ⊕

- Murphy's sign ⊕ → Ask the patient to sit and keep his hand over right subcostal plane

↓

Sitting position

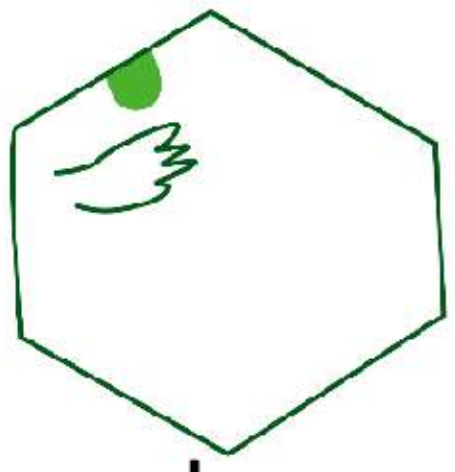

↓ take deep breath ↓ gall bladder touches the hand @ 9th costal cartilage

↓

Moynihan's method → gall bladder examined in supine position

- Boas sign – Hyperaesthesia over right hypochondrium
- IOC for acute cholecystitis – USG abdomen – thickened GB wall, pericystic fluid.

AfraTafreeh.com

Tokyo guidelines for management of acute cholecystitis 00:23:02

TUTORIALS LOGIN FOR SUCCESS

- Grade I
  - Mild
  - Only clinical features seen
  - Treatment: immediate lap cholecystectomy
- Grade II
  - Moderate
  - Fever ⊕
  - Palpable mats ⊕
  - Gangrene ⊕
  - Increased WBC count >18,000

AfraTafreeh.com

- Treatment: Immediate lap cholecystectomy

↓

Open technique if any problem

- Grade III – Organ failure signs
  - Decrease BP
  - Decrease PaO_2
  - Increases serum Creatinine
  - Altered sensorium
  - Treatment: percutaneous cholecystostomy

Management

- NPO
- IVF
- Antibiotics
- Ryle's tube aspiration
- Urinary drainage
- Early lap cholecystectomy: Bailey (<72hours), Sabiston (1week)
  - Interval lap cholecystectomy (delayed): >6weeks
- More chances of converting to open cholecystectomy

Complications of gall stones 00:27:58

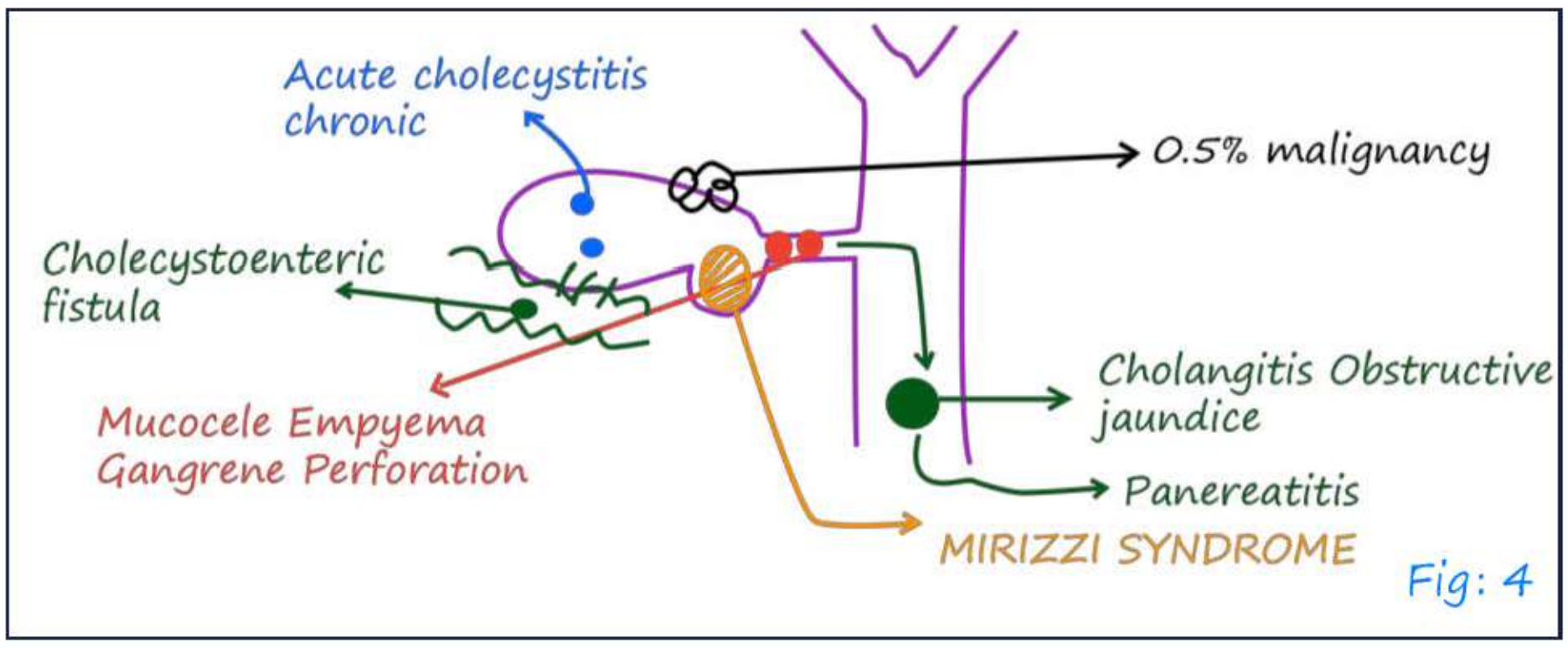

Fig: 4

1.Acute cholecystitis: Tokyo guidelines

2.Mirizzi syndrome

- Stone in Hartmann pouch compress the bile duct causing obstructive jaundice
- Calot's triangle is completely disturbed
- Open cholecystectomy
- CSENDES classification

↓

– Type I: Compression only

– Type II: <1/3 circumference of bile duct eroded

– Type III: 2/3 circumference of bile duct eroded

– Type IV: complete fistula

- Cholecystocholedochal fistula (type II and type III)
- Subtotal cholecystectomy → use the wall of gall bladder to close the defect

↓

Flap of GB wall used to close

AfraTafreeh.com

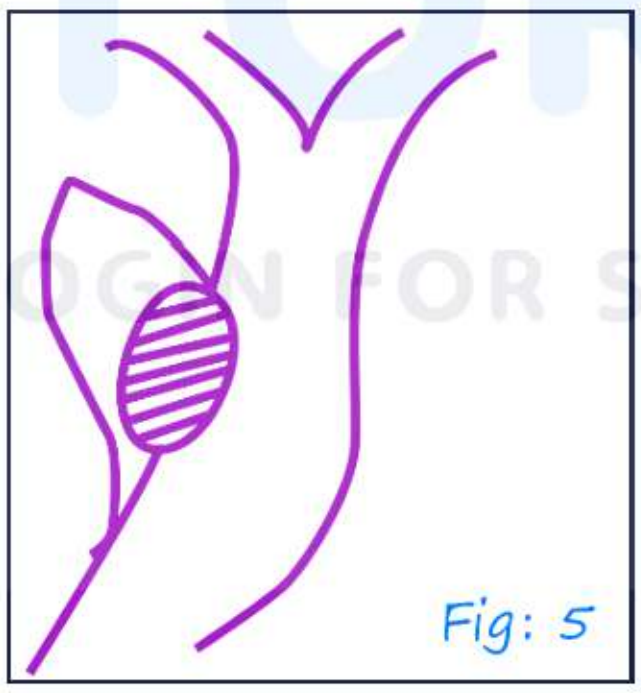

Fig: 5

3.Cholecystoenteric fistula

↓

Common from the stones sitting in the body (or) fundus of gall bladder

↓

erosion of duodenum nearby and

AfraTafreeh.com

forms fistula with duodenum

- Most common site: Duodenum > Transverse colon
- Stone causes occlusion of duodenum itself

↓

Bouvert syndrome

- Stone can pass through ileum and occlude the terminal ileum

– Tumbling obstruction
– Pneumobilia
– Fistula between GB and duodenum

} RIGLER'S TRIAD

- Treatment → Patient unstable

↓

Enterotomy

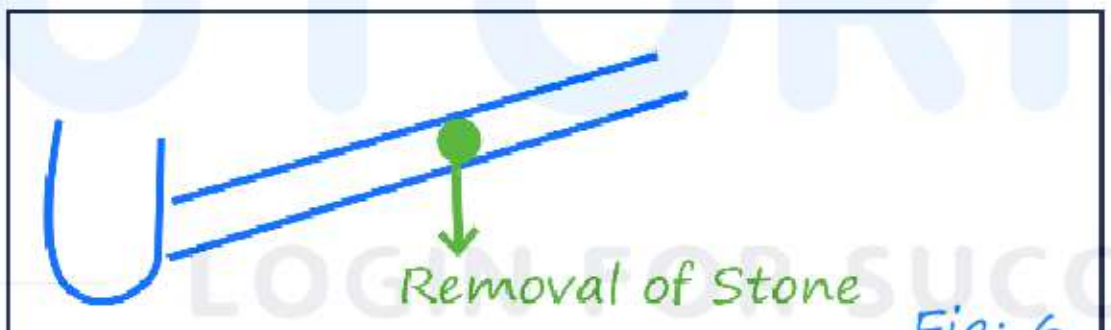

Fig: 6

- Patient stable

i. Enterotomy + stone removal
ii. Cholecystectomy
iii. Close the fistula

4.Gall bladder Ca → 95% associated with stones

- 0.5% of gall stones cause ca

- Risk of cancer >10% → ≥2.5cm stones
  ↓
  Prophylactic cholecystectomy

5.Cholangitis
6.Pancreatitis
] **Increase mortality rate seen**

Gall stones

- Most common type of stone – Mixed stone
- Types of stones
  - Cholesterol stones
  - Brown pigment stones
  - Black pigment stones
  - Mixed

Fig: 7

AfraTafreeh.com

MANAGEMENT OF GALL STONE

Medical Management 00:00:30

Cholesterol stones

- Decreases cholesterol
  ↓
  HMG CoA Reductase Inhibitors
- Increases Bile salt
  ↓
  UDCA

Indications

1. Stone < 1.5cm
2. Radiolucent stone
3. Functioning gall bladder present → HIDA scan → to know the functioning of gall bladder
4. Non acute symptoms

Gold Standard 00:03:31

- Lap cholecystectomy
- 1st done – ERIC MUHE

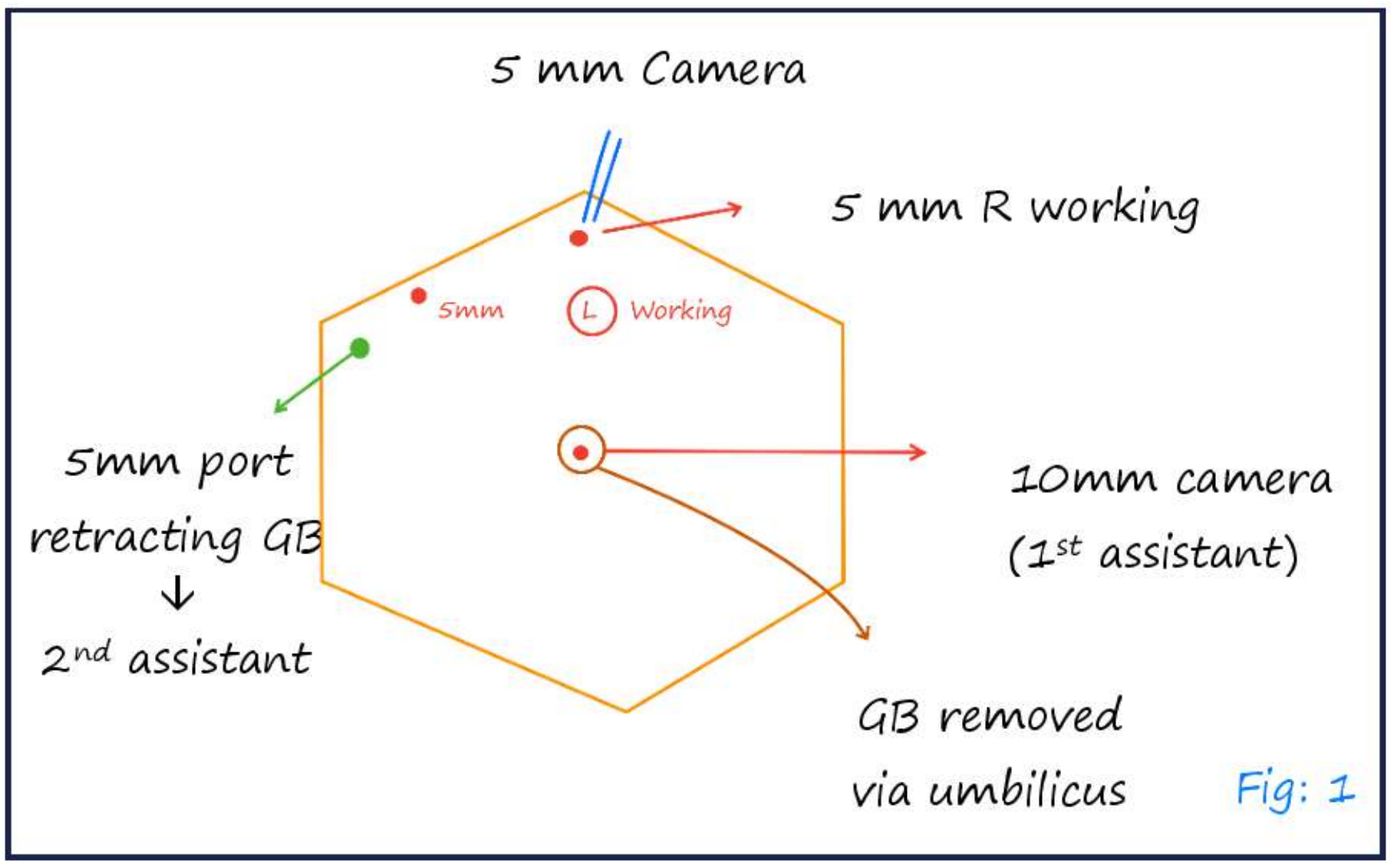

Fig: 1

- Gall bladder removed by 2 methods
  - Fundus 1st
  - Retrograde technique



AfraTafreeh.com
TUTORIALS
LOGIN FOR SUCCESS

Retrograde cholecystectomy

Critical view of Strasberg

↓

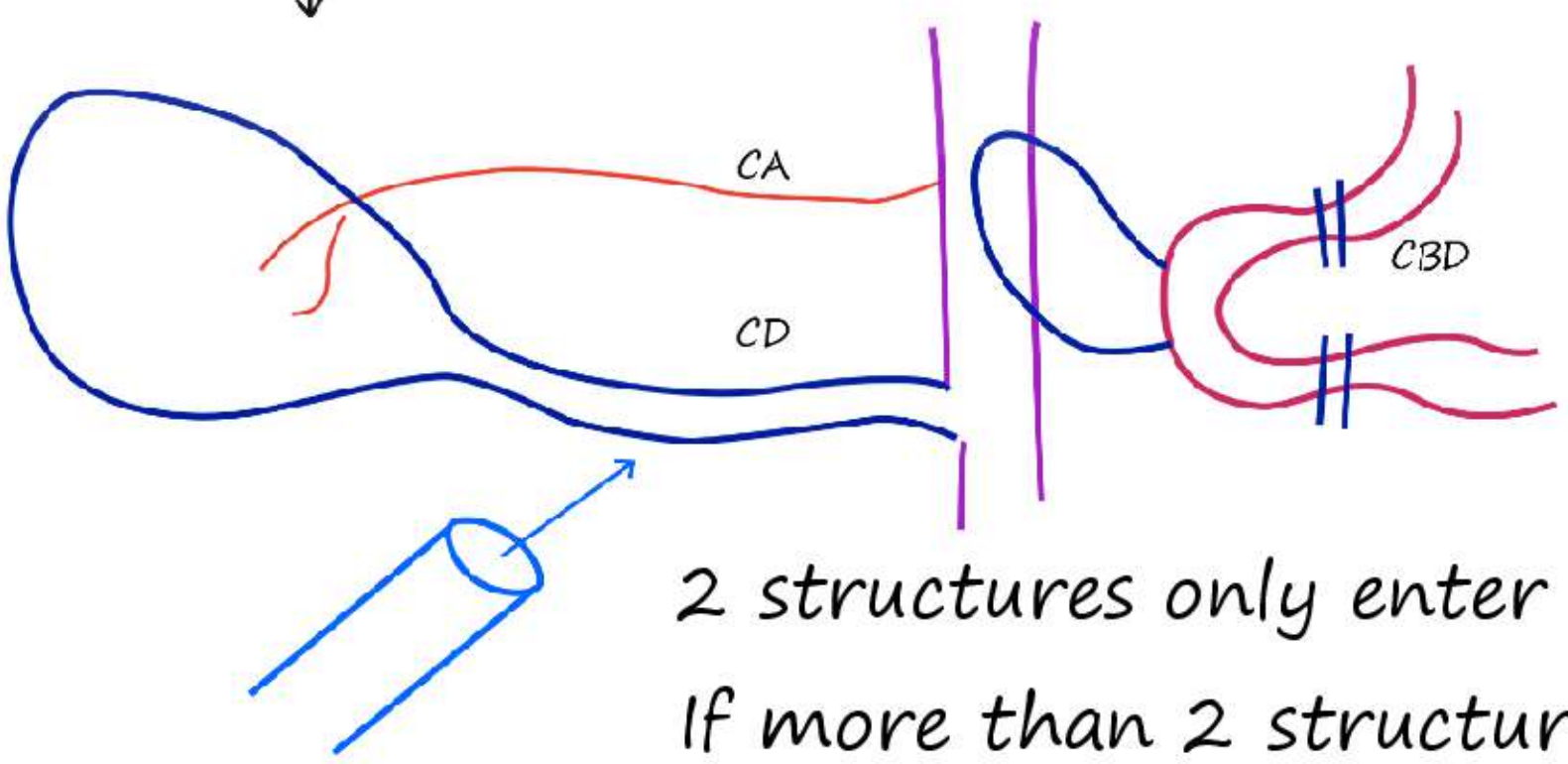

2 structures only enter GB
If more than 2 structures
seen, then it might be CBD

AfraTafreeh.com

Indications of Surgery 00:09:13

1. All symptomatic cases
2. In asymptomatic gall stones
   - 2.5 cm stone
   - + polyp
   - + anomaly
   - Family H/O GB cancer → Immuno compromised
     ↓
     - Chemotherapy
     - HIV 1,2 positive
3. Prophylactic cholecystectomy
   - Porcelain gall bladder
   - BPD bypass surgery
   - Heart and lung transplant (cyclosporine therapy – gallstones)
   - Chronic typhoid carriers
   - On long term TPN

TUTORIALS
LOGIN FOR SUCCESS

- In bailer, cholecystectomy should be done in type 2 DM patients even though they are asymptomatic.

  Not indicated → In multiple GB stones
  ↓
  asymptomatic

Indications of Open Cholecystectomy 00:16:02

1. Cirrhosis + PHT
2. Bleeding disorders
3. Poor CP reserve (COPD, CAD)
4. Suspected GB cancer → chances of dissemination in laparoscopic
5. Unclear anatomy of calot's – MIRZZI Syndrome

Relative C/I for laparoscopy

1. Pregnancy
2. Morbidity obese
3. Adhesions
4. perforated GB

AfraTafreeh.com

TUTORIALS

LOGIN FOR SUCCESS

Acalculus Cholecystitis 00:19:11

- Most common in Hospitalized patients – DM, CKD, Sepsis, Major surgery, TON, burns, typhoid streptococci
- Incidence – 5% of all cases
- Highest mortality
- IOC – USG, Gold standard – HIDA (non visualization of GB)
- Fit for surgery → Immediate cholecystectomy by open method
- Unfit – Percutaneous cholecystectomy

AfraTafreeh.com

BILE DUCT INJURY

Introduction 00:00:12

- Seen in 0.3–0.8% in laparoscopic cases
- Seen in 0.1–0.2% in open cases
- Clinical features
  - Fever
  - PR +++
  - BP decreased
  - O/E – tenderness – Ⓡ hypochondrium

Next step: USG abdomen

↓

Bilioma will be detected

Not IOC for bile leak

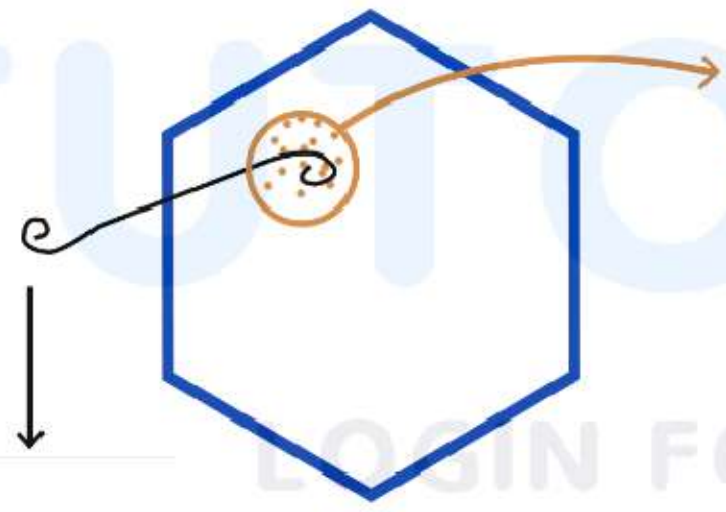

Fig: 1

PCD of collection

↓

Wait and watch for 2 weeks

↓

By 2 weeks → IOC for bile leak

↓ INICET 2020Q

ERCP

↓

Strassberg classification

Strassberg classification 00:05:20

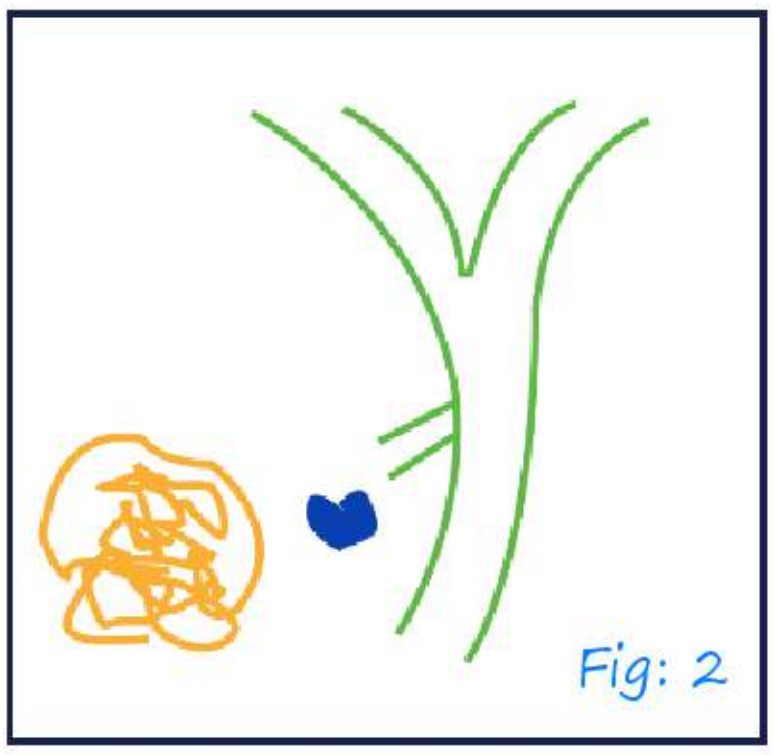

Fig: 2

- Type A – Cystic duct blow out
  - Most common

DOC TUTORIALS
AfraTafreeh.com
LOGIN FOR SUCCESS

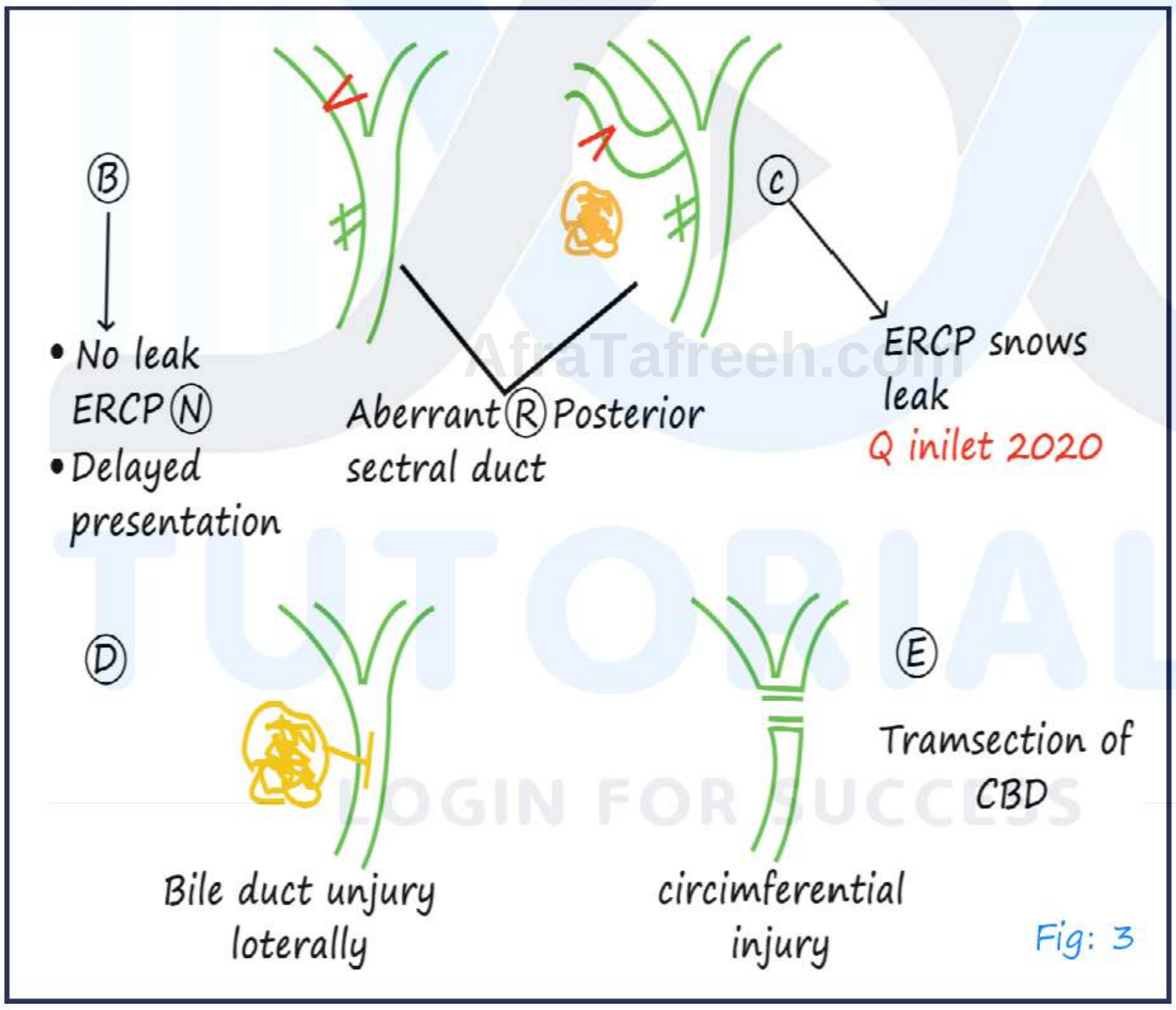

Fig: 3

Sphincterotomy + DP stent

↓

Stricture Bile duct

↓

After 8-12 weeks

C/f: obstructive jaundice

IOC: MRCP



Fig: 4

AfraTafreeh.com

Bismuth classification 00:11:07

1.Stricture seen > 2cm from confluence

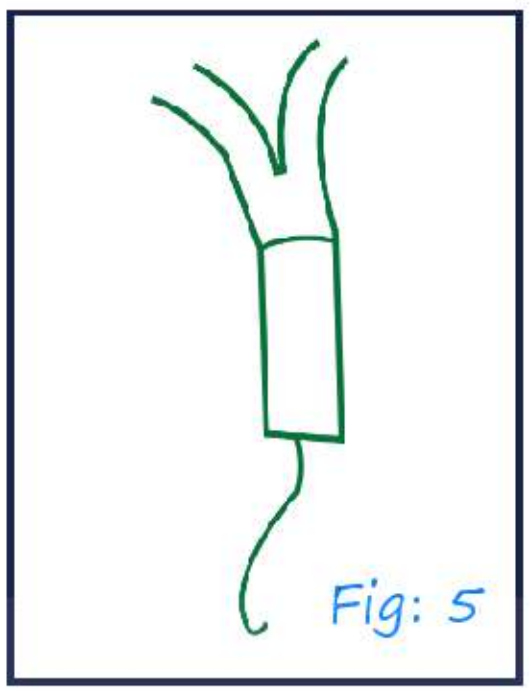

Fig: 5

2.Stricture seen within 2cm from confluence proximal stricture



Fig: 6

3.Confluence stricture (or) hilar stricture

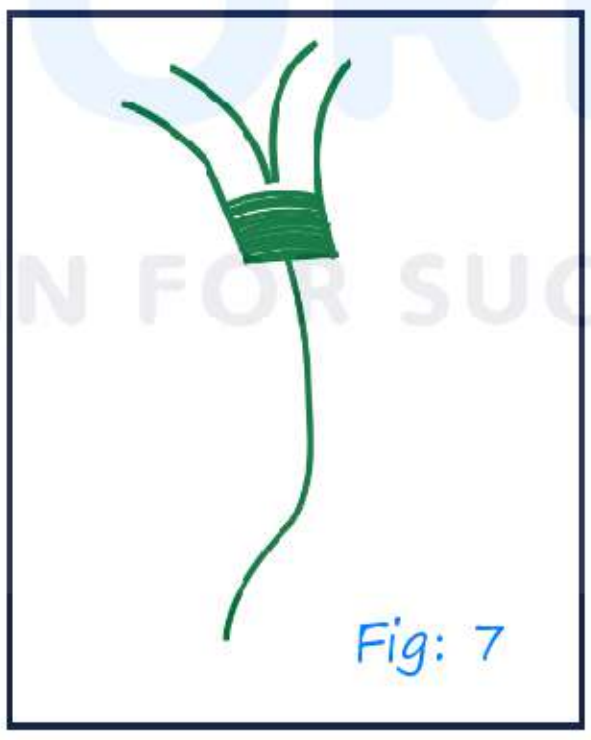

Fig: 7

4.Complete destruction with separated duct

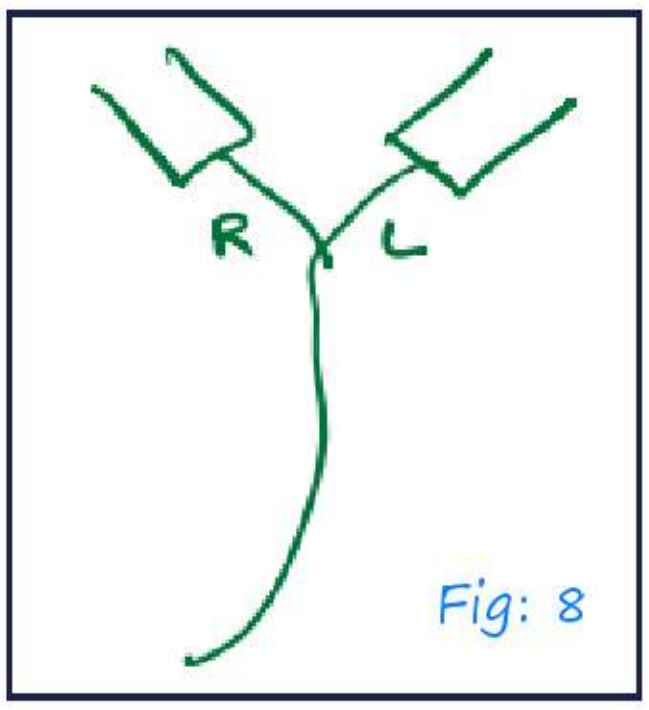

Fig: 8

5.Aberrant ® posterior sectoral duct stricture



Fig: 9

Hepatico jejunostomy 00:13:49

- > 8-12 weeks

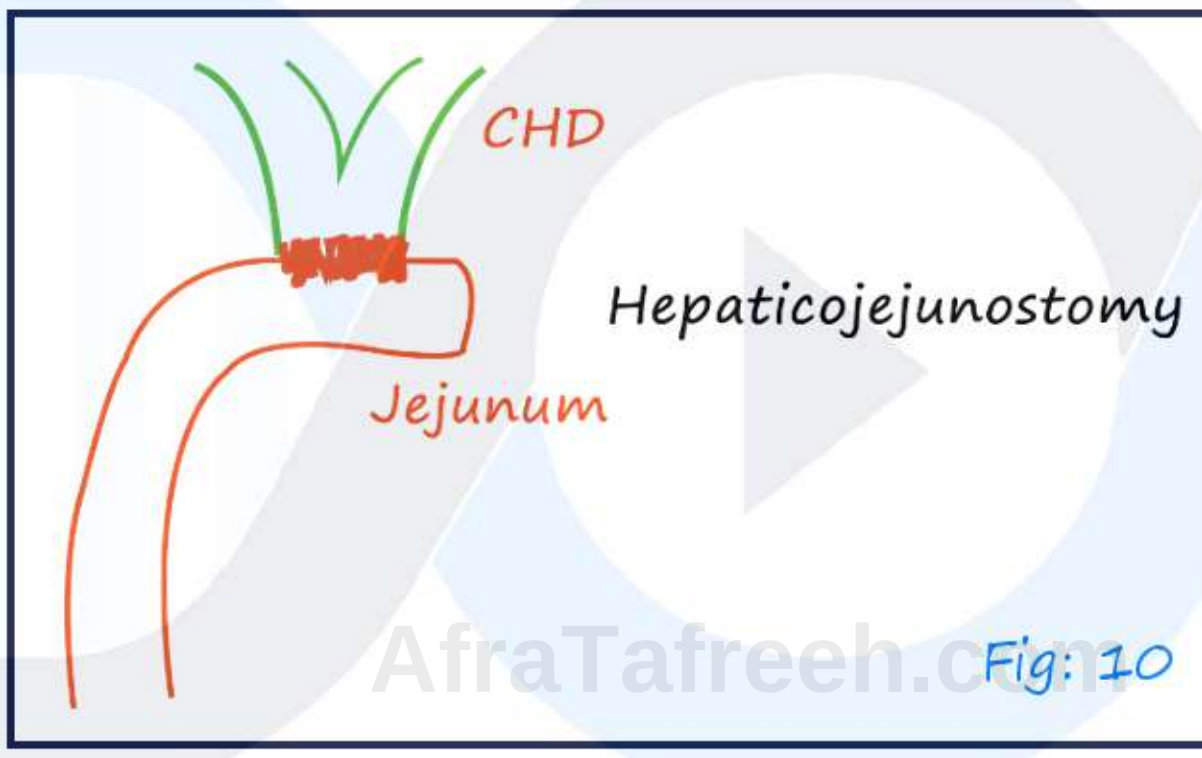

Fig: 10

On table call over 00:14:56

- Bile seen in operative field

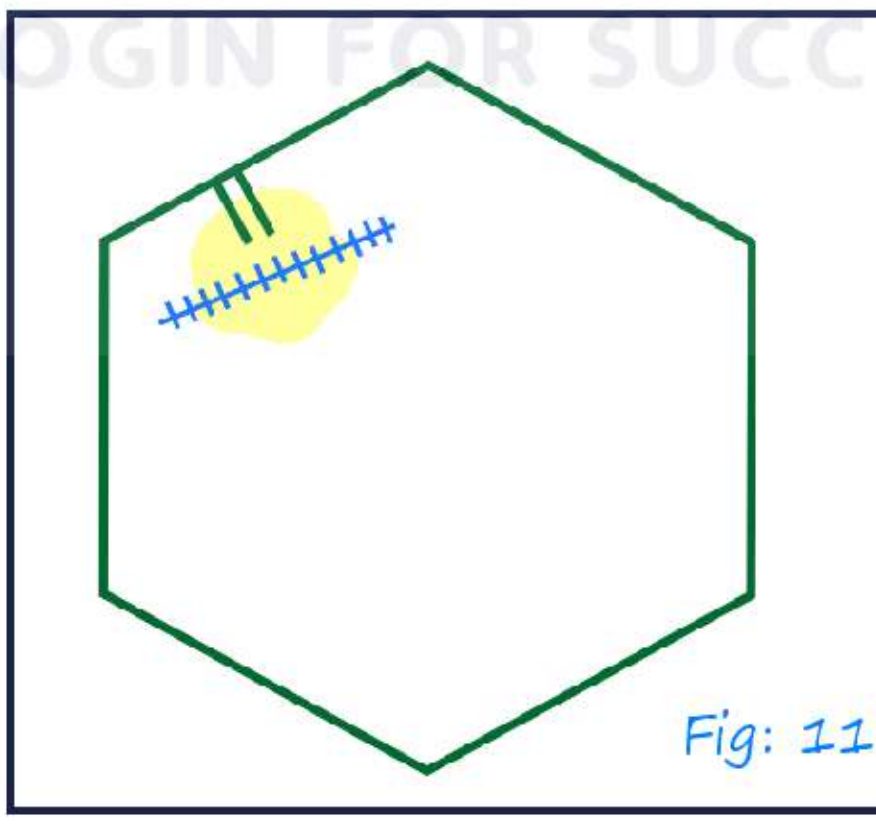

Fig: 11

→ ® subcostal incision

Open the abdomen

Duct > 3mm – Repair → 4-0 vicryl

< 3mm – Ligate

AfraTafreeh.com

AfraTafreeh.com

- If it's a common duct injury (<50% circumference)

  -Repaired by keep 'T' tube inside (4-0 vicryl)

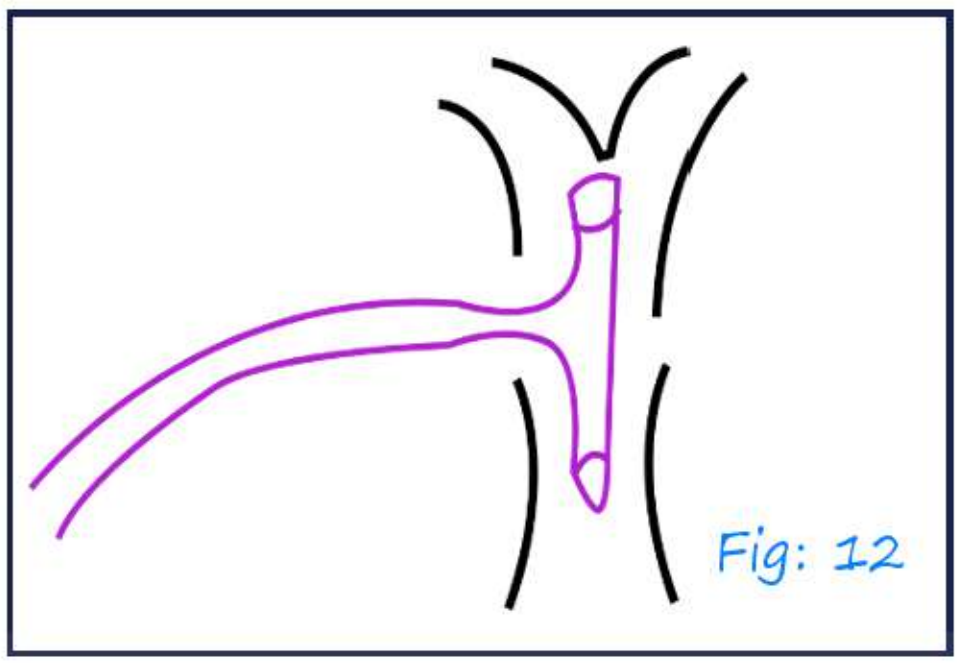

Fig: 12

- > 50% circumference → on table hepaticojejunostomy

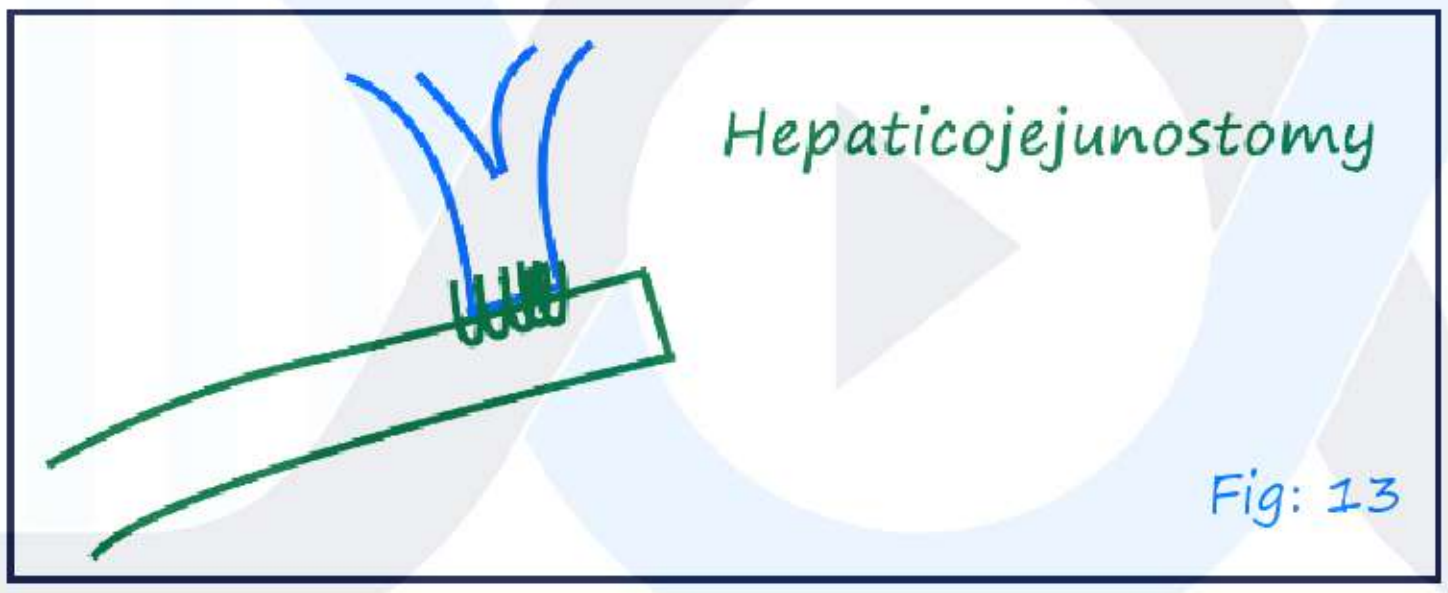

Fig: 13

Inexperienced in biliary surgery 00:17:42

- Keep a drain and refer to surgical gastroenterologist as early as possible

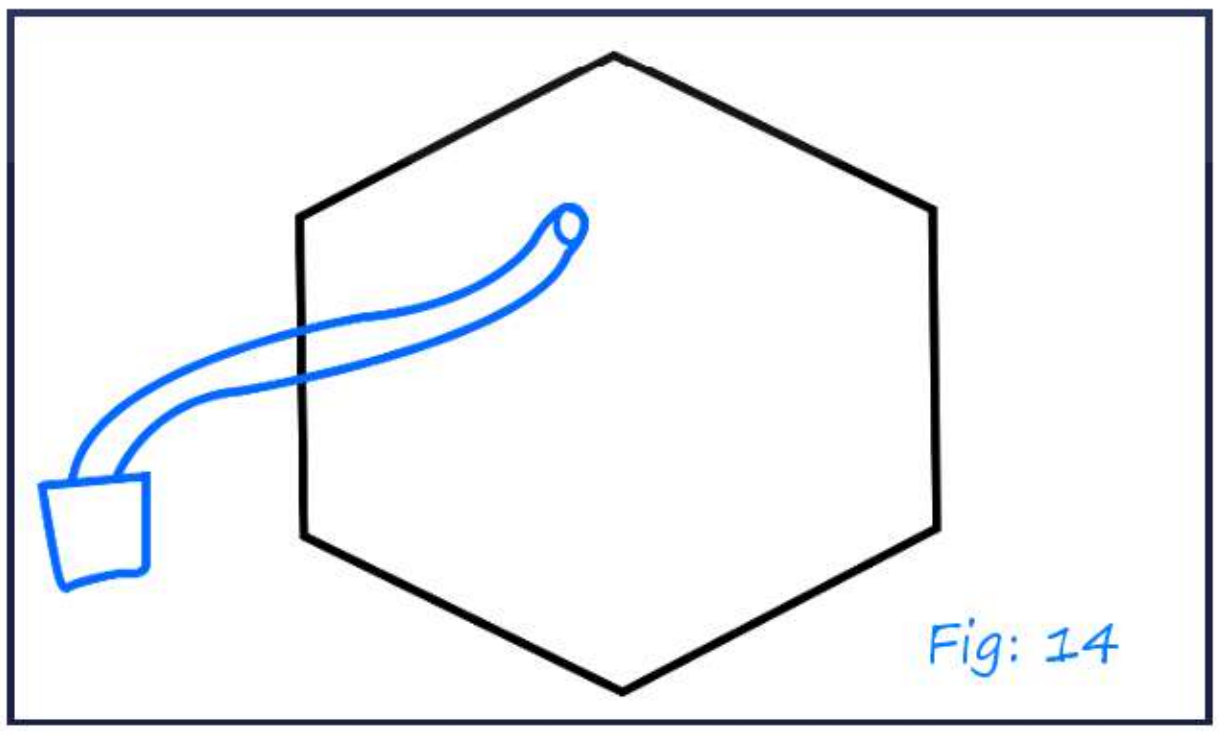

Fig: 14

- Immediate repair within 4-6 hours should be done

DOC TUTORIALS LOGIN FOR SUCCESS

Note: Watch Video 19:22

Fig: 15

TUTORIALS
LOGIN FOR SUCCESS

AfraTafreeh.com

CBD STONES

Basics 00:00:15

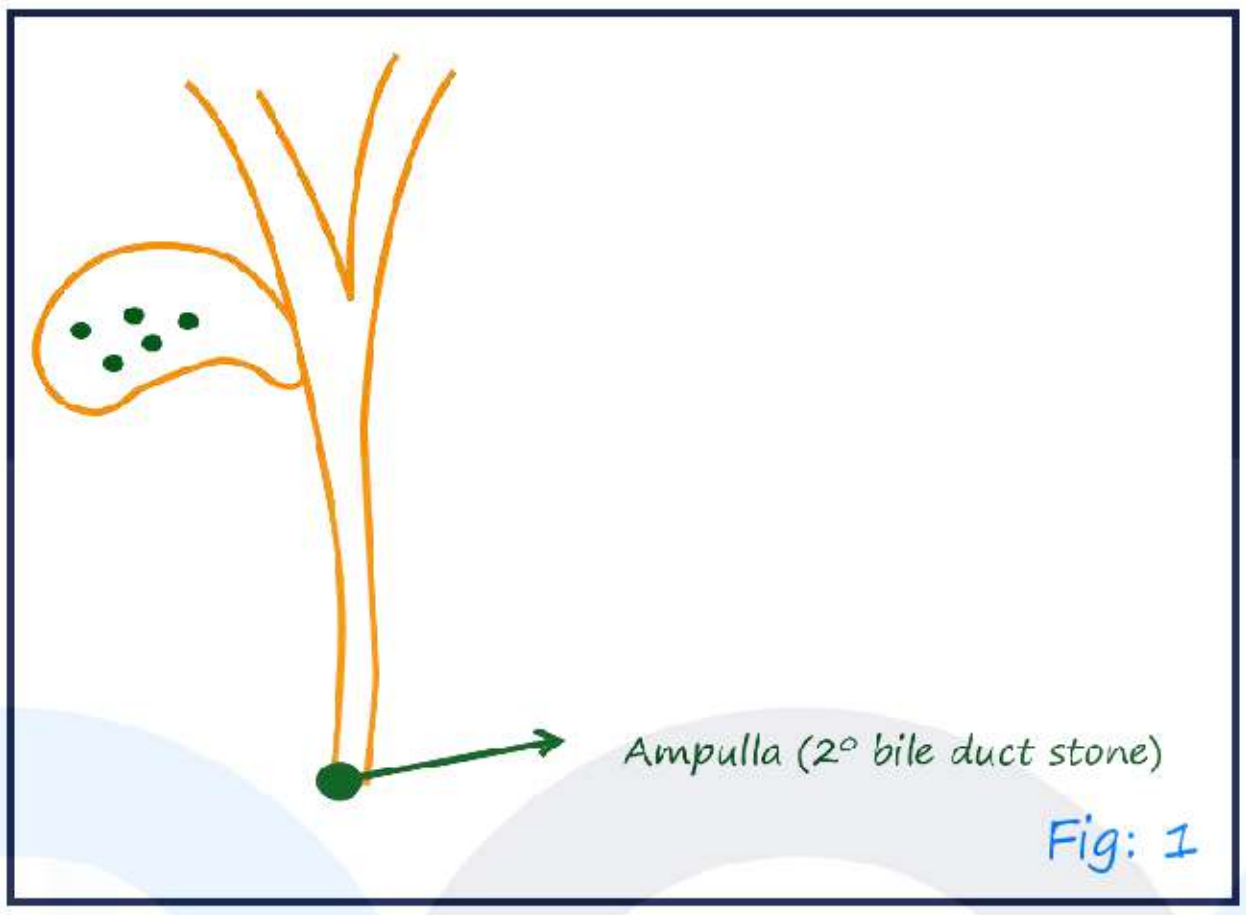

Fig: 1

- Common bile duct stones usually come from gall bladder only
  - Most common site of obstruction – ampulla → 2° BD stone
- If stone is formed in gall bladder
  - 1° BD stone (brown stone)
- Presents with obstructive jaundice
- One of the worst complication of CBD stone

↓

Cholangitis

↓

Charcot's triad (10% mortality)

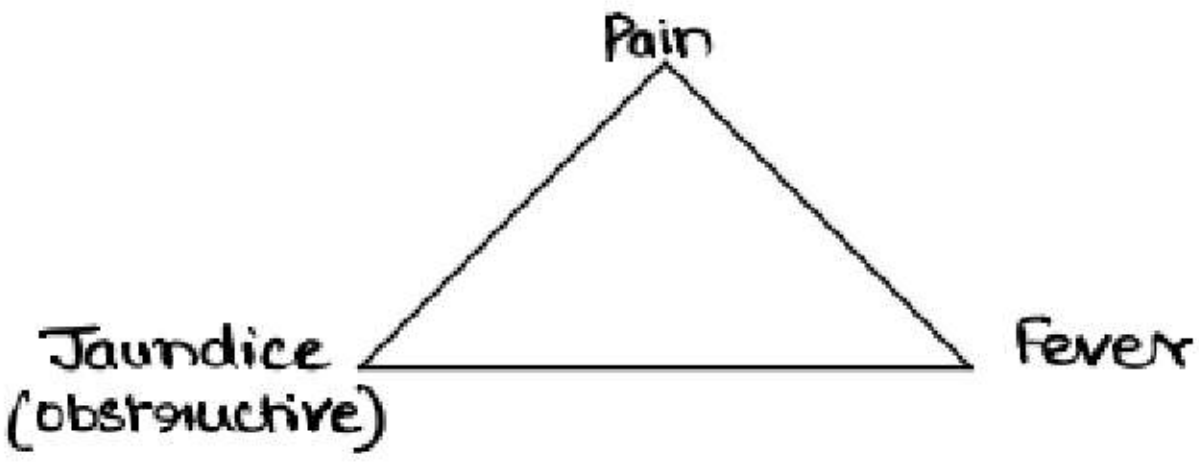

- If not treated
  - Reynauld's pentad (20-50% mortality)
    - i. + septic shock
    - ii. + mental status changes
- 1st done: - USG abdomen
- IOC: - MRCP
- Gold standard: - ERCP (Diagnosis/ treatment)

Jaundice + pain + fever (cholangitis)

- Admit in ICU
- IVF
- Higher antibiotics
- Monitor vitals

AfraTafreeh.com
TUTORIALS
LOGIN FOR SUCCESS

Not resolved

↓

Emergency ERCP+
Sphincterotomy+
Stone removal+
Stenting

↓

Failed ERCP

↓

Interventional transhepatic biliary drainage (PTBD)

↓

Failed PTBD

↓

SGE → Cholecystectomy + CBD exploration (Kehr's T tube)

Resolve cholangitis → SGE → Cholecystectomy + CBD exploration (Kehr's T tube)

AfraTafreeh.com

Jaundice+ (No cholangitis)

- 2 methods

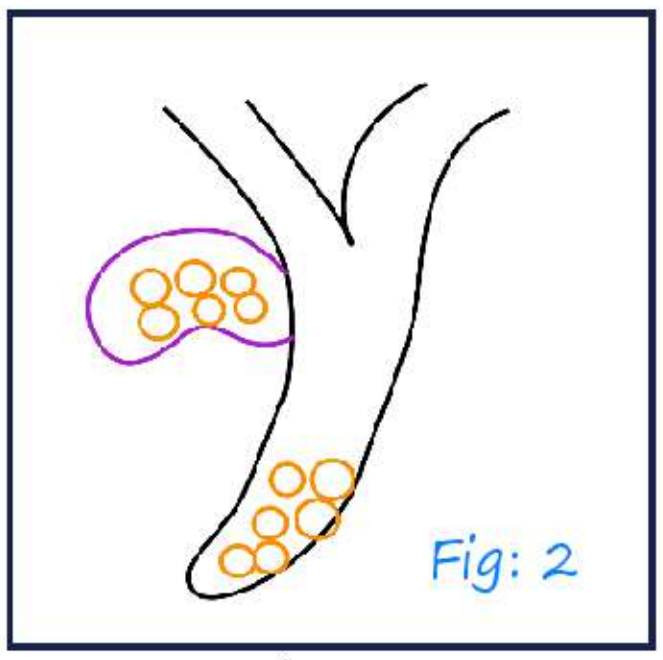

Option 1

MGE → ERCP + Sphincterotomy
Stone removal
Stenting done
↓
SGE → Lap cholecystectomy (most common followed)

Option 2

SGE → Open/ lap chole

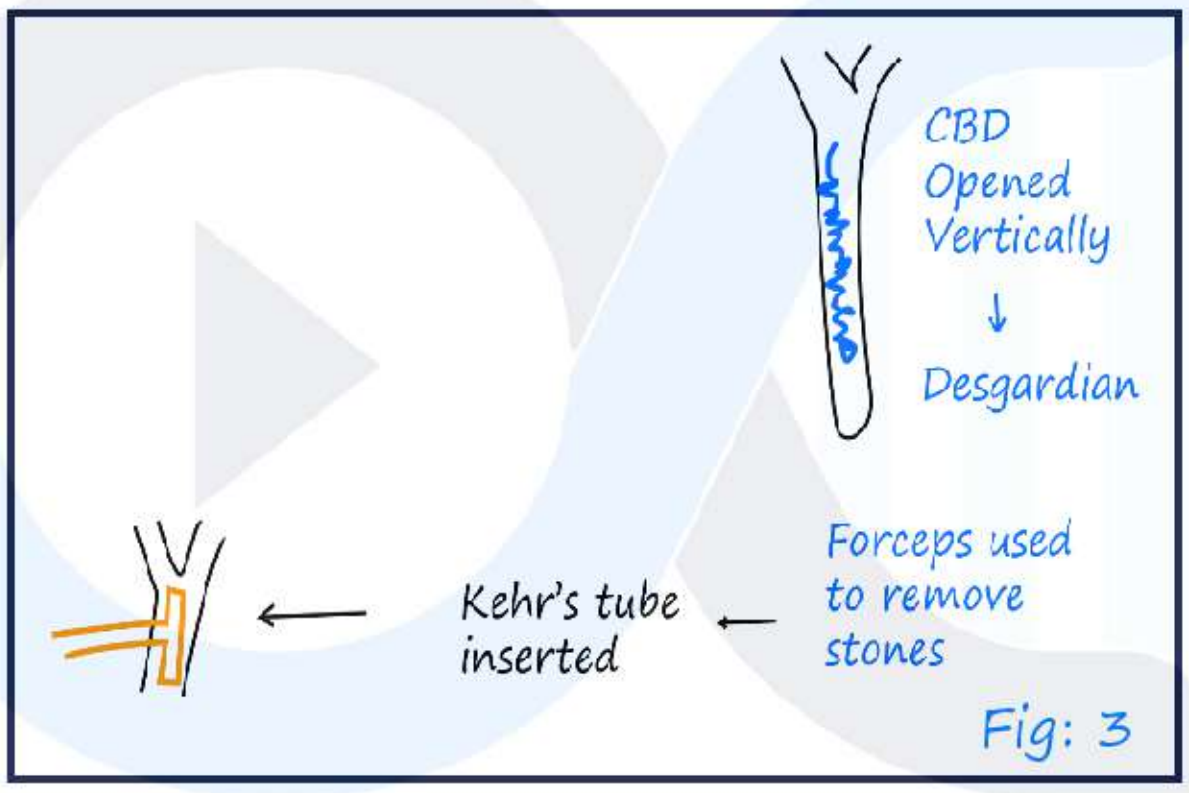

- Choledocholithomy (CBD exploration)
  - CBD < 12mm – 'T' tube
  - CBD > 12mm – Choledochoduodenostmoy/jejunostomy

TUTORIALS LOGIN FOR SUCCESS

ERCP contraindications 00:16:15

1. CBD stone > 1.5 mm
2. Multiple CBD impacted stone
3. Ampullary stenosis
4. Proximal hepatic duct stones

(1–4) – Direct CBD exploration

CBD stones

- **Cholangitis**
  - ↓ IVF, antibiotics
  - ↓ ERCP stone removal
  - ↓ PTBD
  - ↓ OC + OCBD
- **No cholangitis**
  - ERCP+ Stone+ LC
  - LC + LCBD
  - OC + OCBD

Purpose of kehr's 'T' tube 00:19:15

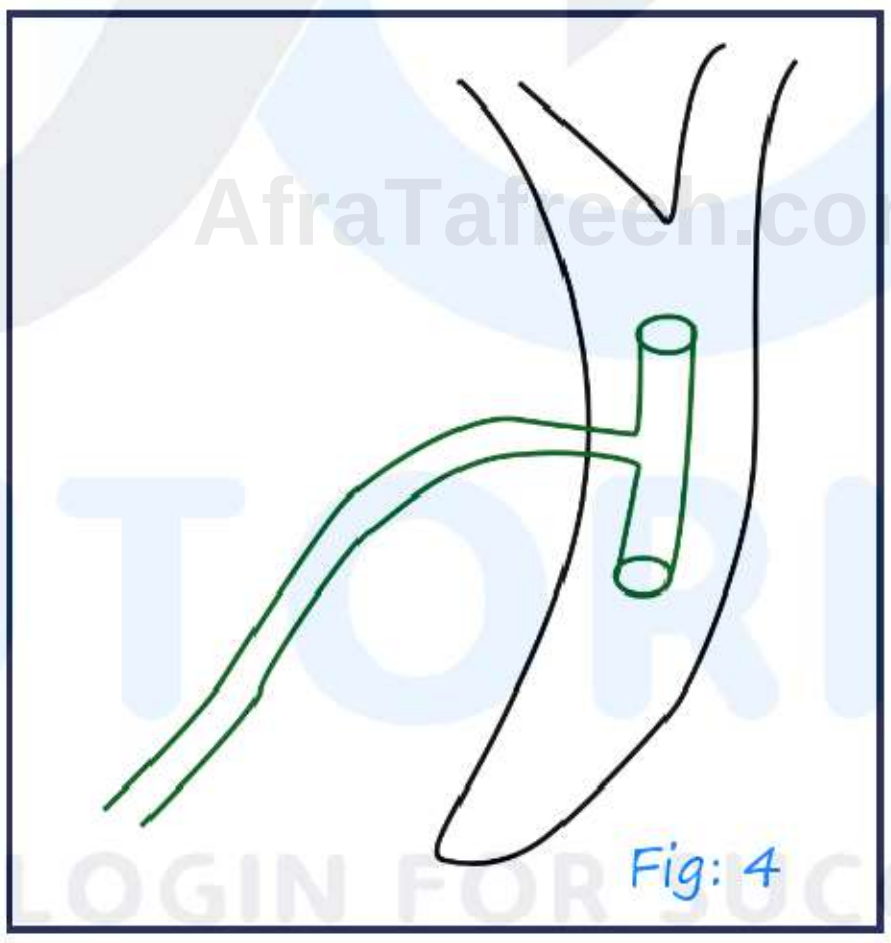

Fig: 4

1.Drain the bile

AfraTafreeh.com
DOC TUTORIALS LOGIN FOR SUCCESS

AfraTafreeh.com

2.To look for any missed stone

↓

'T' tube cholangiogram on 7th/ 8th POD

- Normal
  No leak
  No stone
  ↓
  Remove 10-14 days

- If stone ⊕

  Wash with MTBE (methyl terbutyl ether)
  Heparinized saline
  ↓
  > 6 weeks → remove T tube

  Cholangioscope removal of stone with 'T' tube tract → Burhenne technique

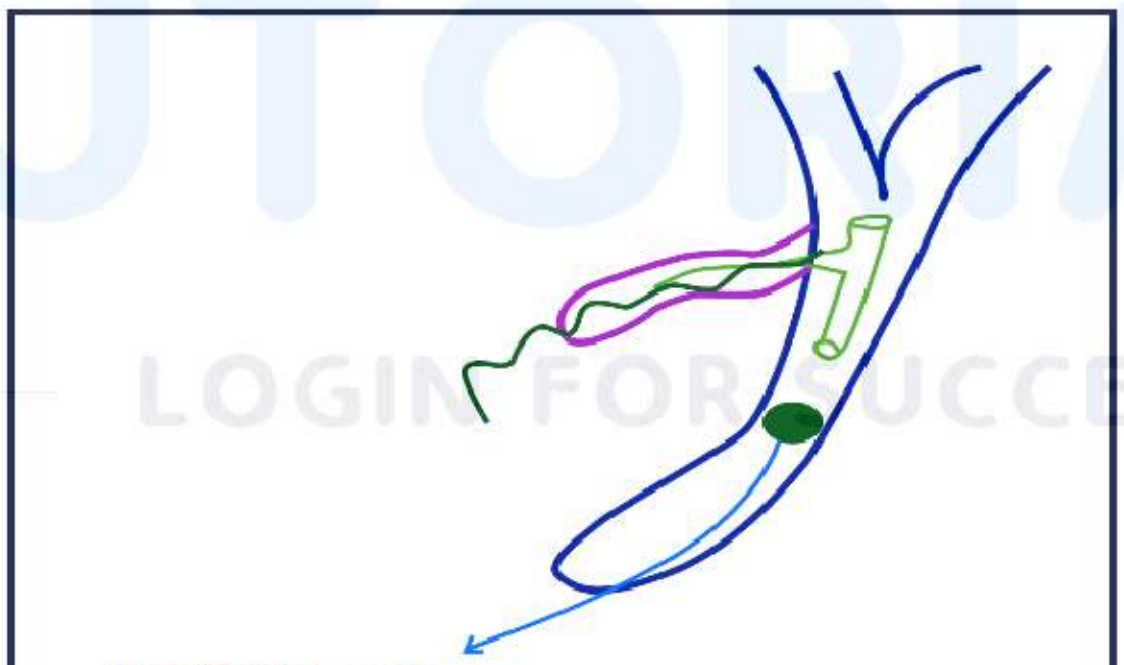

Fig: 5

- Missed/ retained stone – stone found after surgery < 2 years
  i. T tube → burhenne technique
  ii. T tube removed → ERCP/ sphincterotomy + stone removal (MGE)

- After 2 years

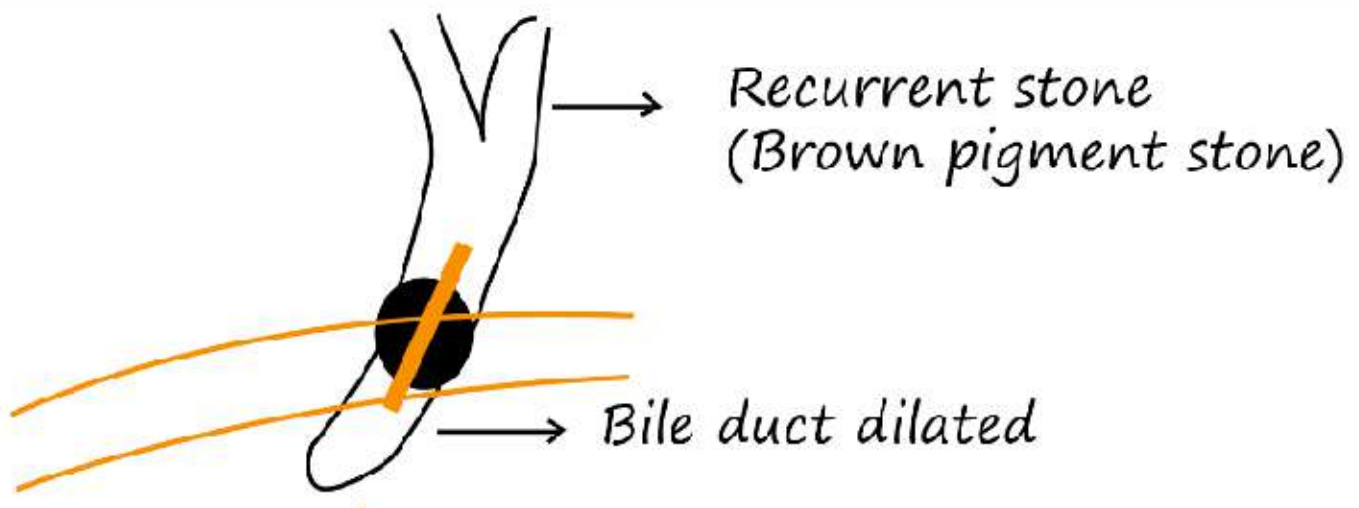

Fig: 3

AfraTafreeh.com
TUTORIALS
LOGIN FOR SUCCESS

AfraTafreeh.com

MISCELLANEOUS DISORDERS

Jaundice

- Choledochal cyst → Most common infants; Most common females
- EHBA → M=F; new-born
- Primary Sclerosing Cholangitis → Most common males 40-50 years

Choledochal cyst 00:01:45

- Abnormal dilatation of bile duct

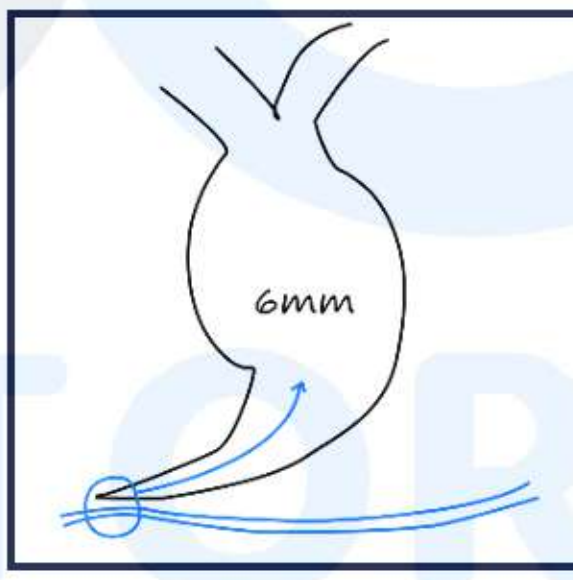

Fig: 1

- Congenital
- > 6mm
- Known etiology: - Anomalous pancreatic bile duct junction
- Clinical features-triad
  - Jaundice
  - Mass
  - Pain
- Types: - Alonso/ todani
  - I – Fusiform dilatation (most common type)

- II – Diverticulum
- III – Diverticulum near ampulla – choledochocele (L/C)
- IV a – All ducts dilated
- IV b – Extrahepatic duct dilated
- V – Caroli's disease (Intrahepatic duct dilated)



Fig: 2

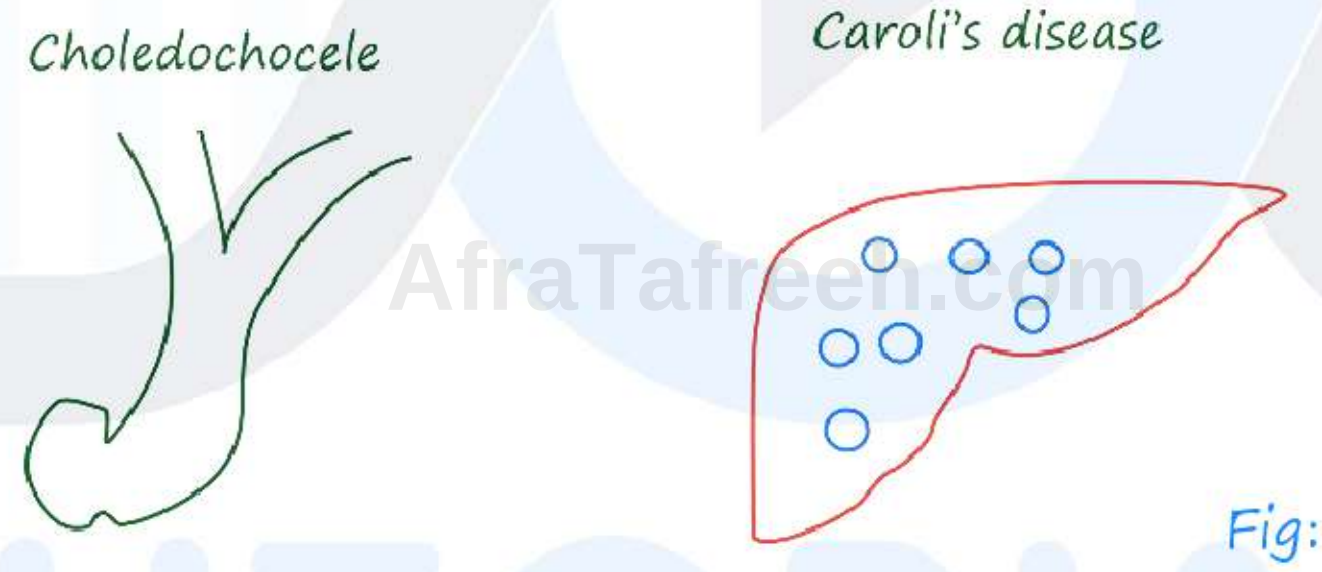

Fig: 3

AfraTafreen.com
TUTORIALS
LOGIN FOR SUCCESS

Complications

- Stones
- Cholangitis
- PV thrombosis
- Cirrhosis

Pre malignant

- Gall bladder
- Bile duct
- Intrahepatic

AfraTafreeh.com

- Pancreatic
- IOC: – MRCP

  – Type V: – CECT abdomen



Central dot sign

↓

Stands for portal vein radicle

Management

- Type I & II

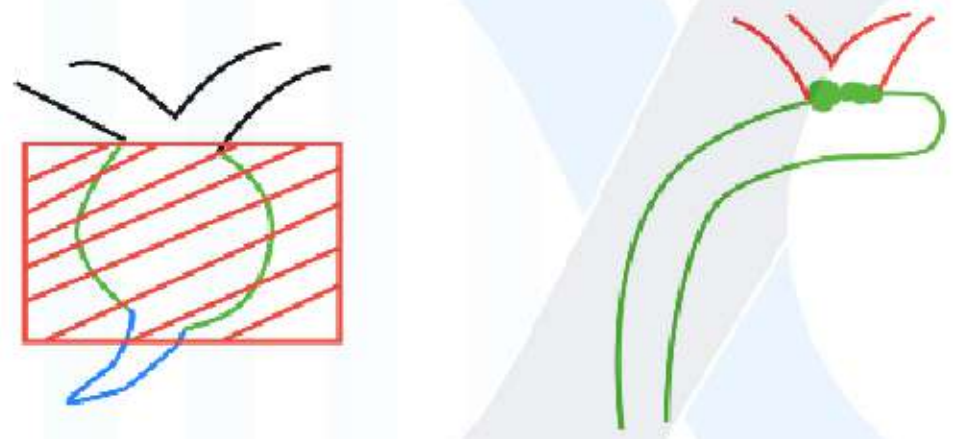

- Type III: – Choledochocele

  ↓

  Trans duodenal sphincteroplasty

- Type IV, V: – Liver transplant

DOC TUTORIALS
LOGIN FOR SUCCESS

EHBA 00:18:44

- Inside the liver bile duct is normal
- Outside the liver – becomes atresia

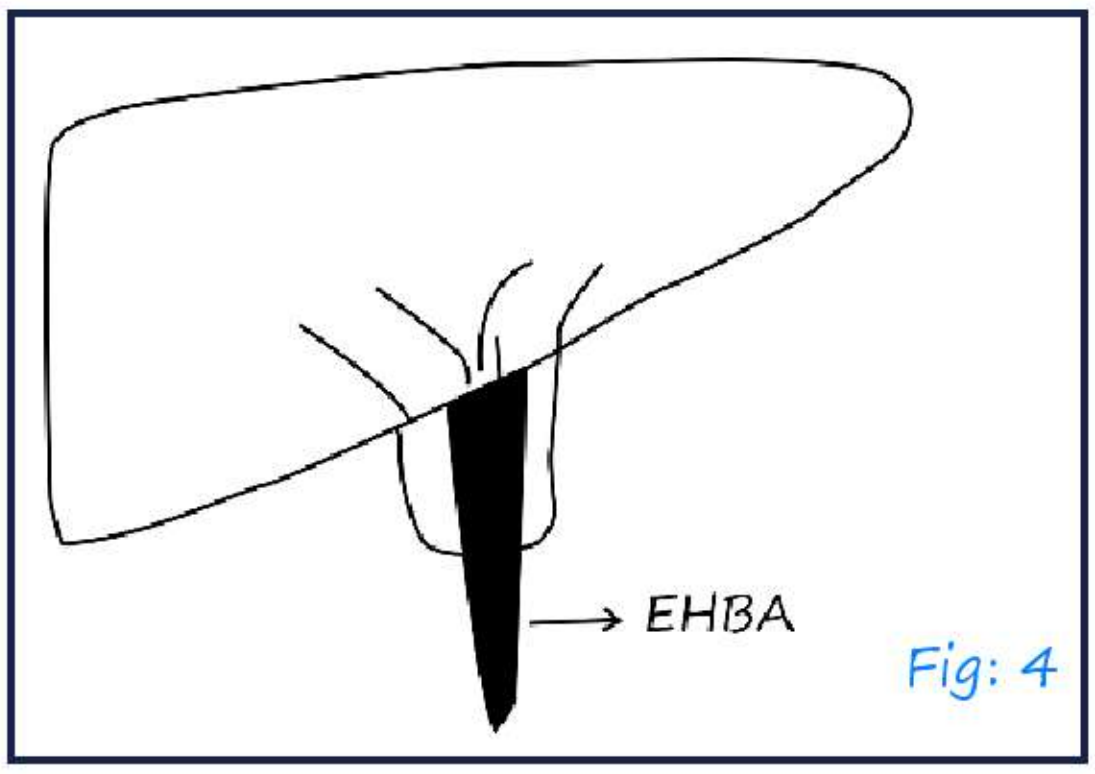

Fig: 4

Clinical features

- Jaundice
- Cholangitis
- Itching

Types

- I



  - Atresia seen distal to cystic duct at the level of common bite duct
  - Gall bladder is enlarged

- II

  - Atresia seen at common hepatic duct level
  - Gall bladder not palpable

- III



  - Atresia at porta hepatis level (90%) (most common)

AfraTafreeh.com

AfraTafreeh.com

Complications

- Cirrhosis – 2° biliary cirrhosis
- Cholangitis

IOC

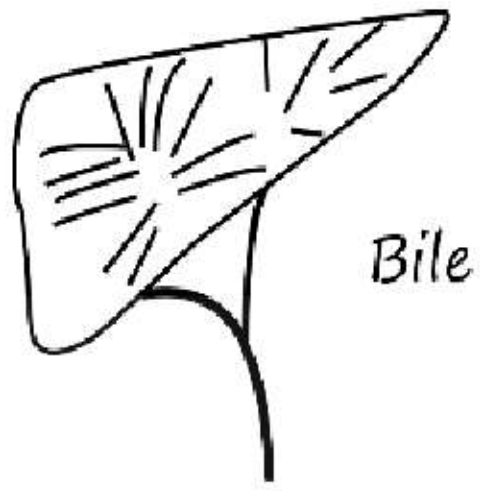

- Gold standard: –
  - Old: Pre-op cholangiogram
  - New: Liver biopsy
- USG abdomen: Triangular cord sign

Management

- Emergency treatment –

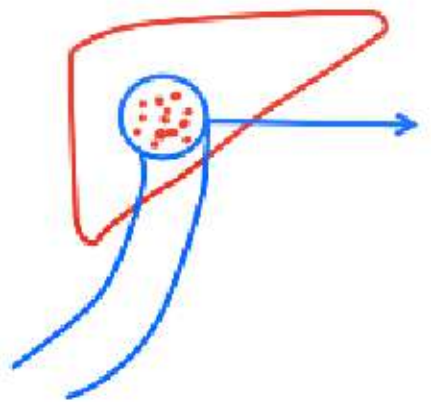

- Good prognostic factors
  - Age < 6 weeks
  - Size of ductules > 150 μs
  - No cirrhosis

- No cholangitis

↓

Bridging procedure

Liver transplant is definitive treatment

↓

Segment 2 and 3 given to newborn

- Q. most common indication of liver transplant in children is EHBA

Cholangitis 00:22:39

- Bile ducts are abnormally dilated and strictured

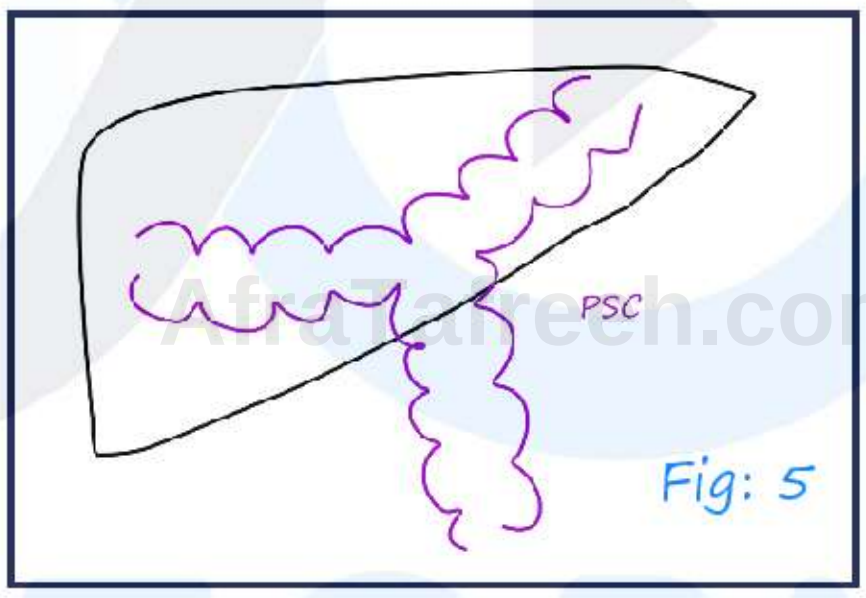

Fig: 5

Clinical features

- Jaundice
- Cholangitis

Types

- 1° sclerosing cholangitis → unknown etiology – associated with HLA + Reidel's thyroiditis dequervain's disease
- 2° sclerosing cholangitis –Most common – etiology : i. UC

AfraTafreeh.com

ii. CD

Complication

- 10% - cholangiocarcinoma every year

IOC for PSC

- ERCP – Prune tree appearance

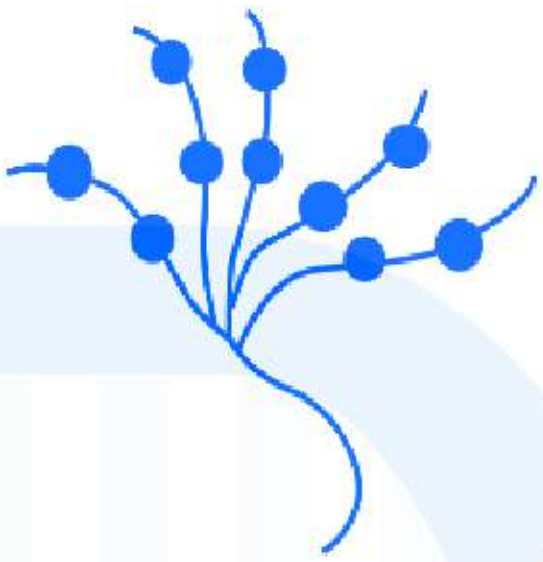

Management

- 10% develop cancer, so only treatment – Liver transplantation
- Management of all cases – last resort
  ↓
  Liver transplant

TUTORIALS
LOGIN FOR SUCCESS

BILIARY MALIGNANCY

Cancer Gallbladder and bite duct 00:00:28

- Cancer is more common in gallbladder and in fundus →
  Most common – mimics gall stone d/s when it infiltrates → presents as obstructive jaundice.

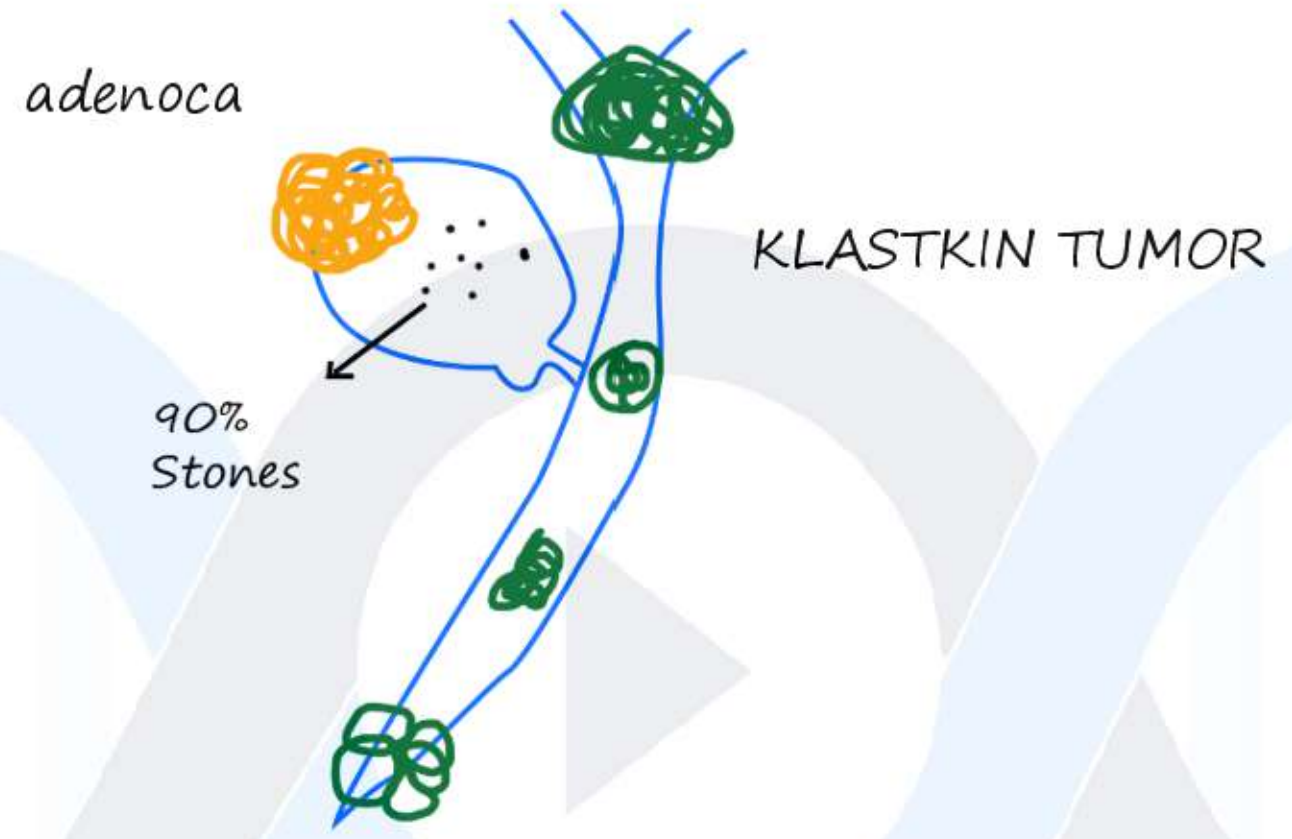

AfraTafreeh.com
TUTORIALS
LOGIN FOR SUCCESS

- Tumor in bile duct is common at bifurcation and known as klatskin tumor.

Courvoisier's law 00:02:42

- Obstructive jaundice – 1. Gall stones
  2. Cancer

AfraTafreeh.com

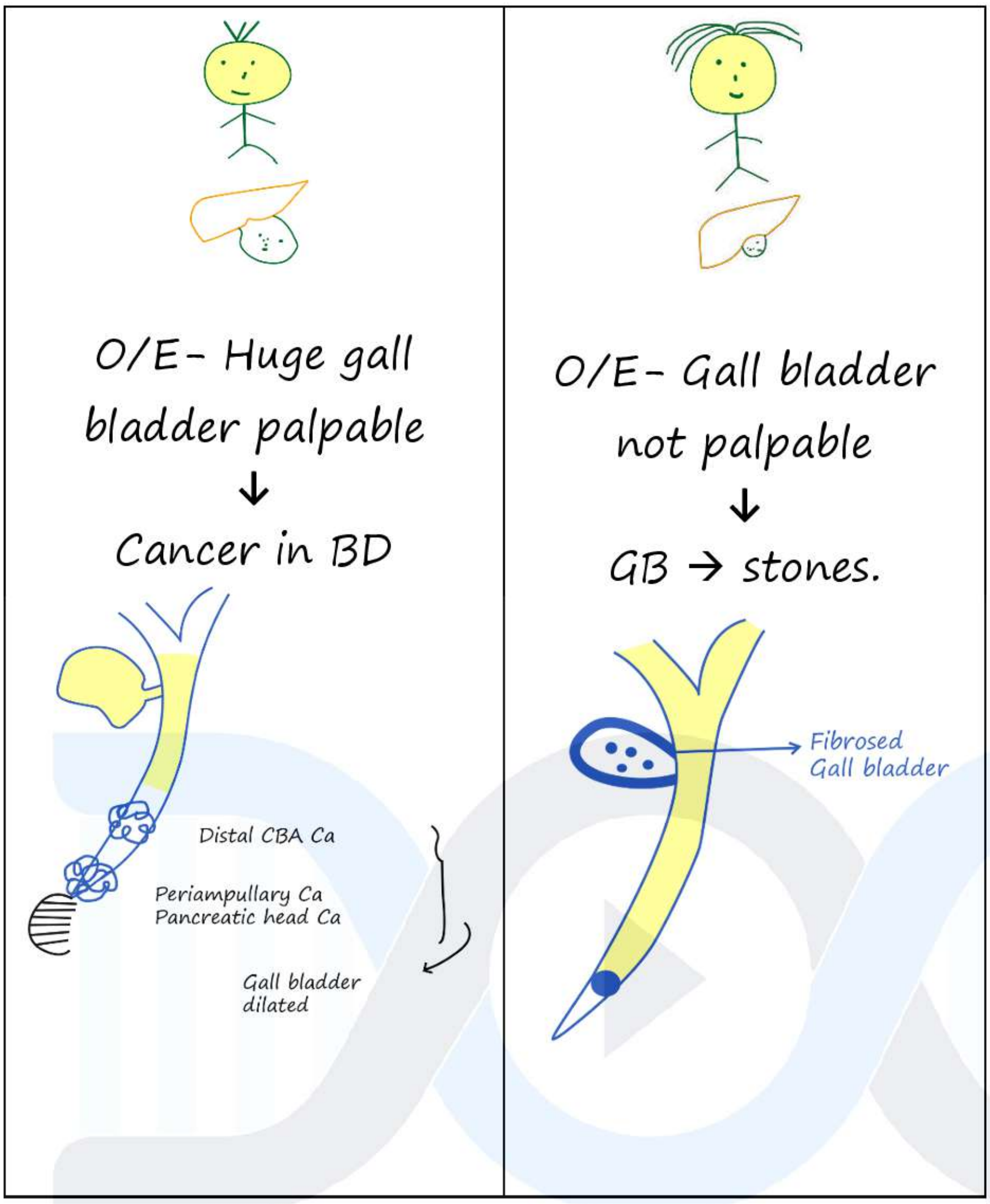

Exceptions: -

- Cancer ⊕ → no GB palpable klatskin tumor
- Stone, but GB palpable double impacted stone.

TUTORIALS
LOGIN FOR SUCCESS

Etiological factors 00:07:31

1.Most common: - Gall stones (0.5% GS → cancer)

(95% cancer → stones)

10% incidence of cancer: - stone size >2.5 cm

2.Polyp >10mm, porcelain GB

3.Typhoid carrier

4.Estrogen drugs

5.Choledochal cyst

6.Primary sclerosing cholangitis

7.Ulcerative colitis

8.Clonorchis sinensis

9.Carcinogens – Nitrosamines
Rubber
Dyes
Chemicals

Investigations 00:09:56

Investigation

GB cancer

- USG done: - Gall stones + polyp like lesion
- CECT: - triple phase abdomen
- Tumor marker: - CEA
- Diagnostic laparoscopy is advised resection
- PET-CT is advised before resection

Bile duct cancer

- Jaundice
  ↓
  MRCP + MR Angio
- Tumor marker: - CEA CA 19-9

AfraTafreeh.com
TUTORIALS
LOGIN FOR SUCCESS

Staging and management 00:12:26

- Tia: - lamina propria → simple cholecystectomy



AfraTafreeh.com

- Tib: - muscle layer → perineural invasion + Vascular invasion + Margins of CD + → Post op specimen → 2cm margin + nodal clearance → Extended cholecystectomy

  ↓

  Negative

  ↓

  Simple cholecystectomy

- T2: - peri muscular connective tissues serosa not infiltrated liver

  ↓

  4b and 5 lobes removed + nodal clearance

  ↓

  RADICAL CHOLECYSTECTOMY

- T3: - Serosa penetrated, liver involved (or) duodenum (or) colon

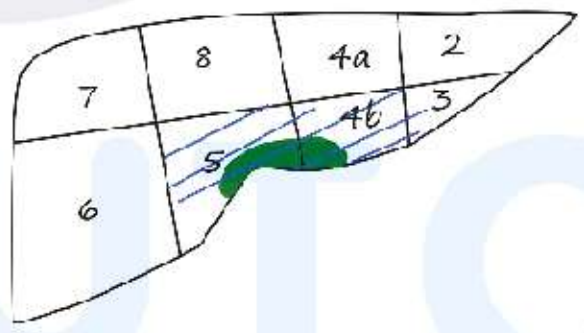

1. Radical cholecystectomy
2. Extended Ⓡ Hepatectomy – Ⓡ trisectionectomy (4a, 4b, 5,6,7,8).
3. Central (TAJ MAHAL) hepatectomy – 4b +5+8

- T4 >I organ infiltrated → inoperable
- N1: - 1-3 nodes + (Pericholedochal nodes)

  ↓

  Nodes along collecting duct CBD, Hepatic artery, portal vein)

- N2: - 4 or more ⊕ (Periaortic, pericaval, SMA and coeliac nodes).

- M1: – distant mets.

SCENARIO 1: – Post op specimen: – showing GB Cancer

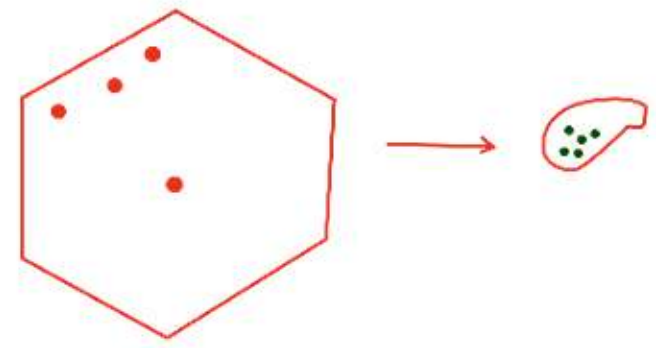 → HPE → cancer ⊕

Lap cholecystectomy done

→HPE → **Cancer** ⊕

Tia	Tib	T2
↓	↓	↓
No further treatment	Extended cholecystectomy (No need to resect port site)	Radical cholecystectomy

SCENARIO 2: – Cancer on laparoscopy

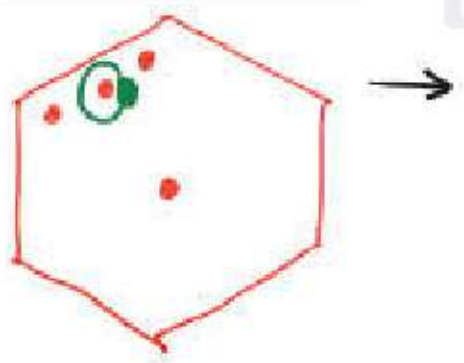 → Inexperienced surgeon

↓

Remove the ports and refer to hepatobiliary pancreatic surgeon.

TUTORIALS
LOGIN FOR SUCCESS

AfraTafreeh.com

- Experienced surgeon

  ↓

  Laparoscopy → OPEN

  ↓

  EC, RC, ERH — based on staging

  ADJUVANT THERAPY – Germcitabine

- In a gall bladder cancer, no need to resect bile duct unless it is directly infiltrating.

Cancer bile duct etiology 00:28:05

- Inflammatory
  - Primary sclerosing cholangitis
  - Ulcerative colitis
  - Hepatectomy c
  - OCH (clinical sinensis).
- Parasitic
  - Clinical sinensis
  - Opisthorchis viverrine
- Chemicals
  - Asbestos
  - Vinyl chloride
  - Thorium
- Congenital
  - Choledochal cyst
  - Caroli's disease
- Post op

TUTORIALS LOGIN FOR SUCCESS

- Bilio enteric anastomosis.

- Most common type – Adenocarcinoma
  - **Sclerosing** → Worst prognosis
  - **Papillary** → best prognosis
  - **Nodular**

Classification of hilar cholangiocarcinoma 00:31:00

Bismuth correlate classification

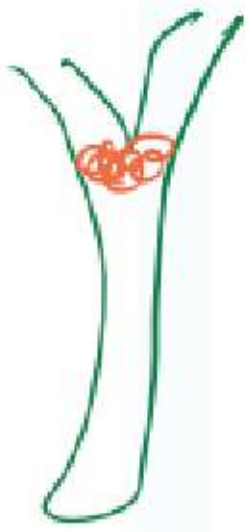

Type 1: – cancer seen at common hepatic duct only
↓
Margins-1cm resect and do Hepaticojejunostomy

AfraTafreen.com

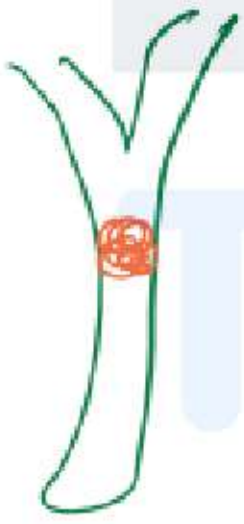

Type II: – cancer seen at congruence
↓
Margins-1cm resect and do Hepaticojejunostomy

DOC TUTORIALS LOGIN FOR SUCCESS



Type III a: – congruence + Ⓡ duct → extended Ⓡ Hepatectomy (5,6,7,8, +4a+4b)

Type III b: – congruence + Ⓛ duct
↓
Extended L Hepatectomy (2,3,4a,4b + 5,8)

AfraTafreeh.com

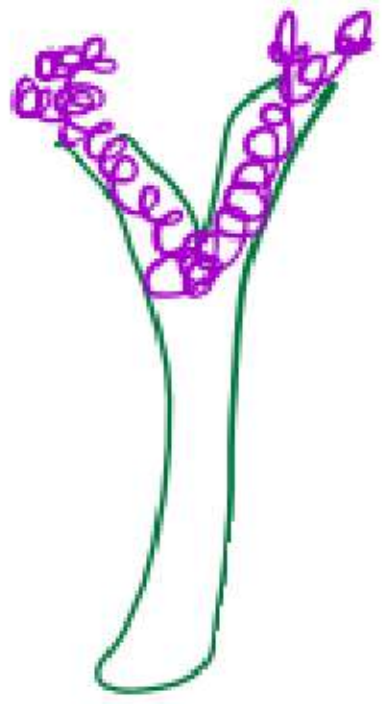

Type IV: - cancer involving both side secondary duct
↓
Inoperable cancer

- Mixed CBD – Resect and Hepaticojejunostomy
- Distal CBD – Whipple operation.

Criteria for unresectable Cancer 00:35:09

1. Biliary 2nd order hepatic ducts involved (Type IV)
2. Main portal vein involved.
3. Atrophy of one lobe due to Hepatic artery involved with clinical portal vein infiltrated.



Atrophy of one lobe

Clinical portal vein involvement

4. Atrophy of one lobe with clinical second order ducts involved.

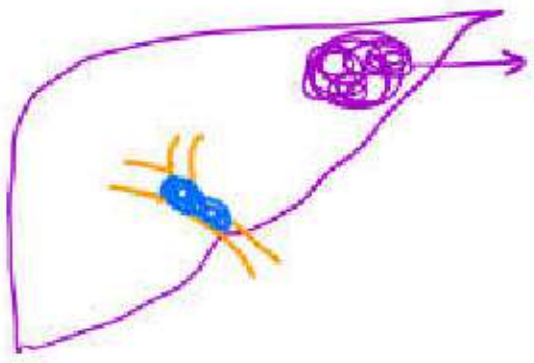

Atrophy of one lobe

5. Distant mets, ascites

For inoperable cancers – SEMS (Self expanding metallic stent).

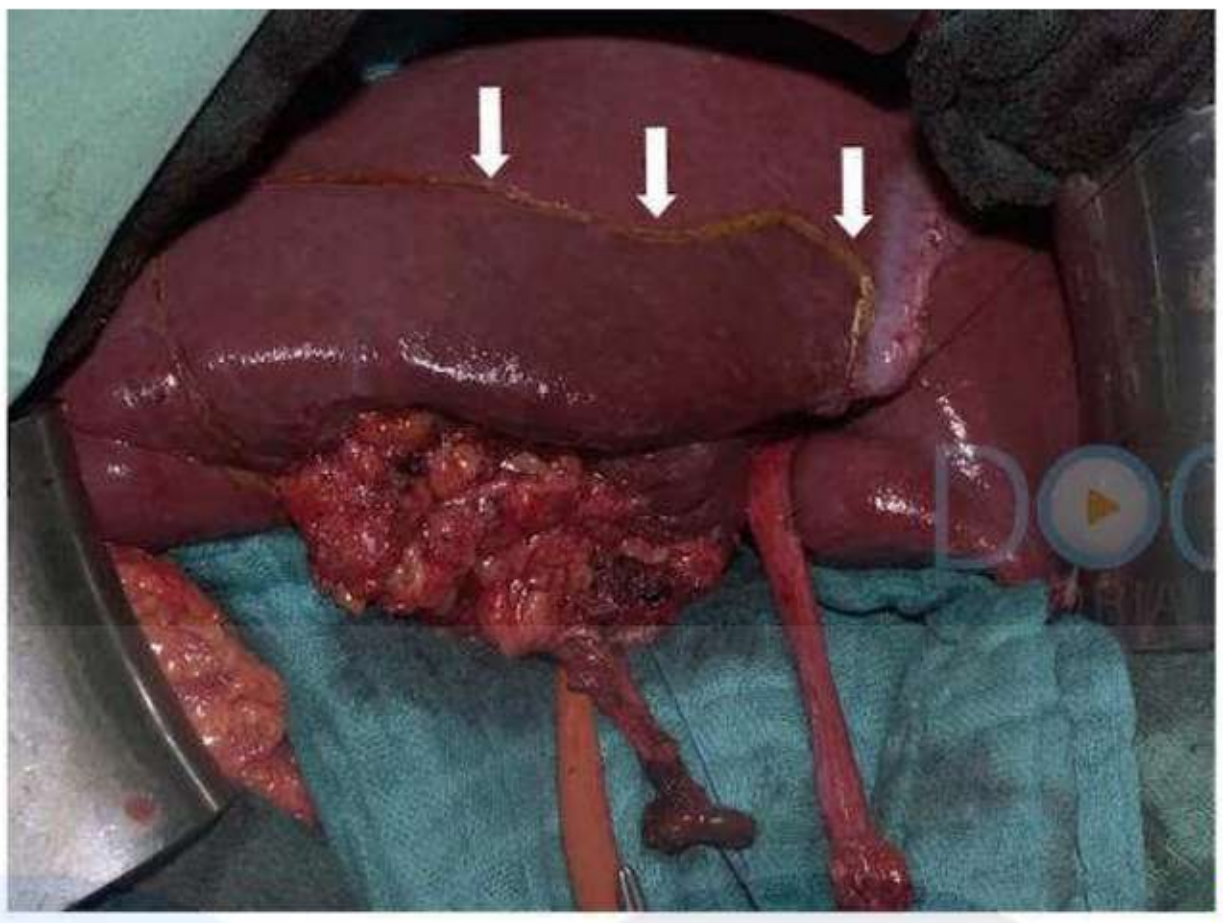

Fig: 1

AfraTafreeh.com
TUTORIALS
LOGIN FOR SUCCESS

AfraTafreeh.com

PANCREAS BASICS

Embryology 00:00:10

- Pancreas derived from 2 buds → Dorsal bud & Ventral bud.
- The ventral bud rotates and fuses with dorsal bud.
- This is done by sonic hedgehog (SHH) pathway
- If this pathway fails, there is failure of rotation of Dorsal bud

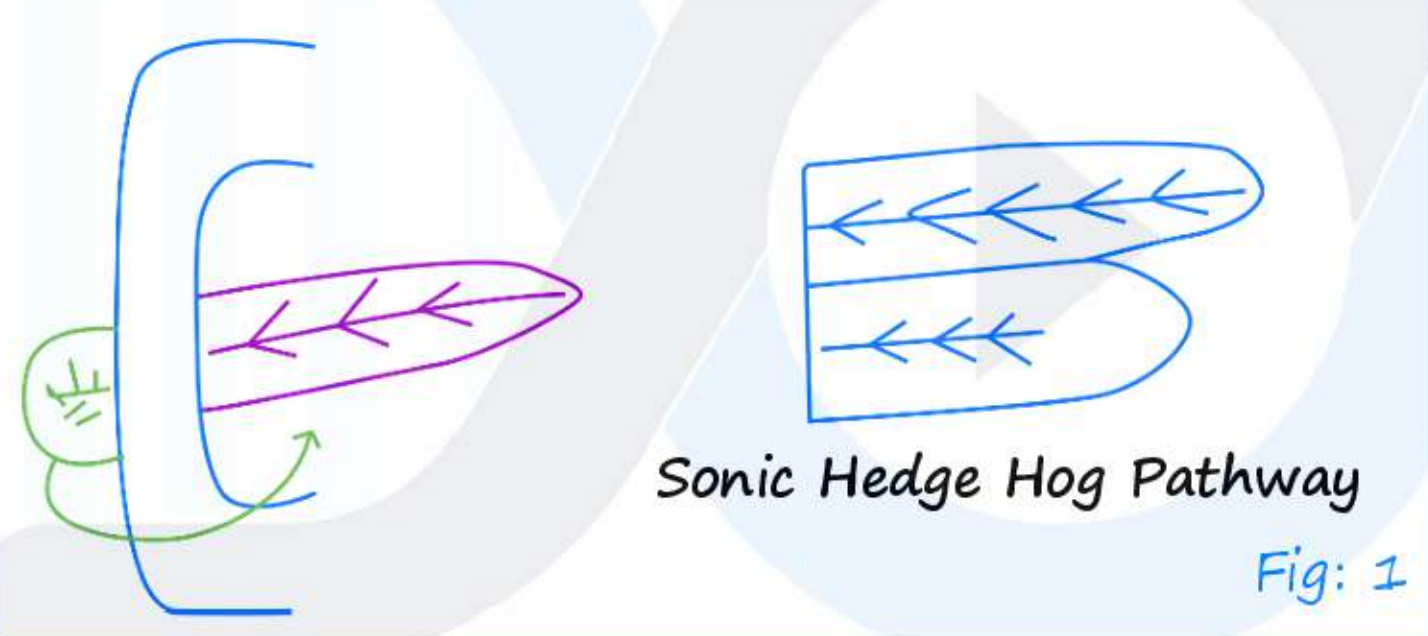

Fig: 1

- Then dorsal bud remain dorsally and ventral bud remain ventrally and the pancreatic tissue encircling the 2nd part of duodenum called as annular pancreas.

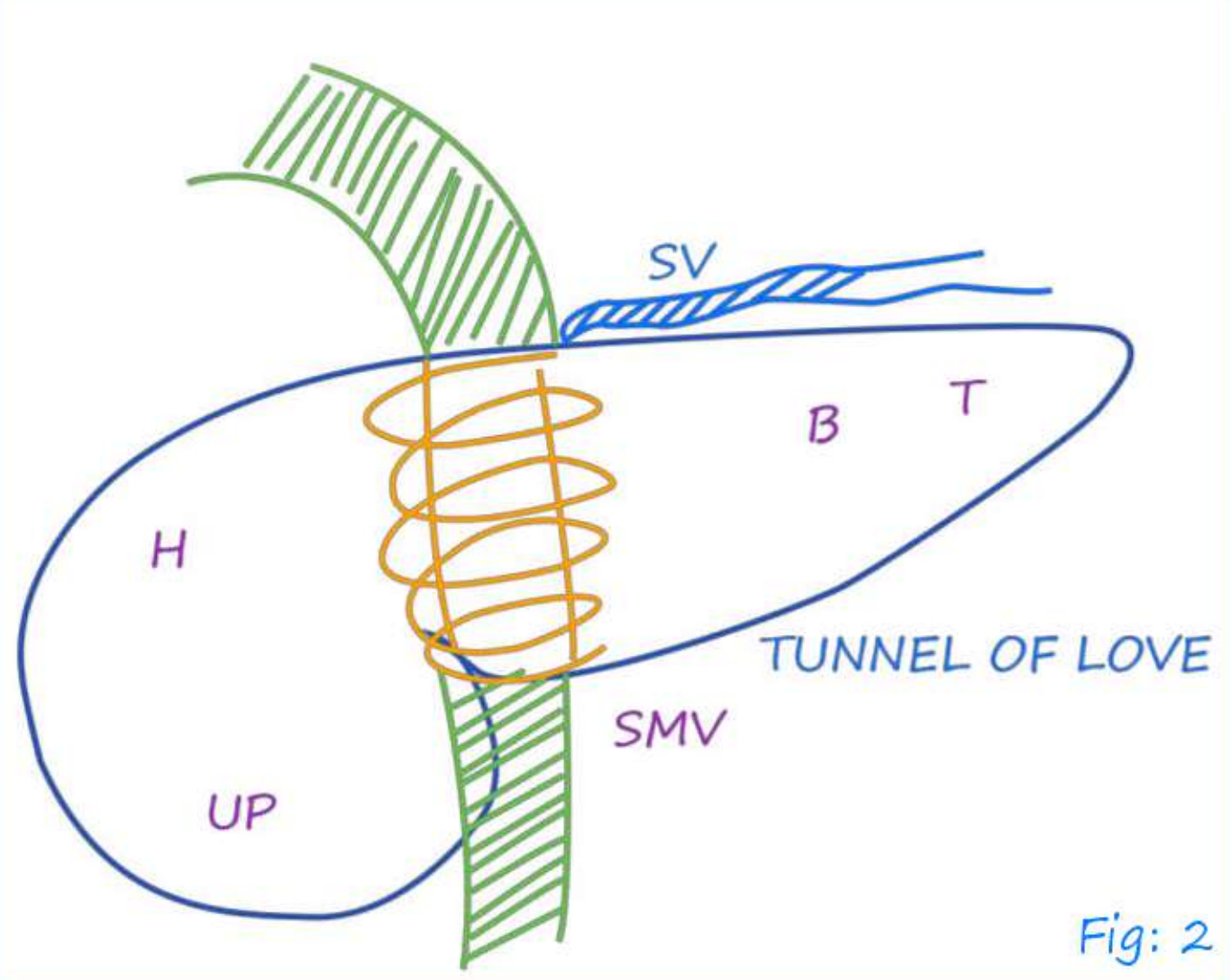

Fig: 2

- Pancreas have head, neck, body, tail, uncinate process.
- The superior mesenteric vein entering behind the neck of pancreas and it comes out as portal vein.
- There is a tunnel behind the neck of pancreas, known as tunnel of love
- This SMV joins with splenic vein to form portal vein at the level of tunnel of love.

Ducts of Pancreas 00:02:25

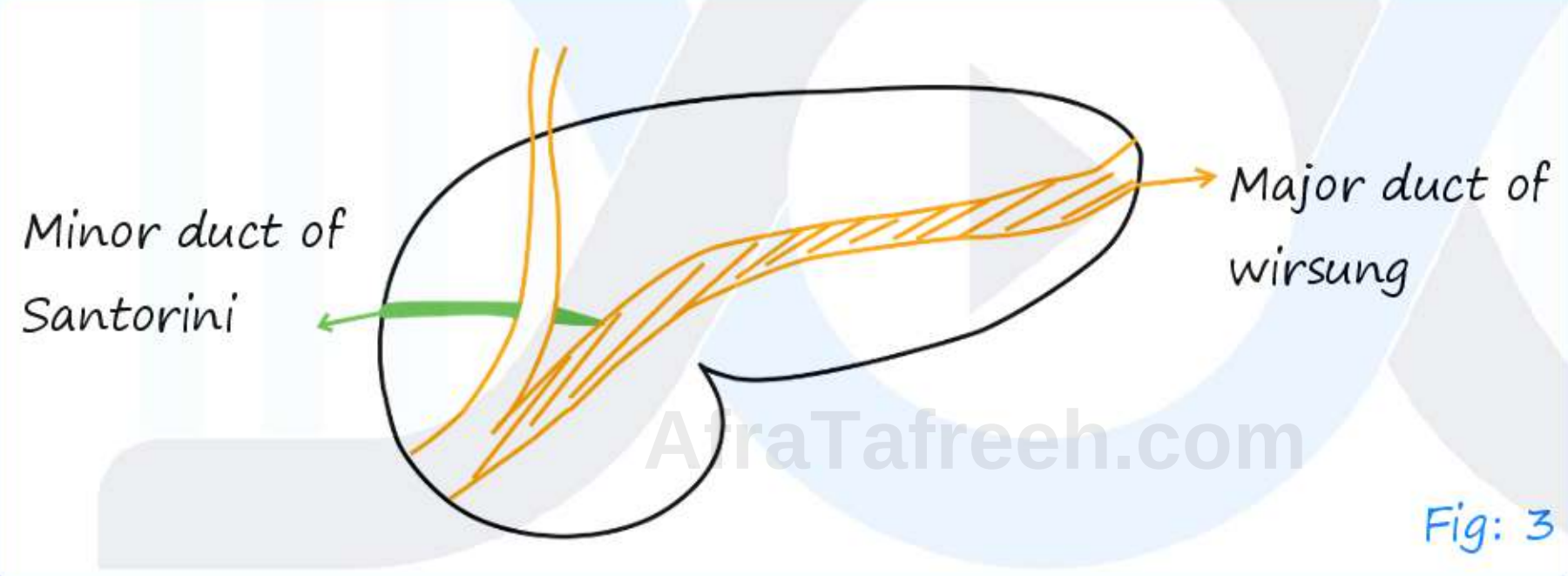

Fig: 3

- The common bile duct comes down & fuses with the major duct of wirsung and there is minor duct of Santorini.
- Minor duct of Santorini is formed by proximal part of dorsal bud.
- The ventral duct of wirsung is formed by distal part of dorsal bud + entire ventral bud.

AfraTafreeh.com

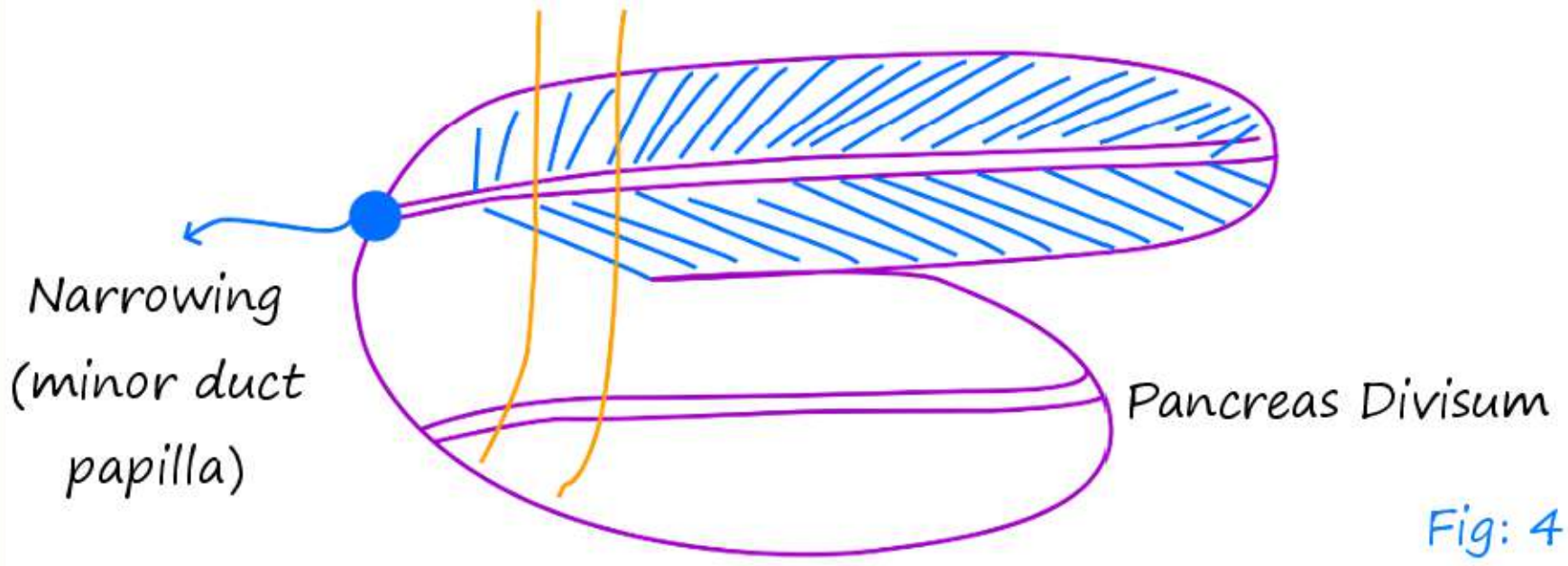

Fig: 4

- If these ducts are not fusing at all, they will remain as in diagram. The ventral duct is joining with CBD. This condition is called pancreas divisum. Here minor duct is draining major part of pancreas. So, the orifice may become narrow and cause minor duct papilla and patient present with feature of acute recurrent pancreatitis.

Annular Pancreas 00:06:34


Fig: 5

- It is most associated with downs syndrome
  - Duodenal atresia
- Mostly they are asymptomatic

- Most common clinical feature – Gastric outlet obstruction
- On x-ray we see double bubble appearance.
- On CECT abdomen – IOC for diagnosis
- Gold standard inv – ERCP, at the level of minor papilla, the absence of ventral bud.
- Treatment – Duodenodenostomy (or) Duodenojejunostomy (pediatric age group)

Pancreas Divisum 00:09:31

- Here the minor duct is draining major pancreas.
- Most common presentation → recurrent acute pancreatitis.
- IOC: ERCP/MRCP
- ERCP – best because we can do treatment – the minor duct papillotomy.

AfraTafreeh.com
TUTORIALS
LOGIN FOR SUCCESS

Ectopic Pancreas 00:10:37

- Most common location is duodenum > stomach
- Also present in Meckel's diverticulum
- 2nd most common mucosa in M.D – Ectopic pancreas (most common is gastric mucosa > pancreatic mucosa)
- Ectopic spleen is seen most common in
  1. Hilum of spleen
  2. Tail of pancreas

AfraTafreeh.com

ACUTE PANCREATITIS

Etiology factor for acute pancreatitis 00:00:13

- G – Gall stones (most common overall cause) (most common in females)
- E – Ethanol – most common in males
- T – Trauma – most common cause in children
- S – Scorpion sting
- M – Mumps
- A – Auto immune
- S – Steroids
- H – Hyper parathyroidism
  - Hypercalcemia
  - Hypertriglyceridemia
- E – ERCP
- D – Drugs
- Infection: - Coxsackie, mumps, CMV, echovirus
  Ascaris worms, Clonorchis sinensis

TUTORIALS LOGIN FOR SUCCESS

Drugs causing acute pancreatitis

- Thiazide diuretics
- Steroids
- Azathioprine
- Asparaginase
- Sodium valproate
- Oestrogen, OC pills

Clinical features

- Most common – epigastric pain radiating to back this sign is Mohammedan prayer sign
- It is a shooting type of severe pain
- Associated with vomiting, breathlessness
- On P/A examination – guarding is seen (should be differentiated with perforation) (Rule out)

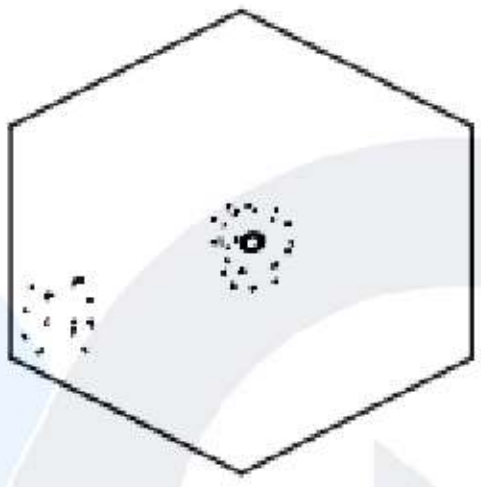

- Pigmentation around the umbilicus – Cullen's sign
- Pigmentation around the flanks → grey turner sign
- Pigmentation in inguinal region – Fox sign (Inguinal ecchymosis)

X-ray abdomen – Erect: Finding

1. Colon cut off sign → The continuation of colon gas is missing in the transverse colon level

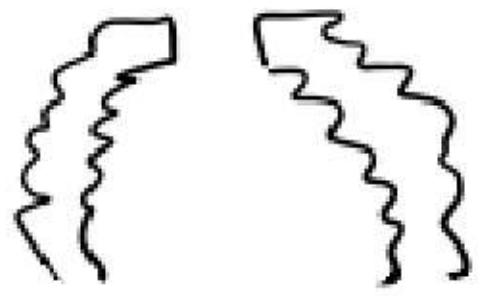

2. Sentinel loop sign – presence of a bowel loop seen prominently like this

TUTORIALS LOGIN FOR SUCCESS

AfraTafreeh.com

3.Gas less abdomen

4.Ground glass abdomen – no air in abdomen, b/o fluid ⊕

Blood investigation 00:08:19

- 1st and most common: - S amylase (normal < 30 IU/L), if it is > 4 times elevated then think of acute pancreatitis
- It is not specific. Since, it increases in perforation, obstruction, colon gangrene, parotitis also
- It is not sensitive. Since, it is elevated in 1st episode, after 3 days of attack. It usually becomes normal. (In 2nd & 3rd episodes, it may not increase)
- If patient comes after 3 days of attack, we should look for urinary amylase, for diagnosis of acute pancreatitis
- Most sensitive investigation for acute pancreatitis is S. lipase (It is not specific because it increases in parotitis also)
- Most specific is serum trypsinogen
- Here CRP>150 – severe acute pancreatitis
- Radiological investigation of choice – CECT abdomen advised after > 72 hours of attack
- At 72 hours, we had scoring systems called Balthazar score (old) – now it is renamed as CT severity index

score (CTSI). CTSI score is used to differentiate mild and severe pancreatitis

Severity of acute pancreatitis 00:12:37

- It decides where we can manage the patient, i.e., at small nursing home (or) admitted in SICU
- It is also required for further prognosis of patient
- There are many scorings' systems

1. BISAP score – Bedside index of severe acute pancreatitis
2. Ranson's
3. Apache II
4. Glasgow
5. CTSI – CT severity index score → Best score
   - Disadvantages: - can be done only after T_2 hours
6. Revised Atlanta → most common used presently
7. Modified Marshall score
8. SOFA score
9. CRP score 'C' reactive peptide

BISAP score

- B – Blood Urea Nitrogen (BUN)
- I – Impaired mental status
- S – SIRs
- A – Age > 60years
- P – Pleural effusion

AfraTafreeh.com

- Ranson's score: - is calculated at admission and at 48 hours

At admission (LAGAW)

- L – LDH > 350 IU/L
- A – AST > 250 IU/L
- G – Glucose > 200 mg/dL
- A – Age > 55 years
- W – WBC count > 16000/mL

  - Score ≥ 3 at admission is severe acute pancreatitis

At 48 hours

- B – Base deficit > 4 mmol/L
- U – Urea nitrogen > 5mg/dL
- C – Calcium < 2 nmol/L
- H – Haematocrit fails
  - Hemoconcentration > 60 mmHg
- O – Oxygen – PaO_2 < 60 mmHg
- W – Water (Fluid) – > 6 litres
  - Score ≥3 at 48 hours is severe acute pancreatitis
- Ranson's score – 2 types
  i. Alcoholic
  ii. Non-alcoholic (for gall stone)
- Many people deteriorated and died between admission & 48 hours, so this score is not followed how

- CTSI – CT severity index → most common used score usually done after 72 hours

CTSI

Pancreatic inflammation

- Normal = 0
- Enlarged pancreas = 1
- Focal E (or) diffuse E
- Intrinsic/ parenchymal changes are seen– 2
- Single fluid collection around pancreas – 3
- Multiple fluid collection around pancreas - 4

Necrosis

- No necrosis = 0
- 30% necrosis = 2
- 30-50% necrosis – 4
- > 50% necrosis – 6
- Total score – 10
- Severe SAP – 7-10 score
- SAP, here motility is 17-20%

AfraTafreen.com
TUTORIALS
LOGIN FOR SUCCESS

Revised Atlanta score

Organ failure ↓	Local complication	Systemic complication
Shock: - SBP < 90 mmHg ARDS: - PaO_2 < 60 mmHg ARF: - S. creatinine > 2 mg/dL GI bleeding: - > 500mg/day		

AfraTafreeh.com

Local complication

- Pseudocyst
- Necrosis
- Abscess

Systemic complication

- DIC
- Metabolic disturbance
- Decrease fibrinogen level

- RAC severity – Revised AHanta classification severity
- Mild AP → less mortality (<1%)
  - No organ failure
  - No local complications

  ↓

  Only increase S. amylase, lipase

  These patients can be managed in general ward also
- Moderate AP: - Organ failure develops
  - But resolves in 48 hours
  - It is called transient organ failure
- Severe AP: - Organ failure persists after 48 hours

  +

  Local complications

  ↓

  High morality (20-40%)

Complications 00:30:43

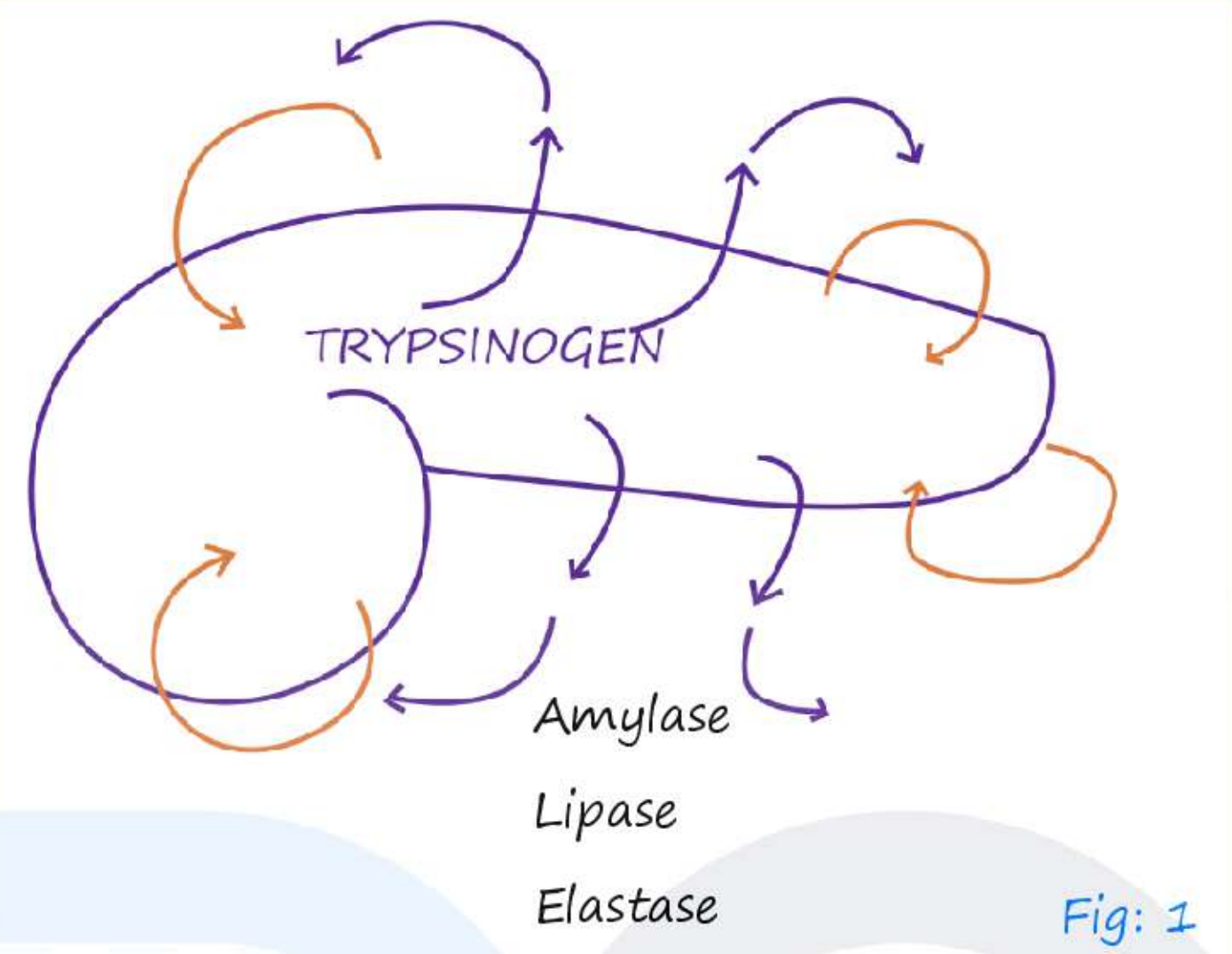

Fig: 1

- The pancreas gets insulted by gall stones (or) alcohol and immediately releases enzymes trypsinogen
- It goes and stimulates amylase, elastase, lipase and all enzymes
- These enzymes start digesting pancreas itself
- This is called auto digestion of pancreas
- Initial event is release of trypsinogen. Auto digestion causes local complications
- IL-2, IL-6, TNF-α are released into systemic circulation and causes systemic complications

AfraTafreeh.com
TUTORIALS
LOOK FOR SUCCESS

Local complications

- Within 4 weeks, there may be fluid collection in pancreas called acute pancreatic fluid collection

AfraTafreeh.com

- This will get loculated and becomes well defined collection. After 4 weeks it is called pseudocyst. Because the wall has no epithelial lining

- Within 4 weeks, the pancreas develops black necrosis – Acute necrotic collection. After 4 weeks, it is called – WOPN – Walled of Pancreas Necrosis
  - Most common complication causing mortality is pancreatic abscess (The collections get infected – abscess) → most common causes of late death
- Pancreatic ascites
- Pleural effusion
- Pancreatic pleural fistula
- Splenic vein thrombosis
- Splenic artery aneurysm – Tunica adventitia layer is digested by elastase enzyme causing false aneurysm
- Colon gangrene

TUTORIALS
LOGIN FOR SUCCESS

Systemic complications

- Shock: - SBP < 90
- ARDS: - PaO_2 < 60
- ARF: - S. creatinine > 2 mg/dL
- GI bleed > 500 ml/day
- Multiorgan failure/ disease

Pseudocyst 00:37:29

- It is a cyst not having epithelial lining
- It has granulation tissue forming as a wall
- It is most common in body and tail of pancreas (most common site)
- It is seen in lesser sac (space behind the stomach)
- Usually formed after 4 weeks of acute pancreatitis
- DI Egidio classification for pseudocyst – 3 types
  - Type I – Follows acute pancreatitis, ducts are normal
  - Type II – Follows acute on chronic pancreatitis, ducts are abnormal, but non strictures seen
  - Type III – Follows chronic pancreatitis (after many months)
  - It can have
    1. Stricture
    2. Stone in the duct
    3. Communication present with duct

AfraTafreeh.com
DOC TUTORIALS
LOGIN FOR SUCCESS

Clinical features

1. Persistent pain in epigastric region radiating to back
2. Epigastric fullness
3. Vomiting
4. Early satiety
   - Persistent elevation of S. amylase
   - IOC – CECT Abdomen

AfraTafreeh.com

- If we have a doubt that the cyst is a pseudocyst (or) a cystic neoplasm, send patient to EVS guided biopsy. It is the IOC to rule out cystic neoplasm

Complications

1. Most common complication → Infection
2. It can rupture and results in pancreatic ascites
3. Rupture into thorax and cause pancreatic pleural fistula
4. Bleeding due to erosion of splenic artery
   - This condition is Hemosuccus pancreatitis → Bleeding into the duct and blood coming out of ampulla

Management

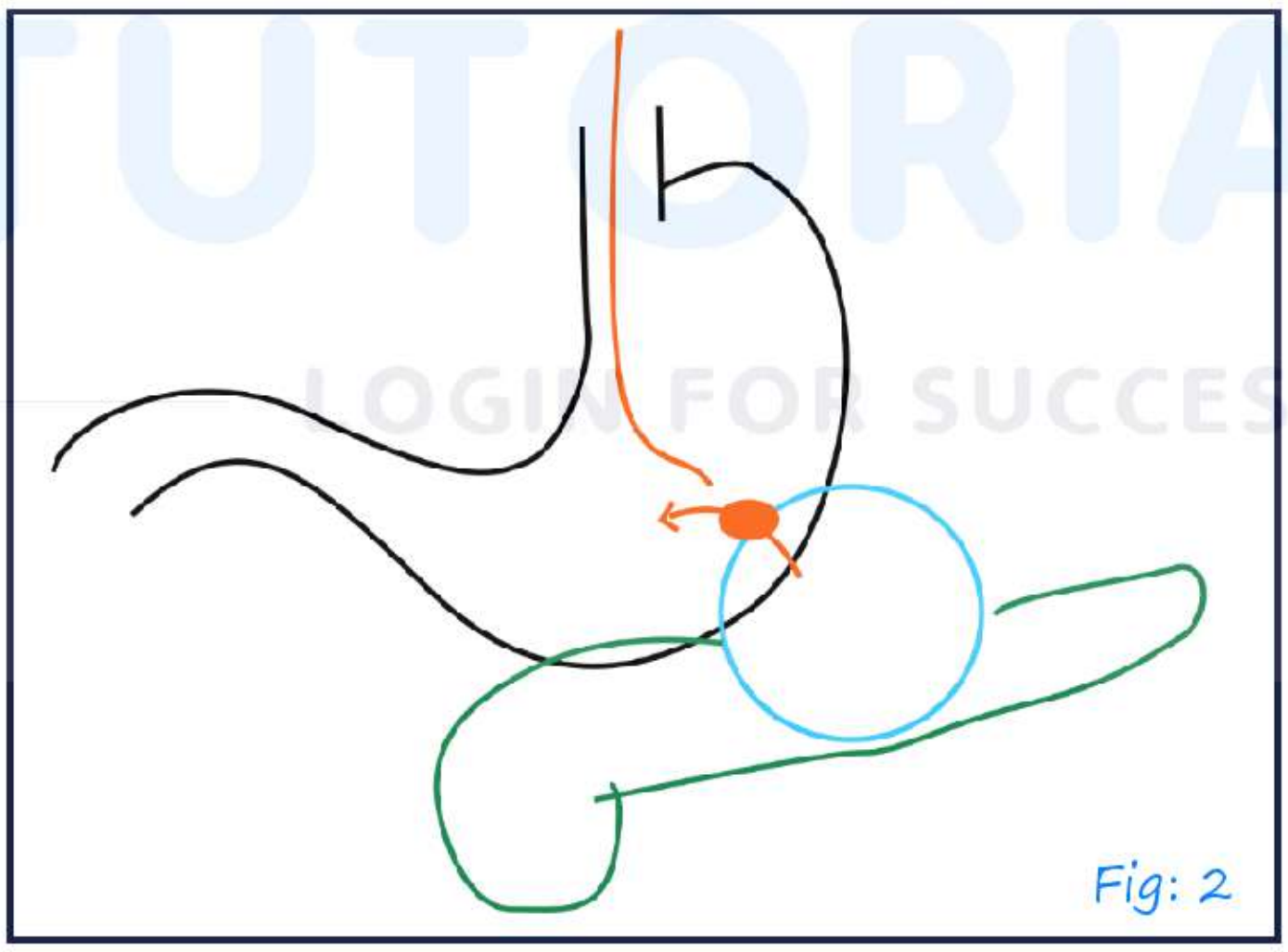

Fig: 2

1. By endoscopy, do a cystogastrostomy called endoscopic cystogastrostomy (internal drainage)
2. By laparoscopic or open method, do cystogastrostomy (Internal drainage)

3.Bring a loop of jejunum & anastomose it with pseudo cyst called cysto jejunostomy (Inter drainage)

- External drainage is done for abscess or infection of pseudocyst

Pancreatic ascites 00:47:00

- Examination of ascitic fluid shows

  1.Increased protein content

  2.Increased amylase

- It is called

  3.High protein ascites

  4.Low SAAG → Serum ascites albumin gradient < 1.1

- There is communication with pancreatic duct
- A gap is present in pancreatic duct through the gap, pancreatic fluid is leaking out

AfraTafreeh.com
TUTORIALS
LOGIN FOR SUCCESS

Treatment

- Paracentesis + infection octreotide
  - If it not resolved → ERCP & pancreatic stenting
  - If ERCP failed → Surgical drainage of duct open the duct and bring the jejunum and anastomose called pancreatico jejunostomy

AfraTafreeh.com

Pancreatic necrosis 00:50:31

- Loss of blood supply in parenchyma of pancreas
  - < 30% necrosis – 2 points
  - 30-50% - 4
  - > 50% - 6
- Usually, necrosis is sterile
- Infected necrosis has air surrounding the area + fever + tachycardia + increased WBC count
- IOC – to confirm – CT guided FNAC
- Treatment:
  - Start on empirical, high 3rd generation cephalosporin like tazobactam + piperacillin
  - Only in infected cases antibiotics are started

Necrosectomy 00:53:09

- Has to be done by
  a. Laparoscopic debridement
  b. Endoscopic debridement
    - VARD: - Video Assisted Retroperitoneal Debridement
- In acute pancreatic necrosis patients, there is a collection. So, we put a peritoneal collection drainage tube with help of radiologist
  - Through this tract, if we dilate tract and use a necroscope and we remove necrosis through it, is called VARD (Necrosectomy is done)

- It has 2 approaches

  a. Step up approaches – most often

  - If there is a collection, first manage conservatively with antibiotics and call radiologist to put a tube, to drain collection

  PCD – Percutaneous drainage

  ↓

  The we do VARD

  ↓ If not cured go for

  Open (or) laparoscopic drainage

  b. Step down approach

  - Directly we go for lap/ open method and remove all necrotic areas
  - Then put a PCD

AfraTafreeh.com

Fig: 3

AfraTafreeh.com

Management of acute pancreatitis 00:59:10

- Depends on whether AP is mild/ severe

Mild	Severe
• Managed in normal general ward • IVF, normal oral diet can be allowed • No antibiotics needed • Analgesics – give only opioids → Injury tramadol	• Managed in SICU • IVF • Antibiotics for infected necrosis • Pain – methimazole -Tramadol

Nutrition in AP

- If mild, no vomiting → can start oral feeds
  - If vomiting, not able to eat – advice nasogastric feeding
- If edema in pancreas present, patient has vomiting and unable to tolerate NG feed, then switch over to naso jejunal feeding
- In enteral nutrition (preferred in mild cases) mode of choice – NG tube feed, if not tolerated go for NJ tube feed
- In case of severe acute pancreatitis, enteral nutrition is contraindicated as patient is in shock. So, enteral feed can cause mesenteric ischemia/ compromise to blood flow to the intestine

- Here TPN is the choice
- Surgeons' role in acute pancreatitis – both mild and severe is minimal
- Medical gastroenterologist – does ERCP stenting + sphincterotomy + for patients developing acute cholangitis with pancreatitis seen in patient with CBD stone (Gall stone pancreatitis + cholangitis) done within 72 hours of onset of pain
- For severe acute pancreatitis patients – multiple surgeon's role, i.e., pseudocyst to be drained
  - Necrosectomy
  - External drainage for abscess
  - Endoscopic stenting for pancreatic ascites

AfraTafreeh.com
TUTORIALS
LOGIN FOR SUCCESS

AfraTafreeh.com

CHRONIC PANCREATITIS

Introduction 00:00:20

- Pancreas is totally burnt out, no enzymes produced.
- Presents with triad of symptoms
  1. Epigastric pain radiating to back (Moderate pain)
  2. Diabetes → > 90% function of pancreas is lost
  3. Steatorrhea → >90% function of exocrine is lost
- In chronic pancreatitis, there are strictures in the duct and stones, causing pain.

Etiological factors 00:03:06

(TIGARO CLASSIFICATION)

T– TOXIC (Alcohol) – most common

I – idiopathic (Tropical people – seen in Kerala

G – Genetic causes – PRSS gene mutation
SPINK-1 gene mutation
CFTRL gene mutation

A – Autoimmune

R – Recurrent acute pancreatitis like pancreas divisum

O – Obstructive due to stones and strictures

- Tests to look for endocrine insufficiency, by measuring RBS, C – peptide (endogenous insulin level)
- Exocrine insufficiency – frequent oily stools steatorrhea

Tests to look for

1. Pancreolauryl test
2. Lundh test
3. fecal fat excretion test → new → gives patient 100 grams of fat to eat, next day if >7grams of fat per day is seen in stool.
4. Fecal elastase test – normal > 200 if it is <100 → then severe exocrine deficiency.

Radiological investigation 00:07:29

- IOC: – CECT abdomen
  - Atrophic pancreas
  - Dilated ducts
  - Stones

  (Atrophic pancreas, dilated ducts, stones: Finding of advanced cases of C.P in CECT)

- Early cases of chronic pancreatitis can be diagnosed by
  - ERCP – Old gold standard
  - EUS – Latest gold standard

ERCP
↓
Cambridge criteria
↓
Chains of lakes appearance in ERCP

EUS
↓
ROSE MOUNT criteria

AfraTafreeh.com
TUTORIALS
LOGIN FOR SUCCESS

Management

- Pain → step up approach
  - T. paracetamol
  - NSAIDS

AfraTafreeh.com

- Opioids
- Coeliac plexus block – CT guided/lap guided (Thoracoscopic splanchinectomy)

It is a temporary relief for 6 months to one year.

- Diabetes → Injection Insulin
- Steatorrhea → Pancreatic enzyme supplements

  Pancrealipase

  Creon

These should be consumed along with meals always given with PPI.

Surgical drainage 00:13:42

Surgical drainage procedures – controls pain in a better way

-the pain is due to strictures and stones, so surgical drainage procedures done.

1. Pure drainage procedures
   a. Lateral pancreaticojejunostomy by modified Puestow procedure. It is done for ducts which are dilated >7mm (Open the duct, bring jejunum and anastomose



Fig: 1

b. If duct is <7mm (or) not dilated, we do a 'V' shaped cut and bring jejunum. (For undilated ducts)



Fig: 2

2. Most commonly done is HYBRID procedure i.e., Drainage + resection **Freys procedure**
Here the head is cored out, open the duct and bring jejunum and anastomose with it.

3. Resection procedures: -

- If patient has pancreas problem, proximal duct is normal and distal duct is having stricture and stones. They do a splenectomy with distal pancreatectomy.

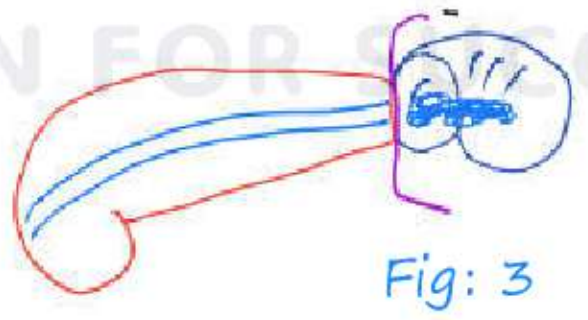
Fig: 3

Distal pancreatectomy + splenectomy → Child – Duval procedure

- If problem in head of pancreas (Stones and strictures) we have to preserve duodenum and remove the head of pancreas and bring jejunum and anastomose.

AfraTafreeh.com

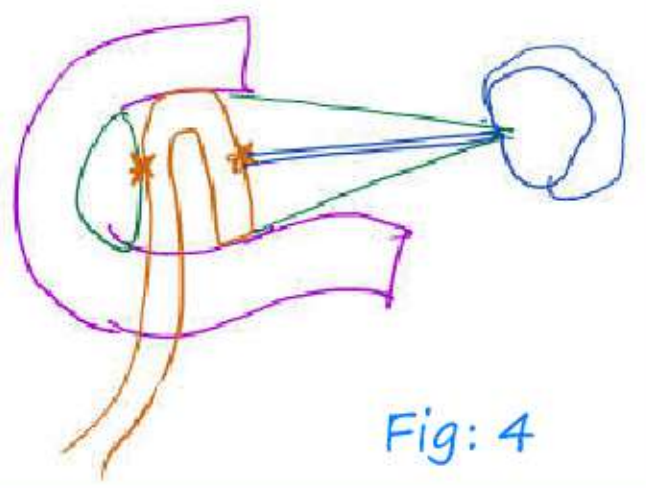

Fig: 4

- Duodenum preserving pancreatic head resection procedure known as DPPHR – BEGER's Procedure.
- Bern's modification of beger's procedure also done.
- For suspected malignancy of head of pancreas, go for Whipple's procedure (pancreaticoduodenectomy)

Procedures done for chronic pancreas are -

1. modified Puestow >7mm
2. izbicki <7mm

↓

These two are drainage

Freys

↓

hybrid

1. Child duval
2. Begar's
   ↓
   Duodenum Preserving
3. Bern's
4. Whipples

↓

Resection procedures for chronic pancreatitis

LOGIN FOR SUCCESS

PANCREATIC TUMORS

Pancreatic tumors

- Exocrine neoplasms → Ductal adeno cancers
- Endocrine neoplasms → Insulinoma, Glucagonoma
- Cystic neoplasms
  - SCN
  - MCN
  - IPMN

AfraTafreeh.com

Pancreatic adenocarcinoma 00:01:48

- Most common site of cancer pancreas – head of pancreas

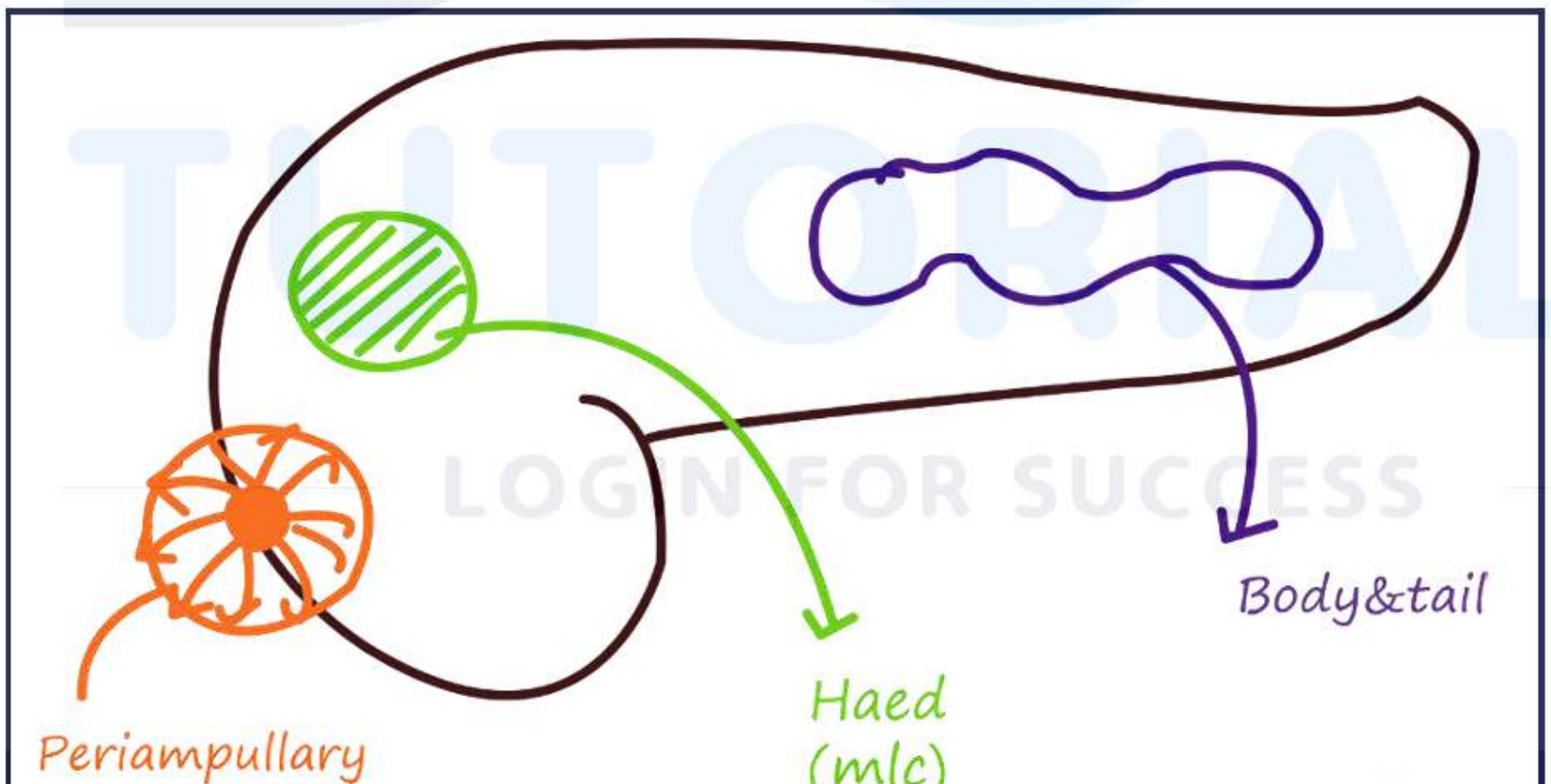

Fig: 1

- Any tumor with in 2cm diameter to ampulla of vater is known as periampullary cancer – 2nd most common site
- 3rd most common site – somewhere in body and tail of pancreas

AfraTafreeh.com

- Most common presentation of head of pancreas cancer is pain
  - Epigastric pain radiating to back + Jaundice is seen + weight loss + late presentation
  - Here only 10% patients are operable, when they come to hospital (90% inoperable) bad prognosis
- Presentation of periampullary cancer is painless, Intermittent jaundice
- In periampullary cancer growth, after some time the blood supply to ampullary tumor decreases, it will slough out and fall down. As it falls down the bile duct which is obstructed, will have sudden flow, then tumor happens again and again like intermittent painless jaundice
- So "early presentation" with jaundice is seen in these patients
- So, around 60% cases are operable and curable, so good prognosis
- Most common presentation of body and tail pancreas is with metastasis. So, worst prognosis (100% have mets when they reach hospital. So, inoperable, so worst prognosis)

Predisposing factors

- Most common mutation seen → K-ras (>95% cases)
  - P16 – 2nd most common
  - p53

- PRSS gene mutation – trypsinogen gene
- SPINK-1 gene
- CFTR gene
- Peutz jeugher's syndrome → STK-11 mutation- 100 fold risk of cancer pancreas
- FAP
- BRCA-2
- Lynch-2 (HNPCC mutation)
- Familial atypical melanoma syndrome

- O/E: **Courvoisier's law**
  - These patients are having obstruction of bile duct, either in the periampullary region (or) head of pancreas – obstruction of bile duct
  - So, there is enlarged gall bladder presentation
  - If tumor is very big, it can occlude duodenum and can cause gastric outlet obstruction
  - Vomiting in pancreas cancer is due to duodenal compression

TUTORIALS
LOGIN FOR SUCCESS

Investigations in patient with pancreatic cancer

- IOC to diagnose any tumor → CECT abdomen with pancreatic protocol cuts (PPC – we have to make 2-3 mm cuts at pancreas, other site 5mm cuts are made), so we will not miss any small lesion
- IOC for TNM staging also CECT by PPC
- Tumor marker is CA 19-9 is elevated in pancreatic cancers

AfraTafreeh.com

TNM staging

- T_1: <2cm
- T_2: 2 -4cm
- T_3: >4cm
- T_4: Infiltration of adjacent structure – SMA, CHA, Coeliac artery

(Infiltration of SMV, PV done don't after staging)

↓

National Comprehensive Cancer Network (NCCN)

- Divides tumors into
  i. Resectable: The tumor is not infiltrating into veins (or) if infiltrates <180° of SMV/ PV axis

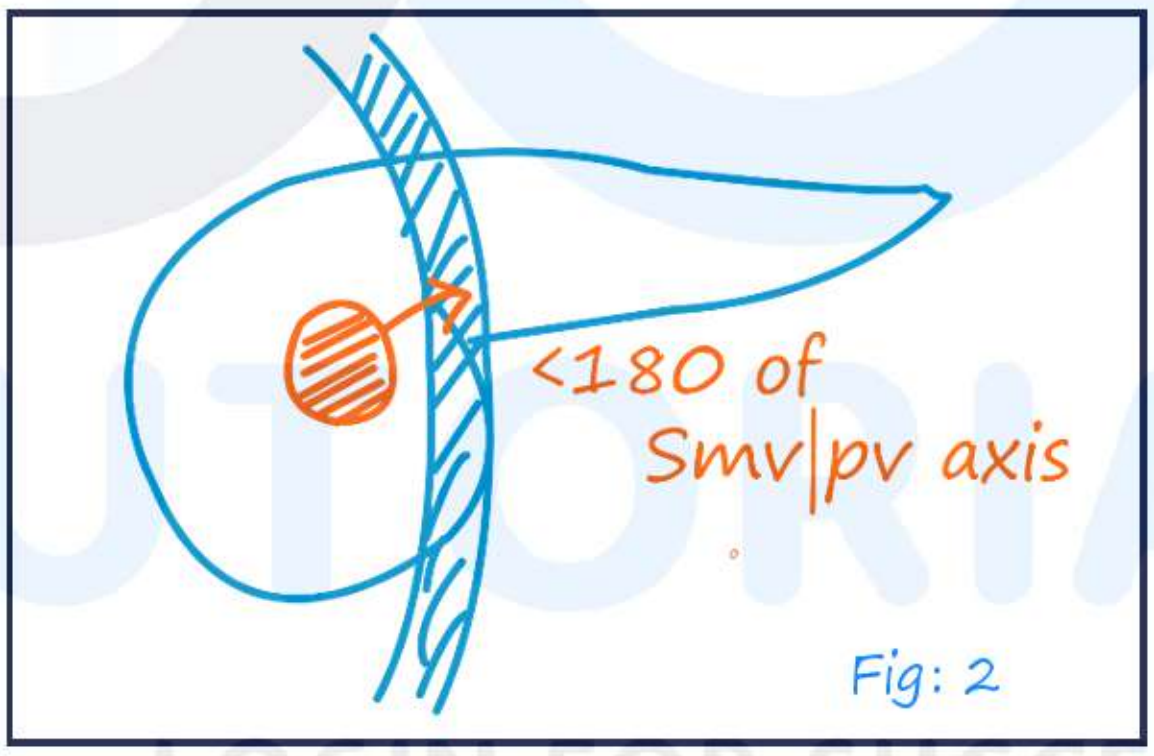

Fig: 2

  ii. Borderline resectable:
    - If tumor is infiltrating >180° of SMV/ PV we need to reconstruct/ cut the involved veins and can do either 1° reconstruction if distance is very small
    - If the distance is large, we have to go for prosthetic reconstruction

- If tumor is infiltrating <180° of SMA/ celiac artery/ common hepatic artery is also called borderline resectable tumor

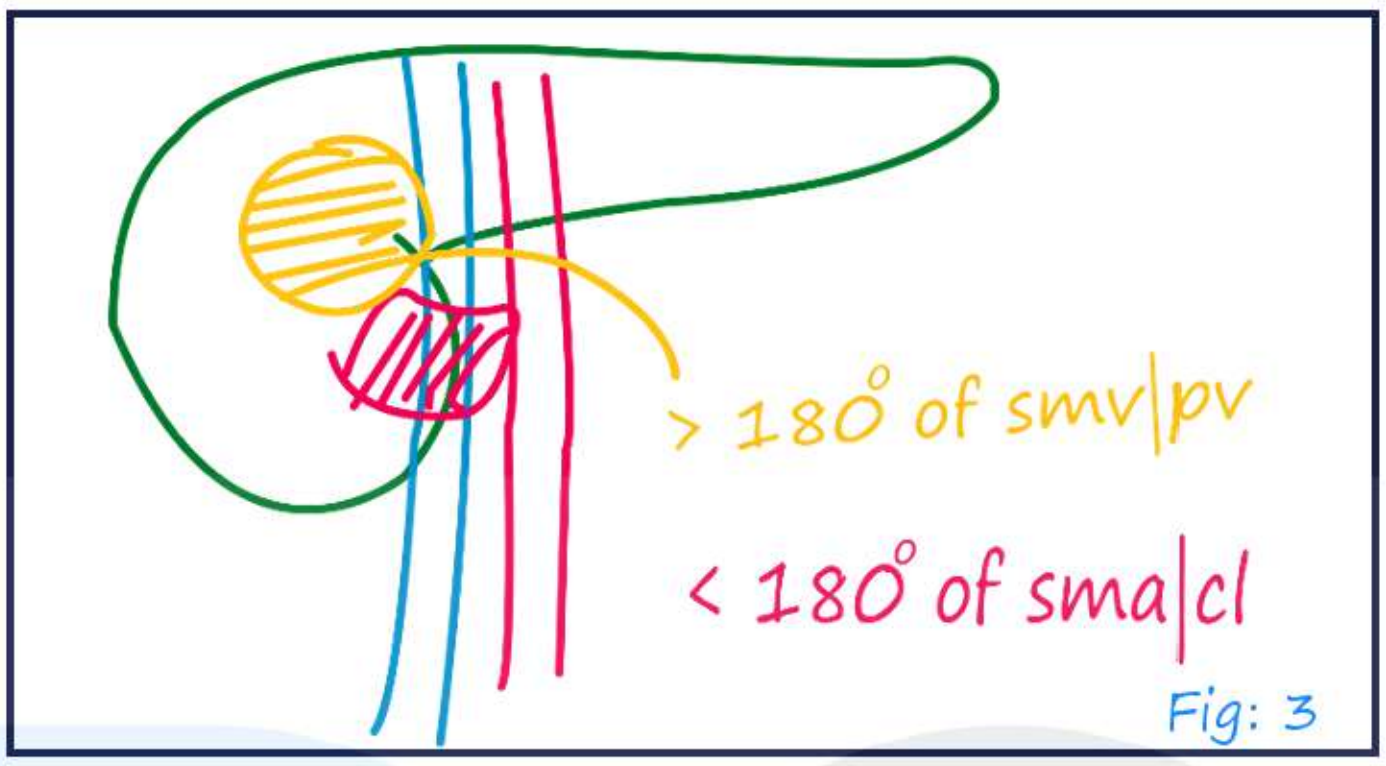

Fig: 3

iii. Unresectable

- Condition where arteries are involved like SMA/ CA/ CHA >180° (or) when metastasis is seen
- All these are derived from CECT, pancreatic protocol CT (2-3mm cut)
- Involvement of 1st jejunal artery is also >180°, so unresectable

Rarely done investigations

- ERCP and biopsy
- Double duct sign seen in ERCP and MRCP
  - Here the pancreatic duct and bile duct are dilated & separated from each other because of tumor of that place


Fig: 4

AfraTafreeh.com

- Barium meal – Epsilon/ Frostberg / reverse '3' sign is seen

Fig: 5

Management of pancreatic cancer

i. Head of pancreas
ii. Periampullary
iii. Duodenal
iv. Distal CBD

(i–iii) → We do whipple's procedure

a. Body and
b. Tail of pancreas

→ Distal pancreatectomy + Splenectomy

Inoperable cancers → palliative treatment

- Palliative treatment for
  - GOO → Bilio digestive bypass(triple bypass) → (or) duodenal stenting
  - Jaundice —(Only jaundice)→ SEMS into the CBD (self-expanding metallic stent)
  - Pain → coeliac plexus block with CT guidance (by absolute alcohol)

- For inoperable cancers, pancreatic cancer with huge obstruction
  - We do triple bypass

1. That is bring the jejunum and anastomose with stomach – gastrojejunostomy → for the food to go

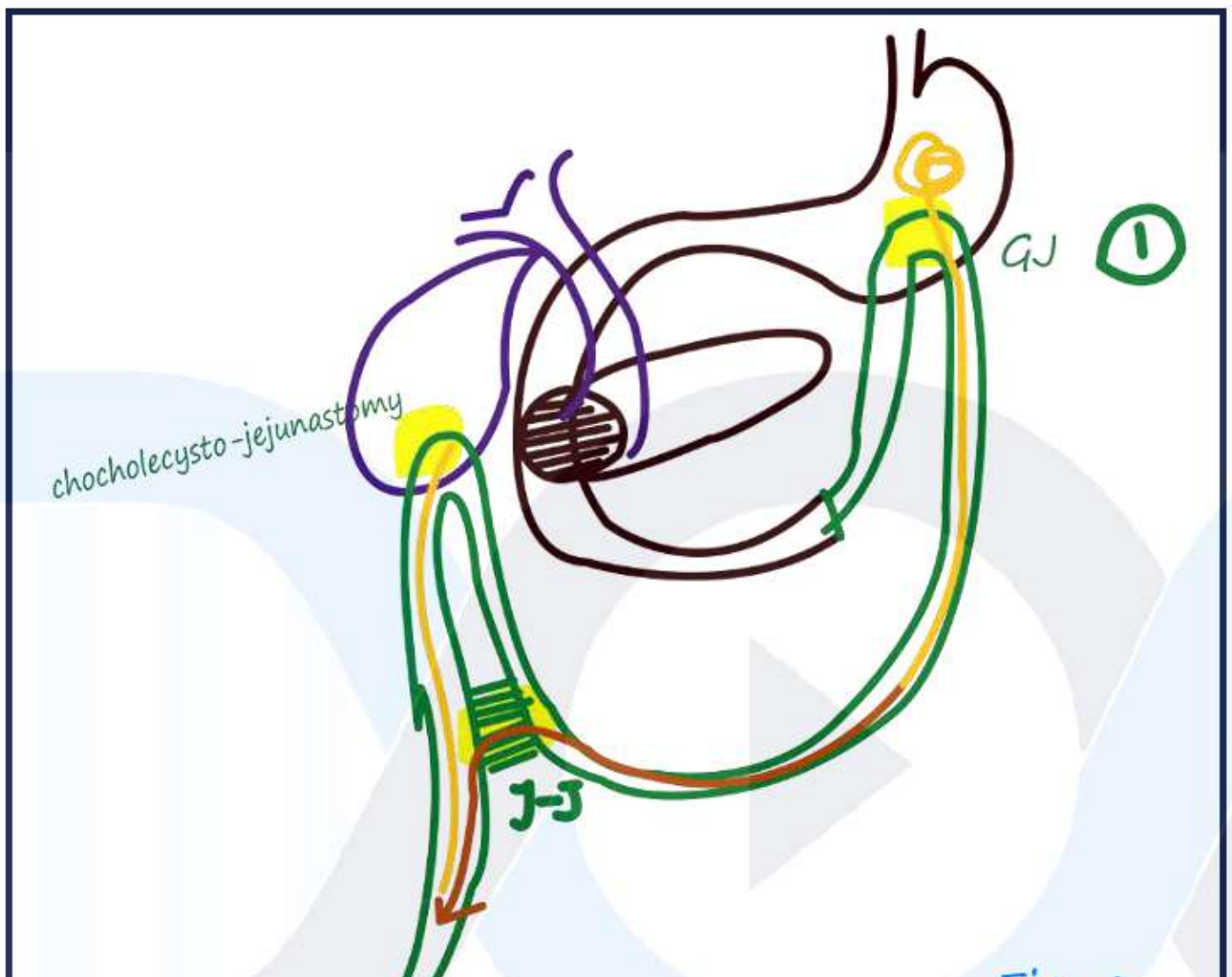

Fig: 6

AfraTafreeh.com

2. Here obstructed bile duct with a distended gall bladder is present. For this bring the jejunum and anastomose with gall bladder called cholecysto-jejunastomy → for biliary bypass to drain bile into jejunum
3. Jejunostomy – so that food wont go to gall bladder level, it passes into jejunum
   - It is a palliative treatment for inoperable patients called biliodigestive bypass

AfraTafreeh.com

Whipple's operation 00:25:36

- Pancreatico-duodenectomy
  - Both pancreas and duodenum have the same blood flow, so to remove lymphatic spread, we have to remove both structures together

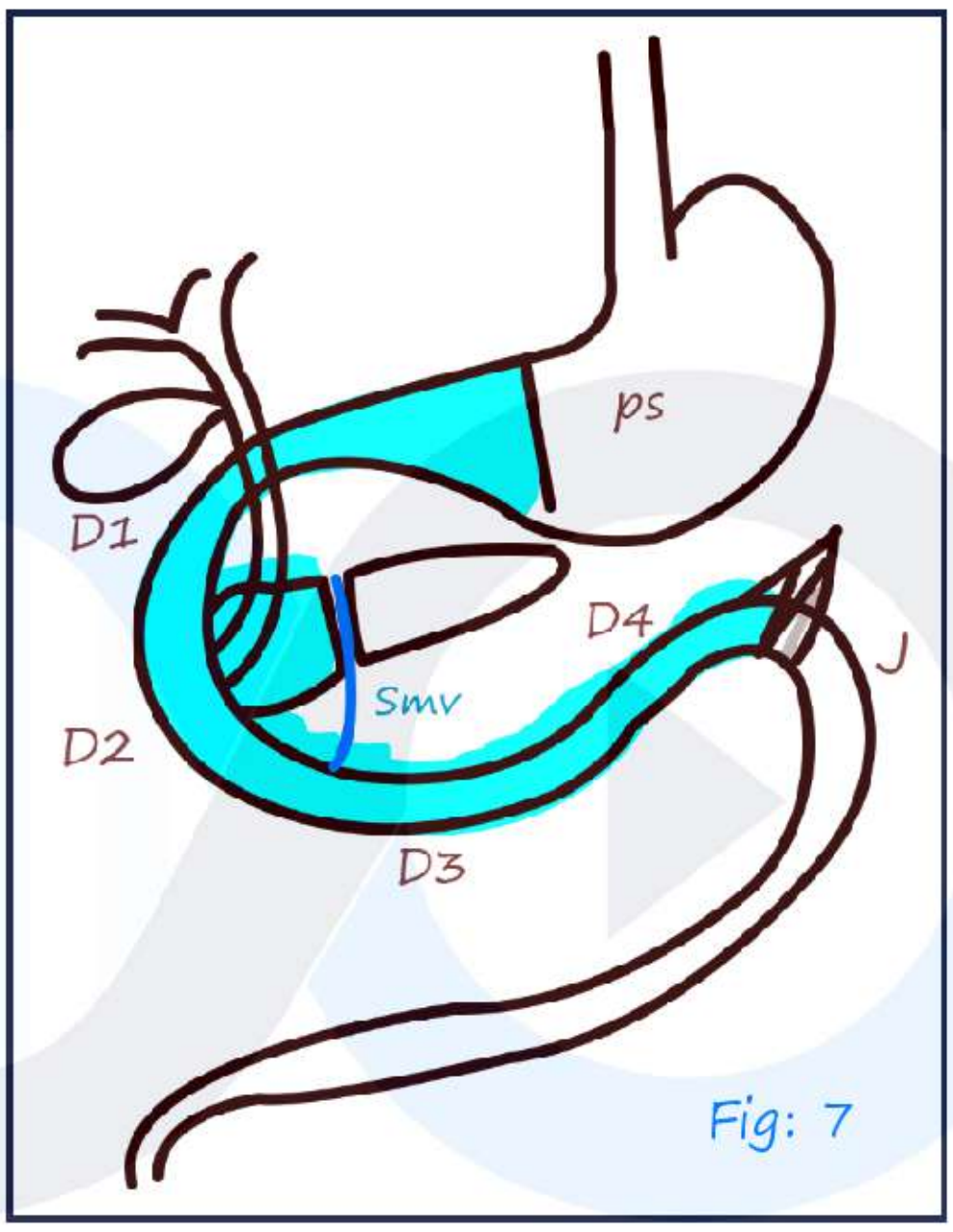

Fig: 7

- It is done for 4 operations
  a. Ca head of pancreas
  b. Periampullary Cancer
  c. Duodenal cancer
  d. Distal CBD Cancer
- Structure removed are distal stomach, entire duodenum, pancreas head, gall bladder, CBD → (medial to the tunnel of love)
- After removing these, bring jejunum and make 3 anastomosis
  a. Pancreatico-jejunal anastomosis

b. Gastro-jejunal anastomosis

c. Hepatico-jejunal anastomosis

- Most common complication after whipples → delayed gastric emptying is seen in 18% of patients
- Most common causes of death → PJ anastomosis leak the pancreatic enzymes – peritoneal cavity cause severe pancreatitis and sepsis
- Achilles heel of whipples → PJ anastomosis
- If there is a drain that is persistent, the collection will come out through that drain and that complication of pancreatic leak through drain is called pancreatic fistula also called POPF- post op pancreatic fistula

AfraTafreeh.com

- POPF – usually diagnosed on 3rd post op day by measuring serum amylase, or fluid amylase
- If DT fluid amylase is 3 times increased of serum amylase, then it is a leak, fistula

TUTORIALS LOGIN FOR SUCCESS

- Other complications are bleeding, abscess, sepsis, death
- Delayed gastric emptying can be prevented by do not cutting the nerve of latarjet, pylorus preserving pancreaticoduodenectomy (PPPD)

i. Pancreatojejunostomy

ii. Duodenojejunostomy (1st part duo) or pylorojejunostomy

iii. Hepaticojejunostomy

AfraTafreeh.com

- PPPD – also called Longmire and Traverso procedure
  - In bailey and love. It is the gold standard for pancreatic head ca and periampullary Ca.

Endocrine neoplasms 00:36:10

- NET (or) PNET (Pancreatic Neuroendocrine Tumors)
  - These tumors arise from endocrine cells of pancreas
  - Nothing but islet cells which produce insulin and glucagon
  - D cells produce – somatostatin
  - G cells – Gastrin
  - Cells producing VIPomas
  - Most common NET's are PPomas – pancreatic polypeptidomas. They are non-functional tumors of pancreas
  - Most common functional NET tumors of pancreas → Insulinomas from Beta cells
  - Most common NET in MEN-I-Gastrinomas (from α cells)

Insulinoma	Gastrinoma
• Most common functioning NET • Mostly benign • Site: Head= body =tail (but insulin producing	• Most common NET in MEN-I • Mostly malignant

β cells are present in distal part of pancreas and tail) **Clinical features:** Present with whipples triad -Signs of hypoglycaemia -Blood sugar at that time <50 mg/dl -Sugar decreases symptoms -So, they keep on eating and weight gain (obese) Insulinoma – tumor with weight gain **Investigation:** • 72 hours fasting blood sugar, if blood sugar goes <50 we should measure insulin level • We have to measure C-peptide, to rule out exogenous insulin	• Most common site – Duodenum (or) PASSARO Triangle (most overall site) -Neck of pancreas -2nd and 3rd part of duodenum -Gall bladder & cystic duct with CBD junction • Here patient present with Zollinger Ellison syndrome ↓ Excessive gastrin secretin stimulates excessive acid production • So, they developed unusual peptic ulcer and unusual recurrence of ulcers • Severe diarrhoea +++ • Serum gastrin level is >1000 pg/ml • If gastrin level is borderline then, we do **secretin stimulation test**. If we give secretin for the patient with borderline value, there

AfraTafreen.com
TUTORIALS
LOGIN FOR SUCCESS

AfraTafreeh.com

administration (C-peptide is increased in insulinoma but normal in exogenous administration) **Locate the tumor** Preoperative - Endoscopic USG (Gold standard for any NET) - SPECT – photon emission CT (Recently using) - Angiography and portal venous sampling, to know where excessive insulin is coming - Intra op USG - for pts whose pre-op unable to locate **Treatment** - Enucleation is enough - If insulinoma is close to pancreatic	is immediate increase of 200pg/ml in 15mins • In gastrinoma, glucaganoma and other NET's, have somatostatin receptors (only NET without somatostatin receptor is insulinoma) • SRS – somatostatin receptor scintigraphy is excellent investigation for gastrinoma • SPECT • Gastrinomas are malignant. - So, either do whipples operation (or) for tumors in passaro triangle **Distal pancreatectomy** + **Splenectomy** - If tumor is distal portion

duct, then we have to do resection also	
If there are metastasis from NET ↓ Even if it is R_1 resection We must try to resect the metastasis. Because even with liver mets, there is good survival 50% survival up to 5 years is seen	
• If past residual insulinomas are treated by insulin inhibitors like –Streptozocin –Diazoxide –Octreotide analogues	• Long acting analogues like i. Pasireotide ii. Lanreotide –New drugs inhibit acid production • Triple dose PPI

AfraTafreen.com
TUTORIALS
LOGIN FOR SUCCESS

Glucagonama

- α-cell tumors
- Glucagon stimulates diabetes (hyperglycemia) causes dermatitis (necrolytic migratory erythema)
- Mostly malignant
- Most common in head of pancreas

VIPoma

- Also called Verner Morrison syndrome/ Pancreatic Cholera/ WDHA syndrome (watery diarrhoea, hypokalemia, achlorhydria syndrome)
- Most common in tail of pancreas

AfraTafreeh.com

Cystic neoplasms of pancreas 00:56:20

i. Serous cystic neoplasm – which is most common in head
   - It is the overall most common
   - It contains clear fluid
   - It is benign cystic neoplasm
   - On FNAC – glycogen rich cells
   - We can wait and watch as they are benign
   - No need of surgery
   - CT scan shows sunburst calcification
   - Most common in females > males

ii. Mucinous cystic neoplasm (MCN)
   - More exclusively common in females (F>>>M)
   - Most common in body & tail
   - Mostly malignant
   - FNAC – show ovarian stroma
   - CECT scan – egg shell calcification
   - Distal pancreatectomy + splenectomy is done

iii. There is a cystic neoplasm arising from duct itself producing excessive mucin known as intraductal papillary neoplasm (AKA) IPMN
   - Most common in head and pancreas
   - M=F
   - Mostly malignant
   - FNAC → shows mucin rich cells

- CECT → Both upstream of downstream i.e., proximal/ distal dilation of the pancreatic duct seen
- ERCP scopy (or) side viewing scopy in IPMN → we can see a fish mouth ampulla is seen (because of continuous secretion of mucin)

iv. Frantz tumor or solid papillary mucinous neoplasm

- These are rare tumors
- IOC for cystic neoplasm → EUS guided biopsy & fluid analysis
- IPMN & MCN → have increased CEA levels

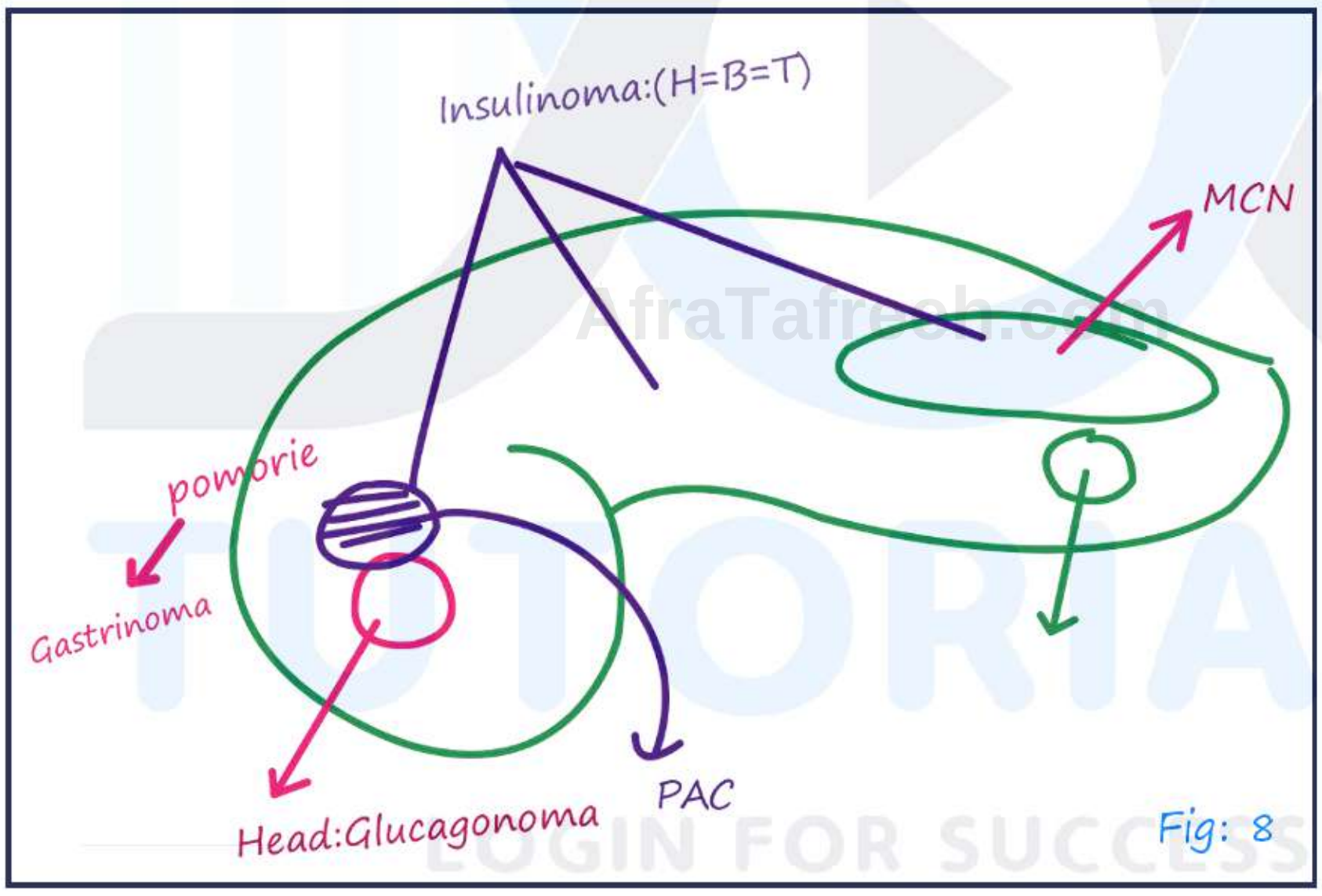

Fig: 8

- Classical finding of periampullary cancer → malena with pale clay stool called Thomas sign – silver stools (Because of obstructive jaundice, mild malena)

AfraTafreeh.com

Fig: 9

Cect Scan with Pancreatic Protocol

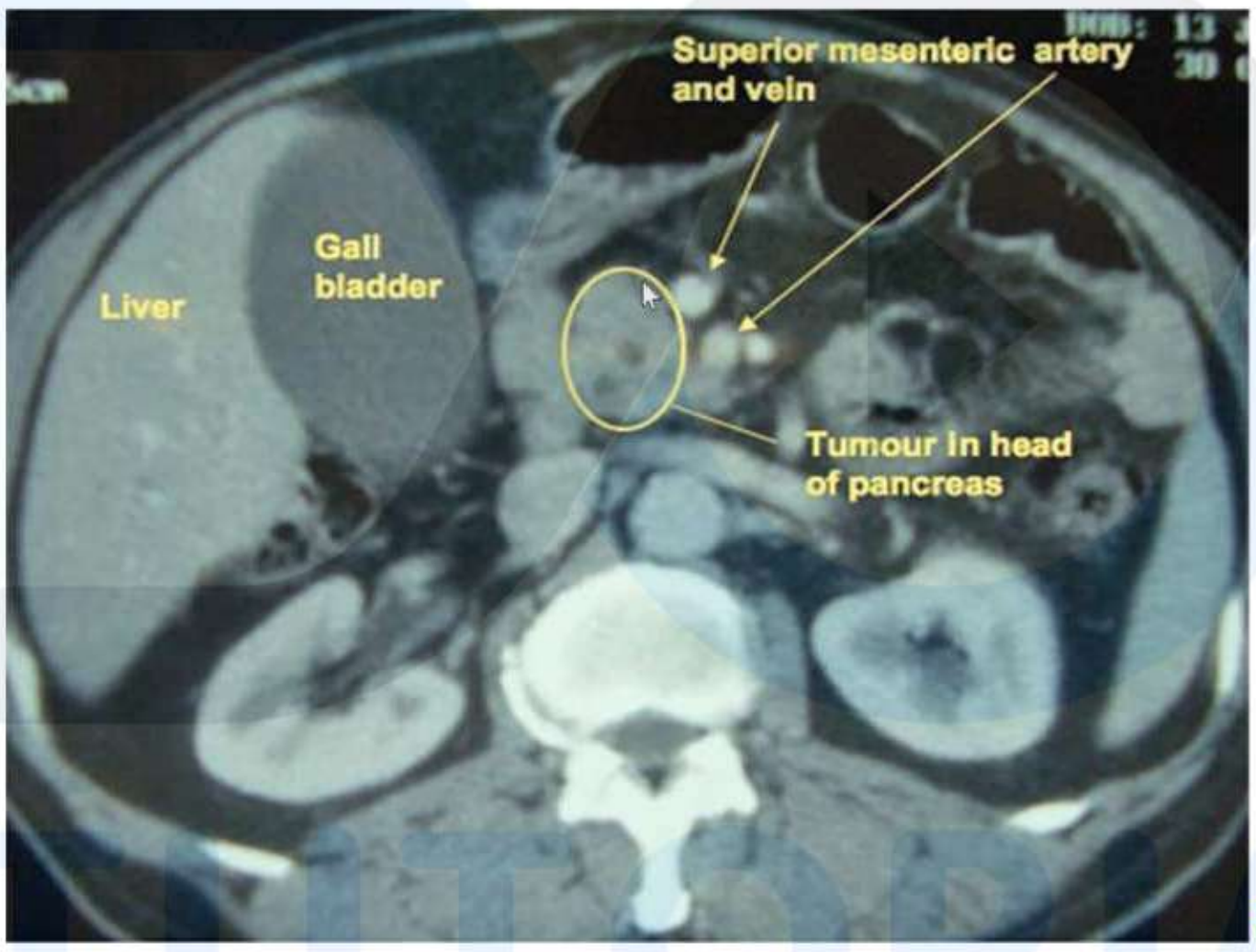

Fig: 10

TUTORIALS
LOGIN FOR SUCCESS

- Mucinous cystic neoplasm in tail of pancreas → distal pancreatectomy done results in pancreatogenic diabetes called type III diabetes (occurs after pancreatectomy)

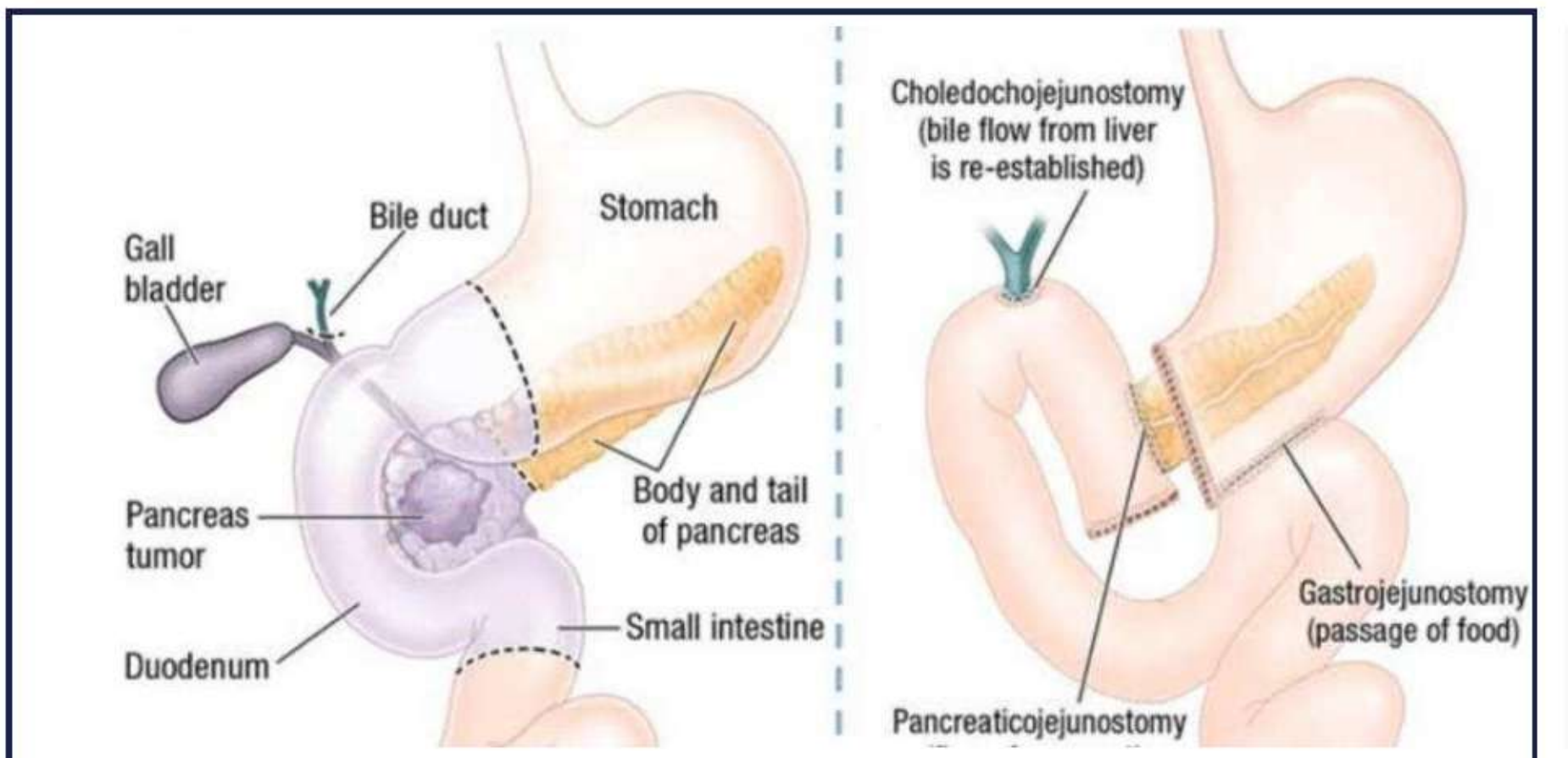

Fig: 10

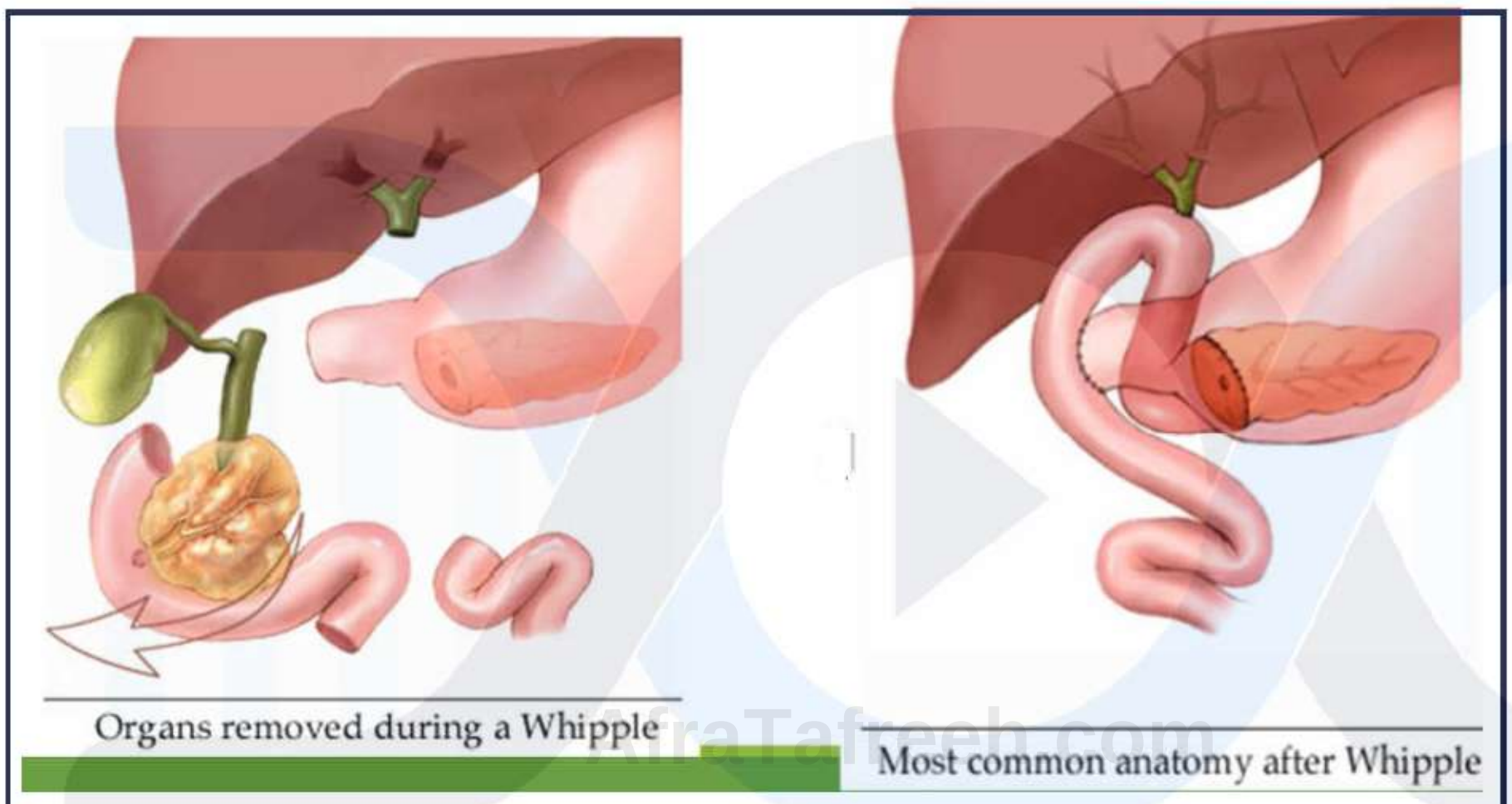

Fig: 11

TUTORIALS
LOGIN FOR SUCCESS

AfraTafreeh.com

INTRODUCTION TO LIVER

- Liver is the largest solid organ in the body
  - On inferior surface liver has porta hepatis, through which 3 important structures enter the liver
  - Posteriorly, we have portal vein entering the liver
  - Anteriorly, to the left hepatic artery entering
  - Anteriorly, to the right bile duct entering

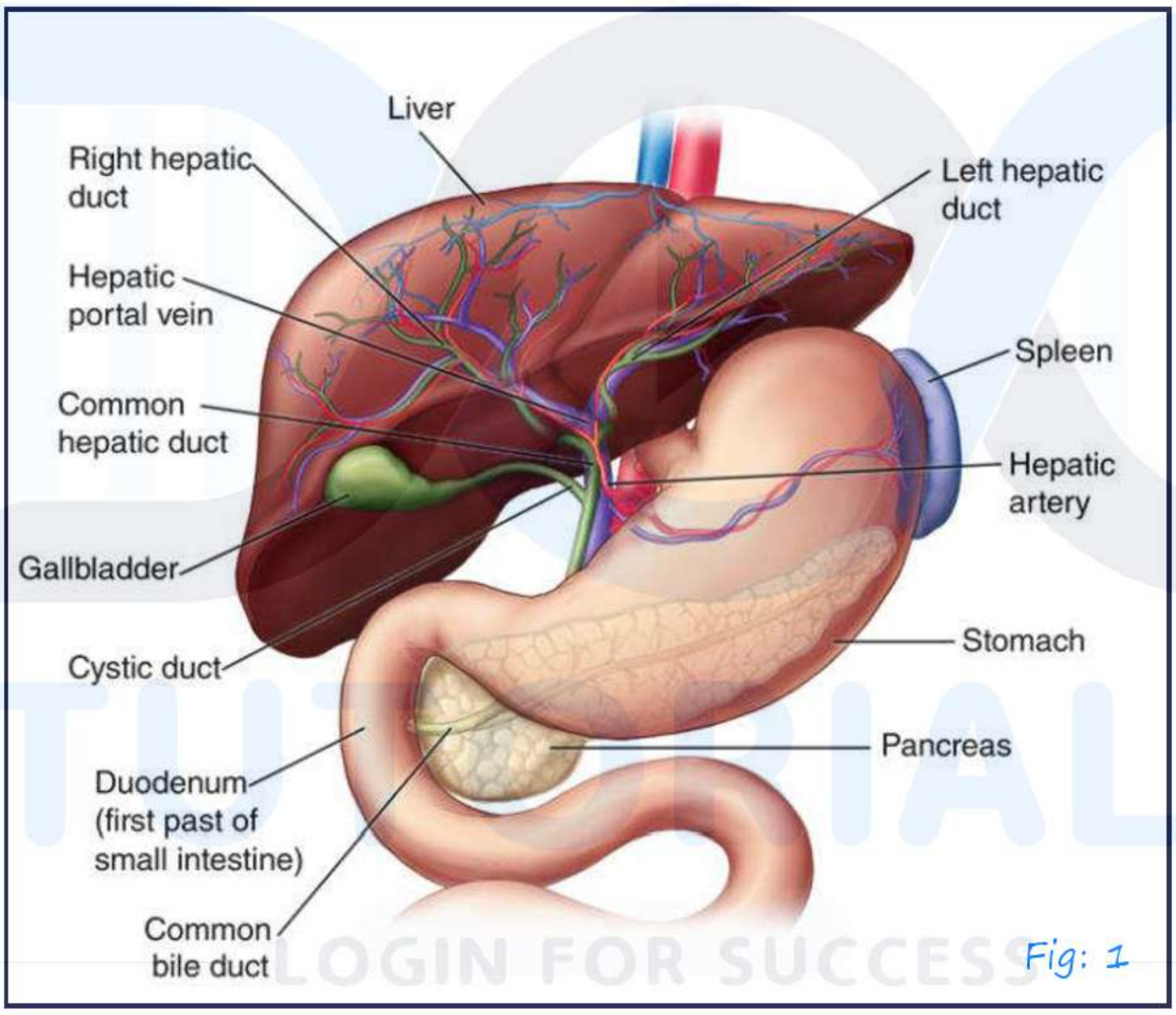

Fig: 1

- Portal veins give 80% of blood supply to the liver
- Hepatic artery given 20% of blood supply to the liver
- 100% of O_2 to the liver coming from hepatic artery only
- If there is tumor in liver HCC/mets → tumor receives blood supply only from hepatic artery. This

is the concept behind hepatic artery embolization in treatment (Tumors can be reduced/shrunken)

Abnormal arteries 00:02:18

- Sometimes left hepatic artery is replaced (or) we can see an accessory/aberrant LHA, origin from left gastric artery seen in 20-30% of patients. It will be running on the lesser omentum. (Normal LHA arises from proper hepatic artery). This aberrant/accessory/ replaced left hepatic artery is having to be in our mind while doing pars flaccida technique in fundoplication
- Right hepatic artery → can also be replaced/aberrant/accessory and it comes from superior mesenteric artery. Normally, it runs anterior to portal vein. This abnormal RHA will run posterior to portal vein and give branch to right lobe of liver. During whipples operation, if we not a big abnormal artery posterior to portal vein, think of abnormal RHA
- Abnormal/aberrant/replaced cystic artery arises from GDA (Gastro duodenal artery)

Supra duodenal bile duct

- Bile duct gets the blood supply from 3'O clock & 9'O clock-2 arteries running parallel to bile duct.

AfraTafreeh.com

These are formed by branch from right hepatic artery from above (or) from GDA from below

Couinaud's segments of liver 00:08:17

- segmental anatomy of liver concept
- Each segment of liver is a separate functional unit, that is having a hepatic venous drainage, portal vein supply, hepatic artery supply, bile duct drainage. Total 8 segments of liver are present
- Divide the liver into two by drawing a line from the right side of IVC to gall bladder fossa (an imaginary line) which corresponds to middle hepatic vein. This line is called cholecystocaval line known as Cantle's line
- Other important veins are right hepatic vein and left hepatic vein
- From below portal vein comes and divided into right and left portal veins. Based on hepatic vein and portal vein drainages, we have totally 8 segments → 2,3,4a,4b,5,6,7,8
- Segment 1 is seen separately, posteriorly called caudate lobe. It has direct drainage into IVC
- The hepatic vein is having 3 fissures
  - Right main fissure
  - Left main fissure
  - Main fissure
- Main fissure is nothing but cantles line

- Portal vein is running on scissura, on right side it is called right scissura, on left side – called left scissura
- Segment 2 and 3 are called left lateral segments. Removal of these segments lateral to falciform ligament is called left lateral hepatectomy
- 4a & 4b are called left medial segments
- 5 and 8 are located anteriorly, so called right anterior segments
- 6 and 7 are right posterior segments (Right post segmentectomy)

Brisbane 2000 Terminologies (new terms)

00:15:15

AfraTafreeh.com

- Left hepatectomy (old term) → new called left hemi hepatectomy segments are 2,3,4a,4b
- Right hepatectomy (old term) → now called right hemi hepatectomy. Segments removed are 5,6,7,8
- Extended left hepatectomy (old) → (new) left trisectionectomy 2,3,4a,4b⊕,5,8 segments removed
- Extended right hepatectomy (old) → (new) right trisectionectomy 5,6,7,8⊕,4a,4b
- Central hepatectomy as known as taj mahal hepatectomy remove segments like taj mahal dome 4b,5,8 segments are removed
- Left hemi hepatectomy is done for left lobe HCC (or) mets of left

AfraTafreeh.com

- Right hemi hepatectomy is done for right lobe HCC
- Extended right hepatectomy → done for type 3A hilar cholangiocarcinoma
- Left trisectionectomy → type 3B hilar cholangiocarcinomas
- In radial cholecystectomy the segments removed are 4b & 5
- We have 2 advantages in the segmental anatomy
  i. Now we can do curative resections very well
  ii. Liver donor transplants are possible
    - For paediatric case → 2 and 3 segments are donated for adult case → 5,6,7,8 segments (right liver) are donated
- Cadaveric liver transplant → one liver can save 2 people
  - 2,3 segments can save paediatric case
  - 4b,4a,5,6,7,8 can be given to adult
  - So, we can do split liver transplant

TUTORIALS
LOGIN FOR SUCCESS

Special scans in liver 00:22:46

- Liver cells
  i. Hepatocyte → is the largest functional unit of liver
  ii. Kupffer cells → reticuloendothelial cells in liver
    - Both these can be picked up by radionucleotide scan, HIDA

- HIDA is taken up by liver and is excreted without any change coming through bile duct and enter duodenum, on the way it is concentrated in gall bladder
- It is based on functioning hepatocytes → HIDA scan

Uses of HIDA

i. To know the use/assess the liver function
ii. To diagnosis bile leaks
iii. To show physiology of bile flow
iv. To investigate for biliary obstruction
v. Gold standard investigation for acute cholecystitis
   - GB not visualised → because of edema in the cystic duct
vi. Used to diagnose choledochal cyst
vii. Hepatocellular tumors can be differentiated

AfraTafreeh.com
DOT TUTORIALS
LOGIN FOR SUCCESS

Sulphur Colloid Scan

- Scan based on kuppfer cells is sulphur colloid scan (functioning reticuloendothelial cells)
- If there is functioning kuppfer cells, they appear as hot spot
- There is only on tumor with functioning kuppfer cells is focal nodular hyperplasia
- So, sulphur colloid scan shoes FNH as hot spot
- No other tumor has functioning Kupffer cells

AfraTafreeh.com

- In HCC, the hepatocytes are damaged, even the HIDA scan not shows HCC
- So, HCC will not be shown on sulphur colloid scan as well as HIDA scan, (both are useless in diagnosis)
- To differentiate hepatocellular tumors – HIDA scan

LFT- liver function tests

Bilirubin

- Direct bilirubin is increased in obstructive jaundice/surgical jaundice
- Indirect bilirubin is increased → medical jaundice/hepatocellular jaundice
- ALT & AST are produced in liver, in case of liver damage they increase
  - ALT is liver specific
  - For chronic liver damage – Albumin decreased
  - P.T & INR are increased in chronic liver damage

LOGIN FOR SUCCESS

Cirrhotic livers 00:32:18

Modified child pugh score

- Based on 5 factors

	1	2	3
B-Bilirubin	1-2 mg/dL	2.1 to 3mg/dl	>3mg/dl
A – Ascites	No	Mild	Moderate to severe

A – Albumin	≥3.5 gm/dl	2.8 to 3.4	< 2.8 gm/dl
P – P.T (increase in seconds) Normal–12 - 16 seconds	Increase 1-4 seconds elevation	4.1 to 6 second elevated	>6 seconds elevated
E – Encephalopathy	No	Grade 1 to 2	Grade 3 to 4

- With the scores we categorise them into
  - Child A – score 5 to 6
  - Child B – score 7 to 9
  - Child C – score 10 to 15
    i. Minimum possible score is 5
    ii. Maximum score is 15
- Any surgery is not done in child 'c' case (not even hernia). They will have severe bleeding
- Child A we can do surgery child B we have to assess before surgery

TUTORIALS
LOGIN FOR SUCCESS

MELD score

- Modified end liver disease score (new)
- It is based on log of
  - C – Creatinine
  - B – Bilirubin
  - I – INR

AfraTafreeh.com

- With this score only, we make the patient into waiting list for liver transplant
- The score is from 6-40 waiting list is given to patients who are having score >15

Exceptions for MELD score

- HCC
- Amyloidosis
- PCLD
    - MELD score is used for adults
    - For paediatric population, separate score PELD score

Paediatric end liver disease score

- B – Bilirubin
- A – Albumin
- N – Nutritional status
- I – INR
- A – Age
    - Acute fulminant liver failure → The liver goes to failure in 15days
    - For these patient, we have to go for emergency transplant called as auxiliary liver transplant (we will keep another liver underneath patients liver (don't remove patient liver)

TUTORIALS
LOGIN FOR SUCCESS

King's college criteria

Liver transplant in acute fulminant liver failure

Paracetamol induced

↓

- pH < 7.30
- (irrespective of encephalopathy)

(or)

- PT > 100sec + s.creatinine > 300 μmol/L + grade 3,4 - encephalopathy

Non paracetamol

(NEET PG 2020)

↓

- PT >100 seconds

(or)

Any 3 of the below

↓

- Age <10 or >40years
- Etiology: non A/non B liver damage due to halothane/ drug induced
- >7days of jaundice before encephalopathy
- S. bilirubin ≥300 μmol/L
- PT > 50 seconds

AfraTafreeh.com
TUTORIALS
LOGIN FOR SUCCESS

AfraTafreeh.com

INFECTIONS IN LIVER

Routes of infection to liver 00:00:37

a. Biliary route

- Any infection in biliary system due to stones (or) cancer, we get cholangitis. It is most common route of infection to liver
- Most common follows cholangitis (most common reason)
- Cholangitis is usually due to stones in Asian countries and cancer in western countries
- Most common organism isolated from multiple organisms is E.coli (worldwide)
- 2nd → klebsiella (1st most common – Asians)

b. Arterial route: Hematogenous

- Mainly because of sepsis (bacteraemia/septicaemia/osteomyelitis)
- In hematogenous route – most common organism is staphylococcus
- It is usually multiple micro abscess seen
  - Arterial route – mono organism
- It is usually macro abscess seen in biliary route – most common multiple organ

c. Portal vein route

- Any infection comes to the portal vein, P.V infection is called pyelophlebitis

- Pyelophlebitis in neonate is due to umbilical sepsis
- In adults any infection in the intestine like appendicitis, diverticulitis and perforation peritonitis
- Even cancer colon is found to transfer bacteria to liver
- Amoebic infection/ abscess is only through portal vein route

d. Direct spread

- From near by infections
- Due to trauma also – direct spread from subcutaneous tissue to liver
- Most common cause of pyogenic abscess is through biliary route
- Cryptogenic origin is we don't know where the injection is from
- Most common cause of pyogenic abscess is cryptogenic cause (unknown)

AiraTahoor.com
DX TUTORIALS
LOGIN FOR SUCCESS

Pyogenic abscess 00:07:36

- Infection caused by bacteria
- Most common organism isolated is E. coli–in world; Klebsiella–in India
- If it is hematogenous route (or) in children → It is staphylococcus

AfraTafreeh.com

Clinical features

- M:F = 1.5:1
- Patient came with high grade fever + chills/rigor
- Hepatomegaly⊕
- Severe right hypochondrial tenderness⊕
- Most common lobe involved is right lobe 50% cases are multiple abscess
- Patient with pyogenic abscess, patient look sick, probably patient has septicaemia, bacteraemia
- Most important predisposing factor is
  i. Immunocompromised status like HIV, CGD (children)
  ii. Diabetes

TUTORIALS
LOGIN FOR SUCCESS

Investigations

- Increase LFT → ALT increase, increase bilirubin, increase ALP, increase PT, increase INR
- Blood culture/sensitivity – 50-60% times the organisms are ⊕

Gold standard

- CECT abdomen
- We see abscess are not well defined, they are clustered, hypodense lesions on CT scan
- They have peripheral rim enhancements
- Nuclear scans – pyogenic
  - Abscess – hot spot

Complications

- Sepsis
- Endogenous endophthalmitis seen in 3% cases of klebsiella infection + DM
- Osteomyelitis can happen
- Infective endocarditis can happen

Management of pyogenic abscess

- IV antibiotics at least for 2 weeks
- Percutaneous aspiration is done under cover of antibiotics (previously done)
- Now-a-days percutaneous drainage tube is better

Amoebic abscess AfraTafreeh.com 00:07:36

- Infection caused by entamoeba histolytica
- Most common cause – E. histolytica
- It enters the intestine through infection of colon
  - Caecum/sigmoid colon
- Infection enters portal vein route
- 1/3 patients will have H/o diarrhoea
- 1/3 patients will have subclinical infection
- 1/3 patients will have to history at all
- M >>>>> F (rare in females)
- Menstruating female are protective against amoebic (for unknown reason)
- Iron deficiency anaemia is protective against amoeba

TUTORIALS LOGIN FOR SUCCESS

AfraTafreeh.com

- Patient present with hepatomegaly ⊕ pain right hypochondrium (no fever)
- Amoebic abscess – 2 types

  i. Acute – present with in 10 days
    - 50% times multiple in nature

  ii. Chronic – present > 21 days
    - 90% times most common in right lobe of liver
    - 90% solitary
    - Patient with amoebic abscess, not so sick, he is alright
- Predisposing factor – Alcohol

Investigation

- One test – patient increase, INR increase
- We have to examine/look for anti-amoebic antibodies
- Indirect haemagglutination test which is 90% sensitive
- Recently done test is ELISA 99% sensitive for anti-amoebic antibodies
- ELISA is not much useful in endemic areas, it will be positive for chronic cases also
- In endemic areas, we should look for amoebic lectin antigen test
- It can be found in liver abscess, serum also

DOC TUTORIALS LOGIN FOR SUCCESS

Gold standard

- CECT abdomen
- Well defined abscess, most common in right lobe, with peripheral edema present (no peri enhancement)
- Nuclear scans with Ga/Tc^{99m} can be done, these scans show leucocytes.
- Amoebic abscess have no leucocytes. So, they appear as cold spot in nuclear scans

Complications

- Anchovy sauce color pus (odourless)
- It causes liquefactive necrosis of the tissue
- It will not attack Glisson's capsule (It is resistant to amoebic trophozoites)
- Most common complication – reactive effusion of lung
- Most common site of rupture – peritoneal cavity. It needs surgery (wash)
- If it ruptures into pleura – put ICD
- It can rupture into bronchi – patient cough out the pus filled sputum
- We put patient in prone position dependent drainage. So, that he will cough out all the pus
- No ICD required
- Give bronchodilators
- Chest physiotherapy is advised

AfraTafreeh.com

- It can rupture into mediastinum, rarely and cause pericardial tamponade

Management of amoebic abscess

- Does not need aspiration
- TOC: oral metronidazole 750mg TDS & 2weeks
  - 2-3rd day – response is seen
- If patient not tolerates metronidazole, go for alternate drugs
- Give luminal amoebicides for 10days. They are
  - Dilaxonide furoate
  - Emetine
- Indications of percutaneous drainage od amoebic abscess
  - Size > 5cm
  - Superficially located
  - Left lobe abscess
  - Doubt full diagnosis
  - Not responding to metronidazole for 2-3days
- Double pig tail stent is kept in cavity slowly abscess is drained, within 1month, abscess is completely drained out, we can remove it
- Radiologically the cavity remains for 3-9months (residual cavity)

Hydatid cyst 00:34:45

- It is very common in India
- Caused by dog tapeworm – Echinococcus granulosis
- E. multilocularis → malignant hydatid cyst, common in fox, wild animals, dangerous disease
  - We need to do liver resection for these cases
- Dog's S.I, ileum lodges hydatid trophozoites. They shed the eggs in the stool. Goat/sheep consumes this stool and they become intermediate host. From sheep/goat, it goes to dog
- In between accidentally, man gets the infection
  - Man is the end host, becomes trophozoites entering the human will not form adult worm. Instead they form hydatid cyst
- In man hydatid enters duodenum, it forms oncospheres. Which are having hooklets. They enter the portal venous circulation; it enters into various places in the body
- Most common organ it will reach is the liver, other organs are lungs, kidney, brain etc
- Hydatid cyst in all places is covered by 3 layers
  - i. Outer layer – pericyst as known as ectocyst → derived from host tissue
  - ii. Inner germinal layer – living layer harbouring scolices and hydatid sand. Scolices form daughter cysts and can't become another worm

AfraTafreeh.com
TUTORIALS
LOGIN FOR SUCCESS

AfraTafreeh.com

iii. Middle laminated layer – Allows nutrition to daughter cysts and it is permeable to selective components (nutrition)

- It is resistant to bacterial entry, so infected hydatid cyst is very rare

- Inner germinal layer + middle laminated layer = Endo-cyst
- In which organs ectocyst is not seen → in lungs and brain; ectocyst present in kidney & liver
- Hydatid cyst commonly seen in right side of the liver (seg 6,7, right posterior segment)
- Most common presentation of Hydatid cyst is pain
  - O/E – huge hepatomegaly
- Hydatid thrill is seen in clinical examination
- Jaundice is present if bile duct is obstructed by daughter
- Sometimes, patient has H/o passing grapes in motion is due to hydatid rupture into biliary tree, then enters duodenum and coming through motion
- IOC: CT scan
  - Most common investigation done once upon a time is Casoni's intradermal test
- Now a days, we do
  - Immunoblot assay
  - ELISA
  - Immune electrophoresis
  - Arc 5 test

DX TUTORIALS LOGIN FOR SUCCESS

- CECT abdomen (classically shows some findings)

WHO classification (old name is Gharbi et all)

- CE 1 – clear unilocular cyst
- CE 2 – Honey comb appearance (multiple daughter cysts)
- CE 3 – Floating snake, water lily appearance
- CE 4 – Heterogenous cyst, partial classification is seen
- CE 5 – Fully calcified cyst
  - These can be found both on USG as well as CT scan CE I, II, III are living/active
- CE 4 and 5 are dead
- Most common complication is biliary tree rupture
- Seen in 27 to 30%
- If the cyst ruptures into biliary tree, daughter cysts obstruct the bile duct and present with clinical features of
  - Increase alkaline phosphatase
  - Increase bilirubin
- And patient has jaundice and cholangitis features

Risk factors for rupture of hydatid cyst

- Size > 10cm
- Male patient
- Centrally located hydatid cyst (at the bifurcation)
- If there is elevation of liver enzymes – GGT, ALP

AfraTafreeh.com

- If hydatid cyst is bile stained/purulent fluid

Conventional treatment

- Start them on T. Albendazole 400mg BD for 4weeks with a gap of 2 weeks, after and it is continued upto 6 cycles and upto 12 cycles also
- Under cover of albendazole
  - Commonly done old method is partial pericystectomy
- By open/lap, we deroof the pericyst wall partially & remove the entire cyst content. We leave the posterior wall as such. Posterior wall should not be tried to remove, as there are important blood vessels like hepatic artery, portal vein forms the posterior wall. If we try to remove, we may damage it
- After removal surgeons use to keep the omentum inside the cavity to get it obliterated
- Partial hepatectomy is also done in some cases
- While doing pericystectomy/hepatectomy, we should look for biliary communication
  - If it is found, it should be carefully suture the biliary tree
- We also should do CBD exploration to look for daughter cyst inside and keep a T-tube inside, if we suspect a biliary rupture
- IOC is to rule out bile duct hydatid – MRCP

- If before surgery on MRCP – bite duct hydatid is found, then go for ERCP and sphincterotomy is done

- If intra operatively found – then open CBD and put a tube after clearing CBD

New treatment is **PAIR** (percutaneous aspiration infusion and reassurance)

- We use
  - 20% hypertonic saline
  - 0.5% silver nitrate
  - 95% ethanol
  - Mebendazole

  ] **Scolicidal agents are used**

- 10% povidone iodine which was used previously is not used how because of yellow colour, it causes confusion with biliary communication
  - Even in open surgery, open cavity, pack all around liver with hypertonic saline. So, if the cyst ruptures also, saline prevents going for anaphylactic reaction
  - 3 types of PAIR
    1. PAIR → done in size <6cm (or) <100ml content
    2. PAIR with catheter kept inside → done in size >6cm, >100ml content inside
    3. PEVAC → percutaneous evacuation of cyst contents

AfraTafreeh.com

PAIR contraindications

- Not used for honey comb cyst cannot completely aspirate for type CE_2
- For dead cyst i.e., type CE_4, CE_5
- When there is communication with biliary tree, if we use scolicidal agents, they block biliary tree and cause fibrosis
- Superficially located cyst
- Not used in lungs and brain, as they don't have ectocyst
- Already ruptured into peritoneum (or) pleura

TUTORIALS
LOGIN FOR SUCCESS

LIVER TUMORS

- Most common tumor of liver → secondaries
- Primary tumors of liver are

Benign ↓

a. Hemangioma (most common)
b. Adenoma
c. Focal nodular hyperplasia (FNH)

Malignant → are common in males ↓

a. HCC – most common
b. Intrahepatic cholangiocarcinoma
c. Fibrolamellar type of HCC
d. Hepatoblastoma most common in children <5 yrs

In FAP, infants, congenital hepatoblastoma. So, upto 1 year screening is needed.

AfraTafreeh.com
TUTORIALS
LOGIN FOR SUCCESS

AfraTafreeh.com

Benign Tumors of liver 00:02:31

Hemangioma	FNH	Hepatic Adenoma
- Common around age 45 yrs - Most common in females	- Common in middle aged females	- Common in 20-40 years - Common in females - a/w OCP and steroid consumption - Multifocal adenoma is equal in M&F in 20% cases no association with OCP called as adenomatosis
- It is the most common Incidentaloma - Equal in right and left lobe - Childhood hemangiomas - 12% of liver tumors in children - They are multifocal	- It is the only tumor in liver which has functioning reticuloendothelial called (Kupffer cells) - It is the only tumor in liver which has functioning reticuloendothelial	

- Involves other organs - When they are very large, they can cause AV shunting is seen - Results in CCF	cell called Kupffer cells. - So, it is the only tumor appear as hot spot in Sulphur colloid scan	
Complications- - Rupture and bleeding - Giant >5cm, **>10cm → Kassabach merit syndrome** ↓ Thrombocytopenia CCF	- Rupture and bleeding	- Rupture, bleeding and malignancy
Triple phase CT - Slow enhancement of contrast from periphery to centre and slow wash out	'Central stellate scar' ↓ Also seen in Fibrolamellar HCC, Sulphur colloid scan is done to differentiate shows 'hot spot'	Early enhancement of contrast with heterogenous lesions
Treatment - Asymptomatic →No Rx - Symptomatic →enucleation with	- Usually no need treatment	- Adenoma always need excision

AfraTafreeh.com
TUTORIALS
LOGIN FOR SUCCESS

AfraTafreeh.com

inflow arterial control	- Excision is done for doubtful and symptomatic	

Investigations

- For any space occupying lesion in Liver, IOC is Triple phase CT
- IOC to Hemangioma is MRI shows "light bulb sign" in T2 weighted image
- FNAC is C/I in any liver mass

Hepatic Adenoma

- Lesion of 20-40 years' females, who are taking OCP.
- 80% are solitary, 20% multiple cases – (M=F) no H/O OCP
- Beta catenin mutated H.A
  - They have high risk of malignancy
  - Exon 3 mutation – high risk of malignancy
  - Exon 7,8 mutation – No risk of malignancy
- Sonic Hedgehog activated adenomas
  - Seen in 5% cases only
  - Associated with obesity and bleeding

Hepatocellular carcinoma 00:18:59

- Most common in males
- It is the 5th most common tumor
- It is 2nd common causing death (after lung cancer)

- Most common 1° malignant tumor is HCC

Risk factors of HCC

i. Infections
   - Most common cause hep. B infection
   - In U.S.A → most common cause if Hep. C infection
   - In worldwide 50% cases are due to chronic Hep. B infection.
   - Such cases of chronic HBV infection are insertional mutagenesis and HCC arises from normal liver.
   - In all other cases cirrhosis is associated
   - This risk of malignancy is increased by presence of Hepatitis B antigen (HBeAg) and positive HBV DNA

ii. Cirrhosis
   - Any cirrhosis can cause HCC
   - Alcohol
   - Autoimmune
   - 1° Biliary cirrhosis

AfraTafreeh.com
TUTORIALS
LOGIN FOR SUCCESS

iii. Exposure/Environmental risk factors
   - Aflatoxins
   - Pyrazolidone alkaloids
   - Thorotrast
   - Nitrosamines

iv. Congenital (or) metabolic disorder
   - α_1 antitrypsin deficiency
   - Haemochromatosis
   - Wilson's

AfraTafreeh.com

- Glycogen storage disorders
- Extra hepatic biliary arteria (EHBA)

Clinical features of an HCC patient

- Many times HCC patient are K/C/O cirrhosis (or) K/C/O HbsAg positive
- Such known cases suddenly deteriorates → Sign of HCC
- It can present with mass, weight loss, jaundice, ascites (additional features a/w malignancy)

Paraneoplastic syndrome

- Most common PNS is hypercholesterolemia (other books → hypoglycemia)
- Other PNS are hypercalcemia, polycythemia
- Most common PNS of RCC → increases E.S.R

Pattern of growth of HCC

- 1st – Hanging pattern → Hanging down from liver.
- 2nd – Pushing pattern → Here, it will not infiltrate into vessel, just it pushes them
- 3rd – Infiltrating type → It has worst prognosis. They are inoperable, they have bad prognosis.

TUTORIALS LOGIN FOR SUCCESS

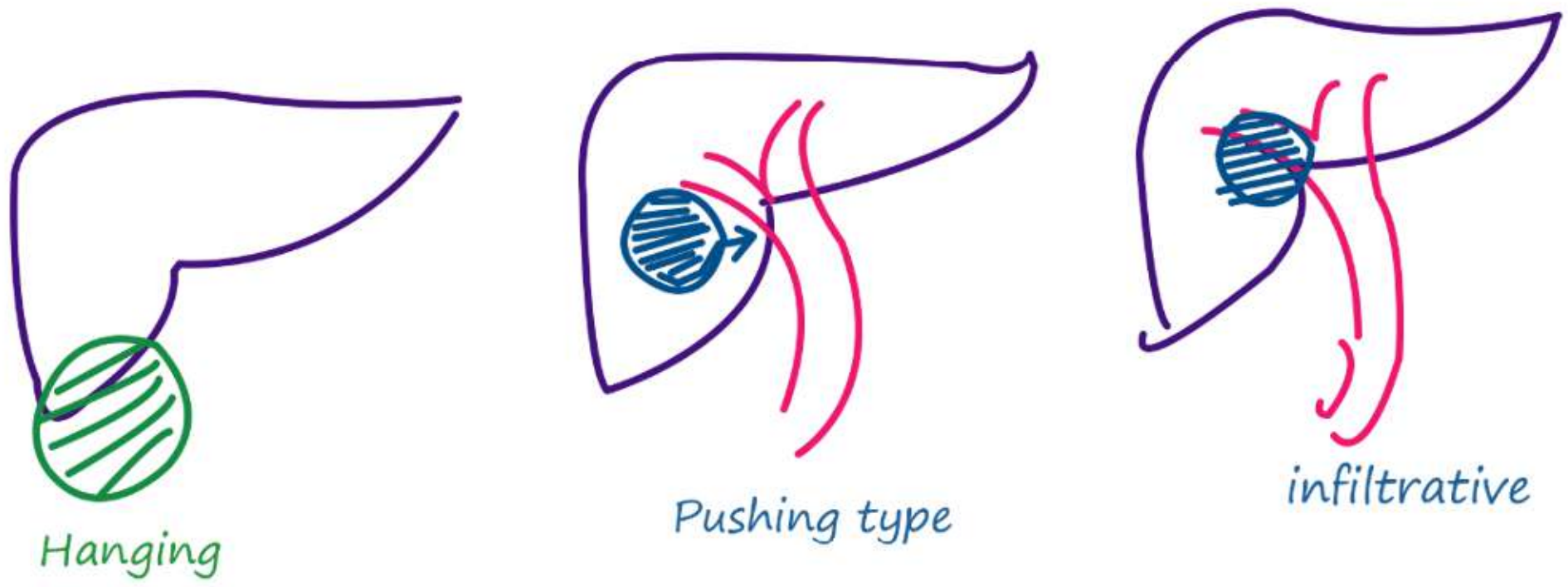

- Hanging type has best prognosis
- Pushing type can be operated

Investigations

Conventional Tumor markers

- AFP - >400 mg/dl → conclusive of HCC
  - It is not sensitive (as it is increases in colorectal Ca, hepatitis, intrahepatic cholangiocarcinoma)
  - It is not specific for HCC, but if >400 – chance of HCC
  - In HCC, 70% cases AFP>20 ng/dl
    In 30% cases, it is not diagnosis.

TUTORIALS
LOGIN FOR SUCCESS

New tumor markers are

i. PIVKA – protein induced vitamin K absence
ii. Glypican 3
iii. AFP – Lectin-3 fraction

- Gold standard for HCC is radiological investigation-Triple phase CT

AfraTafreeh.com

- In triple phase CT, there is early enhancement in arterial phase and rapid washout diagnostic of HCC.
- Lesion is 1-2cm → we need 2 imaging. CECT abdomen and MRI is used.
- Biopsy is not advised in a HCC. It is advised only in inoperable cases for whom we are doing palliative therapies.

Staging system

- TNM staging is not used in HCC
- Staging's used are

I. OKUDA staging

T – Tumor size, >50% of liver surface involved

A – Ascites ⊕

A – Albumin <3mg/dl

B – Bilirubin > 3mg/dl

II. Clip score – Cancer of liver Italian program (most validated score)

C – Child Pugh score – A: 0

B: 1

C: 2

L – liver morphology – If tumor is

i. Uninodular and <50% involved – 0 points

ii. Multinodular >50% involved – 1 point

iii. >50% involved – 2 points

I – markers → AFP > 400 ng/dl – 0 point

< 400 mg/dl – 1 point '

P – Portal vein thrombosis → absent - 0

Present - 1

III. Chinese University prognostic index (CUPI)

BCLC Staging 00:38:00

- Latest scoring system in Barcelona clinic staging system (BCLC)

1. Very early stage
   - Patient has single lesion <2cm
   - It's a child A case
   - With performance score - 0
2. Early stage
   - MILAN criteria says early stage is lesion <3cm and 1 to 3 lesions with no extra hepatic spread
   - Child A, B case
   - Performance score - 0
3. Intermediate stage
   - There are multinodular lesions
   - With child A, D
   - Performance score - 0
4. Advanced stage
   - Patient cannot be operated, because – portal vein invasion

extra hepatic spread performance

score 1 to 2 child A, B

AfraTafreeh.com

5.Terminal stage

- Any child 'C' case
- Performance score 3-4

Performance score (PS)

- 0 – normal patient
- 1,2,3,4 are divided based on actions, they do
- 1- will do mild activities

  ECOG performance score – European cancer oncologist group
- 2 - <50% time bed ridden
- 3 - >50% time bed ridden
- 4 – Moribund patient

TUTORIALS
LOGIN FOR SUCCESS

Treatment

I. Very early stage → If he is a candidate for liver transplant go for transplant

   If no-go for Ablation technique

II. Early stage

- If it is a single lesion and he is a candidate for liver transplant → Then go for liver transplant
- If patient is fitting under MILAN criteria, we should go for liver transplant in selected cases.
- If single lesion, not a candidate for transplant, we do resection
- If patient fits, better to go for liver transplant, because it addresses both cirrhosis & HCC problem.

III. If patient in intermediate stage –

- Patient with intermediate stage and multinodular lesion, treatment advised by BCLC is TACE – Trans Arterial Chemo Embolization.

IV. For advanced cases – Treatment advised is SORAFENIB

V. For terminal stage is only bed side, palliative care

- In very early stage, we can do
  - i. Percutaneous ethanol/Acetic acid injection, (Percutaneous ablation techniques)
  - ii. Resection
  - iii. Transplant
- Early cases
  - i. Resection
  - ii. Transplant
- Intermediate → TACE
- Advanced → Sorafenib
- Terminal → X no Treatment

AfraTafreeh.com
TUTORIALS
LOGIN FOR SUCCESS

Resection 00:45:10

- Segmental hepatectomy (or) anatomical resections are gold standard treatments for HCC
- For 10-20% cases only resection is possible
- After resection major problem is liver failure

AfraTafreeh.com

- This liver failure can be prevented by knowing FLR- Future Liver Remnant
- If there is tumor is normal liver and tumor in cirrhotic liver. In the normal liver after resection of lesion, atleast 25% liver is needed to prevent liver failure (in the normal liver)
- In a HCC patient with cirrhotic background, how much liver, atleast 40% FLR of cirrhotic liver is needed.
- Surgery is only advised for child A cases and selected child B cases

  Liver resection is C/I for child C cases

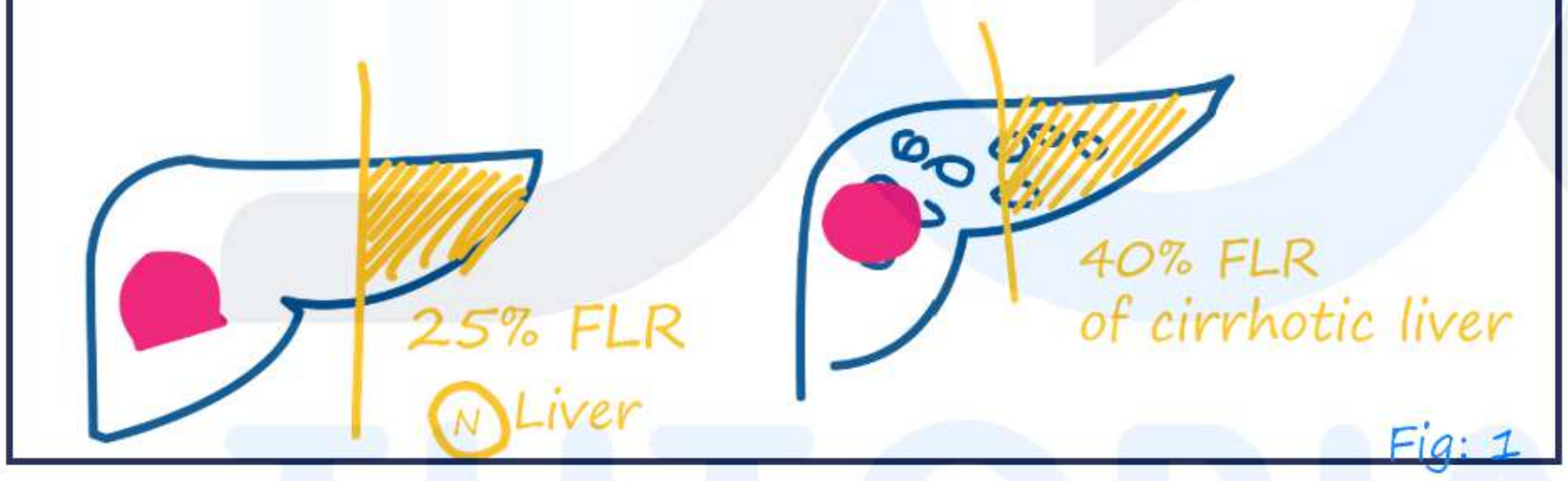

Fig: 1

Milan Criteria 00:47:24

- To do liver transplant for HCC patients
- Indications → single lesion < 5cm

  3 lesions (all are < 3cm)

  No extrahepatic spread

  Extended criteria says → Irrespective of Tumor size

  No extrahepatic spread

Ablation Techniques

Percutaneous infections

↓

1.Ethanol

↓

Single inj. (< 2cm)

Multiple inj. (2-5cm)

2.Acetic acid

↓

- More necrotizing ability
- More useful for septated tumors

Thermal ablation

↓

i. RFA

ii. Cyroablation

iii. Microwave ablation

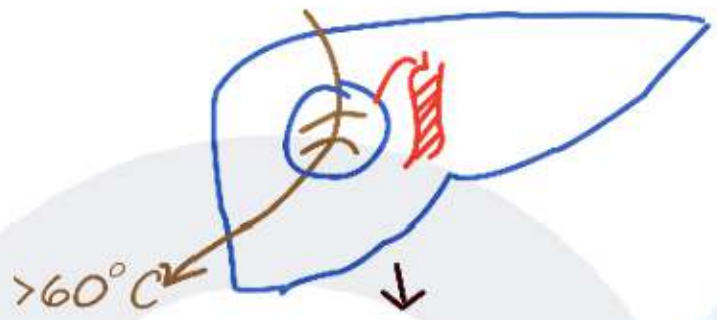

↓

RFA probes are inserted percutaneously into tumor by high temp (>60°C)

- Heat sink effect seen

↓

C/I near blood vessels

- RFA

↓

- Upto 7cm can be used
- Efficacy decreases >3cm

AfraTafreeh.com
TUTORIALS
LOGIN FOR SUCCESS

AfraTafreeh.com

TACE (Transarterial Chemoembolisation) 00:53:56

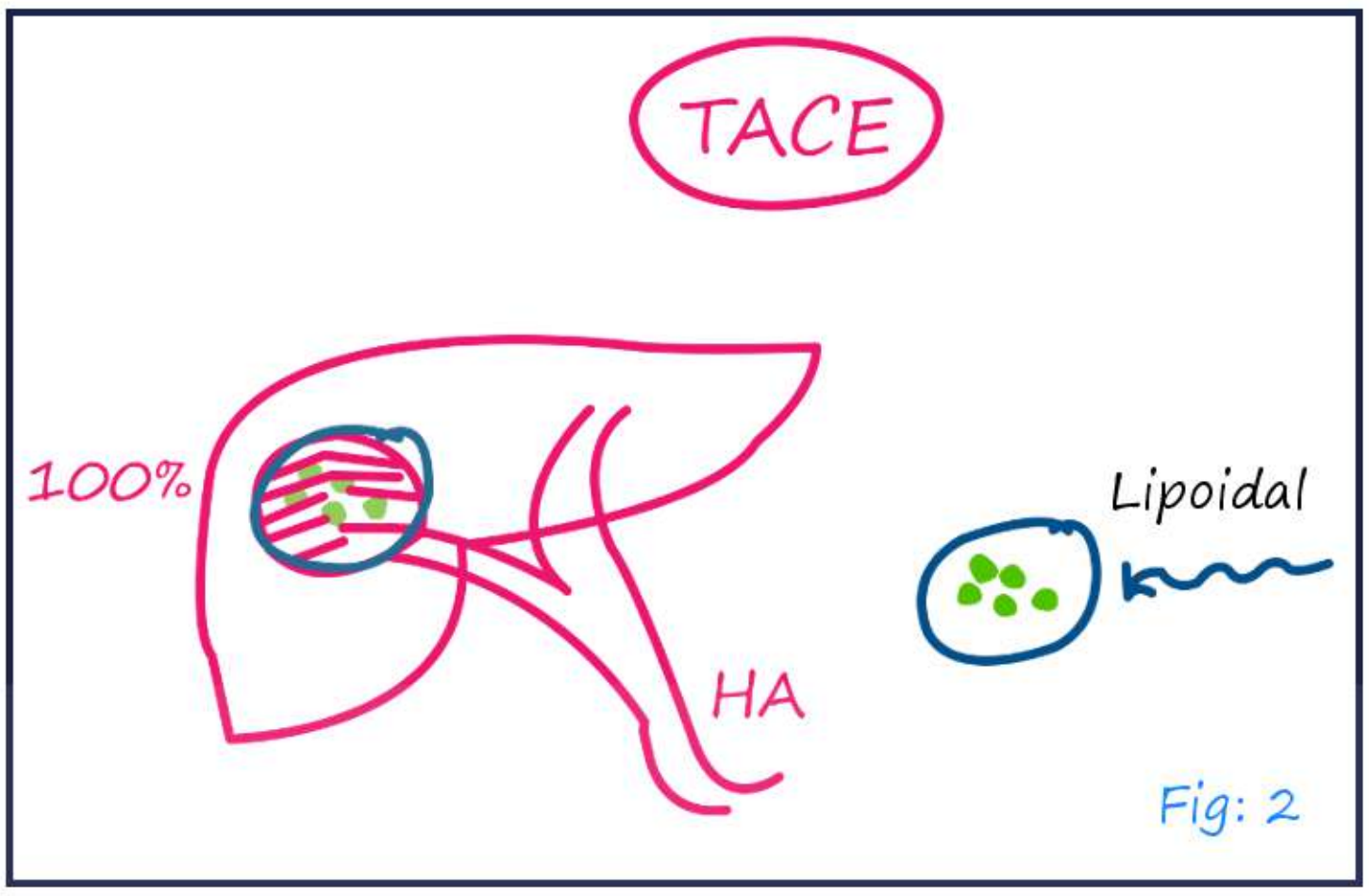

Fig: 2

- Tumors are receiving blood supply form one artery → Hepatic artery
- Chemotherapy particle along with lipoidal solution is injected through the artery and tumor destroyed.

- Prerequisites
  ↓
  - Adequate normal liver is needed (If no adequate liver → liver failure happens)

Portal Vein Embolization

↓

- If future remanent liver (FLR) is less

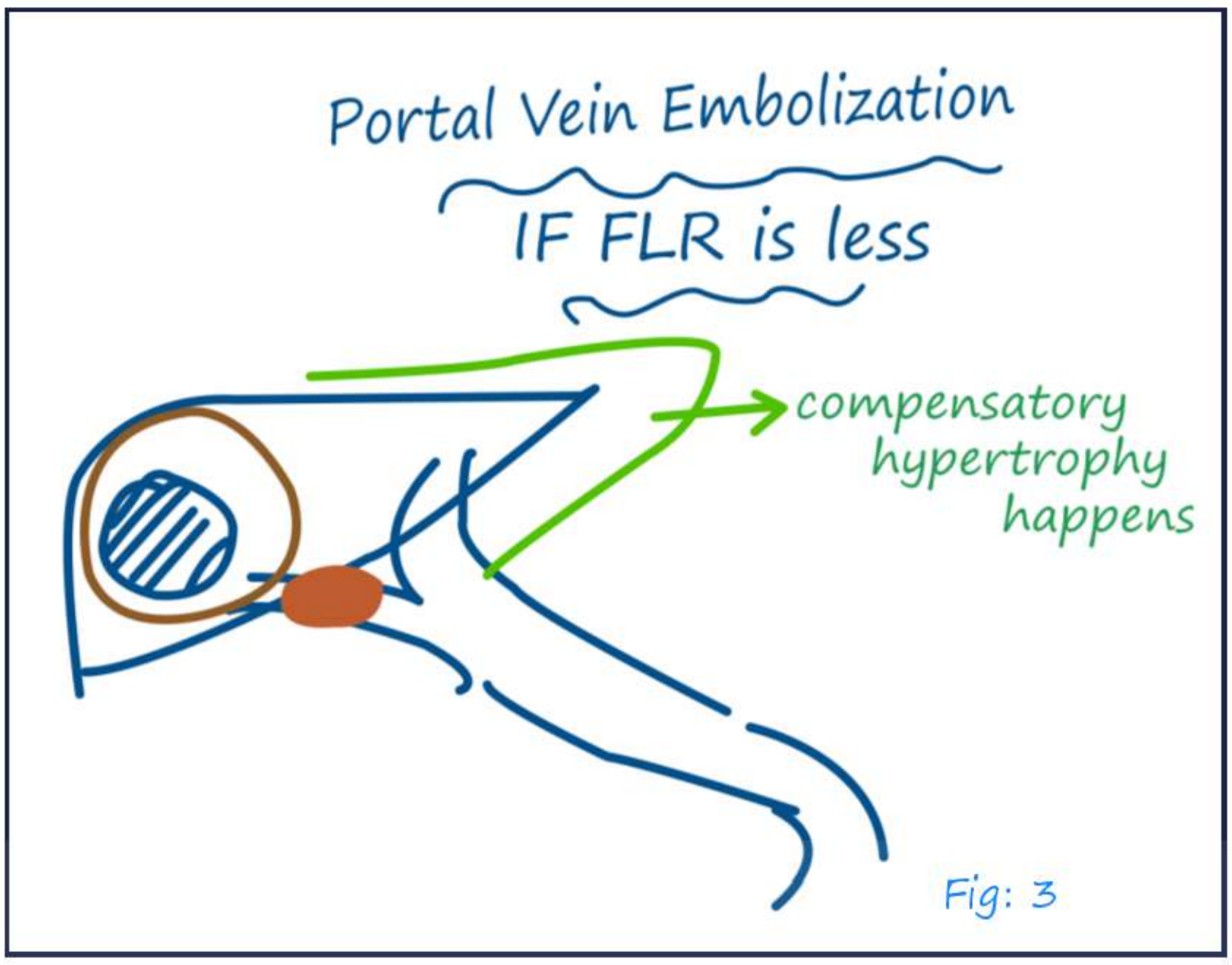

- Coil embolization of portal vein done 4 weeks before surgery

  ↓

  Shrinks tumor part of liver and remaining part compensatory hypertrophy happens.

AfraTafreeh.com

- TARE – Transarterial radioembolization also done for few cases.
- Inoperable/Metastatic HCC

  ↓

  Sorafenib → multikinase Inhibitor

  ↓

  i. Serine threonine inhibitor

  ii. VEGF threonine inhibitor

  iii. TK threonine inhibitor

  iv. PDGF threonine inhibitor

  (Platelet derived growth factor)

AfraTafreeh.com

Extra edge

- Tumor can grow into hepatic artery and portal vein
- Portal vein invasion carries bad prognosis
- 10-20% resectable

Fibrolamellar HCC ↓	HCC ↓
• M=F (Females increase incidence)	• Most common in males
• Young age	• Old age
• HBV & HCV <5%	• HBsAg ⊕, HCV ⊕
• Alcohol <5%	• Alcohol +++
• Neurotensin B increases	• AFP increases
• Central scar	• CECT – rapid enhancement of contrast and rapid washout
• No cirrhosis	• Cirrhosis ⊕
• Good prognosis most resectable	

TUTORIALS LOGIN FOR SUCCESS

Metastasis in Liver 01:02:06

- Most common 1° from colorectal cancers
- Outside GIT, most common from breast

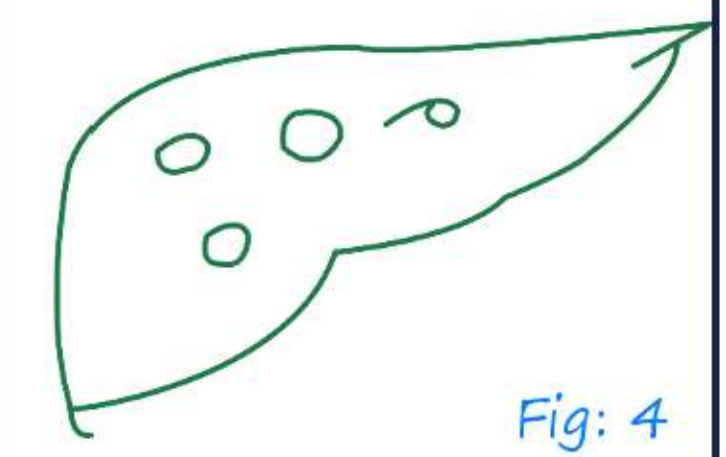
Fig: 4

- Best prognosis seen with neuroendocrine mets.
- 2nd best prognosis seen with – colorectal mets
- Better prognosis – Genitourinary mets
- Stomach, Breast, Lung Ca, Melanomas, Sarcomas – Bad prognosis

Types of Mets

Hypovascular (Hypodense)	**Hypervascular (Hyperdense)**
↓	↓
– Detected on portal venous phase of liver	– Detected on arterial phase
↓	↓
– GIT primaries	1.RCC
– Lung primaries	2.Thyroid cancer
– Breast primaries	3.NET: Insulinomas, Carcinoids
– Head & Neck primaries	4.Sarcomas
	5.Breast cancer
	6.Melanomas

AfraTafreeh.com
DOCTUTORIALS LOGIN FOR SUCCESS

- Colorectal cancer with liver secondaries

  ↓

  Operate

  ↓

AfraTafreeh.com

Treatment resection

- Neuroendocrine with liver 2°

↓

R_1/R_2 Debulking positive margin

↓

Microscopical positive margin

R_2 – macroscopical positive margin

- **Fong's Clinical Score** – outcome of liver mets

i. Size of tumor >5cm

ii. Disease free interval < 1 year

iii. More than 1 tumor

iv. CEA > 200 mg/dl

v. LN positive primary

All 5 positive – 22 months
1 positive – 51 months

Cystic Tumors 01:10:53

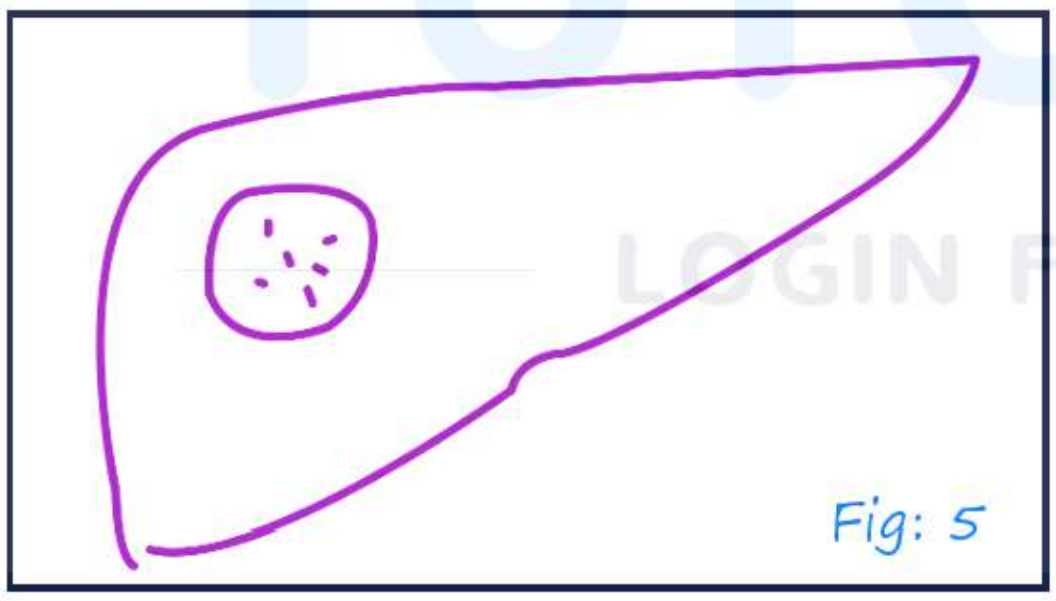

Fig: 5

- Simple cysts
  - Laparascopic deroofing (fenestration operation)
  - No risk of malignancy

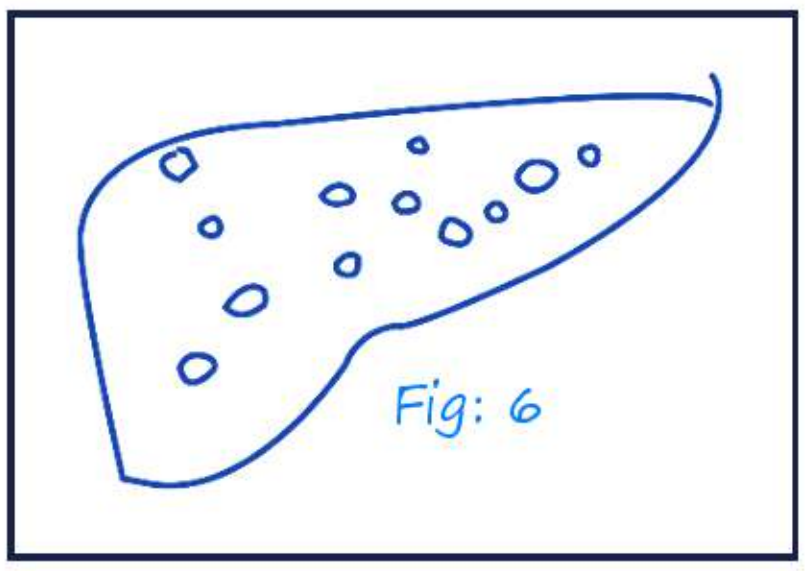
Fig: 6

- Polycystic liver disease → associated with PCKD

  Treatment – Symptomatic cases
  - Major problem – renal failure
  - Never develop liver failure
  - Laparoscopic deroofing of selective cyst done → can develop ascites

Biliary Cystadenoma

- Septal walls will enhance on contrast

AfraTafreeh.com


Fig: 7

TUTORIALS LOGIN FOR SUCCESS

- Can go for malignancy

AfraTafreeh.com

CT scan Hepatic adenoma – early enhancement

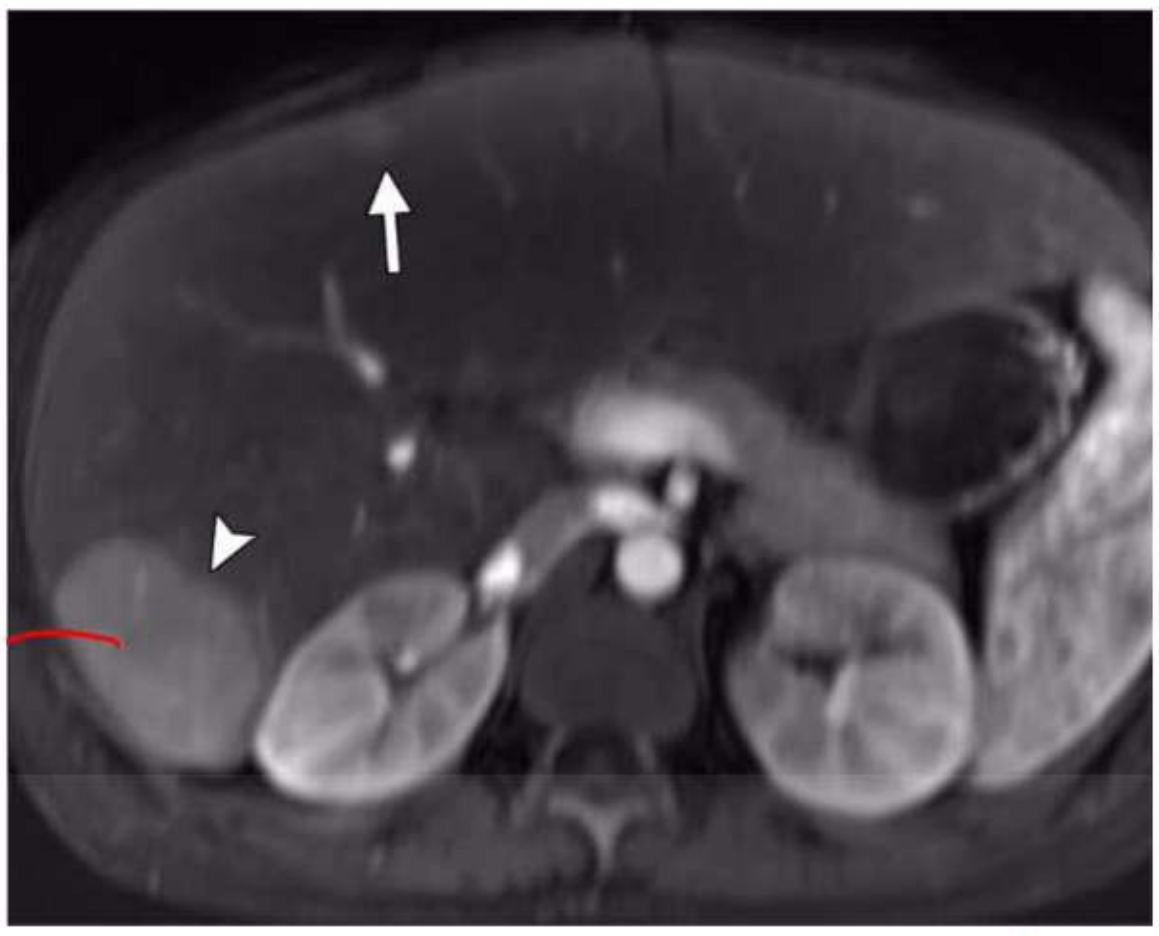

Fig: 8

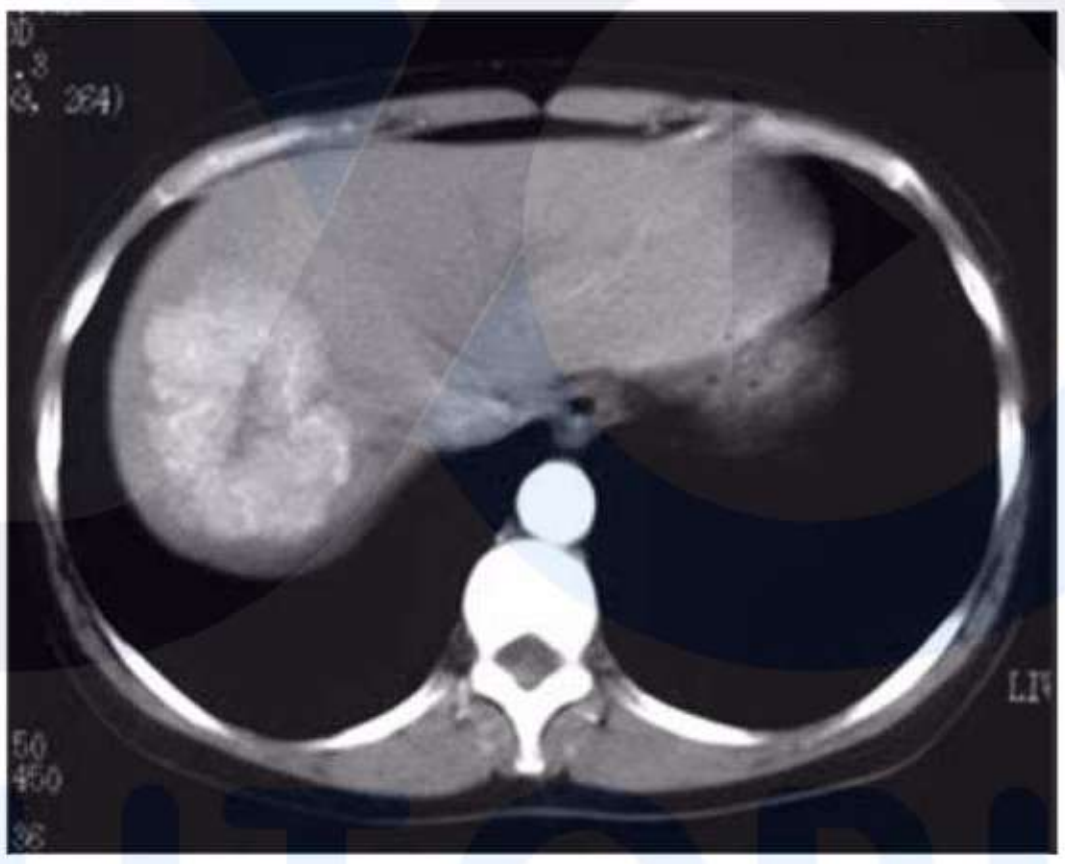

Focal Nodular Hyperplasia Fig: 9

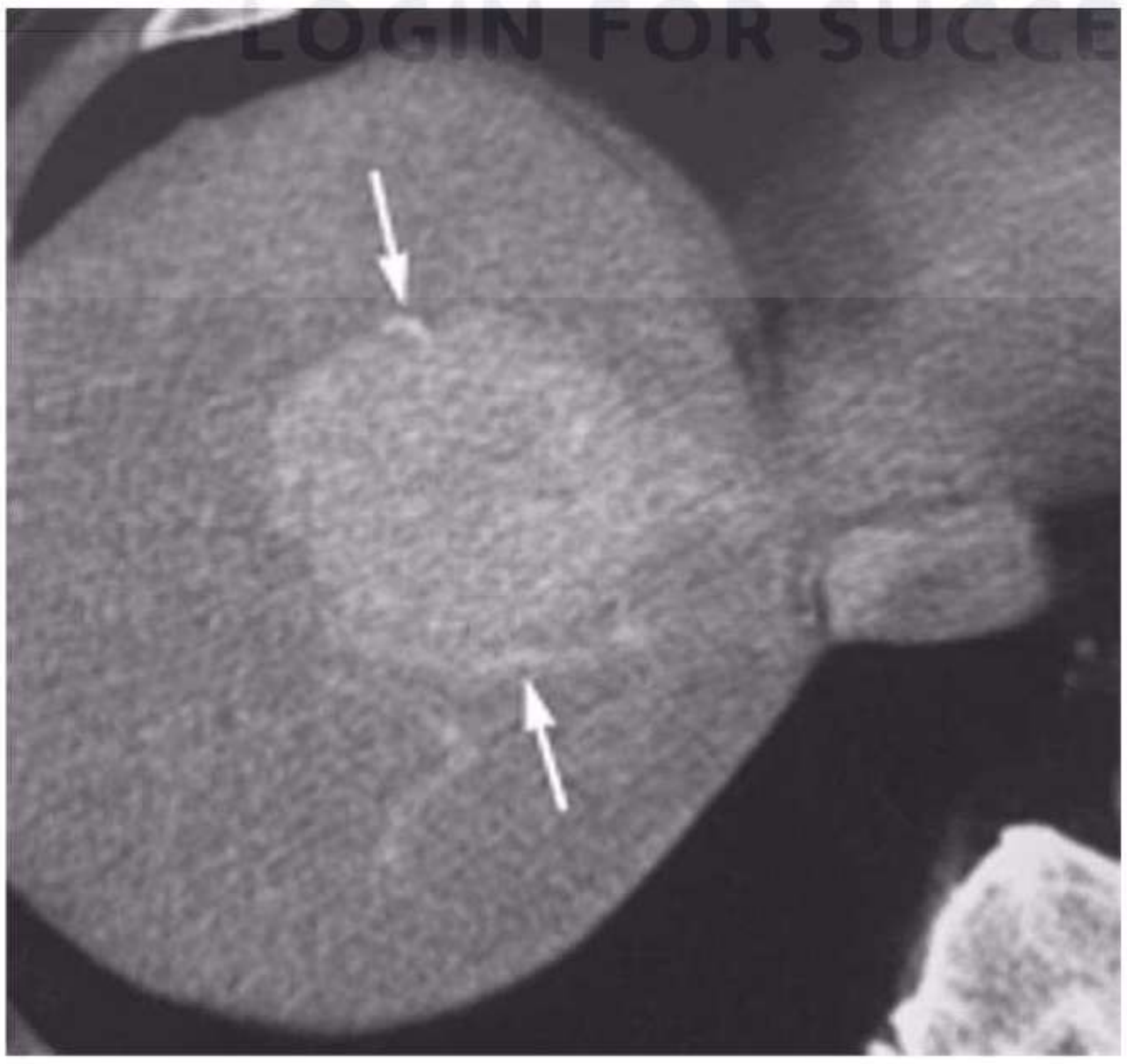

Fig: 10

TUTORIALS
LOGIN FOR SUCCESS

PORTAL HYPERTENSION

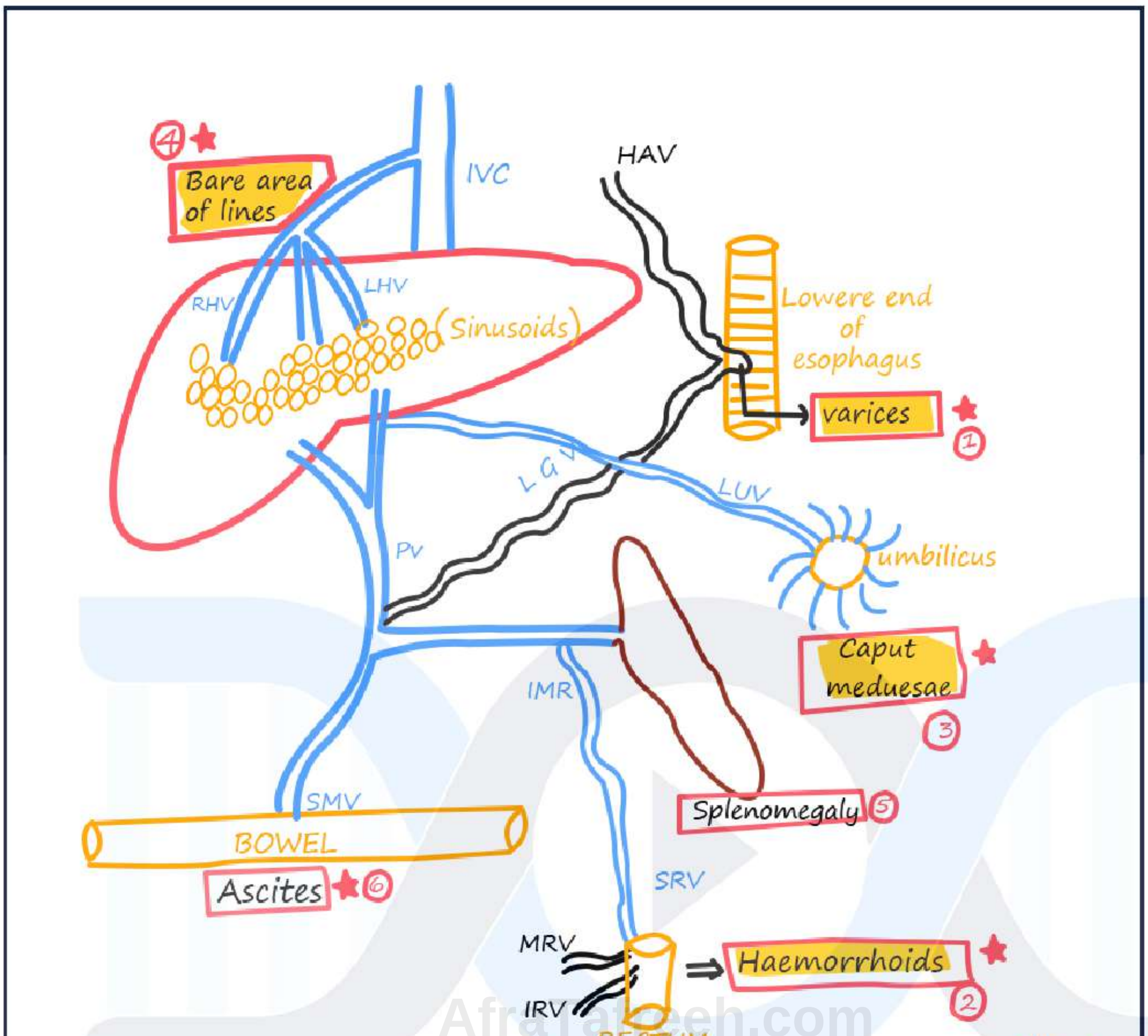

Fig: 1

AfraTafreeh.com

- Portal vein length – 5-8 cm
- Portal vein pressure – 5-8 mmHg
- Superior mesenteric vein brings blood from bowel
- Portal vein divides into multiple branches and they all will now drain into hepatic vein → IVC → Heart
- If portal pressure > 10mmHg – Portal HTN
  > 12 mmHg – Collaterals open up (varices)
- 80% supply is through portal vein.

AfraTafreeh.com

Collaterals between portal vein and systemic vein

00:03:49

i. Collaterals at bifurcation of PV and SV joins with azygous vein hear lower end of esophagus → varices

ii. Inferior mesenteric vein continues as superior mesenteric vein
↓
Form collaterals with middle rectal vein & inferior rectal vein → Hemorrhoids

iii. Left umbilical vein forms collaterals around umbilicus known as caput medusae

iv. Bare area of liver

v. Retroperitoneum

- Other problems in portal HTN
  ↓
  i. Splenomegaly
  ii. Ascites

DOT TUTORIALS
LOGIN FOR SUCCESS

Etiology 00:08:31

- Most common cause: cirrhosis of liver

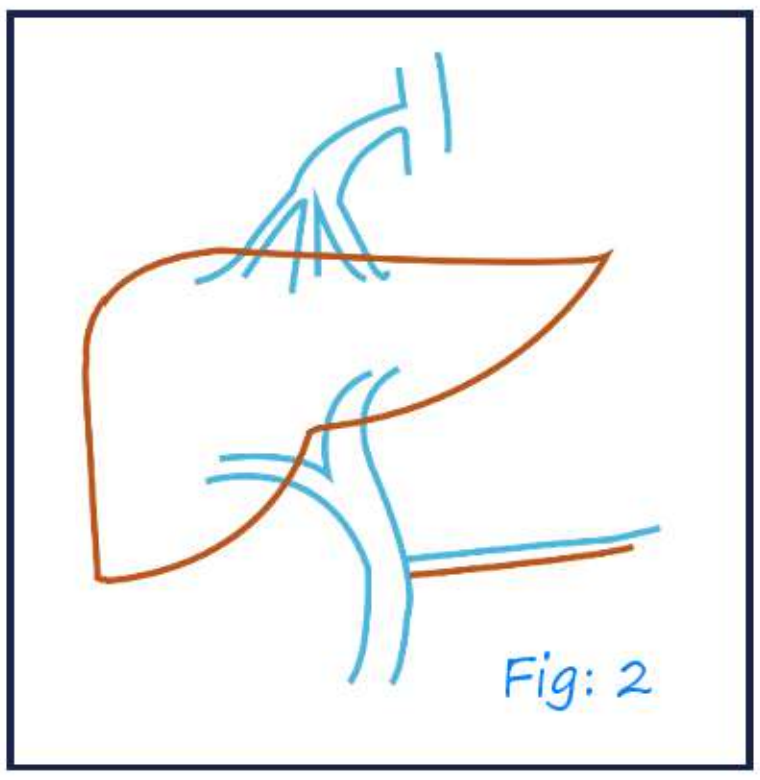

Fig: 2

- Intrahepatic causes
  - Presinusoidal ↓
    - Schistosomiasis
    - Non cirrhotic portal fibrosis (NCPF)
  - Sinusoidal ↓
    - Cirrhosis
  - Post sinusoidal ↓
    - Veno occlusive disease
    - Sublobular venules affected

- Prehepatic causes ↓

  i. Extrahepatic portal vein obstruction (obstruction of main portal vein or 1st order branch)

  ii. Sinistral (left sided portal HTN) → SV thrombosis

AiraTahreen.com
TUTORIALS
LOGIN FOR SUCCESS

- Post hepatic causes ↓
  - Budd Chiari syndrome
  - HV thrombosis
  - IVC web

Complications 00:13:59

i. Hematemesis (GI bleed) → 2nd most common cause of death

ii. Liver failure → most common cause of death

AfraTafreeh.com

iii. Hepatopulmonary syndrome

iv. Porto pulmonary HTN.

v. Hypersplenism

vi. Ascites

- Most common cause of hematemesis → rupture of varices

Hepatopulmonary syndrome	Porto-pulmonary HTN
↓ Vasodilation ↓ - Hypoxia - Platypnea - IOC – Echo - Treatment of choice ↓ Liver transplant	↓ Vasoconstriction ↓ Pulmonary artery pressure >25mmHg - IOC: PCWP(pulmonary capillary wedge pressure) ↓ Portal pressure increases, pulmonary Pr. >50mmHg ↓ Liver transplant is C/I - Liver transplant should be done earlier - Bad prognosis

TUTORIALS
LOGIN FOR SUCCESS

- C/I for TIPS → Hepatopulmonary syndrome
  → Porto pulmonary HTN

Protocol in portal HTN with Variceal bleed

80% other causes	20% variceal
↓	↓
Most common – duodenal ulcer	i. Most common cause – Esophageal varices ii. Gastric Varices iii. Portal hypertensive gastropathy

- Variceal bleed starts when portal pressure >12 mmHg

AfraTafreeh.com

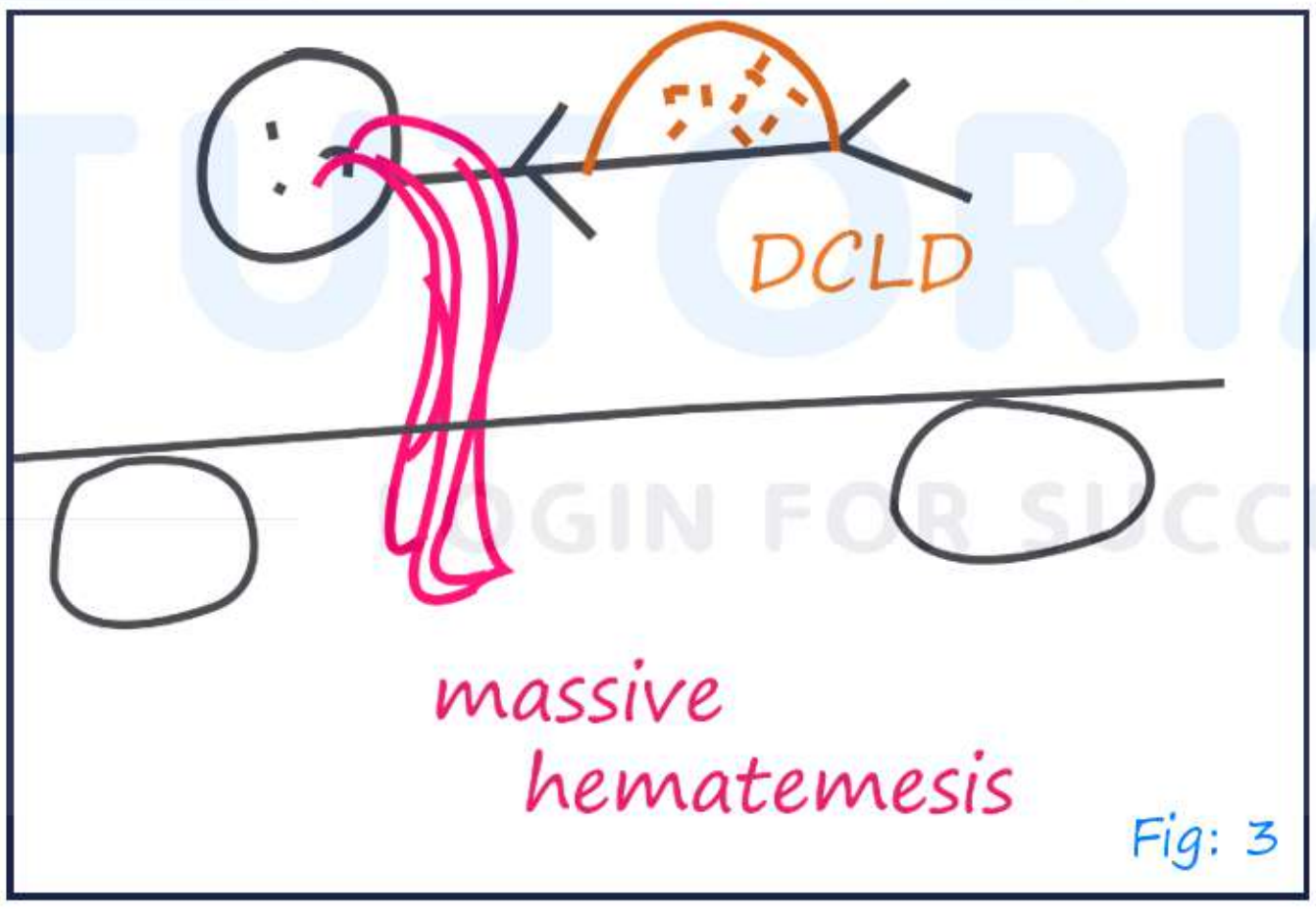

Fig: 3

- DCLD patient with ascites presents with massive hematemesis
  ↓
  i. IV fluids
  ii. Ryles tube decompression
  iii. Inj. Pantoprazole

AfraTafreeh.com

- DOC – Octreotide (Somatostatin analogue)
- Others
  - Terlipressin
  - Vasopressin

  ] + NTG also given to prevent vasoconstriction of heart

If Bleeding not stopped

↓

<table>
<tr>
<td>Sengstaken Blakemore
↓

• Made of rubber
• 3 lumen & 2 balloon
↓
– Aspirate from stomach
– Inflate esophageal balloon
– Inflate gastric balloon</td>
<td>Minnesota tube
(modified SB tube)
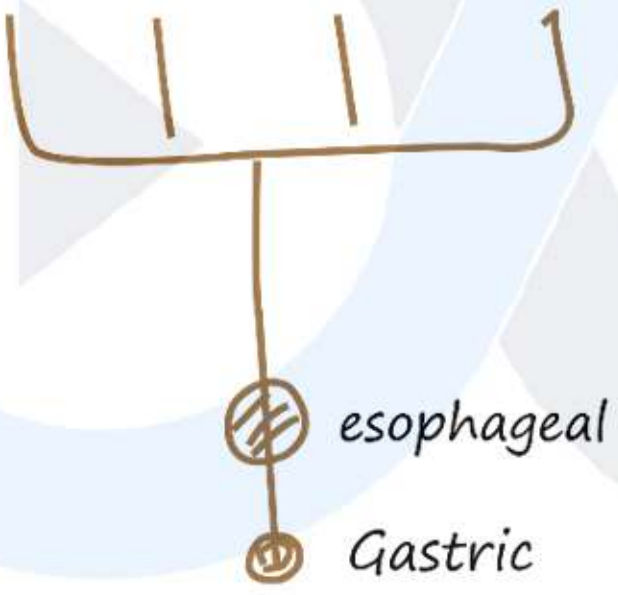

– Made of rubber
– 4 lumen & 2 balloon
↓
4th → Aspirate from esophagus</td>
</tr>
</table>

- Linton tube
  - 3 lumen with 1 balloon
  - Not available

Steps

i. Inserted through the mouth

ii. Inflate gastric balloon – 300ml of air

iii. Fix the tube @ mouth

iv. Inflate esophageal balloon – until 40mmHg of air

v. Leave the tube only for 12 hours

↓

Refer to MGE

- If tube retained for > 12 hours → esophageal necrosis/perforation

↓

Refer to MGE

↓

Gold standard – Endoscopic banding (Best)

AfraTafreeh.com
TUTORIALS
LOGIN FOR SUCCESS

Endoscopic sclerotherapy using STD

Gastric varices → Cyanoacrylate glue

↓

Interventional radiologist

↓

TIPSS – Transjugular Intrahepatic Porto-systemic Shunt

↓

- Through IJV enter SVC → right atrium → IVC

AfraTafreeh.com

↓

Hepatic vein

↓

Portal vein

- Pass a stent which will be kept between the hepatic vein and portal vein

  ↓

  stent made PTGE (poly tetra fluoro ethylene)

- Stenting done by VIATOR device
- DIPS → Direct Intrahepatic porta shunt

  ↓

  Stent b/w IVC and portal vein

Complications of TIPSS

- Immediate (early) → capsular rupture and bleeding
- <1 month → Hepatic encephalopathy (non-selective shunt)
- Shunt thrombosis: <1 month
- Shunt stenosis: most common around 1 year

  ↓

  - Restenting
  - Dilatation
  - Liver transplantation
- TIPSS – Bridging procedure for liver transplant

C/I of TIPSS

Absolute ↓

Relative ↓

LOGIN FOR SUCCESS

i. Right heart failure
ii. Polycystic liver d/s
iii. HPS
iv. PPH

i. Postal vein thrombosis
ii. Encephalopathy
iii. Liver tumors

- Ascites decreases / Variceal bleed stops → Use of TIPSS

Surgical shunt

Non selective	Selective
↓	↓
Entire blood bypasses the liver	Only blood from SMV enters liver
↓	↓
Encephalopathy	Ascites

AfraTafreeh.com
TUTORIALS
LOGIN FOR SUCCESS

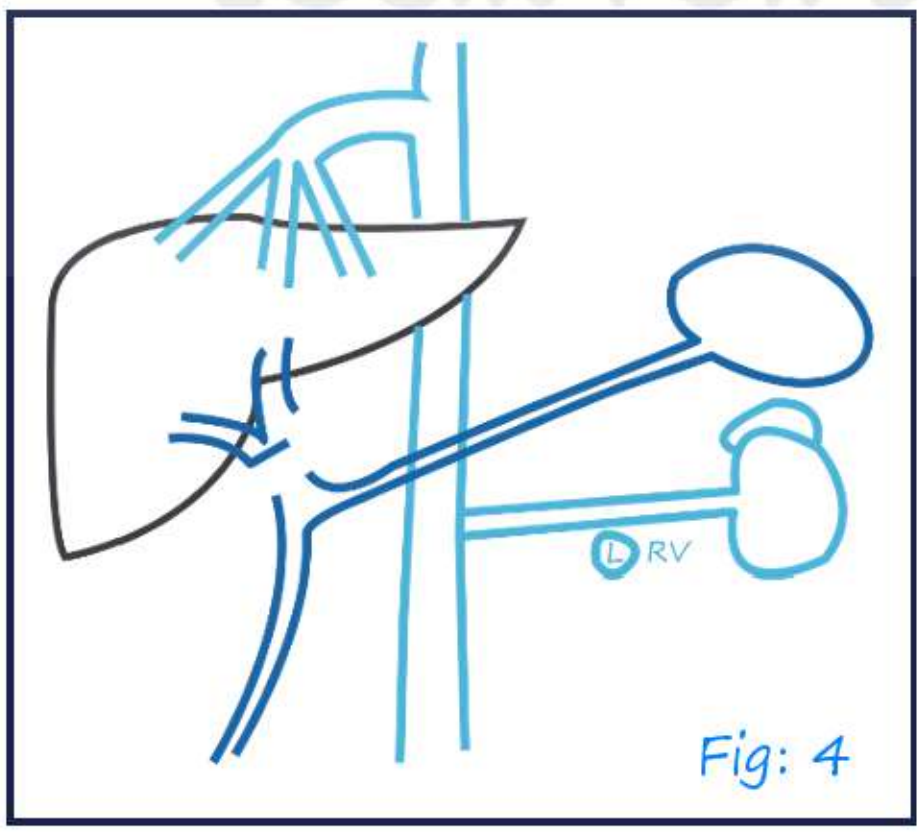

Fig: 4

Non-Selective shunt

i. End – End portocaval shunt (Eck's fistula)

AfraTafreeh.com

ii. Side – Side portocaval

iii. Inter position shunt (16mm stent)

iv. TIPSS

v. LINTON (Conventional, proximal splenorenal shunt)

↓

Distal splenic vein with spleen cut

↓

Proximal splenic vein connected to renal vein

- Splenectomy done in Linton shunt

Selective shunt

i. DSRS – Distal Spleno renal shunt – Warren's shunt

↓

Distal part of splenic vein anast with renal vein

ii. INOKUCHI SHUNT

↓

Anastamose left gastric vein directly to IVC.

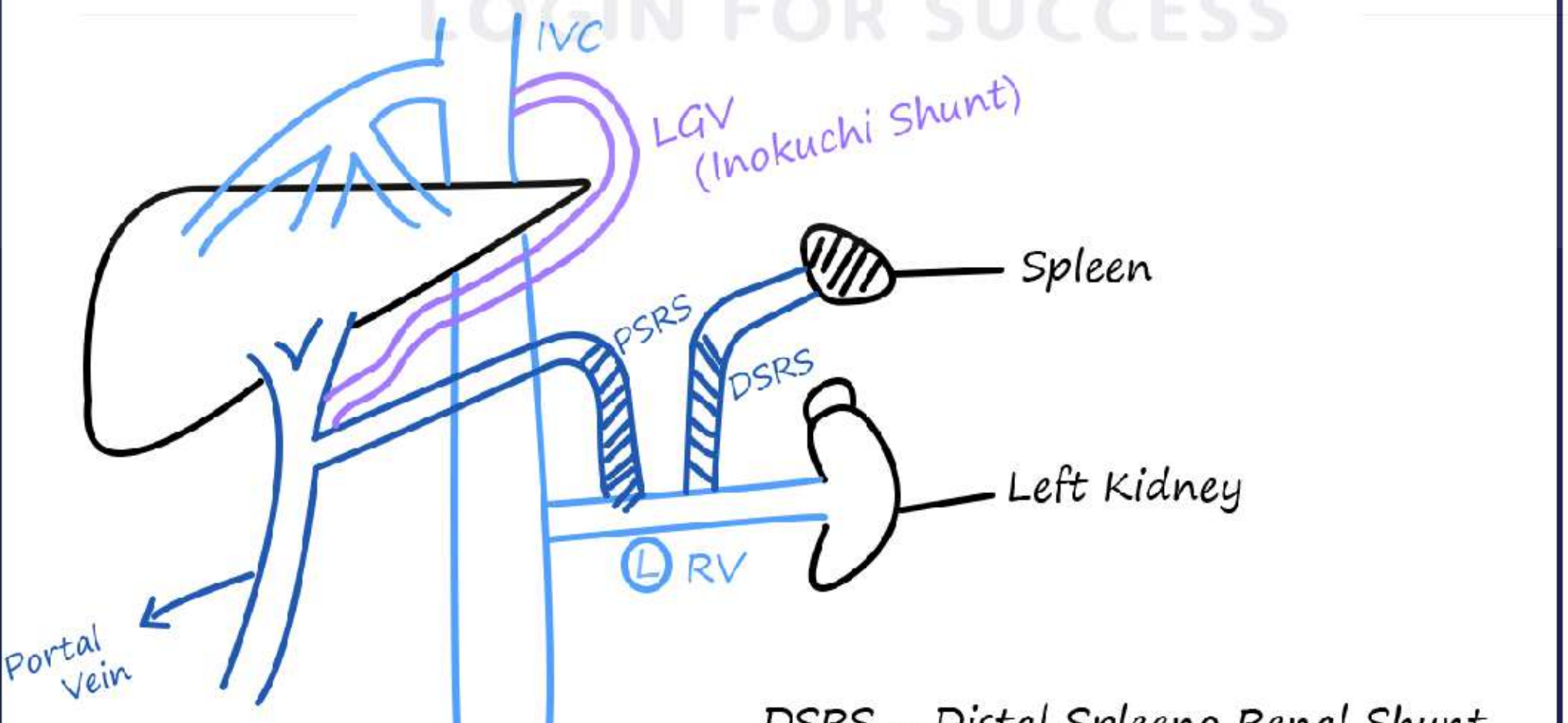

DSRS – Distal Spleeno Renal Shunt

PSRS – Proximal Spleeno Renal Shunt

Fig: 6

C/I for shunt operation

i. Splenic vein thrombosis

ii. SMV thrombosis

iii. Splanchnic vein thrombosis

Devascularisation procedures

↓

SUGUIRA Operation

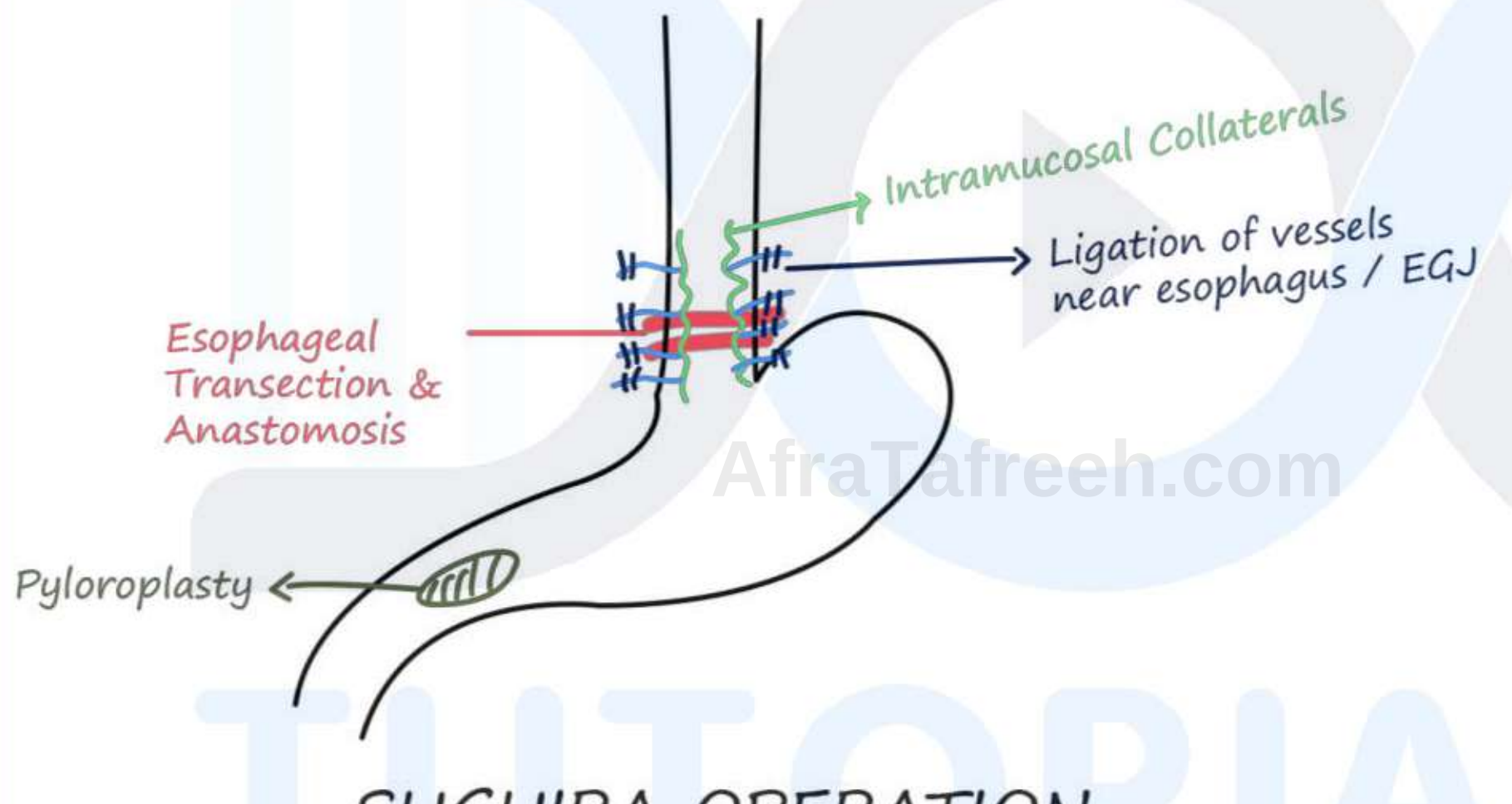

Fig: 7

AfraTafreeh.com
DOC TUTORIALS
LOGIN FOR SUCCESS

i. Ligation of veins near esophagus/EGJ

ii. Vagotomy

iii. Esophageal transection and anastomosis

iv. Splenectomy

v. Pyloroplasty

- **Liver transplant** → Replaced shunt operation ⎤ surgeries
  ↓ Devascularisation ⎦

  Gold standard & of portal HTN

AfraTafreeh.com

Sinistral (L-sided) portal HTN 00:56:24

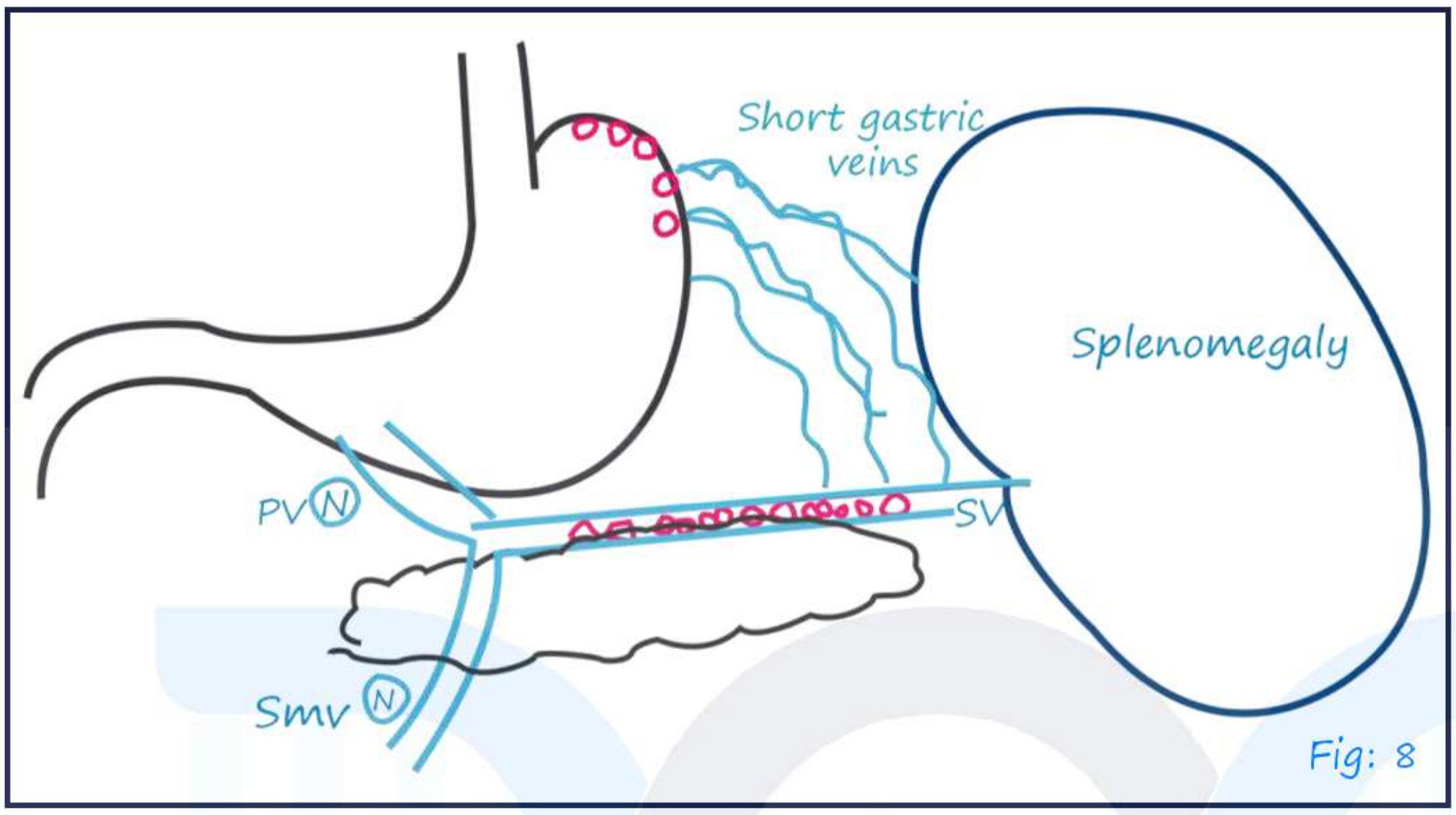

Fig: 8

- Portal vein and superior mesenteric vein Ⓝ
- Splenic vein developed thrombosis

  ↓

  - Splenomegaly
  - Short gastric veins dialted & forms collaterals over stomach

- Clinical features – Isolated gastric varies

  Splenomegaly
- Most common cause SV thrombosis → chronic alcoholic pancreatitis
- Treatment – splenectomy (TOC)

Non cirrhotic portal fibrosis (NCPF)

↓

- Obstruction @ $2^{nd}/3^{rd}$ order portal vein branches
- 20-40 yrs
- Normal growth

Extra hepatic portal vein obstruction (EHPVO)

↓

- Thrombus in main portal vein or first order portal vein.
- Umbilical sepsis
- <10 years
- Stunted/retarded growth

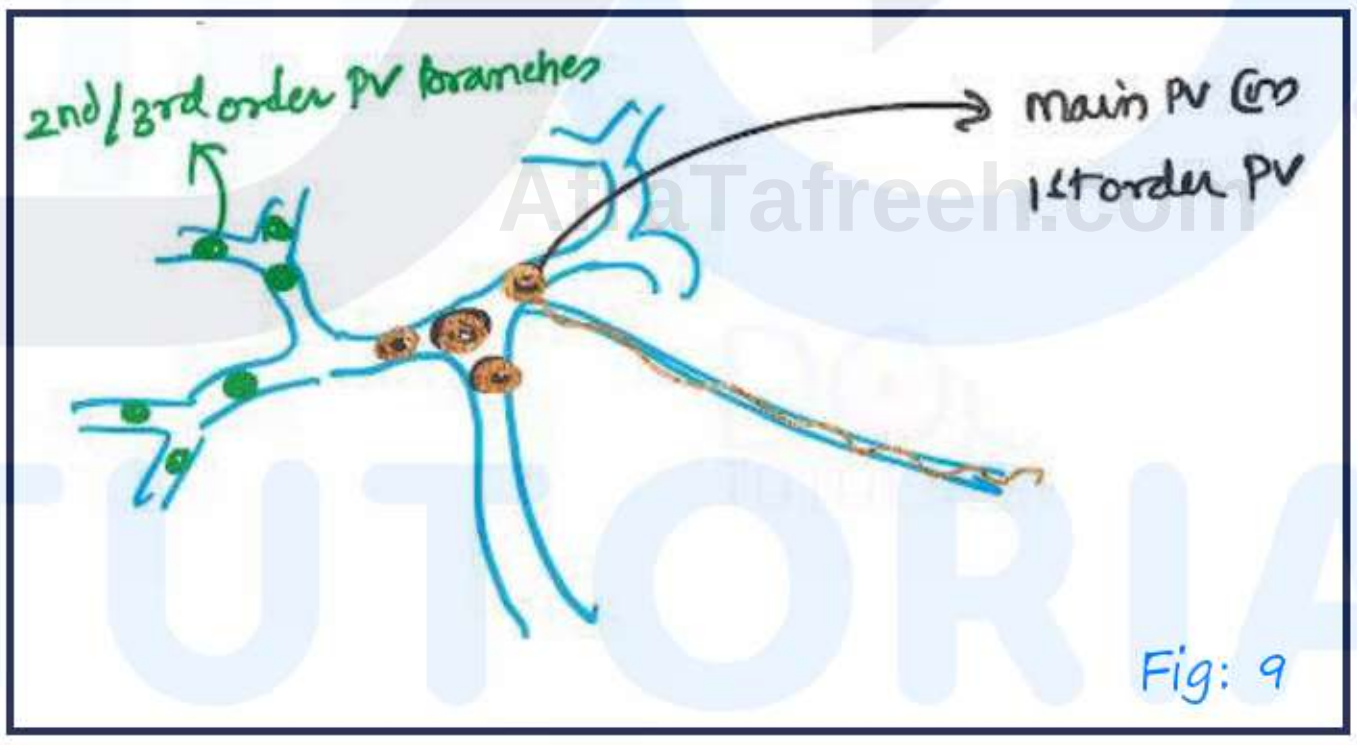

Fig: 9

- Liver is Normal
- LFT is Normal
- No ascites
- Splenomegaly ++ (more in NCPF)
- EG varices ++

↓

Most common presentation – Hematemesis

- No risk of encephalopathy

AfraTafreeh.com

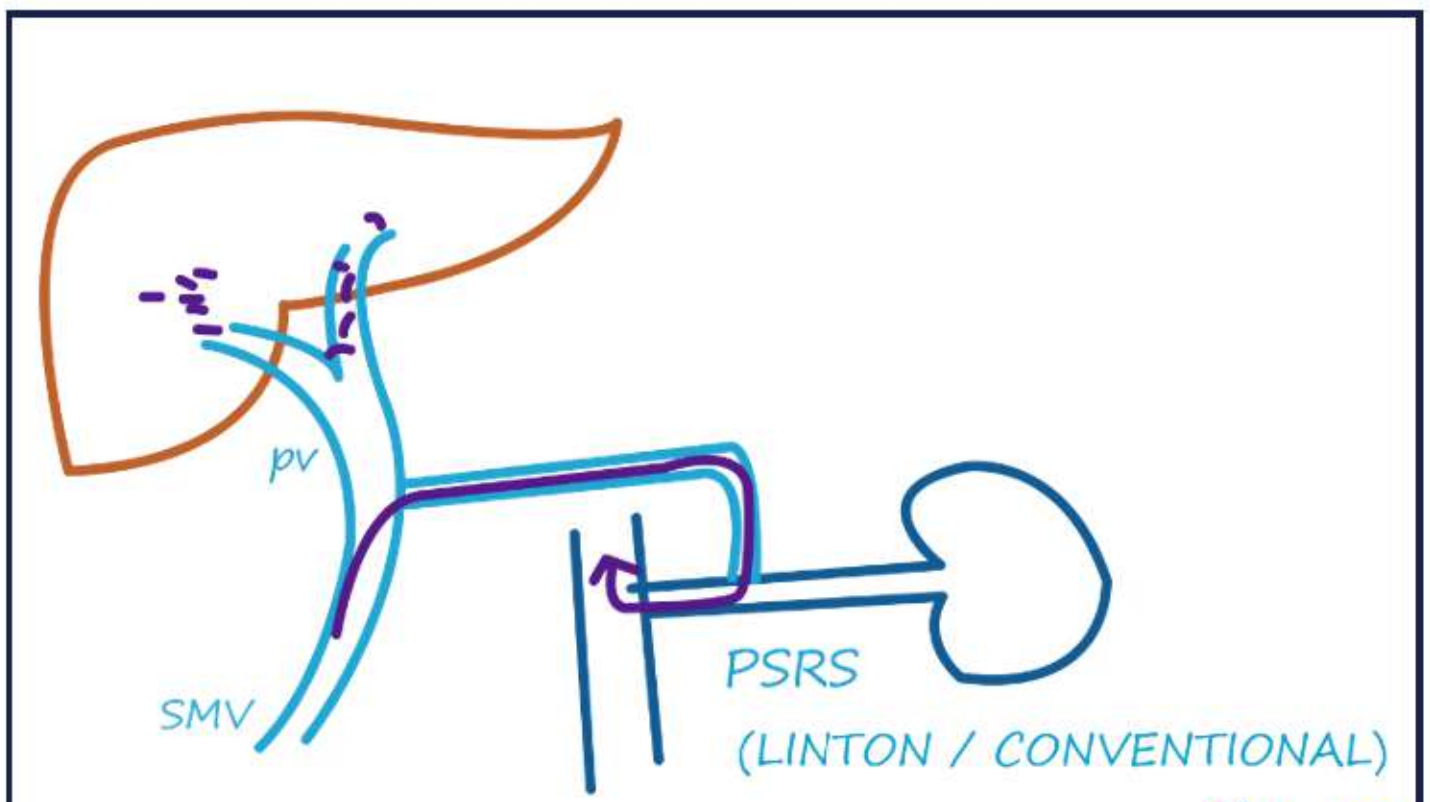

Fig: 10

- Treatment – PSRS/Linton shunt

REX shunt → Pediatric

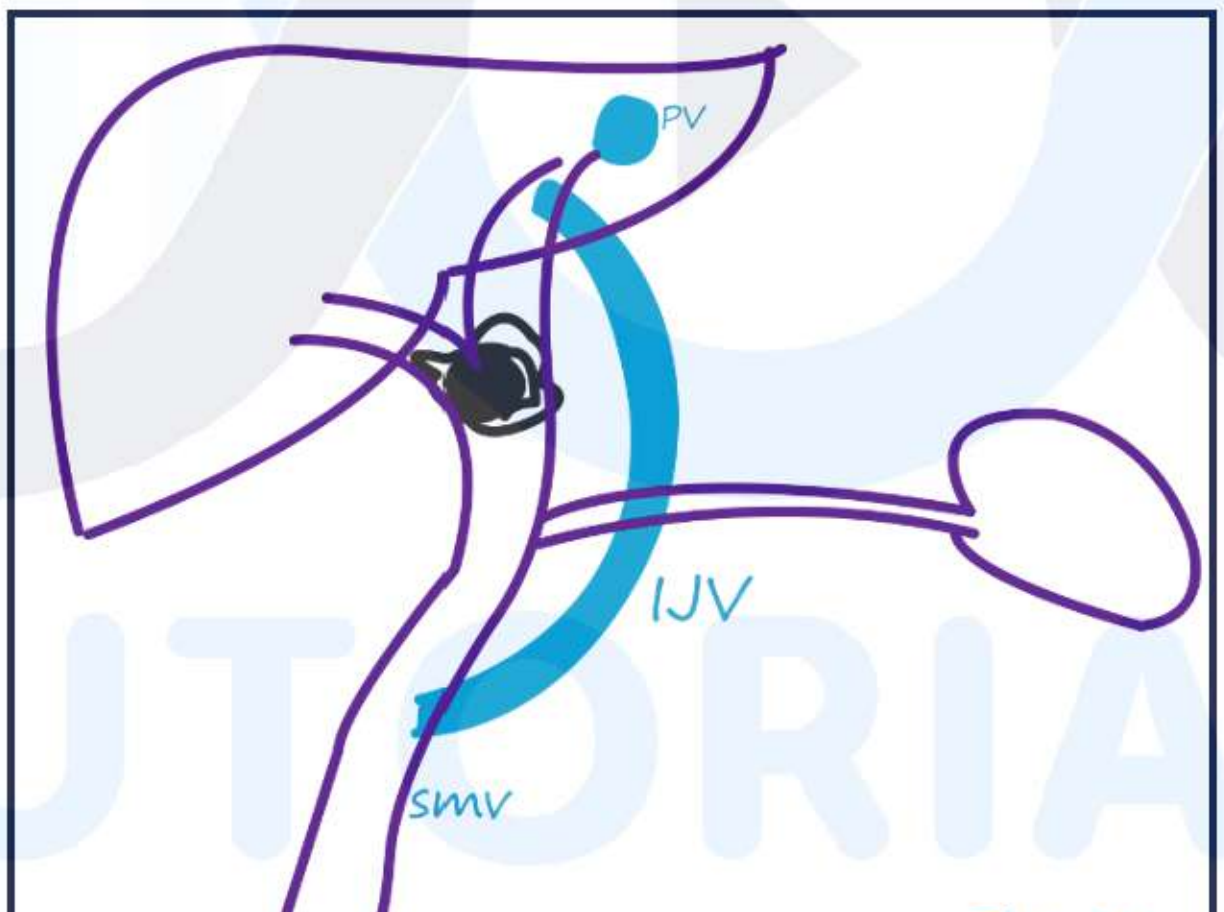

Fig: 11

- Cut IJV and anastomose IJV from SMV to left PV
- Physiological shunt
- Indicated in EMPVO – children

Veno occlusive disease

↓

- Sublobular venules are thrombosed
- Most common etiology: Bone Marrow transplant

Pyrozolidine alkaloids

Azathioprine

- Doc – Defibrotide
- IOC – Hepatic vein wedge pressure increases
- Venography – HV / IVC is normal

Budd chiari syndrome 01:09:51

- Causes – Hepatic vein thrombosis (western)
  IVC membranal webs (Indian)
  - Most common cause of thrombosis – polycythemia vera
  - In India – congenital webs
- Clinical features – In congenital webs
  ↓
  Multiple collaterals seen on abdominal wall running from below upwards (HARVEY's SIGN)
- Investigations

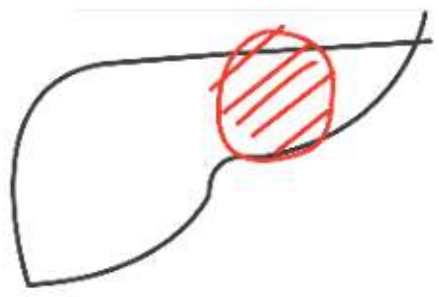

CECT Abdomen is IOC
→ Caudate lobe enlarged → Hot spot

Hepatic venograpy
↓
Spider web appearance

AfraTafreeh.com

- Treatment

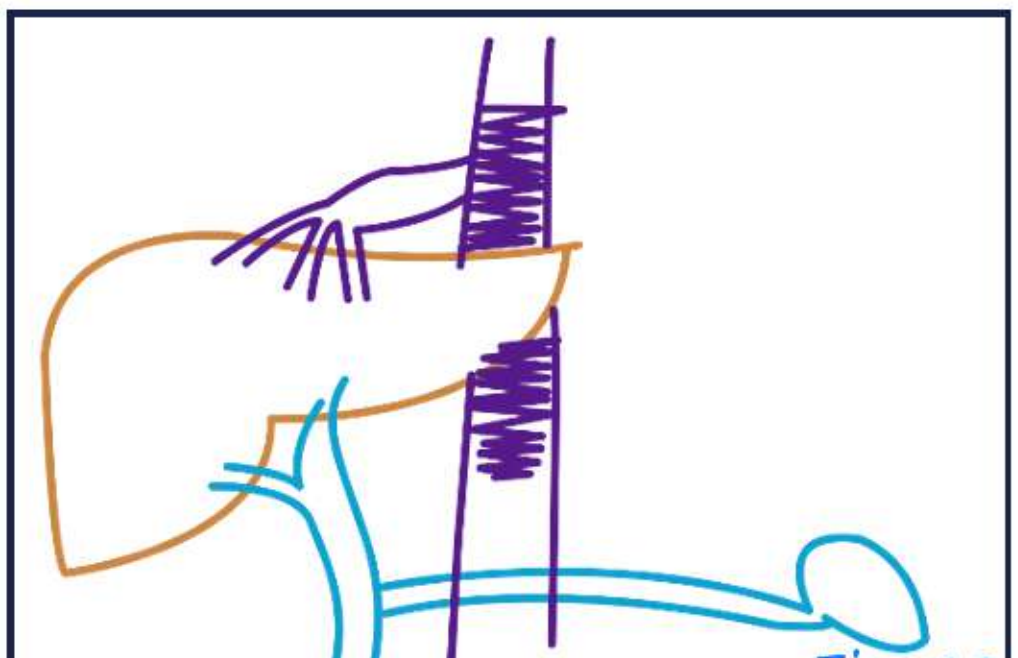

Fig: 12

- Normal liver, IVC web → Intracaval stent

→ If stent is not possible

↓

1. Shunt b/w PV and IVC (side – side portocaval shunt)
2. Cavo-atrial shunt with prosthesis (IVC – atrium)

- Hepatic vein thrombosis → Side to side portocaval shunt is enough
- Liver cirrhotic → liver transplant

↓

Ascites ⊕

LFT abnormal

USG – cirrhosis of liver

SPLEEN



Fig: 1

- Weight of spleen – 250g
- Spleen develops from dorsal mesogastrium
- Lying parallel to 9,10,11 rib
- Usually spleen not palpable, in children, it is palpable
- Largest lymphoid tissue

AfraTafreeh.com

Attachments of spleen 00:01:49

TUTORIALS
LOGIN FOR SUCCESS

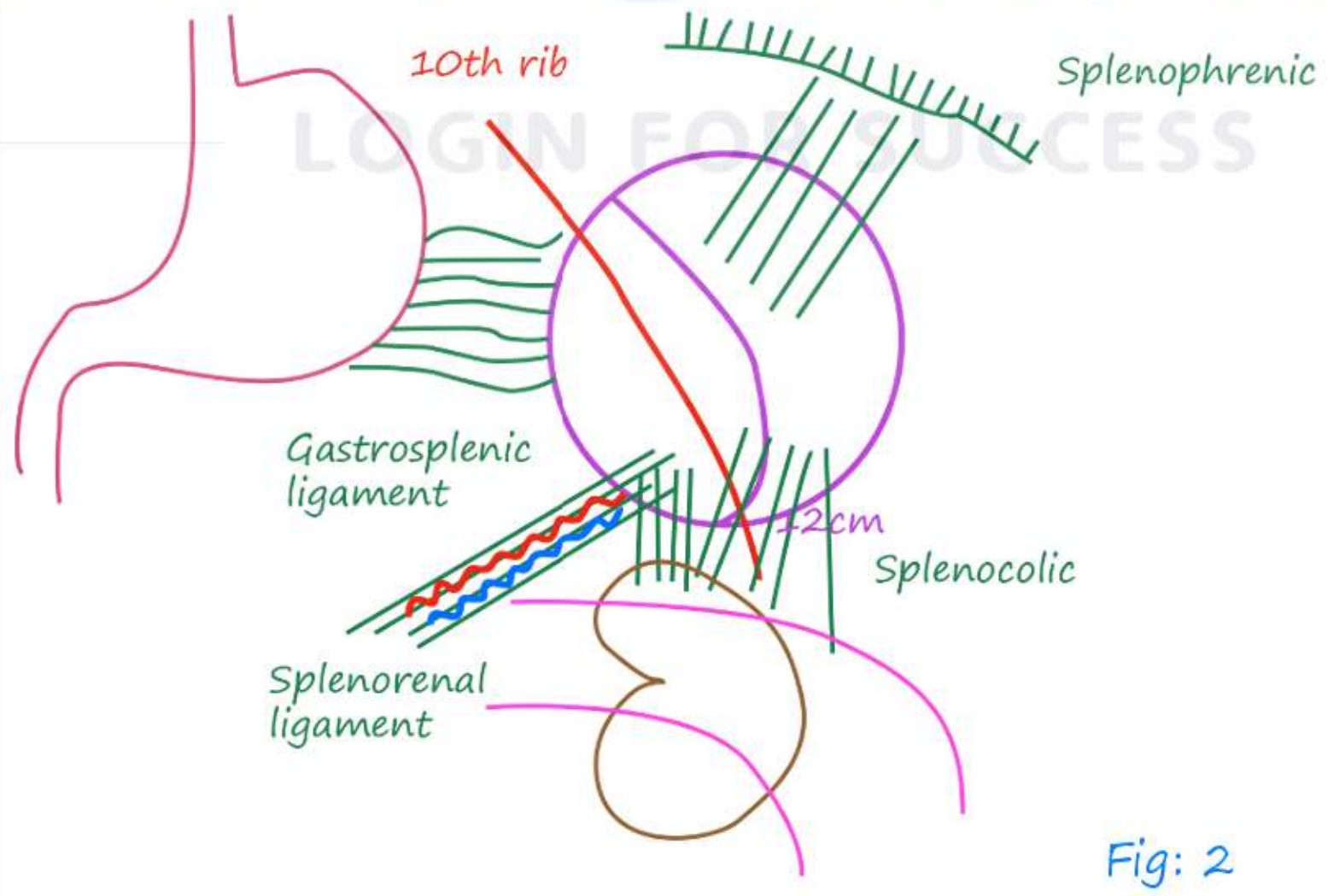

Fig: 2

- 12cm long, 7 cm wide and 3cm thickness
- Long axis lies exactly on 10th rib

AfraTafreeh.com

- Ligaments
  - Attaching spleen and diaphragm → splenophrenic ligament
  - Attaching spleen and colonic flexure → splenocolic ligament
  - Attaching spleen and stomach → gastrosplenic ligament
  - Attaching spleen and kidney → splenorenal ligament

- Splenic artery and splenic vein run over splenorenal ligament
- Splenophrenic ligament, Splenocolic ligament] Avascular ligaments
- Gastrosplenic ligament carries short gastric artery

Q. First ligament cut in emergency splenectomy – splenorenal ligament

Q. In elective open splenectomy → Gastrosplenic vessels are ligated

Q. Elective lap. splenectomy → splenocolic, splenophrenic] ligaments

- In 30% of cases, tail of pancreas touches the spleen

DOT TUTORIALS LOGIN FOR SUCCESS

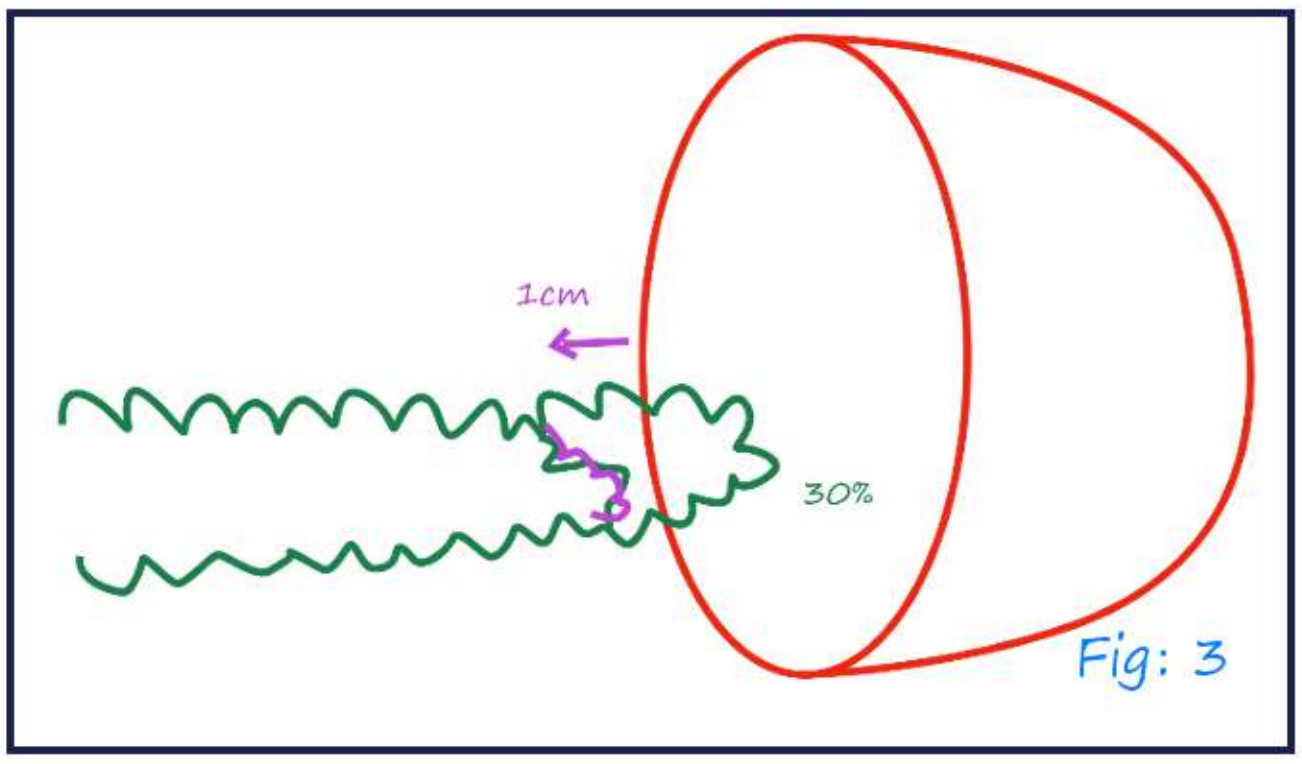

Fig: 3

- In 70% individuals, tail of pancreas is seen with in 1cm
- Splenic artery and vein should be ligated with in 1cm from splenic hilum to prevent injury to spleen
- Injury to spleen would cause splenic fistula
- In 70% splenic artery are divided far from spleen

  ↓

  Distributed type → Branches given away

AfraTafreeh.com



Fig: 4

- In 30%, splenic artery enters hilum and then divides

  ↓↓

  Magistral type

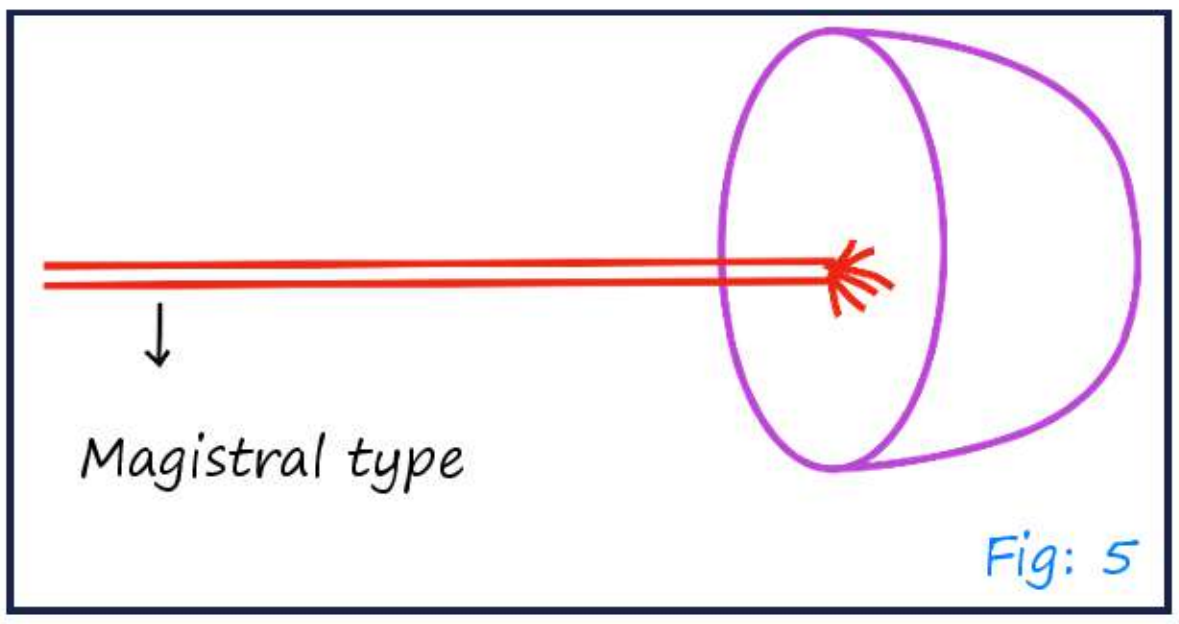

Fig: 5

AfraTafreeh.com

Dissected anatomy of spleen 00:11:42

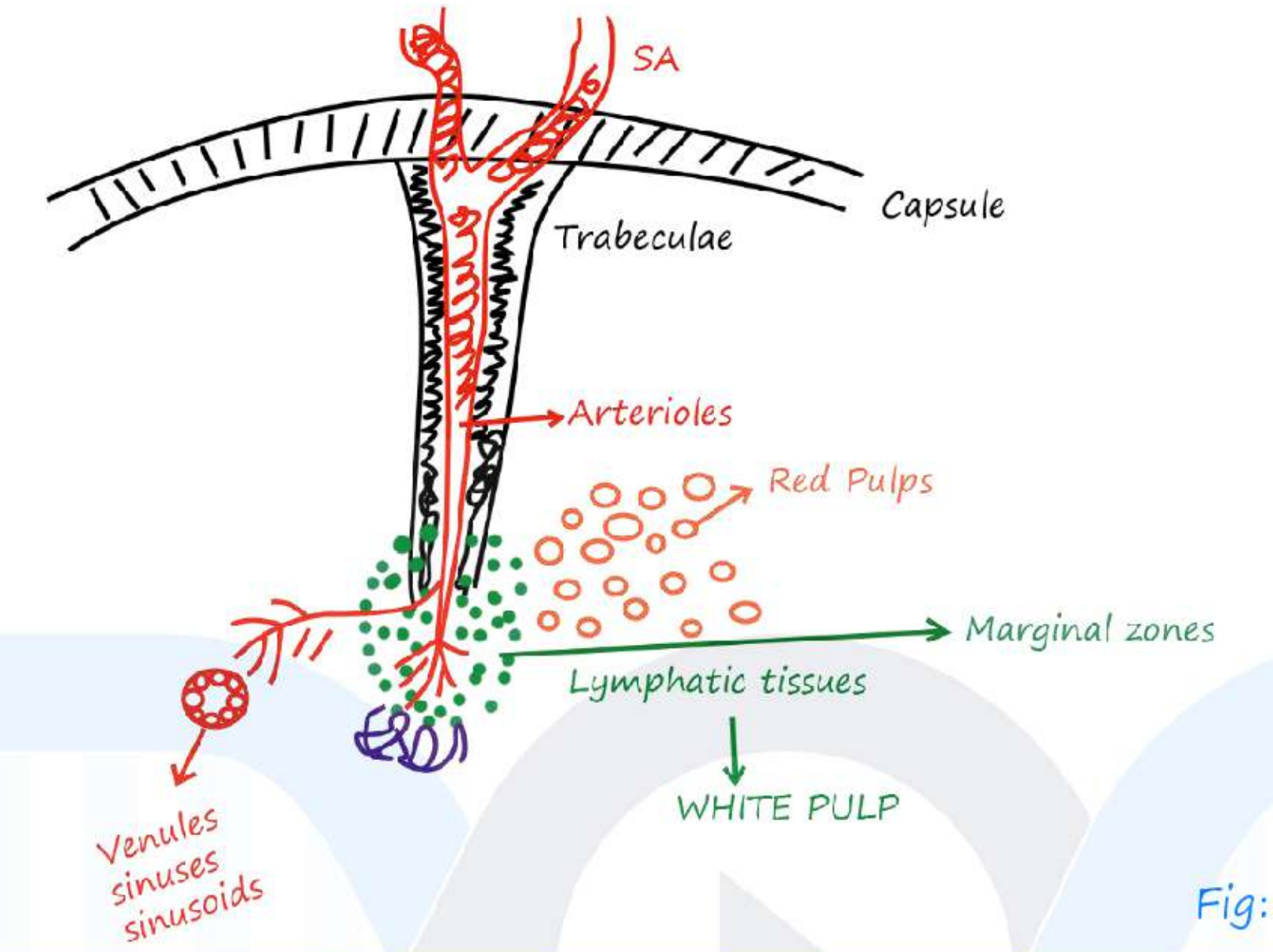

Fig: 6

- Branches of splenic artery enter splenic capsule and form trabeculae
- Splenic vessel is now surrounded by a thick sheet called trabecular sheet and that makes compartilisation of spleen
- Arteries now become arterioles and divide into small branches finally and merge with splenic pulp and adventitia is replaced by lymphatic tissues and continue till the end of arterioles as capillaries
- Lymphatic tissue forms the white pulp of spleen and conite pulp are interspersed between the arterioles
- White pulp interferes with red pulp at the marginal zone

- In the marginal zone, arterioles loose lymphatic tissue and become venous sinuses or sinusoids
- All the sinusoids will get fused and form venules which run in the same trabecular sheath
- In closed system, blood goes into splenic arteries, then goes into smaller arterioles, then capillaries and directly enters veins
- In open system, blood flows through the arterioles and they are going to flow through reticuloendothelial sieves (in splenic sinuses) blood flows to venous sinuses. Therefore, cellular elements are filtered
- In open system, unwanted contents like RBC, nucleoli, parasites are removed
- Reticuloendothelial sieves are seen around splenic sinusoids

Functions of spleen 00:19:51

1.Hematopoietic (3-5 weeks of IUL)

↓

RBC, WBC

> 6 Weeks → Bone marrow produces cells

- If spleen becomes the site of erythropoiesis

↓

Extramedullary erythropoiesis → myelodysplastic syndrome

2.Reservoir of RBC and platelets (1/3rd are in platelets)

AfraTafreeh.com

Splenomegaly (80% inside spleen)

↓

Thrombocytopenia

↓

Increase count happens after splenectomy

3.Filtration

- Removal of senescent RBC
- Hereditary spherocytosis

- Biconcave RBC's passes through this sieve
- This type of plasticity is not available for senescent RBC
- Because of filtration, there are no abnormal RBC's in blood
- In absence of spleen
  - Nuclear remanent of Howel jolly bodies
  - Denatured Hb – Heinz bodies
  - Iron particles – Pappenheimer body
  - Target cells – Codocytes
  - Spur cells
- Removal of inclusions from RBC – Pitting
- Removal of iron from RBC – culling

] Normal functions of spleen

TUTORIALS LOGIN FOR SUCCESS

4.Destructive

- Abnormal RBC's like sickle cell

  Hereditary spherocytosis

  Hereditary elliptocytosis

  ↓↓ Aged RBC > 120 days

  Removed by destruction

  ↓

  – Anemia

  – Auto splenectomy

- Spleen → platelet destruction by producing Ig G autoantibody against platelets

  ↓↓

  ITP

AfraTafreeh.com
TUTORIALS
LOGIN FOR SUCCESS

5.Immunity

- Low IgM levels after splenectomy opsonins → immune factors

Decrease properdin

- Globular protein
- Also known as factor p
- Involved in alternate complement pathway

  ↓

  Bacteria are destroyed

Tuffsin decrease

- Tetrapeptide
- Involved in phagocytosis
- Derived from heavy chain Ig G
- Spleen brings tuffsin to circulation

6.Removal of organisms

- Capsulated bacteria like strep. Pneumoniae, H. influenza — Removed by spleen

AfraTafreeh.com

N. meningitidis

↓

OPSI

Indications of splenectomy 00:37:06

Idiopathic thrombocytopenic purpura (ITP) 00:37:10

- Platelets < 1 lakh/ml
- Spleen produces antibody known as Ig G against the platelets → decrease platelet count
- Dysfunction of megakaryocytes

1°	2°
• New onset: < 3months	• Medications
• Persistent: 3-12 months	• Infections
• Chronic: - >12 months	• Rheumatological

- Clinical feature: - mucosal bleeding – Epistaxis
  Gingival bleeding
  Purpura ⊖

GI bleed
Hematuria } **Rare**

TUTORIALS LOGIN FOR SUCCESS

Intracerebral bleed also rare (can cause of death of the patient)

- Other causes of thrombocytopenia
  - False low count
    - In vitro clotting due to EDTA
    - Anticoagulant not added
    - Giant platelets mistook for WBC
  - Pregnancy
  - Drugs
    - Heparin
    - Quinines
    - Sulphonamides
    - Vancomycin
  - Viral infections
    - HIV
    - EBV
    - HCV
    - Rubella, Dengue
  - Bacteria
    - H. pylori
    - Malaria
  - Alcohol
  - Rheumatological causes
  - Nutritional
  - Hematological
    - Myelodysplastic syndrome
    - Thrombotic thrombocytopenic purpura

AfraTafreeh.com
TUTORIALS
LOGIN FOR SUCCESS

AfraTafreeh.com

- DIC
- CLL
- NHL

ITP

- Most common in young
- Females
- 70% < 40 years

- Children
- M=F
- Sudden onset
- Severe disease
- Disease persists in age (3-12 months) > 10 years girls

Platelet count [Q]

- > 50,000: - observation
- 30,00 – 50,000: - more frequent follow up
- < 20,000: - Admit the patient + mucous bleeding
- <10,000: - Risk of internal bleeding
- Doc for ITP: - steroids – Prednisolone 10 mg/kg/body wt.

  1.Mucosal bleeding (< 50,00)

  2.HTN, Peptic ulcer high risk activities

  3.20000-30000 even without bleeding

  - Platelet count increases in 1-3 weeks (> 50,000)
- Immunoglobins → 1gm/kg/BW → 2 days

↓

Count increases on day 3

1.Pregnancy – bleeding

2.Splenectomy

- Role of platelets in severe hemorrhage

  - Only after ligating splenic pedicle

- Refractory ITP

  1.Oral dexamethasone

  2.Rituximab

  3.Thrombopoietic receptor antagonism

  ↓

  Eltrombopag

  Romiplastin

Indications of splenectomy in ITP

- Count <10000 for >6 weeks
- Refractory to steroids
- If toxic dose of steroid needed
- Inadequate response to steroids
- Pregnancy 2nd trimester
- High risk activities

AiraTafreeh.com
TUTORIALS
LOGIN FOR SUCCESS

Splenectomy is not done if

- When count is >50000 for >6 months

Note -

- During splenectomy, platelets are transfused only after ligating splenic pedicle

Postoperative response after splenectomy

- 72% has complete response

AfraTafreeh.com

- Pre-op indium III scan → platelets show sequestration in spleen – good response
- Hepatic sequestration in pre-op Indium 3 scan

  ↓

  Poor response
- Relapse/no response → think of accessory spleen
  - In accessory spleen → characteristic peripheral smear will not be seen
- 10-20% asymptomatic HIV patients have ITP

  ↓

  Do splenectomy

  ↓

  Delays HIV progression

  Q. In 2021. Most common indication for elective splenectomy: – ITP.

Hereditary anemias 01:02:06

Hereditary anemias

- **RBC Membrane defect** ↓ Hereditary spherocytosis
- **Erythrocyte enzyme deficiency** ↓
  - G6PD deficiency
- **Decrease Hb synthesis** ↓
  - Thalassemia
  - Sickle cell anemias

- Pyruvate
  kinase
  deficiency

Hereditary spherocytosis 01:03:56

- Most common anemia in congenital
- Autosomal dominant
- Mutation of spectrin and band 3 protein

  ↓

  Biconcave RBC's become spherical
- As the spherical cells are moving through the open system of blood flow in spleen

  ↓

  They are filtered by sinusoids

  ↓

  Lysed by spleen

  ↓

  - Anemia
  - Increase reticulocyte count
  - Indirect bilirubin increase
  - LDH increase
  - Osmotic fragility increase
  - Coombs test is negative
  - Decreased haptoglobulin
- Presents with black pigment stones in gall bladder
- Splenectomy + cholecystectomy after 5 years

AfraTafreeh.com
TUTORIALS
LOGIN FOR SUCCESS

AfraTafreeh.com

- Associated diseases: -
  - Elliptocytosis
  - Pyropoikilocytosis
  - Xerocytosis → No splenectomy needed Q
  - Hydrocytosis

Pyruvate Kinase Deficiency and G6PD deficiency

01:08:57

PKD	G6PD
2nd most common, but most common cause of hemolytic anemias	Most common
AR	X – linked
Involved in glycolysis + ATP production ↓ Integrity of RBC lost ↓ Splenectomy beneficial	Involved in NADPH production ↓ Oxidative stress ↓ Stress factors ↓ • No splenectomy • Avoid stress factors

Haemoglobinopathies

01:12:21

Beta thalassemia 01:12:37

- AR
- Disproportionate α:β ratio

Sickle cell anemias 01:12:17

- Homozygous inheritance of Hbs
- Point mutation of β chain 6th position → valine replaced by glutamate
- Affected cells become rigid and sickle shaped

↓

Hemolysis

↓

Auto splenectomy

↓

Peripheral smear: - WBC increase

Platelet increase

Howel jolly bodies ⊕

Salmonella abscess in spleen

- Suddenly, spleen may be affected by sickle cells and go for sequestration crisis

↓↓

Immediate splenectomy

AfraTafreeh.com
TUTORIALS
LOGIN FOR SUCCESS

AfraTafreeh.com

Neoplasms of spleen 01:18:00

- Hodgkin's: – FDG-PET can find out spleen involvement no staging splenectomy needed
- NHL: – Hypersplenism ⊕ → splenectomy done
- Hairy cell leukemia: –
  - 1st line: Purine analogues
  - 2nd line: Immunotherapy
  - 3rd line: Splenectomy
- CLL: – most common leukemia in world

  Incidence of splenectomy reduced due to drugs
  - Fludarabine
  - Rituximab
  - Cyclophosphamide
- CML: – BCR-ABL fusion (Philadelphia chromosome)

  ↓

  Splenectomy needed (Hypersplenism ⊕)

TUTORIALS
LOGIN FOR SUCCESS

Splenectomy indications (Elective)

Most common:
- ITP

Hematological diseases
↓
All except G_6PD, Hereditary Xerocytosis

Malignancies
↓
All except CLL Hodgkin's

Tumors of spleen 01:22:17

- Most common tumors – Lymphomas
- Most common benign tumor of spleen – Haemangioma
- Most malignant tumor – Haemangiosarcoma
- Secondaries are very rare in spleen

↓

- Usually, multivesicular secondaries → most common lungs > Breast
- Isolated secondaries

↓

Most common: - ovary > colorectal

Q. Highest rate of mets of spleen → malignant melanoma

AfraTafreeh.com

Ectopic spleen 01:25:50

- Also known as splenculi (or) accessory spleen
- Spleen is derived from dorsal mesogastrium
- Accessory spleen can occur anywhere in dorsal mesogastrium

TUTORIALS LOGIN FOR SUCCESS

AfraTafreeh.com

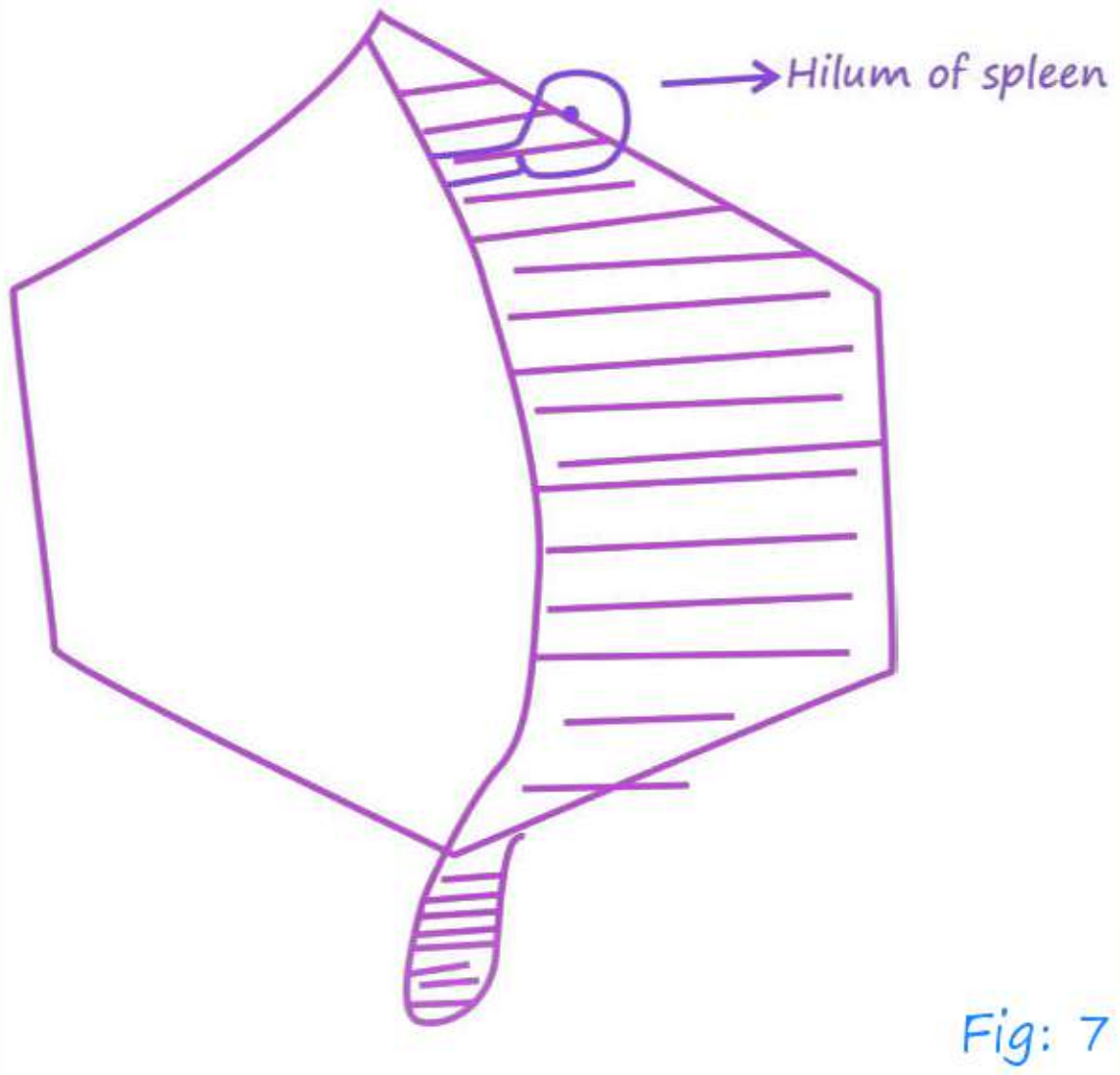

Fig: 7

- Most common site: Hilum of spleen
- Second: – Tail of pancreas
- Others: – Splenocolic ligament

  Perirenal omentum

  Small bowel mesentery

  Uterine adnexa

  Paratesticular region
- Incidence: – 10-30%
- Usually, multiple > solitary
- Ectopic spleen is encapsulated ♂ encapsulated
- Have white and red pulp like normal spleen
- More prone for torsion and that can cause pain on and off → resection
- Ectopic spleen is due to incomplete fusion of splenic tissues by 5th week
- Ectopic spleen should be differentiated from splenosis
- Splenosis means trauma causes rupture of spleen and distribution in peritoneum and can survive

Splenic artery aneurysm 01:30:00

- Splenic artery and vein are closely related to superior pole of pancreas
- Usually, false aneurysms develop in chronic pancreatitis
- True aneurysm most common in females (0.5-1%)

  ↓

  Usually solitary, multiple can be seen in ¼th of cases
- Most common cause of splenic artery aneurysm (overall)

  ↓

  Arteriosclerosis



- **Etiology-**
  - Intrabdominal sepsis
  - Pancreatitis
  - Arteriosclerosis
- 83% asymptomatic
- Can rupture and cause death
- High risk of rupture in

  1.Young females

  2.3rd trimester pregnancy can rupture

  3.Absent calcification

  4.Size > 1.5cm

AfraTafreeh.com

5.HTN

- Management
  - < 2cm and asymptomatic: - No treatment
  - > 2cm and symptomatic: - treatment
  - Splenectomy + removal of diseased artery is done
  - If splenic aneurysm is not dissectible, ligation done front and back

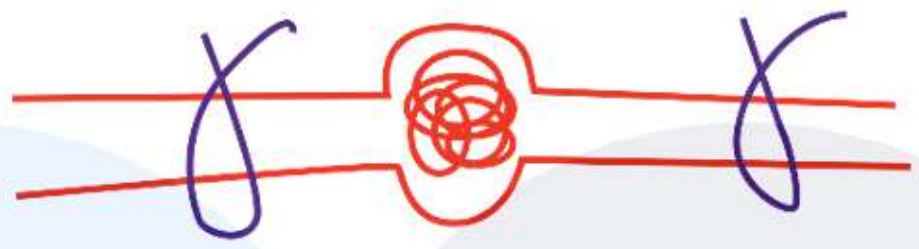

- In unfit patients → embolization of splenic artery

Splenic abscess 01:35:04

- Predisposing factor: -
  - HIV
  - Immunocompromised – DM and Chemotherapy
  - Polycythemia
  - IV drug abusers
  - Trauma
- Most common organism causing abscess – staphylococcus > streptococcus
- Most common route – Hematogenous
- In sickle cell anemia → abscess is formed by salmonella
- HIV – Fungal abscess
- IOC: - CECT

TUTORIALS LOGIN FOR SUCCESS

- Treatment: -

↓

Single abscess

↓

Percutaneous drainage



↓

Multiple abscess

↓

Splenectomy

Splenic cyst 01:37:04

Splenic cyst

- Parasitic
  - ↓ Hydatid cyst (most common)
- Non-parasitic
  - True cyst (epithelial) ↓ Epidermoid cyst
  - Pseudocyst (most common) ↓ Caused by trauma

DOCTUTORIALS
LOGIN FOR SUCCESS

Epidermoid cyst

- Lined by squamous epithelium
- 10% of all cysts
- Benign cyst → no malignant potential
- Fluid analysis is positive for CEA and CA 19-9 may elevated
- If symptomatic → partial splenectomy
  → atleast 25% of spleen needed to prevent OPSI

AfraTafreeh.com

Wandering spleen 01:39:50

- Due to improper fusion of dorsal mesogastrium with posterior peritoneum
- Clinical features: -
  - Intermittent abdominal pain
  - Splenomegaly ⊕
  - Torsion
- Congenital
- Seen in females 20-40 years
- Multiparous women → Hormones would cause laxity of attachments
- CECT: - whorled vascular pedicle

  Because of vessels rotated – Non contrast spleen

- Treatment: - splenopexy or splenectomy

TUTORIALS LOGIN FOR SUCCESS

Splenectomy 01:42:35

Splenectomy

- **Laparoscopic** ↓ Look for spleen enlargement
  - **Mild**
  - **Moderate**
  - **Severe**
- **HALS** ↓ Hand assisted laparoscopic splenectomy
- **Robotic splenectomy**

↓	↓	↓
<500 g	500 – 1000 g	>1000g

- Recent sabiston says laparoscopic splenectomy indicated only for mild cases.
- C/I in portal HTN
  Medical comorbid conditions
- Pregnancy 2nd trimester is not a C/I (ITP)

HALS

- Hand port used to remove spleen
- No more mentioned in books
- Robotic splenectomy – no added advantage
  Not advised
- Position for splenectomy – right side decubitus position

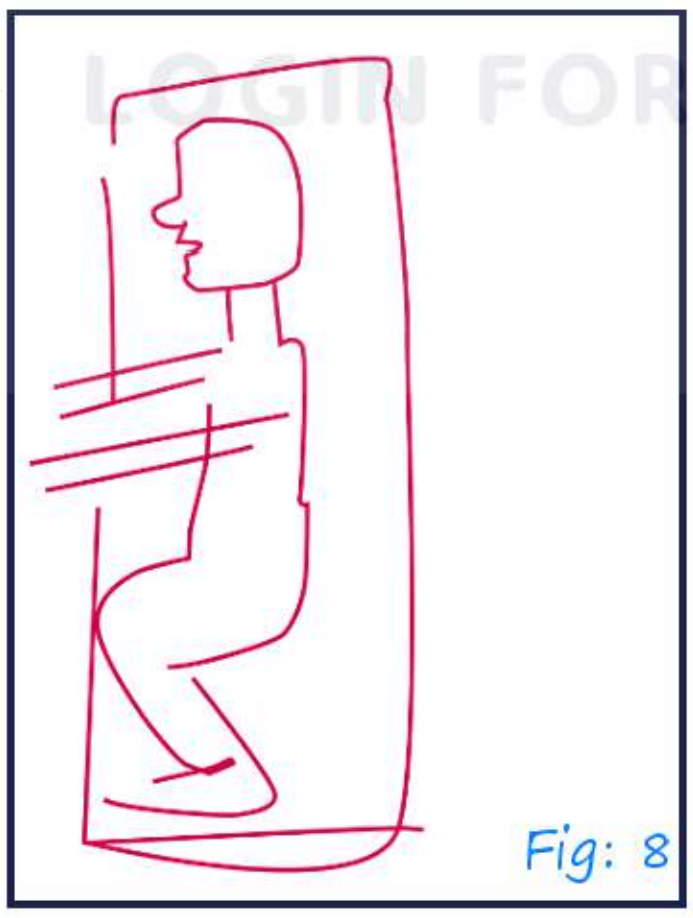

Fig: 8

- Surgeon stands on right side of patient

AfraTafreeh.com

- Supine position is not followed → surgeon stands in between legs

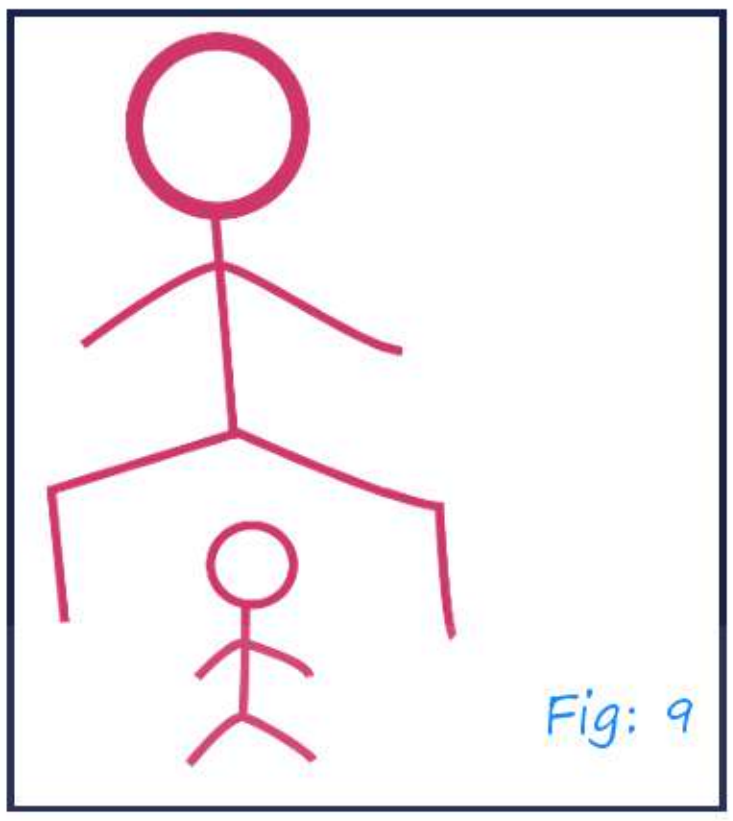

Fig: 9

- In distributive mood, dissection done 2cm away from hilum

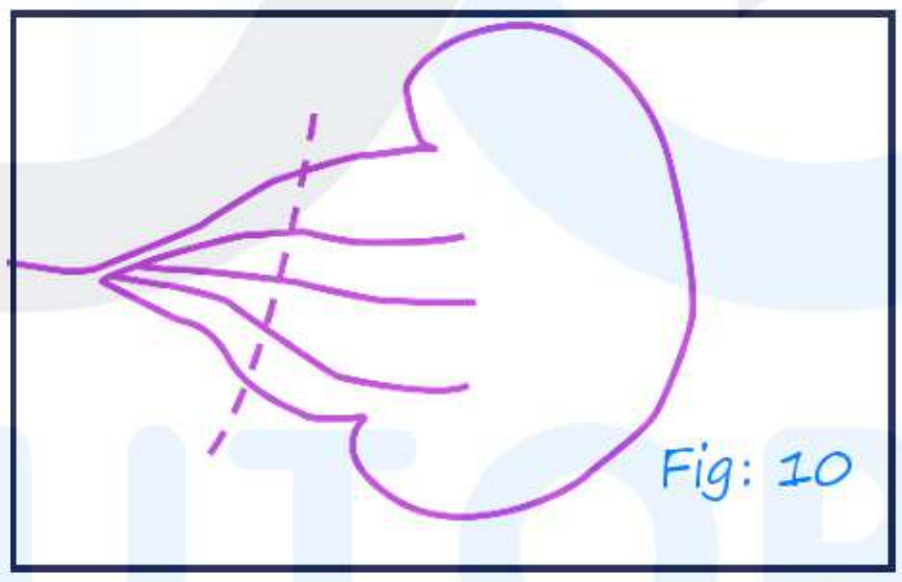

Fig: 10

- Multiple methods to transect → hemolock clip
  Endovascular stapler

Splenectomy and its complications 01:48:26

Splenectomy and it's complications

Immediate	**Intermediate**	**Delayed**
↓	↓	↓
- Haemorrhage - Hematemesis - Gastric dilation	Most common overall - lung atelectasis (15%) - Pancreatic fistula - Pancreatitis - Pseudocyst - Gastric fistula - Subphrenic abscess - Hematomas	1. Thromboembolic manifestations 2. OPSI 3. Portal vein thrombosis

AlfraTafreeh.com
TUTORIALS
LOGIN FOR SUCCESS

- Post splenectomy → Increases WBC / Increases Platelet] Normally > 3 weeks

↓

If platelets > 10 lakhs – antiplatelet drugs to be given

AfraTafreeh.com

- Post splenectomy thrombosis can occur in
  - Splenic vein
  - Superior mesenteric vein
  - Portal vein

  ] - 10% cases
  - Most common in myeloproliferative disorders + huge spleen

  ↓

  Systemic anticoagulation interventional thrombolysis

OPSI 01:52:58

- Most common with capsulated bacteria
- Most common
  - Streptococcal pneumonia
  - H. influenza
  - Meningococcal
- Malaria increases

  Babesia increases
- No increase risk of viral infection
- Risk factors
  - Young age
  - Thalassemia → 8% risk (highest)
  - Sickle cell anemia
  - ITP
  - Lymphoma
  - Immunosuppression
- Most common fatal late complication
- Can happen any time after splenectomy
- Most common after 2 years

- 40% > 5 years
- Incidence: 3-5%
- Mortality 40%
- OPSI – 1/300 in children
  1/800 in adults
- Clinical features – Typical flu like symptoms
  ↓
  - Fever, chills, rigor, diarrhea, vomiting, DIC, ARDS, MODS, Coma and death.
  - Within 24-48 hours they progress to coma.
- If they survive → Multiple morbidities like
  - Amputation of limbs,
  - Gangrene
  - Osteomyelitis
  - Endocarditis
  - Cardiovascular events

AfraTafreeh.com
TUTORIALS
LOGIN FOR SUCCESS

AfraTafreeh.com

- To prevent OPSI → **vaccination**

Electively
↓
- 10-12 week before surgery
- Bailey says atleast 2 weeks before surgery

Emergency
↓
Before discharge/ <14 days after surgery

Pneumococcal
↓
13 valent (1st dose)
↓
23 valent (@8 weeks)

Meningococci
↓
Quadrivalent (Conjugate ACWY series)
+
Monovalent meningococcal 'B' vaccine series

H. influenza
↓
Type B conjugate

- Routine vaccines given
- In trauma patients, auto implantation → 50% spleen kept in omental pouch
- Booster dose @ every 5 years – PPV 23
  - Quadrivalent

- Antibiotic prophylaxis

Daily antibiotic

(Australian spleen society)

↓

- Upto 16 years age (children)
- Upto 5 to 3 years (Adults) after surgery

↓

Stand by antibiotics

- HIV and immunocompromised patients → lifelong antibiotics

Emergency supply

↓

Oral amoxycillin

↓

(Augmentin)

If allergic

↓

Macrolides like azithromycin

AfraTafreeh.com
TUTORIALS
LOGIN FOR SUCCESS

AfraTafreeh.com

UROLOGY - I

- Avascular line around the kidney – Brodel's line

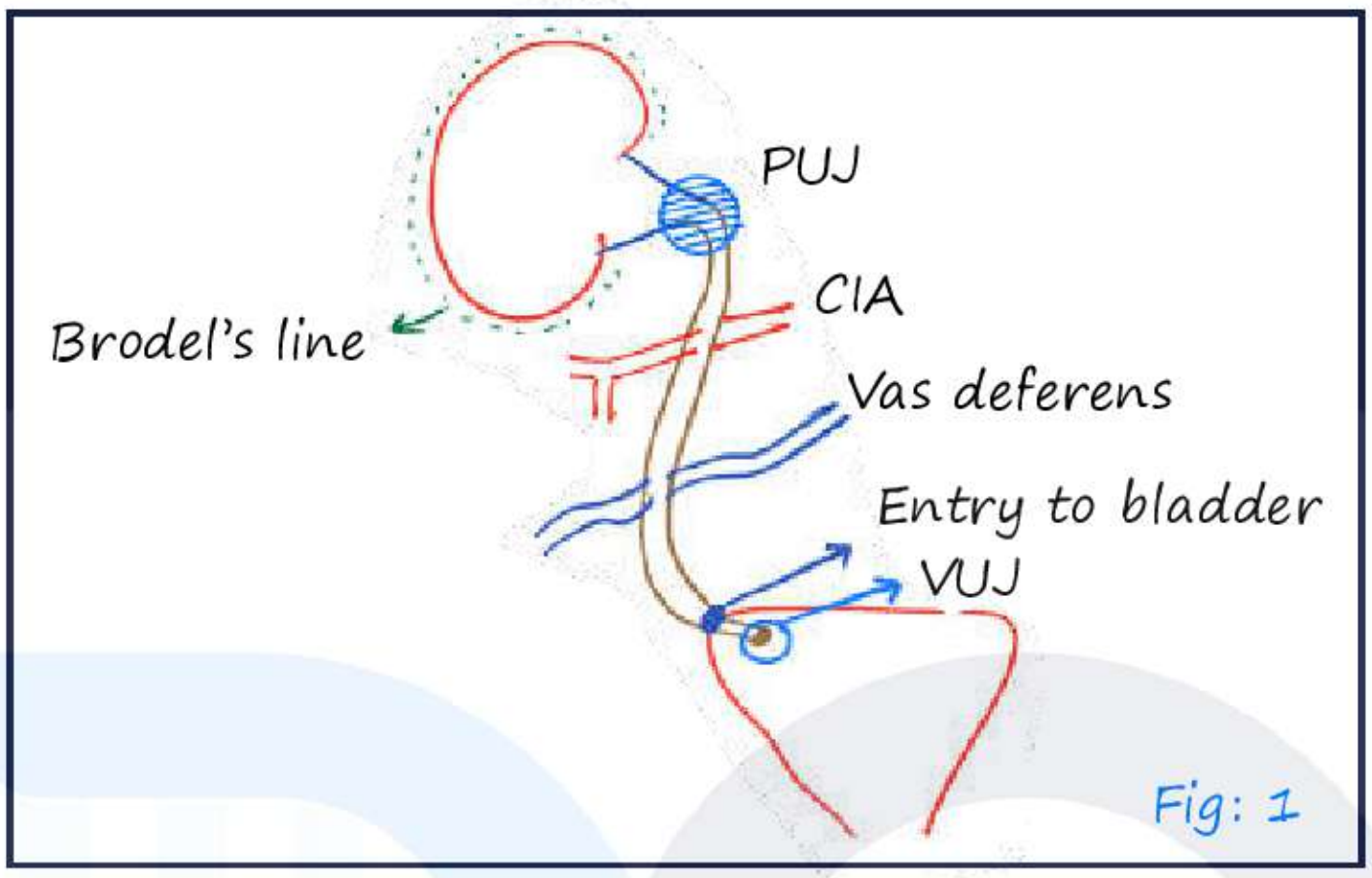

Fig: 1

Narrow points

1.PUJ

2.Crossing of common iliac artery

3.Crossing of vas deferens (Males) or round ligament (Females)

4.Entry to bladder

5.VUJ – Most common for ureteric stone

Kidney investigations 00:04:16

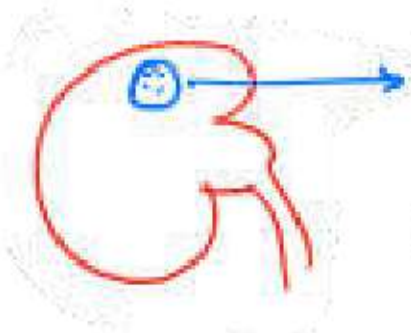

Cyst in kidney

↓

IOC – CECT abdomen

↓

Bosniak classification

I – Simple cyst → 0.1 risk of malignancy

II – Benign cyst hair line septation → 0.1%

IIF – Complex cyst → 0.5%

↓

No soft tissue component

Hair like septation (+)

III – Indeterminate mass – 50%

↓

Cyst wall (+) ⎤
Septations (+) ⎦ Enhancement

IV – Malignant cystic mass – 100%

Soft tissue (+)

- Biopsy advised for III – Biopsy
- IV – Resection

Special scan for kidney :

DMSA	DTPA	MAG-3
↓	↓	↓
Dimercapto succinic acid scan	Diethylene triamine penta acetate	Mercapto acetyl triglycine scan
↓	↓	
Morphology of kidney	Perfusion of kidney (physiology)	
↓	↓	
(Anatomy)	PUJ obstruction	

AiraTafreen.com
TUTORIALS
LOGIN FOR SUCCESS

AfraTafreeh.com

- IOC for PUJ obstruction → MAG 3 scan
- Now-a-days DTPA scan is replaced by MAG-3 scan

Renal stones 00:12:07

- Clinical infection: Mostly asymptomatic
- Renal → Back pain
- PUJ → Pain radiating loin to testicles (Genital br. of genitofemoral nerve)
- Mid ureter → Mimics appendicitis on right side and diverticulitis on left side
- VUJ – Pain radiating from loin to groin/medial side of thigh (Ilioinguinal nerve > Iliohypogastric nerve)
- Intramural ureteric stone → Strangury

Dietel's crisis 00:17:32

- Stone obstructs the ureter

  ↓

  Hydronephrosis of kidney

  ↓

  Takes alcohol/Beer

  ↓

  Stones pushed out

  ↓

  Enormous urine passed and mass disappears

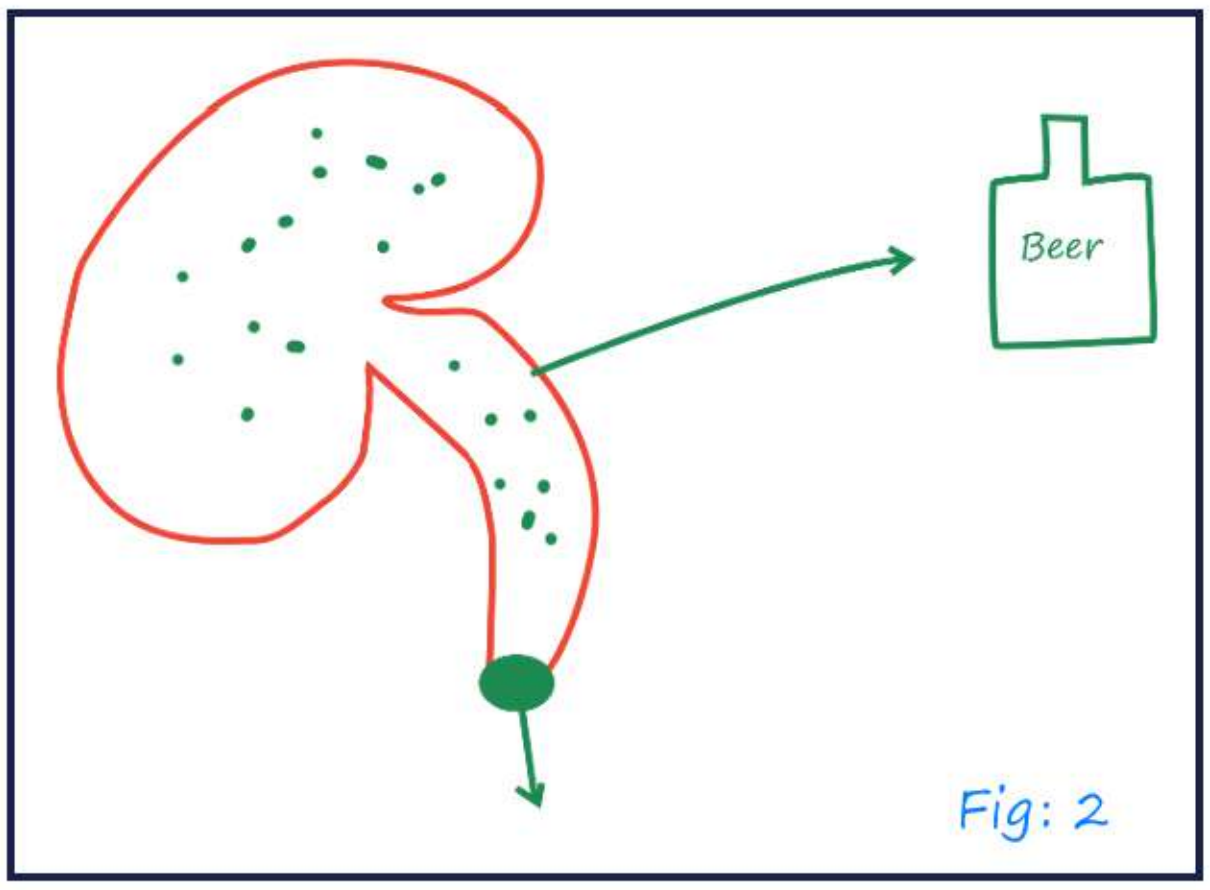

Fig: 2

Other clinical features

- Hematuria
- ↑ frequency
- Strangury
- Pain (+) → 1st treatment → Inj. diclofenac

Types of stones 00:20:43

AfraTafreeh.com

Calcium oxalate	Ca, Mg NH4 triple phosphate	Cystine	Uric acid	Other rate
- COM - COD - Mulberry stone 	- Struvite stones - Jack stones - Staghorn 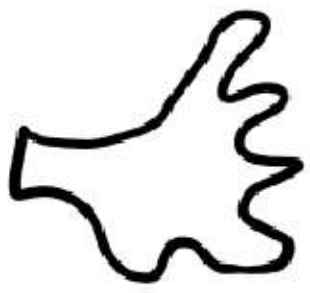 - Most common	- Cystinuria - Hard - Contains double Sulphur Bond SH=SH - No calcium	- Radiolucent - Smooth yellow stones - Hyper uremia - Gout cancers	- Indinavir stones HIV - Xanthine Stones in Xanthine oxidase def - Both are radiolucent

AfraTafreeh.com

- Most common type - Most common to cause hematuria	in infection proteus - Most common in alkaline urine - Smooth surface	- Bonds make it radiopaque		

Urinary crystals 00:27:16

- Calcium oxalate: Bipyramidal
- Calcium oxalate monohydrate (Hardest): Dumb bell
- Triple PO4: Coffin lid
- Cystine: 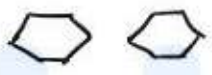 Hexagonal crystals benzene ring
- Brushite: Needle like
- Uric acid: Multifaceted appearance

Order of breaking ESWL

- M-Calcium oxalate monohydrate
- B-Brushite
- Cystine

Drugs causing renal stones

- T-Triamterene
- I-Indinavir

- M-Mg Trisilicate (present in antacids)
- E-Ephedrine
- S-Septran
- C-Ciprofloxacin
- A-Acetozolamide
- L-Loop diuretics
- L-Laxatives (MG containing)

Management

- <5mm – No treatment
- Increased fluid intake: >2.5L/urine

Restrict/Avoid

- Protein
- Salt
- oxalate diet
- Juice → Cranberry juice is given

More consumption
↓
Calcium supplements

AfraTafreeh.com

TUTORIALS
LOGIN FOR SUCCESS

Bladder stone 00:37:38

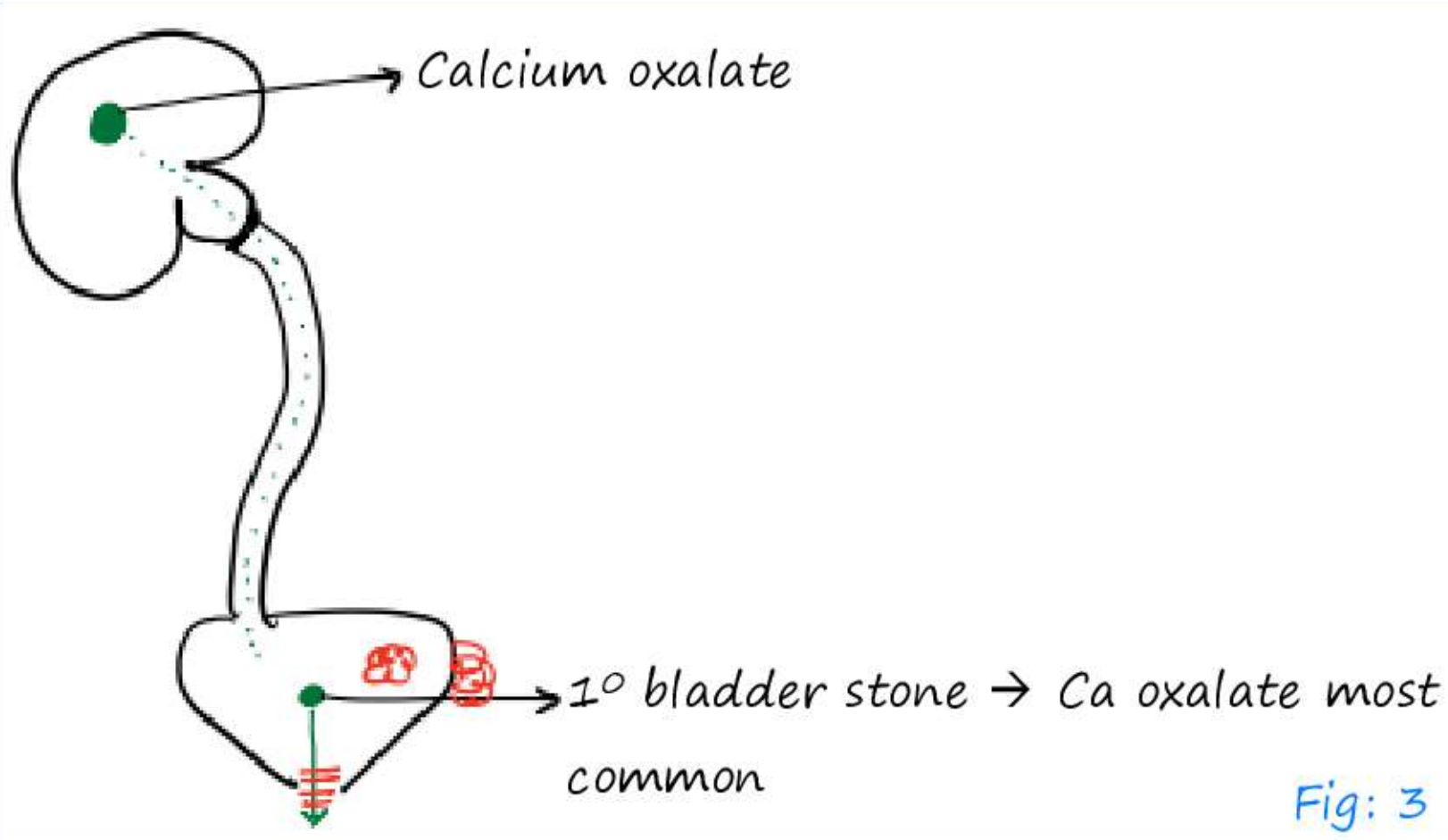

Fig: 3

AfraTafreeh.com

- 2° bladder stone – Some pathology causing bladder stone & Most common type
- Most common type of 2° stone → Ammonium urate

↓

Gets coated with calcium on the surface

↓

Calcium apoplexy

↓

Calcium apoplexy

↓

100% radio opaque stone

Management

- ESWL → Extra corporeal short-wave lithotripsy
- PCNL → Percutaneous nephrolithotomy
- RIRS → Retrograde intra renal surgery

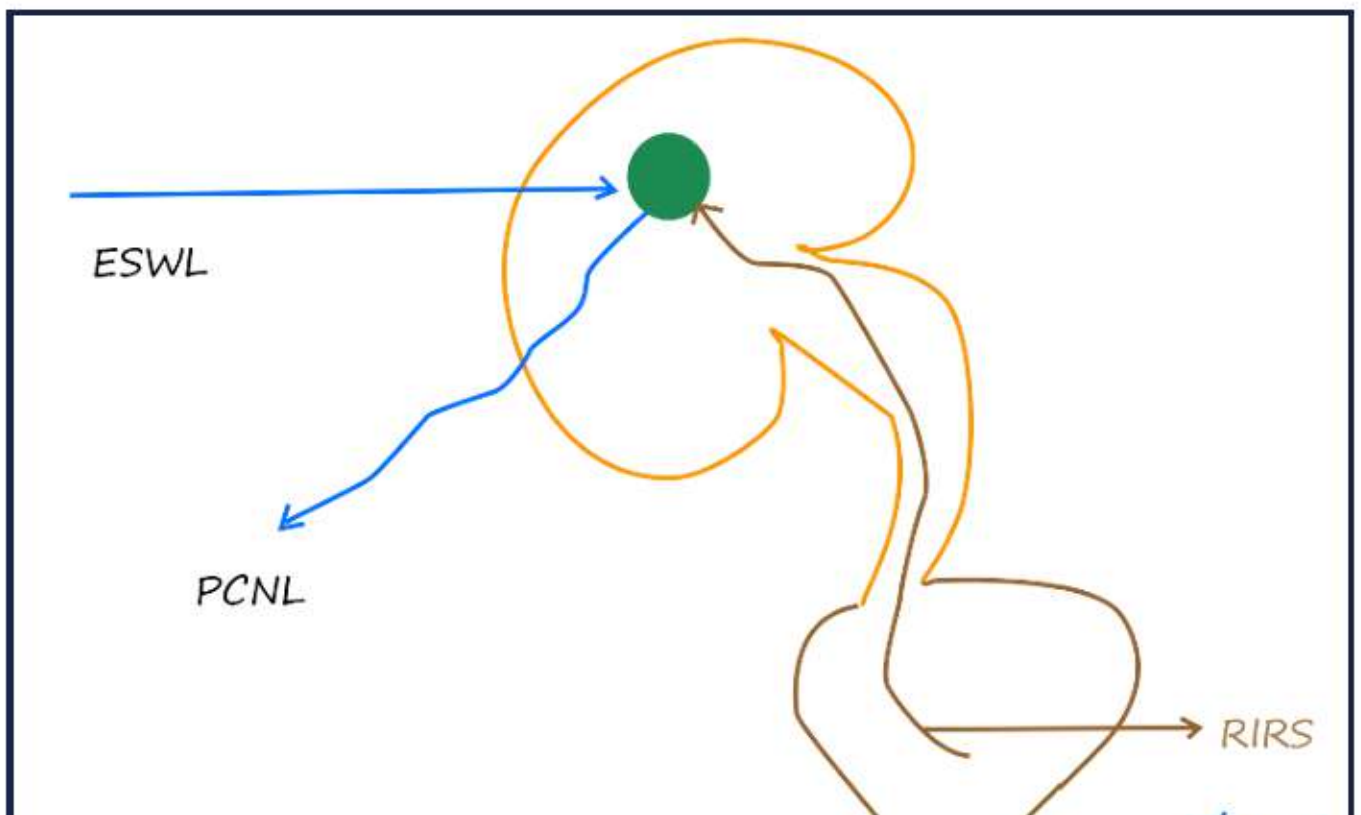

Fig: 4

- Olden days (Open methods) – Nephrolithotomy

↓

Cut along brodel's line and remove stone

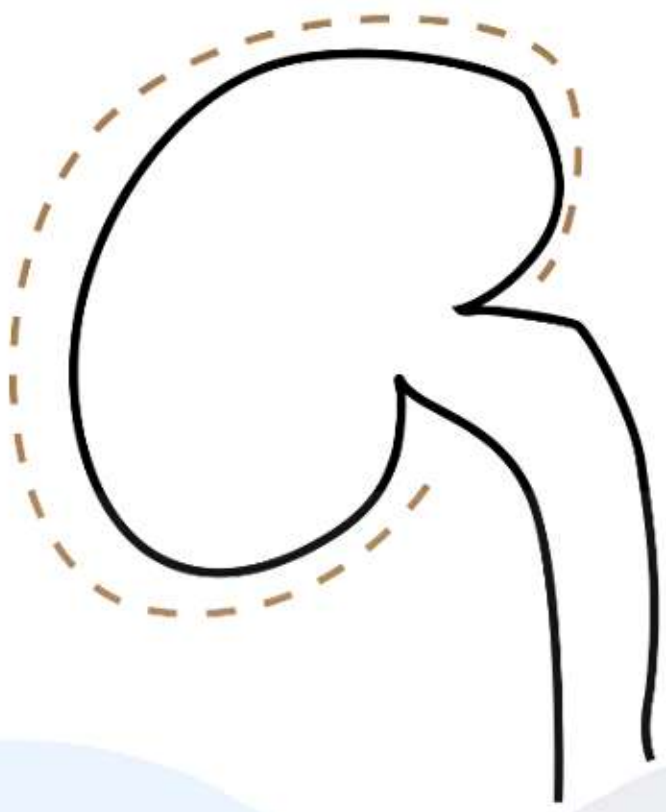

Pyelolithotomy

↓

Cut along the renal pelvis and remove stone

ESWL 00:45:00

AfraTafreeh.com

- Indication – <1.5cm size
- Done for kidney, Pelvis, Upper ureter → Stones
- Not done for lower ureteric stones (as pelvic bone will cause hindrance)

TUTORIALS LOGIN FOR SUCCESS

Contraindications

- Absolute → Pregnancy bleeding diathesis
- Relatives
  - Obstruction
  - Infection
  - Hematuria
  - Renal dysfunction

AfraTafreeh.com

Complication

- Hematuria
- Incomplete clearance
- >1.5cm
- Stones will come down as street –Stein strasse (Stone Street)

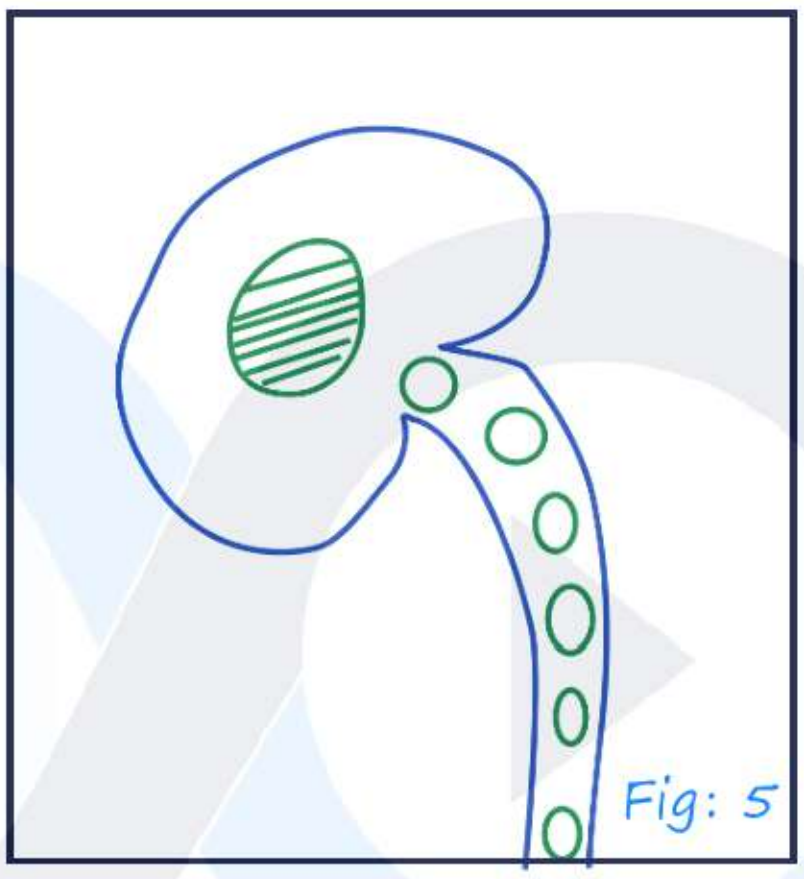

Fig: 5

- Stone >1.5cm → DJ stenting D



Fig: 6

PCNL 00:50:34

- Indication:
  - >2cm size
  - Infected urinary system

- Obstructed urinary system
- Cystine stone
- Failed ESWL
- Anatomical anomalies (Calyx diverticulum stones)

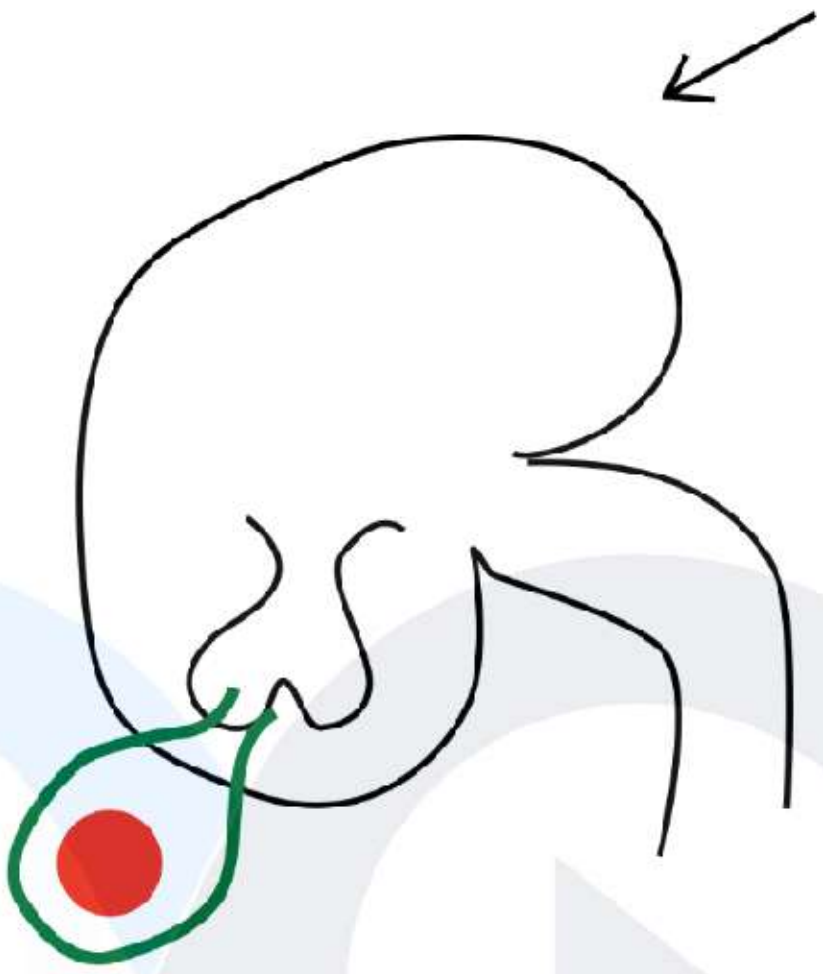

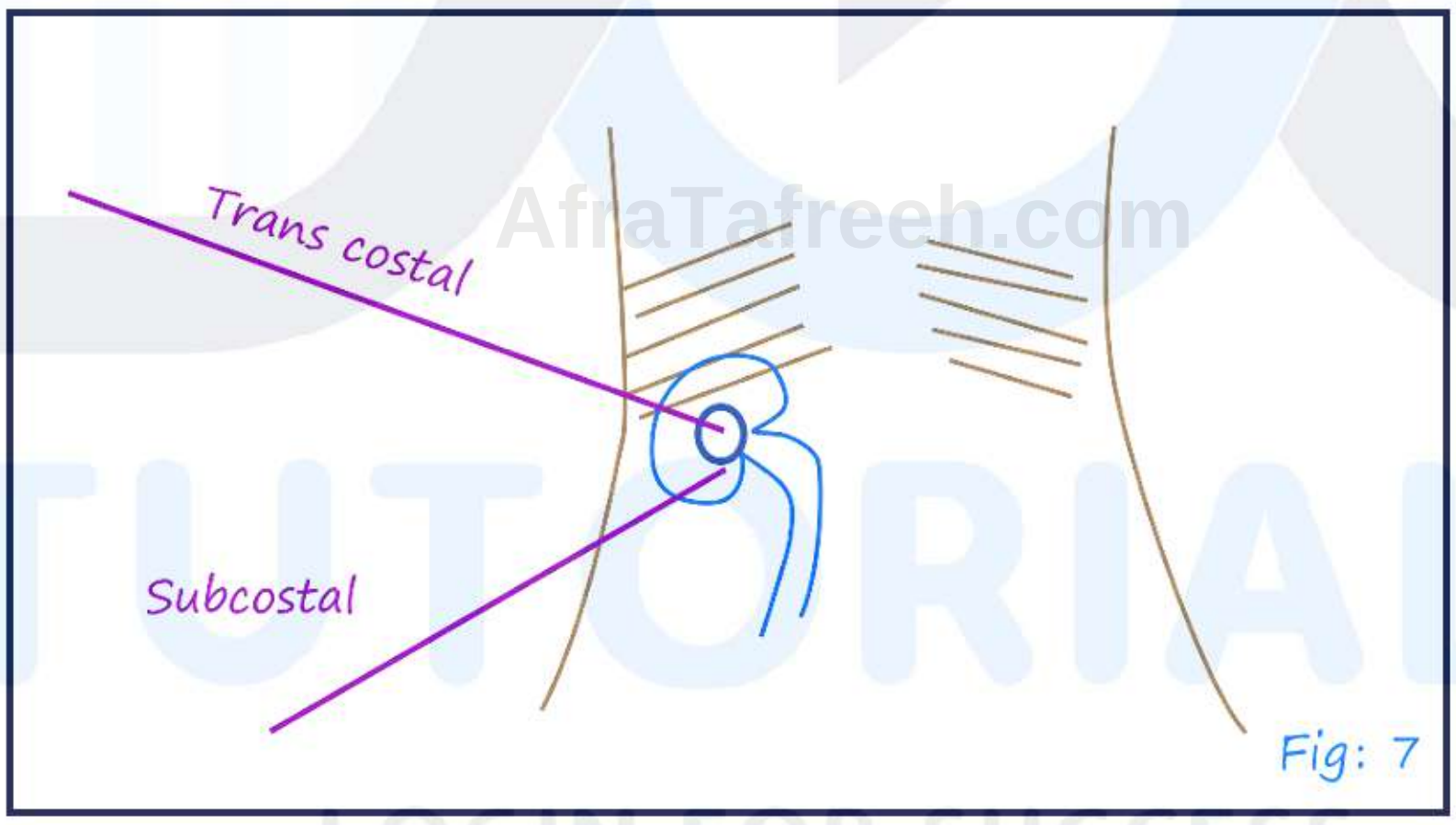

Fig: 7

- 2 Approach – Trans costal & subcostal
- Dilate and then pass a scope → Nephroscopy

Complications

- Bleeding
- Sepsis
- Perforation
- Trans costal approach:

AfraTafreeh.com

  - Pleural injury
  - Hydrothorax
- Subcostal approach:
  - Duodenal injury
  - Colon injury
  - Liver/Spleen injury
- Injury to (R) artery/Vein/IVC

Staghorn calculi

↓

Sandwich

↓

ESWL

↓

Break → PCNL

TUTORIALS
LOGIN FOR SUCCESS

RIRS

- Indication: Renal pelvis stones & Mobile stones

Ureteric stone

- <5mm → No treatment
- >5mm and impacted → Ureteroscopic retrieval using dormia basket
- Push bang technique

  ↓

- Upper ureteric stones and reachable by ureteroscope

  ↓

- Push the stone to pelvis and do ESWL → DJ stent
- Treatment of bladder stones –Trans urethral cyst lithotripsy

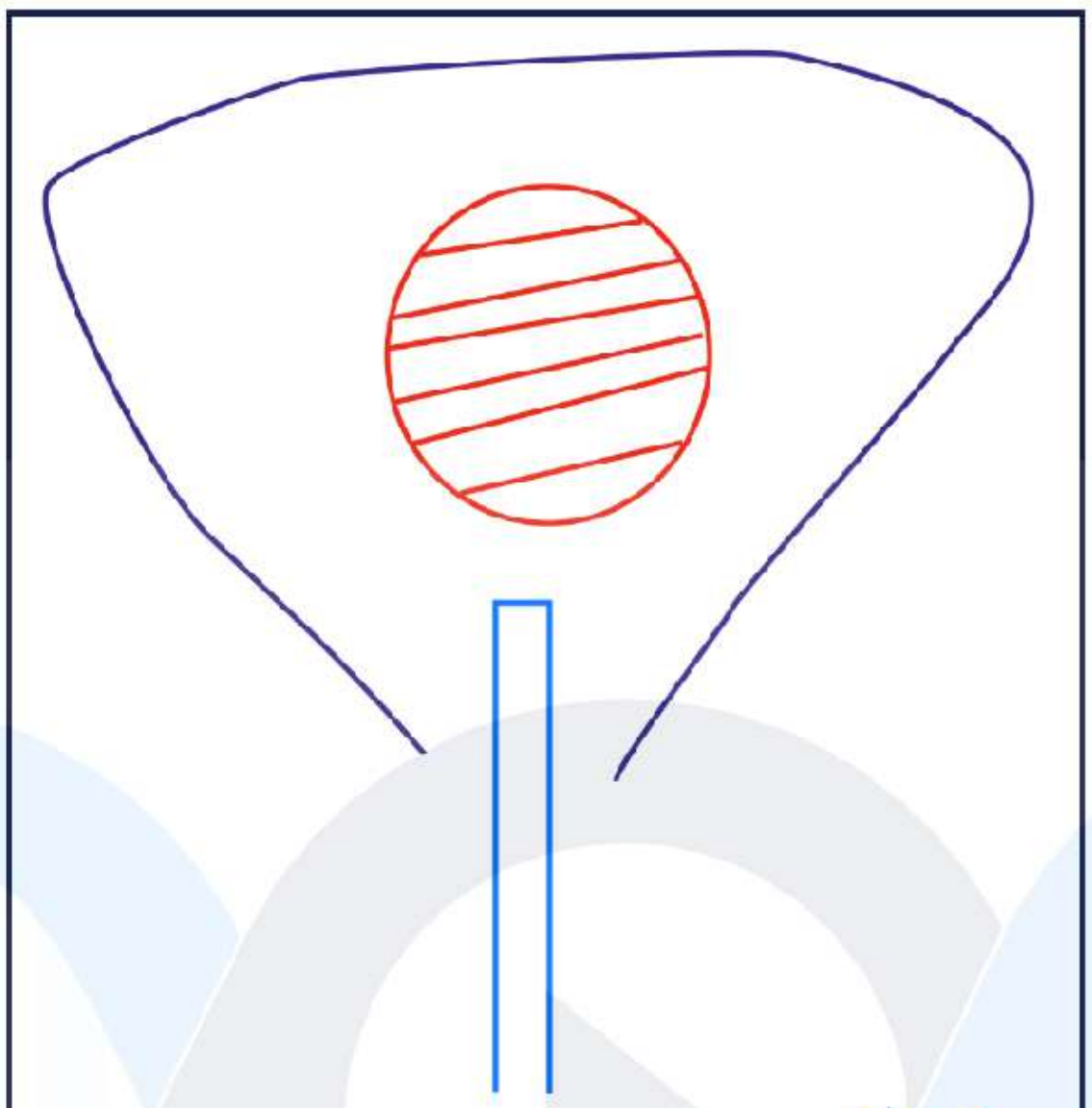

Fig: 8

- Commonly used lasers – HO: YAG (best) & ND: YAG

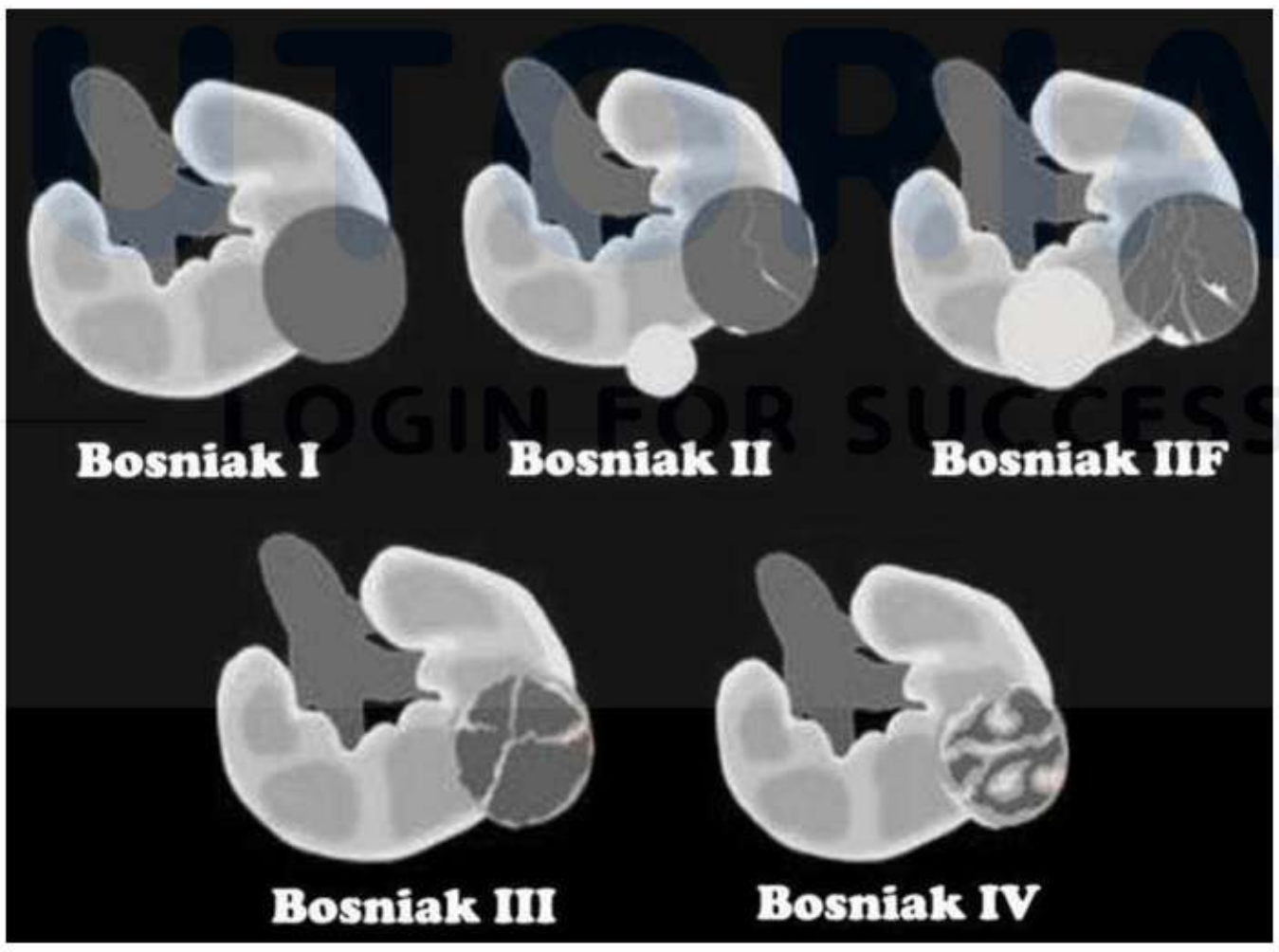

Fig: 9

Grawitz tumor

- Also known as RCC/Hypernephroma
- Most common type – Clear cell adenocarcinoma
- Most common in men (2:1)

AfraTafreeh.com

- Most common in upper pole of kidney
- Most common arises from proximal convoluted tubules
- Common in 50-60yrs
- Most common neoplasm
- Most common presentation
  - Hematuria
  - Pain
  - Mass

  (Hematuria, Pain, Mass) — RCC triad (HMP)

Pathology

Clear cell (most common)	**Papillary RCC**	**Chromophobe RCC**	**Medullary RCC**
• Associated with VHL gene mutation • 3p mutation	• Trisomy 7,16,17 • Chr. 7mutation • Tumor most common in PCKD patients on dialysis	↓ Best prog	↓ Seen in sickle cell trait

DOC TUTORIALS LOGIN FOR SUCCESS

Other clinical features

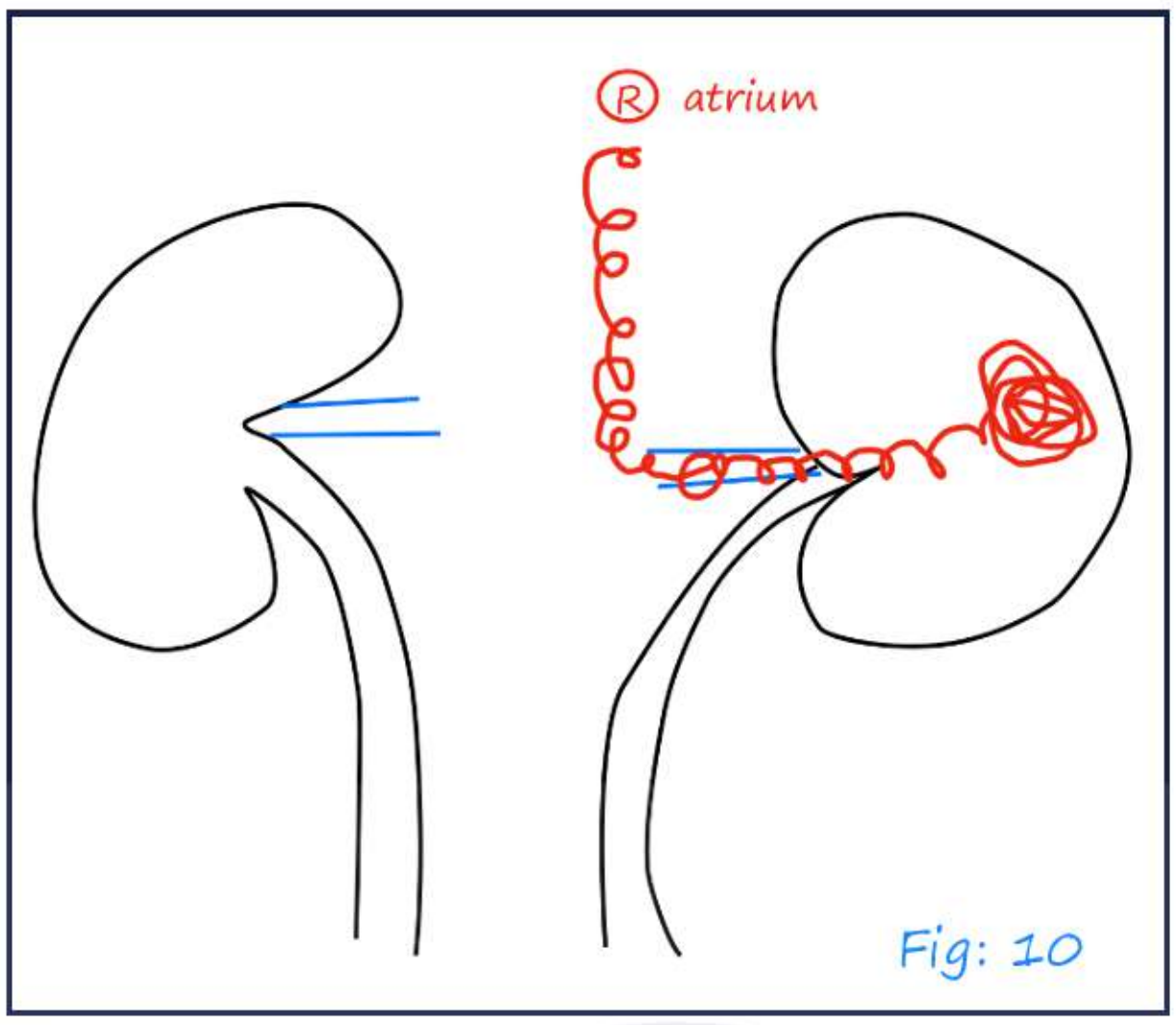

Fig: 10

- RCC has special property to invade and grow into renal veins IVX, (R) atrium
- Still operable
- (L) varicocele testis → Irreducible
- RCC – hematogenous mets → Pulsatic skull secondaries
- Most common distant mets → Lungs (Cannon ball mets)

AfraTafreeh.com
TUTORIALS
LOGIN FOR SUCCESS

Grading systems

- FUHRMAN's → based on nuclear grade
- LEI Borich score → Based on histological features

AfraTafreeh.com

Staging system

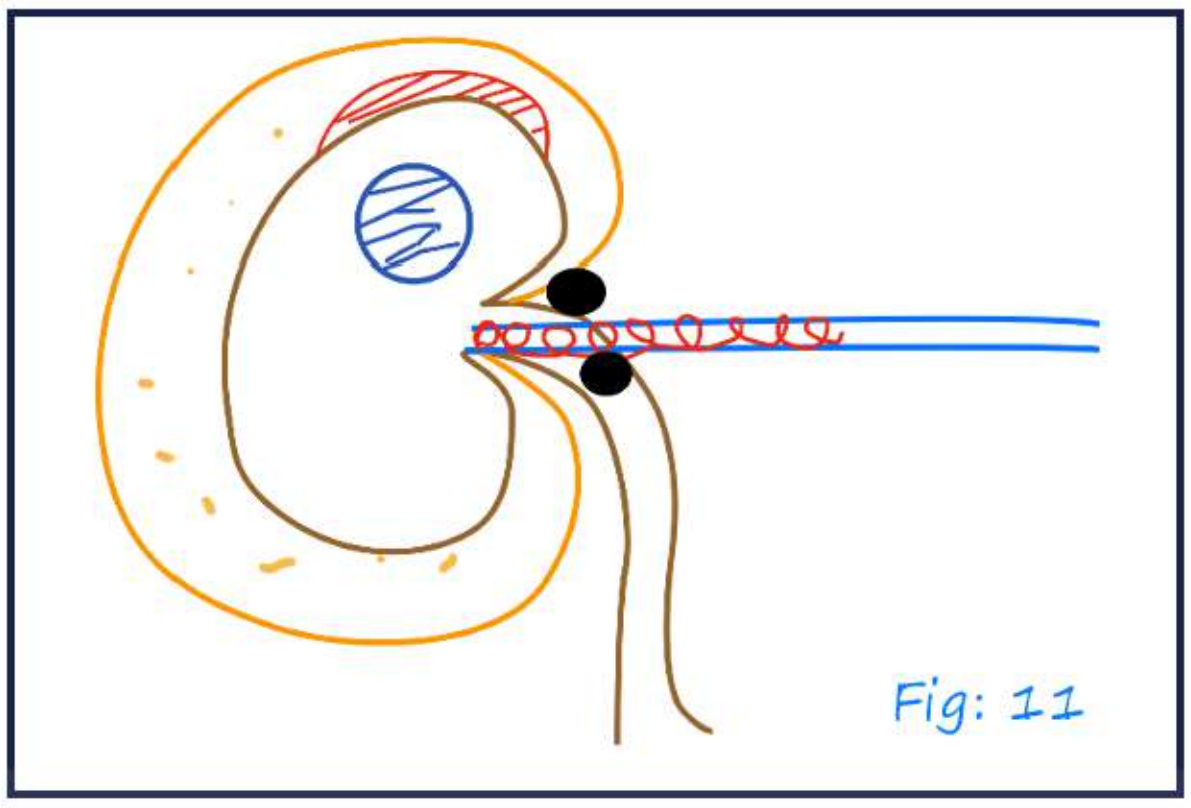
Fig: 11

- Stage I – Tumor <7cm and limited to kidney
- Stage II – Tumor >7cm and limited to kidney
- Stage III – Cancer infiltrating renal vein/adrenal gland/regional nodes
- Stage IV – Out of gerota's fascia
- Treatment – Radical nephrectomy if operable
- Structures removed

1.Kidney

2.Adrenal gland

3.Perirenal pad of fat

4.Regional nodes

5.Part of upper ureter

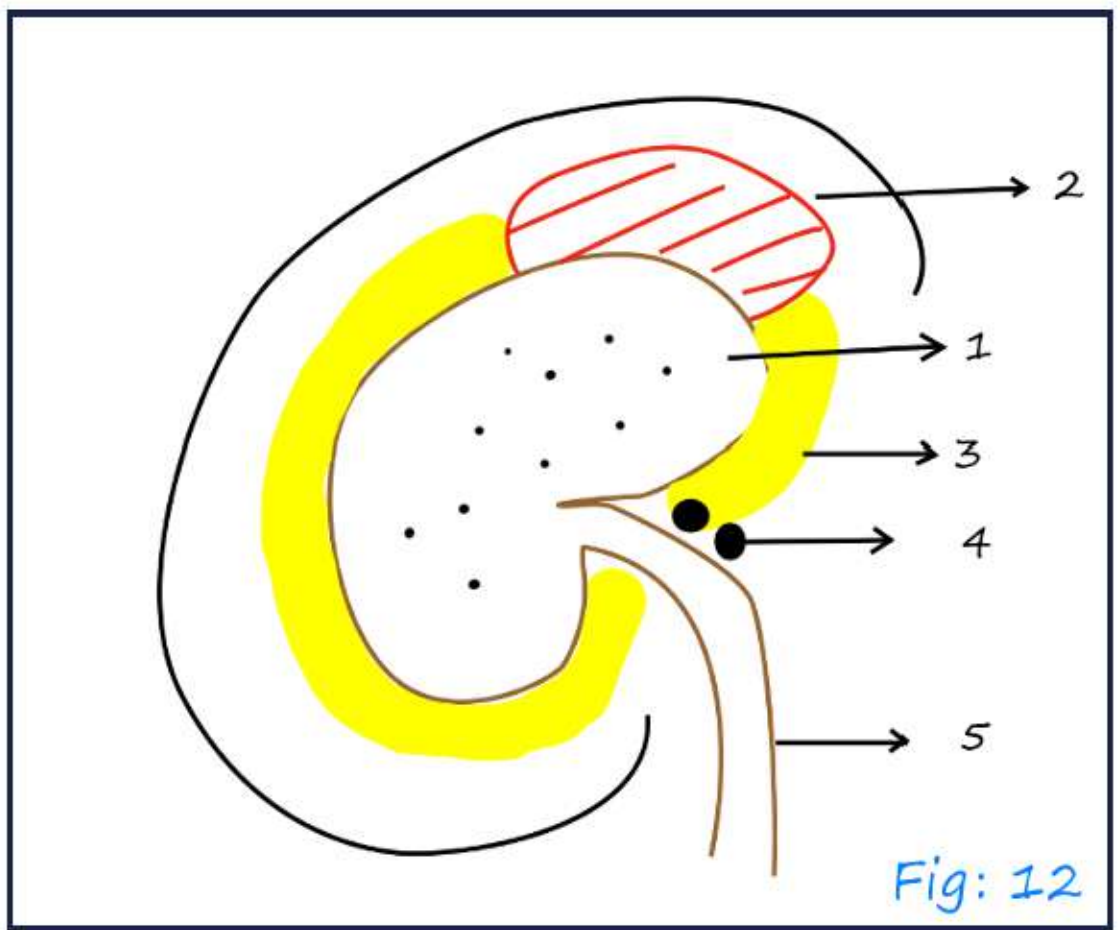

Fig: 12

- Gerota's fascia also removed

Partial nephrectomy (Nephron sparing procedure)

- T1 < 7cm (NEET 2020 Q) → Even in presence of normal opposite kidney
- Single functioning kidney
- VHL-B/L RCC
- Renal failure (DM, HTN)

AfraTafreeh.com
TUTORIALS
LOGIN FOR SUCCESS

AfraTafreeh.com

RCC	WILMS tumor
• Chromosome 3p (VHL)	• Chromosome 8/11
• 50-60yrs	• 1-5yrs
• Most common malignant tumor	• Most common 1° tumor of children
• H – Hematuria	• H – Hematuria
• M – Mass	• M – Mass
• P – Pain	• P – Pyrexia
	• HTN wt. loss
	• Associated with – Beck with weidmann syndrome ↓ Macroglossia Visceromegaly ↑ Insulin WAGR ↓ Wilms tumor Aniridia Genitourinary anomalies Renal anomalies
• Most common distant mets – lungs	• Lungs
• Pre-OP biopsy not needed	• Pre-op biopsy must
• Treatment of choice surgery	• Surgery
• Chemo resistant	• Chemo sensitive
• radioresistant	• Radio sensitive
• Sunitinib – Mab → for Metastatic RCC	• Vincristine
	• Actinomycin

TUTORIALS
LOGIN FOR SUCCESS

Protocols in management of wilm's tumor (AIIMS Q)

NWTSG
↓
National wilm's tumor study group
↓
Staging
Surgery first
↓
Chemotherapy

SIOP
↓
International society of oncopediatrician
↓
Chemotherapy
↓
Surgery
↓
Post chemotherapy
↓
Staging

Survival is same

AfraTafreeh.com
TUTORIALS
LOGIN FOR SUCCESS

- Treatment: Radical nephrouretectomy
- B/L wilm's tumor – Chemotherapy 1st
  ↓
  Shrink the tumor
  ↓
  Nephron sparing operation

- RCC – Bad prognosis
- Wilm's tumor – Excellent prognosis
- D/D of wilm's tumor – Neuroblastoma

Angiomyolipoma 01:36:21

- Hamartoma of kidney
- Associated with 50% tuberous sclerosis

AfraTafreeh.com

- EPL – Epilepsy
- LO – Low intelligence
- A – Adenoma sebaceum

- Components
  - Angio – Blood vessels
  - Myo – Muscle
  - Lipoma – Fat
- IOC: CT scan (Fat inside lesion) -HMB 45 positives
- Clinical features
- Hematuria
- Hypertension
- Mass
- Pain
- Anemia
- Can rupture Retroperitoneally / Spontaneously → Wunderlich syndrome ↓ Self-limiting

TUTORIALS LOGIN FOR SUCCESS

Treatment

- <4cm: No treatment
- >4cm: Partial nephrectomy
- Selective embolization

Bladder cancer: 01:40:21

- Most common – Transitional cell (90%)
- 2nd – SCC (10%)
- 3rd Adenocancer (<2%)

↓

Urachal remnants

- Squamous cell cancer predisposed by
- S – Stone
- S – Schistosomiasis
- S – Special disease in bladder – Diverticula & Long-term catheter
- Transitional cell cancer predisposed by
- Most common risk factor – Smoking
- Associated with schistosomiasis
- Occupational cancer
  - Beta naphthylamine (Coal)
  - Diamino biphenyl (Aniline)
  - Amino biphenyl
  - Nitrophenyl

AfraTafreeh.com

- Most common presentation – Painless terminal hematuria

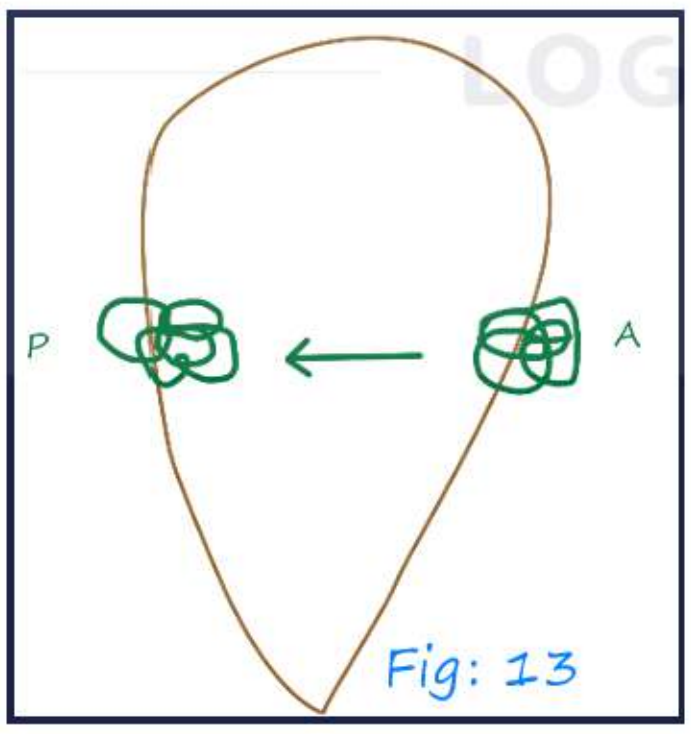

Fig: 13

- Due to rubbing of anterior & posterior wall cancer in anterior wall may go to posterior wall → Kissing cancer

AfraTafreeh.com

- Most common site – Dome and lateral wall

Investigation:

- Urine examination for special proteins → Screening test

↓

NMP2 protein

MCM protein

- IOC to stage – CECT abdomen & Pelvis
- Diagnostic IOC – Cystoscopy biopsy
- Most common node involved – Obturator node

Staging:

- Ta – Noninvasive papillary cancer
- Tis – Ca in situ
- T1 – Subepithelial connective tissue
- T2 – Muscularis propria involved
- T3 – Peri vesical tissue involved
- T4 – Adjacent organs – Prostate, seminal vesicles, vagina, abdominal wall

DX TUTORIALS LOGIN FOR SUCCESS

Cancer bladder

Noninvasive muscle cancer	Muscle invasive	In situ tumors
↓	↓	↓
Ta, T1	T2, T3, T4	Poor prognosis (<5%)
↓	↓	↓
Excellent prog (75%)	Worst prog (25%)	High risk of muscle invasion
↓	↓	↓
TURBT (TOC)	- Radical cystectomy f/b chemotherapy (or) - Neoadjuvant chemo f/b radical cystectomy	Initial treatment: BCG
↓		↓
Transurethral resection of bladder tumor		Not responding
↓		↓
BCG vaccine inside the bladder (Intravesical)		Cystectomy
↓		
↑ Recurrence seen in - High grade - T1 - Simultaneous in situ cancer - Multiple tumors		

Intravesical therapy

- Mitomycin C
- Doxorubin
- Thiotepa
- BCG (Best)

Structures removed radical cystectomy

- Bladder + Fat
- Prostate + Seminal vesicles

AfraTafreeh.com
TUTORIALS
LOGIN FOR SUCCESS

AfraTafreeh.com

- Uterus + Cervix + Fallopian tube + ant. vagina
- ± Urethrectomy
- Pelvic lymphadenectomy
- Implant ureter into conduit

Urinary conduit

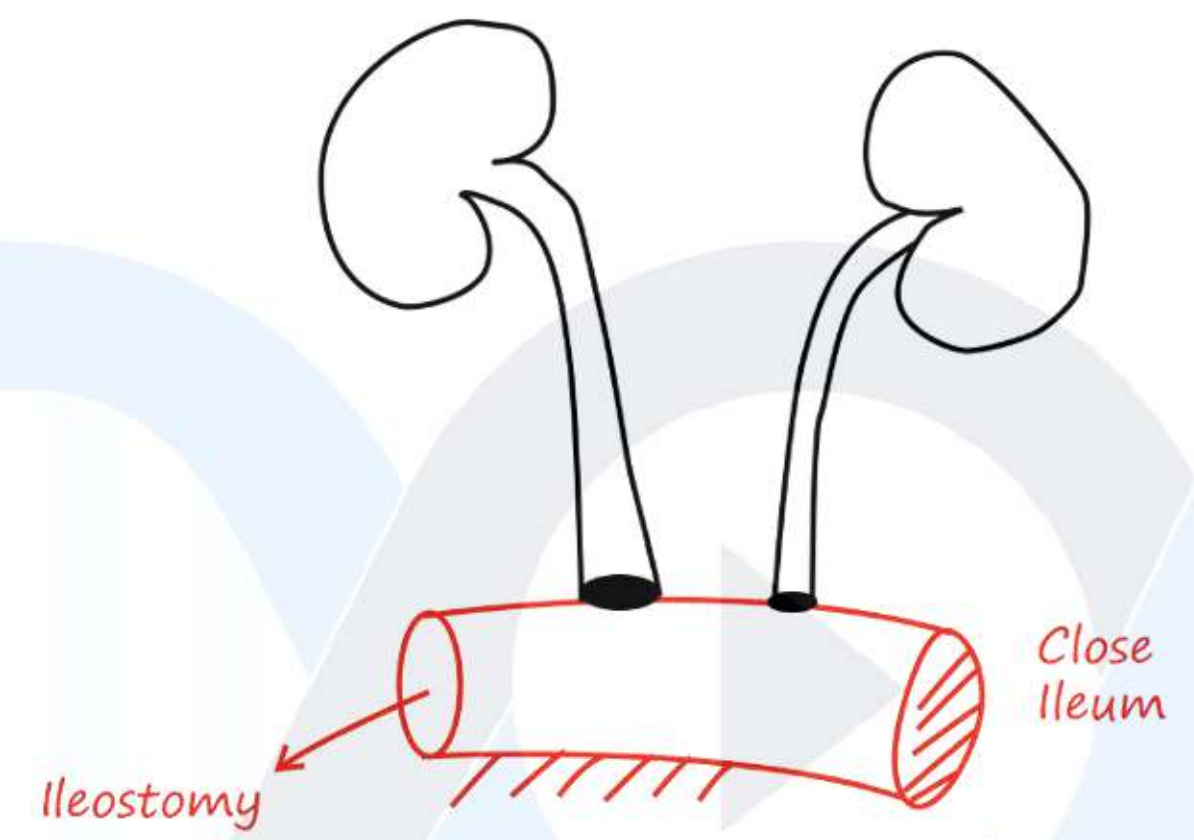

Fig: 14

- Most common used conduit – Ileum
- Most common complication – Uretero ileal stricture
- Colon conduit → Main advantage – No need of any stoma

stoma ↓ Most common complication ↓ Infection, Risk of malignancy

Main advantage ↓ Urine will be passed through anus ↓ Check normal anal continence by infusing 200ml of normal saline

If membranous urethra is not involved – neo bladder using ileum

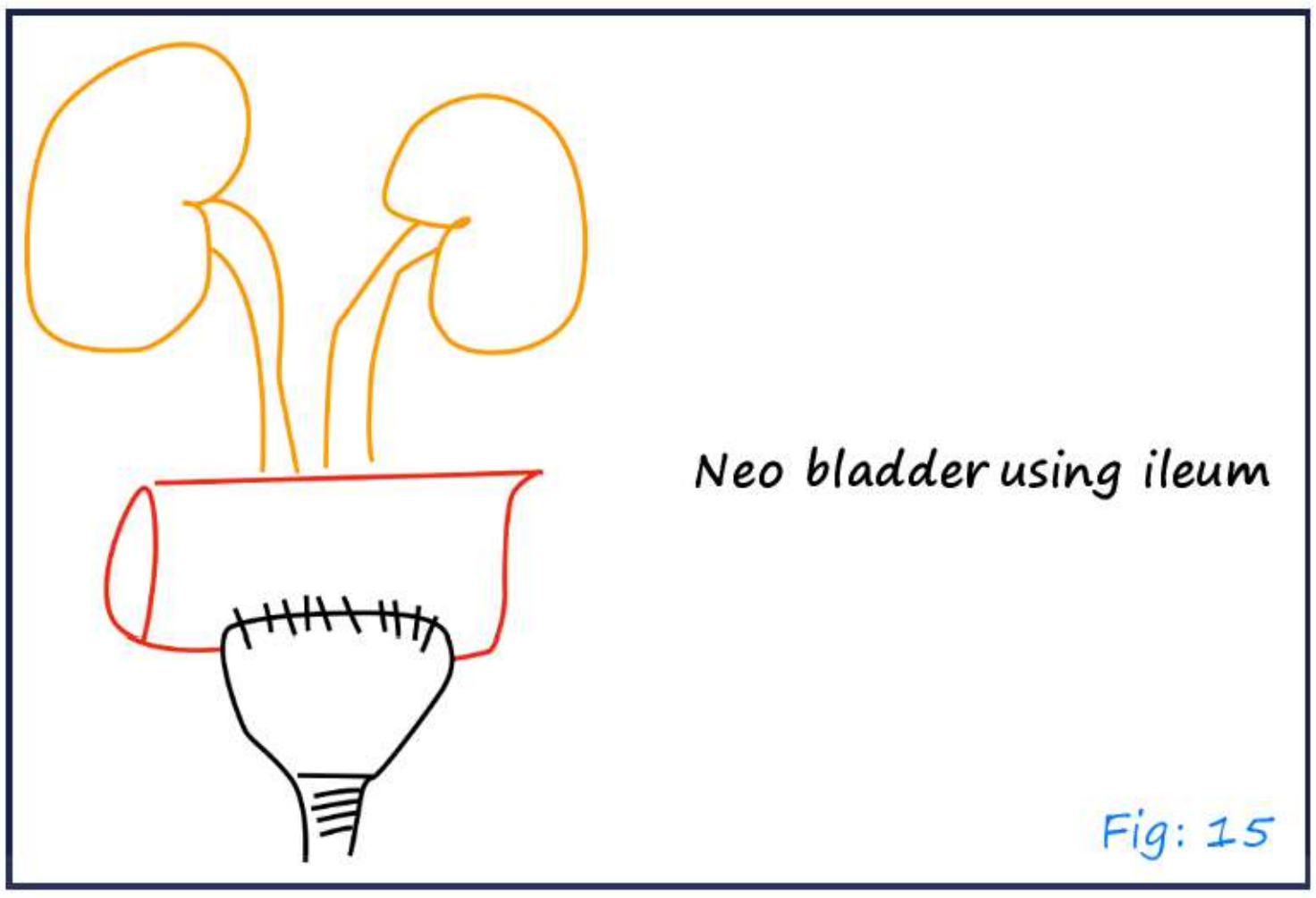

Fig: 15

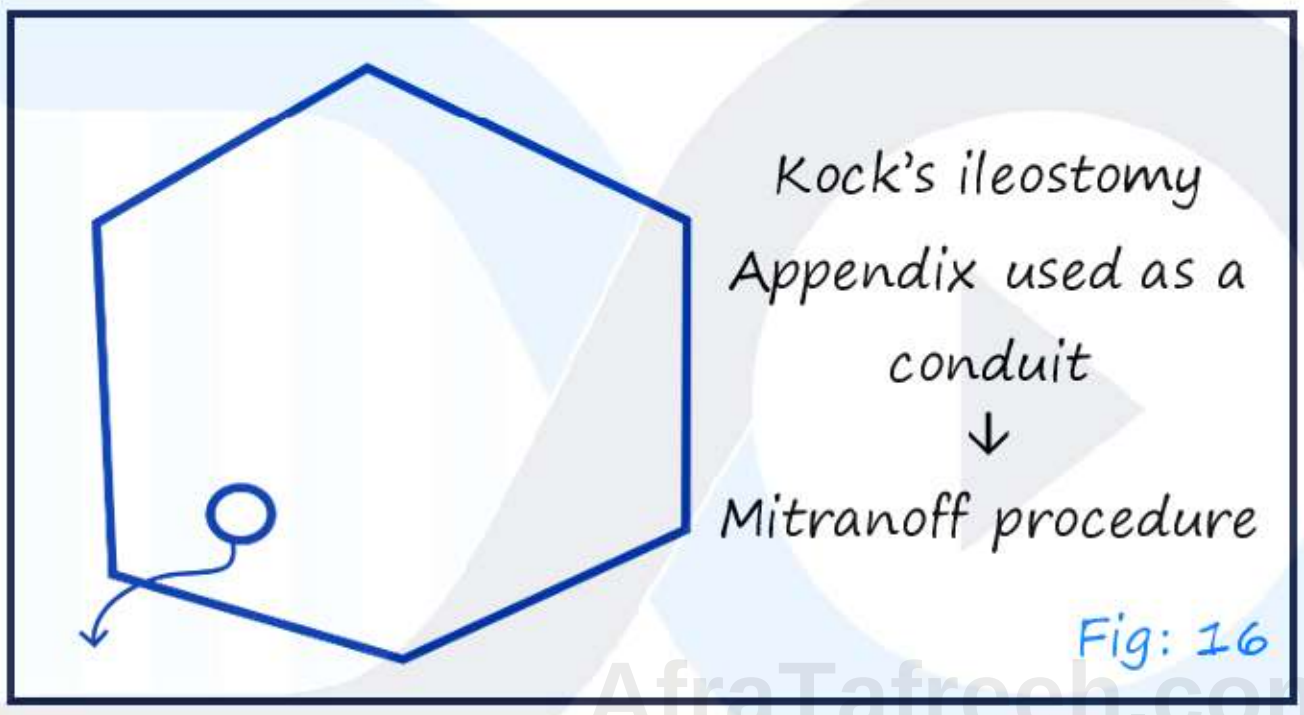

Fig: 16

- Conduits – Electrolyte imbalance
- Ileum – Metabolic acidosis + ↑ cl (↑ H^+, ↑cl^-)
- Jejunum – Metabolic acidosis + ↓cl
- Colon – Metabolic acidosis + ↑cl
- Stomach – Metabolic alkalosis + ↑cl
- Renal failure
- Mgmt; ↑H^+ & ↑cl^- → IV saline + $NaHco_3$

↓

Oral potassium citrate + $NaHco_3$ → TDS

AfraTafreeh.com

Chemotherapy 02:08:29

- GC regimen
- Gemcitabine + Cisplatin
- M-VAC (Old regimen)
- Methotrexate
- Vinblastine
- Actinomycin
- Cisplatin
- Post OP RT is not beneficial

Types	Genetic defects
Clear cell RCC	Loss of sequence in Chromosome 3 (VHL gene)
Papillary RCC	• Trisomy 7, 16 and 17 and loss of Y is male patients for Sporadic form • Trisomy 7 in the familial form • Due to mutated MET gene in Chromosome 7
Chromophobe RCC	• Multiple chromosome loss • Hypoploidy • Chromosome 1, 2, 6, 10, 13, 17, 21 and Y losses
Medullary RCC	Sickle cell trait

Infections in urinary tract

- Most common organism causing UTI – E. coli

- Kass criteria
- Men – >10^5 CFU/Ml of urine (MSU)
- Females – Catheterize → 10^3 CFU/Ml (+)
- Most common cause prostatis – E. coli

Renal TB 02:17:43

- Most common – kidney
- Ureter
- Bladder

(Most common – kidney, Ureter, Bladder) – by hematogenous route

- Earliest and most common features of renal TB → ↑ frequency of urine
- Do for increased frequency of urine
- DM
- UTI
- TB → D/E → Sterile pyuria +++
- No bacteria ↑↑ WBC
- Early morning urine sample x 3days → AFB
- Earliest feature of kidney is blunting of calyx

AfraTafreeh.com
TUTORIALS
LOGIN FOR SUCCESS

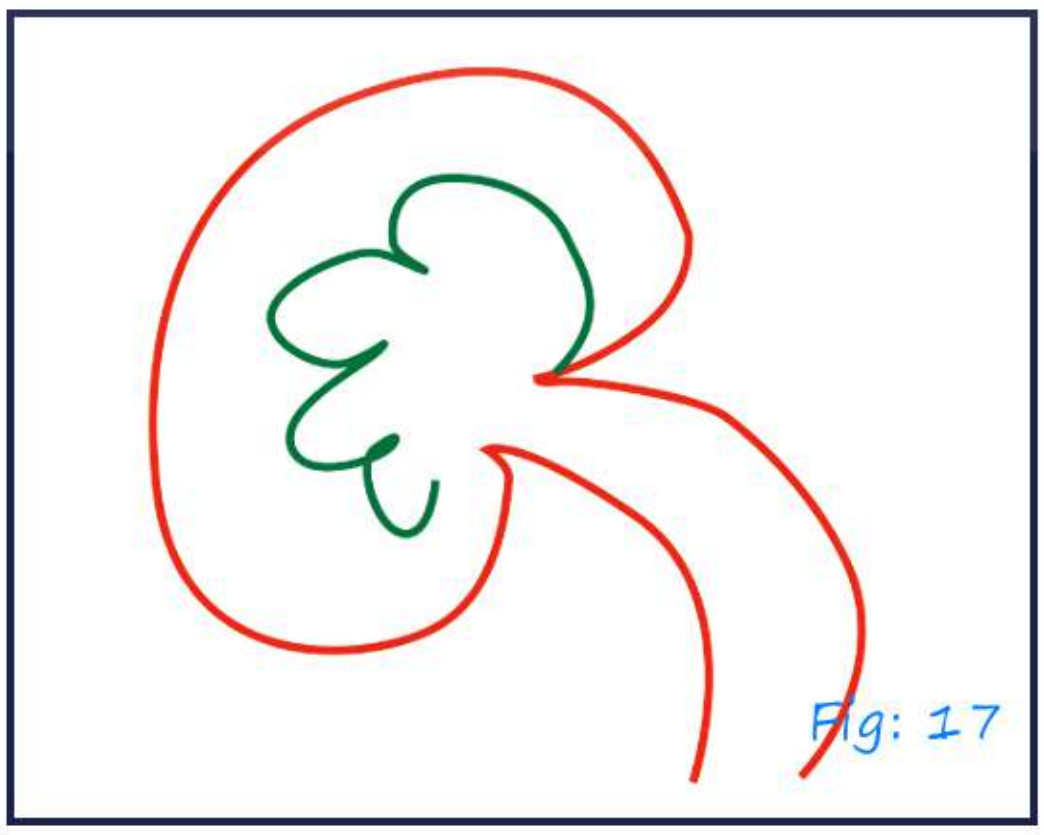

Fig: 17

AfraTafreeh.com

- IOC to diagnose early TB: old – IVP & New – CT pyelogram

Complications of chronic TB

- Cement/Putty kidney
- Golf hole ureter →

- Thimble small bladder
  ↓
  operate
- Optimum time of surgery → 6-12wks after ATT

Renal trauma

- Most common – Blunt injury
- Most common presentation – Hematuria (Omnious sign)
- IOC – CECT abdomen

Grades of renal trauma (AIIMS Q 2019)

- Grade I – Subcapsular hematoma (nonexpanding)
- Grade II – laceration <1cm –Hematoma confined to Gerota's fascia
- Grade III – Laceration > 1cm, no urine extravasation
- Grade IV – Laceration > 1cm urine extravasation (+) Injury to renal artery/vein

- Grade V – shattered kidney, Avulsion of Renal Hilum, Uretero pelvic avulsion Complete laceration of RA/ RV,

- IOC: CECT abdomen (stable) Laparotomy (unstable)

  ↓

  Nephrectomy

- 90% managed conservatively
- 10% need surgery

Renal trauma

↓

Stable

↓

CT abdomen

↓

Renal injury (+) → IVP is must → Normal → Discharge the PT

↓

In a stable pt, IVP – normal (L) kidney (R) kidney not able to visualize –do immediately explore renal hilum, do renal artery repair and do on table IVP

AfraTafreeh.com

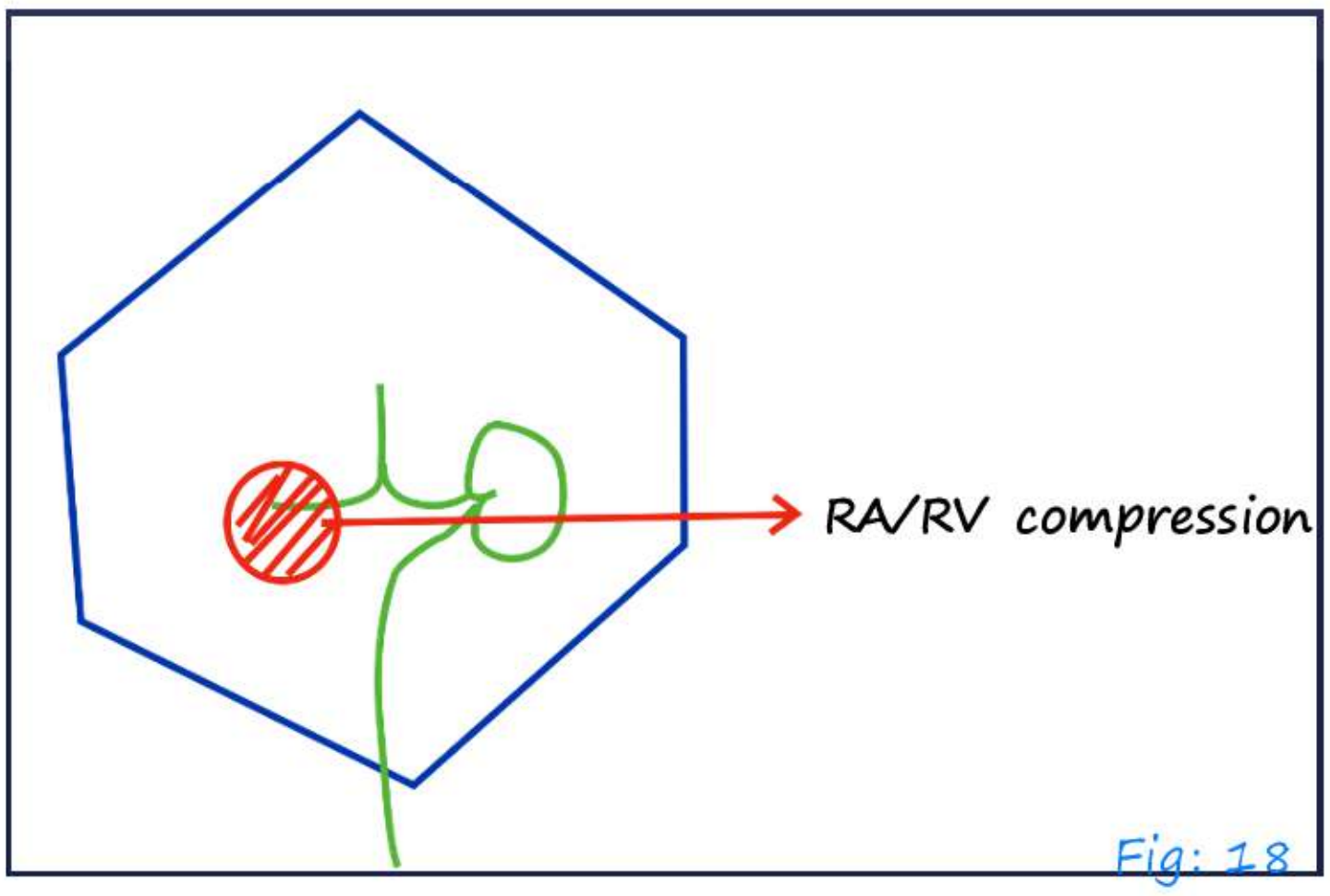

Fig: 18

AfraTafreeh.com

Injury to ureter 02:36:40

- Ureter is identified during surgery by its peristalsis
- On table → Injury to ureter → Repair it end to end by using 3'0 vicryl by keeping a stent inside

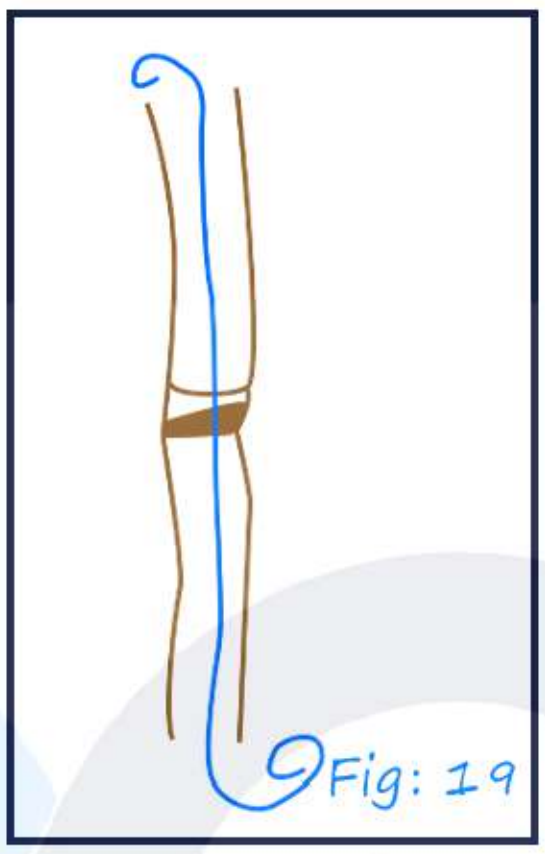
Fig: 19

- If the kidney ureter is far away and unable to approximate
- Flap with bladder wall and connect with ureter – Boari flap

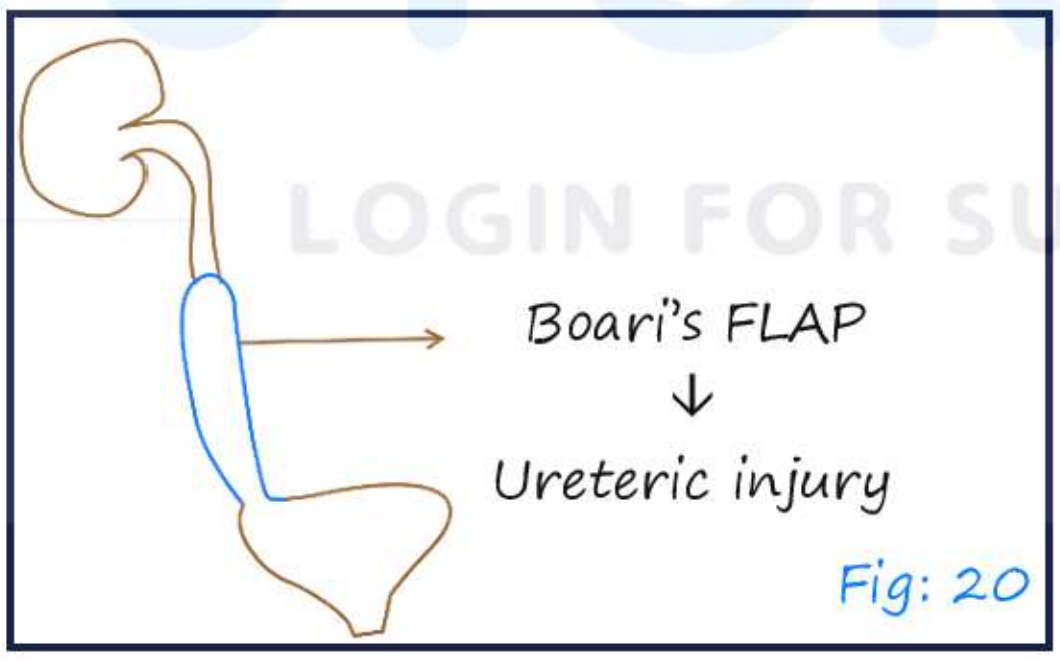

Fig: 20

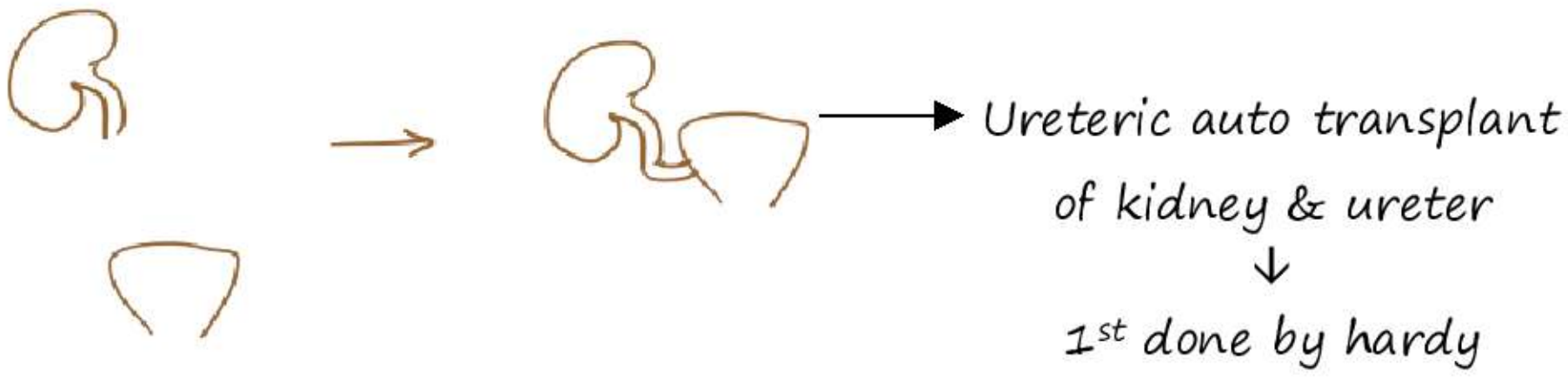

Ureteric auto transplant of kidney – kidney placed in pelvis

Bladder Injury 02:40:55

- Parts of bladder is intraperitoneal
- 2types of injuries to bladder → Intraperitoneal injury & Extraperitoneal rupture

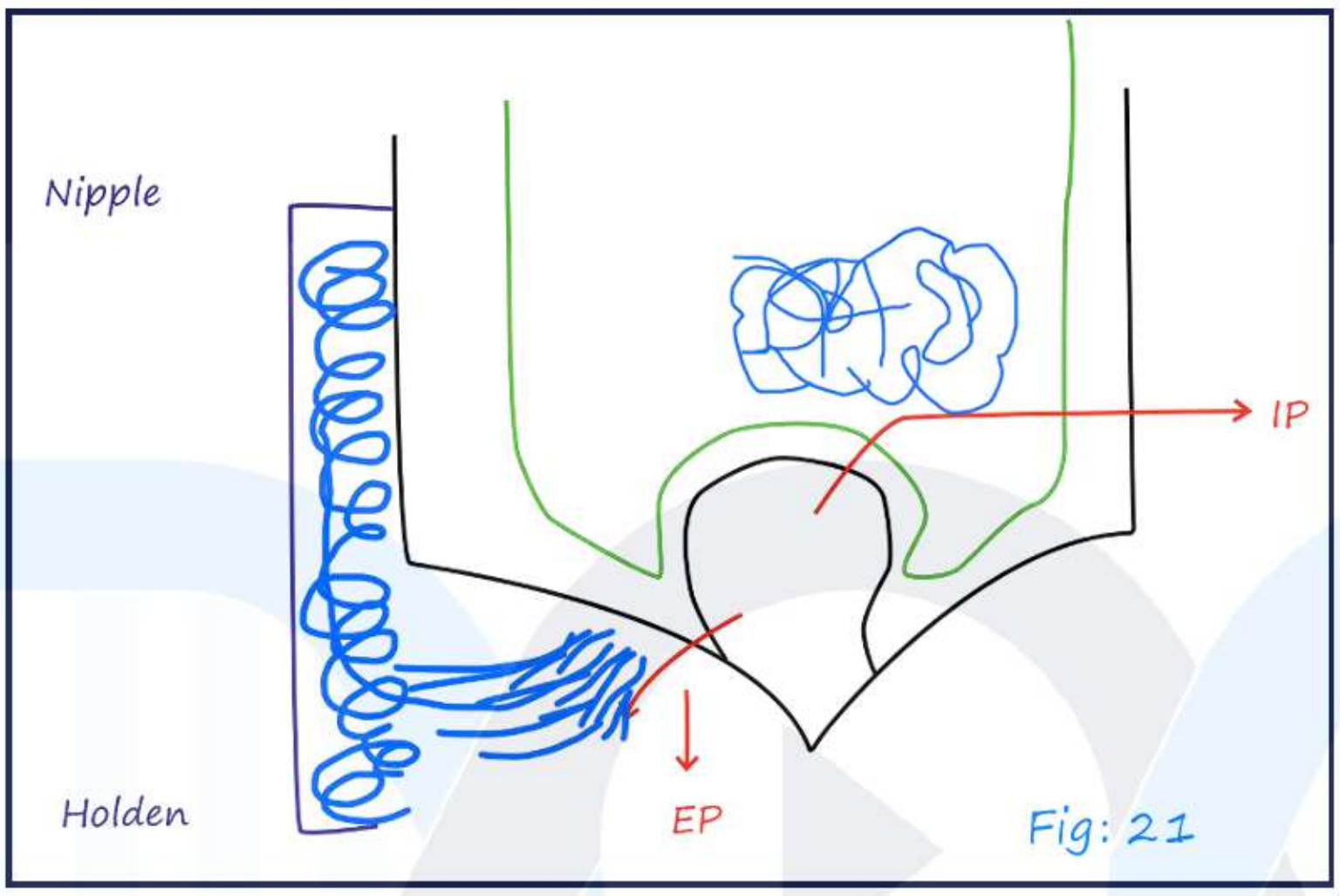

- Intraperitoneal rupture of bladder → Urine will extravasate into bladder
- Extraperitoneal → Urine will extravasate into subcutaneous plane and extend up to nipple level above and Holden line below
- Intraperitoneal rupture → Most common mechanism of injury → Direct blow

  ↓

  Uremic peritonitis

  ↓

  immediate surgery needed

- Extra peritoneal rupture → Most common mechanism → fracture of pelvis

AfraTafreeh.com

- IOC – Retrograde cystography
- Treatment: IP rupture → Repair immediately & EP rupture → wait and watch

Urethral injuries

Male urethra

- 20cm long
- Q. Most dilatable urethra – Prostatic urethra
- Q. Least dilatable urethra – Membranous urethra
- Q. Narrowest part – External urethral meatus
- In posterior urethra → Most common injured – Membranous urethra
- Mechanism - fractured pelvis
- Clinical infection – Blood at urethral meatus, bladder full
- P/R – Prostate high lying and floating - Vermooten sign
- Deep extravasation ++
- Inverted tear drop bladder

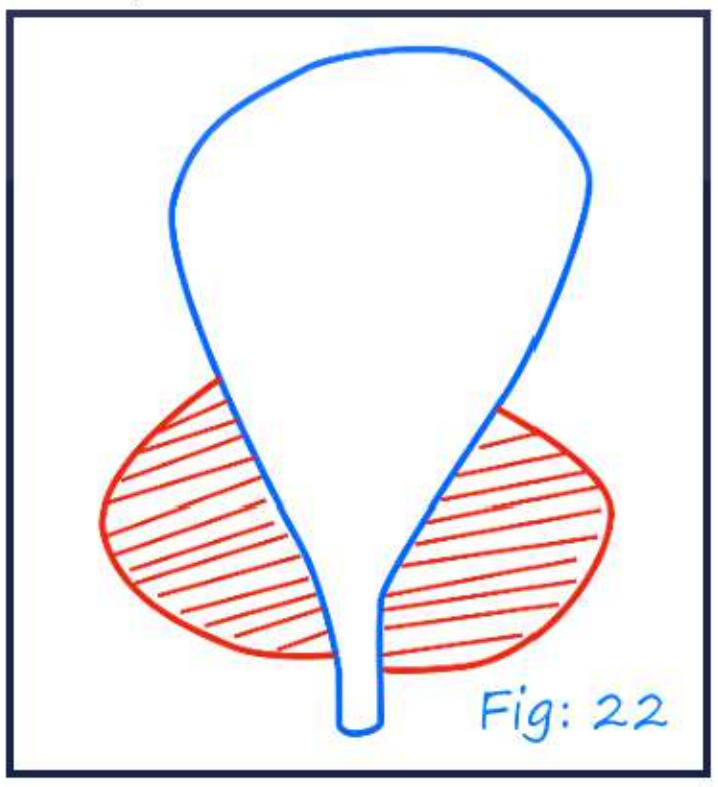

Fig: 22

Bulbar urethral injury

- Most common mechanism – Straddle

- Clinical – blood at meatus full bladder
- Don't put foley's catheter
- Use suprapubic catheter

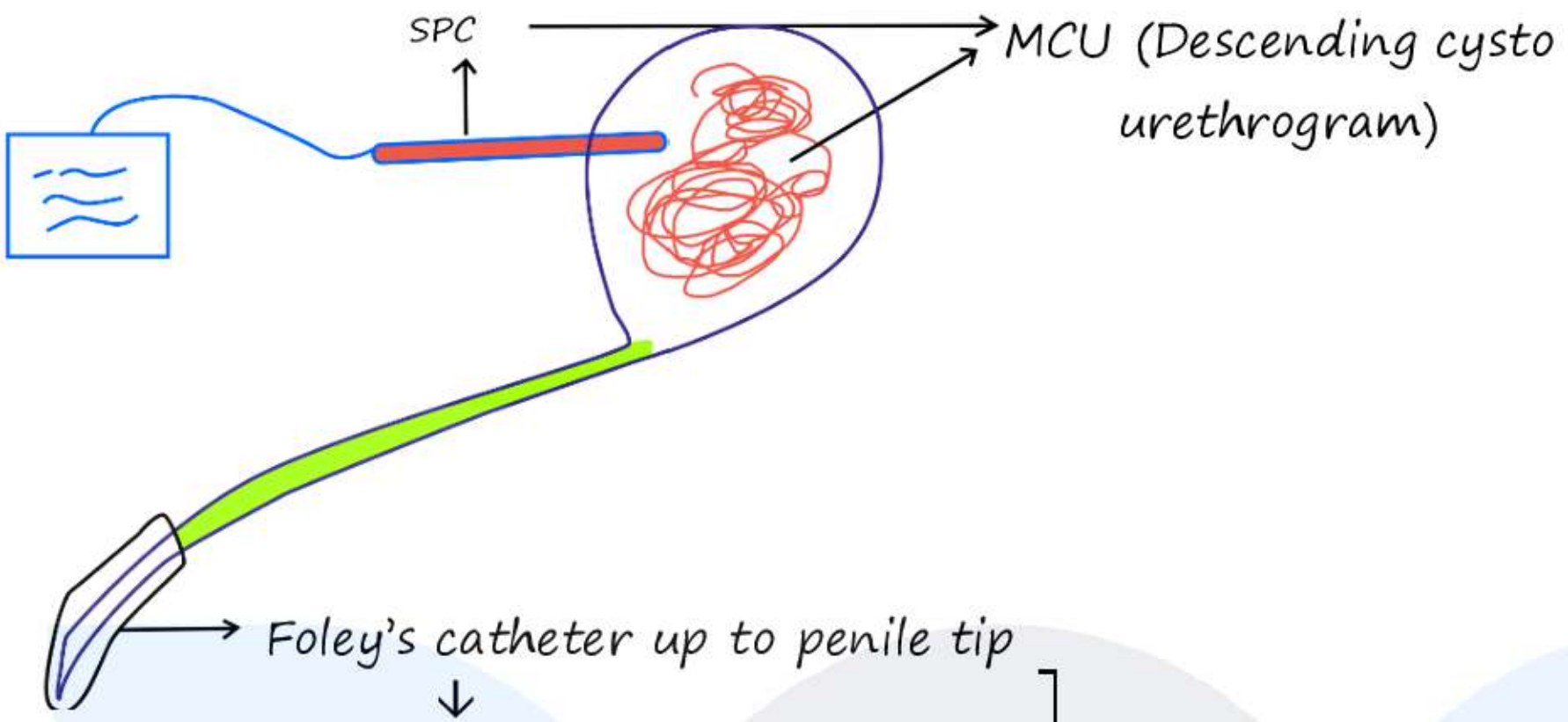

Foley's catheter up to penile tip
↓
Push the contrast
↓
Look for injury

] Retrograde urethrogram

MCU
↓
Contrast is through SPC
Bladder is full

RGU
↓
Contrast through foley's
Bladder incomplete

Wait for 6-8 weeks
↓
Urethral strictures

- Small
  ↓
  Dilators
- Multiple long
  ↓
  Stricturoplasty
  ↓
  Buccal mucosal flap is used

AfraTafreeh.com
TUTORIALS
LOGIN FOR SUCCESS

AfraTafreeh.com

Congenital anomalies 03:03:14

- PCKD (M=F)
- Ectopic ureter → Most common in females
- Congenital PUJ obstruction
- Ureterocele → Most common in females
- horse shoe kidney
- VUR → Congenital & Acquired (Most common in females)
- Ectopia Verica

Ectopic ureters

- Most common anomaly – Duplication of renal pelvis and ureter U/L > B/L

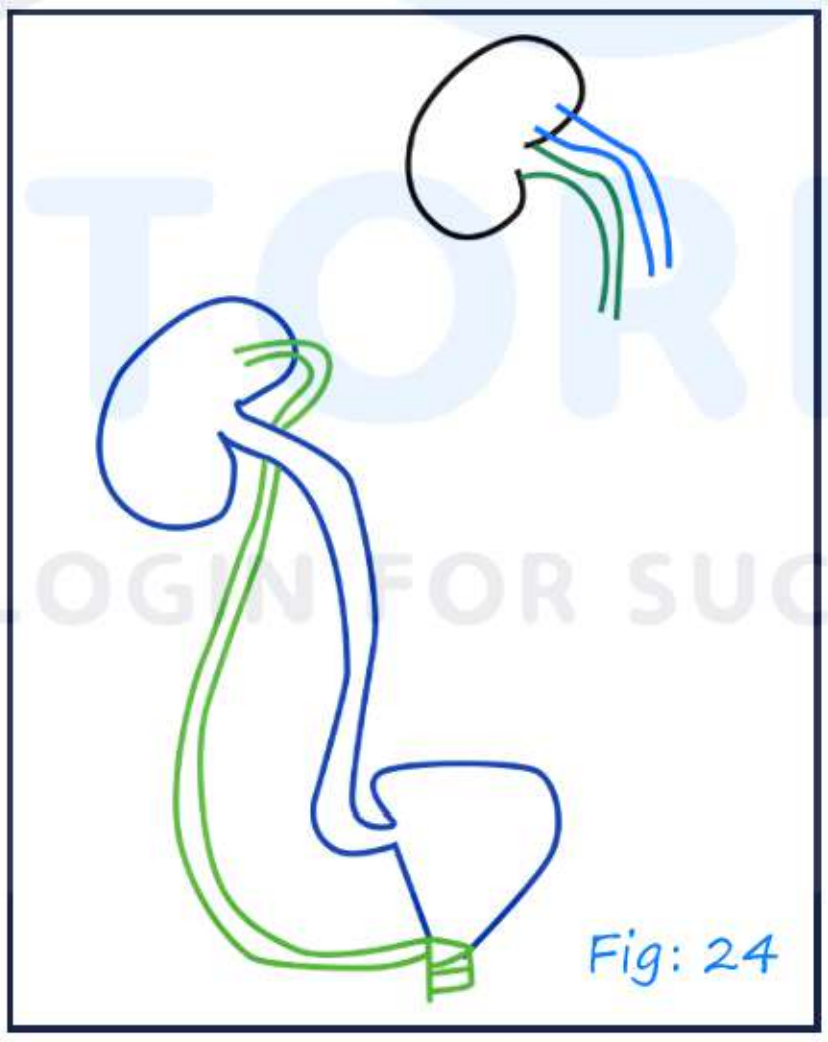

Fig: 24

- Ectopic ureter usually arises from upper pole and run downwards laterally outwards and joins distally
- UTI → Boys – Prostatic urethra
- Girls → urethra (Distal to EUS)→ Paradoxical urinary incontinence (+)

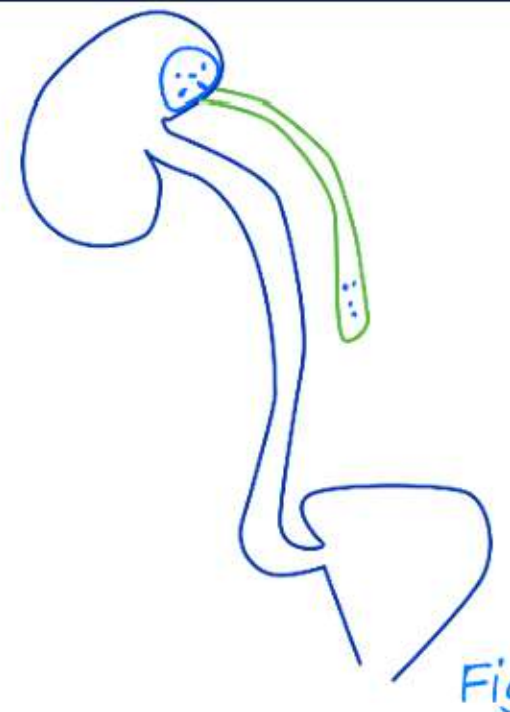

Fig: 25

- Upper pole ureter is obstructed

  ↓

  Stagnation of urine in upper pole

  ↓

  Ureterocele

- normal ureter develops VUR
- Weigert meyer rule – Upper role is usually an ectopic ureter and its orifice inserts infero-medial to normal opening

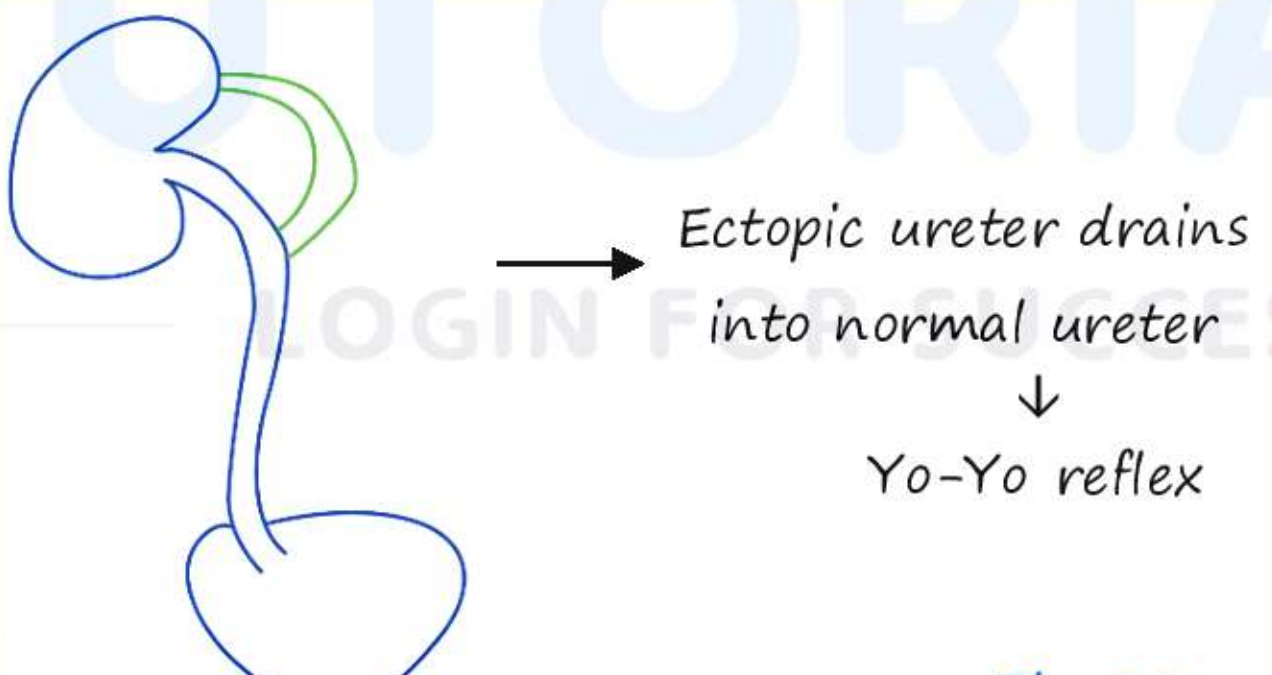

Fig: 26

- IVP – Diagnostic of ectopic ureter

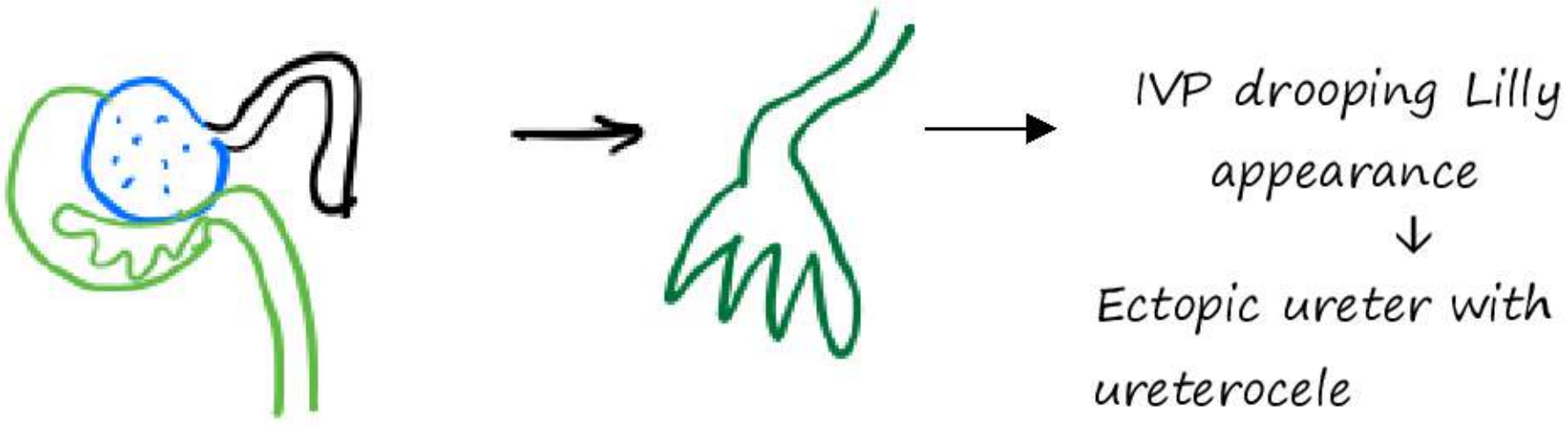

DOC TUTORIALS LOGIN FOR SUCCESS AllaTafreen.com

AfraTafreeh.com

Polycystic kidney disease

- 2 types
  - Adult
  - Infantile (<1yr) → AR-die

Adult PCKD

- Autosomal dominant
- Criteria's to diagnose
- USG – 1kidney – 3cysts (or) Bilateral kidney – 2 in each
- Clinical features – Always B/L (95%)
- 1/400 – 1/1000
- Manifest before 40yrs → HTN can be seen 20yrs onwards
- kidney failure → 40yrs onwards
- On palpation – Kidney will be enlarged.

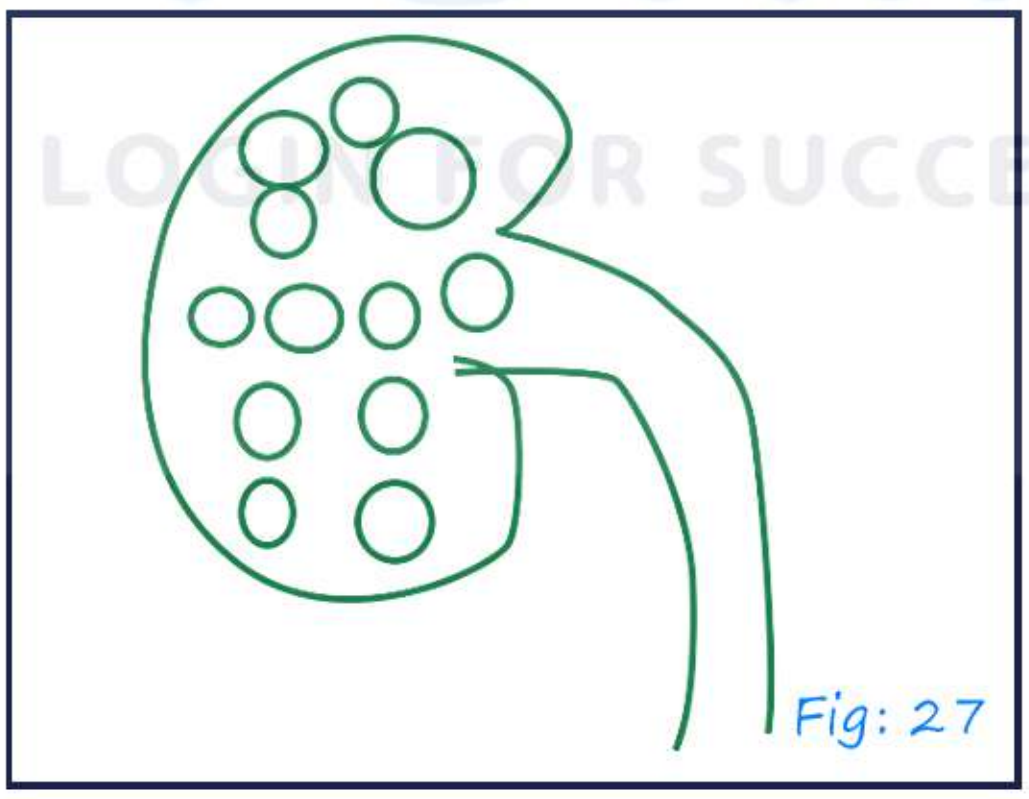

Fig: 27

- Rare clinical features – Hematuria
  Kidney stones (Most common uric acid) (20%)

ESRF → Most common in M>F

Dialysis

Associated anomalies

- Cysts in → Liver
  Spleen
  Pancreas
  Ovary
  Not in lungs
- Berry aneurysm
- MVPS (Mitral valve prolapse syndrome)
- Colonic diverticulitis → Sudden abdominal pain
- Liver fibrosis

AfraTafreeh.com

Treatment

- Olden days → Rovsing's operation
- Tolvaptan → Vasopressin receptor antagonist
  → First approved drug
  → ↑ urine excretion
  → ↑ Na^+ content in body
  → Used for cirrhosis, heart failure pts
- TOC: Transplant

Congenital PUJ obstruction

- Most common cause of congenital hydronephrosis
- Cause unknown
- Abnormal renal artery/Renal vein may be seen

AfraTafreeh.com

- Most common in boys
- U/L but 40% cases B/L
- Pressure at renal (High) pelvis and Bladder (Low) are measured
- Whitaker test
- Treatment – Aderson's Hynes pyeloplasty

Vesicoureteric reflux

- May be → Congenital – boys or Acquired – Girls
- Urine from bladder reflex above
- Longitudinal bladder muscle is deficiency

International classification of Vesicoureteric reflux

- Grade I: Reflux in to non-dilated ureter
- Grade II: Reflux going back in to collecting system (Non dilated ureter)
- Grade III: Dilated ureter blunting of calyx seen
- Grade IV: Grossly dilated ureter
- Grade V: Renal injury

TUTORIALS LOGIN FOR SUCCESS

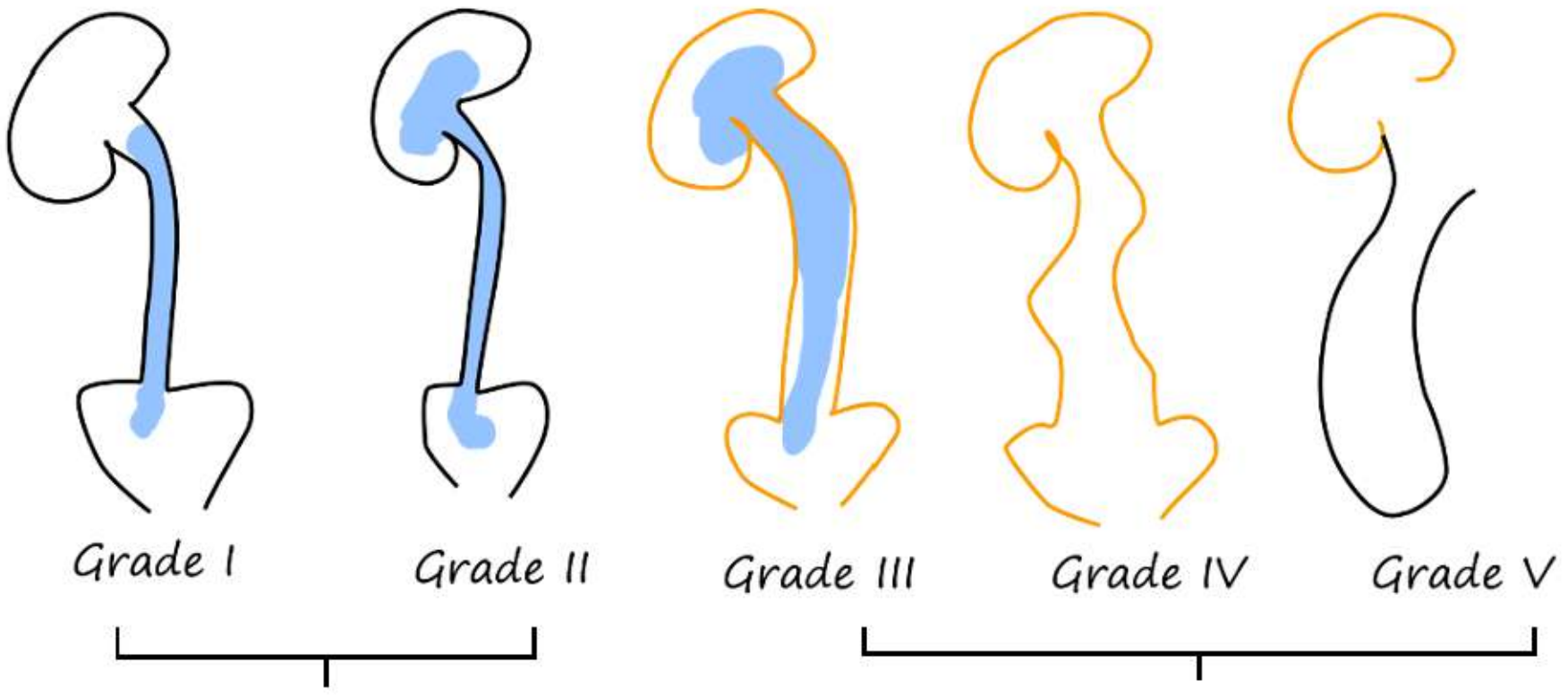

No surgery needed
UTI: antibiotics
↓
Not responding to antibodies → Operate these cases

B/L (Grade III) B/L (Grade IV) U/L (Grade V)

- Treatment reimplants the ureter
- IOC – MUC

Disease	IOC
1. Ectopic ureter	IVP
2. ADPKD	CT KUB
3. Congenital PUJ obstruction	MAG – 3
4. VUR	MCU

Horse shoe kidney 03:32:53

- 1/1000
- Most common in men
- Usually fused at lower pole at level of L4
- Clinical features – Asymptomatic
- Isthmus is cut only during abdominal aortic aneurysm surgery

AfraTafreeh.com TUTORIALS LOGIN FOR SUCCESS

AfraTafreeh.com

- IVP: Flower vase appearance & Hand shake
- Pregnancy is not contraindication → ↑ UTI (+)

Ectopia vesica 03:35:50

- Also known as exstrophy
- Cloacal membrane overdevelops and ruptures
- Huge defect in anterior abdominal wall

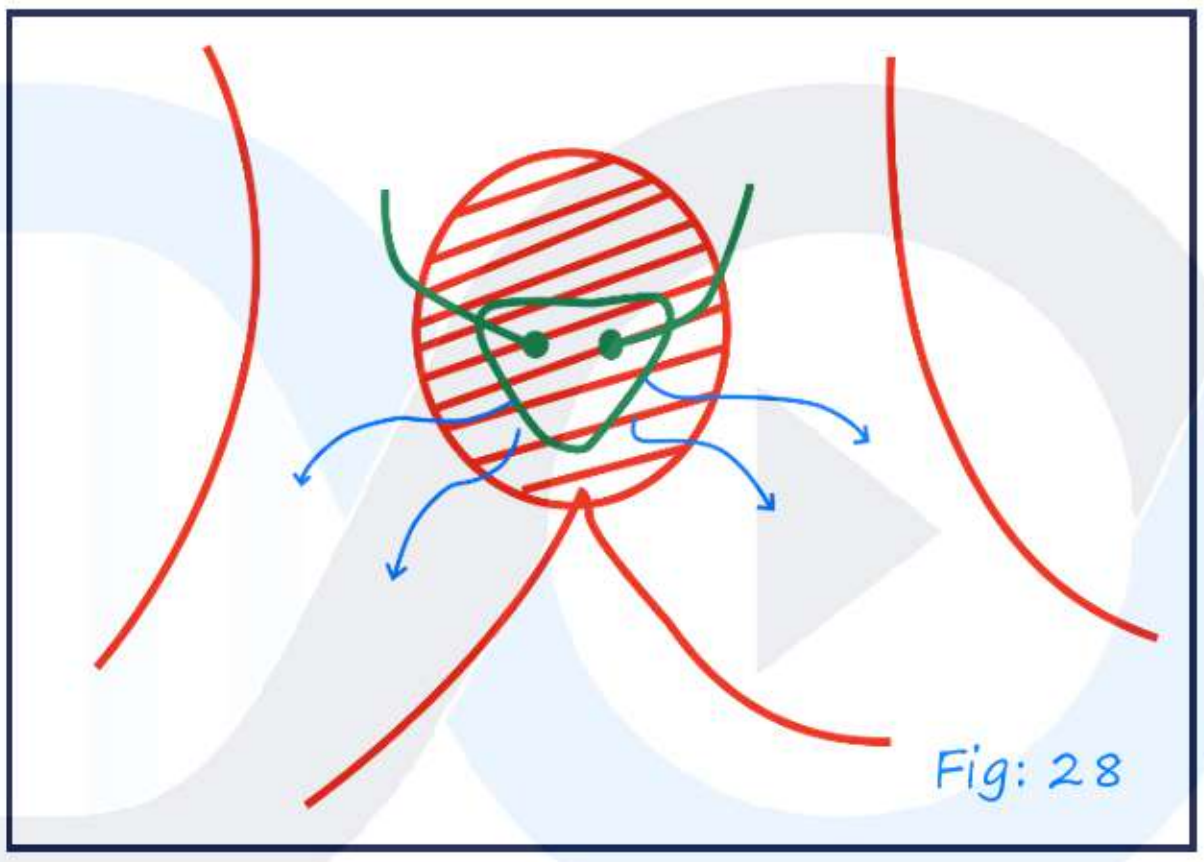

Fig: 28

- Posterior wall with ureteric orifice is seen anterior wall absent directly see the posterior wall

Associated anomalies

- Males
  - Umbilical hernia
  - Inguinal hernia
  - Epispadias
  - Undescended testis
- Females
  - Umbilical hernia
  - Epispadias

- Split clitoris
- Wide open pelvis (Duck gait)
- Wide labia

- Urinary incontinence
- Increased risk of bladder cancer

Rx: plastic surgery reconstruction

Ureterocele

- Lower pole of ureter dilated
- IVP – Cobra head appearance

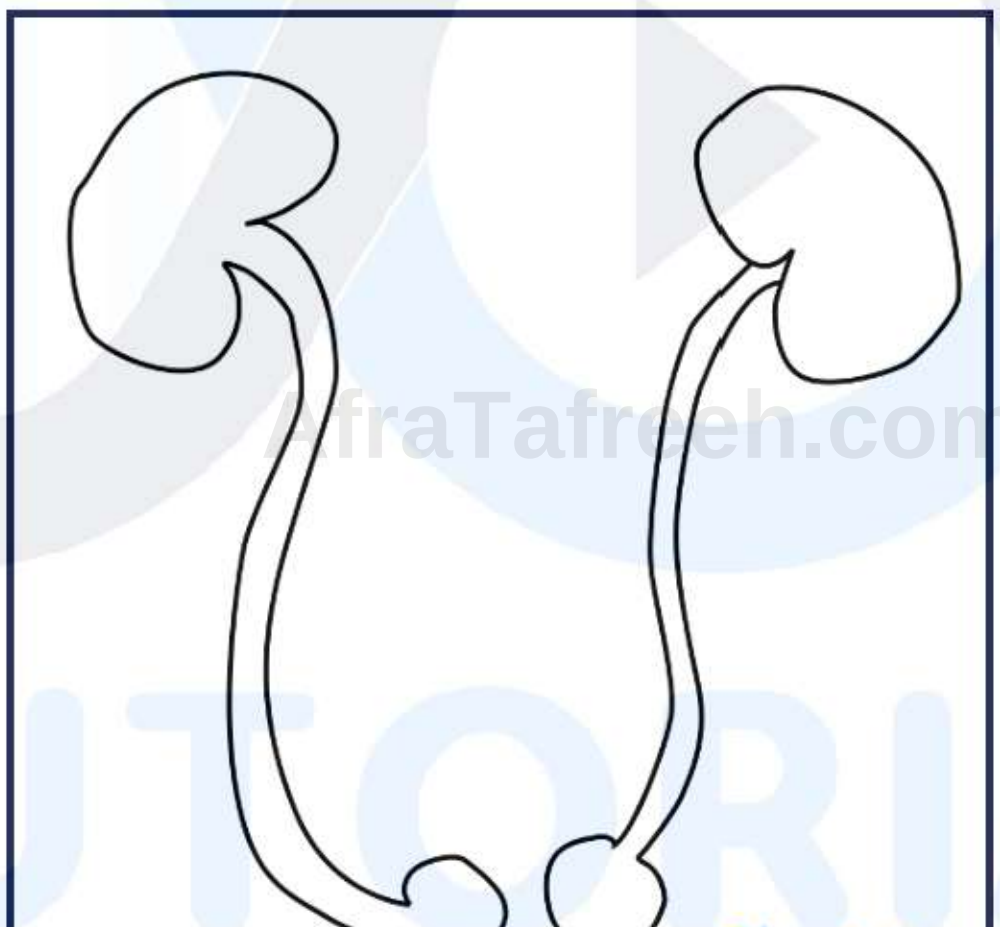

Fig: 29

- Stagnation of urine → Infection
- Most common in females
- 10% B/L
- Most common presentation – UTI
- Treatment – Ureteric reimplantation

DOC TUTORIALS LOGIN FOR SUCCESS AfraTafreeh.com

AfraTafreeh.com

Disease	Sex
Polycystic kidney disease	No sex predilection
Ectopic ureter	Females
Congenital PUJ obstruction	Males
Ureterocele	Females
Horse shoe kidney	Males
Congenital VUR	Males (Acquired VUR in females)
Ectopia vesica	Males

TUTORIALS
LOGIN FOR SUCCESS

URLOGY - II

Anatomy of prostate 00:00:15

- 3 zones

  Mc Neal's classification

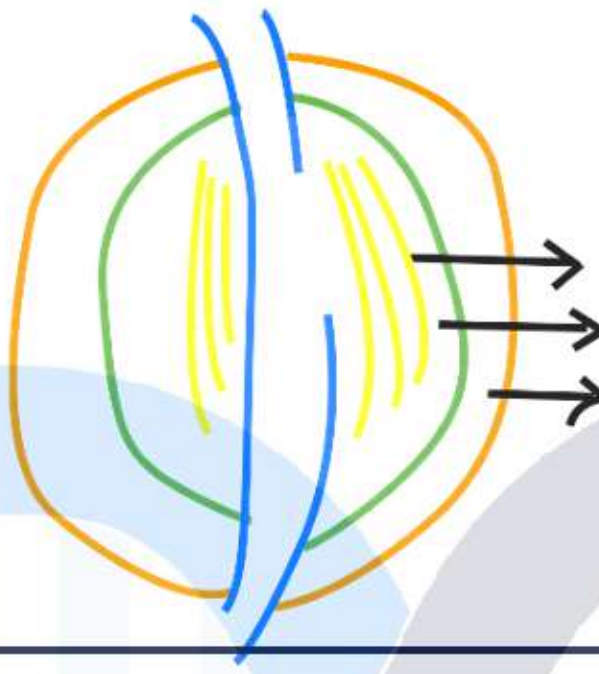

Fig: 1

- Transition zone consists of urethra
- Most common zone involved in BPH – transition zone (median lobe)
- Most common zone involved in malignancy – peripheral zone (posterior lobe)
- 5 lobes
  - 2 lateral lobes
  - 1 median lobe
  - 1 posterior lobe
  - 1 anterior lobe
- BPH
  - Disease of old age
  - Problems → bladder outlet obstruction
- Ca prostate
  - Old age

TUTORIALS
LOGIN FOR SUCCESS

AfraTafreeh.com

- Hormone dependent (increase androgen)

- Prostatic calculi

  Most common type of calculi in

  - Prostate → calcium phosphate
  - Kidney → Calcium oxalate
  - Bladder → ammonium urate
  - Gall bladder → mixed stones

- Prostatitis

  - Caused by E. coli
  - Treatment: antibiotic for 4 weeks

Bladder outlet obstruction 00:07:28

Symptoms

Irritative ↓

- Most common
- Increase frequency of urination
- Nocturia
- Urgency
- Hesitancy
- hematuria

Obstructive ↓

- Dribbling of urine
- Thin stream of urine
- Retention of urine

- IOC: - uroflowmetry

  200ml bladder filled

  ↓

  Urine flow rate: - >15ml/sec
  Bladder pressure: - <60cmH2o
  (voiding)
  } normal

  ↓

  <10ml/sec
  >80cmH2O
  } Diagnosis of BOO

  USG Abdomen: - Prostate enlargement

Post void residual urine

Look for B/L hydro ureter nephrosis

- Medical treatment

Increase size of prostate

↓

5α reductase inhibitor

6 months – 40% reduction

↓

Finasteride 5mg

Open bladder neck

(Relax smooth)

↓

α1 A blocker

↓

Tamsulosin

↓

Quick action

Prazosin and Terazosin:

Not used now as they

cause postural hypotension

-finasteride 1mg used Male pattern alopecia

Indications of surgery 00:15:27

- Retention of urine
  - Acute
  - Chronic (PVP > 200ml)
- Complication of BOO
  - Diverticula
  - B/L HUN
  - Bladder stones
  - Hematuria
  - Recurrent UTI
- Uroflowmetry
  - <10ml/s
  - >80cm H2o

AfraTafreeh.com
TUTORIALS
LOGIN FOR SUCCESS

AfraTafreeh.com

Surgeries 00:17:42

1.TURP (Gold standard)

2.Open prostatectomy

- Retropubic approach → Milan's (most common)
- Transcervical approach → Freyer' s
- Perineal approach → young

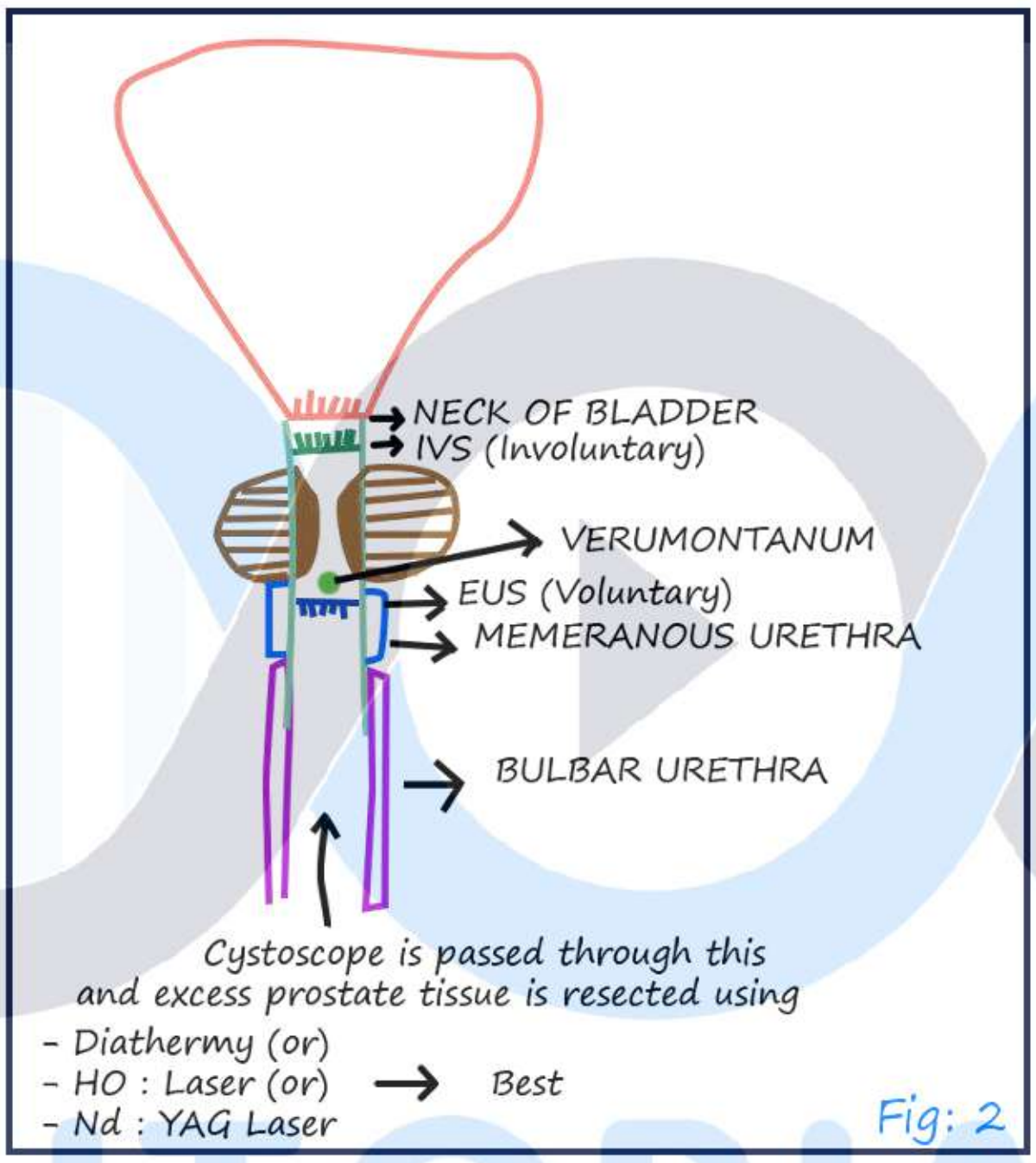

Fig: 2

- Below the neck of bladder, we start resecting
- Distal limit of TURP: - verumontanum

↓

beyond verumontanum → we might injure EUS → incontinence (worst complication)

IUS→ retrograde ejaculation

- Bladder neck injury: - bladder neck stenosis → symptoms same as BOO
- During surgery

↓

Monopolar diathermy used

↓

Fluid used to wash the area

-1.5% isotonic glycine

- distilled water

- NS not used if using monopolar diathermy

- NS used if using bipolar diathermy/laser

- Now a days, HO laser used → HOLEP

↓

Holmium laser enucleation of prostate

TULIP→transurethral USG laser induced prostatectomy

After procedure, patient is shifted to ward with 3 lumen 18G

Foley's catheter

- 1 lumen – inflate balloon
- 1 lumen – wash
- 1 lumen – urine drained

AfraTafreeh.com
TUTORIALS
LOGIN FOR SUCCESS

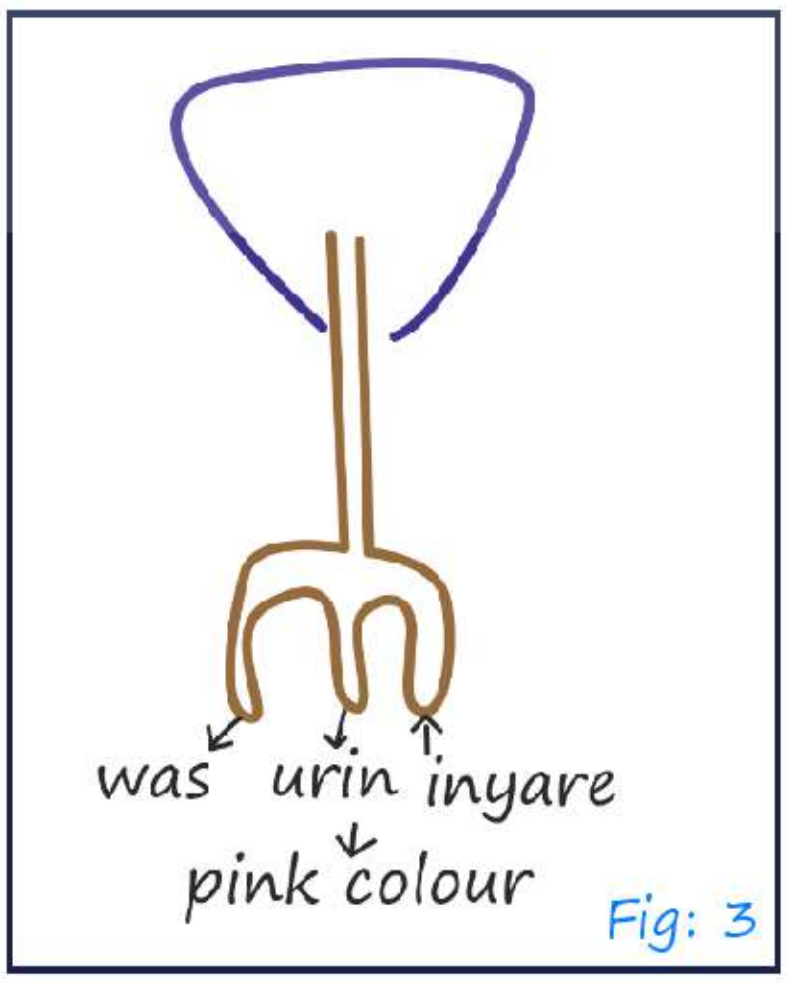

Fig: 3

- Post op fluid of choice for irrigation – normal saline

AfraTafreeh.com

- Immediate post op complication
  - Severe hemorrhage: - FLOCH arteries → inferior vesical artery
  - TUR syndrome: - confused, irrelevant
    ↓
    Dilutional hyponatremia- water intoxication
- Delayed complication
  - Bladder neck stenosis
  - Retrograde ejaculation (most common)
  - Incontinency

Cancer prostate 00:32:59

- BOO + Back pain
- Screening: - DRE + PSA
- PSA: - normal: <4ng/ml → biopsy
  - PSA >10ng/ml: - localized cancer
    >35ng/ml: - metastasis
  - PSA velocity/recently measure
  - PSA density

TUTORIALS LOGIN FOR SUCCESS

Biopsy 00:35:32

- TRUS guided BX
- Trans perineal template biopsy (TPTBT)

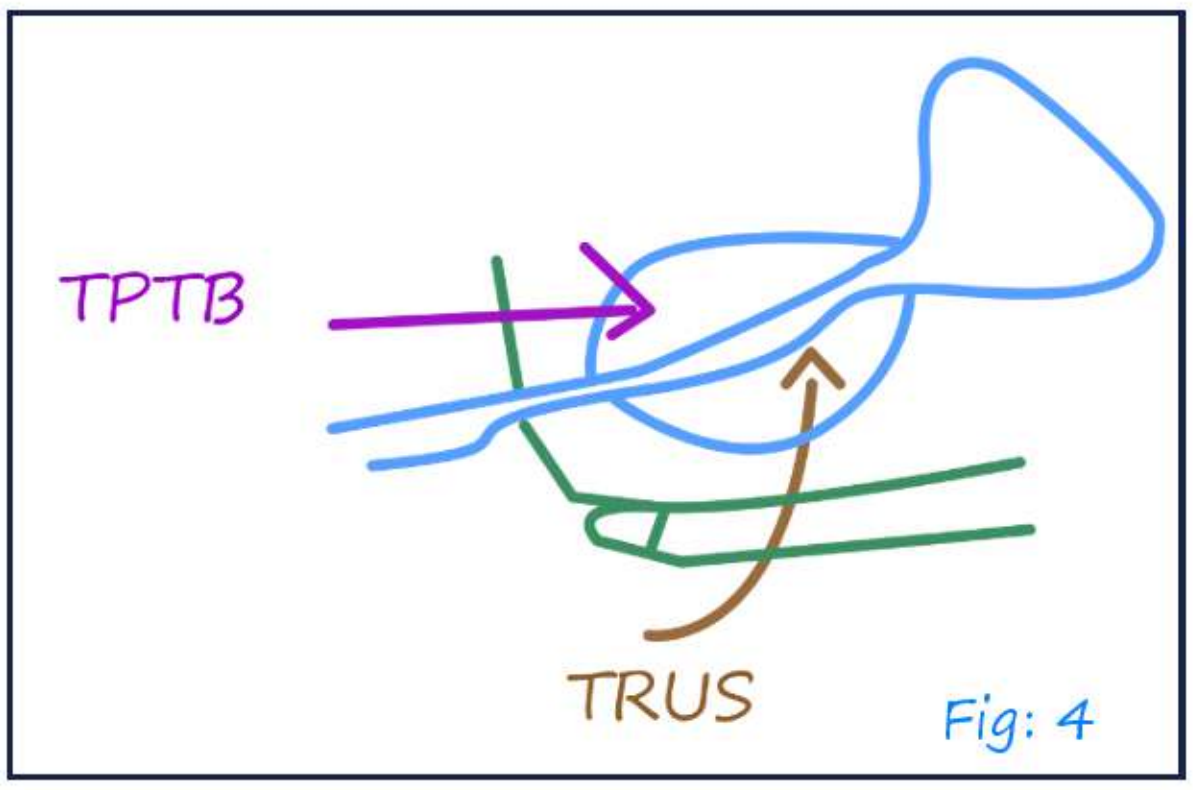

Fig: 4

TRUS

- Traditional
- Increase risk of infection
- Prophylactic antibiotics to be given
- Less areas biopsy possible

TPTBP

- Anterior biopsy possible
- 36 biopsies possible
- No infection

IOC to stage prostatic cancer

- CECT Abdomen and pelvis
- 1st node involved: - obturator node

T staging 00:39:00

- T1 – detected on TURP spe
- T1a: - <5% has malignancy
- T1b: - >5% has malignancy
- T1c: - PSA increase

AfroTafreeh.com
TUTORIALS
LOGIN FOR SUCCESS

AfraTafreeh.com

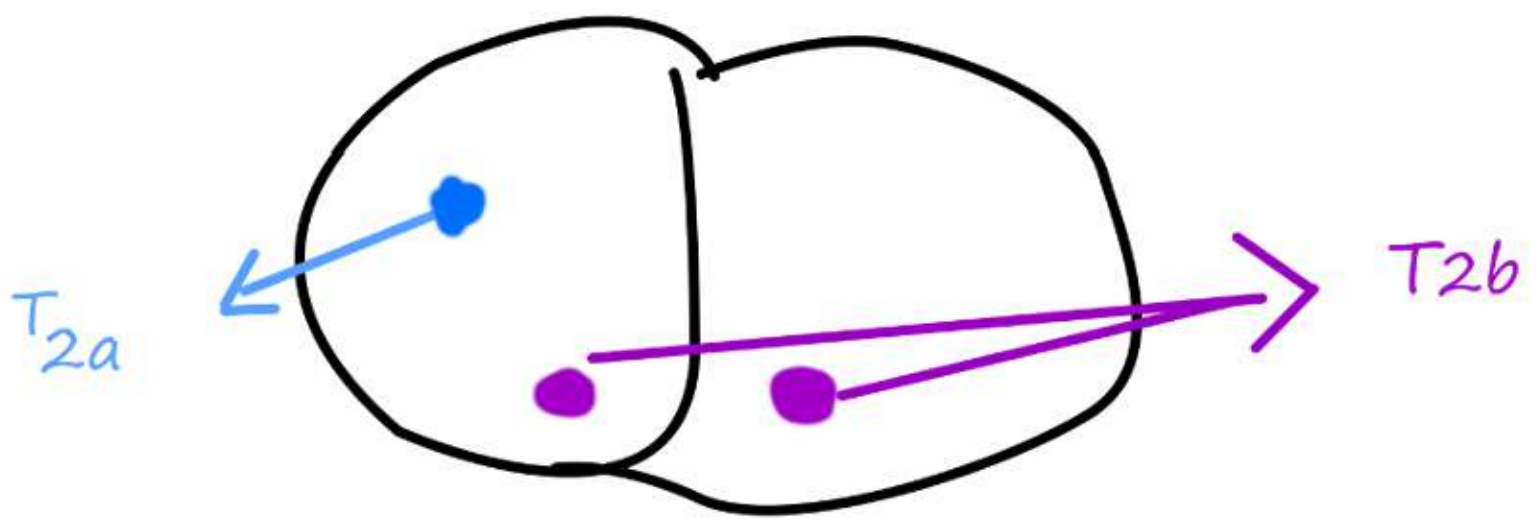

- T2 – DRE
- T2a – involving one lobe
- T2b – involving both lobes

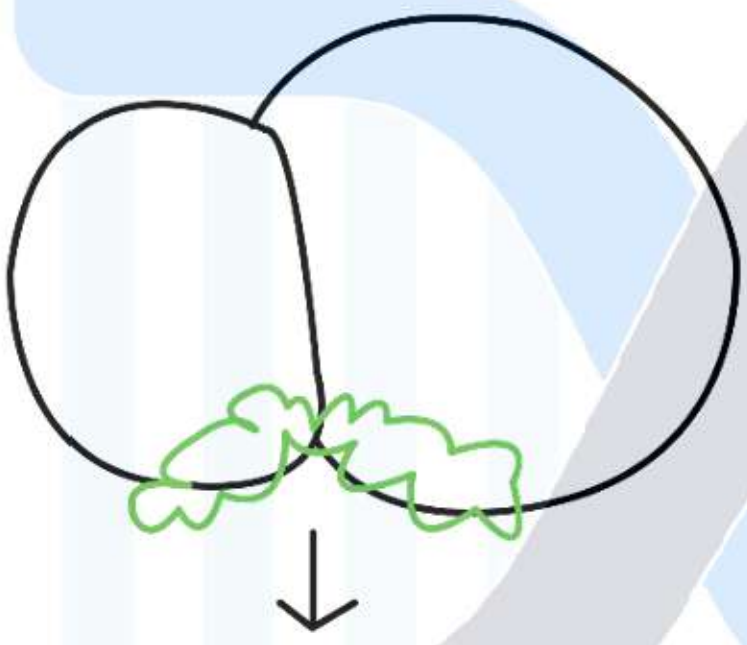

- T3 – involving the adjacent structure

  ↓

  Seminal vesicle involved and spread beyond cap
- T4 – locally advanced cancer gone to bladder neck, rectum, pelvic bone

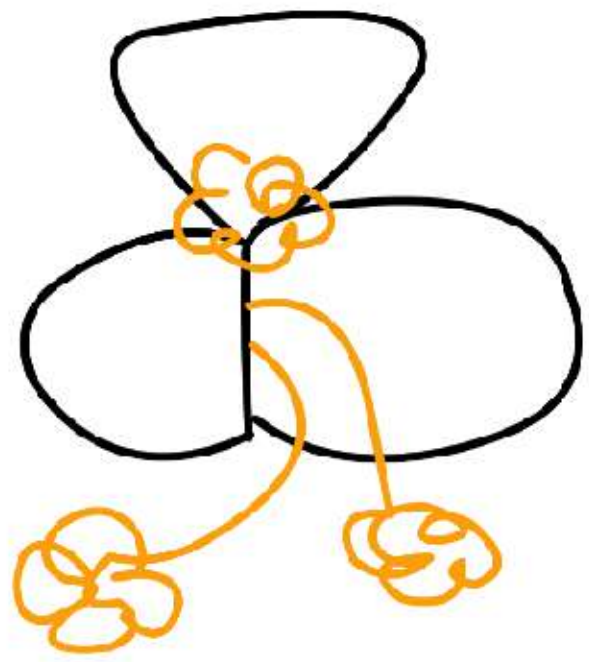

- T1, T2 – early disease

- T3, T4 – locally advanced disease

Management

- T1, T2 – radical prostatectomy → <70 years
  → fit for surgery
- T3, T4, M1 – Androgen ablation therapy
  – gold standard: - subcapsular orchidectomy
  – LHRH agonists: - flutamide
  – leuprolide
  – gosereline
- A man > 70 years unfit for surgery
  – T1 T2 prostatic cancer → wait and watch

Gleason's score → Adenocancer 00:47:16

- Grade 1 – small uniform glands/well differentiated



- Grade 2 – more space between glands

- Grade 3 – distinct infiltration of cells in margin



- Grade 4 – irregular masses
- Grade 5 – lack of gland pattern

frsTutorials.com TUTORIALS LOGIN FOR SUCCESS

AfraTafreeh.com

- Gleason's new scoring system extends from score 1-10
- Most common site of mets – lumbar osteoblastic secondary's

Male infertility 00:51:00

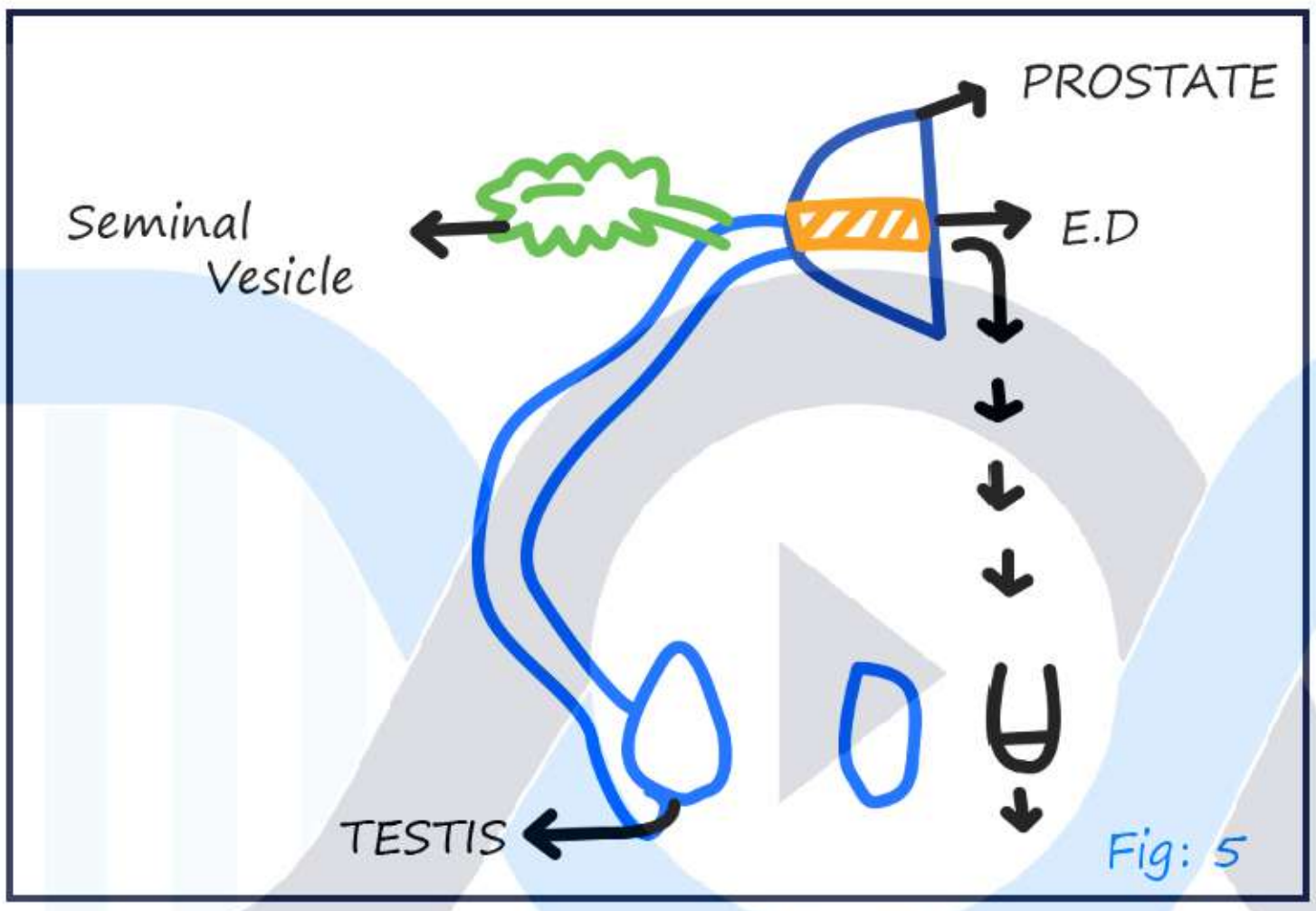

Fig: 5

- Energy (Fructose) to sperm is given by seminal vesicles
- Seminal and vas join together to form ejaculatory duct
- Male infertility – semen analysis

TUTORIALS
LOGIN FOR SUCCESS

decrease volume sperm ⊕ ↓ causes
- retrograde ejaculation
- obstruction of vas/ejaculatory duct/ seminal vesicles one side

azoospermia ↓ causes
- ejaculatory duct obstruction
- testicular failure
- vas obstruction (B/L)

– Infertility → semen analysis

↓

sperm count normal

decrease fructose

↓

obstruction of seminal vesicle

- Most common cause of obstruction of vas/ seminal vesicle – TB.
- IOC for ejaculatory duct obstruction → TRUS
- Vasography
- Final test – testicular biopsy

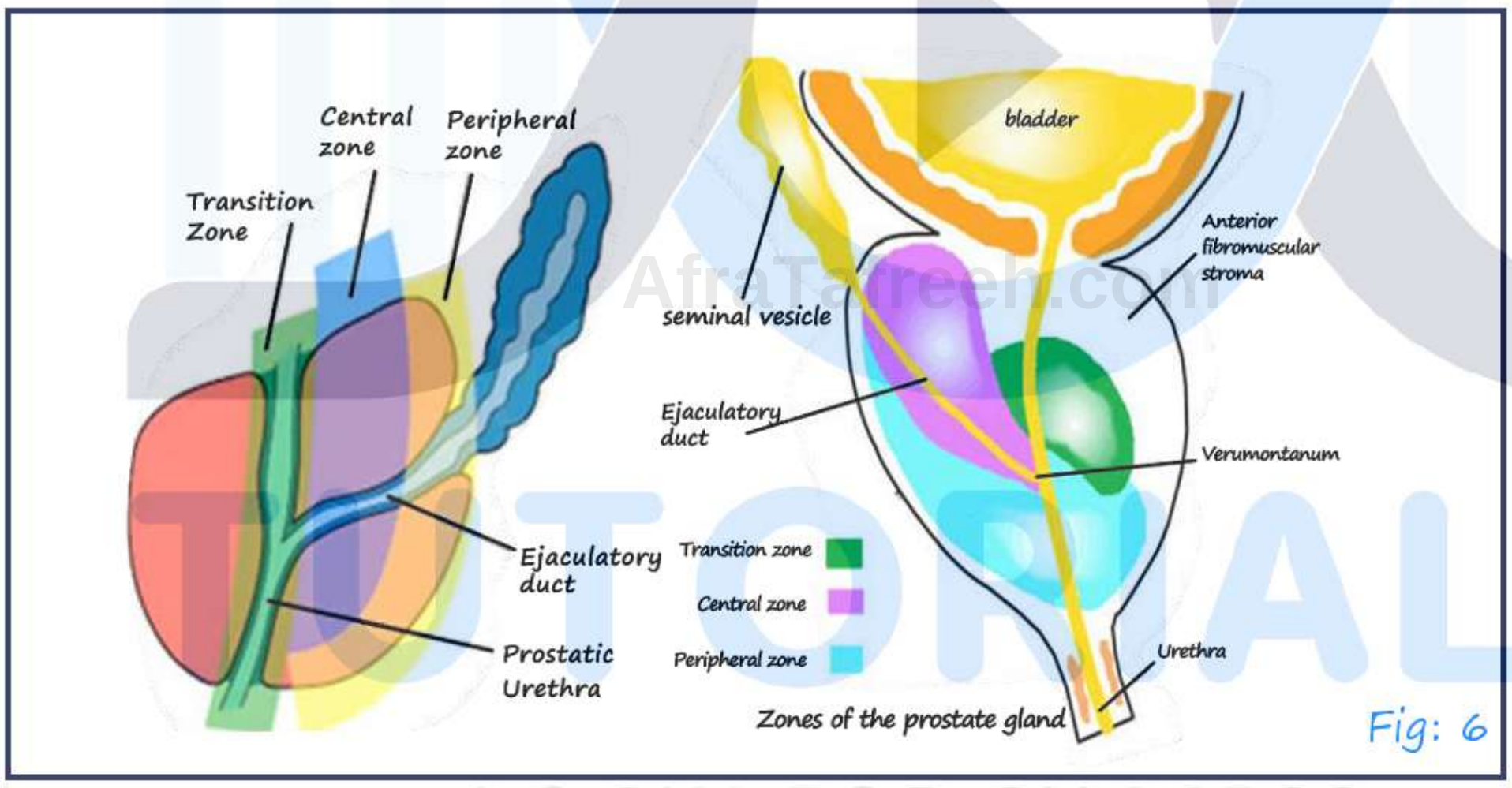

Fig: 6

LOGIN FOR SUCCESS

Urethra and penis 01:01:20

1.Hypospadias

- Most common congenital anomaly of lower urinary system
- Incidence – 1 in 250

AfraTafreeh.com

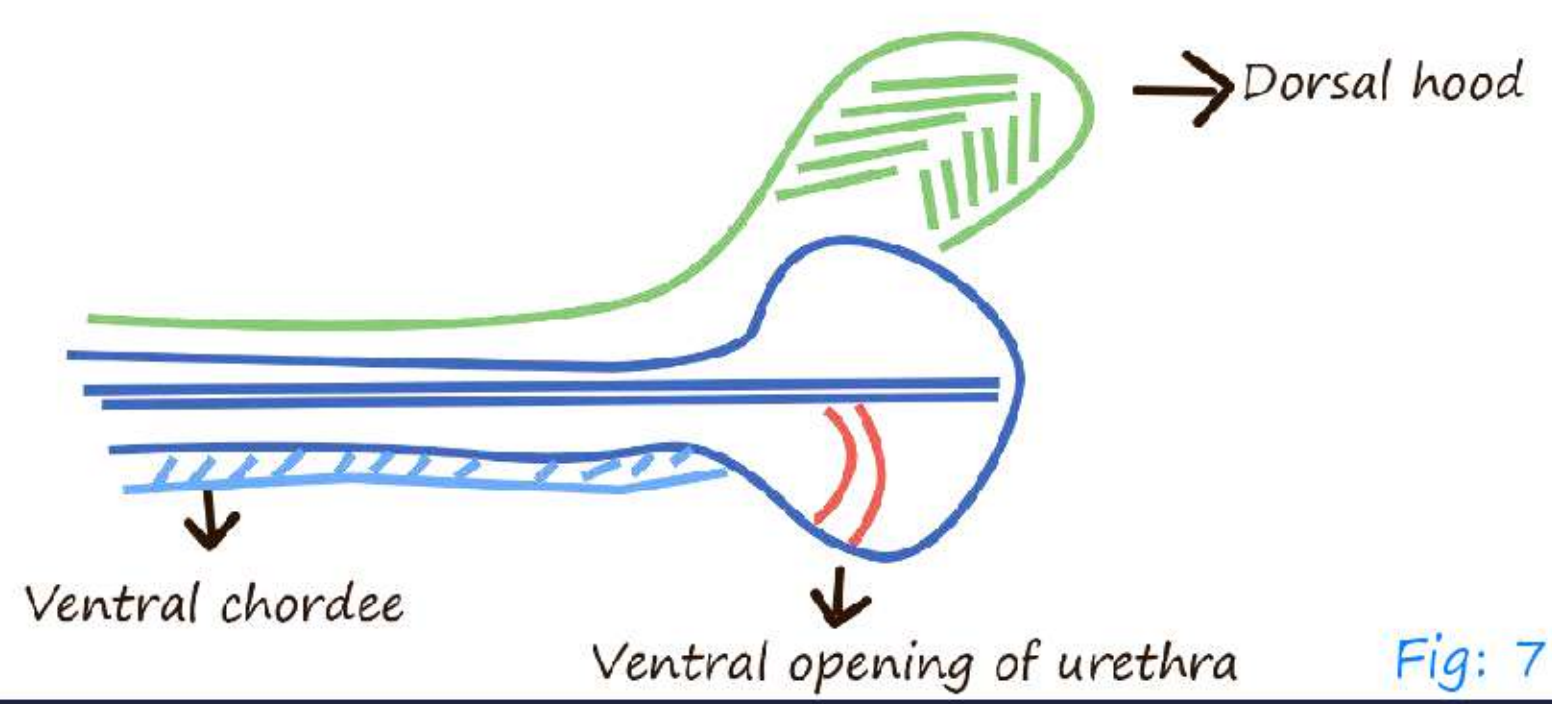

Fig: 7

- Components
  - Ventral opening of urethra
  - Dorsal hood
  - Ventral chordae
- Other features: cryptorchidism (8%)
- Types
  - Glandular → most common type, no treatment
  - Coronal
  - Penile
  - Perineal
- Age:6 months – 1 year
- Circumcision is C/I
- Old surgery: - Dennis brown – 2 stages surgery
- Recent: - MAGPI procedure – 1 stage surgery

↓

meatal advancement glanuloplasty incorporation

↓

- Orthoplasty (penile straight)
- Urethroplasty
- Glans plasty
- Meatoplasty

TUTORIALS
LOGIN FOR SUCCESS

– Scrotoplasty

– Skin reconstruction

2.Epispadias

- urethra opens on dorsal side of penis
- when urine is passed, if flows like fountain

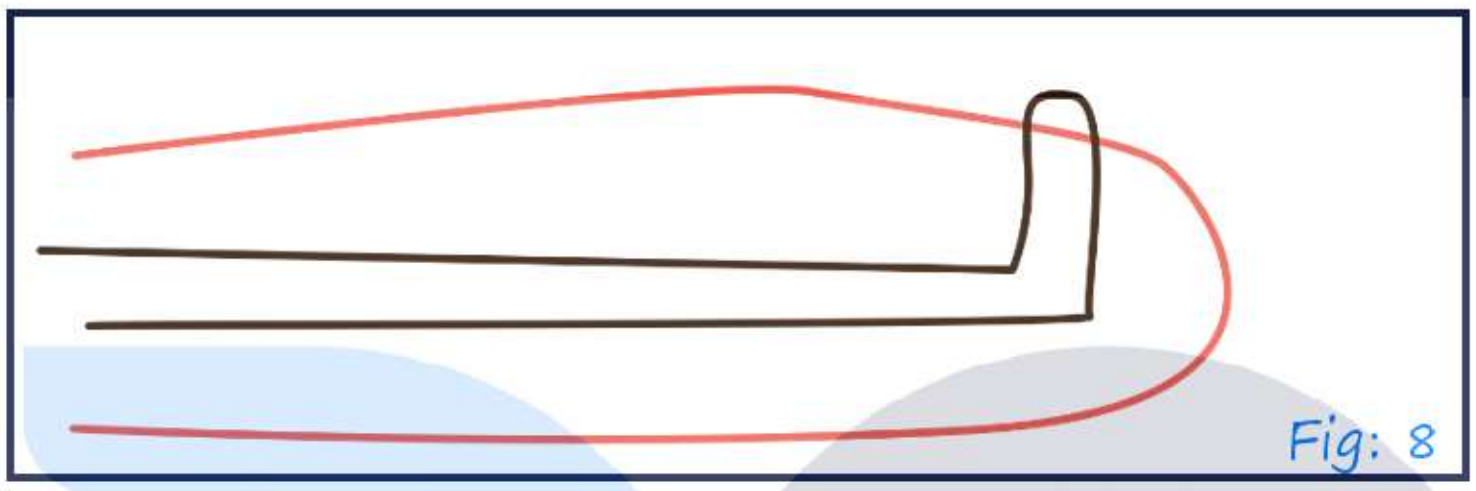

Fig: 8

- Rare anomaly
- Most common association with ectopia Vesicae

AfraTafreeh.com
TUTORIALS
LOGIN FOR SUCCESS

Phimosis

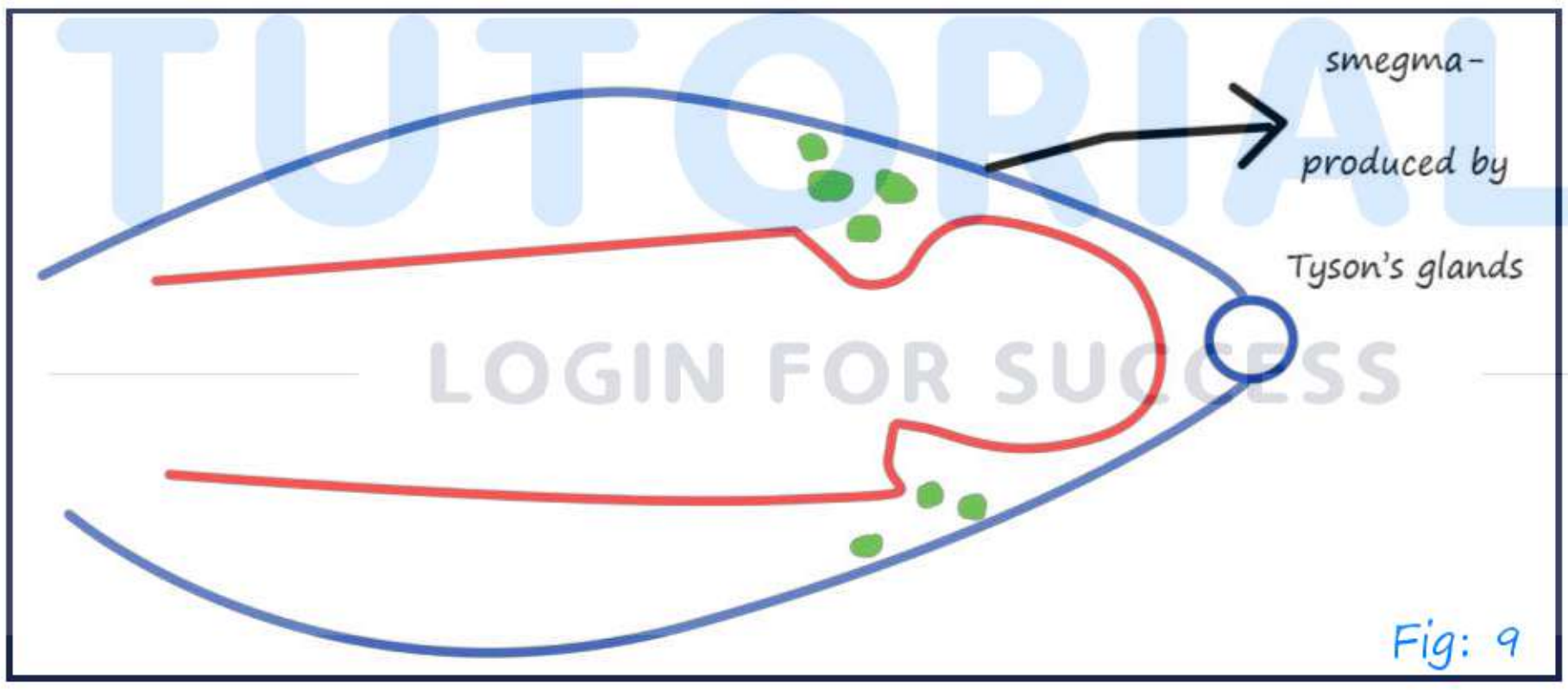

Fig: 9

- unable to retract the prepuce backwards

  – collection of smegma in corona area

AfraTafreeh.com

2 types

- **Congenital**
  - ↓
  - Congenital adhesions up to 6 years
  - ↓
  - wait 5-6 years
- **Acquired**
  - ↓
  - Inflammation
  - DM
  - Balanitis xerotica obliterans
  - Cancer
  - Trauma
  - ↓
  - Surgery is done

– < 1 year: - severe ballooning of preputial → operate

– < 1 year – Hollister device (plastibel)

- Conventional methods

  – Dorsal slit → safer method

  – Guillotine method

- Types

  – Neonatal: - birth – Jews → 100% protective of ca penis

  – Infantile: - < 1 year – Muslims → decrease incidence of ca penis

  – Adult: - no relation with ca penis

TUTORIALS LOGIN FOR SUCCESS

Paraphimosis

- preputial skin has come back and not going to normal position

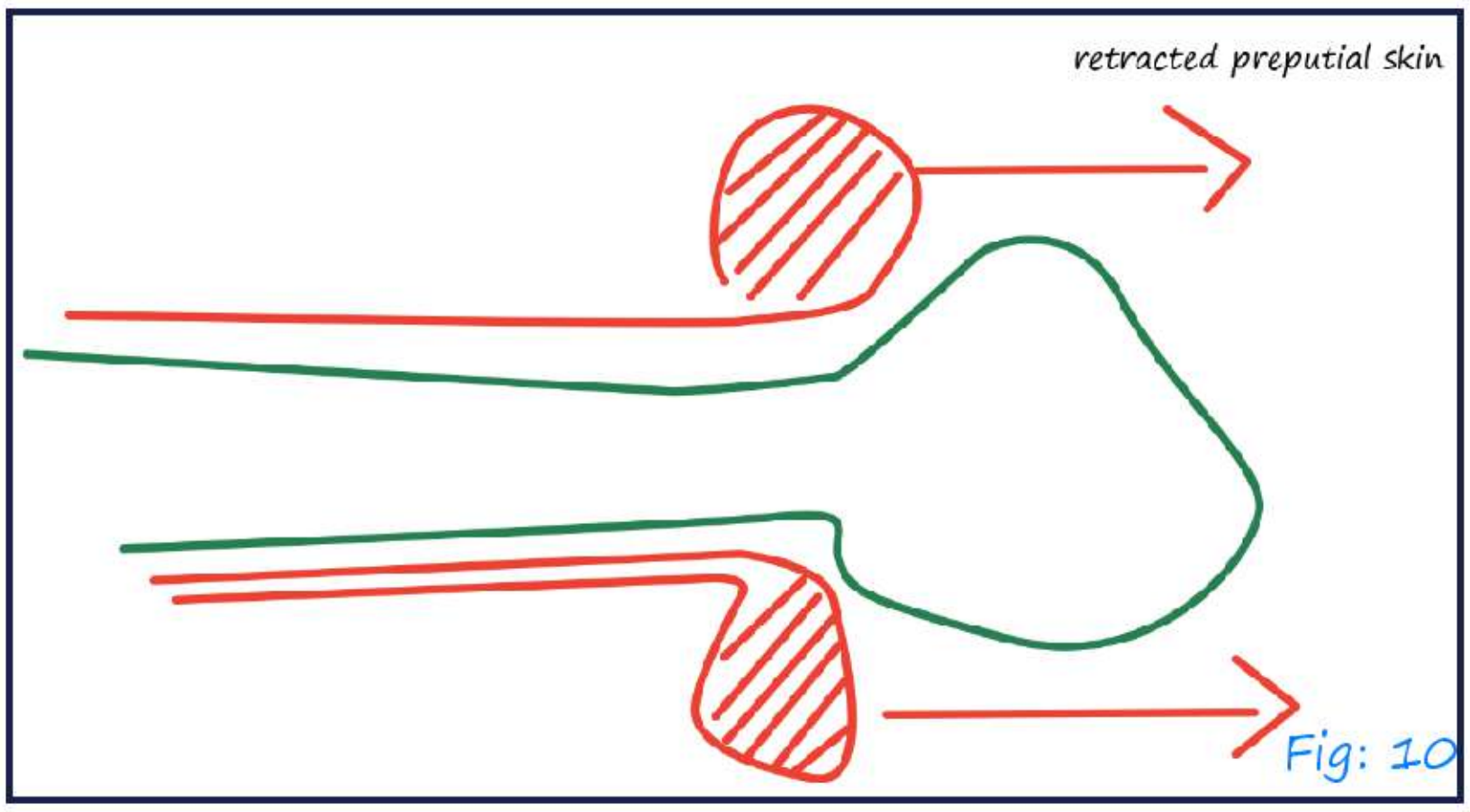

Fig: 10

- Patient comes with pain and edema
- Ice pack compression given
- Puncture with needle, apply lignocaine jelly and manually pull back the skin
- Circumcision later
- If manually skin not retracted → treatment dorsal slit

AlfaTafreen.com
TUTORIALS
LOGIN FOR SUCCESS

Pyronies disease

- Fibrosing condition associated
  - Duputryen's contractur4e
  - Retroperitoneal fibrosis
  - Resides thyroiditis
- Penis gets curved(dorsally)
- painful persistent erection and deformity occurs

AfraTafreeh.com



- Usually, penis turns dorsally
- Middle aged men
- X ray: - calcified fibrous plaques
- Treatment: - Nesbitt procedure – wedge resection.

Priapism

- painful erected penis
- derived from name Priapus god

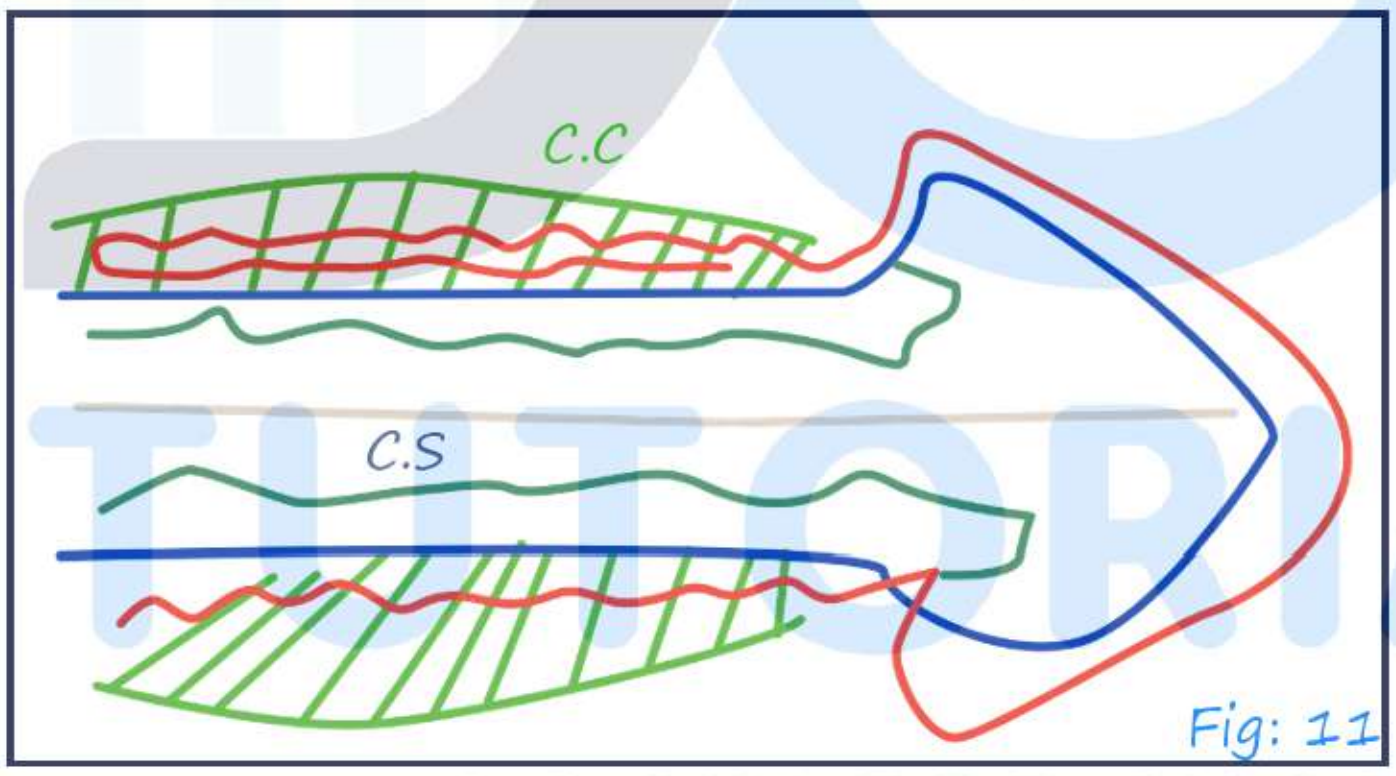

DOC TUTORIALS
LOGIN FOR SUCCESS

- Blood flows through the arteries to the penis
- As the blood enters, penis becomes enlarged and erected until ejaculation
- After ejaculation, blood will go back through the veins and erection falls down
- Two problems

  – High flow priapism

  ↓

Increase arterial flow

↓

Seen in spinal cord injury

retro peritoneal injury

papaverine injection

↓

ABG analysis – increase O2 content

↓

Treatment: - usually resolves

– Low flow priapism

↓

Seen in sickle cell anemia

leukemia

lymphoma

Venous return of blood is obstructed

↓

ABG analysis – decrease O2 content

↓

Needs urgent intervention

AfraTafreeh.com
TUTORIALS
LOGIN FOR SUCCESS

Treatment:

- injection phenylephrine / adrenaline injected in penis (<36 hours)
- > 36 hours → shunt operation

↓

between corpora cavernosum and spongiosum

↓

distal corporospongiosum shunt

↓

winter shunt

AfraTafreeh.com

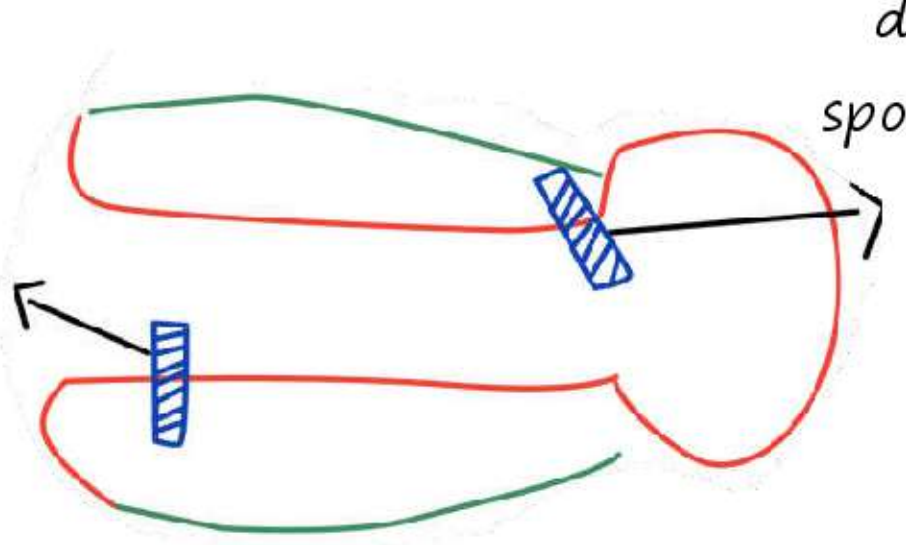

Fig: 12

- Gray hack shunt → corpora cavernosa + saphenous vein

Congenital posterior urethral valve

- one of the causes of urinary outflow obstruction
- most common – boys
- may be associated with vesico urethral reflex
- cystoscopy: – normal
- diagnosed by micturating cystourethrography (MCU)

DOC TUTORIALS
LOGIN FOR SUCCESS

Cancer penis 01:35:45

- Common in 40 years men
- Most common – SCC
- Other rare types
  - Bcc
  - Adenocarcinoma
  - Melanoma
  - Kaposi sarcoma
- Adenocarcinoma arise from under surface of penis from the tyson's glands



Fig: 13

- Most common site of Ca penis
  - Glans penis (50%)
  - Preputial skin (20%)
  - Others – corona sulcus and shaft

Predisposing 01:31:36

- Most common – smegma
- R/F:
  - Leukoplakia
  - Balanitis xerotica obliterans
  - Buschke Lowenstein tumor (HPV)

AfraTafreeh.com
TUTORIALS
LOGIN FOR SUCCESS



Fig: 14

- Carcinoma arising insitu from glans – erythroplasia of queyrat
- Carcinoma insitu from shaft → bowen's disease
- Verrucous cancer

AfraTafreeh.com

– A variety of squamous cell cancer

– Low malignant potential

– Aggressive growth on Radiotherapy

Clinical feature of Ca penis

- fungating growth with foul smell odour → 2° infection
- inguinal nodes involved

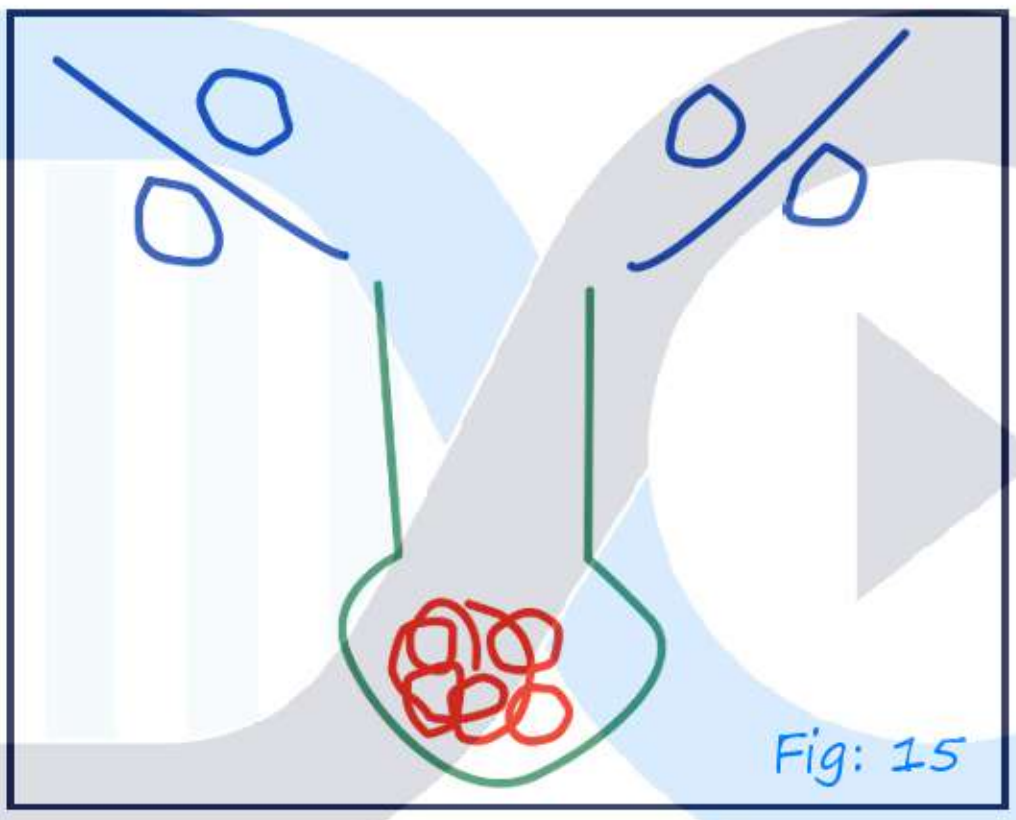

Fig: 15

- sentinel node of Ca penis → cabana → superficial inguinal node
- C/E → Jackson staging → not used now
  - I: involves glans, prepuce
  - II: involves shaft
  - III: nodes ⊕
  - IV: mets ⊕

TUTORIALS LOGIN FOR SUCCESS

TNM staging 01:39:37

- T1 – <2cm
- T2 – 2.5cm
- T3 – > 5cm / invade corpora spongiosum

  Cavernosum

  Urethra

- Usually, urethra not involved because of transitional epithelium
  - T4 – adjacent structure involvement
  - N1 – single LN ⊕
  - N2 – multiple LN (UL/BL)
  - N3 – deep inguinal nodes / Iliac nodes
- Because of nodal mass → erosion of femoral artery causes torrential

  bleed → most common cause of death

AfraTafreeh.com
DOCTUTORIALS
LOGIN FOR SUCCESS

Management of Ca penis

i. Primary

- RT
  - Interstitial BT
  - 5 FU cream
  - Moh's micrographic
  - Laser excision
- Surgery (Best)

AfraTafreeh.com

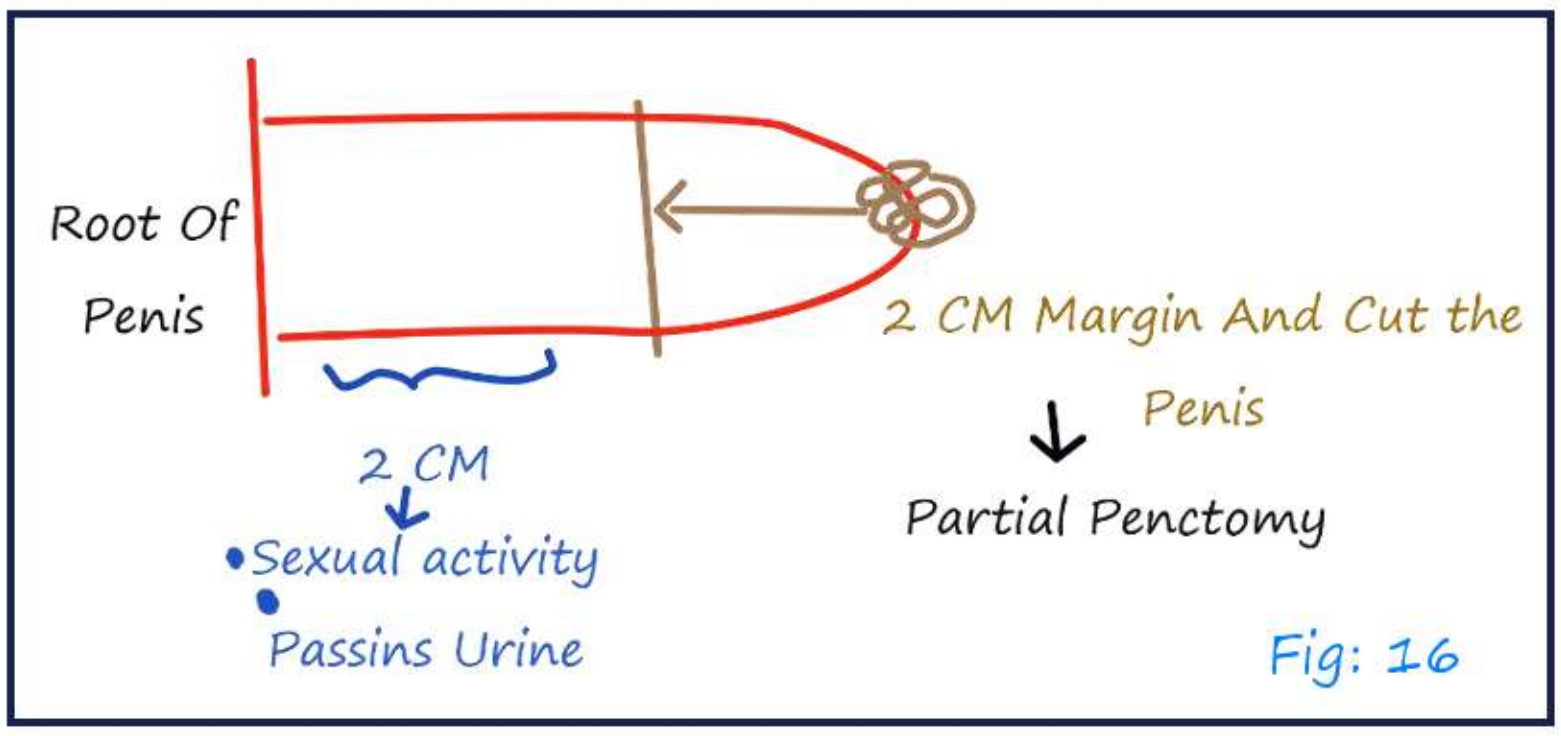

Fig: 16

- Total amputation of penis → <2cm shaft, urethral involvement
- Young's operation → partial penectomy + b/l ilio inguinal dissection
- Piersey gold operation → total amputation + scrotum (emasculation)

ii. Secondary's

- Already a palpable node ⊕
  ↓
  Lasy s incision
  ↓
  Ilio-inguinal block dissection

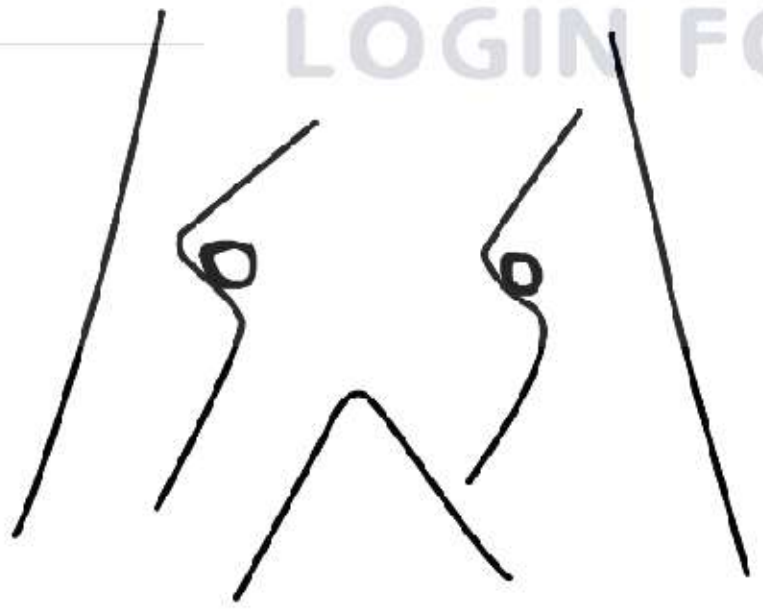

- Node negative
  - Sentinel node biopsy of cabana (1st node)
  - Superficial inguinal dissection of dassler → HPE
    ⊕

TUTORIALS LOGIN FOR SUCCESS

↓

Ilio inguinal block dissection

- Latest protocol for No nodes

↓

Modified Ilio inguinal dissection of catalona

↓

Superficial group
Deep group
} removed → HPE → positive → II block

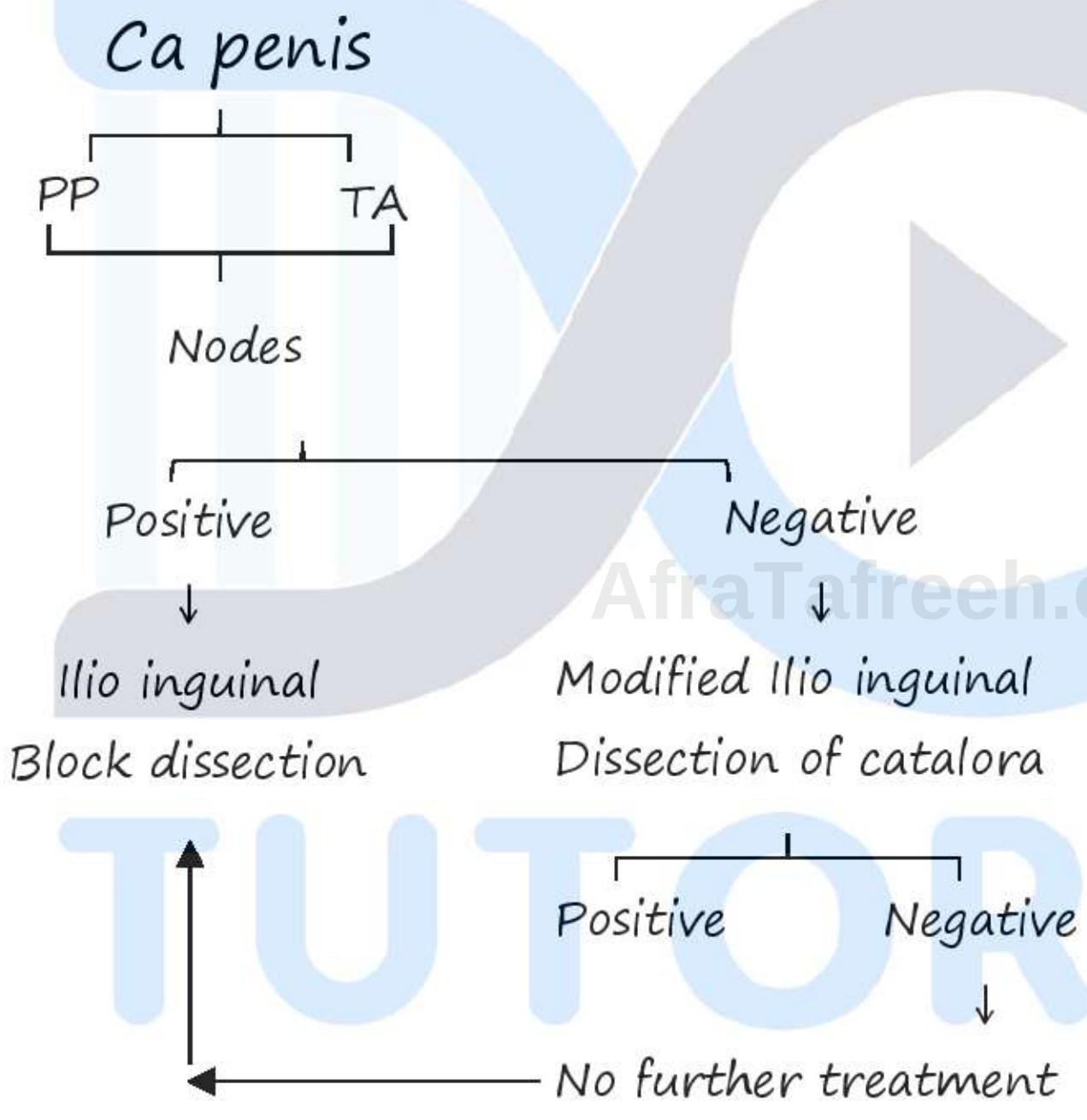

AfraTafreeh.com
TUTORIALS
LOGIN FOR SUCCESS

AfraTafreeh.com

Testicular cancer

- Pathology: -

Pathology

- **Germ cell tumor**
  - **Seminoma**
    ↓
    - Common in 40's
    - Radiosensitive
    - LN > Hematogenous
    ↓
    LDH increase
    ↓
    Good prog
  - **Non-seminomas**
    ↓
    - Choriocarcinoma
    - Yolk sac tumor
    - Teratoma
    - Embryonal cell cancer
    ↓
    30's
    Radioresistant
    Chorioca – hematogenous
    Others – LN Mets
    ↓
    Increase HCG
    Increase α FP
    Increase LDH
    ↓
    Bad prog
- **Sex cord tumor**
  ↓
  - Leydig cell
  - Sertoli cell

DOC TUTORIALS
LOGIN FOR SUCCESS

- Clinical feature:
  - 3rd decade: - non-seminomatous
  - 4th decade: - seminomatous
  - >5th decade: - lymphoma of testis



- Predisposing factor
  - Undescended testis (seminoma)
    - Risk factor remains same after surgery
    - Orchidopexy helps in early diagnosis
  - Klinefelter syndrome
  - Testicular feminizing syndrome

- Maternal exposure of diethylstilbesterol
- Sibling's h/o testicular tumor
- H/o testicular tumor

- Clinical feature:
  - Painless lump ⊕
  - Testicular sensation lost → tumors, syphilis
  - Abdominal lump
    - para-aortic nodes
    - Ⓡ – inter aorta canal node
    - Ⓛ – pre aortic nodes
  - hurricane tumor – feature of choriocarcinoma
  - Sertoli: - feminization ⊕
    gynecomastia ⊕
  - Leydig: - precocious puberty

AfraTafreeh.com

- IOC:
  - to diagnose: - biopsy
  - staging: - MRI
  - Tumor marker: - HCG, αFP

DOC TUTORIALS
LOGIN FOR SUCCESS



- trans scrotal biopsy is contraindicated
- CHEVASU MANUEVER biopsy
  - make inguinal incision
  - pull testis out → do frozen section

Positive ↓ high inguinal orchidectomy

Negative ↓ keep it back

AfraTafreeh.com

Staging 02:10:20

- T1

  - tumor confined to testis
  - no lymph vascular invasion

- T2

  - Tumor confined to testis
  - Lymphovascular invasion ⊕
  - Tumor extends to tunica albuginea

- T3 – tumor has gone to spermatic cord

- T4 – tumor extending to scrotal wall

Stage	Treatment of seminoma	Treatment of non- seminoma
I	RT	RPLND
II	RT	RPLND
III	RT	RPLND
IV	RT	RPLND

- N1: <2cm – RT   RPLND + Chemo
- N2: 2-5cm – RT   RPLND + Chemo
- N3: >5cm – chemotherapy   chemotherapy

- M1: mets– chemotherapy chemotherapy
  (Most common – lungs – canon ball mets)

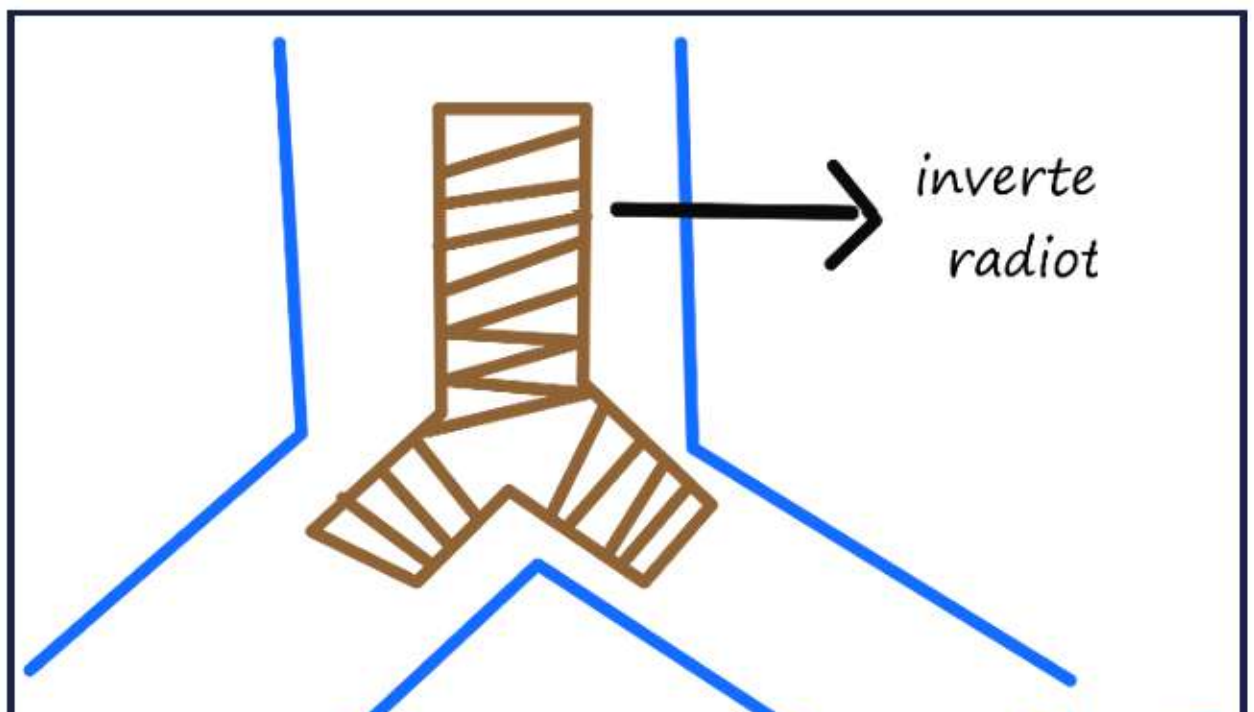

Fig: 17

- Chemotherapy
  – B: Bleomycin
  – E: - Etoposide
  – P: - Cisplatin

AfraTafreeh.com
TUTORIALS
LOGIN FOR SUCCESS

Varicocele testis

- Usually young, tall, thin (male)
- Clinical feature:
  – Bag of worm sensation
  – Cough impulse ⊕
  – Disappears on lying down
- Most common on lift side
- Ⓡ testicular vein joins IVC
- Ⓛ testicular vein long course → joins L renal vein
- Adrenal veins cross at renal vein→catecholamines produced → spasm
  Sigmoid colon compresses renal vein
  Ca L kidney can cause thrombus → obstruction of L testicular vein

AfraTafreeh.com

- Lift side varicocele does not disappear on lying down-suspect renal cancer
- Patient develops infertility
- Most common treatable cause of infertility – varicocele
- Treatment
  - Palomo operation → retroperitoneal ligation of testicular veins
  - Inguinal approach → invanisserich procedure

Painful testis 02:21:05

- Torsion

Fig: 18

- Orchitis
- Lift tests lies horizontally with long meso orchium

  ↓

  Bell clapper deformity → can be B/L

  ↓

  Most common cause of torsion
- Angel sign – normal testis → horizontal

- Deming sign – affected testis lies higher up
- Other causes of torsion
  - Undescended testis
  - Testicular inversion

Orchitis

- Caused by chlamydia infection (most common)
- Follows UTI
- Phren's sign – on lifting the scrotum → pain relief (whereas in torsion pain increases)

Torsion testis

↓

1st hour – manual detorsion

< 4 hours – save testis > 4 hours – gangrene

- IOC – color Doppler
- B/L exposure
  - Affected testis removed
  - Unaffected testis – orchidopexy
- Treatment of orchitis
  - Antibiotics
  - Scrotal support

AnuFaheeh.com
TUTORIALS
LOGIN FOR SUCCESS

Hydrocele testis 02:27:35

- Collection of fluid between layers of tunica vaginalis
- Color of fluid – amber color

AfraTafreeh.com

- Brilliant trans illuminant $\oplus$
- Get above swelling $\oplus$
- Fluctuation $\oplus$
- 1° hydrocele – testis not palpated separately
- 2° hydrocele – testis is palpable
- Types

Vaginal-confined to scrotum
- 1° -unknown
- 2° -infection
  - Inflammation
  - Tumors

  } testis palpable separately

infantile
- Fluid up to the level of superficial ring

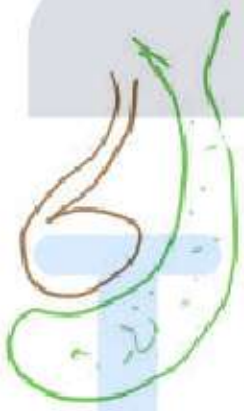

Congenital hydrocele
- Extends up to peritoneal cavity
- Inverted ink bottle effect

Encysted hydrocele cord
- Fluid collected in cord
- Movement Decreased on pulling testis

TUTORIALS
LOGIN FOR SUCCESS

Epididymal cyst (middle age)	Spermatocele (any age)
Congenital embryological remnants	Acquired condition
Multi locular, B/L	Solitary, U/L
Contains clear fluid	Contains barley water color fluid ↓ Collection of sperm inside
Chinese lantern trans illumination	May/may not be trans illuminant
	3 testicles like appear

AfraTafreeh.com
TUTORIALS
LOGIN FOR SUCCESS

Management of hydrocele

- Jaboulay's eversion of sac – bigger
- Lord's plication of sac – small with thin sac
- Excision of thick sac

Complications

- Pyocele
- Hematocele

Note: Rupture is not seen

AfraTafreeh.com

Undescended testis 02:39:45

- Testis – organ of lumbar region
  - 2nd month of life – lumbar region
  - 3rd month of life – iliac fossa
  - 7th month of life – deep ring
  - 7-8 month of life – travels in the canal
  - 8 month of life – superficial ring
  - 9 month of life – scrotum

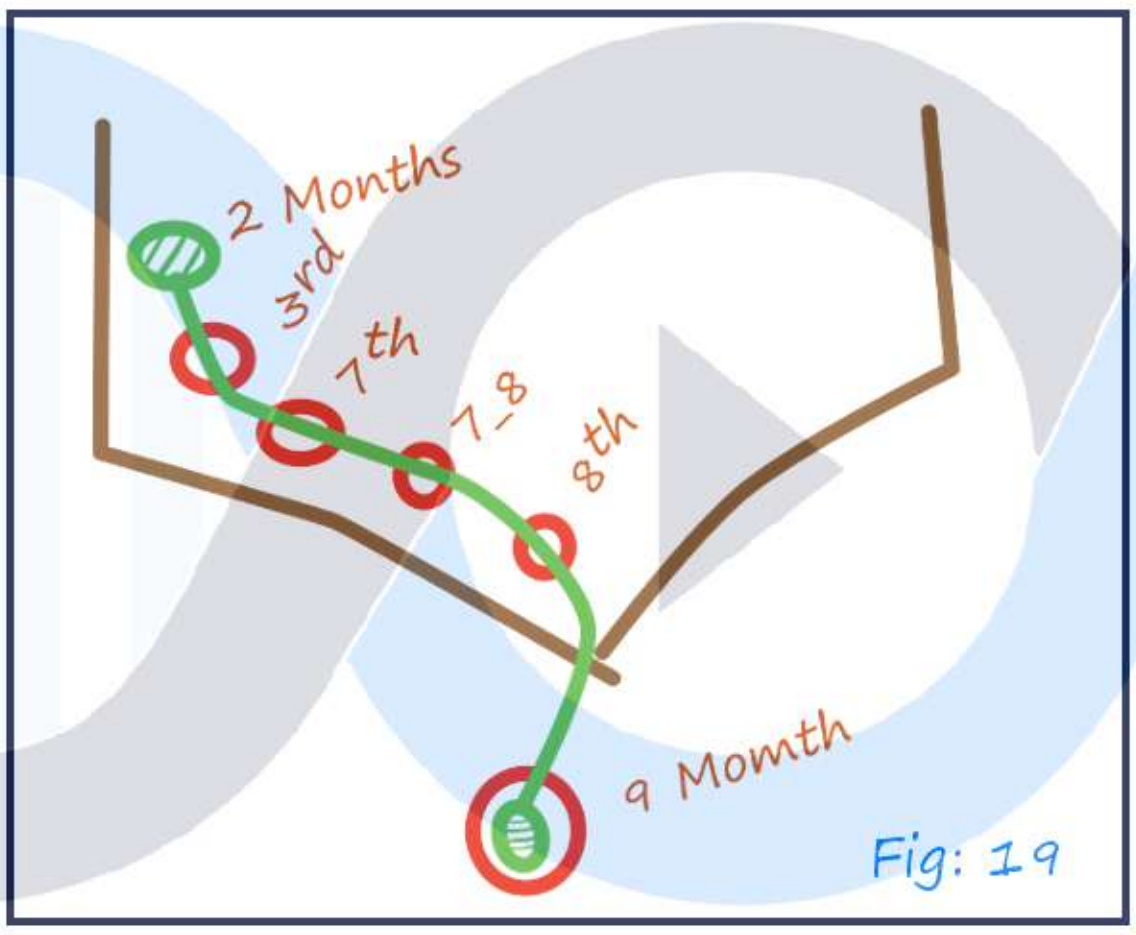

Fig: 19

- Testis is brought down by
  - Gubernaculum tail
  - Scrotal tail (Dominance)
  - Perineal tail
  - Inguinal tail
  - Pubic tail
  - Femoral tail

TUTORIALS
LOGIN FOR SUCCESS

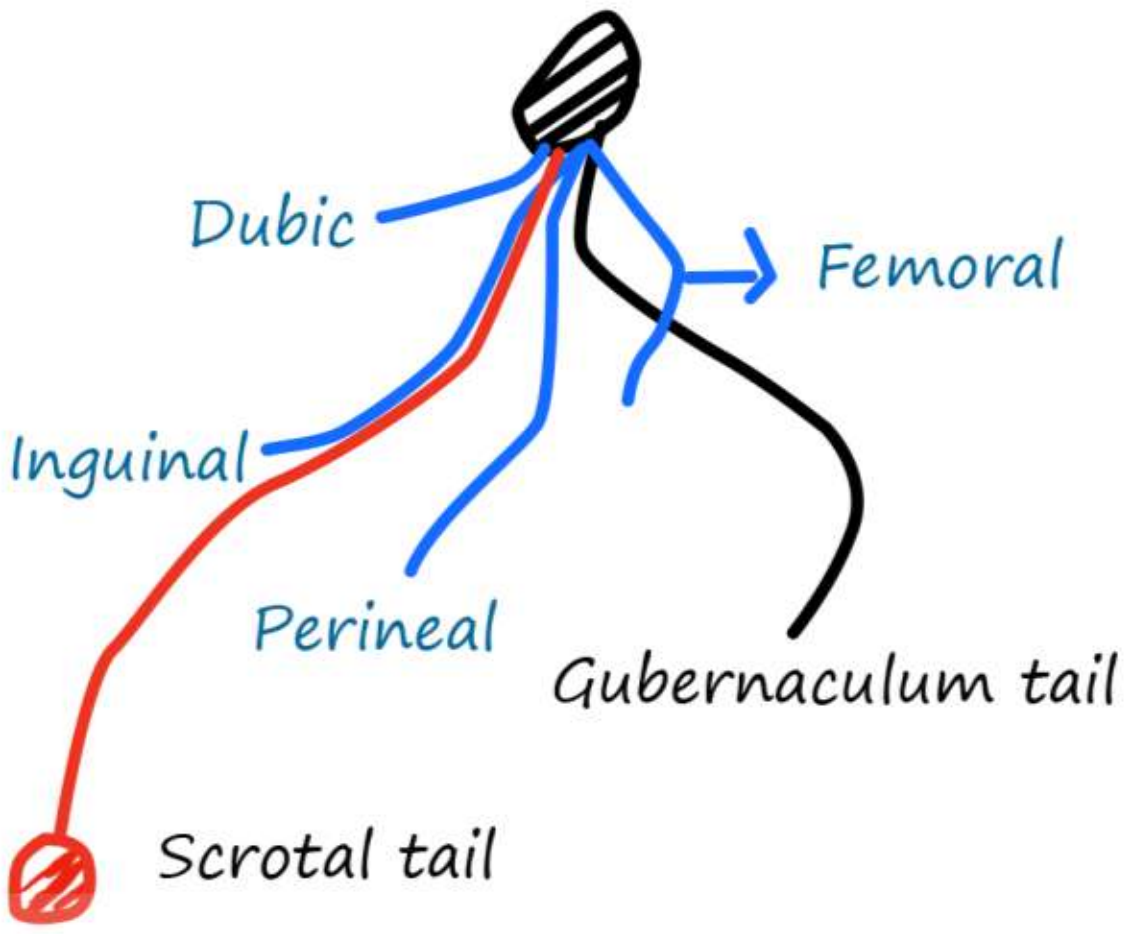

- If inguinal tail is dominant, testis lies in superficial inguinal pouch → most common site of ectopic testis

UDT	Ectopic
↓	↓
Arrest in normal pathway	Deviation from normal pathway
↓	↓
Underdeveloped testis	Normal developed
↓	↓
Complications: -	**Complication** – trauma
T – torsion	- Scrotum normal
E – epididymorchitis	
S – sterility	
T – trauma	
I – indirect inguinal hernia	
S – seminoma	
- Scrotum not developed	

AfraTafreeh.com
TUTORIALS
LOGIN FOR SUCCESS

AfraTafreeh.com

Retractile testis

- Scrotum normal
- Testis in superficial ring
- D/D – ectopic testis
- We can pull the retractile testis to scrotum

UDT

- Most common location – inguinal canal
- 70% may come to normal location in 3 months
- Most common in preterm babies
- Most common in right side
- Leydig cells normal ⎤ — secondary sexual characters normal
- Sertoli cells affected ⎦
- Premalignant
- Investigation
  - Gold standard: – diagnostic lap.
  - Inguinal UDT: – USG is enough

    ↓

    Usually associated with indirect inguinal hernia

TUTORIALS
LOGIN FOR SUCCESS

Diagnostic laparoscopy 02:48:38

- Testicular vessels entering deep ring one side
- Testicular vessels ending blindly on other side

  ↓

  Atrophy/absent testis

  ↓

  Nothing can be done

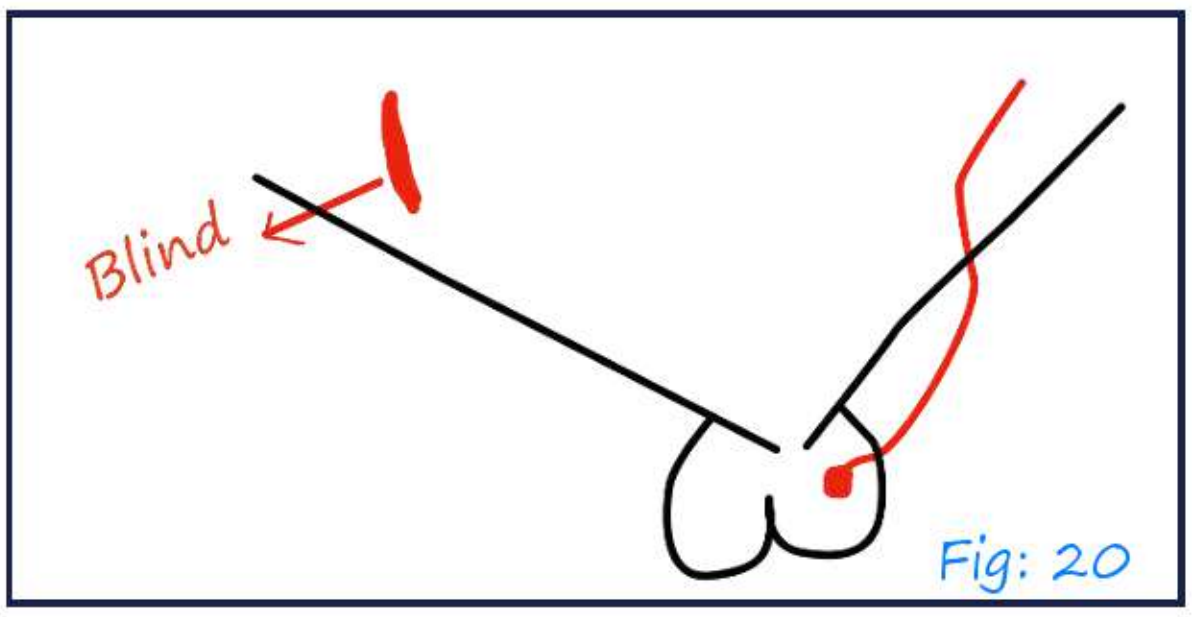

Fig: 20

Management

- B/L UDT: – β HCG and testosterone (measured)
- Testis must be brought to scrotum
  - To prevent Trauma
  - To detect malignancy
  - To allow Normal spermatogenesis
    - Testis placed in Dartus pouch → Subdartus operation most common

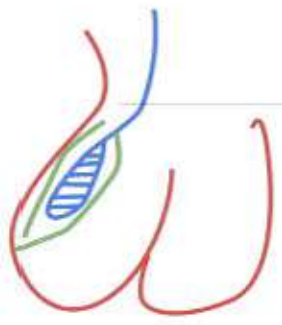

    - Brought to the thigh and fixed → Keetley thorek

    - Placed along with opposition testis → Ombredanne procedure

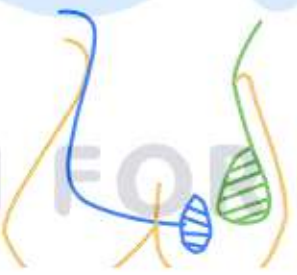

    - Bring it scrotum and suture it →
      - One it sutures to testis
      - Other to medial side of thing

      LADDC GRON TECHNIQUE →

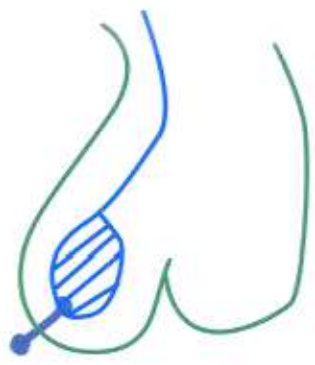

- When not coming to scrotum
  - Silbar – microvascular anastomosis
  - Fowler Stephen – 2 stage operation.

AlfaTutresh.com TUTORIALS LOGIN FOR SUCCESS

AfraTafreeh.com

ARTERY

Aneurysms

- Important DD for aneurysm is **ectasia** → blood vessel is <50% diameter dilated

Aneurysm 00:00:31

- Blood vessel is dilated >50% diameter
- Most common aetiology – **Atherosclerosis**
- Most common site overall – Circle of Willis
- Most common extracranial site – Abdominal aorta, usually infra renal abdominal aorta
- Most common site of peripheral art aneurysm – popliteal artery
- Most common site of visceral art aneurysm – splenic artery
- Mycotic aneurysm (misnomer) – caused by staphylococcus
  - It is most common in femoral artery
- Aneurysm – 2types
  - True aneurysm – which contain all the layers. Tunica intima, media and adventitia
  - False aneurysm – It will lack 1 or 2 layers

Aneurysm

- Fusiform aneurysm – symmetrical enlargement
- Saccular aneurysm – It is like a diverticulum from bowel
  - It is very dangerous as high chance of rupture is present
  - It is asymmetrical
- Dissecting aneurysm – Blood tracks in between the layers, through Tunica intima

Abdominal aortic aneurysm 00:05:28

- Most common located below renal artery
- Most common presentation is "back pain"
- It can go for rupture
- Rupture can be at 2 places, either anteriorly (or) posterolateral
- Anterior rupture (20%), posterolateral -80%
  - In anterior rupture, more space, major blood loss, patient dies in spot
- In posterolateral aneurysm there is retroperitoneal space, so the rupture is compressed by hematoma, they will come with severe back pain, shock. They also have high mortality, still we can save them
- IOC for AAA – CT angiography
- USG – used for follow up

AfraTafreeh.com

AfraTafreeh.com

Indications of management

- Any symptomatic patient – operate
- Asymptomatic patient on USG – anteroposterior diameter >55mm (5.5cm) is the cut off for management (>5.5cm needs treatment)
  - Conventional treatment done is → resect the aneurysm and use a graft made of Dacron called Dacron pant graft
  - Conventional removal of aneurysm is not done now. Not we are doing endovascular procedures

Complications of conventional removal 00:11:08

- Most common cause of death → M.I
- Other problems
  - Renal failure
  - Leak of graft
  - Colonic ischemia (if, not properly reimplanting the inferior mesenteric artery)
  - Injury to artery of Adam kiewicz – It is artery supplying spinal cord
- Arising from posterior intercostal artery. It supplies anterior part of spinal cord → damage of it causes – anterior spinal artery syndrome resulting in **paraplegia**
- It can also be damaged in oesophagectomy operations
- Mortality of elective cases → 2%

DOCTUTORIALS LOGIN FOR SUCCESS

- Emergency cases of rupture → 50%

- **EVAR – Endovascular aneurysm repair**
  - They keep a stent in the blood vessel and blood flows through it and aneurysm collapses
- **Hunterian ligature**
  - Operation is used to be done in old days leaving the blood vessel above and below, they ligate the aneurysm up and down – after ligation aneurysm collapses. It is not done now a days
- Material used in aneurysm repair is Dacron, PTFE (poly tetrafluoro ethylene)
- Suture material used is 3-0/ 4-0 prolene – for suturing abdominal aorta

AfraTafreeh.com

Aortic dissecting aneurysm 00:15:28

TUTORIALS LOGIN FOR SUCCESS

- On the right lateral wall, there is a tear happening @ tunica intima level, transverse tear
- This is the most common site of dissection beginning
- 2nd most common site of tear – distal to ligamentum arteriosum
- Immediately blood will flow between the layers and either it will reopen somewhere into artery. If it is not reopening it will compress the aorta and cause multiple problems
- It is most common seen in men of 60-70 years
- Most common risk factor is HTN

AfraTafreeh.com

- Other risk factors – Marfans, Ehler danlos, Takayasu arteritis, coarctation of aorta

- Patient present to hospital with severe pain, hypotension and sometimes M.I develops if coronary ostium is involved in dissection
- X-ray chest shows – widened mediastinum
- IOC for stable patient is CECT Thorax
- For unstable patients (no time) do transoesophageal echo
- On CT scan we can diagnosis type of tear by the DeBakey classification
  - Type I – The dissection involves ascending aorta, arch of aorta and dissecting aorta are involved
  - Type II – Smallest tear, involve only ascending
  - Type III – Only involves descending aorta
  - DeBakey I and II are now named as Stanford A, III – Stanford B

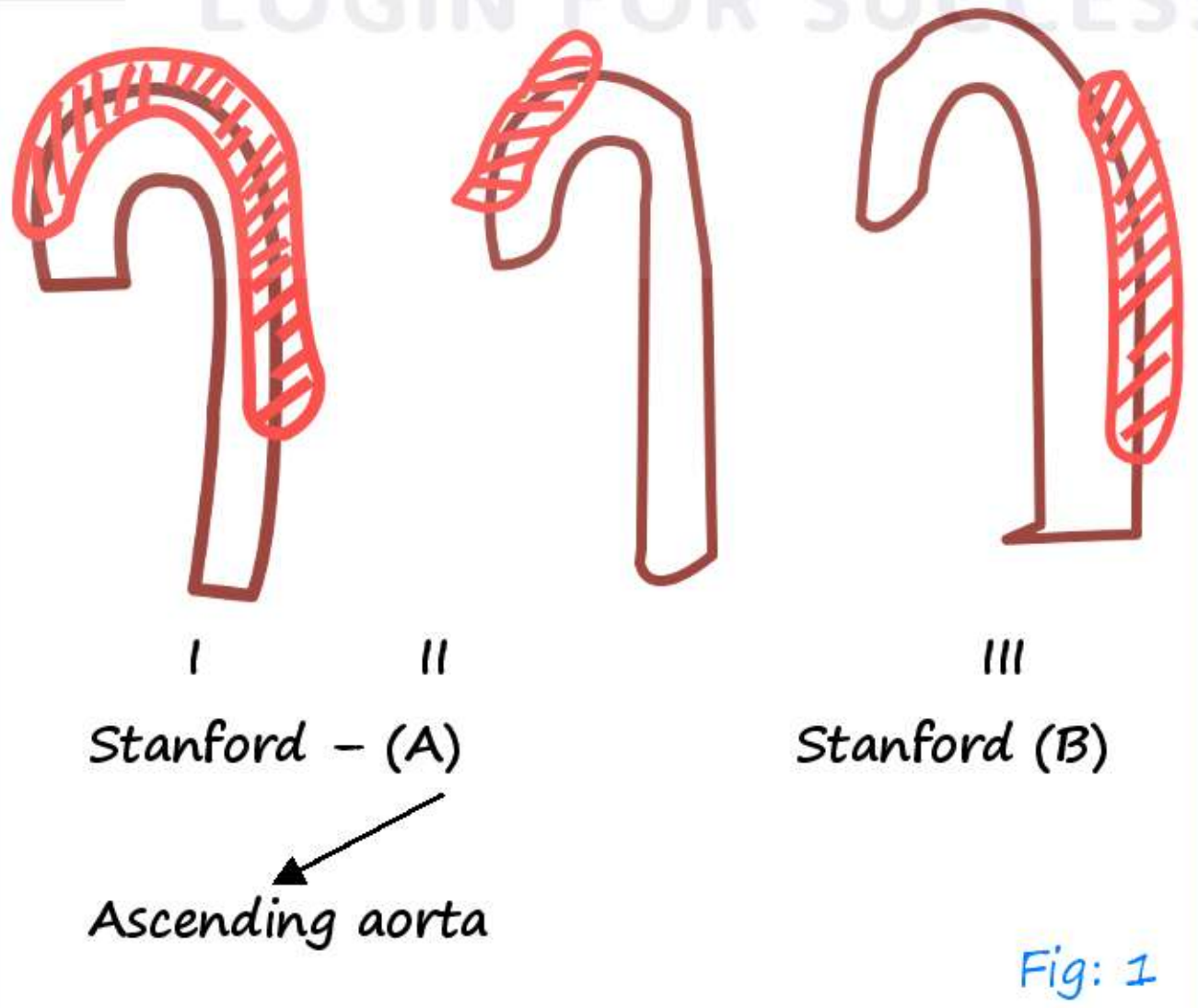

Fig: 1

- Clinical features: Patient has pain, shock
  - Disproportionate B.P between upper limb & between UL & LL
- Treatment: Immediate surgery → Thoracotomy and Dacron graft is done

Crawford classification of Thoraco-Abdominal Aortic aneurysm

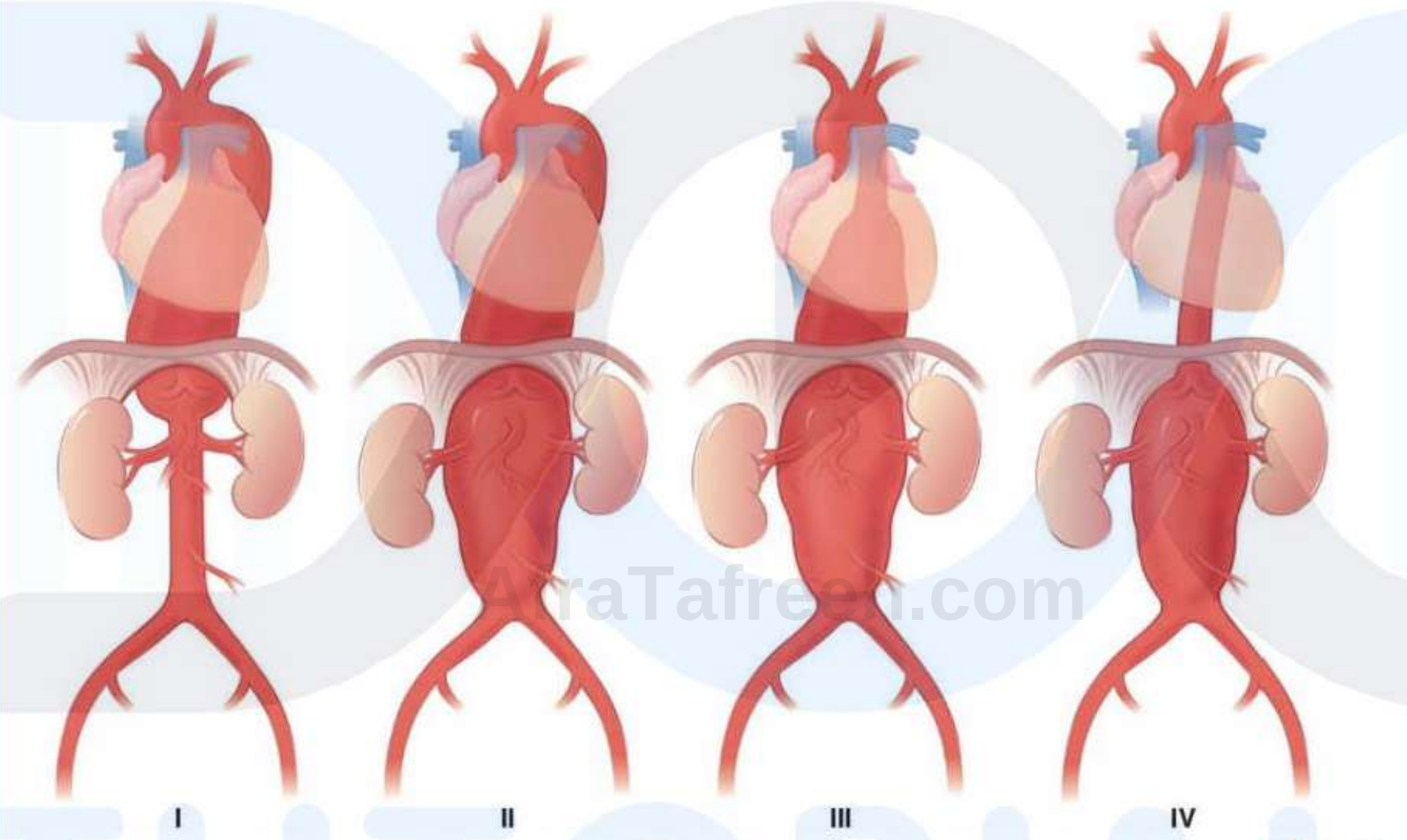

Fig: 2

- Crawford Type I – Aneurysm seen from left subclavian artery to renal artery level
- Crawford Type II – Biggest, from left subclavian artery to the bifurcation of vessels
- Crawford Type III – From mid-descending aorta to bifurcation
- Crawford Type IV – Involves suprarenal, may/may not involve the renal artery also upper abdominal aortic aneurysm

AfraTafreeh.com

Peripheral artery aneurysms 00:25:12

Popliteal artery aneurysm

- It is the most common peripheral artery aneurysm
- 2/3 bilateral
- We can wait upto 25mm, above that we have to operate
- Major issue with it, is can form thrombus/ embolus and cause distal occlusion

Mycotic aneurysm

- Caused by staphylococcus
- Seen in femoral artery
- It is a false aneurysm

Acute limb ischemia 00:28:06

- Most common cause – by embolus from left atrial thrombus, which gets disconnected and comes down, obstruct lower vessels
- Classical symptoms of this is 6P's
  - Pain
  - Paraesthesia
  - Pulselessness
  - Poikilothermia
  - Paralysis
  - Pallor

- It is an emergency; we have to intervene within 4-6 hours

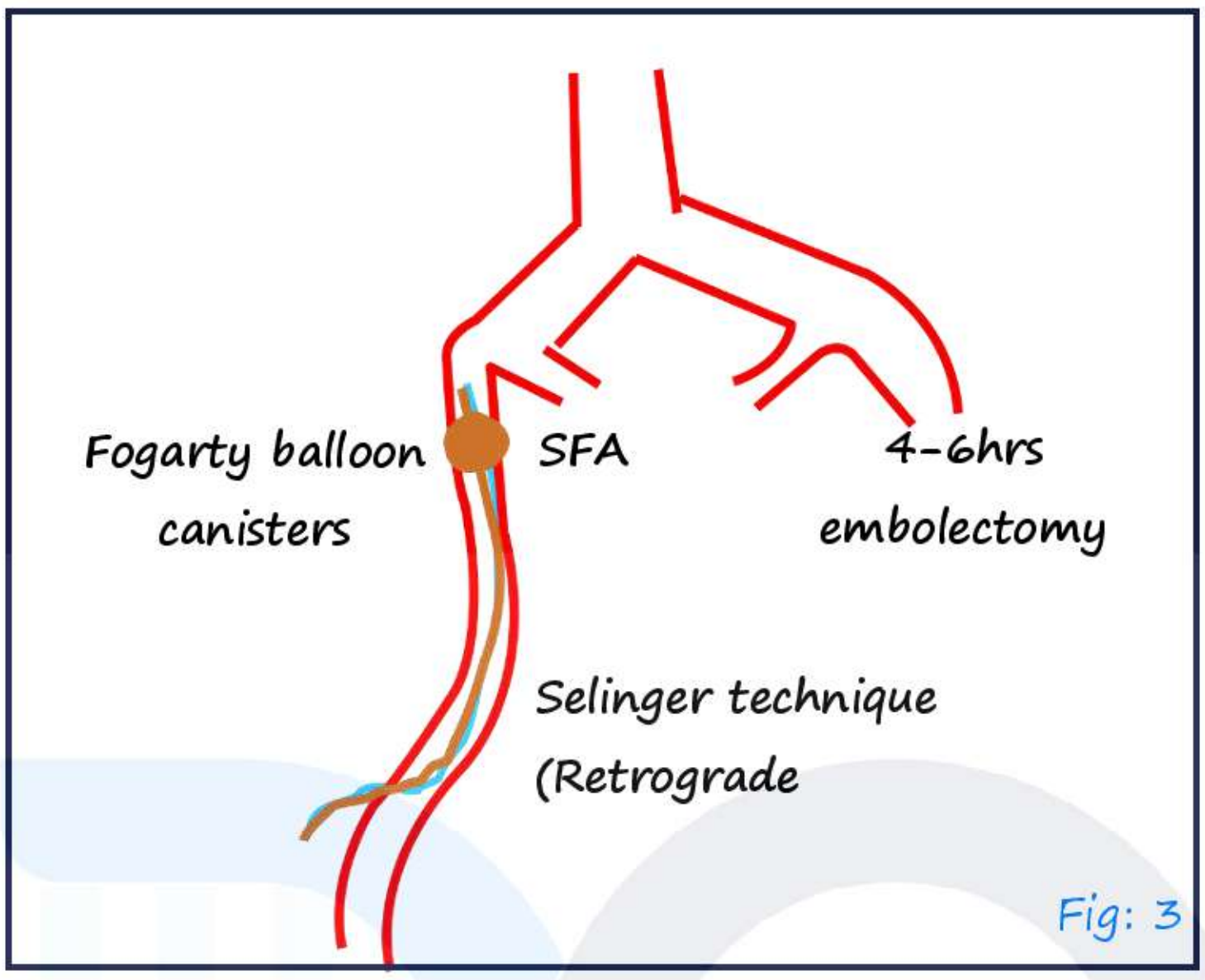

Fig: 3

- Now, assume there is an embolus in superficial femoral artery and cause vessel flow obstruction, now we will use Seldinger technique – we cannulate the artery in a retrograde way using a special needle called Seldinger needle, will cannulate and pass the guidewire distal to the embolus and through guidewire pass a balloon. Now inflate balloon and withdraw the catheter. Catheter is known as FOGARTY balloon catheter. As we withdraw catheter, we will remove the embolus. This procedure is known as embolectomy (should be done within 4-6 hours)
- If delayed, patient lands up in gangrene
- If gangrene already started, only amputation of gangrenous part of limb

AfraTafreeh.com

AfraTafreeh.com

Chronic limb ischemia 00:31:43

- Mainly caused by peripheral vascular disease & TAO

PVD	TAO
Causes:	
- DM, HTN, hypercholersterolemia obesity - PVD results in atherosclerosis & obstruction of blood flow - Main problem is thrombus formed in vessels (due to atherosclerotic lesions). Thrombus occlude the vessels - Mainly involves aorta, common iliac, external iliac, superficial femoral artery - Most common involves major vessels, atherosclerotic occlusion - Atherosclerosis is Unilateral or bilateral - Common in old age - Here, upper limb not affected - Adjacent veins and nerves are not affected	- Main cause/ risk factor is smoking - Vessels are occluded by vasospasm - It involves infra popliteal lesions - Usually bilateral, symmetrical - Common in young age <50 years - Seen exclusively in males - Not at all seen in females - Upper limb also affected - Adjacent veins and nerves are also affected

DX TUTORIALS LOGIN FOR SUCCESS

Clinical features:

- Intermittent claudication pain
  - Pain not present at rest
  - Pain starts on walking
  - Pain not present on standing
  - Pain decreases on rest
- Neurogenic claudication: Pain increases on standing up
- Most common site of claudication pain – calf
  - Because most common site of occlusion is superficial femoral artery

Claudication pain 00:40:08

AfraTafreeh.com

- Buttock
- Both thigh
- Both calf

(Buttock, Both thigh, Both calf) – **Aorto-iliac occlusion**

- Patient C/O pain in buttock (rarely)
  - One thigh
  - One calf

(One thigh, One calf) – **Unilateral common iliac artery occlusion**

- Only in thigh and calf – external iliac artery occlusion
- Only in calf → superficial femoral artery/ popliteal artery occlusions

TUTORIALS LOGIN FOR SUCCESS

AfraTafreeh.com

Lerich syndrome

- At the bifurcation of aorta, there is saddle shaped thrombus sitting. It causes buttock claudication and impotence called lerich syndrome

Boyd's clinical classification of claudication

- Grade I – Patient starts walking, he develops pain in lower limb and he walks with pain. Pain disappears
- Grade II – Patient starts walking, pain appears, he walks with a limp
- Grade III – Patient starts walking, get pain, he is unable to walk, he is compelled to take rest/ sit
- Grade IV – Patient has rest pain

TUTORIALS
LOGIN FOR SUCCESS

Other classification systems are

- Fontaine
- Rutherford
- ABPI: Ankle Brachial Pressure Index

$$\frac{\text{Ankle pressure}}{\text{Brachial pressure}} = 0.9 \text{ to } 1.1$$

- If ankle pressure low due to occlusion
  - If it is < 0.9 – Claudication
  - < 0.5 – Rest pain
  - < 0.3 – Imminent necrosis
- Patient have false high value >1.3 value → Because of calcified arteries seen in DM and CKD patients

Investigations of vascular disease

- 1st done investigation – Colour Doppler
  - It is repetitive, non-invasive
- Gold standard investigation for atherosclerotic disease – CT angiography. It acts as a road map for surgery

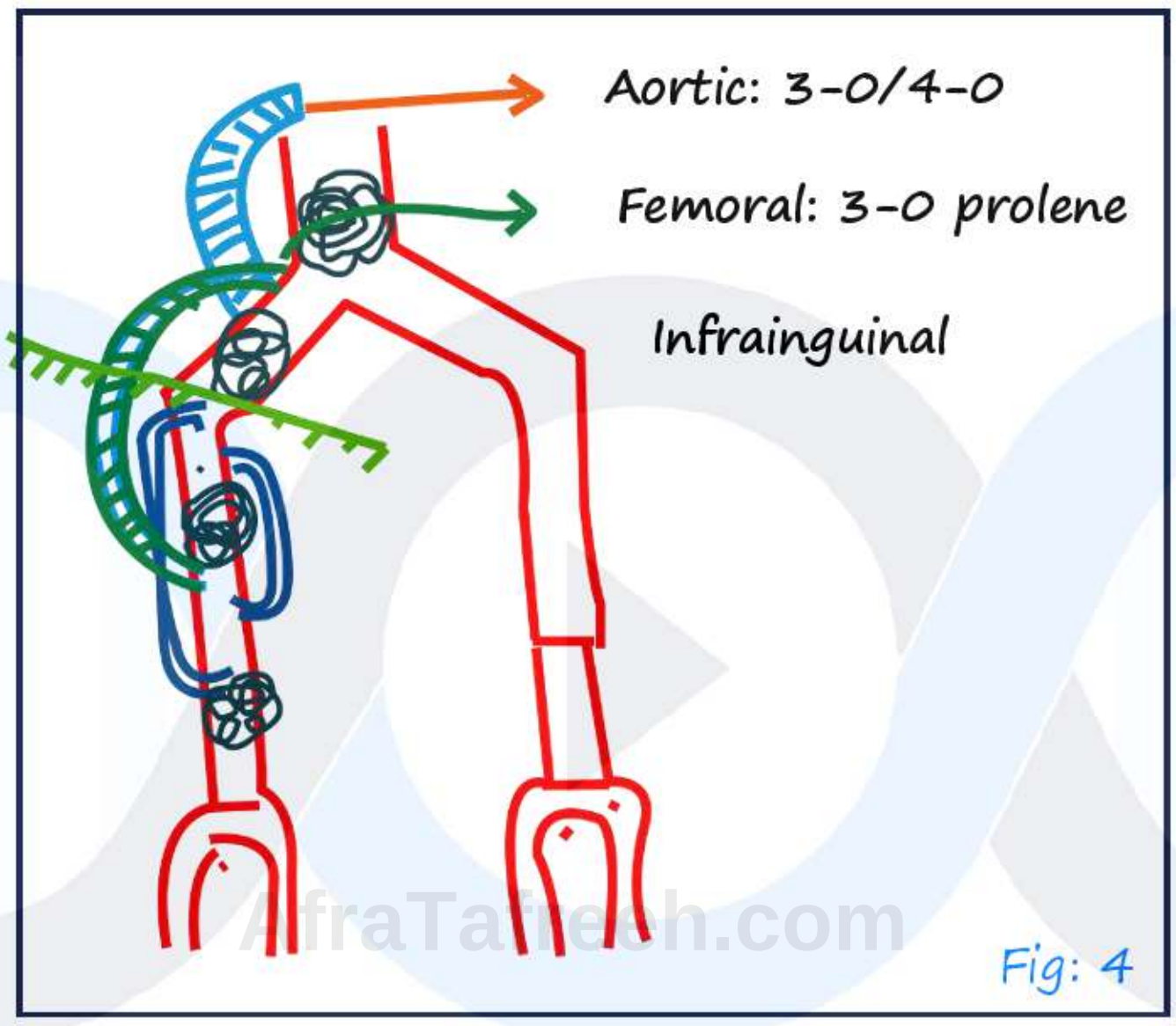

Fig: 4

- If there is thrombus/ occlusion at the aorta (or) occlusion in external iliac/ superficial femoral/ popliteal – due to thrombus, these are the places, we get atherosclerotic occlusions
- In olden days the treatment done to these patients is bypass operation
- Bypass operation are done with Dacron, poly tetra fluro ethylene/ patient own saphenous vein → can be 2 types
  a. Insitu saphenous vein
  b. Reverse saphenous vein

AfraTafreeh.com

- For aorta – iliac/ aortic replacement we use Dacron, for aorta, we use 3'o/ 4'o prolene sutures
- For iliac femoral bypass we use PTFE, suture material is 5'o prolene
- Infra inguinal bypass (femorotibial, femoropopliteal) is done with patient own saphenous vein
- Insitu vein means → in the same place we cut the vein above and below and anastomose with artery & destroy the values with valvotome
- If we reverse the vein, no need to destroy values
- Now these type of bypass procedures are obsolete
- Now a days doing angioplasty – minimally invasive vascular interventions. Seldinger needle is passed, we put a stent, intra-arterial stent is placed. It prevents the occlusion

TAO (Thrombo angiitis obliterans) 00:53:42

- Rare in western countries, common in India especially South India
- Criteria for TAO is

i. Patient has H/O smoking

ii. Onset should be before 50 years in male

iii. Lesion present, infrapopilteal only

iv. It can involve upper limb also

v. There will be superficial thrombophlebitis will be present

- No other risk factors e.g.: if patient has DM, he doesn't come under TAO
- In TAD occlusion is due to sympathetic over activity → There is vasospasm starts from popliteal artery – then anterior tibial, posterior tibial. Disease is confined below the popliteal artery, other arteries are normal
- It is bilateral, no thrombus, no occlusion. There is formation of multiple collaterals to the lower limb.
  - They are corkscrew collaterals
  - Tree root collaterals
  - Spider leg collaterals are the various collaterals seen on angiography
- It is a symmetrical lesion in both limbs
- Young make, symmetrical bilateral limb lesion, present with bilateral leg claudication pain

TUTORIALS
LOGIN FOR SUCCESS

Advice

- First stop smoking
- Do Bueger's exercises – increases collaterals to lower limbs. Example: Lies down and do cycling in air with the limbs
- Life style modification
- Only surgery may be beneficial is Lumbar sympathectomy
- While doing lumbar sympathectomy, one side L_1 should be preserved, to prevent retrograde ejaculation

AfraTafreeh.com

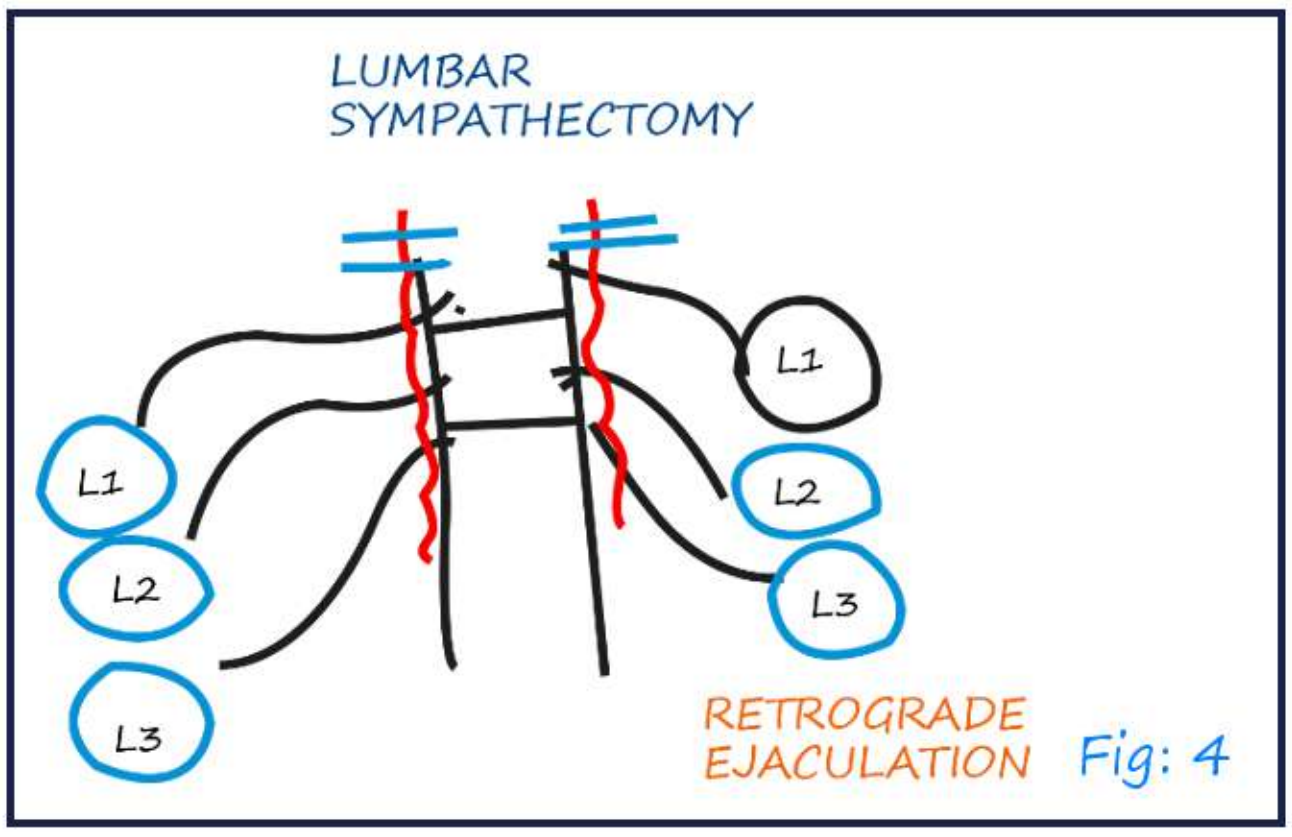

Fig: 4

Indications of lumbar sympathectomy in TAO

- Done only for
  - Rest pain
  - Ulcer
  - Superficial gangrene
- It is contraindicated in
  - Intermittent claudication pain
  - ABPI >0.3
  - Diabetic patients – in them already autonomic sympathectomy happened. So, no use of doing sympathectomy

TUTORIALS
LOGIN FOR SUCCESS

Arteriovenous fistula

- Abnormal communication between artery and vein is A-V fistula
- Most common cause is Iatrogenic. We create a fistula for dialysis purpose
- Most common acquired cause → penetrating trauma
- Genetic syndromes causing it
  - Sturge weber syndrome, Beckwith Weidman syndrome, klippel trenanauy syndrome

- CIMINO fistula is surgically created fistula in the wrist between cephalic vein and radial artery

- Pathophysiology:
  - Arterialisation of veins
  - Limb lengthening
  - Temperature ↑
  - Pulse rate ↑
- On examination: Machinery murmur (continuous thrill)

Nicoldani sign (or) branham's sign

- If we compress more proximally to an A-V fistula, immediately the number disappears, swelling decreases, thrill decrease, P.R decrease

Raynaud's disease 01:06:56

- It happens due to unknown cause
- It can also happen due to scleroderma, SLE
- Main problem occurring here is vasospasm of limb/ hand mainly due to cold exposure/ continuous vibration exposure
- The patient will develop 3 phenomena in same limb
- Pneumonic: W-B-C
  - White
  - Blue
  - Crimson red

AfraTafreeh.com

- The limb color in Raynaud's phenomenon (in the sequence)
- Because of vasospam arteries and veins are occluded – so white in color
- Next, artery is occluded and veins will open up they stagnate venous blood – cyanosis due to absent of oxygenated blood gives blue color
- Next, artery also opened and limb becomes red color
- Treatment of Raynaud's
  - CCB
  - Avoid cold
  - Cervico dorsal sympathectomy (doubtful benefit)

- Miller cuff: - It is cuff between artery & prosthesis. Interposition of veins.

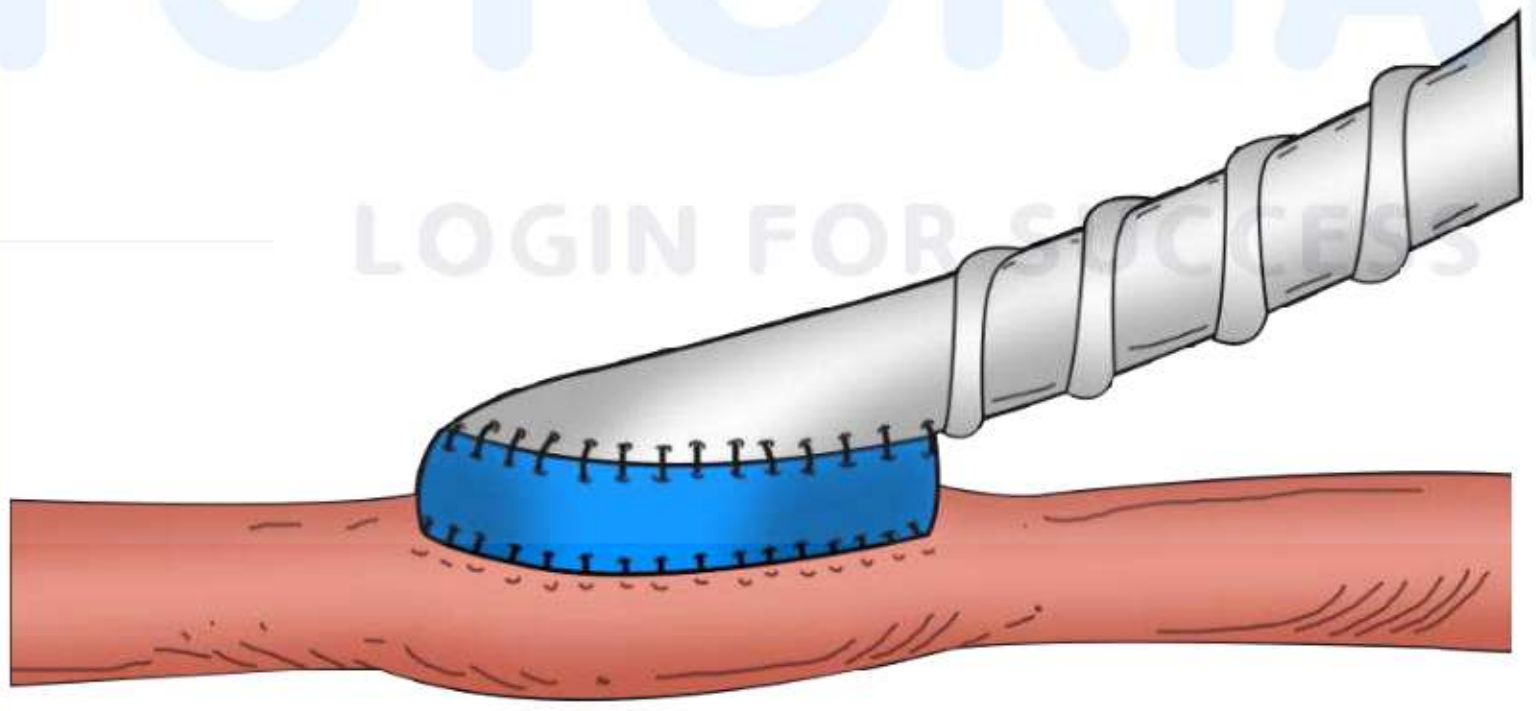

Fig: 4

VENOUS SYSTEM

Venous system 00:00:33

- Deep venous system – contains femoral vein, popliteal vein, anterior tibial vein and posterior tibial vein (Below the deep fascia)

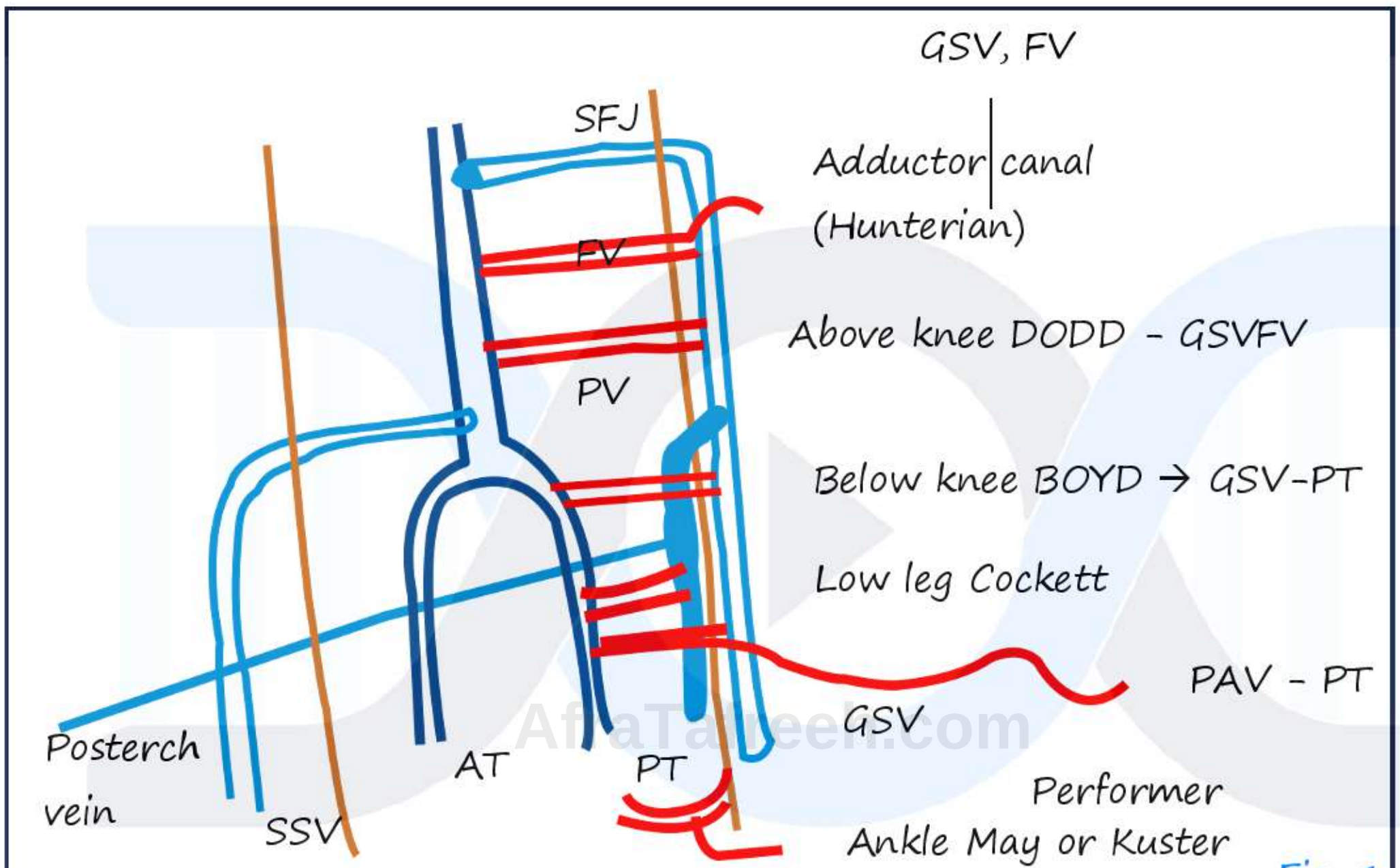

Fig: 1

- Superficial venous system → contains great saphenous vein GSV running on medial side, above the deep fascia and enters fascia.
  - GSV enters femoral vein at saphenofemoral junction.
  - Short saphenous vein joins at saphenofemoral junction into popliteal vein on lateral side at sapheno popliteal junction.
- Perforators: - Those veins which enter superficial vein to deep vein
  - Mid-thigh level →Adductor canal perforator aka Hunterian perforator

AfraTafreeh.com

- Above knee level → Above knee perforator aka Dodd perforation
- below knee perforator aka Boyd perforator
- lower leg perforator aka Cockett perforator
- Ankle perforator aka May/Kuster perforator

- These 5 perforators are on medial side
- Hunterian perforator connects GSV (Superficial vein) and femoral vein (deep vein)
- Dodd perforator connects GSV and femoral vein
- GSV has a tributary called posterior arch vein
- Boyd perforation is from GSV to posterior tibial vein
- lower leg perforator/ cockett posterior is from posterior arch vein and posterior tibial vein

Varicose veins 00:07:08

Basic pathophysiology

i. if there is DVT, the superficial veins cannot drain and results in varicose veins.

ii. If there is incompetence of the valve at saphenofemoral junction

iii. If the perforators are incompetent.

- These 3 problems can be detected by simple clinical tests.

Clinical features of varicose veins

- Dilated tortuous veins (>3mm)

DBMCI TUTORIALS LOGIN FOR SUCCESS

- Skin will be stretched.
- Eczema, pigmentation
- Ulceration (maybe) on medial side of foot
- Loss of hair
- Brittle nails

  (All these skin changes due to increased venous pressure)
- Lipodermatosclerosis → is a skin pigmentation due to increased venous pressure due to rupture of RBC, releasing and deposition of hemosiderin
  - Telangiectasia – vein size <1mm
  - Reticular vein – 1-3mm diameter
  - Varicose vein - >3mm diameter

AfraTafreeh.com

Tests for varicose veins 00:11:18

a. Saphenofemoral incompetence

↓

Trendelenburg – I

Morrisey's cough impulse

b. Perforator incompetence

↓

Trendelenburg – II

Multiple tourniquet test

Pratt's test

Fegan test

c. DVT → Perthes

Modified perthes

TUTORIALS LOGIN FOR SUCCESS

AfraTafreeh.com

Old tests – Homan's sign

Mosis sign

Pratt's sign

Trendelenberg test – I 00:13:10

- Saphenofemoral junction (SFJ) is present 4cm below & lateral to pubic tubercle
- Either we tie a tourniquet at this level (or) compress SFJ tightly with thumb. First make patient lie down and reduce the varicose veins.
- After reducing, place finger (torniquet) over SFJ tightly press and make patient stand. After that when the moment you take away your finger over SFJ, Veins fill last from above downwards is seen.
- Trendelenburg II – Here we do not take out the finger, by keeping the finger there, we will see veins slowly filling from below downwards. It is due to perforator incompetence.

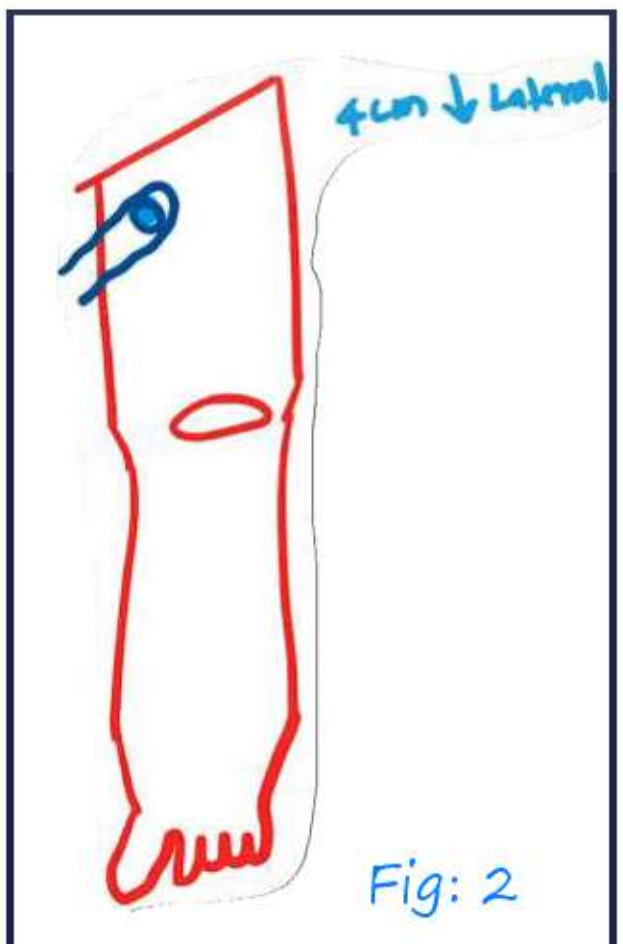

Fig: 2

Multiple tourniquet test: -

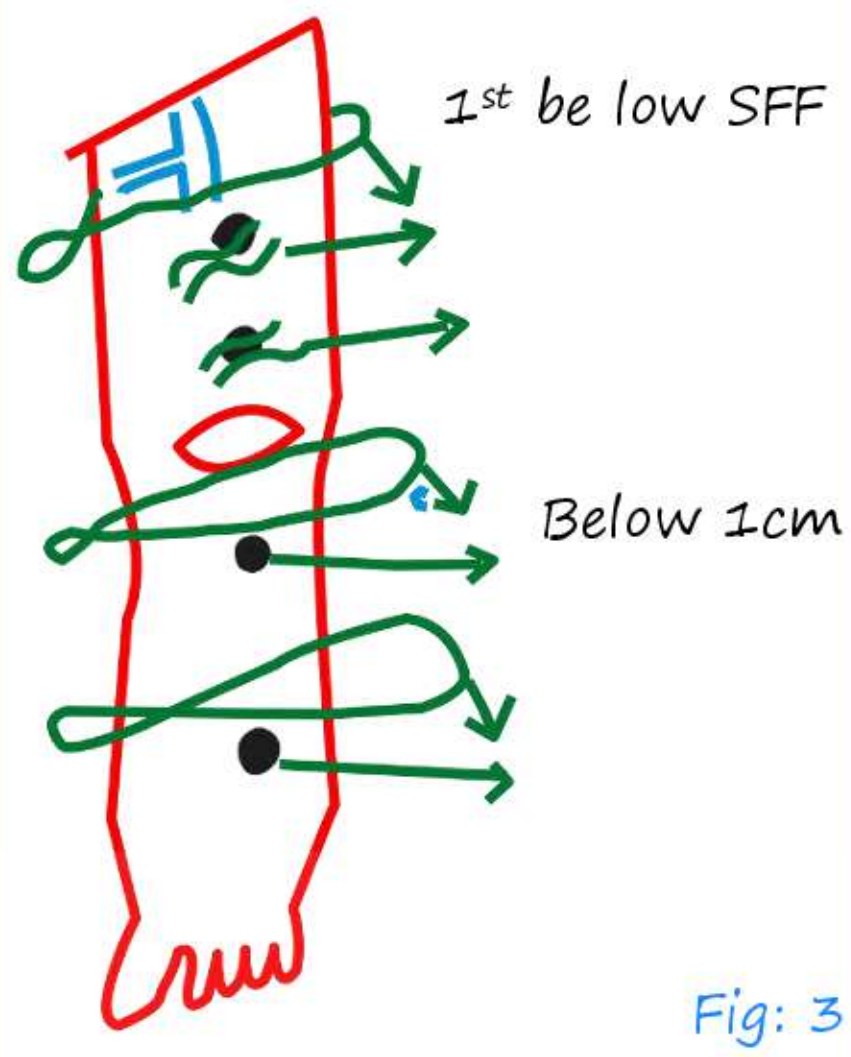

Fig: 3

- Tie the tourniquet at multiple levels
- First is at below the SFJ
- Another at below the knee
- Another on lower leg

  And if the veins appear between SFJ torniquet and the below knee torniquet that means incompetence of hunterian perforators/ above knee perforator incompetence.
- It is used to know perforator incompetence

Perthes Test – For DVT 00:17:16

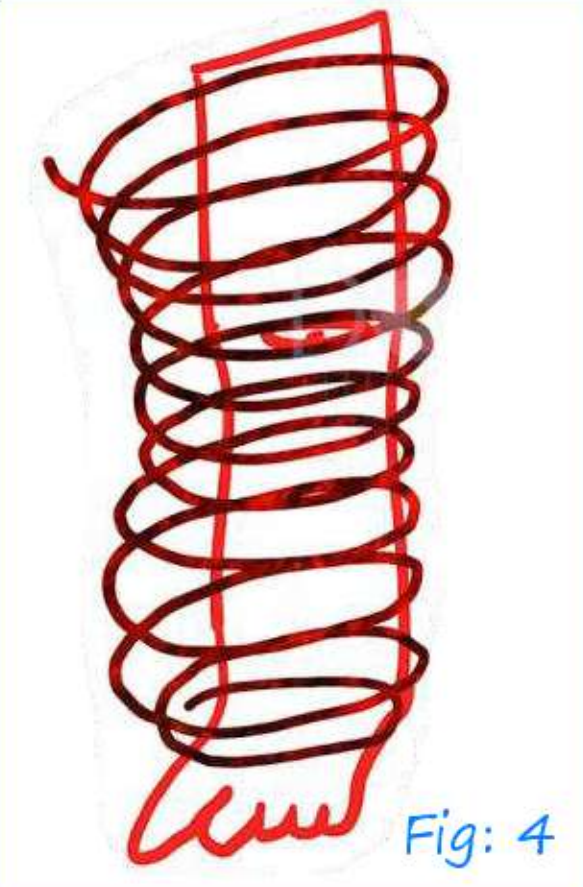

Fig: 4

AfraTafreeh.com

- Since there is DVT, only superficial veins drain blood. If we apply tight elastocrepe bandage, compressing the superficial veins & ask patients to walk, patient complains severe pain on walking. It is a subjective test as patient only tells pain.

Modified Perthe's Test

- Put a tourniquet tightly below SFJ and ask him to walk.
- Now already dilated veins become more dilated. We can see dilatation and patient also c/o pain. So, it is both subjective and objective test.
- Pre requisite for the test → To do this test there should not be any perforator incompetence. If perforator incompetence ⊕ then we won't get dilatation & pain.

Pratt's test – To look for perforator incompetence

- Put an elastocrepe bandage tightly from below up and completely empty the veins.
- Now take another bandage and start applying from above downwards, we remove the previous bandage. We can note the bulging of perforators. Make a mark at below out point.
- After removing both bandages, where ever the blow out is present, on palpation, the deep fascia will have a pit/gap.
- This is called FEGAN's test.

Schwartz test

- If we have long varicose veins, we tap the vein below level with a finger and feel this impulse with another finger in the above/upper level. This is due to valve incompetency. So, valve incompetency can be detected.

Morrisey's cough Impulse test

- Put the finger on SFJ and ask patient to cough, we can see cough impulse positive. Before coughing we can see a bulge in the SFJ called saphenavarix (because of weakness)

DVT tests

- Homan's sign – Forceful dorsiflexion of the ankle
- Moses' sign – Forceful compression at mid-calf level.
  - Both causes severe pain and both can stimulate pulmonary embolus. So, these two tests are C/I.
- Pratts's sign – We do lateral compression of calf.

AfraTafreeh.com

CEAP classification of varicose veins 00:26:15

- Clinical Etiological anatomical pathological classification

Clinical

- C_1 – Telangiectasia (<1mm)/Reticular (1-3 mm)
- C_2 – Varicose Veins (> 3mm)

AfraTafreeh.com

- C_3 – Edema in the leg
- C_{4a} – Pigmentation/eczema in leg
- C_{4b} – Lipodermatosclerosis (or) Atrophie Blanche
- C_5 – Healed venous ulcer
- C_6 – Active venous ulcer

Etiological

- Ep – Primary
- Ec – Congenital
- Es – Secondary

Anatomical

- As – Superficial vein involvement
- Ap – Perforator involvement
- Ad – Deep vein involvement

Pathophysiological

- P_r – Reflex
- P_o – Obstruction
- P_{ro} – Reflex + Obstruction

Risk factors of varicose veins 00:30:04

- Family H/O
- Long standing job
- DVT
- Defective valves

- Mass in the abdomen
- Pregnancy
- Congenital → Klippel Trenanay syndrome

↓

i. Port wine stain

ii. Lateral varicose veins

iii. Limb lengthening/Hypertrophy

Complications of V.V

- Most common are skin complications
  - Eczema
  - Pigmentation
  - LDS
  - Atrophie Blanche
  - Inverted champagne bottle appearance of the leg.
  - Ulcer
  - Bleeding
- Skin ulcer – Exactly on medial malleolus, the venous pressure is very high there results an ulcer called varicose ulcer/venous ulcer.
- Most common site is Gaiter area
- It has sloping edge
- Floor is covered by granulation tissue.
- Base is formed by tibia
- This ulcer can bleed
- This ulcer can cause periosteitis tibia.

AfraTafreeh.com
TUTORIALS
LOGIN FOR SUCCESS

AfraTafreeh.com

- Because of pain, patient walks on tip toe → Equinus deformity.
- On long standing, the varicose ulcer can go into Marjolins ulcer → It is a type of squamous cell carcinoma.
- These ulcers are managed by Bisgaard method.

Investigations –

i. Hand held doppler

Obstruction → sound + (If there is an obstruction, a continuous sound is heard)

If we keep doppler over SFJ and compress the calf & leave it. We can hear the reflex sound as "Woosh sound". "Woosh sound" is heard on compression & release at SFJ. It is done to fine saphenofemoral incompetence.

ii. IOC → Color doppler (Duplex scan)

- If there is normal antegrade flow, the duplex scan shows it as color blue.
- If there is reflex, it is seen as red color (incompetent vein have reflex)
- Mickey mouse sign is seen in SF area on color doppler

↓

Face stands for femoral vein

Lateral ear is for femoral artery

Medial ear is great saphenous vein.

TUTORIALS LOGIN FOR SUCCESS

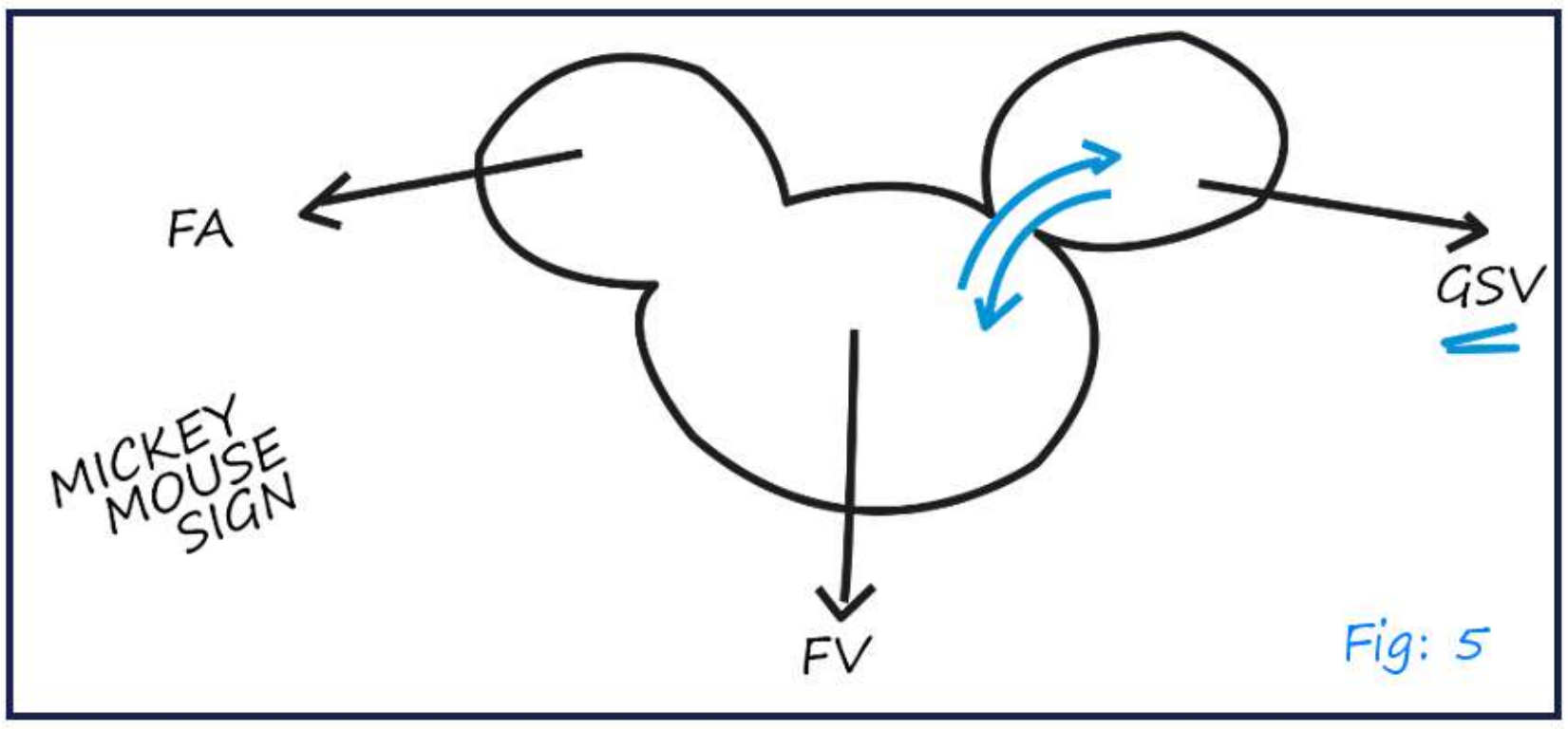

Fig: 5

- Mainly Duplex scan is done
  - i. To rule out DVT
  - ii. To mark the perforators

Management

- Compression stocking: (available to prevent varicose veins also)

AfraTafreeh.com

British classification of stockings

- Class 1 – It gives 14 – 17 mmHg
- Class 2 – It gives 17-24 mmHg
- Class 3 – It gives 25-35 mmHg
  - Usually we use class 3 – 25-35 mmHg stockings for established varicose veins & venous ulcers.
  - Class 1&2 are used as prophylactic stocking before the varicose veins have formed (or) in early stages of reticular veins/Telangiectasia

Venous Ulcer Management 00:40:55

Bisgaard method

- Ask patient to lift the leg (while sitting/lying)

AfraTafreeh.com

- Leg lifting
- Clean ulcer with water/normal saline
- Pus culture sensitivity – antibiotics
- If bleeding – Lift the leg (then bleeding stops)

- Simultaneously with the above, we should do 4-layer bandage should be applied to heal this venous ulcer
  - 1st layer – made up of cotton wool (rotate all along leg)
  - 2nd layer – cotton bandage
  - 3rd layer – elastic bandage
  - 4th layer – cohesive bandage
- In case of varicose vein ulcer with this 4-layer bandage, we have to give high pressure of 35-40 mmHg before giving this pressure, we have to rule out ABPI.
- Normal ABPI is 0.9-1.1
- If ABPI is 0.5 – 0.8, we use only 30mmHg pressure (to prevent peripheral artery disease to other complications)
- If ABPI is <0.5 → do not do compression at all first do revascularisation of artery before anything.
- Then clean the ulcer and put a split skin graft over ulcer.

TUTORIALS
LOGIN FOR SUCCESS

Surgical management of varicose veins 00:45:00

- The conventional treatment is Trendelenburg operation

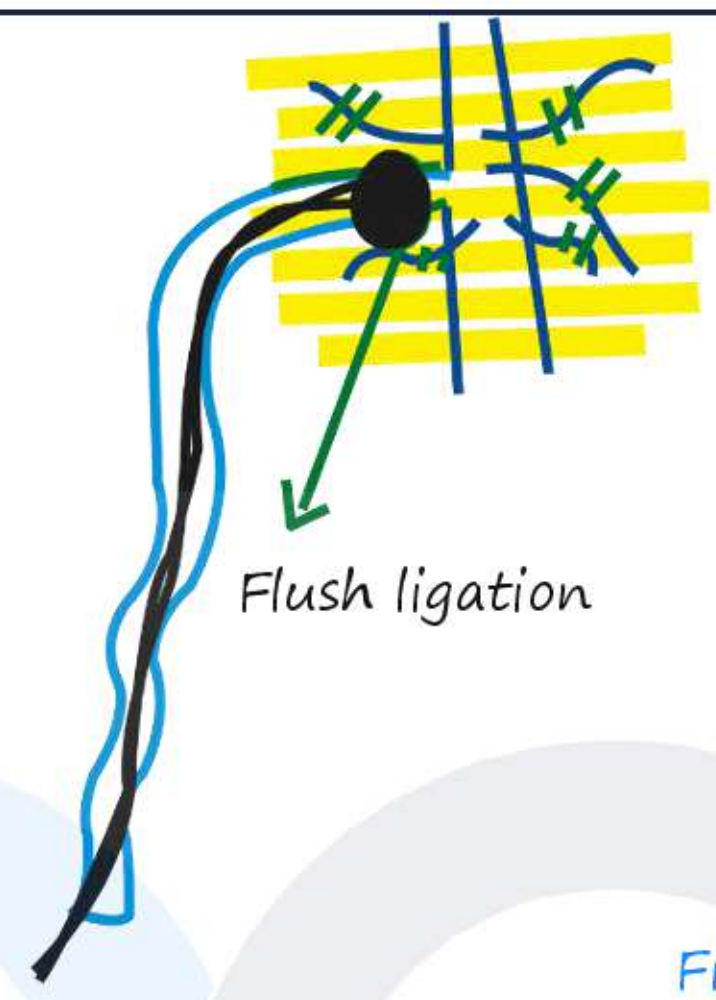

Fig: 6

- Here, first dissect the area, then identify the SFJH, ligate saphenofemoral vein as a flush ligation to the femoral vein
- At some time, ligate all the small tributaries (superficial veins) in the area
- This is called Trendelenburg operation – flush ligation of saphenous vein at SFJ and ligation of all tributaries.
- Now introduce a stripper from downwards (mild calf level). Tie th3e vein at SFJ and withdraw stripper. This stripper is called OESCH pin stripper. By withdrawing stripper, entire vein comes out.
- We should do this only up to mi calf level, not below this.

AfraTafreeh.com

AfraTafreeh.com

- If we go below midcalf level, we can injure saphenous nerve medially and sural nerve laterally.
- Before doing varicose vein surgery, we should ensure there is no DVT. Because if DVT is present, surgery is C.I, because, if the superficial vein which drains blood in DVT, If the superficial vein which drains blood in DVT, if we remove superficial vein, patient dies off venous gangrene.
- For perforators → we have to ligate them below the fascia (or) above the fascia.

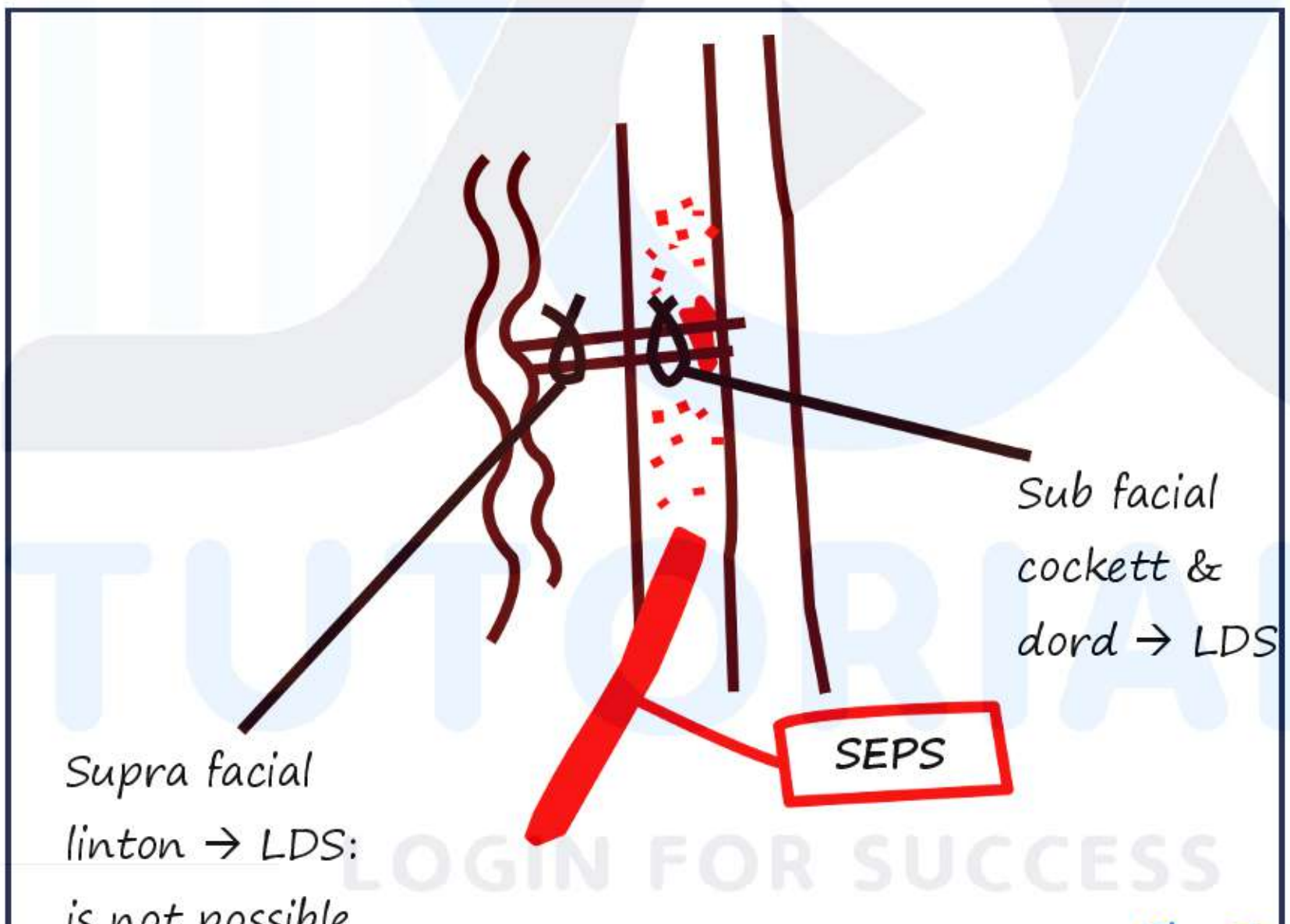

Fig: 7

- Above fascia called → suprafacial ligation of LINTON
- Below facia → subfacial ligation of COCKETT & DODD
- Latest operation is by laparoscopic minimally invasive, we go beneath deep fascia and clamp the

vessels called Subfacial Endoscopic Perforator Surgery)

- For lipodermatosclerosis, LINTON operation is not possible since fascia and skin are fibrosed (so c/f). we do COCKETT & DODD operation

Trivex system:

We throw light subcutaneously – we can see the veins, by minimally invasive method we use hooks, we hook the veins which are dilated and ligate them.

Foam sclerosants:

Under USG guidance we can inject sclerosants into dilated varicose veins, sclerosants used are

- STD – Sodium Tetradecyl sulphate (most common used)
- Sodium morrhuate
- Polidochanol
- Ethanolamine oleate

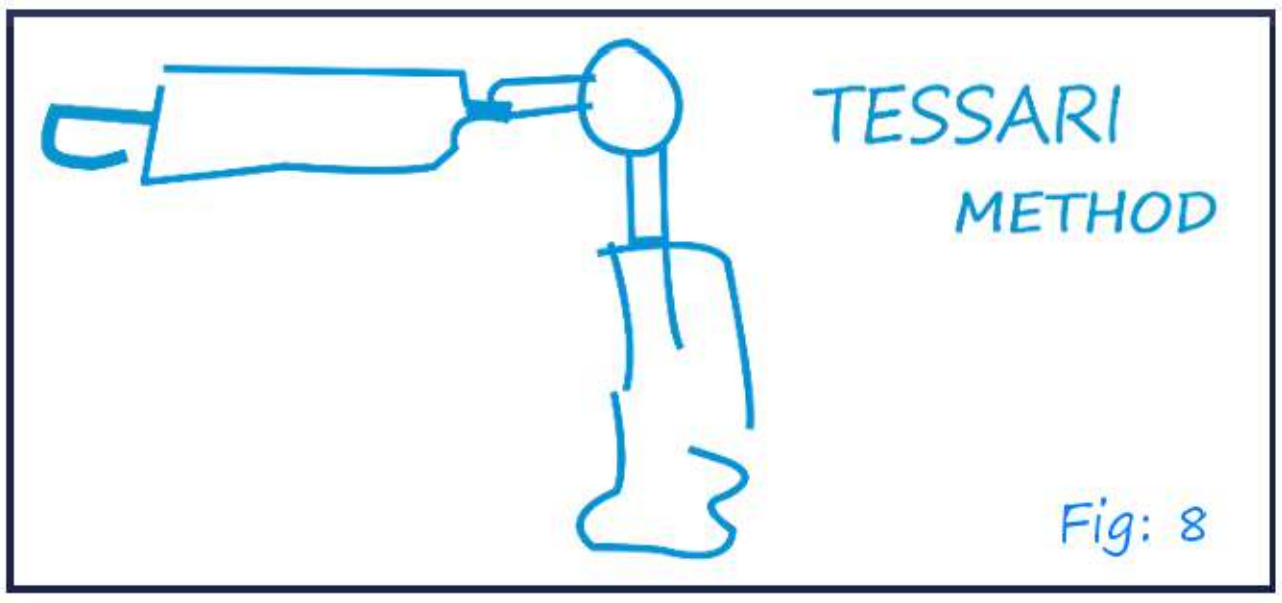

Fig: 8

AfraTafreeh.com

By the method of creating foam → with a 3 way stop cock with syringes called TESSARI method of foam sclerotherapy

Now a days we are doing endovenous laser ablation and radiofrequency ablation

EVLA	RFA
They introduce a laser catheter inside veins and 1470 nm laser is applied	They use electromagnetic current and produce thermal energy and burn out all vessels.
It coagulates the full vein and dilated tortuous veins without major surgery, varicose veins are cured	we have a preset cycle valve of current application is available we pass it inside and coagulate all vessels
Advantages: • Any size vein can be ablated • Can be used for perforators • Cheaper cost	Advantages: • Set standard protocol available • Easy for beginners • Less pain full • Less procedure times • Laser protocol is not needed (Wearing protective equipment)

Disadvantage: We have to use universal precautions	Disadvantage: RFA fiber costly cannot be useful for tortuous veins not useful for perforators.

DVT 01:02:22

- Most common clinical presentation is pain and swelling in calf
- Mostly unilateral
- Patient has only low-grade fever
- Most common site of DVT – Calf veins
- Most common site of DVT causing pulmonary embolism – femoropopliteal veins.

AfraTafreeh.com
TUTORIALS
LOGIN FOR SUCCESS

Sings of DVT

- Pratt's sign can be done
- Perthes test
- Modified perthes test

} Important for Δsis of DVT

Causes of DVT

- Patient factors
  - Old age
  - Obesity
  - Immobilization
  - Pregnancy/puerperium
  - High dose of estrogen therapy

AfraTafreeh.com

- H/O DVT
- Thrombophiliac disease

- Diseases associated
  - Trauma
  - Surgery to ortho #
  - Malignancy
  - Heart failure. MI
  - IBD
  - Nephrotic syndrome, renal failure
  - CVA
  - PNH, Homocystinuria

All the above causes lead to Virchow's triad of thrombosis

- Characterized by: stasis
  Hyper coagulable states
  Endothelial damage
  ] These will result in DVT

- Thrombophilia
  - Group of diseases which can cause thrombosis (or) hyper coagulable states
- Congenital causes
  - Antithrombin III deficiency
  - Protein c/s deficiency
  - Factor V Leiden deficiency
  - Lupus anticoagulant present
  - Dysfibrinogenemia
- Acquired causes

- Anti-phospholipid antibody
- Lupus anti-coagulant positive

Risk of DVT (or) Predisposing factor

- High risk surgery for DVT are
  - Any urology surgery > 40 years
  - Any abdominal surgery
  - Pelvic surgery
  - Orthopedic surgery
- Moderate risk are
  - General surgery > 40 years
  - Patient on OCP going for surgery
  - Any surgery lasting > 1 hour
- Low risk
  - Any uncomplicated surgery in <40 years
  - Surgery duration < 30 minutes

Modified well's criteria: - of DVT

(To diagnose) to predict DVT

-2 to 0 points → low probability

1 to 2 points → moderate probability

>2 points →high probability

Factor included are

- Lower limb injury/ surgery/ immobilization in plaster → 1 point
- Bed ridden > 3 day (or) any surgery within 4 weeks → 1

AfraTafreeh.com

- Clinical examination → patient has
  - Tenderness – 1
  - Swollen limb -1
  - Calf diameter > 3cm →1
  - Pitting edema → 1
  - Dilated superficial veins → 1
- History → patient has previous H/O DVT – 1

  H/O malignancy – 1

  H/O drug abuse – 3 points.
- Alternate diagnosis more likely "-2" score (minus 2 score)
- DVT going for pulmonary embolism is predicted by modified well's criteria
- Here score >4 – suggestive of pulmonary embolism

  <4 – less likely to have P.E
- Clinical exam → signs and symptoms → predict DVT → 3 Points
- Alternative Δs less likely than DVT → 3 Points
  - HR > 100/min
  - Hemoptysis
  - Patient has H/O immobilization for > 3 days (or)
  - Surgery done < 4 weeks
  - Patient has H/O DVT /P. E
  - H/O malignancy

Prevention of DVT

A. Mechanical method

- Early mobilization is recommended
- Pneumatic compression device stockings

B.Pharmacological method

- It is best to prevent
- Injection heparin – monitor apt
- Injection LMWH – used now, no need to monitor

  ↓

  Used for prophylaxis
- Warfarin is not used for prophylaxis

  ↓

  Only used for treatment of DVT

AfraTafreeh.com

Treatment of DVT

- First 5 days (1-5) → give heparin + warfarin

  >5 days → stop heparin – give warfarin

  ↓

  We should monitor PT/INR to prevent toxicity of warfarin
- If first episode → 3 months warfarin is enough

  recurrent episode → lifelong warfarin is given
- Thrombolytics are not used for calf vein DVT, but used for iliac vein involvement like alteplase, streptokinase, etc.

AfraTafreeh.com

INR: - International normalized ratio

INR = Patient of patient

Patient of control

= 1 to 1.1 normal value

If INR >1.4 → no surgery is advised

If <1.4, FFP should be given before surgery

- In a case of DVT, patient with warfarin therapy
  → the targe INR is 2 to 3.
- In a case of patient with mechanical heart valve with warfarin → 2.5 to 3.5 is target value.

Surgical Treatment of DVT

- Thrombectomy → if a huge thrombus in iliac (or) femoral veins, we open to remove thrombus and keep an IVC filter known as green field filter to prevent further more thrombus formation to P.E.
- Bypass operation: - if patient has thrombus in iliac vein, we can bring saphenous vein and anastomose to deep vein. so, the blood from deep vein will flow through opposite side saphenous vein to go up

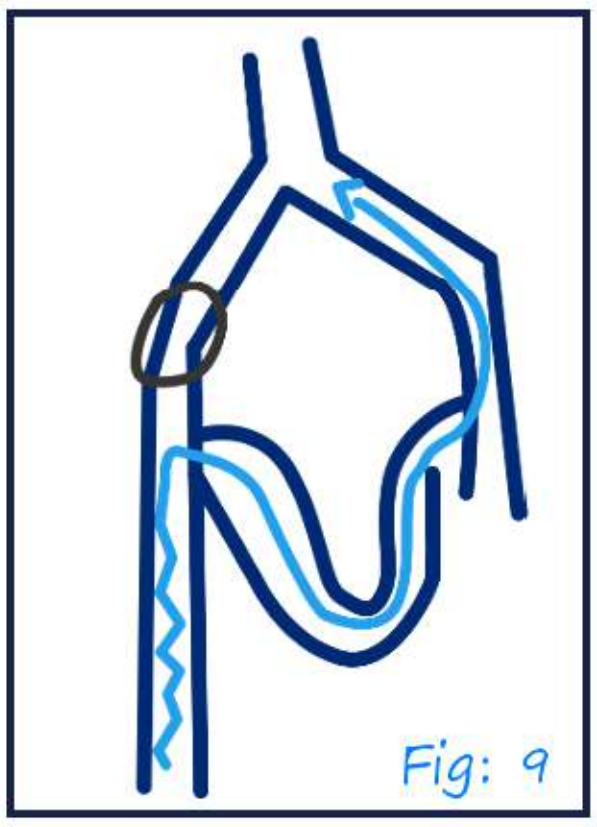

Fig: 9

- This is called palma operation

Green field filter indication

i. When anticoagulants are clinical example: - cerebral hemorrhage

ii. Patient with DVT + Anticoagulants with recurrent pulmonary embolism

May thurner & cockett syndrome

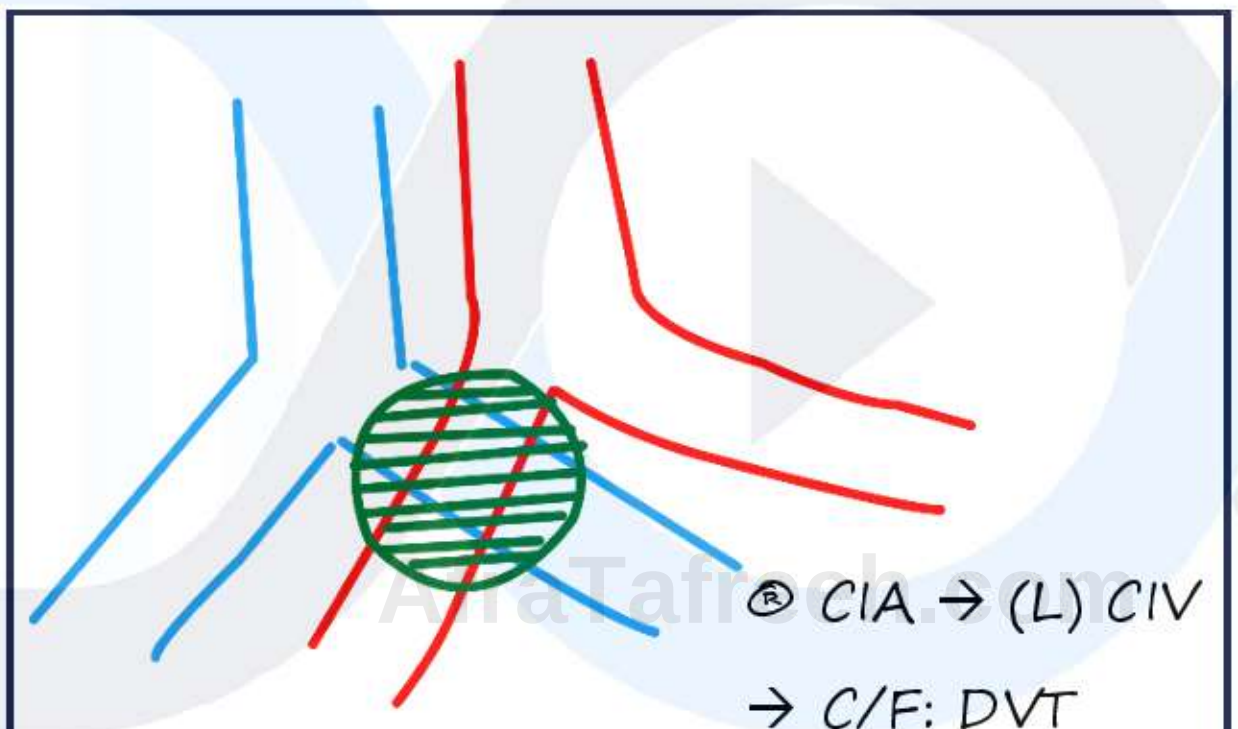

Fig: 10

AnnaTafrosh.com
TUTORIALS
LOGIN FOR SUCCESS

- Ⓡ common iliac artery is running on the Ⓛ common iliac vein. So, Ⓡ common iliac artery compressing Ⓛ common iliac vein resulting in clinical feature like DVT called MTC syndrome.
  - Phlegmasia alba dolens (white leg)
    Here deep veins are all thrombosed
    Superficial veins are patent – leg is white in color
  - Phlegmasia cerulea dolens (blue leg)
    Here deep veins and superficial veins, both are thrombosed.

AfraTafreeh.com

- So, leg is in a venous gangrene stage
- It is an emergency and immediate surgery needed
- It is most common seen in malignancy patients.

TUTORIALS
LOGIN FOR SUCCESS

LYMPHATICS

Lymphedema 00:00:15

- Most common cause worldwide: Filariasis
- Most common cause upper limb: Post mastectomy

Classification

1° ↓ Congenital ↓
- <1yr – Milroy disease
- 1-35 – Meigs disease
- >35 - Tarda

2° ↓ Causes ↓
- Filariasis
- Fungal infection
- Radiotherapy
- Malignancy
- Surgery – MRM
- Trauma
- Superficial thrombophlebitis
- DVT
- Silica exposure

AfraTafreeh.com
TUTORIALS
LOGIN FOR SUCCESS

Primary lymphedema

<1yr (Congenital)	1-35yrs
B/L up to thigh	↓
Milroy's disease	Lymphedema precox (Meig's)



- Most common – Females
- Most common – U/L
- Below knee

> 35yrs – Lymphedema Tarda

Clinical features -

- More confined to foot and toes, ankle

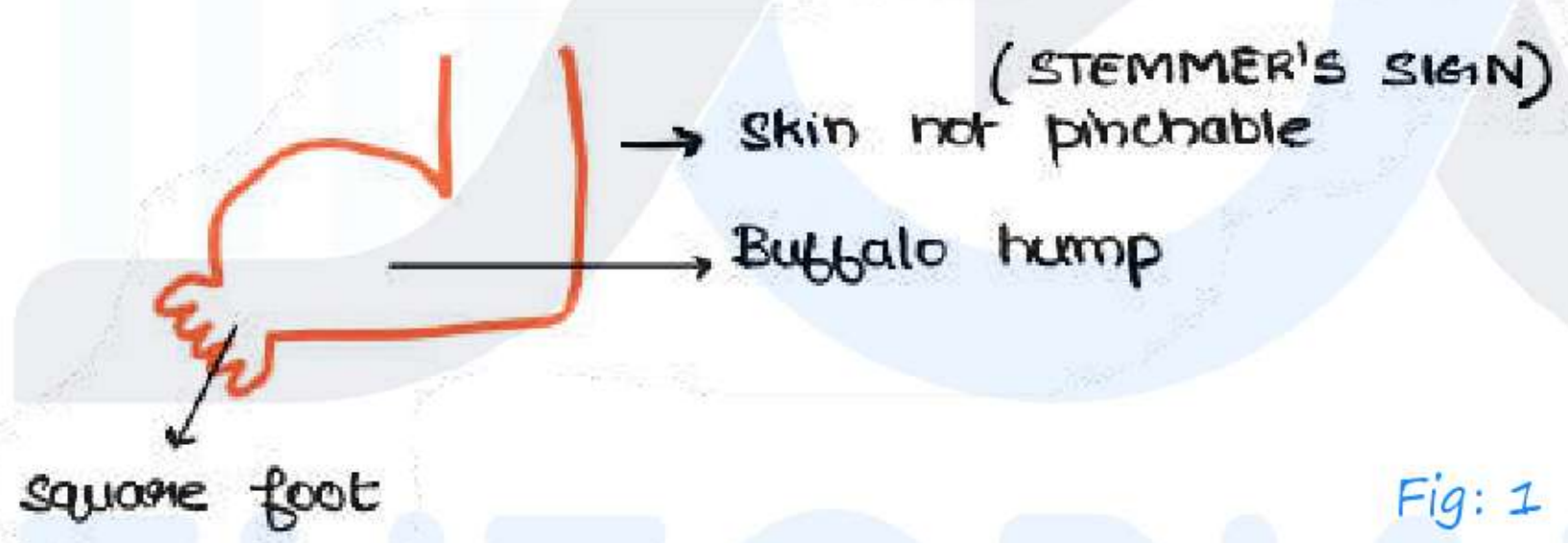

Fig: 1

- Eczema
- Fungal + Skin (Dermatophytosis), Nail (Onychomycosis)
- Fissures, Verruca, Wart
- Ulceration is unusual → R/O venous insufficiency

Lymphangioma 00:07:28

- Dermal lymphatics looking like blister – thrombosed nodules
- Types
  - <5cm – Lymphangioma circumscriptum

- Diffuse – L. Diffusum
- Reticulate – Lymphedema abigne
- Lymphangiomas can OOZE out K/a Lymphorrhea / Chylorrhea
- Other complications: Diarrhea

  Chylothorax ⎤ Chylous reflex
  Chyluria ⎦

Brunner's clinical grading 00:10:34

- Grade I – Pitting edema (+) ↓ On lying overnight
- Grade II – No pitting, no reduction, Stemmers sign positive
- Grade III – Fibrosis papilla → Irreversible skin changes

Conservative treatment

- Pain management
- Antibiotics (Streptococcal)
- Skin: Moisturizers, antifungal ointment
- Multilayer compression stockings > 35mmHg

AfraTafreeh.com
TUTORIALS
LOGIN FOR SUCCESS

AfraTafreeh.com

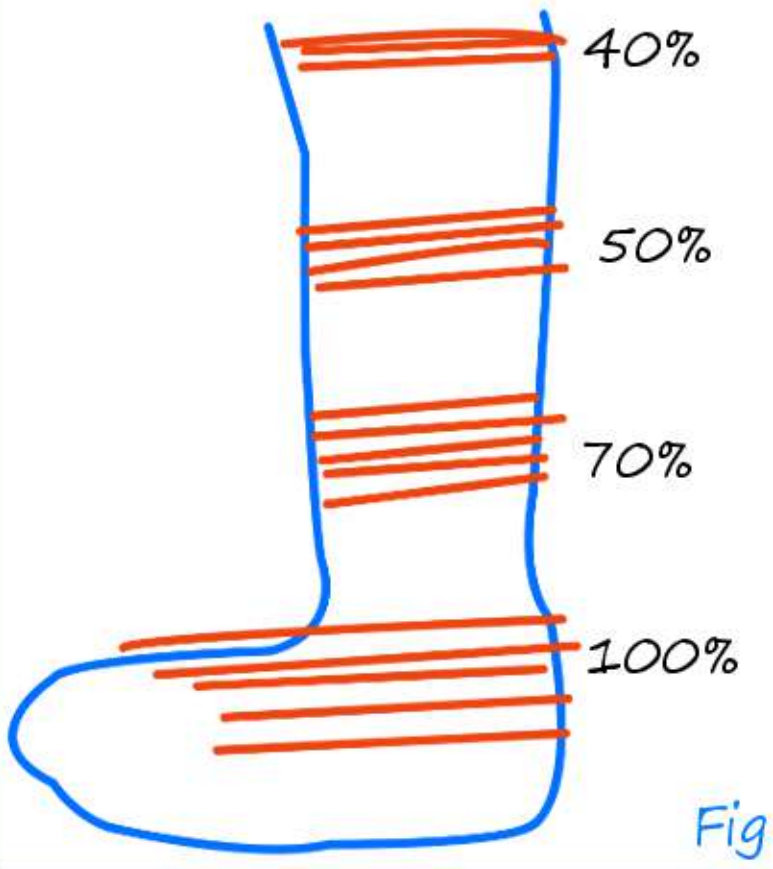

Fig: 2

- Exercises – Not vigorous exercises
  Swimming
  Rhythmic exercises
- Drugs T. DEC

Surgical options 00:15:25

Surgical options

Bypass

- Omental pedicle
- Skin bridge (Gillies)
- Ileal mucosa (Kinmonth)
- Lymphaticovenular
- LN-SV (Kinmonth)

Limb reduction

- Charks
- Sistruck
- Thompson
- Homans

TUTORIALS LOGIN FOR SUCCESS

Charles:

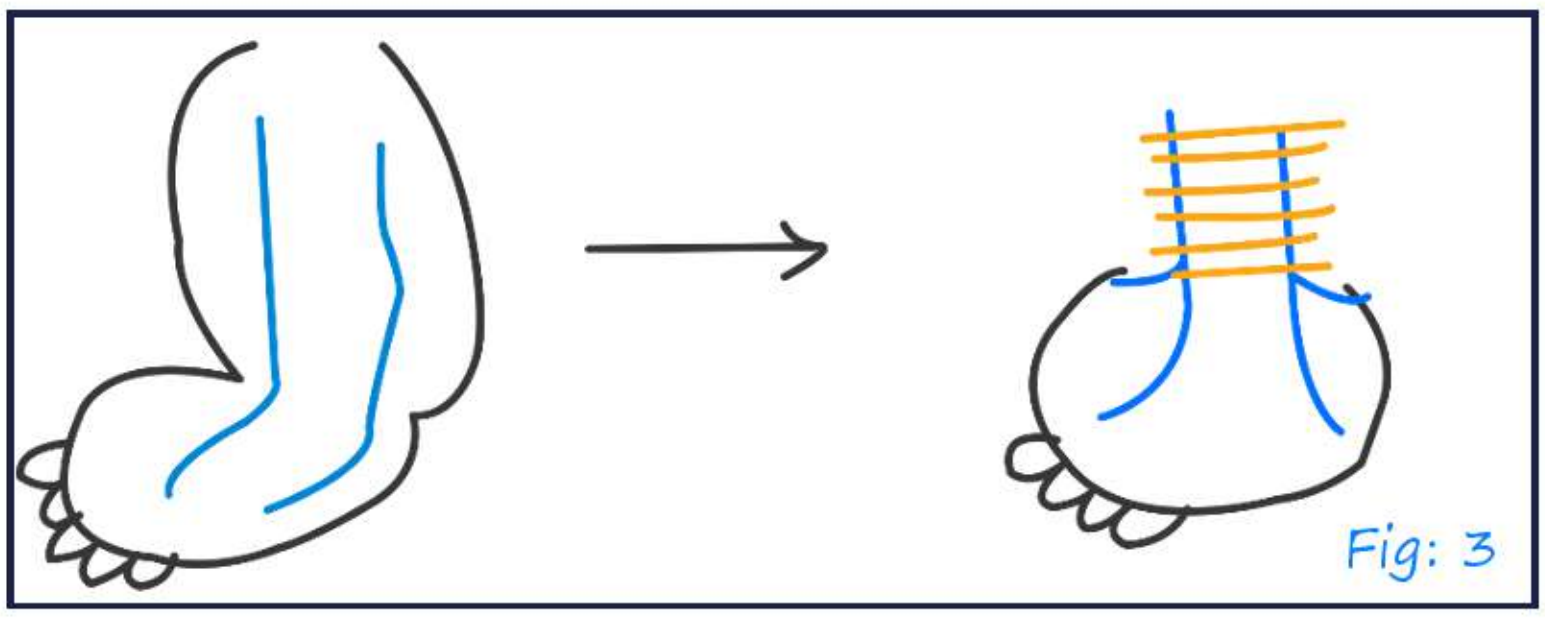
Fig: 3

- Entire skin and SC tissue removed

  ↓

  SSG done
- Lymph OOZE (+)
- Not done now a days

Sistrunk

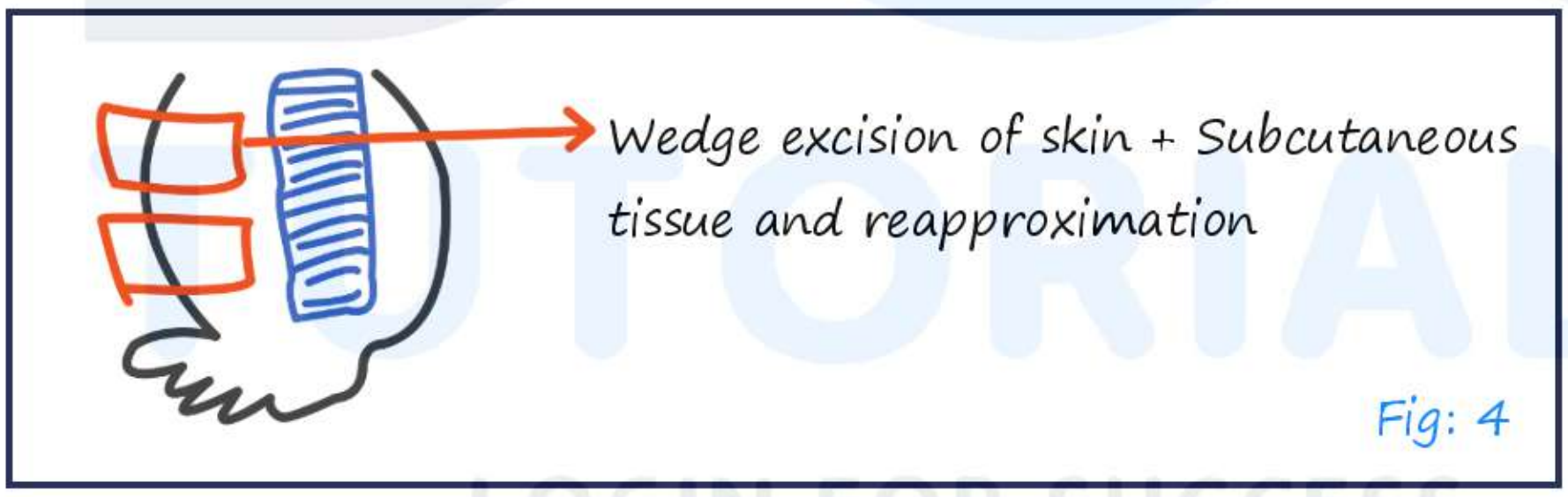

Fig: 4

Thompson

- Buried dermal flap
- Pilonidal sinus can happen

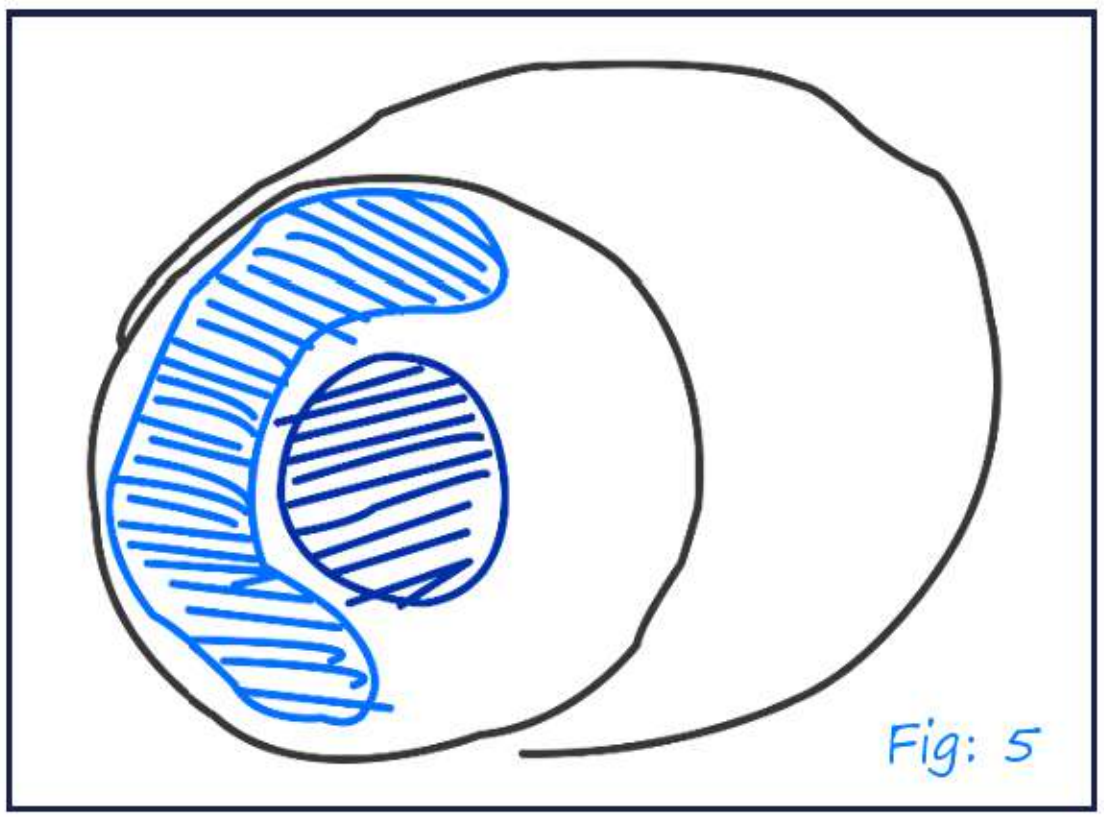
Fig: 5

AfraTafreeh.com
TUTORIALS
LOGIN FOR SUCCESS

AfraTafreeh.com

Homan's

- Flap is raised all subcutaneous tissue beneath are removed → Reclose the flap
- Complication skin flap necrosis
- Most satisfactory operation

Chyluria

- Most common: Filariasis, Ascariasis, Malaria, TB
- 1-2%
- Clinical features: Painless milky white urine

  ↓

  Hypoproteinemia

  Clinical features: - Renal Colicky +
- IV urography/Lymphangiography
- Surgery treatment
- Sclerosants are also tried.

DOC TUTORIALS
LOGIN FOR SUCCESS

PLASTIC SURGERY

Pressure sores 00:00:35

- Also known as bed sores
- Seen in bed ridden patients

Pathophysiology

- Capillary pressure >30mm Hg

↓

Ischemia

↓

Loss of skin, subcutaneous tissue

AfraTafreeh.com
DOC TUTORIALS
LOGIN FOR SUCCESS

Classification

- Stage I – Erythema
- Stage II – Partial thickness (Epidermis + Part of dermis)
- Stage III – Full thickness (Epidermis + Dermis) → Extending up to subcutaneous
- Stage IV – Involvement of muscle, fascia and tendon

Most common sites of bed sore

- Indra – Most common – Ischium
- Gandhi – Greater trochanter
- Statue – Sacrum
- Has – Heel
- More – Malleoli (Lateral > medial)

AfraTafreeh.com

- Ornaments – Occiput

Pressure sore Fig: 1

Prevention of bed sore

- Changing the position of patient every 2 hours
- If sitting in wheel chair, lift 10min for 10 seconds
- Aqua bed

TUTORIALS
LOGIN FOR SUCCESS

Management

- Moist dressings
- Debridement
- VAC devices → (Negative pressure of 120mmHg

TOC

Necrotizing fasciitis 00:08:16

- Rapidly progressing bacterial infection causing necrosis of subcutaneous tissue, skin, fascia and muscles

- Most common organism – Group A beta hemolytic streptococci
- Usually, polymicrobial
- Comon in immunocompromised patient
  - DM
  - Cancer
  - Chemo treatment
- Seen in scrotum – Fournier's gangrene →shameful exposure of testis
- Seen in abdominal wall → Meleney's gangrene
- Most common seen in lower limbs
- Rarely involves head & neck
- **Treatment:**
  - High flow O2 (Hyperbaric O2)
  - Debridement
  - Higher antibiotics

TUTORIALS
LOGIN FOR SUCCESS

AfraTafreeh.com

Cellulitis vs Erysipelas 00:12:11

- Both are caused by streptococcal pyogenes

Cellulitis

↓

Involves S.C tissue (Mainly) + deeper tissue

- Poor demarcation is seen
- Bacteremia (+) tenderness
- S.C tissue is absent in ear
- Ear is not affected

Erysipelas

↓

Involves skin + s.c tissue

↓

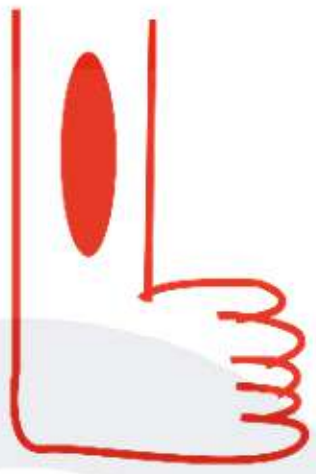

- Boundaries are well demarcated
- Loss of skin → Toxemia (+) (+)
- Ear is affected in erysipelas
- Milian's ear sign positive
- Butterfly shaped lesion over face

TUTORIALS LOGIN FOR SUCCESS

Abscess 00:16:32

2 types

Pyogenic
↓
Bacterial
↓
Staph aureus

- Inflammation (+)
- Drained by cruciate incision

Cruciate incision not done in

- Parotid
- Neck
- Axilla

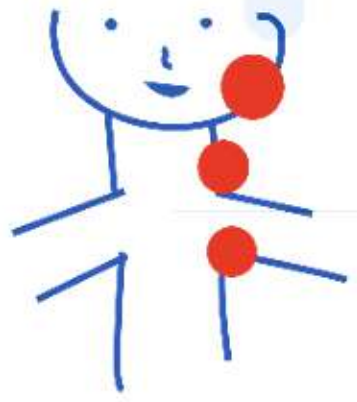

Lister's sinus forceps

- Lister's sinus forceps used wherever there are neurovascular structures
- Hilton's method of drainages

Cold
↓
TB (most common)
leprosy syphilis
No signs of inflammation



Forms sinus/Fistula after drainage so drained in a non-dependent way

AfraTafreeh.com
TUTORIALS
LOGIN FOR SUCCESS

AfraTafreeh.com

Hardenites suppurativa 00:20:52

- Apocrine sweat gland infection caused by S. aureus
- Most common – Axilla & Public region
- Most common in DM patients
- Not to shave axilla, cut the hair
- Extensive hardenites suppurativa needs SSG

Carbuncle

- It is also rapidly spreading cellulitis infection
- Common in DM
- Caused by S. aureus
- Most common – Nape of neck

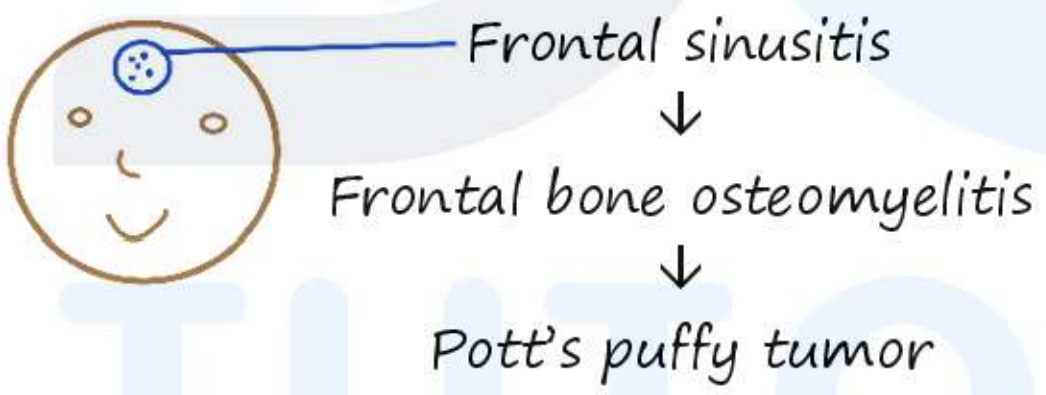

- Frontal sinusitis causes frontal bone osteomyelitis
- It can extend deeper and cause subdural empyema also
- Treatment: I & D

Ulcer 00:27:00

- Discontinuity of skin epithelium
- Parts of ulcer

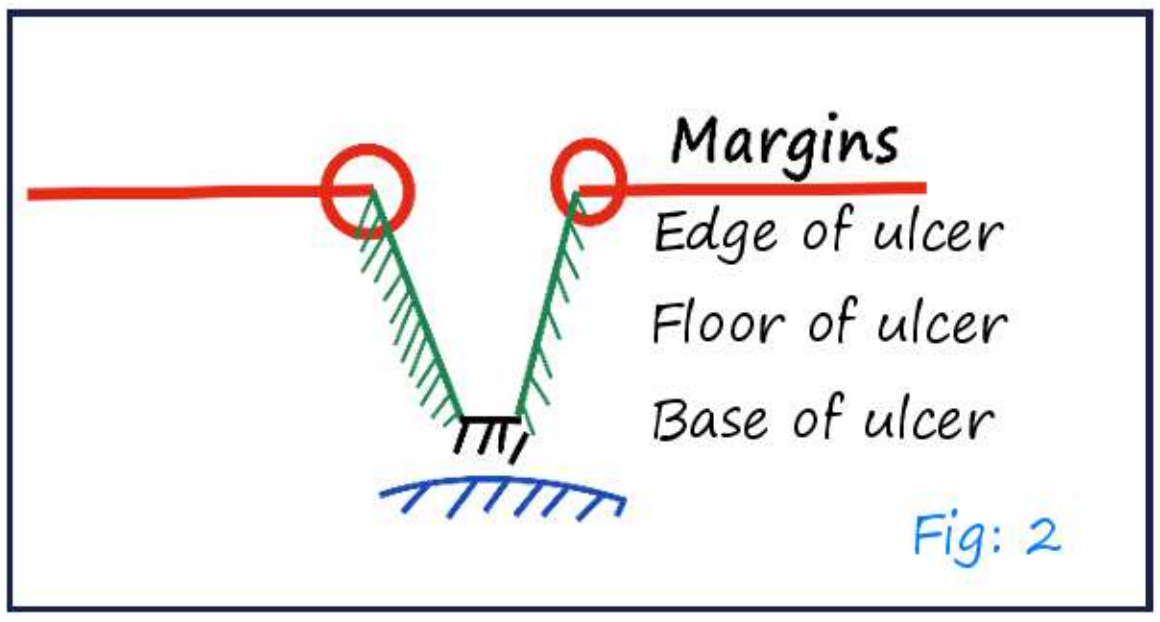

Fig: 2

- Floor of ulcer → Seen on inspection
- Base of ulcer → Seen on palpation
- Floor has → Slough & Granulation tissue
- Based on the edge of ulcer → Various types

	Sloping edge ↓ - Healing ulcer - Venous ulcer
	Punched out ↓ - Syphilis - Trophic ulcer - Arterial ulcer
	Undermined edge ↓ - TB
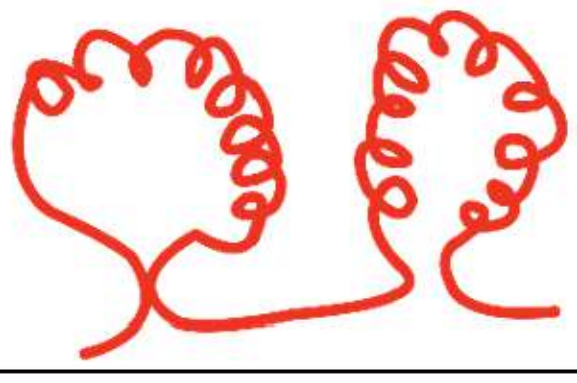	Rolled out ↓ - BCC (Rodent ulcer)
	Everted edge ↓

TUTORIALS LOGIN FOR SUCCESS

AfraTafreeh.com

	- SCC
	- Venous ulcer seen in varicose veins on medial side - Long standing venous ulcer can get converted to malignancy known as Marjolijn's ulcer ↓ - SCC - Can arise from burns, venous and keloids - No LN mets - When growth crosses normal epithelium Then LN mets (+) are seen

DOC TUTORIALS
LOGIN FOR SUCCESS

Swellings 00:32:08

- Lipoma
- Sebaceous cyst
- Dermoid cyst

Lipoma

- Most common skin swelling

- Universal tumor
- Dercum's disease → Multiple painful lipomas
- Emergency
  - GIT (Intussusception)
  - RT (Respiratory obstruction)
- Malignancy liposarcoma
  - Thigh
  - Retroperitoneum
- Clinical effects
- Slip sign (+)
- Pseudofluctuation (+)
- Transillumination (+) / (-)
- Treatment – Enucleation/Excision

AfraTafreeh.com
TUTORIALS
LOGIN FOR SUCCESS

Sebaceous cyst

- Also known as epidermoid cyst
- Obstruction of sebaceous duct

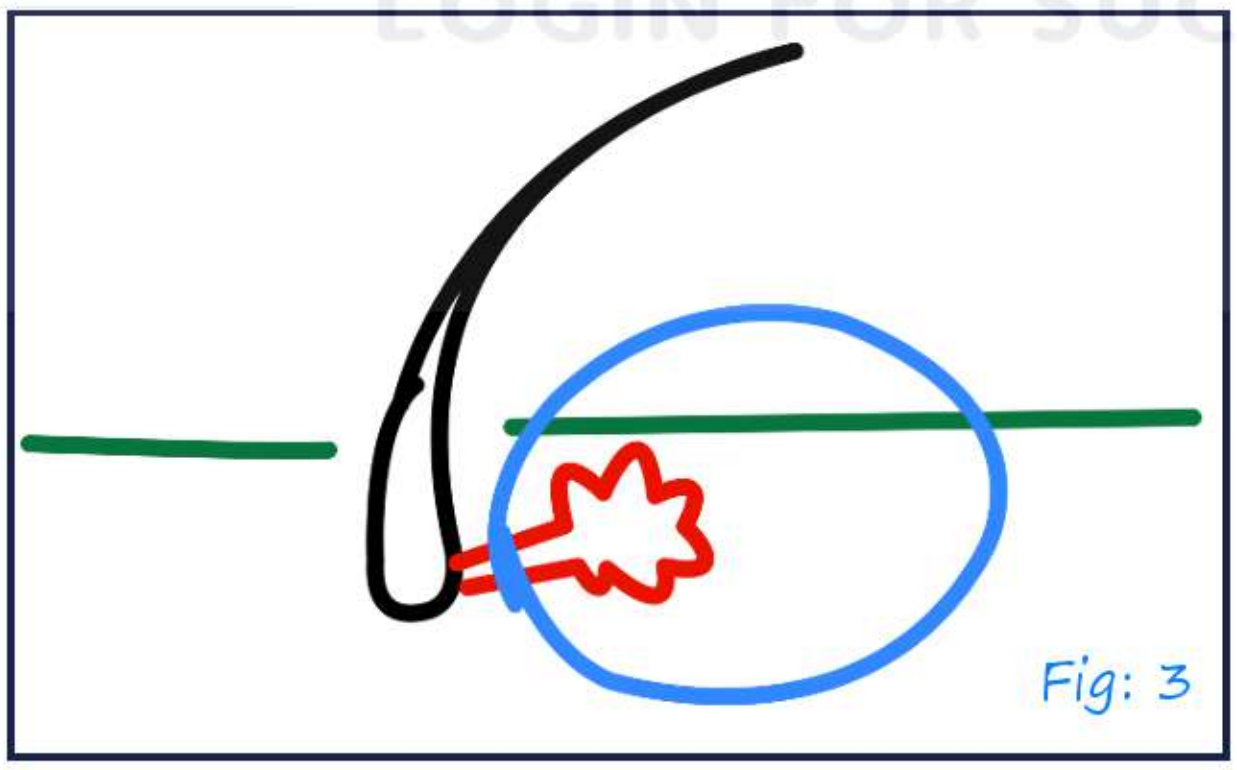

Fig: 3

- Retention cyst
- 70% have punctum
- Content – Bad swelling pultaceous material (+)

AfraTafreeh.com

- Most common – Head
- Exception – Palms & soles
- **Fordyce disease** – Presence of ectopic sebaceous tissue in lips
- Clinical effects
  - Skin not pine table – Classical
  - Putty consistency

Complications

- Cock's peculiar tumor – Ulcerated sebaceous cyst over scalp misnomer
- Sebaceous horn – Dried up sebum
- Most common complication – Infection

Syndromes associated

- FAP + Sebaceous cyst → Gardner's syndrome
- HNPLE + Sebaceous cyst → Muirtorre syndrome

Treatment – Elliptical incision and excision

TUTORIALS LOGIN FOR SUCCESS

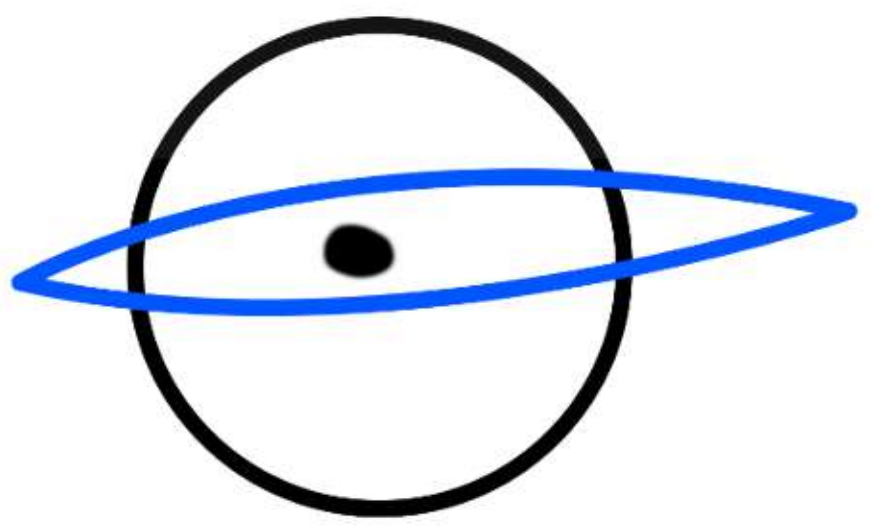

- If infection (+) – cruciate incision and drain the sac

Dermoid cyst

- 4 types

Sequestration dermoid

- Happens due to epithelium entering the line of fusion
- More common
  - Scalp
  - External angular
  - Post auricular
- C/E: Indention of bones (+)
- Treatment: Excision
- Before surgery, CT scan of skull should be done to rule out intracranial extension

Rare types of dermoid

- Implantation dermoid → Tailors/Doctors & Most common finger tips
- Tubulo dermoid → Thyroglossal cyst, post anal dermoid
- Teratomatous dermoid → Skin, Hair, Teeth, muscle and usually seen in ovaries
- Dercum's disease → Multiple painful lipomas
- Cock's peculiar tumor – Ulcerated sebaceous cyst over scalp
- WEN – Multiple sebaceous cyst in scrotum

AfraTafreeh.com

- Dimodex follicularum – Worm present in sebaceous cyst
- Sebaceous horn – Widow Dimanche

SCARS

- 2 types
  - Hypertrophic scar
  - Keloid

Hypertrophic scar

- Proliferation of mature fibroblast
- Proliferation of mature blood vessels
- Arises from a previous incision
- Limited to previous scar
- More common over flexor surface

- No family] Predisposition
- No genetic]
- Treatment: Excision

Keloids

- Proliferation of mature fibroblast
- Proliferation of mature blood vessels
- Claw like extension (+)
- Extends to normal skin also



- Most common extensor surface → Sternum & Face
- Clinical features – Itching
- Genetic – Most common in negros
- Most common in young females
- Treatment: Intralesional steroids → Triamcilone acetate
- Dangerous complication – Marjolin's ulcer

Hemangioma of skin

- Based on involution

NICH	RICH
↓	↓
Non involuting	• Rapidly involuting
Congenital hemangioma	Congenital hemangioma
Appears 4-6 months	• Appears at 4-6 months
Not disappears	• Disappears by 5-7years

- Based on depth of invasion

Capillary	Cavernous
↓	↓
Superficial hemangioma of skin	Deeper

DOC TUTORIALS
AiraTafreeh.com
LOGIN FOR SUCCESS

AfraTafreeh.com

Capillary hemangiomas

Salmon patch
↓
- Appear at birth
- Disappear by 1year
- Most common forehead

Rich
↓
Strawberry
↓
- Appears after birth
- Disappears → 5-7years

NICH port wine stain
↓
- Appears at birth
- Never disappears
- Treatment → Pulsed wave laser therapy

Fig: 2

TUTORIALS
LOGIN FOR SUCCESS

Reconstructive Surgery

Skin grafts

Grafts is a tissue with no own blood supply

- **Partial thickness** → Epidermis (+) part of dermis
- **Full thickness** → Epidermis (+) full dermis

FLAPS

Flap has blood vessel pedicle

- **Axial pattern** → Contains named blood vessel
- **Random pattern** → Leash of unnamed blood vessel
- **Free flap** → Vascular Anastomosis needed

AfraTafreeh.com
TUTORIALS
LOGIN FOR SUCCESS

Skin grafts

- Skin graft is placed over the raw area → Survival
- First 48hrs → Plasma supplying the graft → Imbibition
- 48hrs – 5days → Alignment of blood vessels → Inosculation
- >5days → Revascularized
- Absolute C/I → Presence of beta hemolytic streptococci in wound

AfraTafreeh.com

Partial thickness graft	Full thickness graft
• Thiersch graft • Donor site – Thigh, back • Advantages – No need to cover doner area – Wider areas derived – Repeated grafting from doner site • Disadvantages – Cosmetically ugly – Contractures (+) • Procedures – By using humbly knife/Electrotome – Punctate spots (+) no fat visible	• Wolf graft • Donor – behind Ear • Advantages – No contractures – Cosmetically good • Disadvantages – Wider areas not possible – Donor area needs coverage • Procedure – Manually done

TUTORIALS
LOGIN FOR SUCCESS

Types of partial thickness grafts

- Thiersch – Thin, 0.006 – 0.012 inch
- Blair brown – Intermediate, 0.012 – 0.018 inch
- Paget – Thick, 0.018 – 0.024 inch
- Thin graft
  - High take up
  - Low pregnancy contraction

- Increased secondary contraction
- Thick graft
  - Poor uptake
  - High primary contracture
  - Low secondary contracture

Meshing the grafts

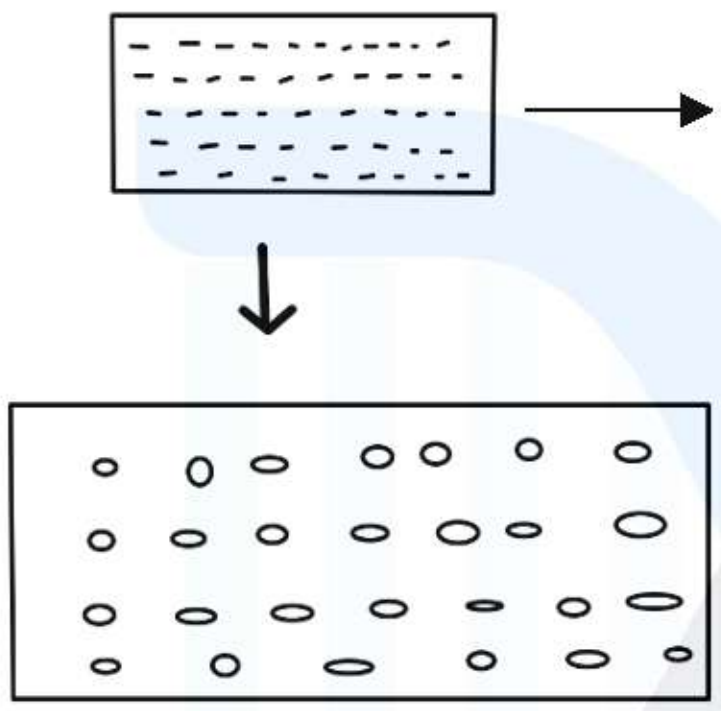

Using 11 size blade small holes are made along the graft

↓

By stretching graft can be made bigger

Any collection beneath graft is drained

↓

Split skin graft

Graft → flap

↓

- Exposed bone
- Exposed tendon
- Exposed joints
- Complex prosthesis
- Complex defects
- Radiation necrosis

AfraTafreeh.com
TUTORIALS
LOGIN FOR SUCCESS

AfraTafreeh.com

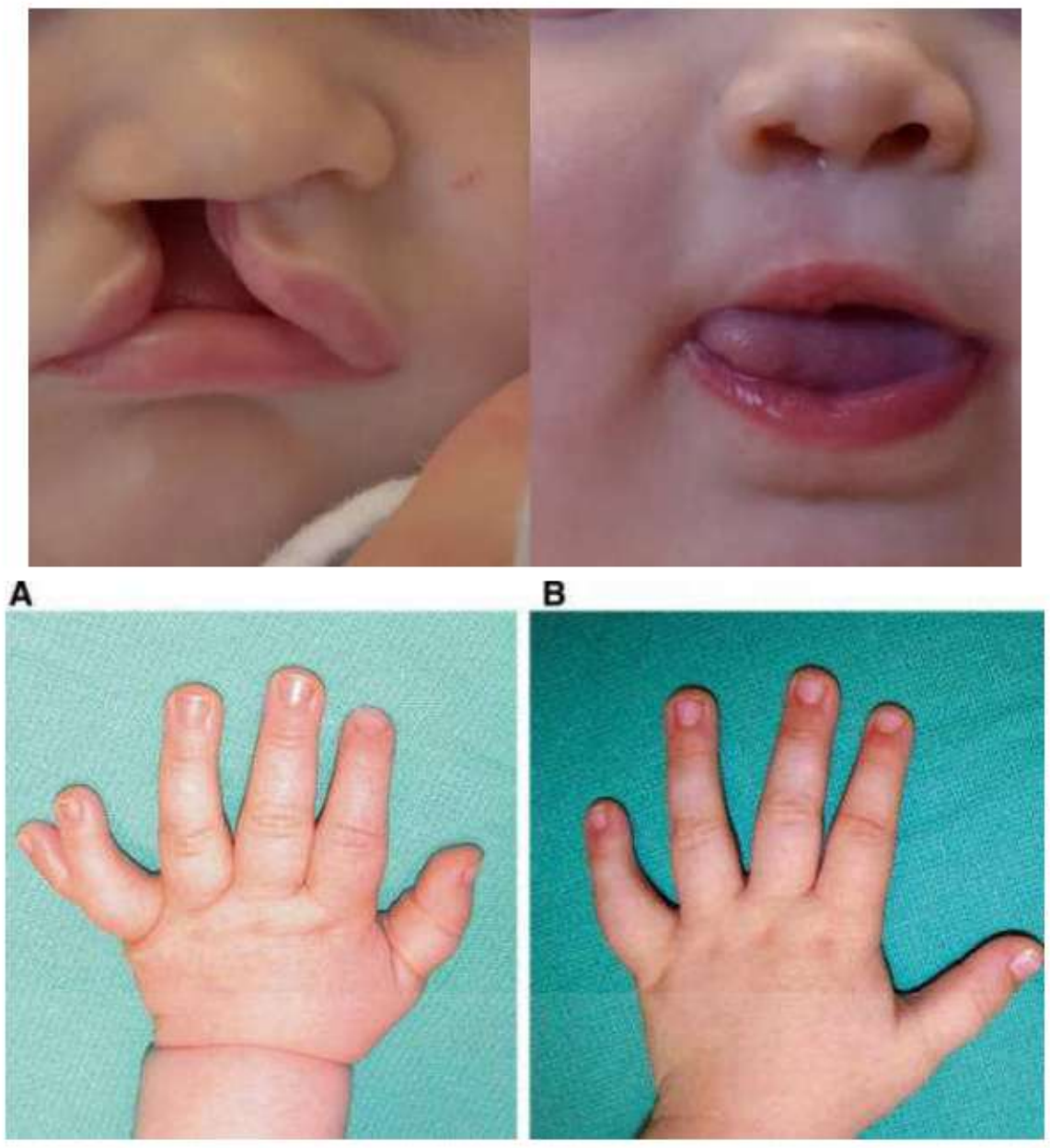

Fig: 3

Axial flap

- pectoralis major myocutaneous flap (PMMC) → oral cavity
- Deltopectoral flap DP
- Tram & DIEP → Breast reconstruction

Flap – Artery

- PMMC – Thoracoacrominal artery
- DP – Inferior mammary artery
- TRAM – Superior epigastric/Inferior epigastric artery
- DIEP – Deep Inferior epigastric artery

1. **Transposition flap**: Rotated about a Pivot point into an adjacent donor site

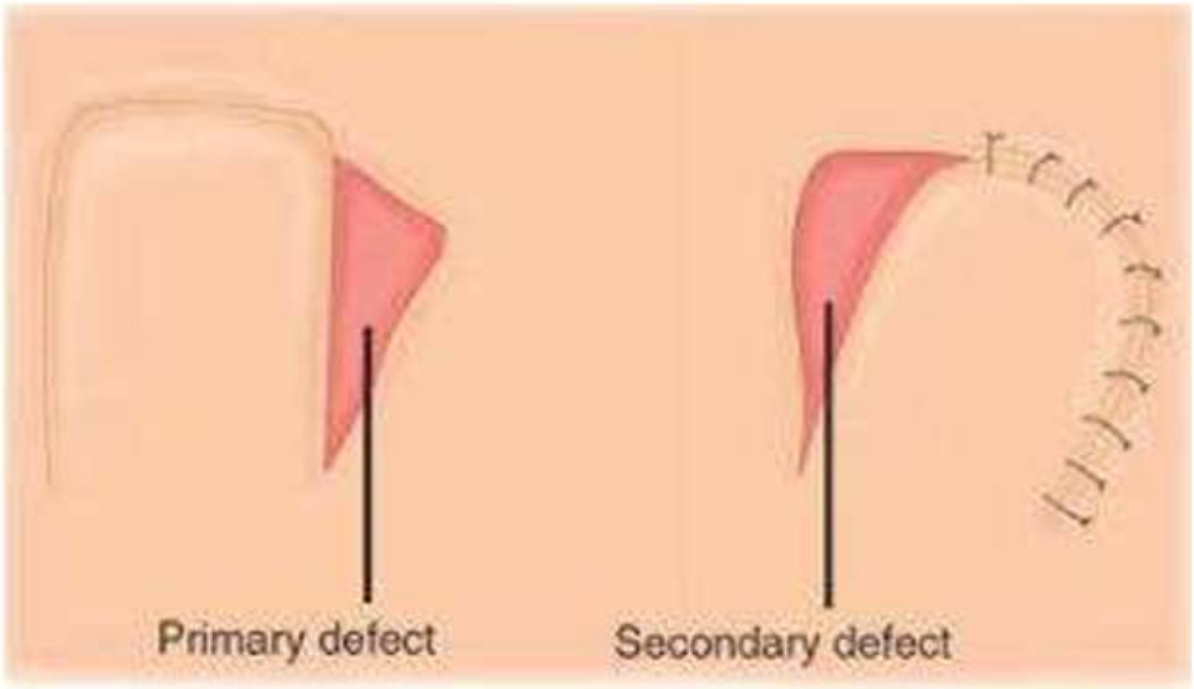

Fig: 4

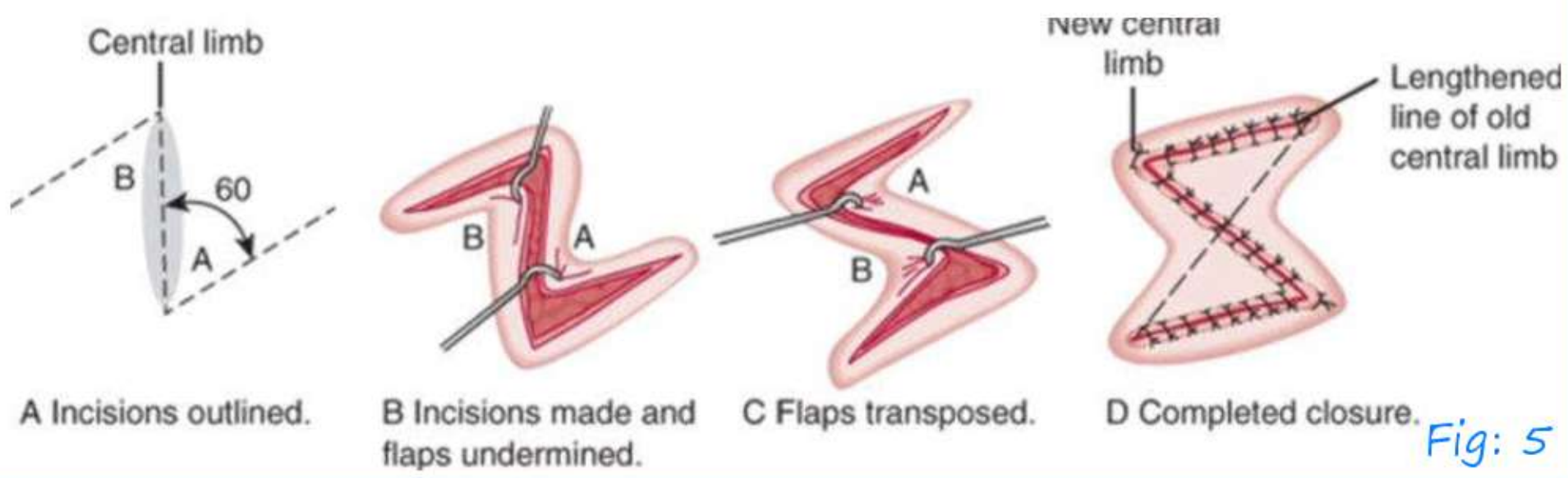

Fig: 5

Fig: 6

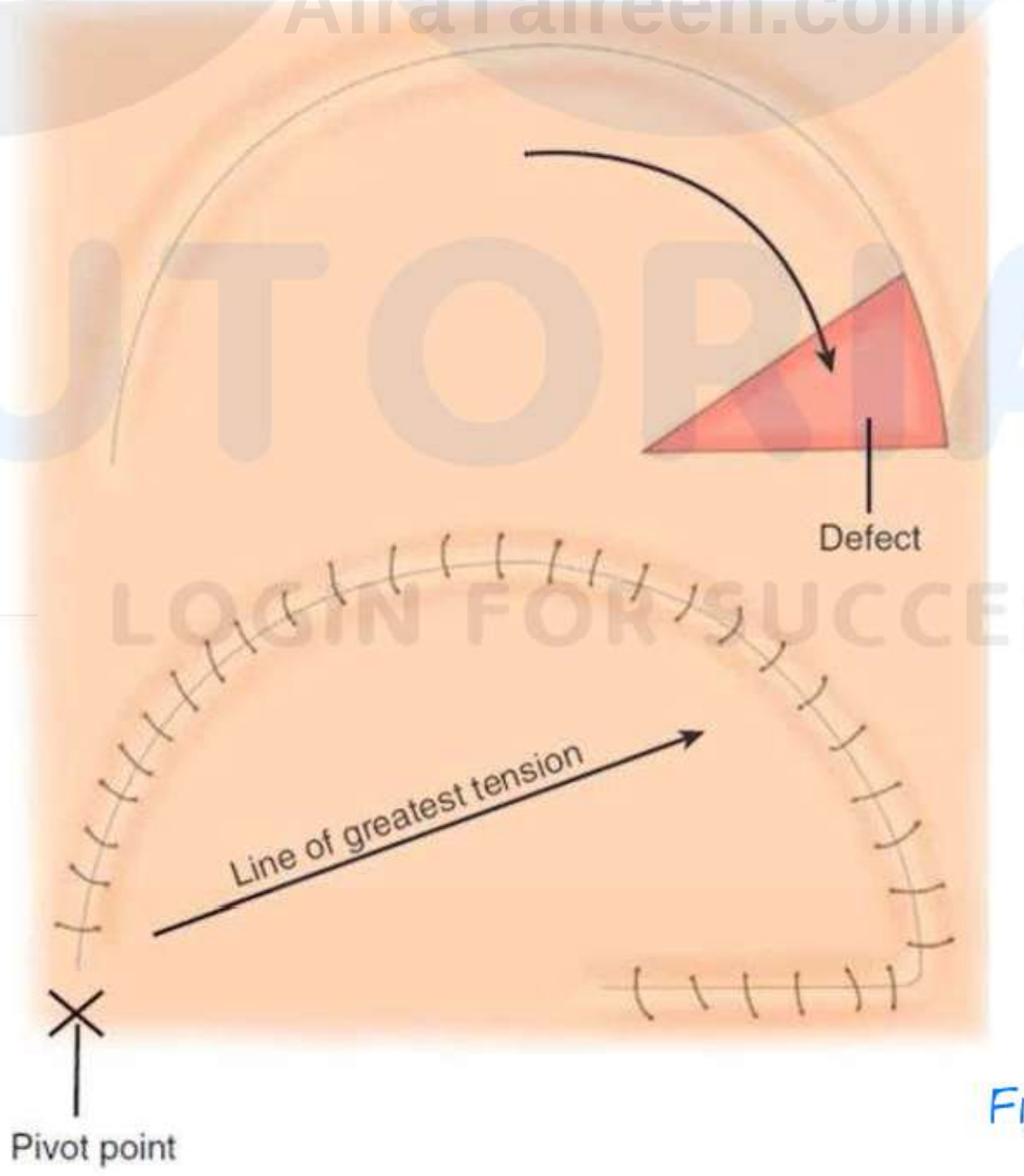

Fig: 7

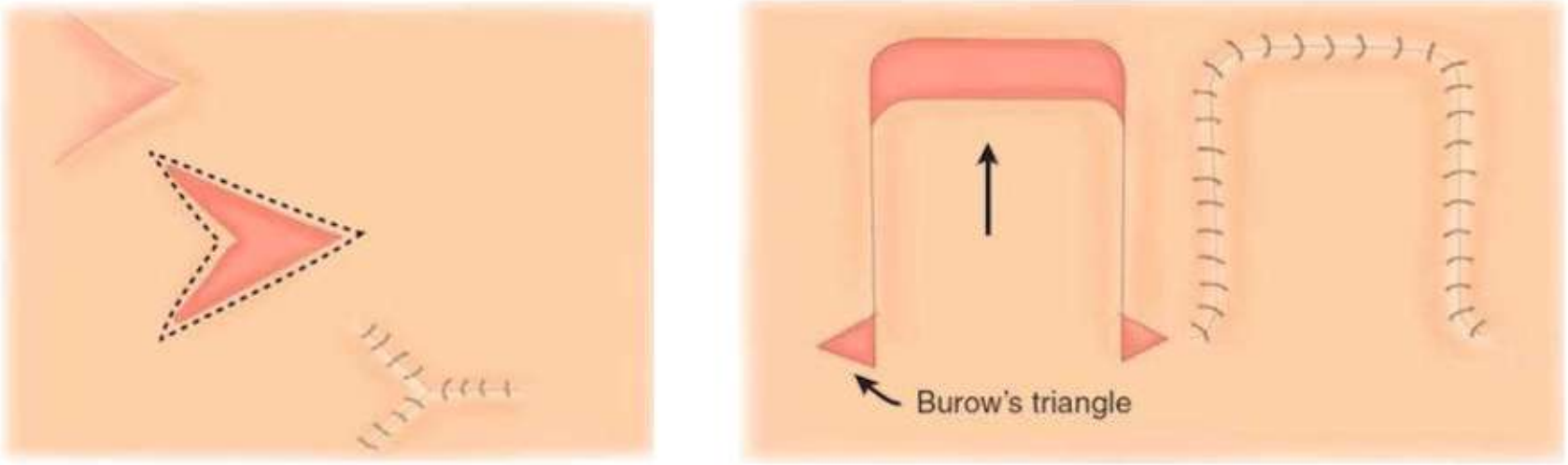

Fig: 8

AfraTafreeh.com

6. Interpolation flaps: Like rotation flaps they rotate about a Pivot point but they insert into defects nearby area but not into adjacent donor site.

E.g. Thenar flap for finger tip reconstruction

Muscle Flaps

- Mathes NAHAi classification

  1.→ Muscle is based on 1 vascular pedicle → Gastrocnemius

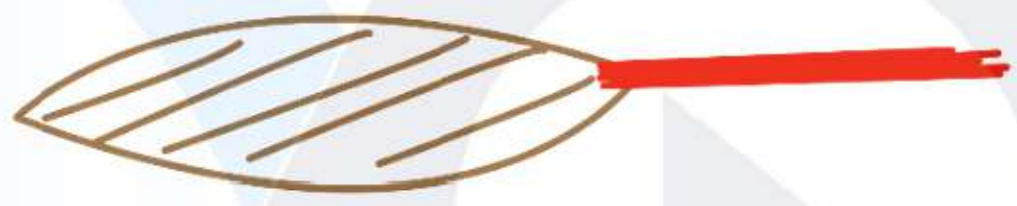

  2.→ One dominant + Minor pedicle → Gracilis

  3.→ 2 dominant pedicle → Rectus abdominis

4.Segmental pedicle → Sartorius m/s

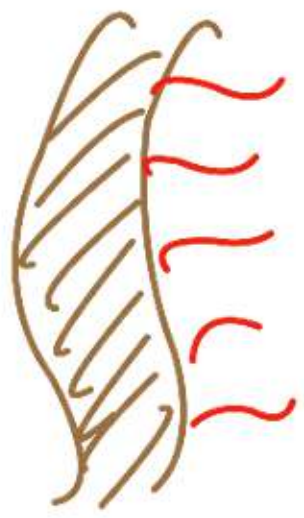

5.Dominant + **segmental** → Pectoralis major

Cosmetic surgery

- Reduction mammoplasty



- Principle
  - ↓ volume
  - ↓ ptosis
  - Anatomical location – Corrected
  - Reposition of nipple/areola → Preserve nerve & blood supply
  - Scar should be minimal

Techniques

- Most common used – Inferior pedicle

AfraTafreeh.com
TUTORIALS
LOGIN FOR SUCCESS

AfraTafreeh.com

Others –

- Superior Pedicle
- Lateral pedicle
- Central pedicle
- Superomedial

Issues

- Any age but size of breast should be same for 12months
- >35 years → Mammography should be done
- Tissue for HPE
- Only one time

Contraindications

- Smoking
- H/O RT recently → Delay surgery

Complications

- Lactation and breast feeding affected
- Nipple sensation altered (↑)
- Wound breakdown
- Hematoma
- Fat necrosis

Implantation of cut digit/limb

1. Wash in clean water



2.Keep the finger in sterile gauze and roll

3.Kept in sterile plastic bag

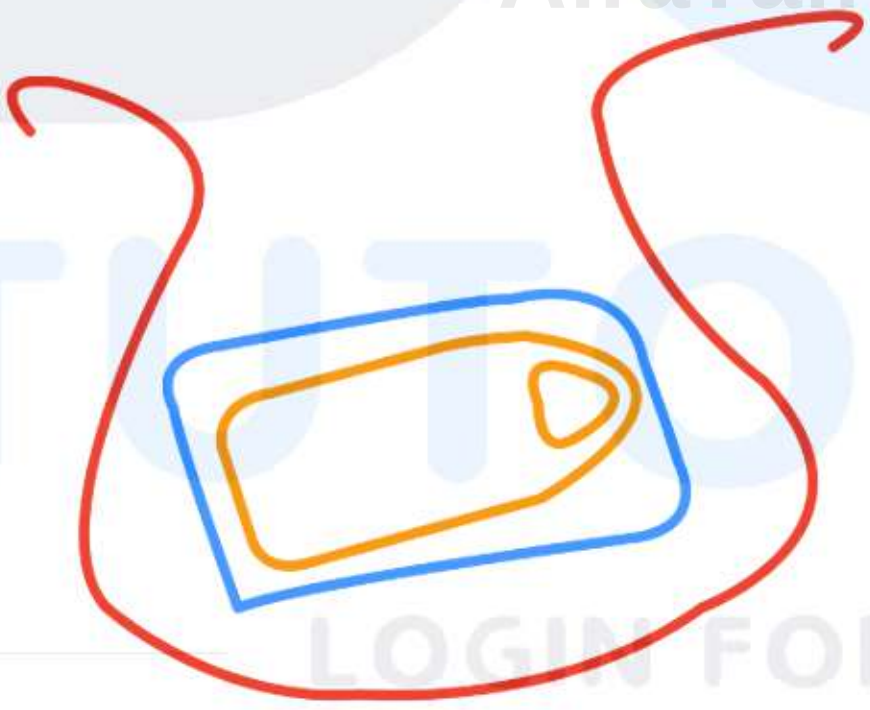

4.Keep it in a box containing full of ice cubes

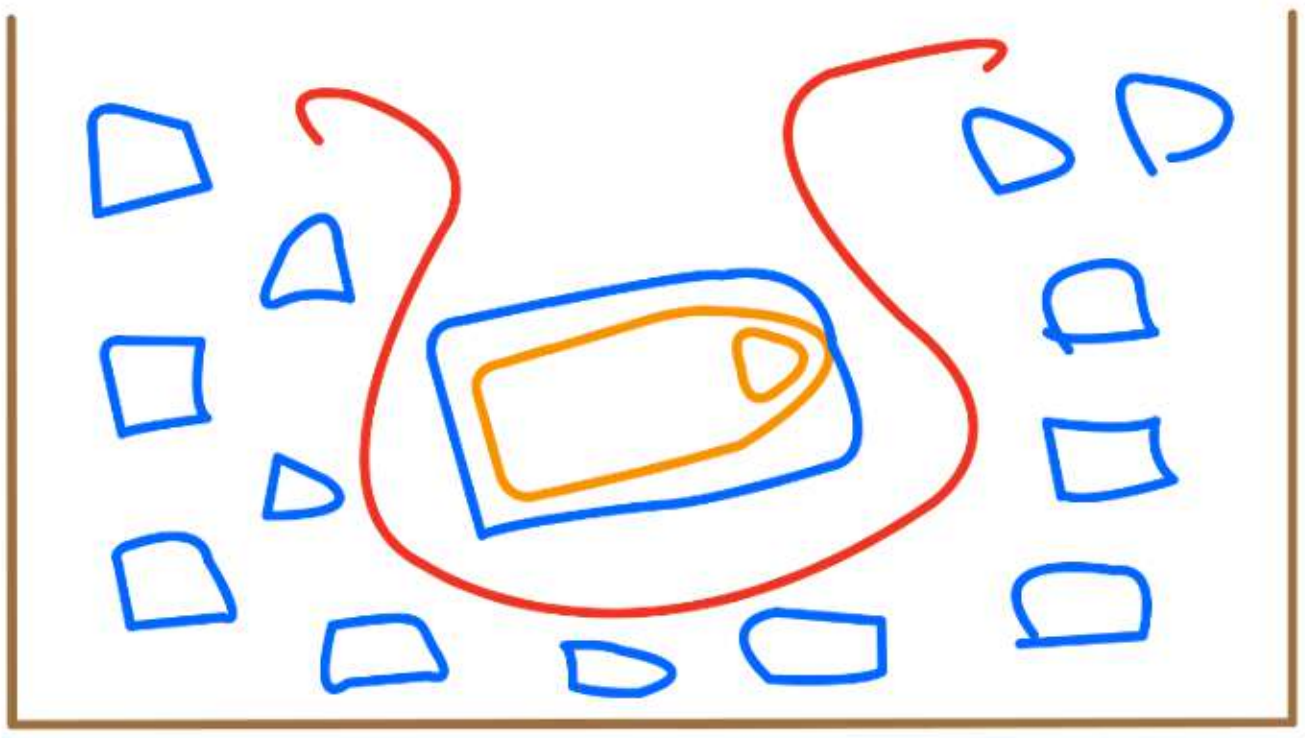

AfraTafreeh.com
TUTORIALS
LOGIN FOR SUCCESS

AfraTafreeh.com

- Patients should reach the plastic surgeon by 6hours

Order of anastomosis

- B: Bone
- E: Extensor tendon
- F: Flexor tendon
- A: Artery → Vein
- N: Nerve
- S: Skin

Fig: 5

Dressing materials

- Alignate dressings
  - Absorptive
  - Non adherent
  - For high drainage wounds with heavy exudates
- Foam dressings

- This can absorb moderate to heavy exudate
- High drainage wounds we use this
- Not to be used in Non-draining wounds

– Hydrocolloid dressings
- Used for bedsores and stasis ulcers
- Facilitates autolytic debridement and remove the dead tissues
- Not to use in high drainage wounds

– Hydrogel dressings
- Rehydrates wound bed with autolytic debridement
- May cause maceration of the wound

– Transparent Film dressings
- Autolytic debridement
- Not to use in high drainage wounds

– VAC dressings
- Negative suction of up to -120 mm Hg given over the foam
- Best method and diabetic foot

TUTORIALS
LOGIN FOR SUCCESS

AfraTafreeh.com

PEDIATRIC SURGERY

Abdominal Wall Defects 00:00:33

- 2 types of defects
  1. One is present in abdomen with a covering membrane. It is congenital defect in the covering membrane of anterior abdominal wall. Peritoneal covering and amniotic membrane covering is present. So, the bowel will be protruding in the covering. It is called as omphalocele aka exomphalos
  2. Other condition where there is no covering membrane and abdominal wall is totally defective and the bowel is protruding in angry looking manner/angry looking bowel called Gastroschisis.
- In omphalocele, the umbilicus is attached to the summit of the membrane.
- In gastroetrisis, umbilicus is seen to the left of the defect. The defect is in the right iliac fossa.
- Omphalocele is a/w CVS anomalies, septal defects seen in 20-40% cases.
- Gastrochisis don't have cardiac defects, but has intestinal atresia.
- Gastrochisis is most common cause of short bowel syndrome in children
- Exomphalos – divided into 2 types

E. minor	E. major
• <5cm defect	• > 5cm defect
• Only small bowel comes out	• Small bowel, liver can come out
• We can wait & watch	• Difficult to close abdominal wall
• Good prognosis	• Bad prognosis
• Strapping alone is enough	• Surgical closure method

- For gastrochisis, immediate surgery is needed.
- In gastrochisis, usually the defect is <4cm (small)

Intestinal atresia 00:06:08

AfraTafreeh.com

• Duodenal atresia – most common according to bailey (follow this for NEET)	• Jejunoileal atresia is most common according to sabiston
• D.A has double bubble appearance	• Has triple bubble appearance.

Duodenal atresia

- It is associated with down's syndrome, annular pancreas, malrotation of gut.

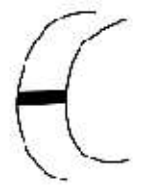

- Types

AfraTafreeh.com

- Type – I – most common
  complete atresia
- Type II – There is a fibrous cord separating 2 ends

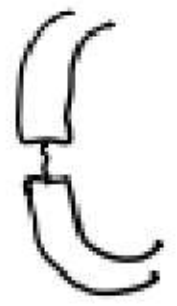

- Type III – There is incomplete (or) partial obstruction



- Wind sack deformity – type of atresia where there is mucosa web, with intact muscle wall

Mucosal web +
intact mucosa

- Treatment of choice – Duodenoduodenostomy
- In duodenal atresia, presentation of babies – 80% come with bilious vomiting.
- 20% comes with non-bilious vomiting (atresia is proximal to ampulla)

Jejunoileal Atresia 00:09:50

- Incidence 1 in 2000
- Intrauterine mesenteric ischemia happened (vascular accident)

- A/W cystic fibrosis
- Types

  - Type – I – There is mucosal web alone
  - Type – II – There is separation, but intact mesentery is seen



  - Type – III – there is 'V' shaped gap in the mesentery

  - III b – The distal bowel has an appearance of apple peel/Christmas tree.



Fig: 1

- Distal bowel receive blood from Iliocolic art, by retrograde way.
- Type IV → Bowel looks like sausage shaped multiple atresias

DOC TUTORIALS LEARN FOR SUCCESS
AfraTafreen.com

AfraTafreeh.com

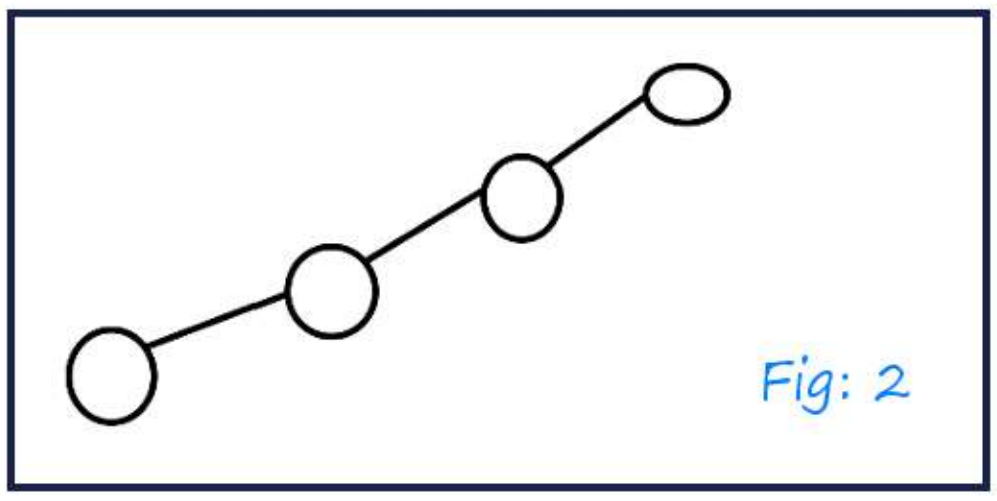

Fig: 2

Congenital Diaphragmatic Hernia 00:13:40

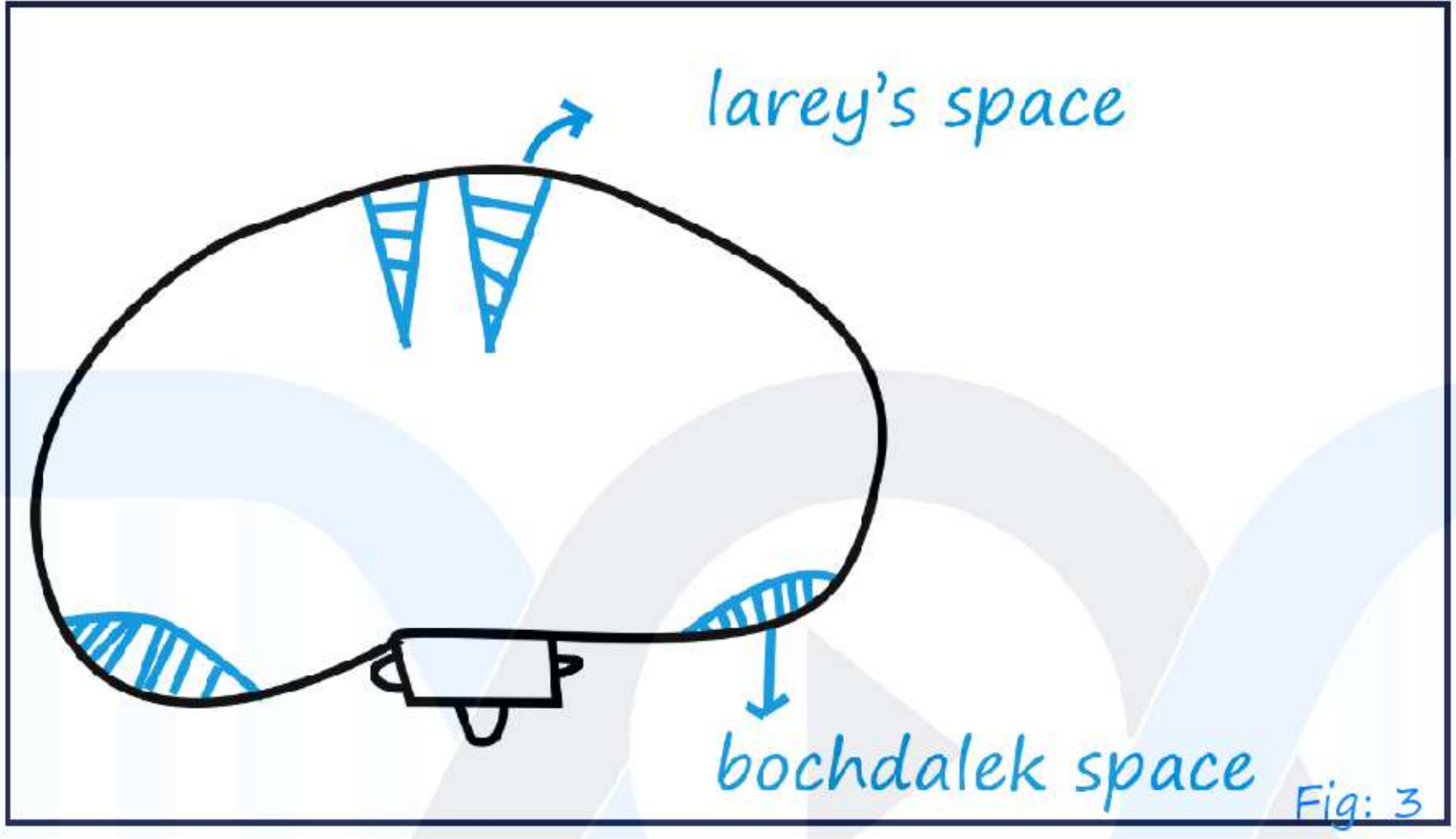

Fig: 3

- Anteromedially the defect is larey's space
- Posteromedially the defect is bochdalek space.
- In newborn babies, through bochdalek space through bowel contents enter into chest called bochdalek hernia.
- B.H is most common on left side posterolaterally
- Most common content – stomach
- If herniation occurs through larey's space – Morgagni hernia
  - Most common seen right side anteromedially
  - Most common content is transverse colon
- In both hernias baby has clinical features – difficulty in breathing & when bag and mask is applied. They

have more difficulty in breathing. So, bag and mask is C/I.

- Immediately intubate these babies and resuscitate with IPPV.
- On CXR – bowel contents are present in chest.
- If Ryles tube is kept, then it is seen in chest.
- After intubation and IPPV, the prognosis of baby depends on pulmonary hypoplasia.
- We intubate the baby and wait for 24-48 hrs, the baby recovers, hypoxia decreases and baby enters honey moon phase.
- At this time we approach transabdominally and repair the hernia (by placing mesh)

AfraTafreeh.com

Cleft Lip & Cleft Palate 00:19:18

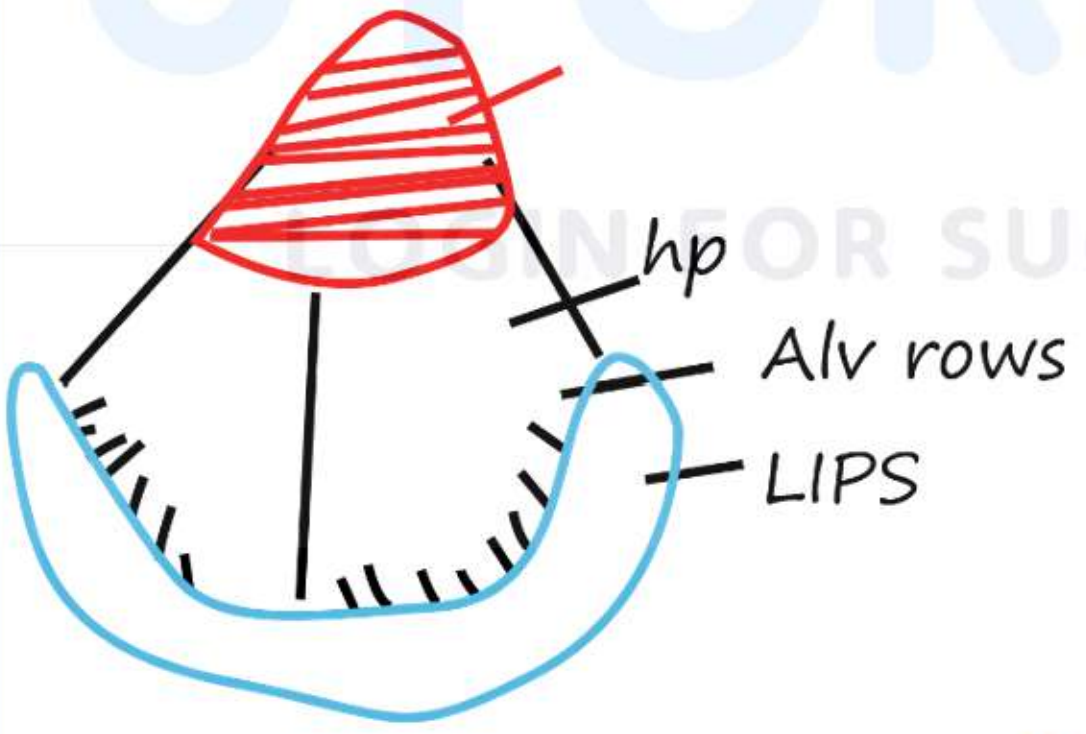

Fig: 4

- If only lip has cleft – Isolated cleft lip – 15%
- If only palate has cleft – isolated cleft palate – 40%

AfraTafreeh.com

- If both then – combined cleft lip and cleft palate – 45%
  - Combined is the most common, seen in 1 in 600 new borns.
  - Combined cases are most common in men.
  - Isolated C-lip is rare 15%
  - Investigation – Antenatal USG – It can detect only cleft lip cases, cannot detect cleft palate isolated cases.
  - ***Causes***

    1. Maternal exposure to drugs like phenytoin, steroids, diazepam.
    2. syndromes associated are

       a. Pierre robin syndrome – characterized by
          - Glossoptosis
          - Retrognathia
          - Resp. difficulties

       b. Downs syndrome

       c. Treacher collin

       d. Sprintzer

       e. Stickler's

TUTORIALS
LOGIN FOR SUCCESS

- ***Clinical Features*** – Babies present with

  1. Cosmetic, ugly looking
  2. Speech problem
  3. Feeding Problems (aspiration)
  4. Middle ear infections

- Cleft palate – failure of fusion of palatine shelves.
- On failure of fushion – if cleft palate is attached to vomer bone/nasal septa – In complete cleft.
- If not attached, then called complete cleft.
- Commonly used classification system in LAHSHAL (Thallwitz). It is from right → left
- If there is a cleft lip, cleft alveolus, cleft hard palate and cleft soft palate and on opposition side also, there is everything complete.

  (first we have to see if it is complete or incomplete)
- If everything is complete, it is given pneumonic as LAHSHAL.

  L – Lips (Right)
  A – Alveoli
  H – Hard palate
  S – Soft palate of right side
  H – Hard palate
  A – Alveoli
  L – Lip (Left)

  Right ↓ Left
- If we write as Lah SH, then it is right side partial cleft lip, cleft alveoli, cleft hard palate and on left side complete soft palate with hard palate and there is no alveoli cleft, lip cleft on left side.
- If Lahshal, (if everything small letters)

  ↓

  Then all are incomplete and B/L

AfraTafreeh.com

AfraTafreeh.com

- LAHSHAL – If all are complete and B/L
- KERNAHAN's System of Classification

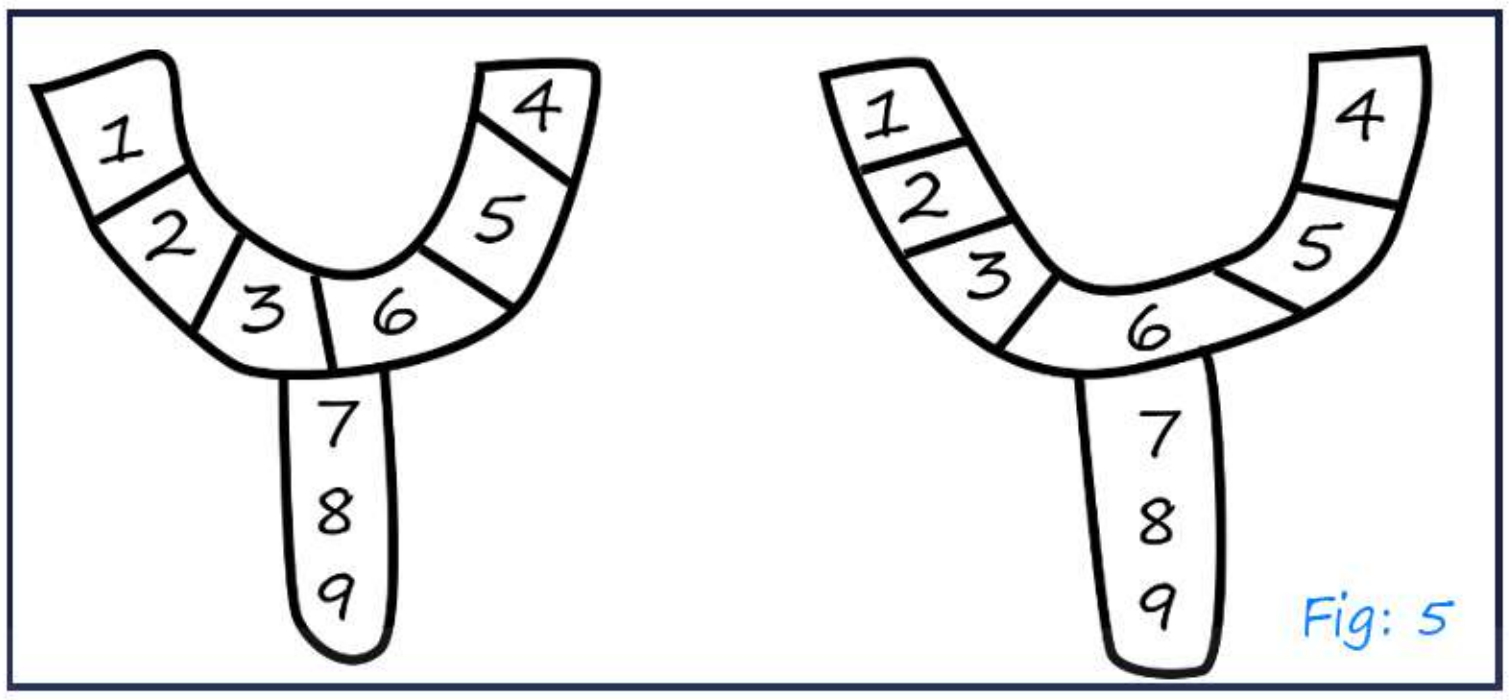

Fig: 5

- 4 stands for lips
- 5 – Alveolus
- 6 – Hard palate
- 7,8,9 – Soft palate

- If 4 means – then it is isolated cleft lip on left side.

Operation

- Timing of operation

  1. If patient has cleft lip and soft palate only
     a. U/L – single surgery at 6 months
     b. B/L — One surgery at 4-5 months
        \ Other surgery at 6 months
     - For soft palate only – 6 months
  2. Combined cases of soft palate and hard palate – 2 surgeries
     - Soft palate – operate at 6 months
     - Hard palate – operate at 15-18 months
  3. If combined all i.e. CL + CSP + CHP
     ↓ ↓
     6 months at 15-18 months

Name of the surgeries

- Cleft lip alone → Millard OP
  → Mulliken
  → Manchester
- Cleft soft palate – Furrow's operation
- Cleft hard palate – Wardil and langenback procedure

Rule of 10 – (old rule)

- They used to operate on 10 weeks' baby, minimum 10 pounds, 10gm% Hb

Complications

- Most common – velopharyngeal incompetency, they have nasal twang in speech.
- Patient unable to speak properly
- Speech problems
- Hearing problems — Acute problems
- Oro antral fistula
- Upper lip has cupid bow deformity
- 2° problems are usually
  - Facial growth affected
  - Dental problem
  - Hearing problem
  - Speech problem

AfraTafreeh.com

Urology operations

- Congenital hydrocele – at 2 years
- Congenital hernia – as early as possible, because it's a narrow canal and can be obstructed.
- Hypospadiasis and UDT – 6 months to 1 year
- Congenital tight phimosis – 1-2 years

Gastro surgeries

- Congenital diaphragmatic hernia → 24-48 hrs
- Extrahepatic biliary atresia (EHBA) → < 6 weeks, Kasai procedure
- CHPS – congenital hypertrophic pyloric stenosis → 4 weeks

  ↓

  RAMSTED's pyloromyotomy
- Midgut volvulus – at earliest, Ladd's procedure
- Umbilical hernia – wait upto 5 years.

Head and Neck

TUTORIALS LOGIN FOR SUCCESS

- Cleft lip – 6 months
- Soft palate – 6 months
- Hard palate – 15-18 months
- Cystic hygroma – operated after birth

Pediatric Oncology 00:44:38

- Most common cancer in childhood – leukemia
- 2nd most common (or) most common solid tumor – brain tumor

↓

Usually astrocytoma grade I

(Pilocytic astrocytoma/GI)

- Most common abdominal tumor
- Most common extra cranial solid tumor

} Neuroblastoma > Wilms tumor

- Most common malignancy in child < 1 year → Neuroblastoma
- Most common soft tissue sarcoma (STS) → Rhabdomyosarcoma
- Most common renal tumor in childhood

↓

Congenital mesoblastic nephroma>wilm's tumor

- Most common tumor to produce mets → Neuroblastoma

(mets → long bones)

Neuroblastoma 00:48:38

- Arises from sympathetic nervous system → most common from

1.Adrenal medulla (38%)

2.Paravertebral region (30%)

3.Chest (20%)

4.Neck & pelvis

DOC TUTORIALS LOGIN FOR SUCCESS AllaTafreen.com

AfraTafreeh.com

- Neuroblastoma in abdomen is seen in various age groups of 1-5 years
- Present with clinical features of abdominal mass/bony mets, skin mets, paralysis.
- 70% have mets on arriving to hospital
- If a baby come with huge mass in abdomen, it can be neuroblastoma (or) wilms.

Points favoring Neuroblastoma

- It is most common
- It has calcifications
- Cross the midline
- Invade the spinal cord
- Produce extensive mets ++++
- VMA ↑↑
  - On IVP, there is drooping lily appearance (as N.B pushes it down)
  - In ectopic ureter & Neuroblastoma, we have **drooping lily** appearance.
- Investigations (or urinary exam)
  - Elevated VMA
  - Elevated Homovanillic acid
  - Elevated dopamine
  - Elevated noradrenaline
- Accurate diagnosis is by CT/MRI
- We have to take biopsy

TUTORIALS LOGIN FOR SUCCESS

- Staging is by international Neuroblastoma staging system
- Treatment
  - For low-risk cases – surgery
  - Intermediate risk – surgery + chemotherapy (CT include carboplatin, cyclophosphamide, etoposide)
  - High risk cases → CT + stem cell therapy
    ↓
    3-year survival <30%

AfraTafreeh.com
TUTORIALS
LOGIN FOR SUCCESS

AfraTafreeh.com

SKIN CANCER

Skin Malignancies 00:00:15

Skin Malignancies
- Basal cell cancer (most common)
- Squamous cell cancer → 2nd most common
- Malignant melanoma → Highest mortality

Basal Cell Cancer 00:01:16

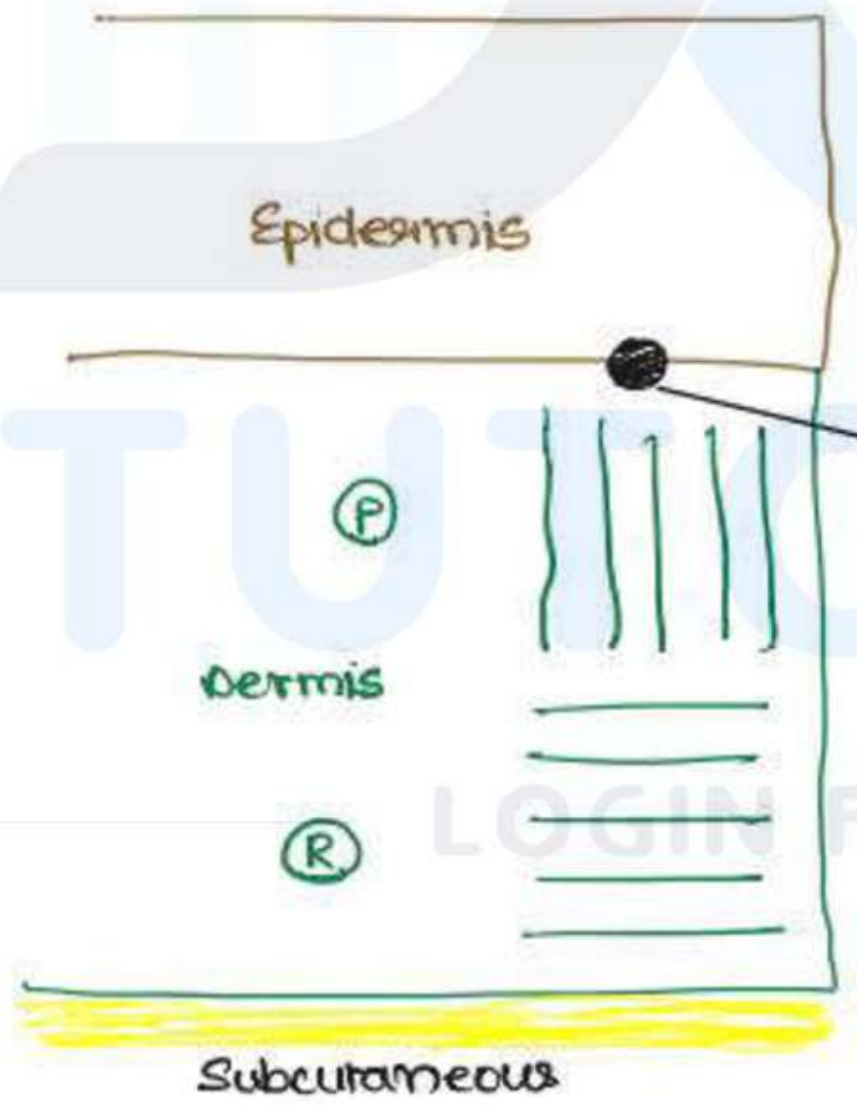

C – corneum
L – lucidum
G – granulosum
S – Spinosum (malphigian layer/ prickle cell layer→ SCC)
B – Basalis → BCC

Malignant melanoma → Dermoepidermal junction

BCC

- Most common – men
- Most common > 40 years
- Most common site – face – inner canthus of eye
  - nose
  - Upper lip (tear cancer)

- Most common – white skinned
- Spread – Only by direct route

rolled out edge – infiltrations into adjacent layer

↓

RODENT ULCER

– Hematogenous spread is very rare (< 0.01)



- Predisposed by: UV light (strongest)
  - Arsenic
  - Coal tar
  - Aromatic hydrocarbons
- **Types of BCC**

90% Nodular (Nodulocystic)
↓
Ulceration +

10% superficial spreading
↓
Field fire

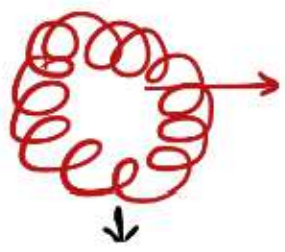

↓
Scaling +
↓
DD – Actinic Keratosis
eczema

DOC TUTORIALS
LOGIN FOR SUCCESS
AfroTafreeh.com

AfraTafreeh.com

Squamous cell cancer 00:10:46

- 2nd most common
- Male > Female
- Arises from spinosum layer (malphigian/prickle)
- Premalignant SCC

  1.Bowen's disease – Insitu SCC of skin, shaft of penis

  2.Erythroplasia of queyrat – Insitu SCC of glans penis

  3.Paget's

  4.Leukoplakia

  5.Erythroplakia

  6.Senile keratosis
- Risk factors

  1.Radiation

  2.Long standing ulcer – Marjolin's

  3.Sunlight

  4.HPV 5,16

  5.Lupus vulgaris

  6.Xeroderma pigementosa

  7.Prolonged exposure of irritation

  - Kang ↓ Buttocks
  - Kangri ↓ Abdominal wall
  - Chimney sweeper ↓ Scrotum

TUTORIALS
LOGIN FOR SUCCESS

- Clinical features

  Excavated edge

  ↓

  - Proliferative
  - Ulcerative + proliferative
  - Verrucous

  ↓

  RT is C/I



- Biopsy – Keratin pearl → onion skin epithelium

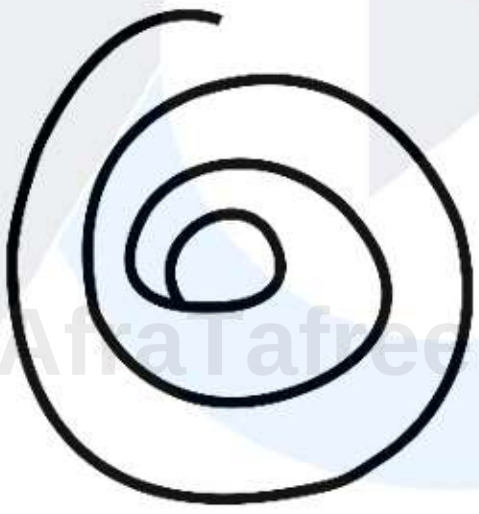

AfraTafreeh.com
DOC TUTORIALS
LOGIN FOR SUCCESS

- Keratin pearl absent in
  - Esophagus SCC
  - Bladder SCC
  - Rapidly growing skin
- Broder's grading
- Tumor markers – CK-1, CK-10

Treatment of BCC & SCC

- Excision – 4- 6 mm margin if lesion > 2cm size

  4 mm margin if lesion < 2 cm size

  Larger tumors – 1 cm margin

AfraTafreeh.com

- Cosmetic areas – MOH's MICROGRAPHIC SURGERY

Serial resection

Until the margin is negative

Others

- 5-FU cream, Electro dissection
- Cryosurgery
- CO_2 lasers
- RT

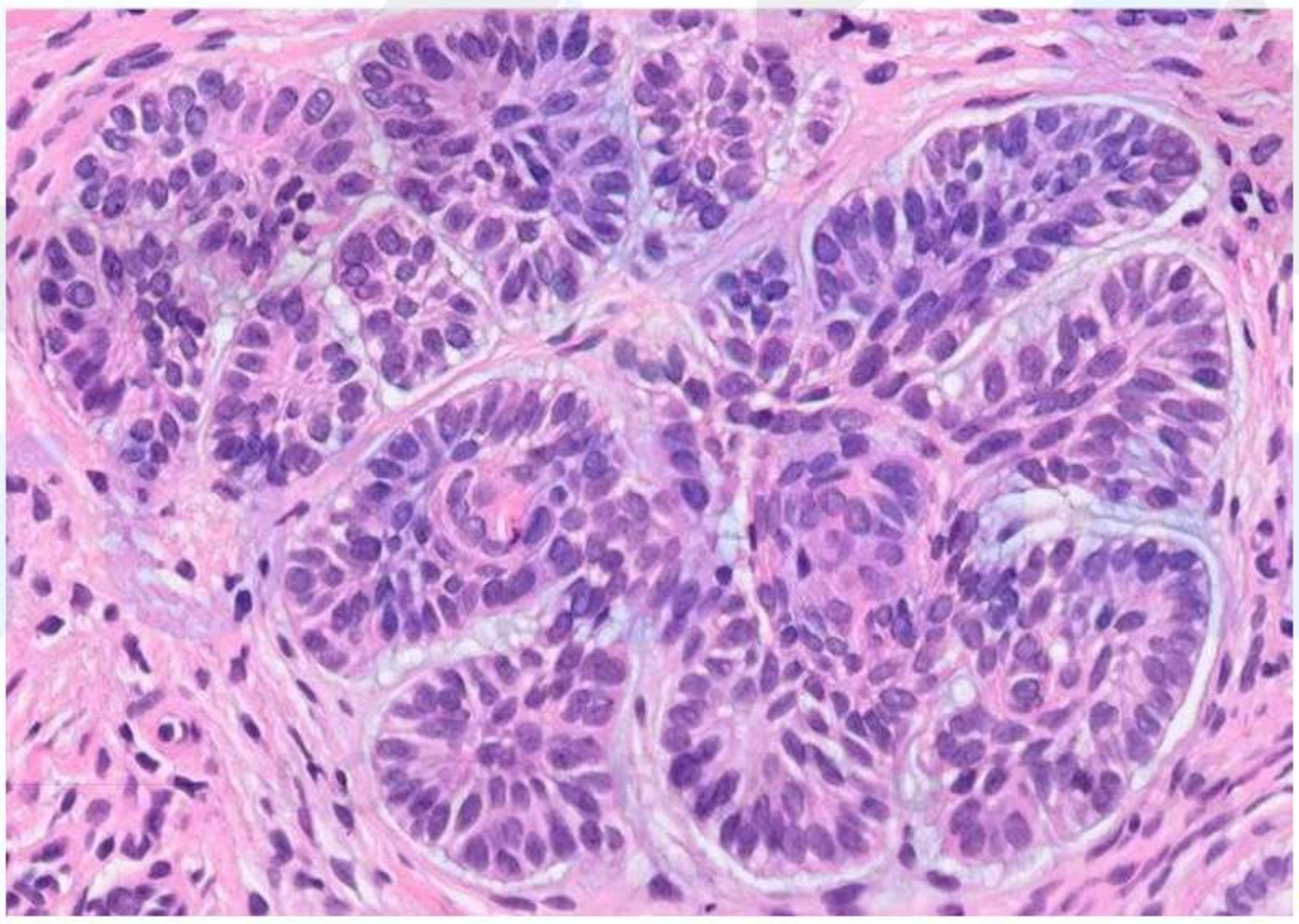

Fig: 1

Malignant melanoma of skin 00:24:20

- 4% of skin cancer
- 79% skin cancer death
- 1.4% of cancer related death
- males – 0.5/1lakh
- Females – 0.2/1lakh

- Most common age group – 20-40 years

  ↓

  Females – Most common cause of cancer death

- R/F

  1.Sunlight

  2.Xeroderma pigmentosa

  3.Family H/O

  4.Dysplastic naevi (10% life time risk)

  5.Immunocompromised

  ↓

  - HIV
  - Cyclosporin A
  - Hodgkin's lymphoma

- Clinical features
  - A – Asymmetry
  - B – Border irregularity
  - C – Color variation
  - D – > 6mm
  - E – Evolution, Elevation, Enlargement
  - F – Funny looking

AfraTafreeh.com
DOC TUTORIALS
LOGIN FOR SUCCESS

Types

- Superficial spreading
- Nodular
- Acral lentiginous
- Lentigo maligna

Superficial Spreading

- Most common type

AfraTafreeh.com

- Most common among white
- Long standing dysplastic naevi → melanoma
- Most common site – Trunk – males

  Lower legs, back-females
- Young age

Nodular

- 2nd most common type
- Most common in head, neck, trunk
- Most common – 50-70 years

  ↓

  Vertical spread

  ↓

  Worst prognosis

Acral lentiginous

- Black people

  ↓

  White areas → palms and soles

  ↓

  Bad prognosis

Lentigo maligna

- Also known as Hutchinson's freckle
- Common in old age
- Most common in face
- Most common in women > men
- Least common

DOC TUTORIALS LOGIN FOR SUCCESS

- Least malignant
- Good prognosis
- Subungual – most common below nail bed

  Hutchinson sign – pigmentation in nail bed

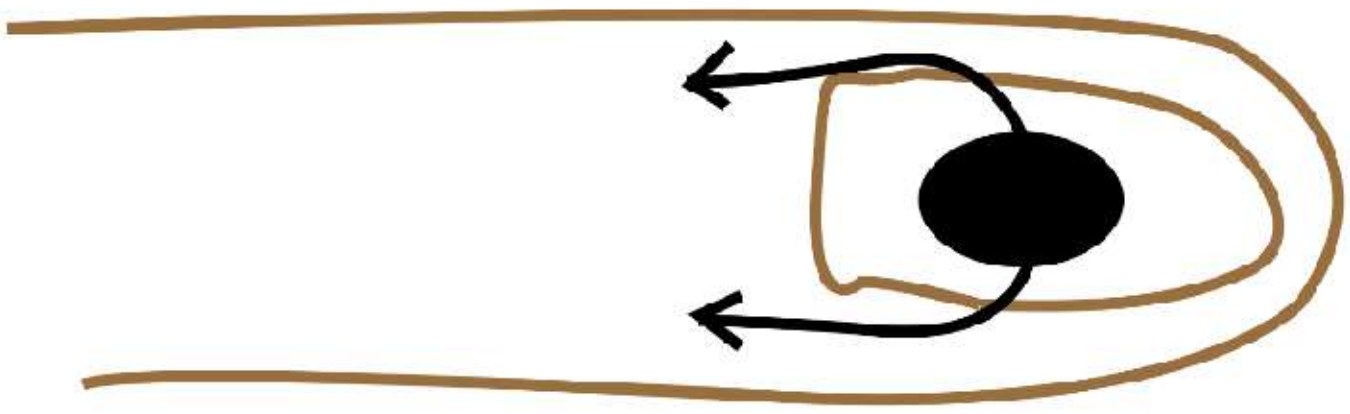

- Amelanotic melanoma – late presentation
- Tumor markers – MELAN – A

  HMB – 45

  S – 100

Spread

Local
↓
most dangerous vertical
↓
Nodular

LN spread
- Nodule within 2 cm of lesion – satellite
- >2cm – In transit nodule

Hematogenous
↓
Brain
Lungs
Liver
Small intestine
Skin
bones
↓
Most common cause of death

Prognostic factor

- Best – Depth
- Bad – Ulceration

  LN+

AfraTafreeh.com
TUTORIALS
LOGIN FOR SUCCESS

AfraTafreeh.com

Satellite +

Distant mets

- Lower limb has best prognosis
- Females – Best prognosis
- Lentigo maligna – best prognosis

Classification

Breslow's thickness	Clark's level
I: <0.75 mm	I: Epidermis
II: 0.75 – 1.5 mm	II: Papillary dermis
III: 1.5 – 4 mm	III: <JN PD/RD
IV: > 4mm	IV: Reticular dermis
	V: Subcutaneous

Management

- Excision of 1°
- Sentinel node biopsy → block dissection
- Reconstruction

LOGIN FOR SUCCESS

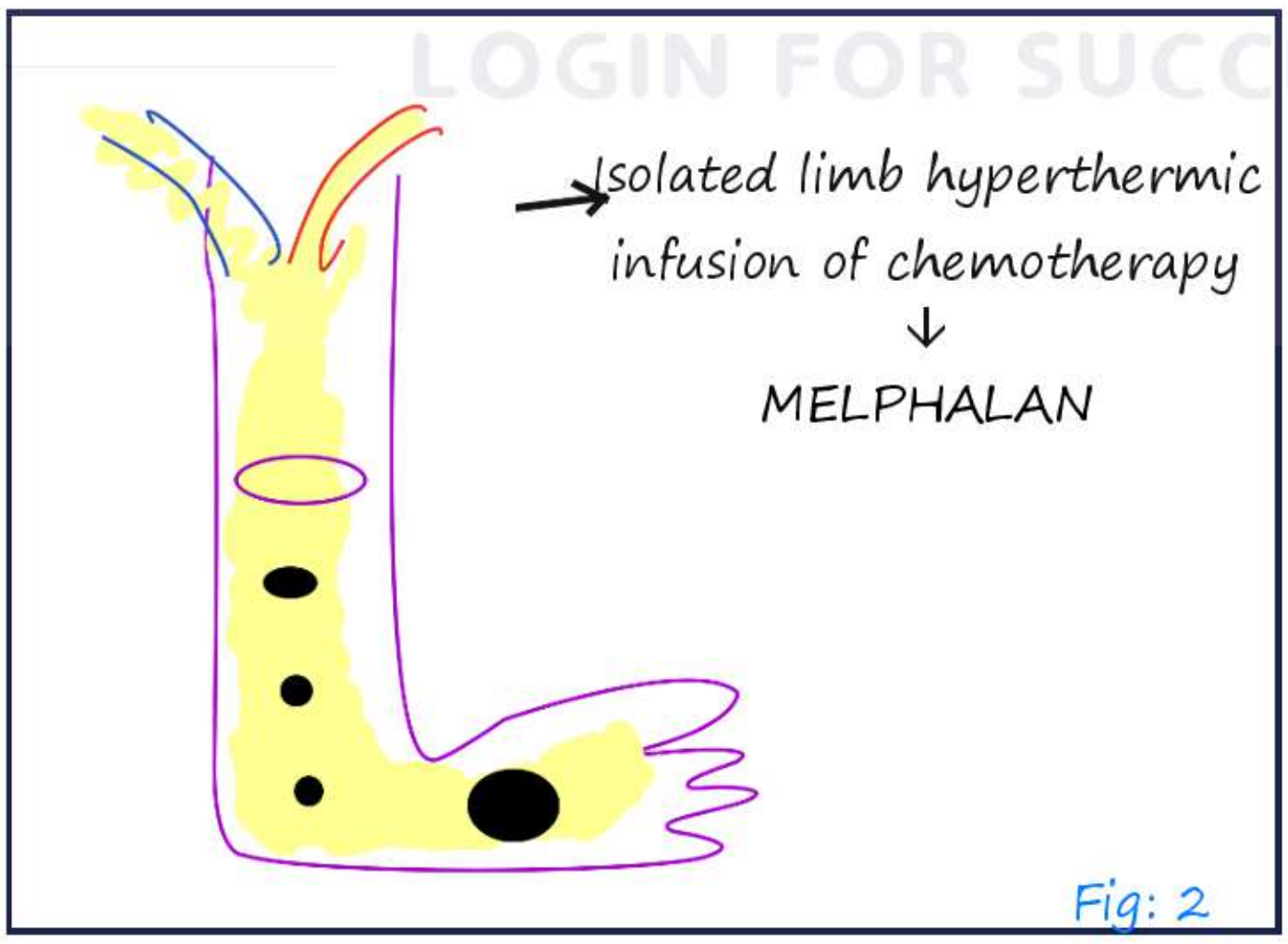

Fig: 2

Excision

- 0-1 mm depth → 1cm margin
- 1-2 mm → 1-2 cm margin
- 2-4 mm ⎤ → 2cm margin
- > 4mm ⎦

AfraTafreeh.com
TUTORIALS
LOGIN FOR SUCCESS

AfraTafreeh.com

CARDIOTHORACIC SURGERY

Cardiac Surgery 00:00:50

Cardio-Pulmonary Bypass Machine

Fig: 1

Functions of heart and lung

i. Oxygenation
ii. Removes particles
iii. Maintains temperature
iv. Maintains circulation (except heart)

- Cardiopulmonary bypass machine

Sternotomy
↓
Expose
↓
Arterial cannulation: done at ascending aorta
↓
Venous cannulation – purse string in right atrium

TUTORIALS
LOGIN FOR SUCCESS

↓

Machine is going to take care

- Myocardium is not taken care by machine

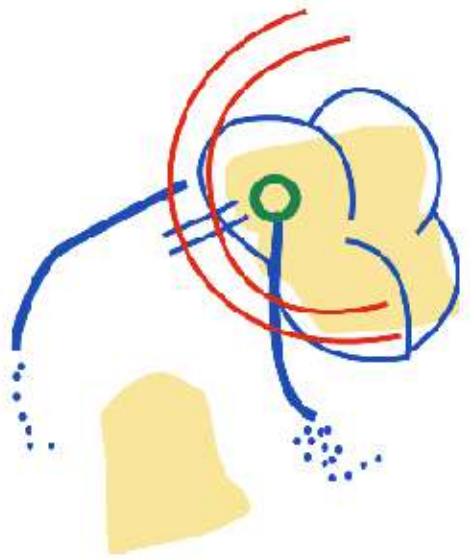

↓

Receives blood supply from LCA and RCA

- To prevent myocardial damage

↓

1. Cardioplegic solution (potassium)

↓

Diastolic arrest

2. Intermittent cross clamping

↓

Ventricular fibrillation

3. Total circulatory arrest in pediatric cases

↓

Myocardium can withstand ischemia for about 15-20 minutes

AfraTafreeh.com
TUTORIALS
LOGIN FOR SUCCESS

Complication of cardiopulmonary bypass

1. Bleeding disorders
2. Infection
3. Air embolism
4. MODS

1. Mesenteric ischemia
2. Myocardial ischemia
3. Neurological dysfunction
4. Pancreatitis
5. Vascular injury

AfraTafreeh.com

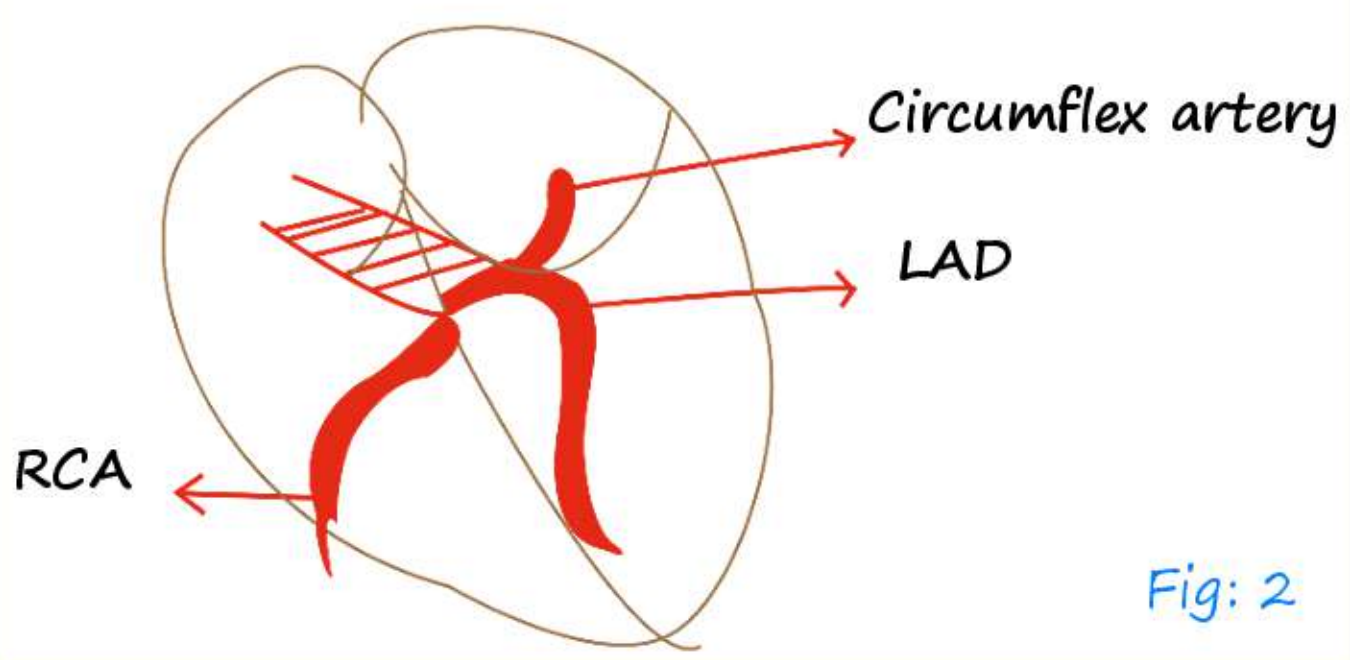

Fig: 2

- From left coronary artery, 2 arteries are coming

Circumflex artery ↓ running on atrio ventricular septum	Left anterior descending artery ↓ running on anterior interventricular with septum

- Right coronary artery continues on posterior side as posterior descending artery (90%)
- In 10% posterior descending artery comes from LCA
- M/c diseased } LAD
  m/c bypassed }
- IOC – Selective coronary angiography
- Indications for CABG
  - > 50% stenosis of LCA
  - > 70% stenosis of LAD
  - Triple vessel disease
  - Poor ventricular function
- Chronic stable angina → Percutaneous transluminal coronary

TUTORIALS LOGIN FOR SUCCESS

↓ angioplasty is done

PTCA > CABG

- Acute coronary syndrome

  Unstable angina – asymptomatic with help of antianginal drugs

  ↓

  Recurrent – PTCA/Thrombolysis

  CABG > 6 weeks

Other indications

- Myocyte necrosis → VSD

  ↓

  3–7 days

  Pulmonary edema + pan systolic murmur + hypotension

  ↓

  Patch closure

- Papillary muscle necrosis → MR

  ↓

  Pulmonary edema + pan systolic murmur +

  ↓

  Mitral valve replacement

- Ventricular aneur → Repair after connecting to bypass machine

AfraTafreeh.com
TUTORIALS
LOGIN FOR SUCCESS

AfraTafreeh.com

Bypass

LSV
Long Saphenous Vein
↓
Most common used
10-year patency 60%
others – SSV cephalic vein

LIMA (left internal mammary artery)
↓
LCA/LAD bypass
↓
10 year – 90%
wound infection – DM
others: - RIMA
Radial artery
↓
Allen test done

- Complications
  - Bleeding
  - Arrythmias (most common – sinus tachycardia)
  - Neurological dysfunction
  - Poor cardiac output
  - Mortality – 2-3%
  - Wound infection

TUTORIALS
LOGIN FOR SUCCESS

- Prognosis
  - 95% - 1 year
  - 90% - 5 year
  - 95% - 10 years

Bypass machine
↓
Off pump CA surgery
↓

Octupus devices

Valve Replacement 00:25:40

Valve replacement

Mechanical
↓
- Any age
- Any size
- Advantage: Long durability
- Disadvantage
  - Thrombogenic
  - Lifelong anticoagulant

Biological
↓
- Allograft – Cadavers
- Autograft – same valves
- Hetero/xeno – porcine
  ↓
  most common
- Advantages – Turbulence is less
- Disadvantages - less life expectancy

AfraTafreeh.com

Complications

- Most common complication – Thrombose formation
  ↓
  Most common in mechanical valve
  Most common in mitral valve
- Valve leaks
- Prosthetic valve endocarditis
  ↓
  Most common Staph. epidermidis
  ↓
  Mortality – 50%

TUTORIALS
LOGIN FOR SUCCESS

AfraTafreeh.com

Tumors 00:30:08

- Most common – mets from lung Cancer (most common)
- most common 1° tumor – Atrial myxoma
- Highest propensity of mets of heart – malignant melanoma

Atrial myxomas 00:31:26

- 3–6th decade
- Most common in females

Sporadic
↓
- Most common in left atrium
- Solitary

Familial
(carney's complex)
↓
- Ventricle
- Multiple

TUTORIALS
LOGIC FOR SUCCESS

- Clinical features
  - Most common – MS/MR
  - Ventricular forms – obstructive features
  - On auscultation – tumor plop sound
    ↓
    Mid diastole
- Emboli like manifestation can happen if it dislodges
- Investigation – 2D Echo
  TEE
- Treatment – Surgical excision

THORACIC SURGERY

Mediastinum

- Divided into
  - anterior mediastinum
  - Middle mediastinum
  - Posterior mediastinum
  - Superior mediastinum
- Most common mediastinal mass as a whole → Thymoma (as per exams by NBE-Bailey) [Correctly most common – neurogenic tumors – as per sabiston for AIIMS & AI exams]
- Anterior mediastinum masses
  - Thymoma (most common)
  - Lymphoma
  - Germ cell tumors
  - Thyroid & parathyroid masses can present
  - Mesenchymal tumors.
- Middle mediastinum
  - Most common – cyst like bronchogenic cyst, pericardial cyst
  - Others – Vascular aneurysms
    Lymph node masses
    Mesenchymal tumors
    Ectopic phaeochromocytoma
- Posterior mediastinum
  - Most common – Neurogenic tumors

AfroTafreeh.com
TUTORIALS
LOGIN FOR SUCCESS

AfraTafreeh.com

Meningocoele

Mesenchymal tumors

Lymphoma

Phaeochromocytoma

Thymoma 00:05:08

- It is most common neoplasm of thymus
- Most common seen in anterior mediastinum
- Seen in 40-60 years
- It is surrounded by a well-defined fibrous capsule
- Types of thymoma are lymphocytic type

  Epithelial type

  Mixed type → Most common type of thymoma
- Classical Clinical feature – asymptomatic (They are not diagnosed) They are detected incidentally on X-ray chest.
- It at all, it can cause symptom, it causes
  - Dysphagia
  - Dyspnea
  - SVC syndrome
  - Paraneoplastic syndrome
- Most common paraneoplastic syndrome in thymoma – myasthenia gravis

PNS of Thymoma

- Rheumatoid arthritis
- SLE
- Polymyositis
- Sarcoidosis

- Myasthenia gravis (most common)
- Neuromuscular dystrophy
- Myotonic dystrophy

- Cytopenia
- Red cell aplasia
- Hypogammaglobulinemia
- Erythrocytosis (sometimes)

Investigation for thymoma

- IOC – CT scan
- Major differential diagnosis – Lymphoma
- Confirmed diagnosis by → Tissue diagnosis
- Cytokeratin is best marker for thymoma
- On CT scan – Thymoma and lymphoma can be differentiated. If it is lymphoma – they always have associated lymphadenopathy
  Thymoma – Solitary lesion with a well-defined capsule.

Staging 00:10:33

- It is done by Masoaka staging system.
- I – Macroscopically, well encapsulated lesion, No microscopic invasion.

AfraTafreeh.com

- II – Well defined capsule, but infiltrated into surrounding fat and pleura
  Microscopic invasion present
- III – Macroscopic invasion into lungs, pericardium, great vessels
- IVa – Pleural mets, Pericardial mets
- IVb – Lympho/Hematogenous mets

Management

- If it is symptomatic – then do sternotomy and thymectomy done
- For large thymomas > 5cm size – thymectomy + chemotherapy done
- For patients with thymoma + myasthenia gravis → Thymectomy + anticholinesterase drugs
- Now a days VATS – Thymectomy is done by video assisted thoracoscopic surgery

TUTORIALS
LOGIN FOR SUCCESS

Bronchogenic cyst 00:14:22

- It is a congenital lung lesion arising from anomalous development of foregut (or) tracheobronchial tree.

It can happen

Mediastinum	Pulmonary parenchyma
↓	↓
Most common – 85%	
↓	

No communication seen with tracheobronchial tree	T.B communication is present ↓ Most common in Right lung lower lobes

Complications

- It can rupture and create pneumothorax
- Can cause atelectasis
- Can cause infection
- Can go for malignant transformation
- When there is communication with tracheobronchial tree.
  They can have hemoptysis

AfraTafreeh.com

Treatment

- Excision by Vats method

TUTORIALS LOGIN FOR SUCCESS

Lung Sequestration 00:17:01

- Small tissue of lung containing, bronchioles, alveoli and it is receiving blood supply from aorta.
- 2 Types
  - Intralobar →within the lung parenchyma
  - Extralobar →outside the lung parenchyma

AfraTafreeh.com

Intra lobar	Extra lobar
- 75% most common - Most common seen in left lung - Communicate with tracheobronchial tree - So, can get infection, abscess, hemoptysis - 100% drain into pulmonary vein	- 25% - aka Rokintansky lobe - No communication with tracheobronchial tree - It is a/w congenital diaphragmatic hernia - 80% drains into azygos vein - 20% drain into pulmonary vein

Chylothorax 00:21:54

- Fluid is milky white in color
  Triglyceride level > 110mg/dL (>1.2 mmol/L)
- Chylothorax is usually a complication of malignancy (or) Surgery like esophagectomy (or) injury to thoracic duct
- Initially we manage by fat free diet (or) medium chain triglycerides (or) Protein diet (or) fat free TPN. By this most of them will heal with this conservative management.

Indication of Surgery

1. When there is no improvement after 5 days of conservative management.
2. Chyle loss> 1500ml
3. Non healing for > 2 weeks

- Then we intervene at the level of POIRIER triangle, we go inside and ligate
- Poirier triangle is bounded by
  - Arch of aorta
  - Subclavian artery
  - Vertebra
- In this triangle – thoracic duct, going and draining into junction of left subclavian and IJV

AfraTafreeh.com

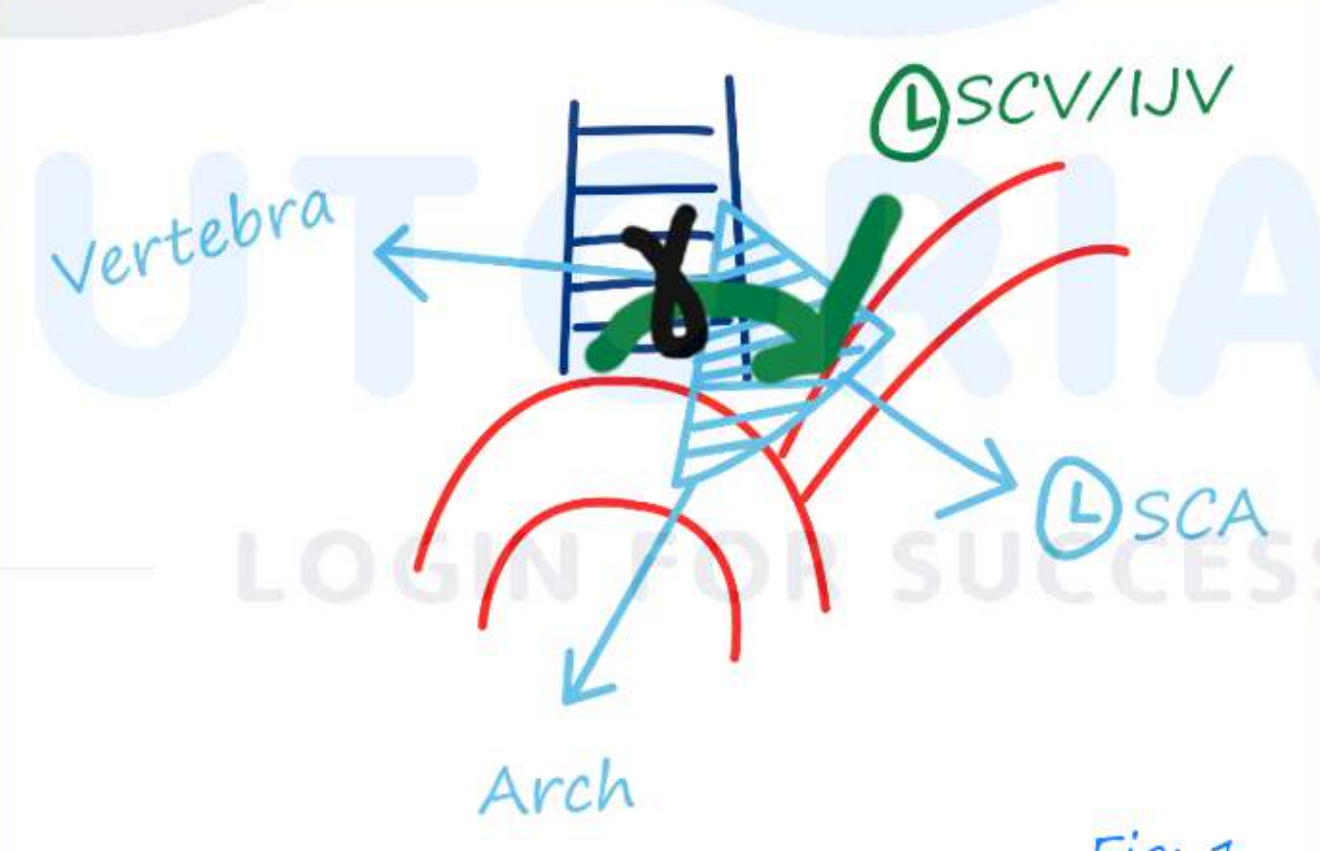

Fig: 1

Lung Tumors 00:25:50

Benign

- Most common benign is pulmonary hamartoma
- It is most common in males

AfraTafreeh.com

- On X-ray it looks like popcorn calcification (Fibroadenoma also looks like popcorn calcification)
- They are most common located peripherally

Malignant

1. Bronchogenic Cancers
2. Malignant mesothelioma – arising from pleura.
   - Usually, mets are most common in lungs than bronchogenic cancers

Bronchogenic Cancer 00:27:24

- M/c primary malignant tumor
- Most commonly from lung hilum
- M/c visceral cancer
- M/c cause of death due to cancer

TUTORIALS
LOGIN FOR SUCCESS

Risk Factors

- Smoking
- Air pollution
- Asbestos, nickel
- Previous scars in lungs lead to adenocancer
- Radiation
- Mutations like K-Ras, Bcl-2, C-myc
- K-Ras – most common mutation causing adenocancer

Pathological types 00:30:30

- Divided into small cell/oat cell cancer & non-small cell cancer

Small cell/Oat cell cancer

- High risk of mets
- Poor prognosis
- Response to chemotherapy is excellent
- Increased paraneoplastic syndrome
- Usually centrally located cancer
- High chance of mets; mets to brain, bone, liver, adrenal.

AfraTafreeh.com
TUTORIALS
LOGIN FOR SUCCESS

Non-small cell cancers

- Adenocancer
- Squamous cell cancer
- Large cell
- Bronchio alveolar cancer → It spreads by air, so we can see satellite nodules & in lung
- No response to chemo
- Risk of mets is less
- Comparatively good prognosis
- Most common type is adenocancer
- Most common type among smokers → Squamous cell cancer
- Undifferentiated type – large cell cancer

AfraTafreeh.com

- Peripheral located cancer

Clinical features of lung cancer

- Most common symptoms – cough (most common); dyspnea, chest pain, hemoptysis are other symptoms
- Presents with malignant pleural effusion
- Tumors is most common on right lobe, usually in upper lobe.
- Hematogenous source is bronchial artery
- Clubbing present and it resolves after tumor excision
- Hoarseness of voice due to R.L.N involvement
- Dysphagia due to esophagus involvement
- Superior venacava obstruction caused by small cell cancer
- Eaton Lambert syndrome can be seen in small cell cancer patients

TUTORIALS
LOGIN FOR SUCCESS

Pancoast tumor

- It is a tumor located in the apex of the lung.
- It destroys first and 2nd ribs
- Causes atrophy of hand muscles
- Causes Horner's syndrome – Ptosis, miosis, anhydrosis
- Pancoast tumor is usually a squamous cell cancer

Squamous cell cancer

- It is the most common cancer in India
- Most common among smoking males
- Pancoast tumor is a squamous cell carcinoma
- It is usually centrally located (small cell Ca also centrally located)
- It can form a cavity inside – Cavitational tumor
- Best prognosis among lung cancers
- It produces ectopic parathyroid hormone → causes hypercalcemia, hypophosphatemia
- T/t – Surgical excision
- It also produces clubbing

AfraTafreeh.com
TUTORIALS
LOGIN FOR SUCCESS

Adenocarcinoma

- Most common type – World wide
- Most common in females
- Most common peripherally located
- Peculiar lung to lung mets are produced
- P.N.S associated are
  - DIC
  - Hypertrophic pulmonary osteoarthropathy
  - Migratory thrombophlebitis called "Trousseau's syndrome"
- It has good prognosis (not better than squamous cell cancer)
- NOGUCHI classification – old classification system of adenocarcinoma

AfraTafreeh.com

Small cell/Oat cell cancer

- Most aggressive cancer
- Worst prognosis
- Only tumor responds to chemotherapy & Radiotherapy
- Produces extra thoracic mets very commonly.
- Most common produces para neoplastic syndrome.

  Due to – Ectopic ADH – SADH – Hyponatremia

  - Ectopic ACTH – Hypocalcemia and cushing syndrome
  - Myasthenia like lambert eaton syndrome
  - Cerebellar degeneration.

Large Cell cancer

- Galactorrhea due to excessive prolactin – in females
- Gynecomastia in males

T – staging of bronchogenic cancer 00:46:19

- T_1 – Tumor size ≤ 3 cm and involving lobar bronchus, not involves main bronchus.

  T_{1a} – < 1cm

  T_{1b} – 1-2 cm

  T_{1c} – 2-3 cm

- T_2 – Tumor size 3-5 cm

  - Main bronchus is involved, but not CARINA

    ↓

    Lung atelectasis, obstructive pneumonitis

It involves only pleura, (Visceral pleura – not parietal pleura)

- T_3 – 5cm – 7cm size
  - It involves – Parietal pleura
    Chest wall
    Phrenic nerve
    Parietal pericardium
- T_4 – > 7cm, with involvement of satellite tumor nodules in I/L lobe
  - Infiltration into esophagus, trachea, heart, vertebra, RLN and Carina
  - All these above involvements are signs of inoperability

AfraTafreeh.com

Non-Invasive Investigations for lung cancer

1. CXR – It shows collapse, atelectasis. Many lungs cancer can be detected from CXR
2. CT thorax – 1st investigation to be done if suspect lung cancer
   Assess/Look for lung resectability
   Any node > 2 cm – metastatic
3. Usually PET-CT is advised
4. Sputum for cytology can be done

Invasive Procedures

1. Bronchoscopy – Transbronchial needle biopsy, usually advised for centrally located tumors

AfraTafreeh.com

2.Endobronchial USG & Biopsy

3.CT guided biopsy – There is chance of pneumothorax here, usually advised for peripheral tumor

Surgical methods of Biopsy

- Mediastinoscopy → under GA, above the sternal notch transverse incision is made, through this we pass a scope inside and take biopsy from carinal (or) paratracheal nodes
- Pneumothorax and bleeding can happen in this procedure.
- Mediastinotomy – Making a space by incision in the 2nd I.C.S by this method we can take mediastinal nodes especially left para-aortic nodes
- VATS – latest, currently done

TUTORIALS
LOGIN FOR SUCCESS

Management of lung cancer

- Surgical is best
- For only small cell cancer – chemotherapy – 90% regression seen
- N_2 nodes cases – neoadjuvant chemotherapy is advised
- For only adeno cancers – oral tyrosine kinase inhibitors (TKI)   e.g. Geftinib
- Single agent chemotherapy for old patients

Surgery

1. If we remove a segment by ligating its pulmonary artery, pulmonary vein and bronchus & remove it → called segmentectomy
2. Wedge resection – apply clamp and remove a part of lung.
3. Lobectomy → possible for early cases of cancer
   Bronchus – Staples (or) sewer
   We have to keep ICD after surgery
4. Pneumonectomy – Remove whole lung
   Mortality rate – 5%
   - After removal, the area is blank and only fluid is collected gradually
   - ICD is placed temporarily
   - It is C/I for tumors involving aorta, heart, esophagus

AHaTaheeh.com
TUTORIALS
LOGIN FOR SUCCESS

Prognosis

- 5-year survival rate for squamous cells – 35-50%
- 5-year survival rate for adeno cancer – 25 – 45%
- 5-year survival rate for small cell cancer – 5%

Chest wall anomalies

1. Pectus excavatum – Sternum is looking disc shaped

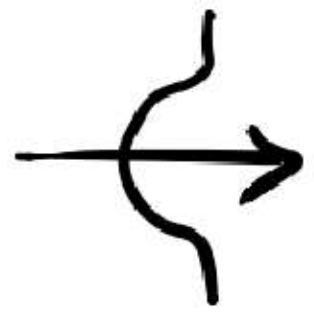

Disc shaped

AfraTafreeh.com

2.Pectus carinatum → Sterum is protruding out pigeon chest

- Both have cosmetic problems they don't cause respiratory problems.
- For pectus excavatum, we do an open operation called RAVITCH procedure – Resect the sternum ribs and reconstruct it (or) a minimally invasive procedure called NUSS procedure → here we keep a long metal bar behind sternum

MCQ points

- Most common histological type overall – Adenocarcinoma
- Most common type in nonsmoker – Adenocarcinoma
- Most common type in females – Adenocarcinoma
- Most common type in smokers – Squamous cell carcinoma
- Most common type in India – Squamous cell carcinoma
- Most common associated with SVC syndrome – small cell carcinoma
- Most peripherally located is – adenocancer
- Noguchi classification is for adenocarcinoma
- Pancoast tumor – squamous cell type

TUTORIALS LOGIN FOR SUCCESS

- Paraneoplastic syndromes are most common with small cell cancer
- Worst prognosis – small cell cancer
- Most common site of metastasis – Liver
- Most common endocrine organ involved is adrenal
- Lung carcinoma – most common tumor metastasis to heart
- Brain mets may present with neurological deficit
- CA lung – most common primary for metastasis to kidney, pancreas, esophagus, liver, spleen, adrenal, brain, skin

Thoracoscore

- It is a score based on a variable to predict the morbidity after surgery and to assess risk of operative mortality in thoracic patients
- It is currently the most robust model available to estimate the risk of death when considering patients for thoracic surgery.
- Nine variables – Mnemonic – ASAP – Plan Doctor's CME

  A – Age

  S – Sex

  A – ASA score

  P – Performance Status

  D – Dyspnea score

  C – Co-morbidity score

  M – Malignant Diagnosis

  E – Extent of duration of surgery

AfraTafreeh.com

MEN SYNDROMES

MEN-1 @ Wermer syndrome 00:00:37

- Truncated menin protein mutation
- AD
- M=F (equally affected)
- Starts from age of 5 years

3P

- **Most common – Parathyroid hyperplasia**
  ↓
  - 90%
  - Multiglandular hyperplasia
- **Pituitary adenoma (Prolactinoma)**
  ↓
  30-40%
- **Pancreatic NET (Gastrinoma)**
  ↓
  - 15%
  - Most common causes of death

- Carcinoids: - Thymus, bronchus → 2nd cause of mortality

Hyperparathyroidism in MEN-I:

- Due to multiglandular hyperplasia
- Most common in 2nd decade
  - First biochemical abnormality – Hypercalcemia
  - Asymmetrical involvement of all 4 glands



- Treatment: - Total parathyroidectomy of all 4 glands

↓

One gland placed in brachioradialis

(or)

3 ½ gland removed (½ of gland in inferior parathyroid)

↓

Titanium clip in situ

- NET: - Gastrinomas → most common – Duodenal mucosa

MEN-2 syndrome 00:06:57

- 'C' cell hyperplasia present
- 100% MCT (Medullary cancer thyroid)
- RET oncogene mutation

Loss	Gain	Somatic
↓	↓	↓
Hirschsprung disease	MEN-2	Thyroid cancers

AfraTafreeh.com
TUTORIALS
LOGIN FOR SUCCESS

AfraTafreeh.com

MEN 2

2A @ sipple

↓

- MCT (100%)
- Phaeochromocytoma (40%)
- Hyperparathyroidism (20%)
- Hirschsprung
- Lichen amyloidosis (cutaneous)

2B @ MEN-3

↓

- MCT (100%)
- Pheo. (40%)
- Mucosal neuromas
- Marfan+
- Megacolon
- Ganglioneuromas in GIT
- Esophageal dysmotility

Medullary cancer 00:11:50

- 75% sporadic
- 25% genetic

Medullary cancer

Familial MTC	**MEN 2A**	**MEN 2B**
↓	↓	↓
RET	RET	RET
↓	↓	↓
Exon 618	Exon 634	Exon 918
	↓	↓
	Prophylactic total thyroidectomy 5years	Prophylactic total thyroidectomy <1year More aggressive

- Hereditary type: -
  - Multifocal
  - B/L
  - Not take RAI
  - Survival 70% @ 10 years
  - 75% LN metastasis
  - Treatment: - Total thyroidectomy + CND + MRND

Phaeochromocytoma

- Arises from adrenal medulla
- 40-50% in MEN 2A and 2B
- Age: - 20-40 years

Hereditary phaeochromocytoma

- Benign always
- Only: - Adrenal
- Bilateral, multifocal
  - Treatment: - Adrenalectomy →only affected gland removed

MEN 4 syndrome 00:18:11

- CDK inhibitor mutation – chromosome 12
- Parathyroid adenomas
- Pituitary adenomas
- Renal tumors
- Reproductive organ tumors like testis and cervix.

AfraTafreeh.com

PARATHYROID

Parathyroid gland 00:00:19

Superior	Inferior
• Derived form 4th pharyngeal pouch • Mostly constant in position, it is seen **posterior to recurrent laryngeal nerve** near zuckerkandl area	• Derived from 3rd pharyngeal pouch • Highly variable in position can be seen from common carotid artery in the neck to mediastinum anywhere in between • But, most common in the lower pole of thyroid **anterior to RLN**

- Weight of each gland is about 30gm and they are brick yellow in color. So, we can confuse it with fat (or) lymph node in surgery
- They produce parathormone, contains 84 aminoacids peptide
- PTH
  - It has half-life of 3-5 minutes
  - If acts on bone, kidney, GIT
- Its main function is to maintain normal calcium value 8.5 to 10.5 mg/dl (or) 2.5 to 2.7 mmol/L
- Ionised calcium is 4.5 – 5.5 mg/dl
- On calcium homeostasis, 3 substances are acting

a. PTH

↓ **On kidney**

- Increases Ca^{++} absorption – increase S. Ca^{2+}
- Decrease phosphate absorption – decrease S. Po_4^{-2}

b. 1,25-dihydroxy vitamin D_3

↓

- Increase Ca^{2+}
- Increase Po_4^{-2}
- Ca and Po_4 absorption in GIT and kidney (both increase)

c. Calcitonin

↓ **In kidney inhibits absorption**

- Decrease Ca^{+2}
- Decrease Po_4^{-2}
- Both decrease

AfraTafreeh.com
TUTORIALS
LOGIN FOR SUCCESS

Hyperparathyroidism 00:07:09

i. Primary:

- It is due to intrinsic abnormality of the gland
- Increased production primarily can be caused by an
  - Adenoma
  - Hyperplasia

ii. Secondary:

- It is secondary to low Ca^{2+} in the body. This low calcium stimulates increase PTH production

AfraTafreeh.com

iii. Tertiary:

- It is a case of secondary hyper-parathyroid where the Ca level becomes normal, in spite of becoming normal, there is increase PTH production
  - There is autonomous secretion of PTH
  - Usually, it is due to an underlying cause like renal failure, renal transplant

Primary hyperparathyroidism

- It is common in females
- Most common in the 5th decade
- Most common presentation is kidney stones
- 40% of them can have hypercalciuria (increase Ca in urine)
- Aetiology -
  - It can be due to
    i. Solitary adenoma
    ii. Hyperplasia
    iii. Malignancy & other causes
  - Associated with MEN I syndrome
  - Associated with MEN II A syndrome
- 1° hyperparathyroidism are usually sporadic cases
- Familial cases can be usually associated with MEN I, MEN II A, hyperparathyroidism (HPT) – Jaw tumor syndrome

TUTORIALS LOGIN FOR SUCCESS

Clinical features of hyperparathyroidism

i. Bones: There is brown tumor, called **osteitis fibrosa cystica**
   - Mainly due to excessive osteoclast production results in osteclastoma
   - Salt and pepper appearance in the skull

ii. Stones: Kidney stones and pancreatic stones are seen

iii. Abdominal groans: Is due to pancreatitis, peptic ulcer

iv. Psychic moans: are due to maniac depressive episodes

Other classical features are

- HTN, LVH, muscle weakness, fatigue, soft tissue calcification in blood vessels & muscles

AfraTafreeh.com
TUTORIALS
LOGIN FOR SUCCESS

Hypertensive crisis 00:14:48

- It is an emergency in hyperparathyroidism
- Happens when S. calcium becomes >14mg/dl
- Should be immediately treated with IVF normal saline
- 200 ml/hr along with calcitonin → decrease Ca
  - Bisphosphonates
  - Steroids
- We should plan for early hyper-parathyroidectomy

AfraTafreeh.com

Diagnosis of hyperparathyroidism

- Increased Ca values
- Increased PTH values
- Decrease PO_4 values
- 24 hours urinary calcium may be increased (or) normal

To localised tumor/ adenoma

- We use investigations
  i. USG of neck
  ii. Sestamibi scan
  iii. 4D CT scan of neck
  iv. TC 99m pertechnate scan
  v. Selective venous sampling from PTH gland
- Sestamibi can works on principle – parathyroid adenoma has increased oxyphil content
- It can be false positive in Hurthle cell adenoma of thyroid, because they have oxyphil. Here we use Tc 99m pertechnate scan to confirm it is not hurthle cell adenoma
- In Tc pertechnate scan, subtraction images are obtained
- We do **MIBI + USG**, if we see a lesion in the neck on US
  - **Discordant imaging** (MIBI is showing lesion at one site and USG is showing on another site)
    - We do 4D CT (4-dimensional CT scan)

i. 4 gland explorations can be done

ii. We do pre op marking by USG → then do MIP

- **Concordant imaging** (both USG and MIBI show lesion on same area)
  - We mark it with pre-op USG and we do minimally invasive parathyroidectomy (MIP)

Asymptomatic cases of hyperparathyroidism

- Should we do surgery (or) not?? It is based on criteria

  i. Age: <50 years – Better to operate

  ii. Sr. calcium: > 1mg/dl above upper limit of normal value

  - 0.25 mmol/L above upper limit of normal value

  iii. Skeletal: Osteoporosis in bone found by the T score is "-0.25" at various places like lumbar vertebra, femur (or) if fracture of spine, in these cases we operate

  - If bone marrow density is decreased in DEXA scan → operate

  iv. Renal: If creatinine clearance <60ml/min, we have to operative. If 24 hours urinary calcium in urine >10mmol/day → operative, i.e., >400 mmol/day coming out → we operate, increased risk of stone formation

TUTORIALS LOGIN FOR SUCCESS

AfraTafreeh.com

- We have to operate all symptomatic hyperparathyroid cases and the asymptomatic cases be operated by above criteria

Surgical techniques in hyperparathyroidism

00:25:12

i. MIP (For adenoma) – Minimal invasive parathyroidectomy with <3cm incision, exactly on the lesion
ii. Bilateral neck exploration
   - For hyperplasia
   - Entire neck exploration by large incision and
     a. Remove 3 ½ gland
        - ½ gland is left, in inferior parathyroid gland which is marked with titanium clip
     b. Remove 4 gland
        - We keep one gland on brachioradialis muscle on non-dominant hand

DOC TUTORIALS LOGIN FOR SUCCESS

MIAMI criteria 00:26:55

- After removal of the gland, intra operatively, we have to measure the parathyroid hormone level and it should decrease by half the maximum of previous value. The decrease should be in 10 minutes (Pre op PTH value should decrease by half in 10 min)

- If it is not decreasing indicates, there is still a problem in the gland. Such cases we should go for bilateral neck exploration
- Miami criteria decides our further management after removal of adenomatous gland. (If decreases surgery over, if not do bilateral neck exploration)

Indications of bilateral cervical exploration

i. Discordant images

ii. MEN-1 cases

iii. MEN 2A cases

iv. Multiglandular hyperplasia patients

v. In patients with failed Miami criteria

vi. Lithium induced hyperparathyroidism

- In MEN 1 also remover thymus gland, because there may be supernumerary thymus gland seen (Thymectomy)
- Newer techniques are available now like
  - Robotics removed
  - Minimally invasive video assisted parathyroidectomy (MIVAP) (multiple approaches are there like transthoracic, axillary, cervical etc)

Post op complications

- Patients may develop

AfraTafreeh.com

1. Permanent hypocalcaemia for life long after removal of gland. They are in need of vitamin D + Ca for >1year post op
2. R.L.N injuries
3. Hyperparathyroidism – 2 types
   a. Persistent
      - At <6 weeks, still there is increase in Ca seen
   b. Recurrent
      - Patient comes back with increase Ca after 6 months

Medical treatment to decrease Ca are

i. Bisphosphonates
ii. Hormone replacement therapy
iii. Calcimimetics (cinalcet) – It is a 'Ca' sensing receptor. So, it decreases the parathyroid hormone production (By setting a new point for Ca stimulus)

TUTORIALS LOGIN FOR SUCCESS

Special cases of hyperparathyroidism 00:34:05

i. Lithium induced HPT
ii. Familial syndromes
   - MEN 1
   - MEN 2
   - HPT – jaw tumor
   - Familial calciuric hypercalcemia

- There is a mutation in Ca receptor gene, it is on chromosome 3

Secondary hyperparathyroidism

- Following a decrease Ca^{++} in serum, stimulates parathyroid hormone production and results in secondary hyperparathyroidism
- Causes:
  - Chronic kidney disease
  - G.I malabsorption
  - Vitamin D deficiency
  - Liver disease
  - Lithium drugs
- If we do lab values
  - 1° HPT → Ca is increase, Po_4 decrease
  - 2° HPT → Ca decrease / normal
  - Po_4^+ decrease
  - Low vitamin D
  - Increase PTH
- The phosphate is reabsorbed in excessive amount from renal tubules, hyperphosphatemia
- Here 2 reasons for 2° HPT
  - Hyperphosphatemia (stimulates ⊕) → increase PTH
  - Hypocalcaemia (stimulates ⊕) → increase PTH

AfraTafreeh.com
TUTORIALS
LOGIN FOR SUCCESS

AfraTafreeh.com

Investigation

- Dexa scan – osteopenia/ osteoporosis
- Localisation studies like sestamibi scan are not needed here, since there is no adenoma here (no localisation required)
- Clinical features
  - Brown tumor aka osteitis fibrosa cystica is not seen on x-ray

Casanova test 00:39:21

- In a case with recurrent hyperparathyroid, with 3 ½ gland removal, there are 2 causes for recurrence
  a. Ectopic parathyroid gland
  b. Gland hyperplasia
  - It can be confirmed by measuring PTH level form venous sampling at the site of the gland left behind. If the venous sampling ratio >20:1 then there is definitely graft hyperplasia and we have to remove the graft/ gland left

Calciphylaxis

- Calcific uremic arteriolopathy seen in 4% of patients
- It happens secondary to surgery for 2° hyperparathyroidism

- There can be purpuric lesions in skin + skin gangrene, skin necrosis → which all can leads to sepsis and death
- It has poor prognosis, seen in patients who are undergoing surgery for 2° HPT

Management of 2° HPT

- Renal transplant is treatment of choice as there is renal failure
- Calcimimetic drugs (cinalcalcet)
  - Phosphate binders
  - Calcium + vitamin D

Indications of surgery in 2° HPT

i. Essential component
  - Persistently high PTH level > 500 pg/ml
  - Phosphate > 6mg/dl
  - Ca > 2.5mmol/L (or) 10mg/dl
    - Both these values are refractory to medical treatment
  - Gland size >1cm in longitudinal axis (or) volume is 300-500 mm^3

ii. Clinical features
  - Brown tumor
  - Clinical features of bone pain, muscle weakness, pruritis
  - Patient has ectopic calcifications

AfraTafreeh.com

- Calciphylaxis
- Dilated cardiomyopathy + heart failure
- Anaemia resistant to erythropoietic stimulating agents
- Decreasing bone mineral content
- For 2° HPT, there is no minimally invasive parathyroidectomy, we go for **subtotal parathyroid excision is TOC**
  - We remove 3 ½ gland and leave ½ gland in situ (or) remove 4 glands and keep Morcellated tissue in forearm brachioradialis. There will be a dramatic response seen

Tertiary hyperparathyroidism

- It is a rare condition
- There is decrease Ca^{2+} stimulating pituitary gland to produce increase PTH and now the Ca becomes normal. But inspite of Ca becoming normal there is still increased PTH production resulting in sometimes autonomous nodule (or) without a nodule, there can be increase PTH. This is known as 3° PTH
- It has
  - Increase Ca^{+2}
  - Increase PTH
  - Decrease Po_4

  (Some features/ lab values of 1° HPT)
- Usually this occurs after 1 year of renal transplant

- No use of calcimimetics in these patients
- Treatment is subtotal PTH excision

Indications of surgery in 3° HPT

i. Severe hypercalcemia > 3mmol/L
ii. Renal graft dysfunction
iii. Nodular hyperplasia
iv. > 2 years of transplant, there are progressive symptoms
   - Like worsening;
     - Bone pain
     - Renal stones
     - Vascular calcifications

AfraTafreeh.com
TUTORIALS
LOGIN FOR SUCCESS

1° HPT

- MIP
- Total parathyroidectomy
  - 3 ½ gland removal (or) 4 gland removal and implanted done

2°HPT	3° HPT
• Medical treatment is best	• Usually follows transplant surgery is indicated
In both cases, no role of MIP, we remove 3 ½ gland (or) 4 glands	

AfraTafreeh.com

- In case, there is HPT, we should think of an ectopic PTH, most common site of ectopic is paraesophageal > mediastinal > thymus

Parathyroid cancer:

- Last cause of HPT can be parathyroid cancer
- Incidence is only 1% of HPT
- It is 0.005% of all cancers
- Only important predisposition factor is H/O irradiation of neck
- Syndromes associated are
  a. HPT – Jaw tumor syndrome
  b. HRPT-2 syndrome → is the parafibromin inactivation is seen

Diagnosis

- It arises/ decade earlier than normal HPT
- Equal in male = female
- Symptomatic at presentation also have neck mass
- They come with increase Ca, increase PTH (5-10 times increased)
- It is diagnosed by IHC showing
  i. Parafibromin positive
  ii. Protein gene product (PGP 9.5 positive)
- Treatment: Radical removal of tumor without spillage.

TUTORIALS
LOGIN FOR SUCCESS

ADRENAL

Adrenal gland

- Adrenal gland is pyramid in shape on (R) side and is crescent shaped on (L) side
- They are 4 grams each
- It has 4 grams each
- It has cortex and medulla tumor arising from chromaffin cells of adrenal medulla is known as **Pheochromocytoma**
- Tumor arising from chromaffin cells of extra adrenal **Paraganglioma**
- Adrenal medulla secretes → Adrenaline > NA > Dopamine
- Zona glomerulosa secrete → Aldosterone
- Zona fasciculate / Reticularis secretes → Cortisol & DHEA (they are the precursors of androgens)
- Most common incidentaloma in adrenal is
  - Nonfunctioning adenoma (78% prevalence)
  - Cushing's adenoma (7% prevalence)
- Most common functioning tumor/adenoma in adrenal gland is Cushing's

Cushing's syndrome 00:03:02

- It is an excessive production of steroids

AfraTafreeh.com

AfraTafreeh.com

- Most common causes of increases steroid in blood is iatrogenic
- Cushing's syndrome is due to

ACTH dependent (75%)
↓
It has a pituitary source
↓
ACTH (+)
↓
Named as Cushing's disease

ACTH independent (15%)
↓
- There is an adrenal source of ACTH
- Most common is adrenal adenoma

- Another ACTH dependent is by ectopic ACTH production from some tumor like small cell lung Ca → It is 10%

Clinical features 00:06:36

- There will be lemon on stick appearance
- Buffalo hump is seen
- Abdominal stria is seen
- Moon facies
- Increased hair growth
- They have definite HTN (B/O excessive steroids)
  Definite Diabetes
  Define hyperlipidemia
- They may have depression, amenorrhea, impotence

TUTORIALS LOGIN FOR SUCCESS

Lab investigations 00:08:24

- Measure the ACTH values at various time
  - It peaks in 4:00am - 10:00 am/ Other times it is normal
  - It is called diurnal variation – It is seen only in pituitary source absent in adrenal source
- High dose dexamethasone given → Normally ACTH values should fall down/Go down it is seen only in pituitary source absent in adrenal source
  - How to differentia the source of hypercortisolemia → By 3 tests

AfraTafreeh.com

	Cushing's syndrome (adrenal source)	Cushing's disease (Pituitary source)	Ectopic ACTH
a. Diurnal variation of ACTH	Absent	+++	Absent
b. ACTH level	<5pg/ml	15-500pg/ml	>1000pg/ml
c. High dose dexamethasone suppression	No response ↓ CECT adenomas	↓↓↓ ACTH values ↓ If it is pituitary source then advise for	No response ↓ We should R/O small cell Ca lung, carcinoids, Pheochromocytoma, bronchial adenoma

TUTORIALS LOGIN FOR SUCCESS

AfraTafreeh.com

		pituitary MRI, Inferior petrosal venous sampling is done	↓ These are diagnosed by CT abdomen CT chest, Somatostatin receptor scintigraphy (SRS) are used for ectopic sources

Treatment

Adrenal source

↓

Single adenoma

↓

U/L Adrenalectomy

- For hyperplasia

↓

B/L adrenalectomy

Pituitary source

↓

- Trans sphenoidal excision by surgery
- Pituitary irradiation
- Stereotactic Radiosurgery (SRS) Deliver radiotherapy only to the tumor

↓

For unremovable pituitary tumor

↓

B/L Adrenalectomy + Lifelong steroids given

TUTORIALS LOGIN FOR SUCCESS

Post OP: 00:16:37

- U/L adrenalectomy → Temporarily give cortisol since C/L gland also has suppressed function after 1year only other gland compensates
- Before stopping cortisol, we have to do Synacthen test. Synacthen is a drug which acts like ACTH, give it and look for cortisol normal secretion. If no normal secretion of cortisol we have to give cortisol supplement whenever there is normal secretion, then only we stop supplement

CONN'S syndrome 00:18:32

- It is primary hyperaldosteronism
- So, they have HTN, hypokalemia
- Most common cause of conn's – Adenoma

Waterhouse Friedrichsen syndrome 00:19:13

- Here B/L adrenal (gives for necrosis) Infarction in meningococcal sepsis it is rapidly fatal

Adreno cortical tumors 00:19:54

- Rare
- Bimodal distribution → In children and 4th decade
- F: M = 1.5:1
- Mostly they are functional tumors – Produce Cushing's syndrome

AfraTafreeh.com

- They present with typical Cushing's syndrome
- MRI – IOC
- **Mc Farlane classification** is for adreno cortical tumors
- Treatment – Enblock removal is done
  - Then past OP chemo with etoposide, doxorubicin, cisplatin
  - Ketoconazole and mitotane should be given to reduce hormone levels

Pheochromocytoma 00:23:02

- It is a catecholamine producing tumor from chromaffin cells of adrenal medulla
- Extra adrenal sources of phaeochromocytoma are most common is para-aortic region 75%; others
  - Thoracic
  - Bladder
  - Neck
  - Pelvis
- Phaeochromocytoma is called 10% tumor because
- 10% extra adrenal
- 10% Seen in children
- 10% familial → Most common associated if NF-1

  others – VHL, Sturge weber, MEN-2, Familial paraganglioma syndrome

  ↓

  Associated with SDH mutation (succinate dehydrogenase)

- 10% malignant
- 10% B/L
- 10% are discovered incidentally

Features suggestive of malignant phaeochromocytoma

- Given by PASS – Phaeochromocytoma adrenal gland scale score
- PASS is based on
  - Ki 67 index
  - Vascular invasion
  - Capsule breach
  - Presence of mets
- Clinical features → 5 'P'
  - Pressure (HTN)
  - Palpitation
  - Pain (Headache)
  - Pallor
  - Perspiration (Sweating)
  - 6th P – Paroxysmal spell (5 PS are not always seen they are seen paroxysmally)

AfraTafreeh.com
TUTORIALS
LOGIN FOR SUCCESS

Lab investigations 00:28:35

- Most (or) Straight forward – Pheochromocytoma excessively produces Nor-adrenaline > Adrenaline
- Extra adrenal Pheochromocytoma – Only Nor-adrenaline

AfraTafreeh.com

- MEN – II Phaeochromocytoma – Only Adrenaline
- Malignant → Dopamine & Homovanillic acid
- Patient present to hospital with a paroxysmal spell the spell i.e., pressure, pain, perspiration will last for 10-60 minutes
- It can happen once daily to once monthly
- It can resolve spontaneously
- It can be precipitated by – Contrast injection
  Drugs
  Exercise
  Micturition

Carney's triad 00:31:34

- Functioning paraganglioma + Gist + Pulmonary chondroma
- **Investigations**: To localize and diagnose Pheochromocytoma

To diagnose

Screening
↓
- 24hours urinary VMA, urinary catecholamines like metanephrine, Nor metanephrine

Diagnosis
↓
- Plasma metanephrines are IOC

- **To localize** in adrenal, extra adrenal and pregnancy in all these cases – MRI

- I^{123} MIBG – Meta Iodo Benzyl Guanidine Scan it is done for
  1.Metastatic cases
  2.Extra adrenal – Multiple tumors
- Now a days for mets and extra adrenal multiples – FDG PET and DOPA PET are used
- For ectopic cases also, IOC – MRI
- We cannot do CECT because it stimulates paroxysms
- On MRI – Adrenal phaeochromocytoma shows **Swiss cheese pattern**

Pre-Op preparation 00:36:06

- First start α – blocker → Phenoxybenzamine (20-160mg) until the patient goes for postural hypotension complete α blockade
- Then give β blockers for tachycardia and arrythmia

Surgical management 00:37:39

- Gold standard – Laparoscopic adrenalectomy
- Anesthesia DOC – Enflurane/Isoflurane

Malignant Pheochromocytoma 00:38:26

- They can have HTN initially and mitotane is given for mets and postop chemo like – Vincristine, Cyclophosphamide, dacarbazine.

AfraTafreeh.com

NEUROSURGERY

CSF Pathway 00:00:38

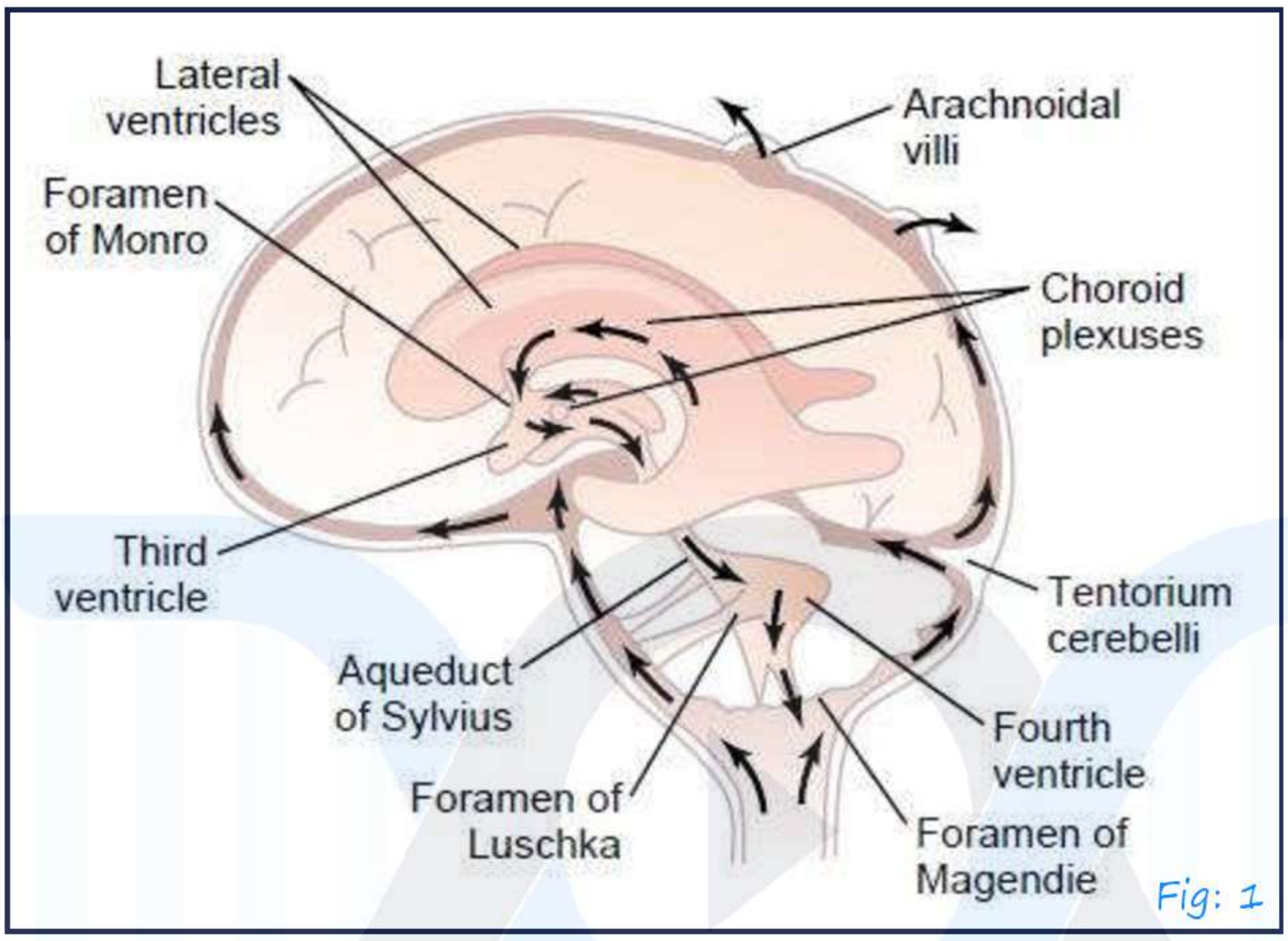

Fig: 1

- CSF is initially produced from lateral ventricles

  ↓

  Enters third ventricle through foramen of Munro

  ↓

  Enters IV ventricle through Aqueduct of Silvius

  ↓

  Joins subarachnoid space through 2 foramen

  ↓

  Magendie – medially

  Luschka – laterally

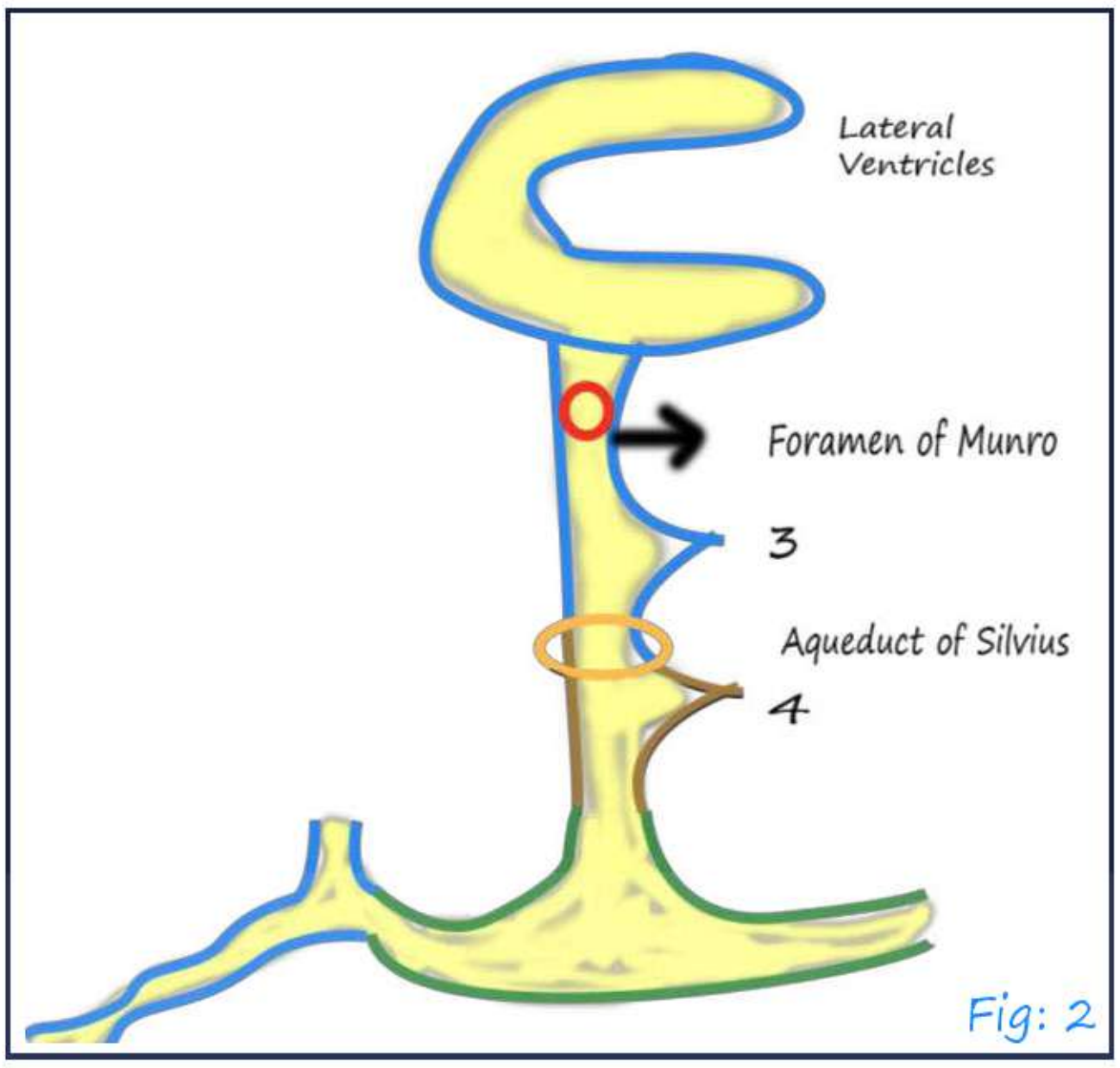

Fig: 2

- In subarachnoid space, we have dural venous sinuses

  ↓

  Enters systemic circulation via veins

AfraTafreeh.com

Hydrocephalus 00:04:15

- High pressure CSF: Headache → Increases on coughing/bending
- Low pressure CSF: Headache → increase on Standing
- High pressure headache

  ↓

  Clinical feature – vomiting
  Vision problem
  Nausea
- In infants, fontanelles are not fully closed

  ↓

  Increases CSF – Bulging fontanelles
  - Papilloedema
  - Parinaud syndrome

AfraTafreeh.com

↓

Dorsal midbrain compression

↓

Upward gaze affected

↓

Sunset sign

Types of Hydrocephalus 00:08:11

Types of hydrocephalus

Obstructive

↓

Compression by lesions inside or outside ventricle

↓

L.P is C/I

Communicating

↓

Failure of absorption

↓

Post haemorrhagic

CSF infection

Increases protein content

LP – 10-30ml removed

Normal pressure hydrocephalus 00:10:11

- Cause of dementia
- Characterized by a triad of – Gait disturbance
  Incontinency
  Cognitive decline
- Etiology – de Novo
  - SAH
  - Meningitis
  - Head injury
  - Tumors
- CT scan – Ventriculomegaly
- LP – Normal pressure

AfraTafreeh.com

Idiopathic Intracranial Hypertension 00:13:24

- Also known as – Benign Intracranial HTN
  – Pseudotumor cerebri
- Rapidly progress to blindness
- Young overweight females
- Characterized by – Headache
  - Visual disturbances
  - Papillo edema
  - Cranial nerve dysfunction
- LP – CSF pressure >25 mmHg

  ↓

  Reason –

  1. Sinus thrombosis
  2. Increases IAP in obese

DOT TUTORIALS
GOING FOR SUCCESS

AfraTafreeh.com

- Treatment – Weight loss
  OCP– stop
  Acetazolamide
  - Shunts – VP, LP – Prevents vision loss
  - Optic nerve sheath fenestration

Management of Hydrocephalus

- Hydrocephalic attack is an emergency

↓

Can go for rapid coma and death

↓

External ventricular drain → Catheter tip is at coronal suture level

→ Tip at foramen of Munro

Fig: 3

- Lumbar drain – communicating hydrocephalus

Fig: 4

→ Ventriculo-peritoneal shunt

Ventriculo pleural shunt

Ventriculo atrial shunt

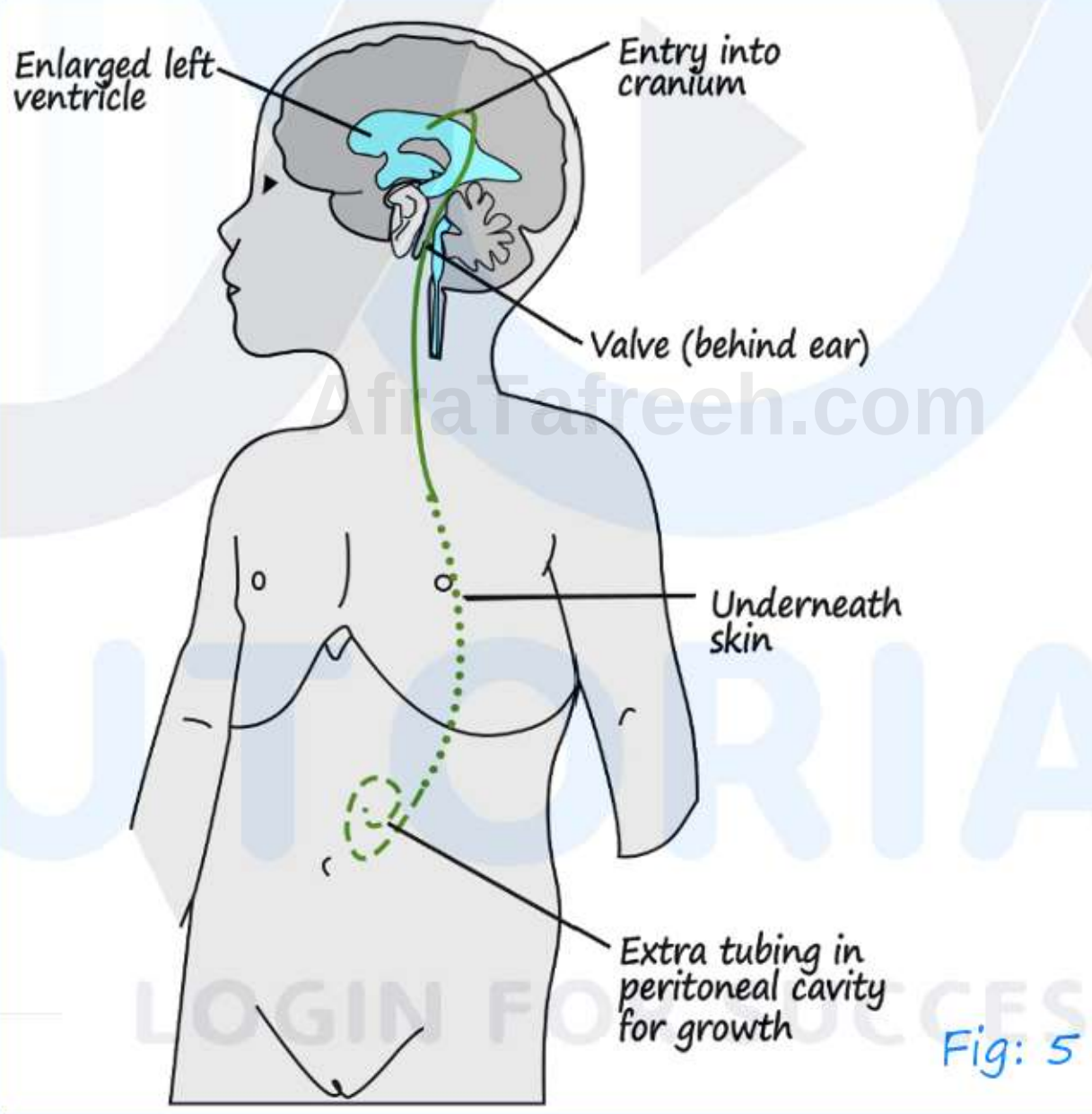

Fig: 5

- Lumbar peritoneal shunt → communicating hydrocephalus

VP shunt

- From lateral ventricle → abdominal cavity
- Can use

AfraTafreeh.com

i. Anti-siphon system

ii. Shunt valve

→ low pressure

medium pressure

high pressure

iii. CSF reservoir

Shunt complications 00:23:37

i. Over drainage → Low pressure headache on standing

ii. Ventricles may collapse

↓

Bleeding in ventricles

↓

- Subdural hematoma
- Subdural hygroma

iii. Slit ventricle syndrome

↓

- Commonly seen in children with poor ventricle and subarachnoid spaces are underdeveloped

↓

Poor brain compliance

- Shunt blockage – ventricles not expand

*Practical problems

↓

Obstruction

Infection → most common cause – staph epidermidis

Disconnection

TUTORIALS LOGIN FOR SUCCESS

Infection occurs in young patients

↓

75% in 1st month

- -Open meningomyelocele
- -Long operating time
- -Increased movement of person in theatre

- 15-20% require replacement of shunt in 3 years.
- Treatment – IV antibiotics
  External CSF drainage
  LP done

Once CSF confirms resolution of infection (protein con. N)

↓

New shunt placed on opposite side

Endoscopic Ventriculostomy

- Done for aqueduct stenosis
- Neuroendoscopy → stent is passed between 3rd and 4th ventricle through foramen of munro
- Serious complication – can injure basilar artery
  ↓
  Permanent memory impairment

Brain Abscess 00:32:00

- Can be due to
  - Direct infection
  - Hematogenous
  - 25% cases- no cause

AfraTafreeh.com
DOC TUTORIALS
LOGIN FOR SUCCESS

AfraTafreeh.com

Bacteria isolated are

Mastoiditis	Hematogenous	Food	Trauma
↓	↓	↓	↓
Streptococci, Bacteroides	Streptococci, Bacteroides	Toxoplasma, Neurocysticercosis	Staph aureus, clostridia

- Infection in HIV by
  - Toxoplasma
  - Cryptococcal
  - JC virus – Multifocal leuco encephalopathy
  - Mycobacterial abscess
- Clinical features
  - Low grade fever
  - Seizures
  - Confusion
  - Focal neurological deficit

TUTORIALS LOGIN FOR SUCCESS

- CRP increases

  Blood culture ⊕

  CECT → IOC

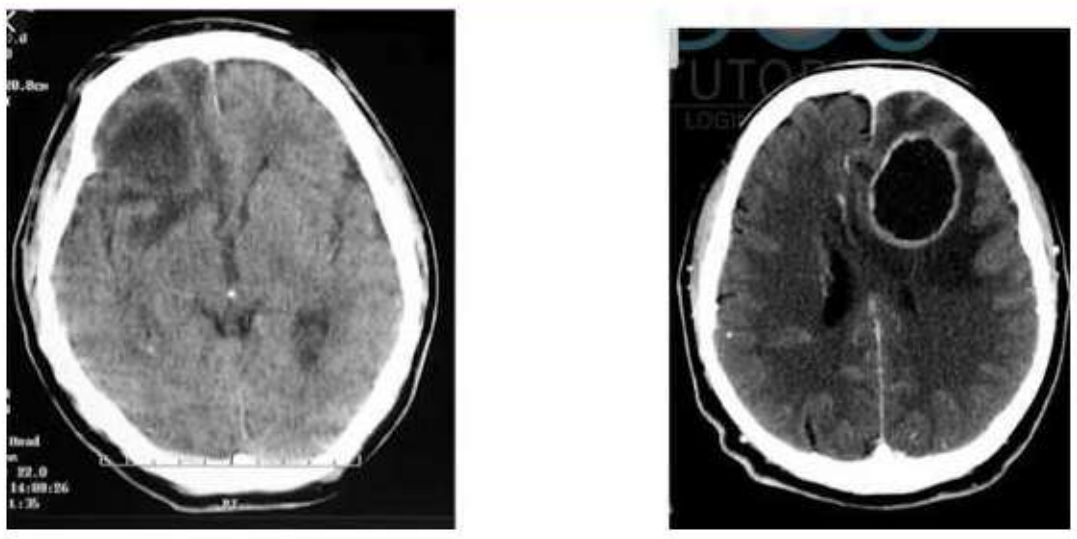

Fig: 6

1st image – Cerebritis: hypodense

2nd image – Ring enhancing lesion → well defined wall

Sometimes MRI is needed to differentiate tumor or abscess

↓

T_2 weighted image → Hyperintense lesion

- Mortality 4%

  ↓

  80% if it ruptures → ventriculitis

- Treatment of choice → surgical drainage of abscess with 6 weeks antibiotics and prophylactic anticonvulsants given.

Subdural Abscess 00:39:55

- May follow sinusitis
  Mastoiditis
  Meningitis

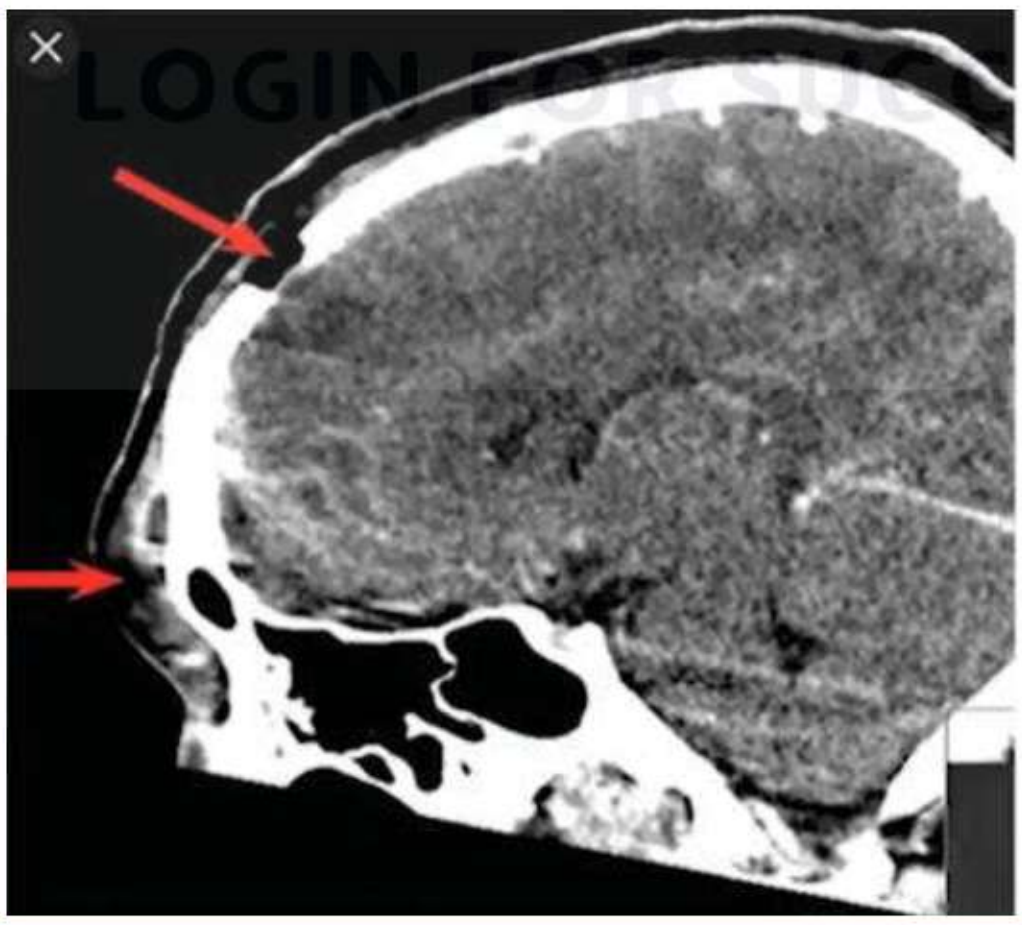

Fig: 7

Frontal bone osteomyelitis

(pott's puffy tumor)

AfraTafreeh.com

AfraTafreeh.com

↓

Can cause subdural abscess

- Treatment – pus seen in parafalcine region

↓

Cortical veins thrombosis

↓

mortality → 8-12%

↓

Burrhole

Cranioectomy + IV antibiotics

Craniotomy

- IOC – CECT
- LP is C/I

Intracerebral Haemorrhage 00:43:12

Subarachnoid Haemorrhage

- Most common cause – Trauma
- Spontaneous SAH – 80% due to berry aneurysm

  20% due to A-V malformation

Berry aneurysm → SAH 00:44:24

- Rupture seen in 10-15/lakh population
- Clinical features – Thunder clap headache

  And LOC

- One type of SAH – Perimesencephalic SAH

↓

  - Bleeding confined to basal cisterns of midbrain and pons
  - No aneurysm
  - Venous bleeding
  - Good prognosis
- Berry aneurysm → SAH
- Predisposing factor
  - Females
  - HTN
  - Smokers
  - Cocaine users
  - Family H/O berry aneurysm
  - ADPKD
  - Marfan's syndrome
  - Ehler danlos
  - Fibromuscular dysplasia

AfraTafreeh.com
TUTORIALS
LOGIN FOR SUCCESS

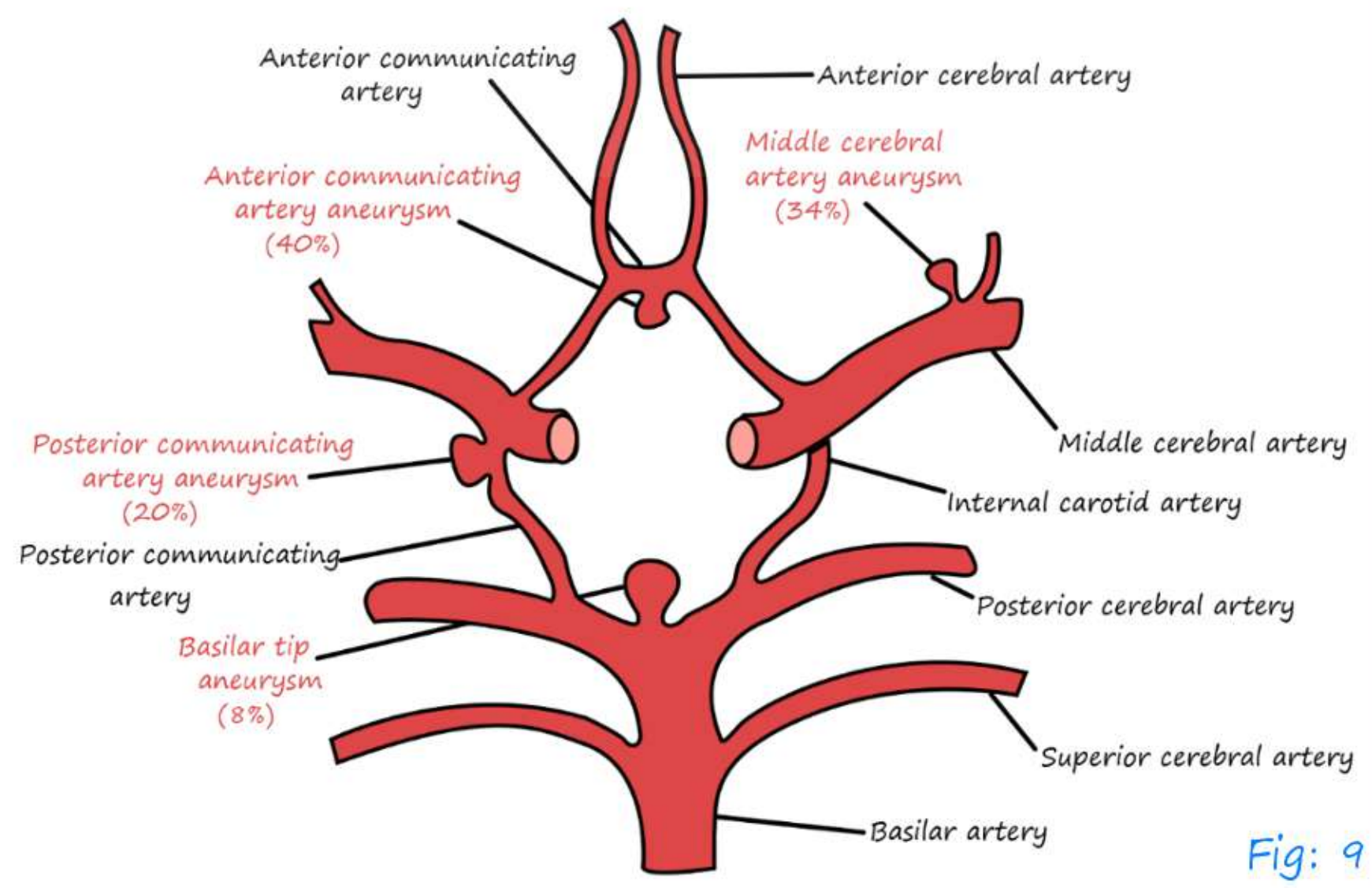

Fig: 9

AfraTafreeh.com

Circle of willis

- Most common site – Anterior communicating artery

  2nd – Middle cerebral artery

  3rd – Posterior communicating artery

  Least common – Basilar tip
- Clinical features of SAH
  - 10-15% die before coming to hospital
  - After reacting hospital → 1/3 will die in hospital

    1/3 will develop neurological deficit

    1/3 recover
- Complications
  - Most common cause of death – Rebleeding (most common complication)
  - Hydrocephalus
  - Vasospasm → prevented by nimodipine

    → Induce HTN

    → Hypervolemia
  - Terson syndrome (10-20%)

    ↓

  SAH + vitreous hemorrhage

TUTORIALS LOGIN FOR SUCCESS

World federation of neurological surgeons (WFNS) grading of subarachnoid hemorrhage

Grade	Glasgow coma scale	Focal deficits[a]
I	15	–
II	13-14	–
III	13-14	+
IV	7-12	±
V	3-9	±

Focal deficit= dysphasia or limb weakness

Clinical Grading System 00:56:05

Hunt & Hess scale

- Gives the idea of outcome
- Grade 1 – Minimal headache/Nuchal rigidity → 70% recover

Grade 2 – Moderate to severe headache
Nuchal rigidity more
Cranial nerve palsy +/- } 70% recover

Grade 3 – Drowsy + Confused + Focal neurological deficit 15% recover

Grade 4 – Hemiparesis ⊕
Stupor ⊕
Decerebrate rigidity ⊕ } **15% recover**

Grade 5 – Coma +
Moribund } 0% recover

AfraTafreeh.com
TUTORIALS
LOGIN FOR SUCCESS

AfraTafreeh.com

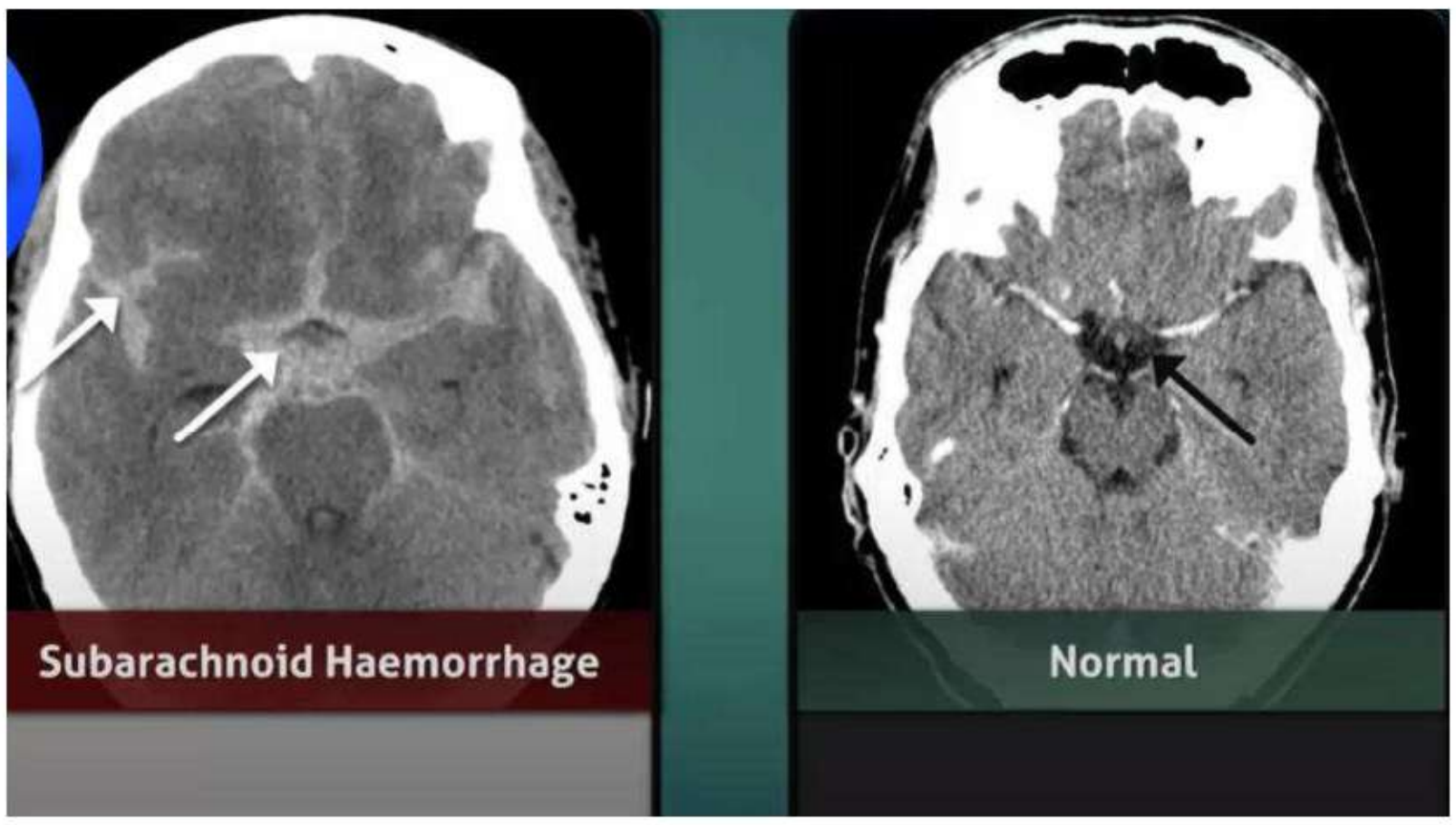

Fig: 9

- IOC – CT scan → Hyperdense signal ⊕ in subarachoid space
- LP – CSF → Xanthochromic
- CT scan grading → Fisher grading
- Cerebral angiography can be done for stable patients
- DSA – Gold standard

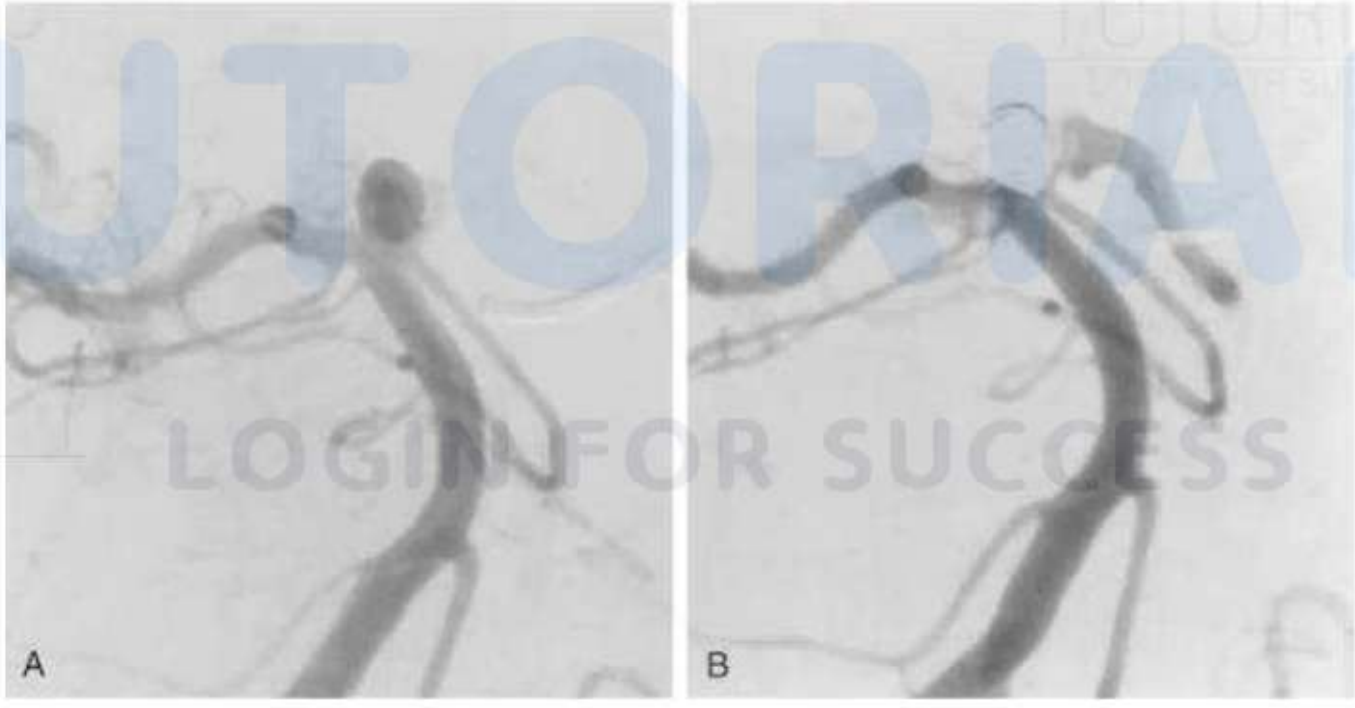

Clipping

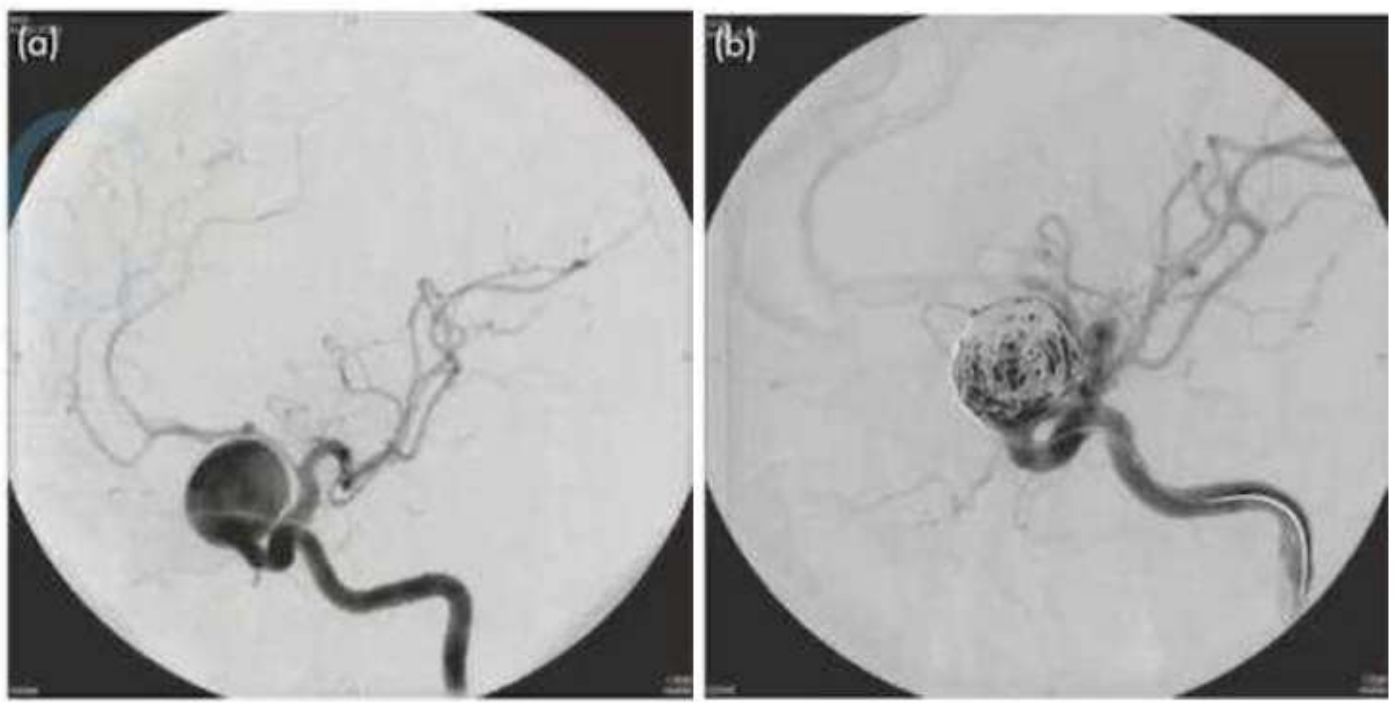

Coiling

Fig: 10

- Clipping and coiling → treatment of berry aneurysm
- Medical treatment 3-10 days

↓ ↑

Prevent delayed ischemic neurological deficit (DIND)

↓

Triple 'H' therapy → Hypervolemia

HTN

Hemodilution

- Oral nimodipine

AV Malformation 01:06:46

- 10% cases of SAH
- Congenital in origin
- Risk of bleeding – 4%/ year
- Treatment – Embolisation

  Surgical resection

  Stereotatic radiosurgery
- Intervene when malformation is >2.5 cm size.
- Spetzler – Martin Grading system

↓

Used in management of AVM

Based on size

↓

<3 cm – 1

3-6 cm - 2

>6cm -3

Location

Eloquent	Not
1	0

Vein

Superficial	Deep
0	1

AfraTafreeh.com

AfraTafreeh.com

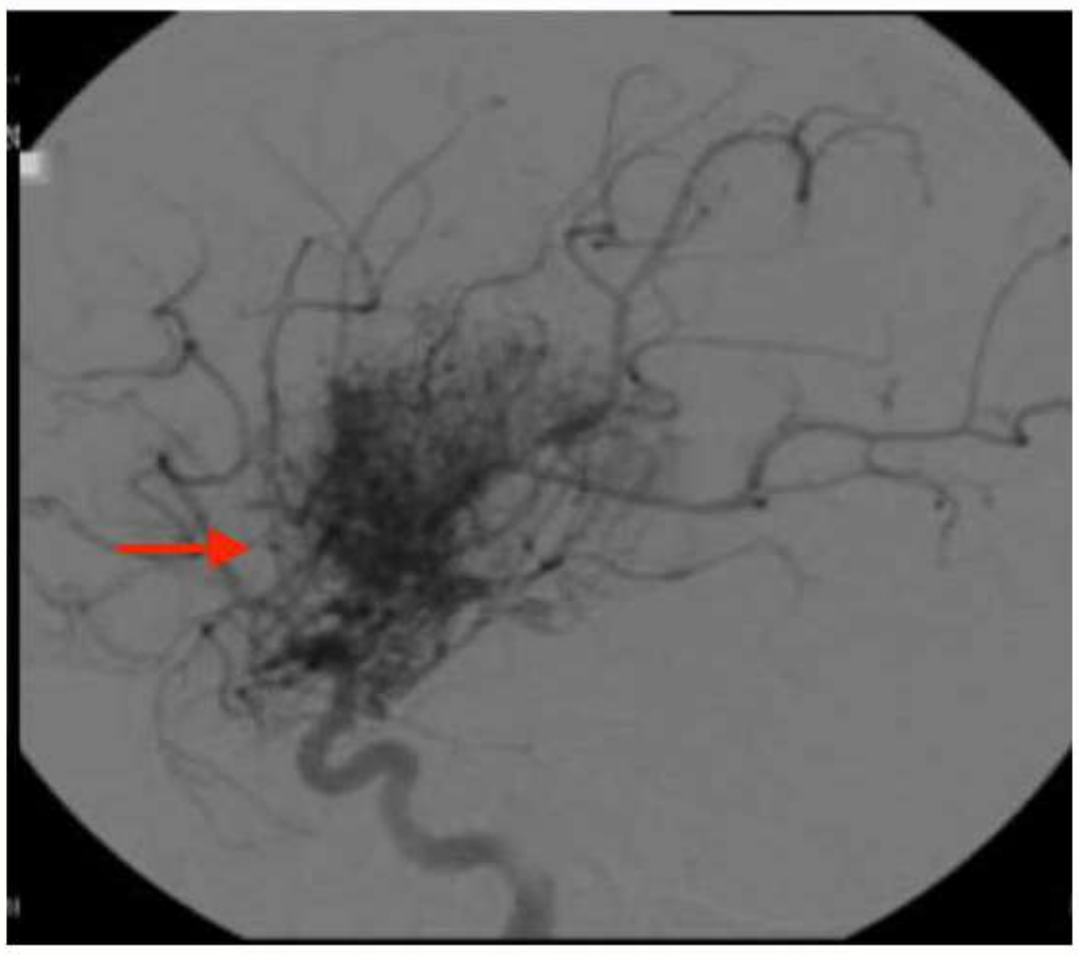

Fig: 11

- Carotid angiogram

  ↓

  Puff of smoke appearance

  ↓

  Moya moya disease

  ↓

  - Autoimmune disease
  - Internal carotid artery is obliterated
  - Multiple collaterals formed from ECA
  - Treatment – Superficial temporal artery to middle cerebral artery bypass is done.

LOGIN FOR SUCCESS

Other causes of Hemorrhage

1. HTN
2. Ischemic stroke

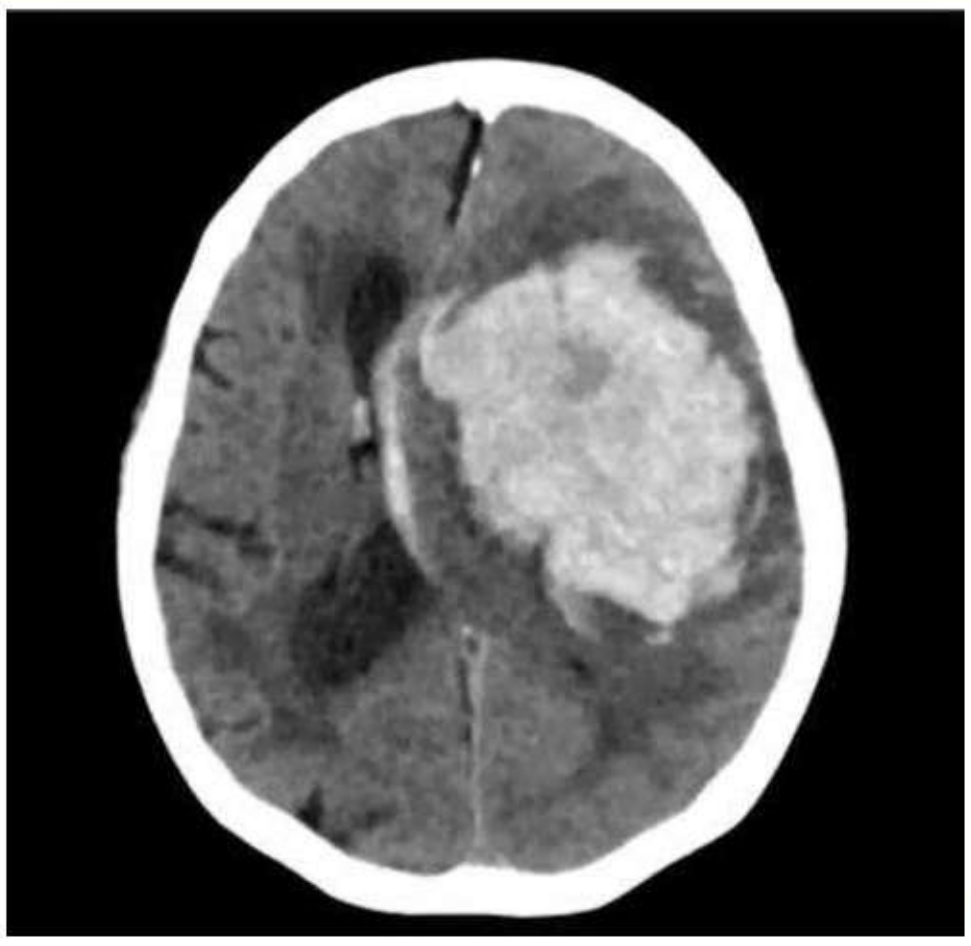

Fig: 12

- CT scan shows hyperdense lesion

↓

ICH

↓

- C/L hemiplegia ⊕
- Mortality 40% in one year
- Cause – HTN

Anticoagulants

Amyloid

Angiopathy

Treatment – stop anticoagulants,

– craniotomy & evacuation

AfraTafreeh.com

Brain Tumors 01:15:03

- Presents with a triad of – Seizures

Increases ICP

Focal Neurological Deficit (FND)

AfraTafreeh.com

Syndromes associated

- NF_1 → Astrocytoma, schwannoma, optic nerve glioma
- NF_2 → Meningioma
- P_{53} → Glioma
- Turcot syndrome → Medulloblastoma
- HNPCC → Astrocytoma
- MEN – I → Pituitary adenoma
- VHL gene → Hemangioblastoma

Based on location 01:19:22

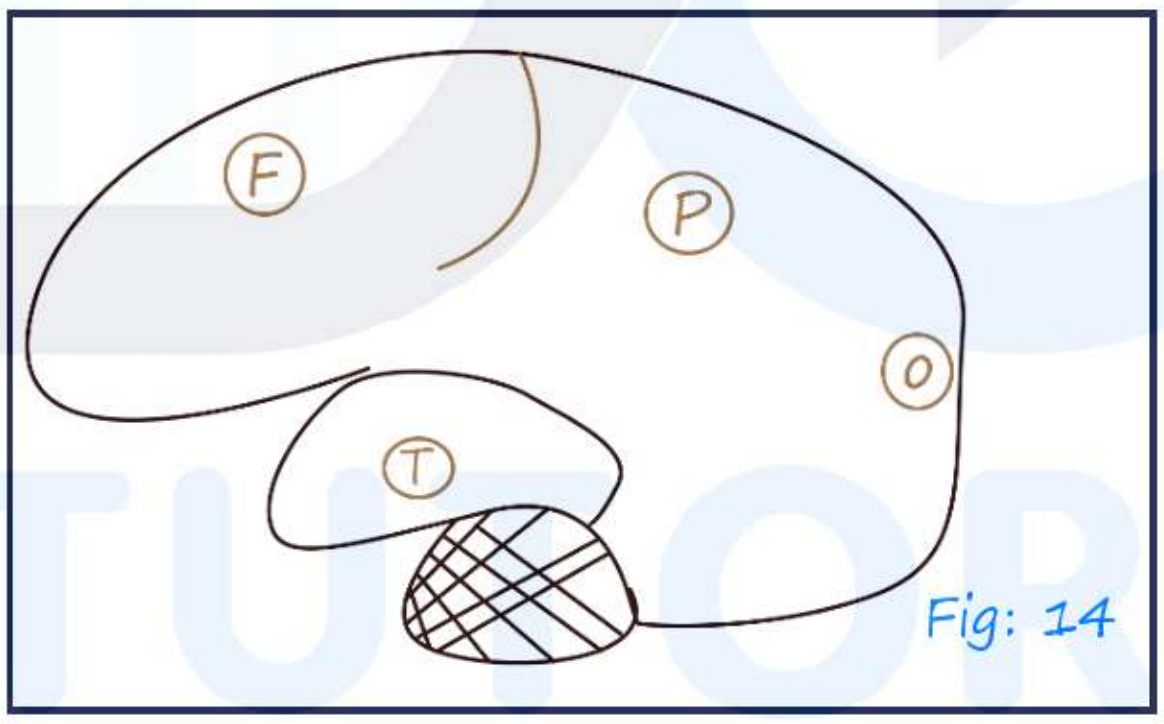

Fig: 14

LOGIN FOR SUCCESS

- Pituitary tumor → Bitemporal hemianopia

- Occipital lobe → Homonymous hemianopia

- Anterior skull base tumors (olfactory groove) →
  Foster kennedy syndrome
  ↓
  - Ipsilateral optic atrophy
  - contralateral papilledema
  - Anosmia

- Parietal lobe tumors – Gerstman syndrome
  ↓
  - Acalculia
  - Agraphia
  - Left → right disorientation
  - Finger agnosia
- Frontal lobe tumors → Gait changes
  Personality
  Urinary incontinency

AfraTafreeh.com
TUTORIALS
LOGIN FOR SUCCESS

- Most common – mets
  ↓
  Lungs – 40% (males/overall) – small cell carcinoma
  Breast – 15% (Females) → Leptomeninges
  Melanoma – 10%
  Renal – 10%
  ↓
  Cerebral hemispheres

AfraTafreeh.com

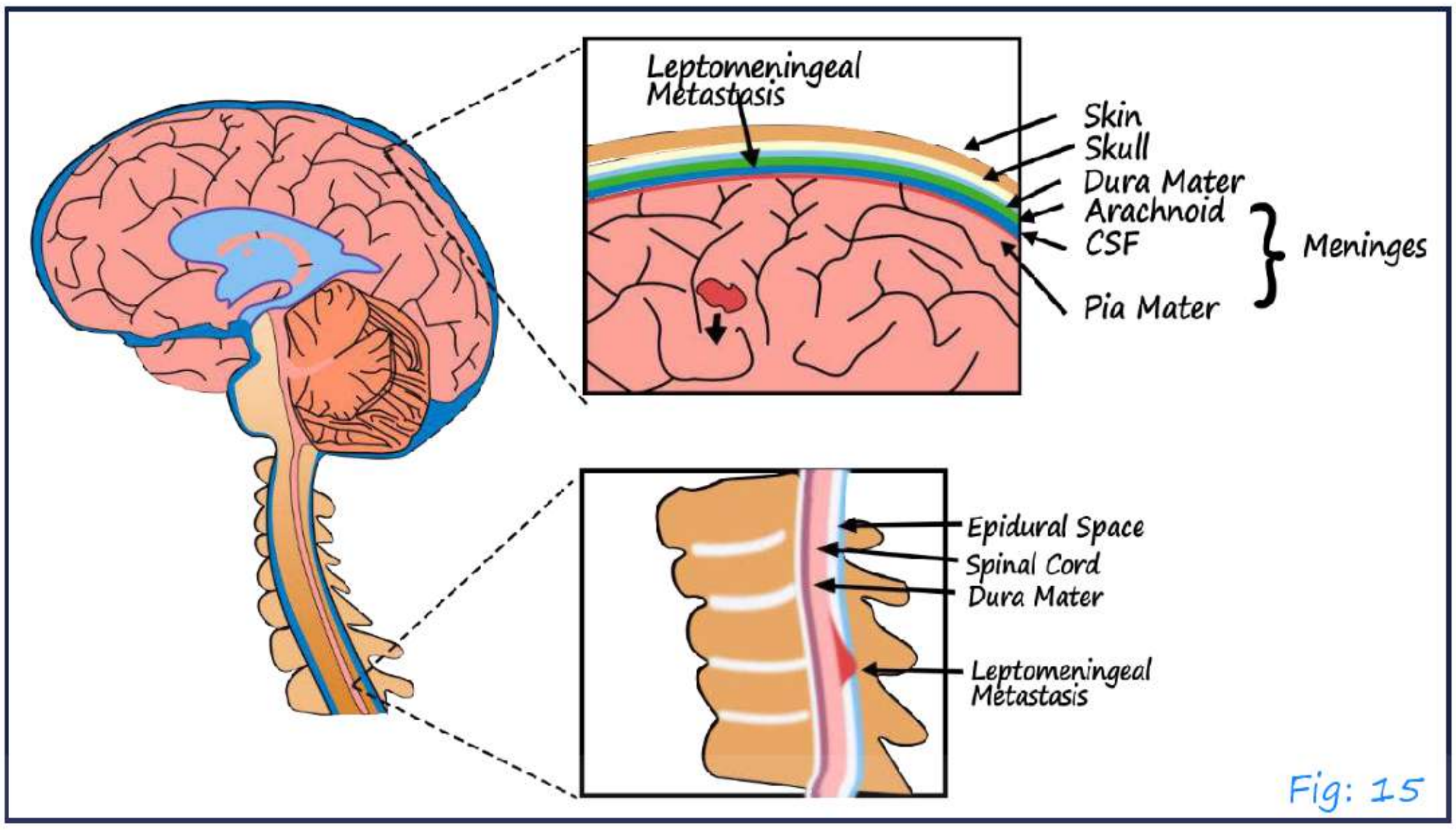

Fig: 15

- IOC for brain tumors → MRI + Gadolinium contrast

Management of mets 01:28:08

- DOC – steroids
- Single mets (upto 3) – Operated
- Whole brain RT

Fig: 16

- Stereotactic radiosurgery

↓

Gomma knife/cyber knife

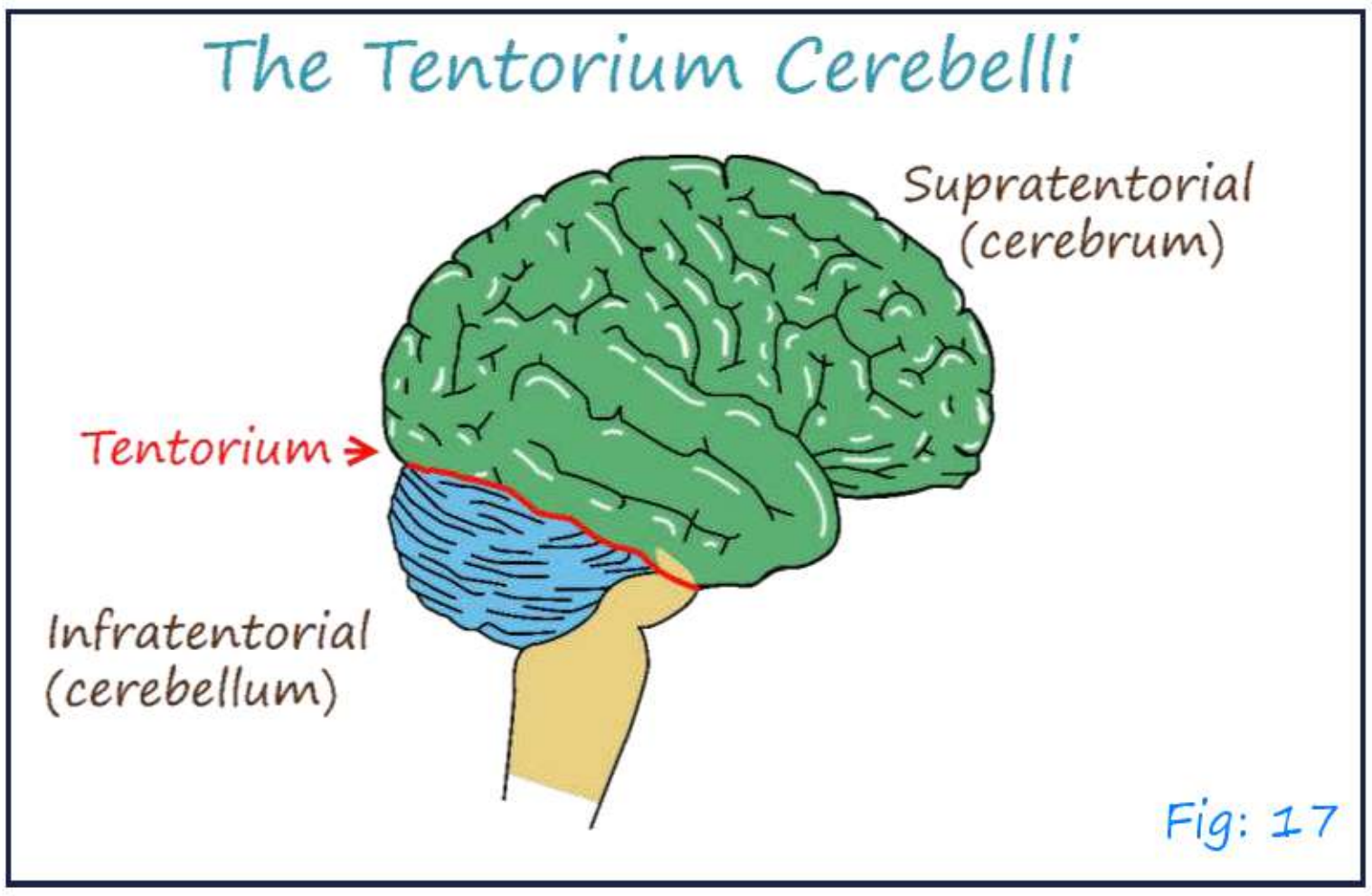

Fig: 17

Primary brain tumors

Adults	Children
80% supratentorial	40% supratentorial
20% Infratentorial	60% Infratentorial

AfraTafreeh.com TUTORIALS LOGIN FOR SUCCESS

- Most common 1° brain tumor in children – Grade I Astrocytoma

  Adults – Grade IV Astrocytoma

Other name of Grade I astrocytoma – pilocytic astrocytoma

Other name of grade IV astrocytoma – Gliobastoma multiforme

AfraTafreeh.com

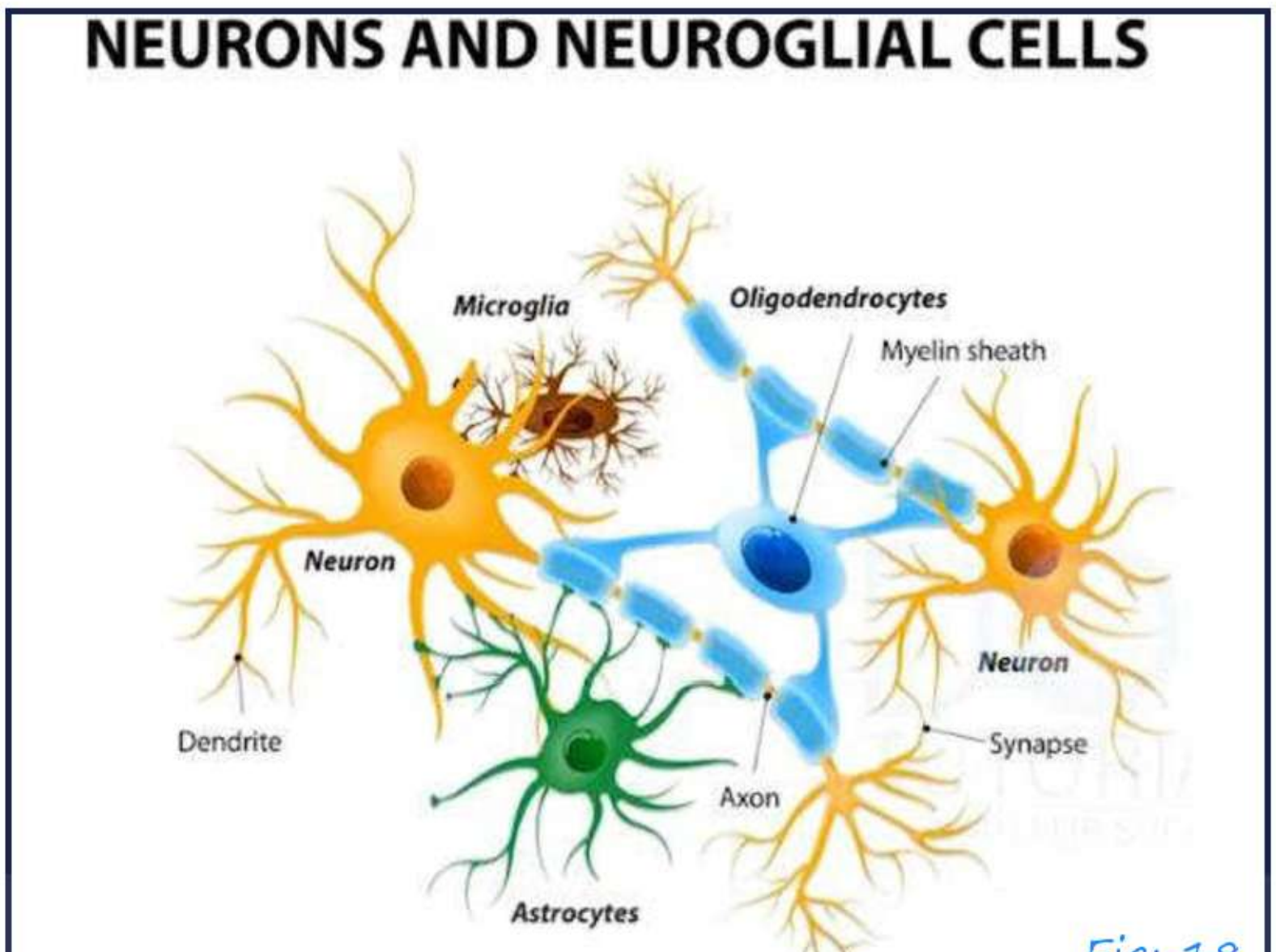

Fig: 18

- Neurons – Structural and functional unit
- Supporting cells of CNS →
  1. Astrocytes → forms blood brain barrier
  2. Oliogodendrocytes → myelin of CNS
  3. Microglia → Scavengers in CNS
  4. Ependymoma → Lines ventricles & produces CSF
- Myelin of peripheral nervous system
  - Schwann cells

    ↓
    - Acoustic neuroma
    - Vestibular schwannoma

Tumors arising from Glial cells

1. Astrocyte – Astrocytoma
2. Oligodendrocyte – Oligodendroglioma
3. Ependymal – Ependymoma

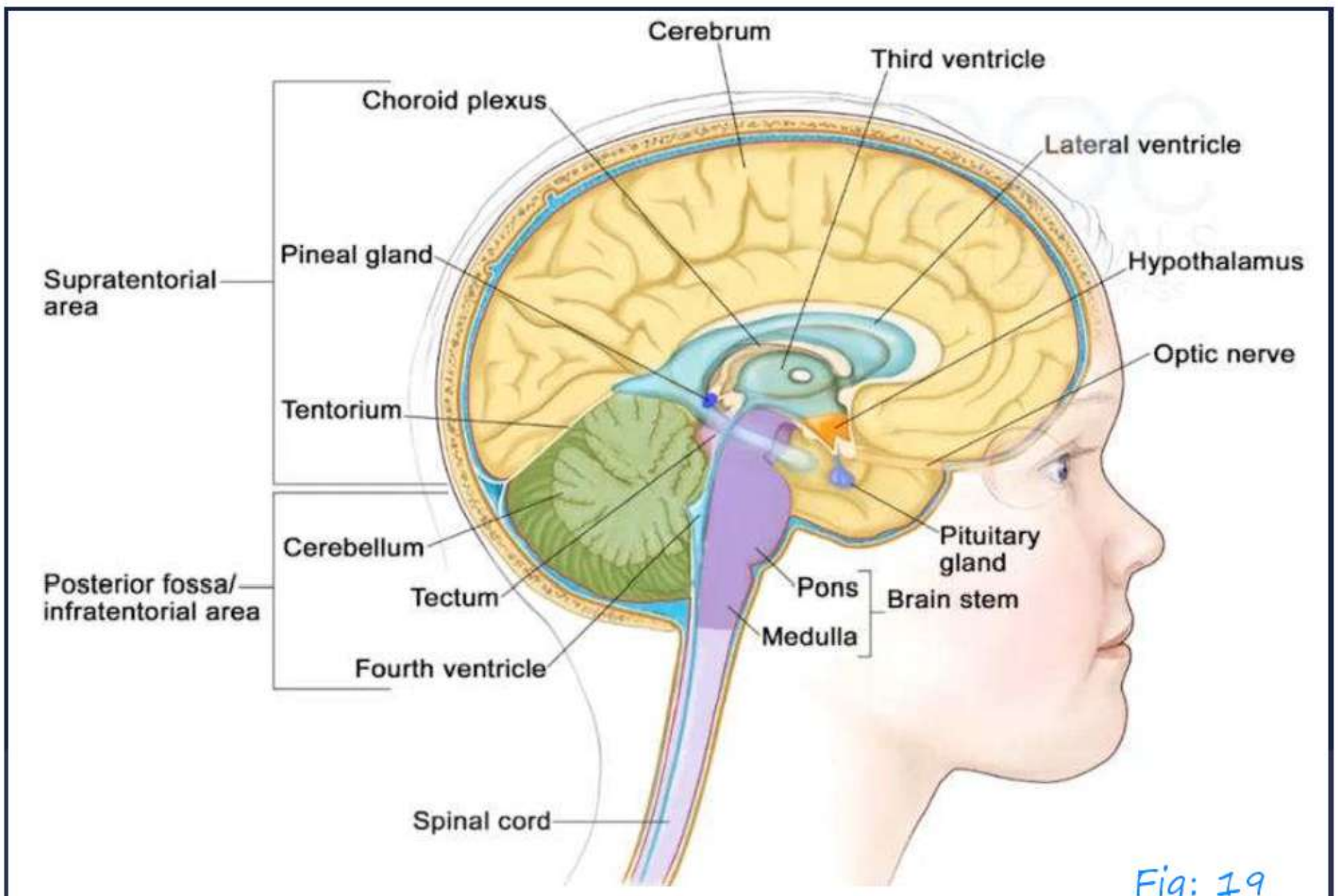

Fig: 19

Other brain tumors 01:38:07

1.Meningioma – 2nd most common tumor

Extra axial tumor → another → vestibular schwannoma

2.Malformations

↓

- Craniopharyngioma
- Dermoid cyst

3.Pituitary tumors

4.NET – Medulloblastoma

Gliomas – Astrocytoma

- Grade I astrocytoma – Most common in children
  - Curable
- Grade II – Young
  - Not curable by surgery

AfraTafreeh.com

- Grade III – Cytoreductive surgery
- Grade IV – High Grade
  - Bad prognosis
  - Most common – GBM

- Grade I– Pilocytic Astrocytoma

  Clinical features – mural nodule with no infiltration

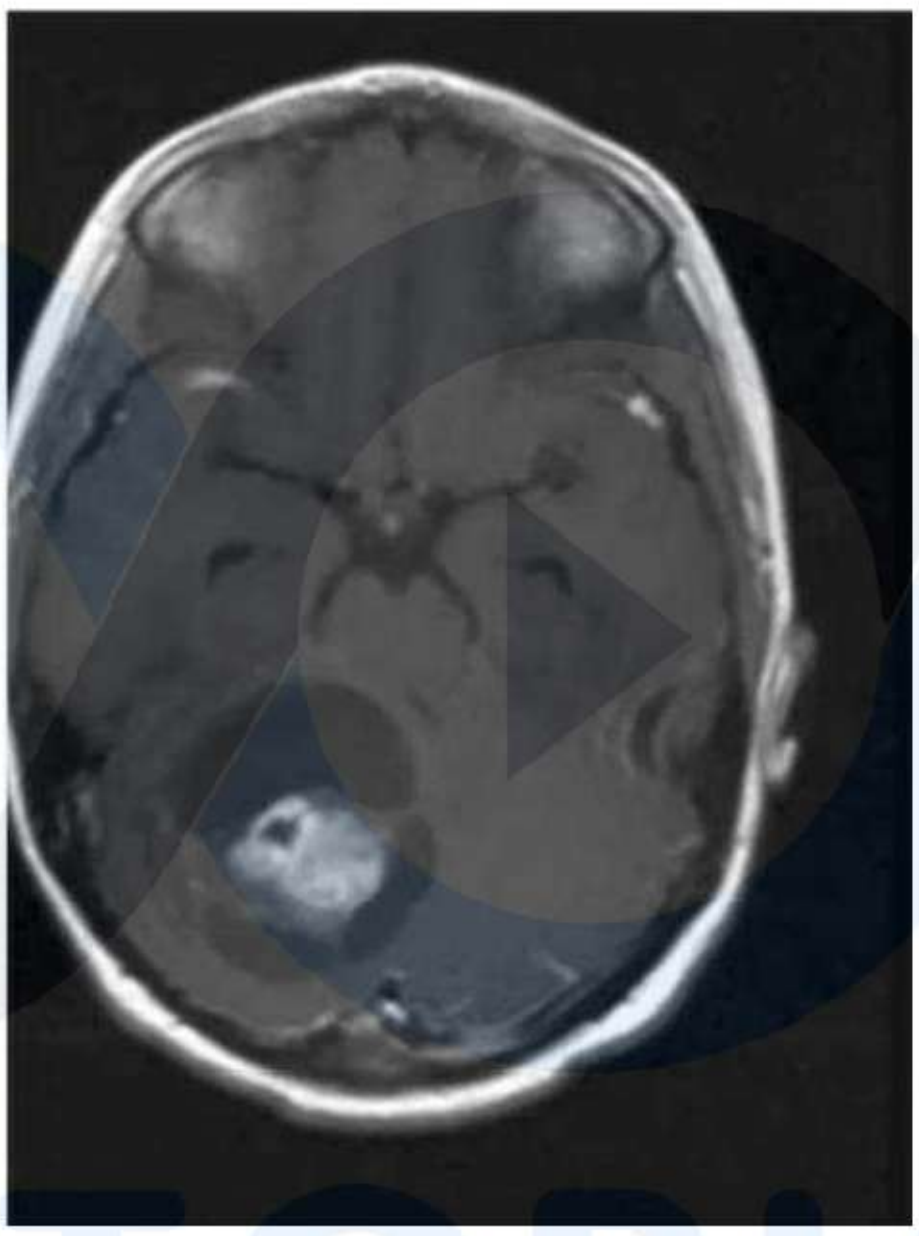

Fig: 20

MRI – IOC, Best prognosis

- Grade II – Also k/a diffuse astrocytoma

  patient and $CDKN_2A$ mutation

  ↓

  High grade

  - IOC – MRI
  - Treatment – Surgery followed by whole brain radio therapy (WERT)

- Grade III – Anaplastic astrocytoma

  Most common – frontal lobe

  Infiltrating margin ⊕

Bad prognosis

Surgery → WBRT

- Grade IV – More than 3 risk factors

Glioblastoma multiforme

HPE – Tumor necrosis ⊕

Pseudopalisade ⊕

MRI – Ring enhancing lesion

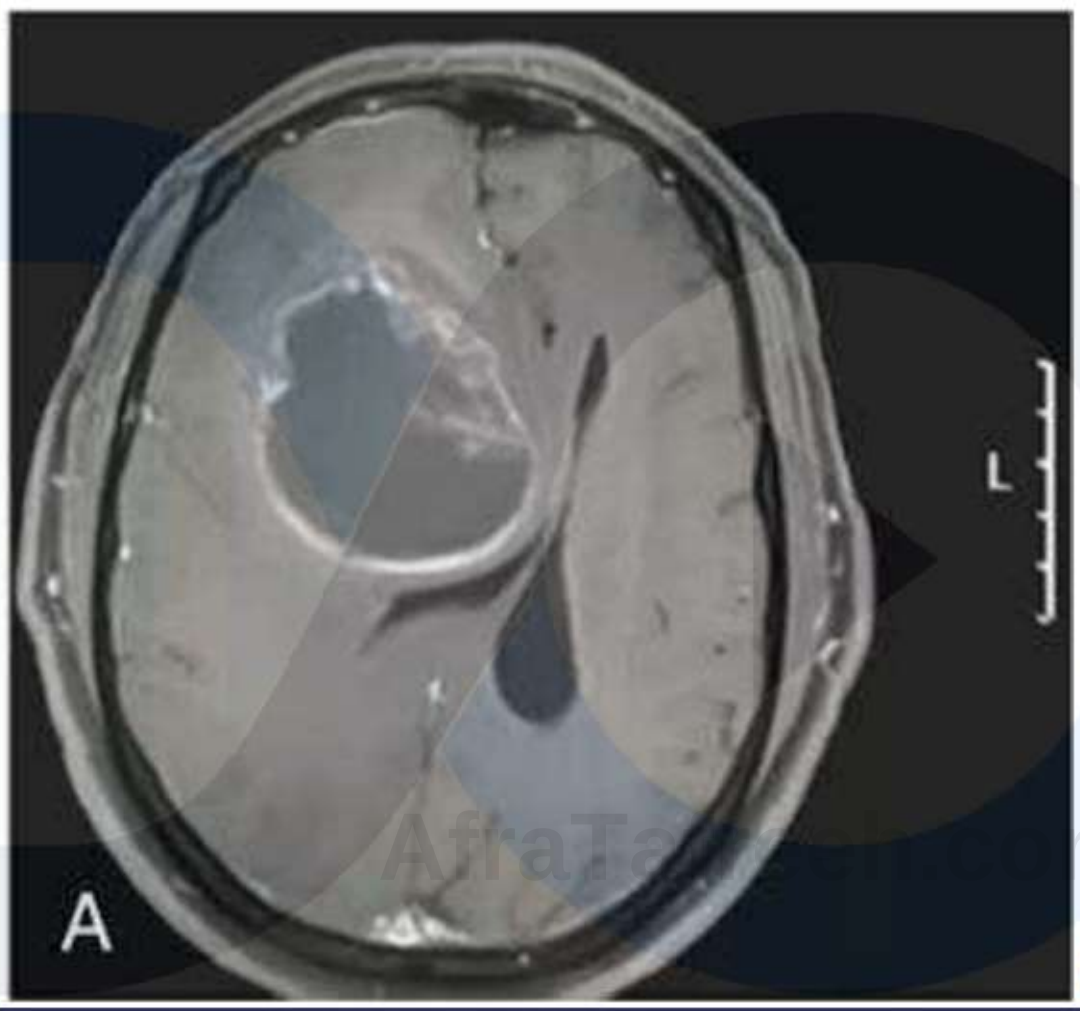

Fig: 21

Extends to opposite lobe → Butterfly tumor

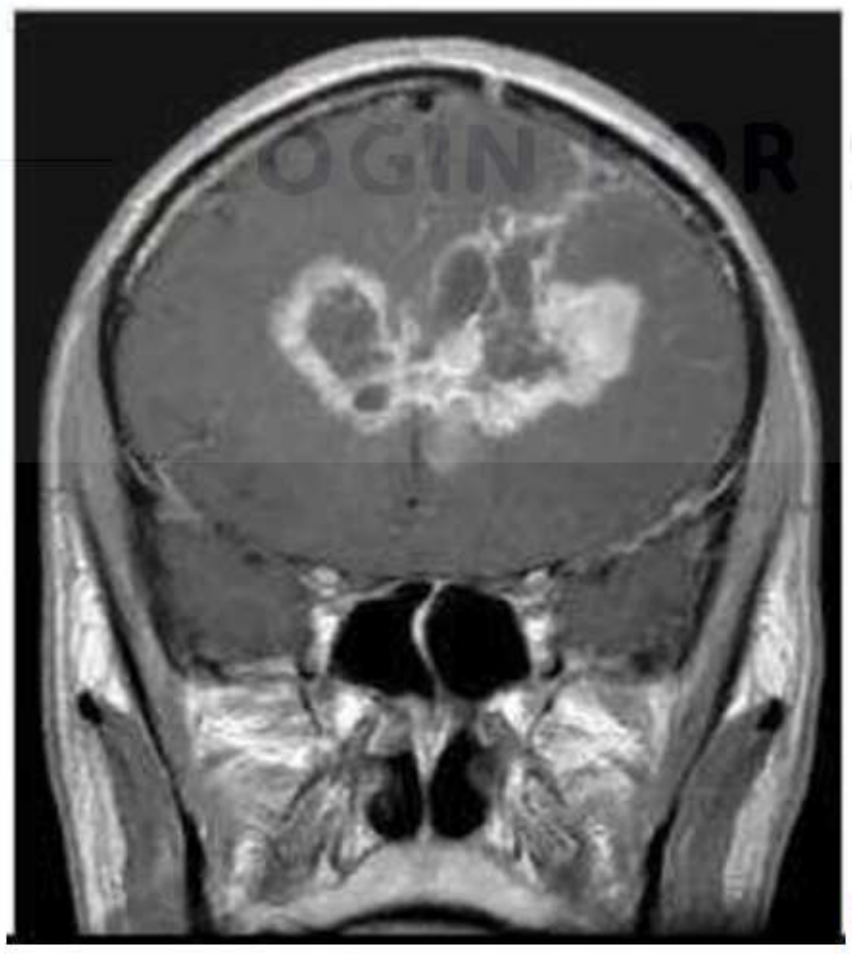

Fig: 22

Treatment – surgery + RT + Chemotherapy

↓

Temezolamide

TUTORIALS LOGIN FOR SUCCESS

AfraTafreeh.com

Most aggressive tumor

Bad prognosis

Oligodendroglioma 01:49:31

- Due to loss of heterozygosity on chromosome 19q
- Characteristic feature – calcifications ⊕⊕⊕

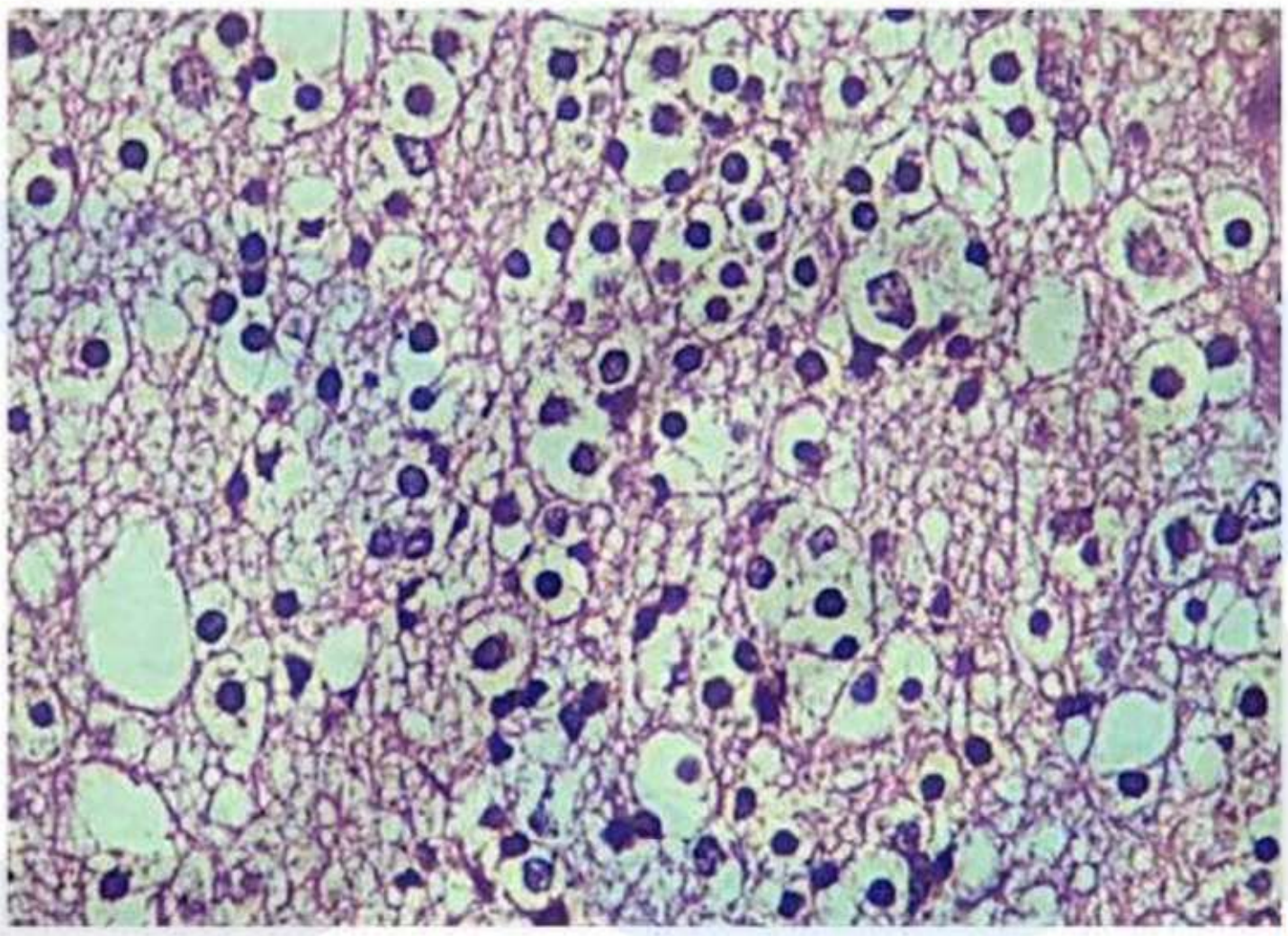

Fig: 21

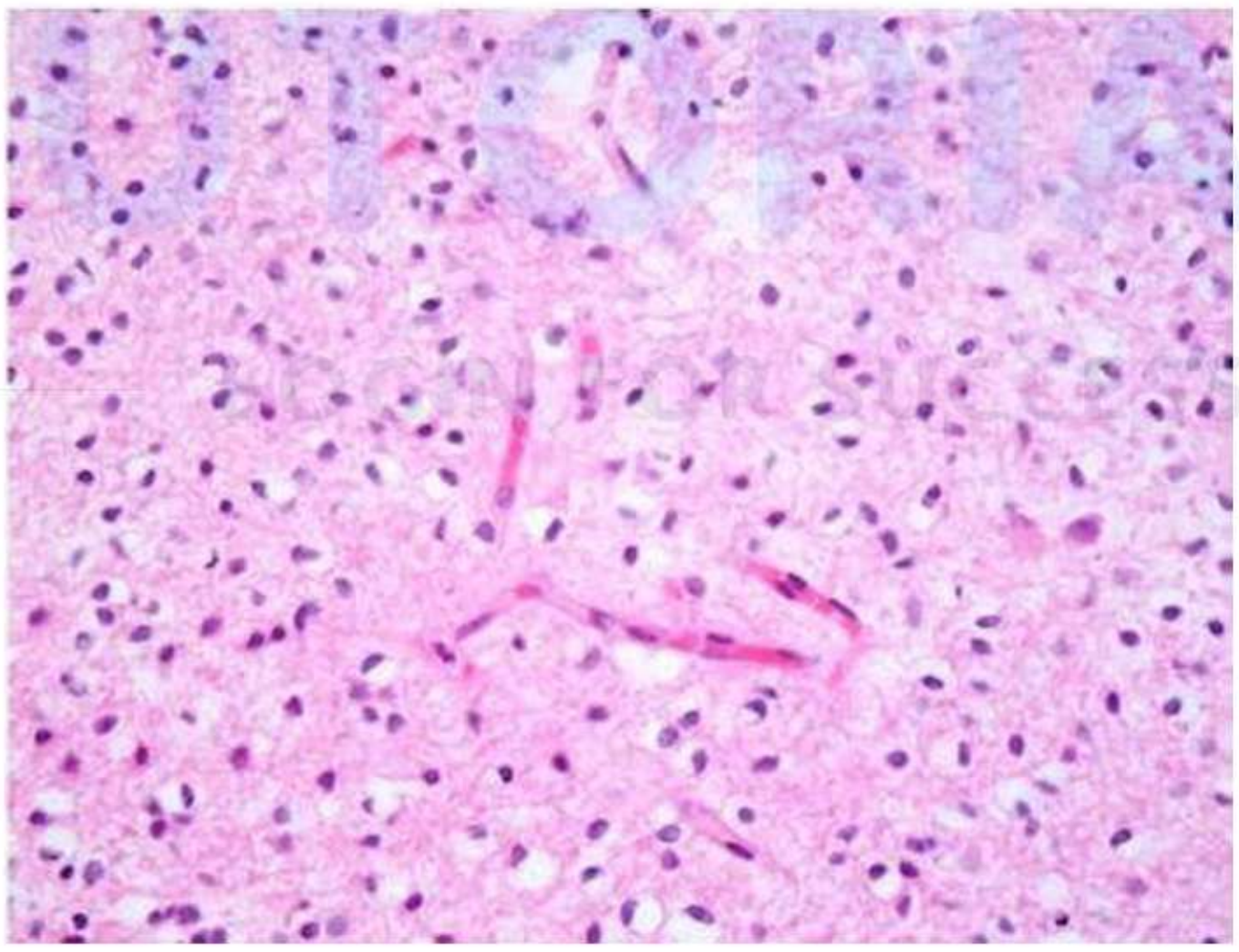

Fig: 22

- HPE – Fried egg appearance
- Blood vessels – Chicken wire blood vessels

  microcalcifications ⊕

Ependymoma 01:51:21

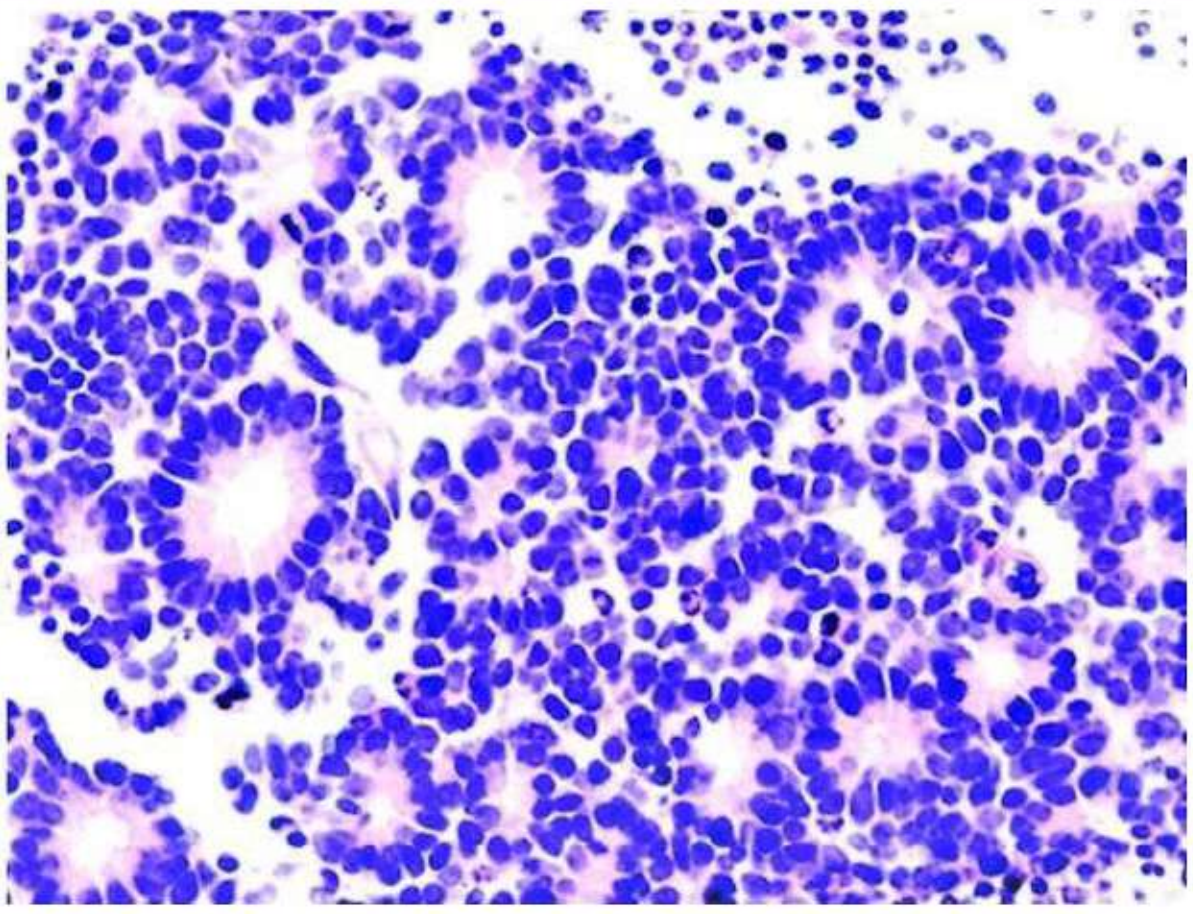

Fig: 23

- Presents with hydrocephalus
- Spread via CSF
- HPE – Pseudorosette
- Treatment – Surgery + craniospinal irradiation

AfraTafreeh.com

Medulloblastoma 01:53:46

- Type of neuroendocrine tumor of brain
- A/W turcot syndrome
- Seen in 3-4 years children
- Infratentorial tumor
- Most common location – cerebellum
- Drop mets to CSF
- Also spread to LN, liver, bones
- Most radiosensitive
- Treatment – Craniospinal irradiation advised

  Carmustine + vincristine → chemotherapy
- CHANG staging

  ↓

DX TUTORIALS LOOK FOR SUCCESS

AfraTafreeh.com

M_1 – CSF mets

M_2 – Intracranial tumor beyond primary

M_3 – Spreads to subarachnoid space

M_4 – CSF outside

Meningioma 01:58:00

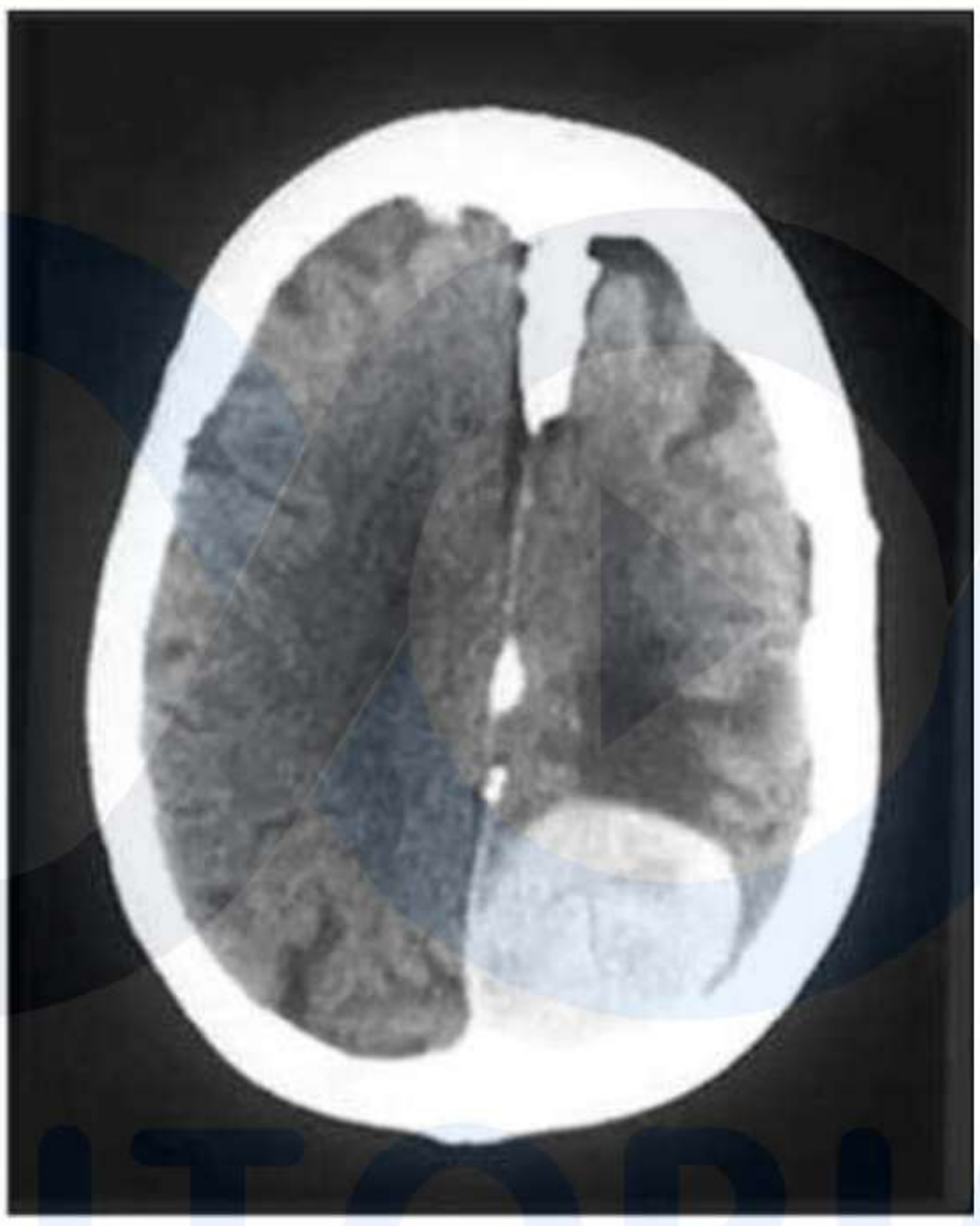

Fig: 22

- Calcifications ⊕
- Associated with NF-1, NF-2
- Most common in females
- Progesterone receptor positive – increases growth during pregnancy
- Clinical features – Compression features

↓

Headache

Seizures

FND

- CT scan – Calcifications ⊕

  Dural tail ⊕

  Sunray spicules ⊕

  Increased vascular markings

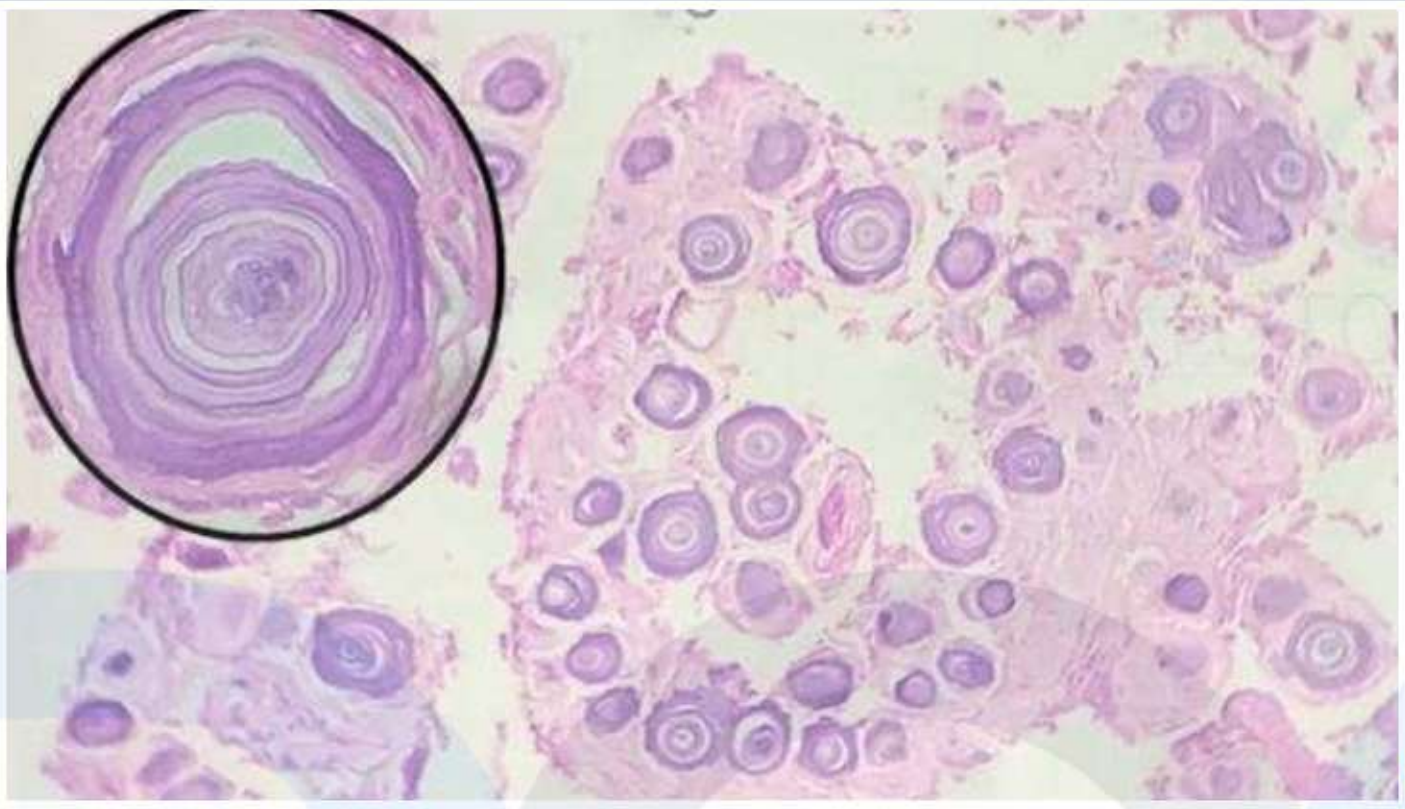

Fig: 23

- HPE

  ↓

  Psammoma bodies → concentric calcification

  ↓

  seen in

  1.Papillary Ca thyroid

  2.Papillary RCC

  3.Serous cystic neoplasm of ovary

  4.Meningioma

  5.Prolactinoma

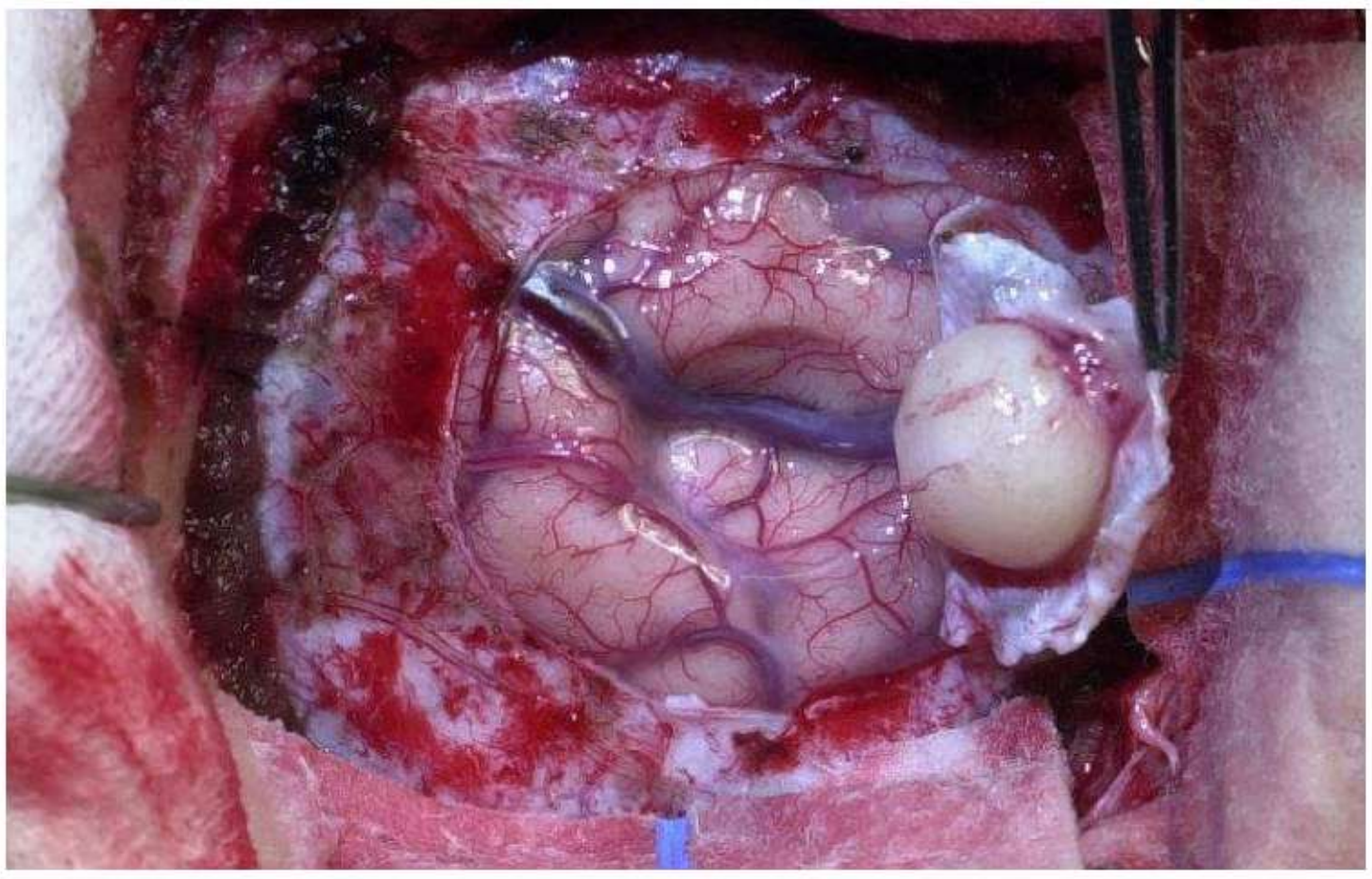

Fig: 24

AfraTafreeh.com
TUTORIALS
LOGIN FOR SUCCESS

AfraTafreeh.com

- Treatment – surgery – excellent prognosis

  Only problem – recurrence

  ↓

  Simpson Grading

  - I – Complete resection including dura/abnormal bone (<10%)
  - II – Duramater cauterized 15%
  - III – Duramater left as such 30%
  - IV – Incomplete resection ⎤ 80-100%
  - V – Biopsy ⎦

Craniopharyngioma 02:03:52

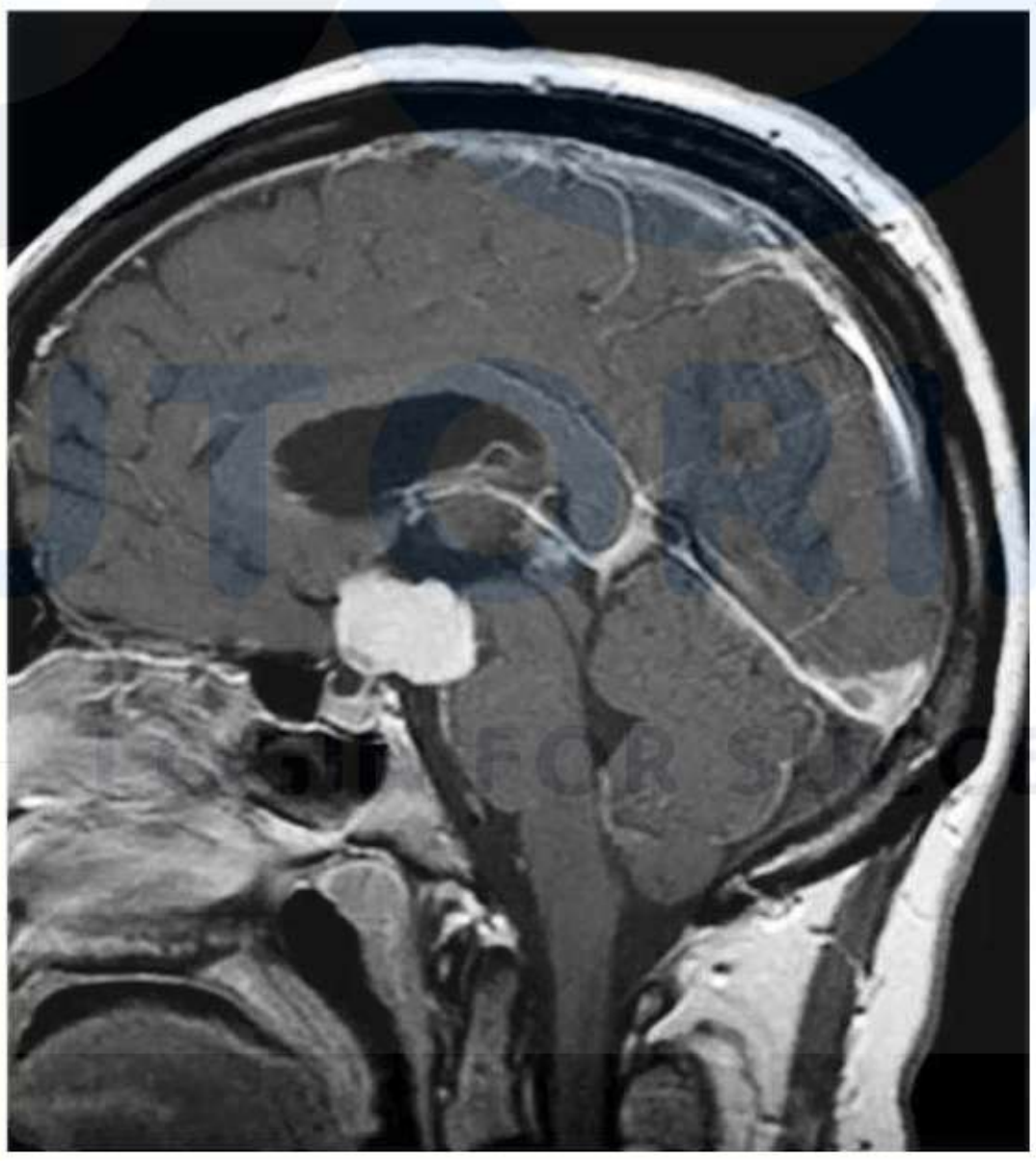

Fig: 25

- Suprasellar calcification

  ↓

  Children → craniopharyngioma

- Arises from Rathke's pouch
- Classical feature – Suprasellar calcification + polyuria

- Clinical features
  - Hypopituitarism
  - Diabetes insipidus
  - Growth retardation
  - Visual anomalies

  (Hypopituitarism, Diabetes insipidus, Growth retardation, Visual anomalies — Triad)

  ↓

  Bitemporal hemianopia
  - Weight gain
  - Sleep disturbance
- Treatment – Trans sphenoidal resection

Pituitary Adenomas 02:06:10

AfraTafreeh.com
TUTORIALS
LOGIN FOR SUCCESS

- Most common arise in anterior lobe.
- a/w MEN-1
- Most common cause of Hyperpituitarism – pituitary adenoma
- Most common clinical feature – Bitemporal hemianopia
- Present in 3rd/4th decode of life
- Male = Female
- Most common functioning pituitary adenoma – prolactinoma

  ↓

  Amenorrhea, Galactorrhea (females)

  Gynecomastia (males)
- Treatment – Transphenoidal excision
- Most common cause suprasellar mass

AfraTafreeh.com

- Children – craniopharyngioma
- Adults – Pituitary adenoma

Spinal Tumors 02:08:46

- Most common tumor – mets → Intradural & extramedullary
- Most common 1° spinal tumor – Nerve sheath tumor
- Most common intramedullary tumor – Astrocytoma

Neural tube defects 02:11:30

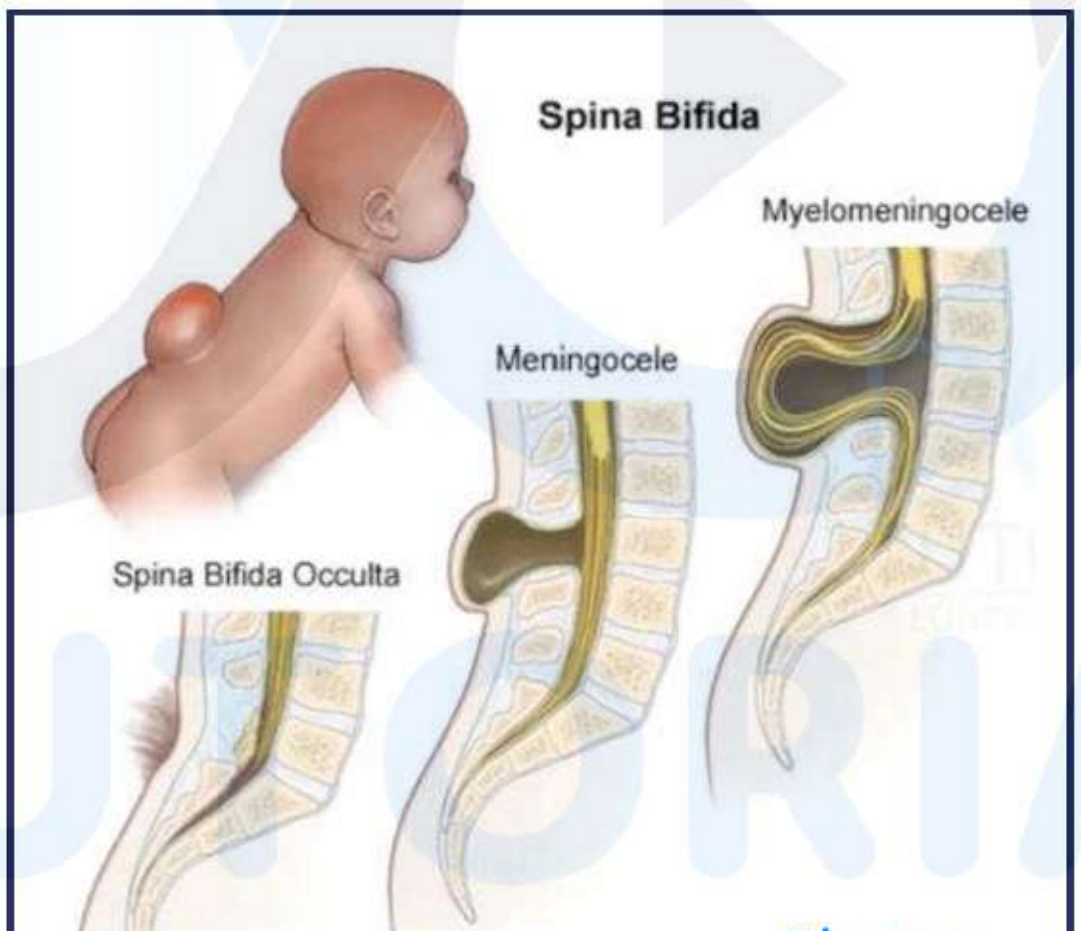

Fig: 26

- Genetic/Folic acid deficiency
- Drugs
  - Trimethoprin
  - Pheynytoin
  - Phenobarbitone
  - Sodium valproate
- Defect which happens in the vertebra
- Divided into

Spina Bifida occulta	Spinal Bifida Aperta
↓ No gap	↓ Gap ⊕ ↓ - Only durameter/arachnoid membrane coming ↓ Meningocele - Durameter, arachnoid & spinal cord & meningomyelocele

AfraTafreeh.com

Spina bifida occulta

- Spina bifida occulta

  ↓

  - No neurological abnormality
  - Only tuft of hair seen
  - IOC – X-ray

Fig: 27

AfraTafreeh.com

Meningocele

- Associated with tethering of spinal cord
- Transillumination ⊕
- Fluctuation ⊕
- Covered by skin
- If no skin covering → continuous CSF leak ⊕
- Most common site – lumbar
- X-ray – open spine vertebra

Fig: 28

Meningomyelocele

- Most common lumbosacral region
- Has → Bladder incontinence
  Bowel incontinence
  Paraplegia
- If a/w thoracic region → Hydrocephalus ⊕
  FND ⊕

Fig: 29

Arnold Chiari Malformation 02:16:43

- Cerebellar tonsil descends down
- Type II – Meningomyelocele
  - Treatment – 24-48 hrs repair done

    Myofascial closure

    25% mortality

    Low IQ

    Bladder problems

    Meninges will have high latex allergy (60%)

    ↓

    Latex gloves C/I

- Cerebellar tonsil herniation through foramen magnum

  ↓

  Herniates > 5mm – chiari malformation

AfraTafreeh.com

Type – I	Type – II
↓ Tonsil descent alone ↓ Occipital headache Syringomyelia Numbness ⊕	↓ Tonsil des + meningomyelocele Also associated with - Hydrocephalus - Syringomyelia

Fig: 30

↓

Cystic expansion of IV ventricle → Dandy walker Malformation

↓

Cerebellar hypoplasia

- Clinical features – Microcephaly
  Hydrocephalus
  Ataxia
- Triad – Enlarged posterior fossa
  Rotation of vermis
  Hypoplasia of vermis

TUTORIALS LOGIN FOR SUCCESS

Herniation of Brain 02:22:19

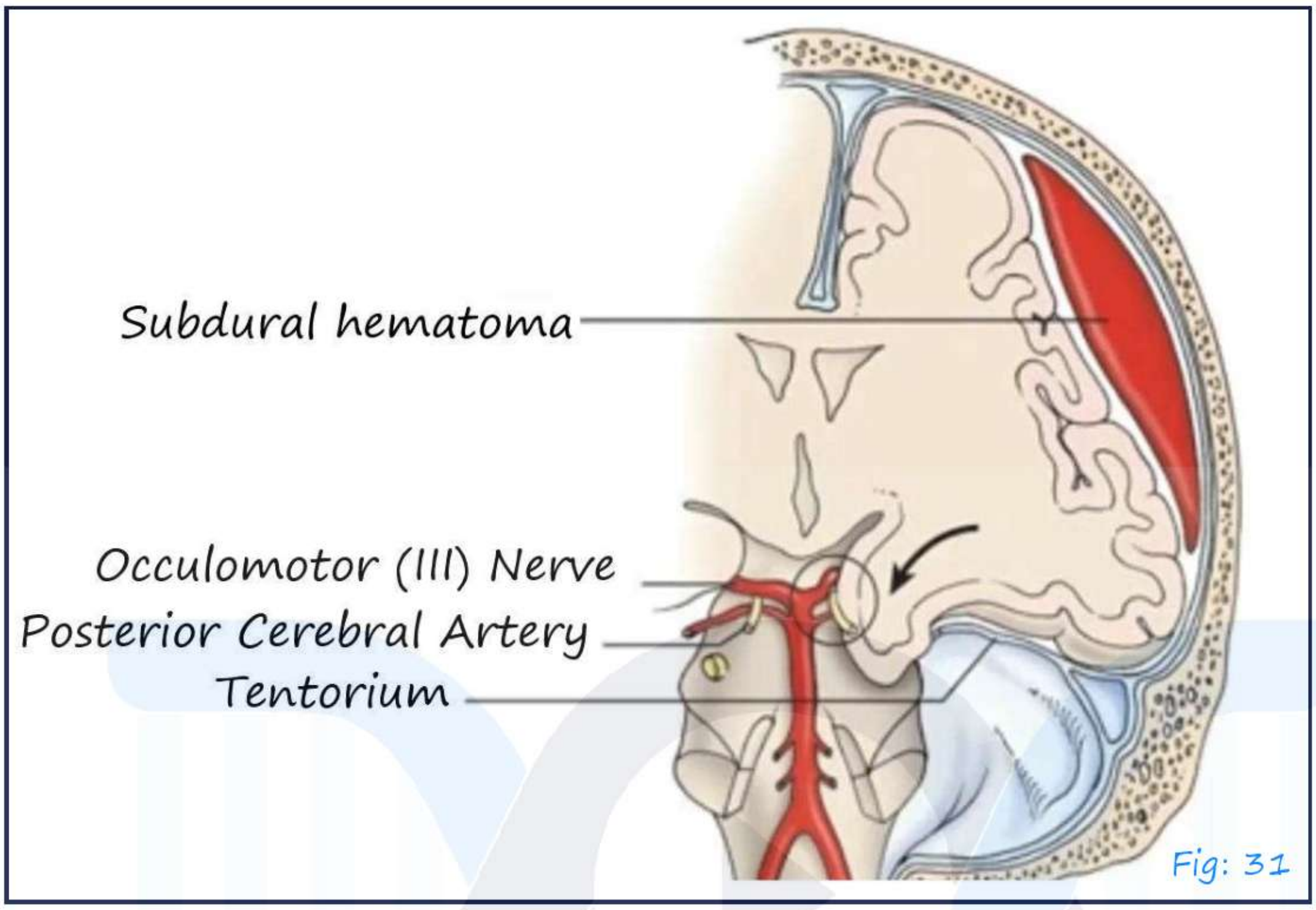

Fig: 31

- Hematoma of brain → compress uncus of temporal lobe

↓

compression of I/L occulomotor

↓

I/L fixed dilated pupil

C/L hemiplegia

- Corticospinal tract of opposite side compressed

↓

I/L hemiplegia → Kernohan Notch Phenomenon

AfraTafreeh.com
TUTORIALS
LOGIN FOR SUCCESS

AfraTafreeh.com

Abnormal Skull 02:25:02

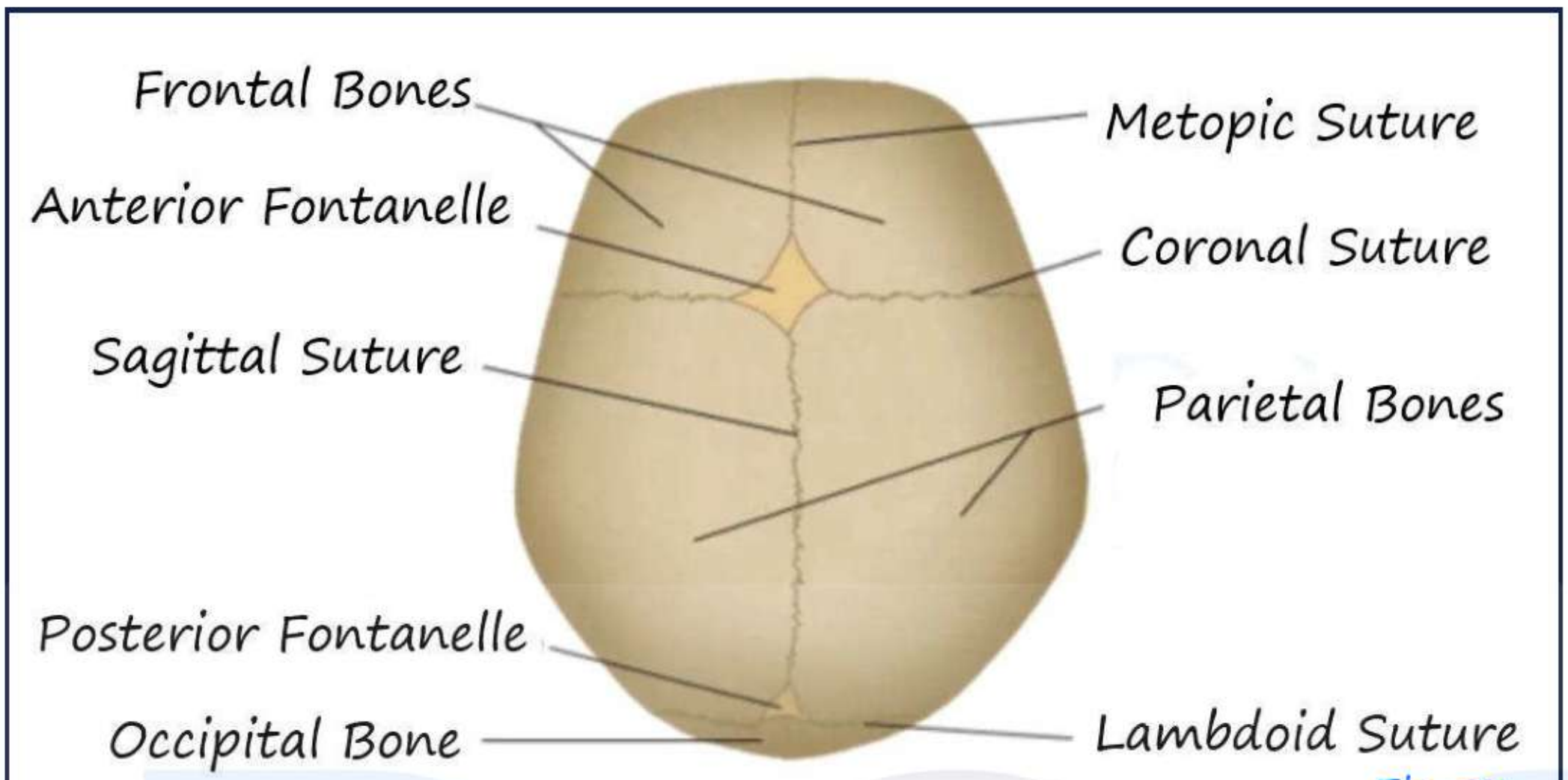

Fig: 32

- Sagital suture fused → Scaphocephaly → Boat shaped
- Coronal suture fused → Brachycephaly → Broad flat
- One side coronal fused + One side lamdoid → plagiocephaly → Asymmetric
- Metopic suture fused → Trigonocephaly → pointed forehead

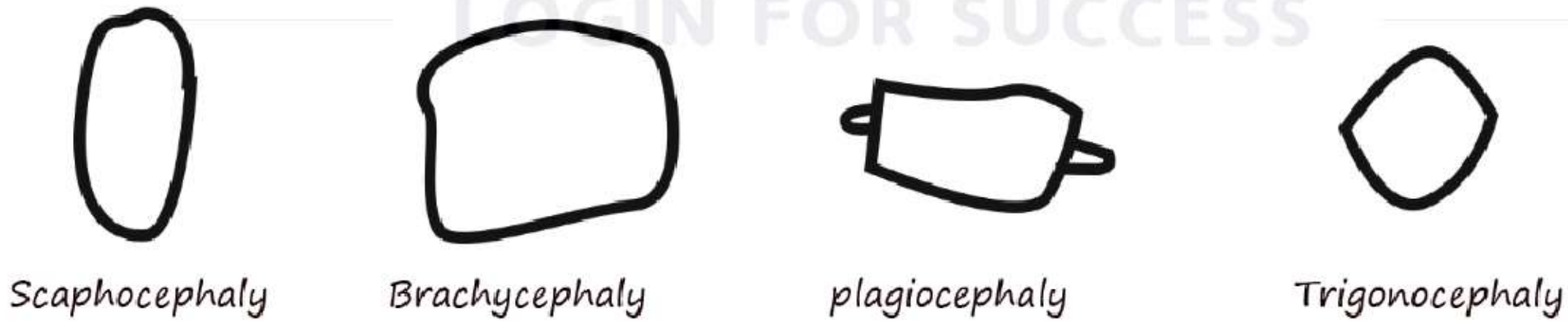

TUTORIALS
LOGIN FOR SUCCESS

Epilepsy surgery 02:25:02

- Complex partial seizures usually develop from temporal lobe

  ↓

  Intra Op grid electrode placed

  ↓

  Area showing high signals removed
- WADA test – Detect which lobe is dominant by injecting sodium amytal
- Mc surgery: anterior temporal lobectomy

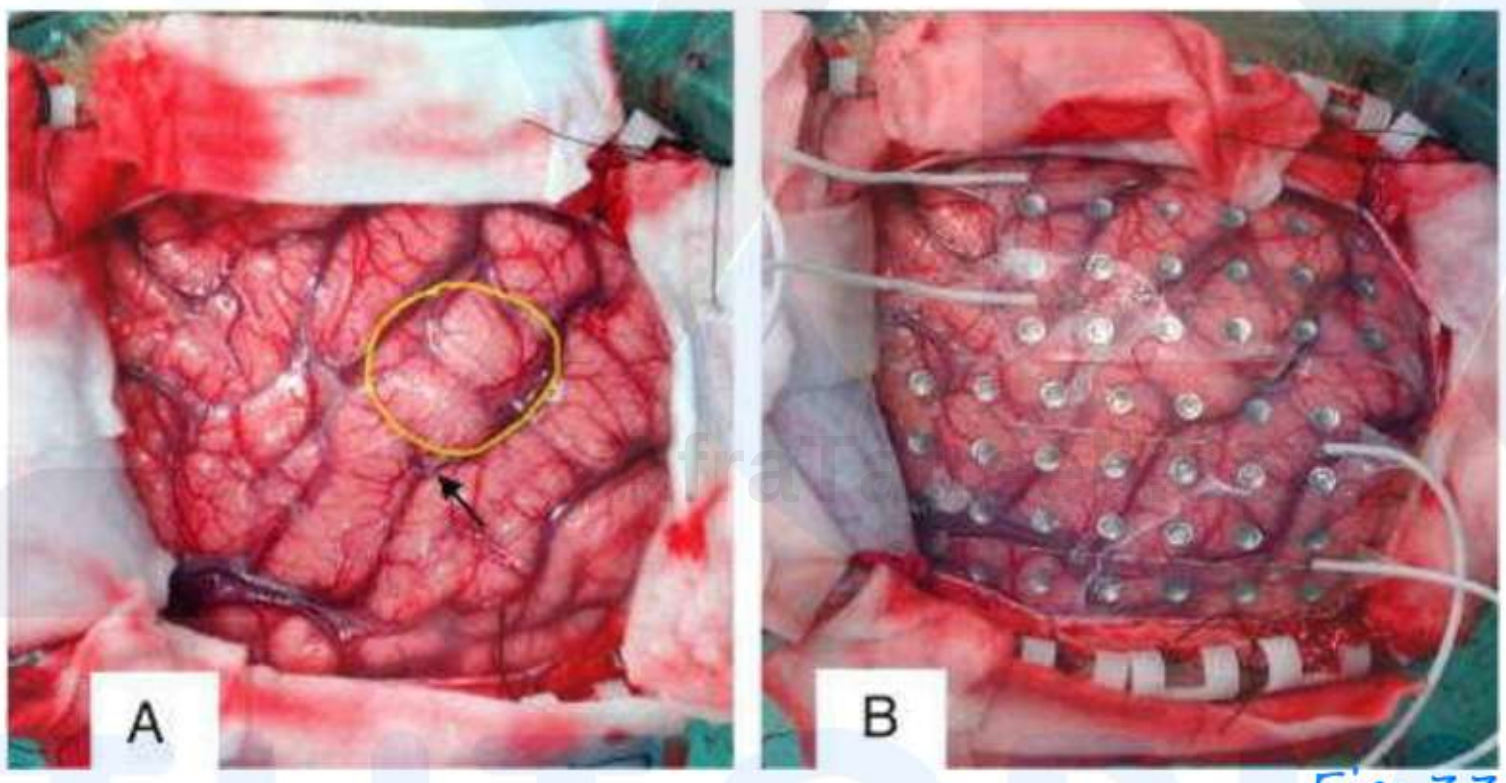

Fig: 33

TUTORIALS
LOGIN FOR SUCCESS

AfraTafreeh.com

BASICS OF TRANSPLANT

Introduction 00:00:20

- August 13th is – organ donation day every year
- 1st transplant of
  - Kidney – Murray (1954)
  - Liver – starzl (1963)
  - Heart – Barnard
  - Pancreas – Kelly & Lillehei

- Person who is going receive organ – Recipient
- Person who is going to donate organ – Donor
- Organ which is going to be transplanted – Graft
- Done by Transplant surgeon

Graft

- **Allograft** → Same species
- **Autograft** → Same individual
- **Xenograft** → Different species → **PIGS**
- **Isograft** → Identical twins

Orthotropic graft

- Transplanted organ placed in same place of affected organ

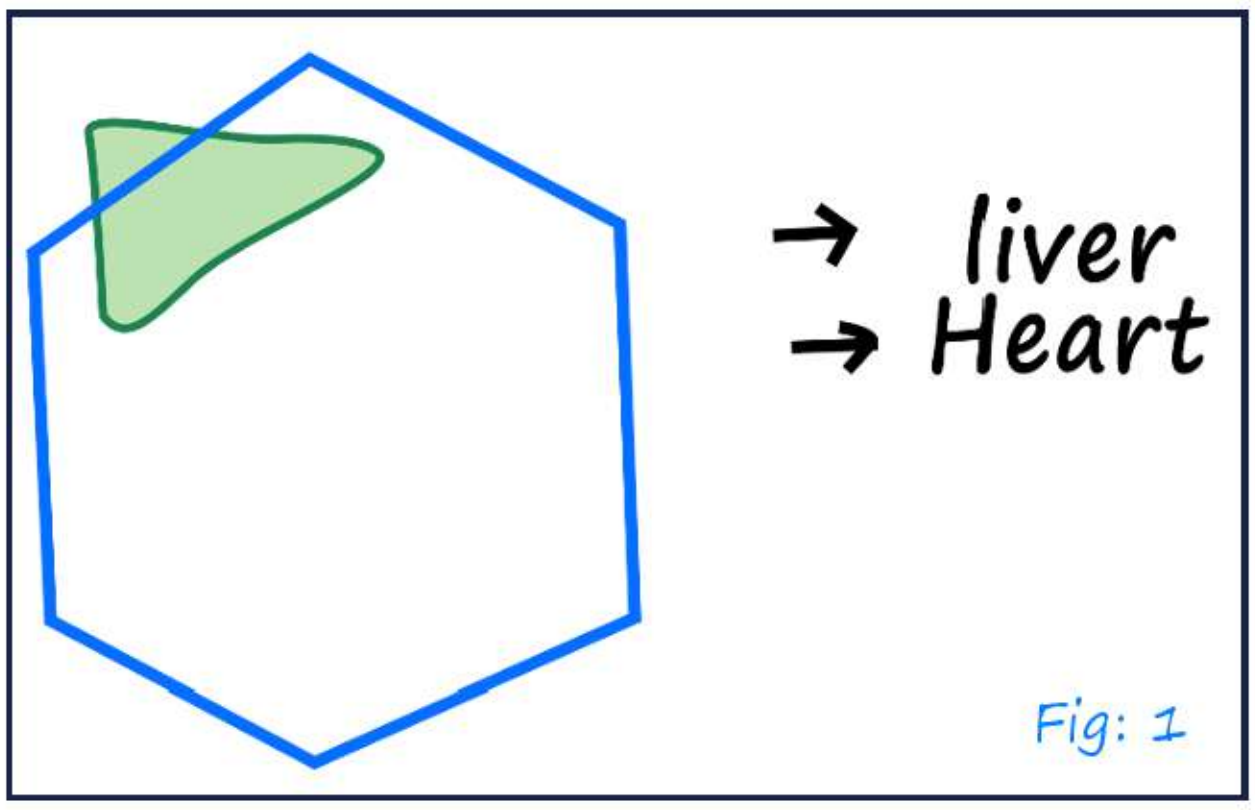

Fig: 1

Heterotrophic graft

- Transplanted organ placed in non-anatomical position of that organ
- Example: Kidney
  - Pancreas

HLA matching 00:08:57

AfraTafreeh.com

- Major histocompatibility complex (MHC)

Class I → HLA A, B

Class II → HLA-DR

TUTORIALS
LOGIN FOR SUCCESS

- HLA matching not needed for liver, cornea, not possible for heart

AfraTafreeh.com

Donor 00:11:42

Donor

- **Live**
  - ↓ Kidney
  - Heart
- **Cadaveric**
  - **Brain dead**
    - ↓ Heart beating ⊕
  - **Donation after circulatory death**
    - ↓ Heart not beating
- **Xenograft**
  - ↓ Pig (heart valves)

Contra indications for organ donation 00:13:40

- HIV
- Creutzfeldt Jacob disease
- Malignancy (< 5years)
  - ↓
  - Skin cancer (SCC, BCC)
  - Ca in situ uterus
  - Brain tumors
- HBV
- Sepsis
- 'O' group → O, A, B, AB
- 'A' group → A, AB
- 'B' group → B, AB
- 'AB' group → AB
- In organ donation, **Rh testing not done**

TUTORIALS
LOGIN FOR SUCCESS

Brain dead Donor 00:08:57

- Heart is beating
- To confirm brain death

↓

UK criteria – 2 doctors (one-consultant, none-transplant surgery)

- Look for

i. Cranial refers – CNS reflexes absent

ii. Motor response – No response

iii. Spontaneous breathing

↓

Checked by raising $PaCO_2$ > 60mmHg

AfraTafreeh.com

DCD Donor 00:19:12

- Maastricht classification
  - Cat 1: - Dead at arrival
  - 2: Dead during resuscitation
  - 3: Brain dead ⎤ Controlled donors
  - 4: Died ⎦
  - 5: Dead in ward
- Uncontrolled donors- 1, 2, 5

Donor age and criteria 00:22:32

- Kidney: - 2yrs to no upper limit
- Liver: - No age limit
- Heart: - 1-65 years

TUTORIALS LOGIN FOR SUCCESS

AfraTafreeh.com

- Lungs: - 5-65 years
- Pancreas: - 10-60 years

Extended donor criteria

Kidney	**Liver**
1.> 60 years age	1.Steatosis
2.50-59 years of age	2.Age > 65 years
- CVA causes death	3.Hep. C positive
- S. Creatinine > 15mg/dL	4.HBV core Ag positive
- H/O HTN	

Scenario 00:26:22

- In OT, anesthetist stops the circuit, the moment heart stops, organs are retrieved by various transplant surgeon
- Cold ischemic solution will be put into the organ and organ will be taken in ice bag to the recipient

TUTORIALS LOGIN FOR SUCCESS

Warm Ischemic time

- Time from heart beat stops to liver put in cord ischemic
- Should be < 30 minutes

Cold Ischemic Time

- Time from organ in cold ischemic solution to reperfusion of organ in recipient
- Cold ischemic solution – University of Wisconin solution (Eurocollins)

↓

1.Lactobionate – Prevents cell swelling
2.Adenosine – Energy
3.Allopurinol – Free radical scavenger
4.Glutathione – Anti oxidant

Cold Ischemic time

Organ	Optimum time	Maximum time
Kidney	< 18 hours	36 hours
Liver	< 12 hours	18 hours
Heart	< 3 hours	6 hours
Pancreas	< 10 hours	18 hours
Lungs	< 3 hours	8 hours
Small intestine	< 4 hours	6 hours

Rejection 00:34:18

Hyper acute	Acute	Chronic
Few mins-days Preformed Ab's ABO incompatibility	T cell mediated (1-6 months) ↓	• > 6 months

AfraTafreeh.com

HLA mismatching ↓ GRAFT THORMBOSIS ↓ Gangrene	Immunosuppressants ↓ Bx: Lymphocytic infiltration	• Most common causes of graft failure ↓ Fibrotic T & B lymphocytes Non immune

Chronic Rejection 00:37:26

- Kidney → Glomerular sclerosis
- Liver → VBD syndrome
- Heart → Accelerated coronary artery disease
- Pancreas → Acinar loss
- Lungs → Obliterative bronchiolitis

Risk factors for chronic rejection

- Previous episode of acute rejection
- Poor HLA matching
- Prolonged cold ischemic time
- Increase blood lipids
- Inadequate immunosuppression

Immunosuppression 00:40:30

- **Immunosuppression given to prevent graft rejection**

Immunosuppression

Induction → Started immunomodulator

Maintenance → Continued for lifetime

i. Calcineurin inhibitors: Cyclosporine
- Tacrolimus

ii. Anti-proliferative agents:
- Azathioprine
- Mercaptopurine
- Mycophenolate mofetil

iii. Steroids: -

iv. MTOR inhibitor – mammalian target of Rapamycin
↓
Sirolimus
Everolimus

AfraTafreeh.com

TUTORIALS

LOGIN FOR SUCCESS

Monoclonal Antibodies 00:43:18

- Muromonab – anti CD_3
- Basiliximab – anti CD_{25}
- Rituximab – anti CD_{20}

Complications of Immunosuppressants 00:44:18

1. Infections: - recipient reactivation: - CMV pneumonitis 6-12 weeks

AfraTafreeh.com

2.Malignancy: - Most common: SCC > PTLD

- HHV 8 – kaposi sarcoma
- HBV - HCC
- HCV
- HPV – Cancer cervix

3.Non immune mediated

- Calcineurin inhibitors – Nephropathy
- NODAT – New onset DM after transplant (30% < 2years)

Complication related MCQs 00:47:20

1.Most common complication due to immunosuppression – infection

2.Most common infection: - CMV

3.Most common parasitic infection: Pneumocystis carnii

- Polyoma BK virus can cause ureteric stricture in post renal transplant patient

4.Most common malignancy: - Squamous cell cancer.

ADVANCE TRANSPLANT

Liver transplant 00:00:26

- Most common indication of liver transplant (adults) – cirrhosis
  ↓
  HCV>HBV
- Most common indication in children – EHBA
- Most common metabolic disorder: α_1-AT deficiency
- Most common indication for emergency transplant – Acute fulminant liver failure caused by paracetamol over dosage
- 1st liver transplant – Starzl in 1963
- 1st split liver transplant – Pichlmayr

AlfaTafreen.com



Fig: 1

- 1st live donor transplant – Tanaka in Japan.

Criterias for liver transplant 00:04:16

- Modified child Pugh score → Bilirubin
  Albumin
  Ascites
  PT

AfraTafreeh.com

Encephalopathy

Child C > Child B

- MELD (Model for End Liver Disease)
  - Logarithmic score of – creatinine
    bilirubin
    INR

  score >35 – priority
  < 15 – waiting list

- MELD exception
  - HCC
  - Amyloidosis
  - Hepatopulmonary syndrome
  - Portopulmonary syndrome

- **King's college criteria**

Liver transplant in acute fulminant liver failure

Paracetamol induced

↓

- pH<7.30 (irrespective of encephalopathy)

(or)

- PT > 100 sec + S. creatinine is >300 μmol/L +

Non paracetamol

↓

- PT > 100 seconds

(or)

Any 3 of the below

↓

- Age <10, > 40 yrs
- Etiology – non A/non B liver damage due to Halothane/Idiosyncratic drugs
- >7 days of jaundice before encephalopathy

Grade 3 / 4 encephalopathy
- S. bilirubin ≥ 300 μmol/L
- PT > 50 seconds

- Milan criteria
  - HCC in cirrhotic liver
  - Indications → size of lesion < 5cm
    > 3 lesions (1-3 cm)
    No extrahepatic spread

Grafts in liver

Orthotopic ↓
- Diseased liver is removed and new liver placed
- Most common

Heterotopic ↓
- New liver is placed beneath/adjacent to damaged liver
- Acute fulminant liver failure

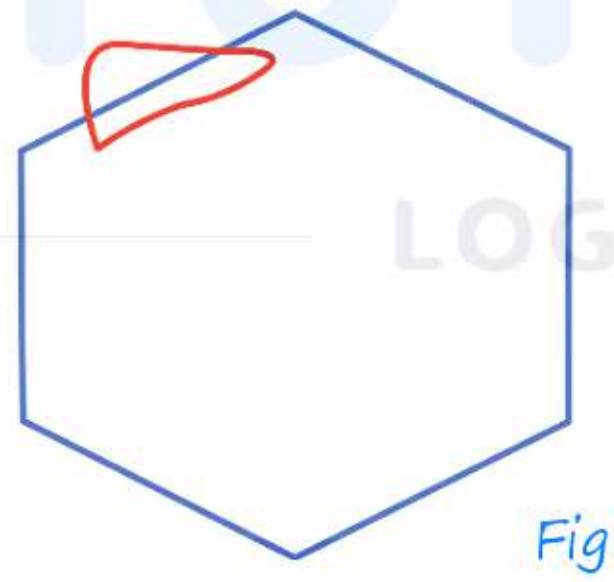

Fig: 2

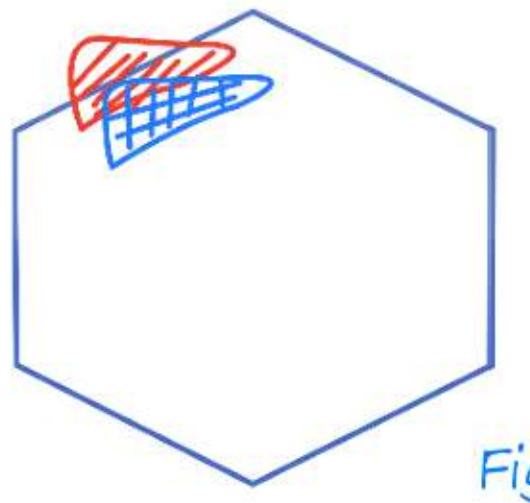

Fig: 3

AfraTafreeh.com
TUTORIALS
LOGIN FOR SUCCESS

AfraTafreeh.com

Types of liver transplant 00:16:16

1. Auxiliary T_x – Indication – Acute fulminant liver failure

↓

- Cut and remove ½ of the liver and ½ of new liver is kept.

↓

Auxiliary partial orthotopic transplant

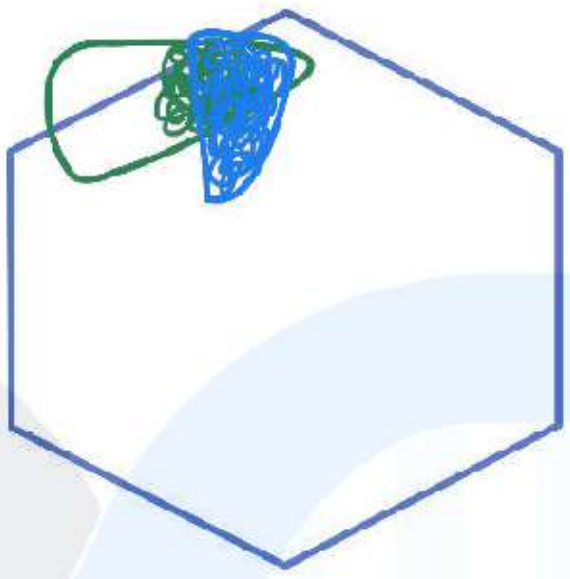

↓

Once diseased liver recovers

↓

Stop immunosuppression/can remove transplanted liver.

- New liver placed below diseased liver

↓

Auxiliary heterotopic transplant

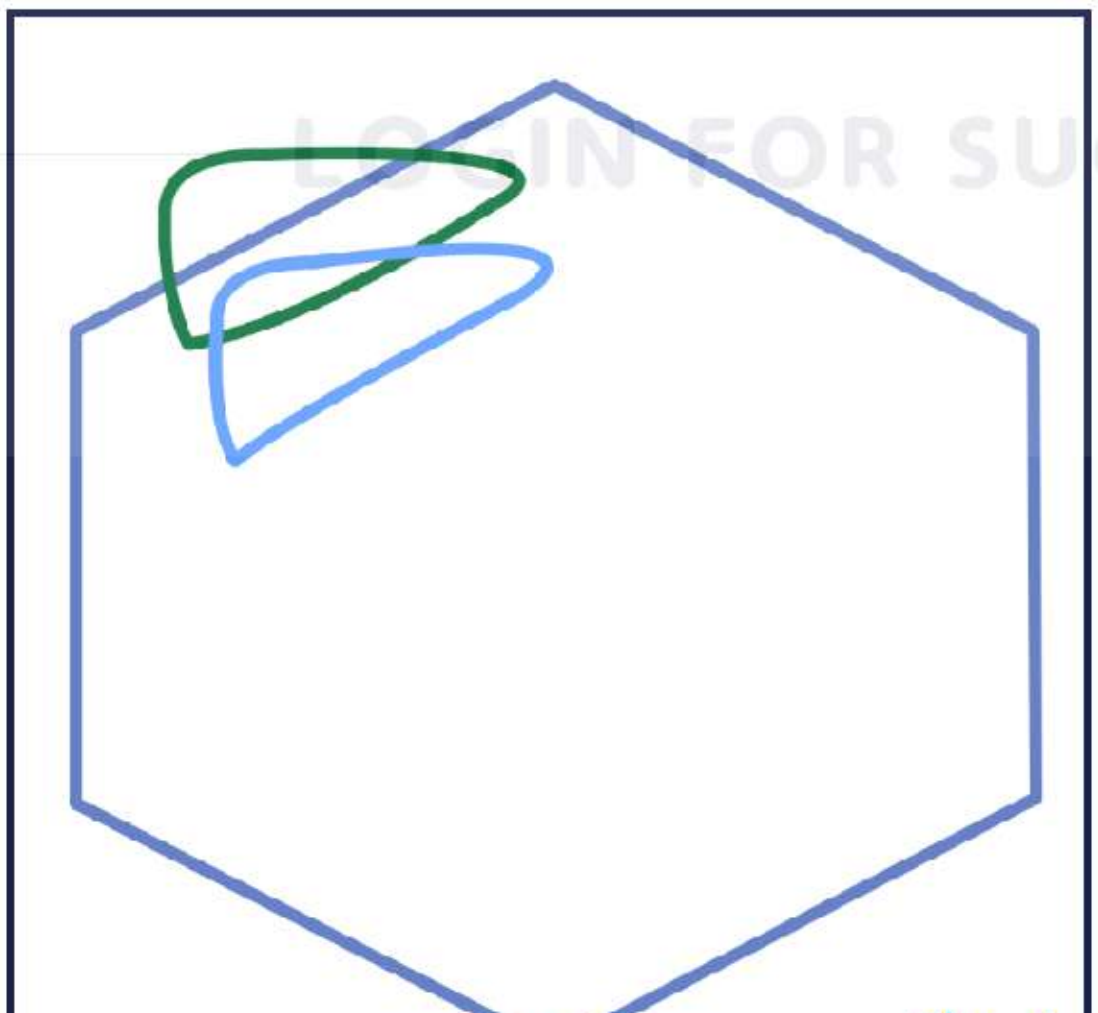

Fig: 4

2.Domino Liver Transplant

- Cadaveric liver is given to amyloidotic liver patient

  ↓

  Amyloidotic liver is transplanted to those whose MELD score >35

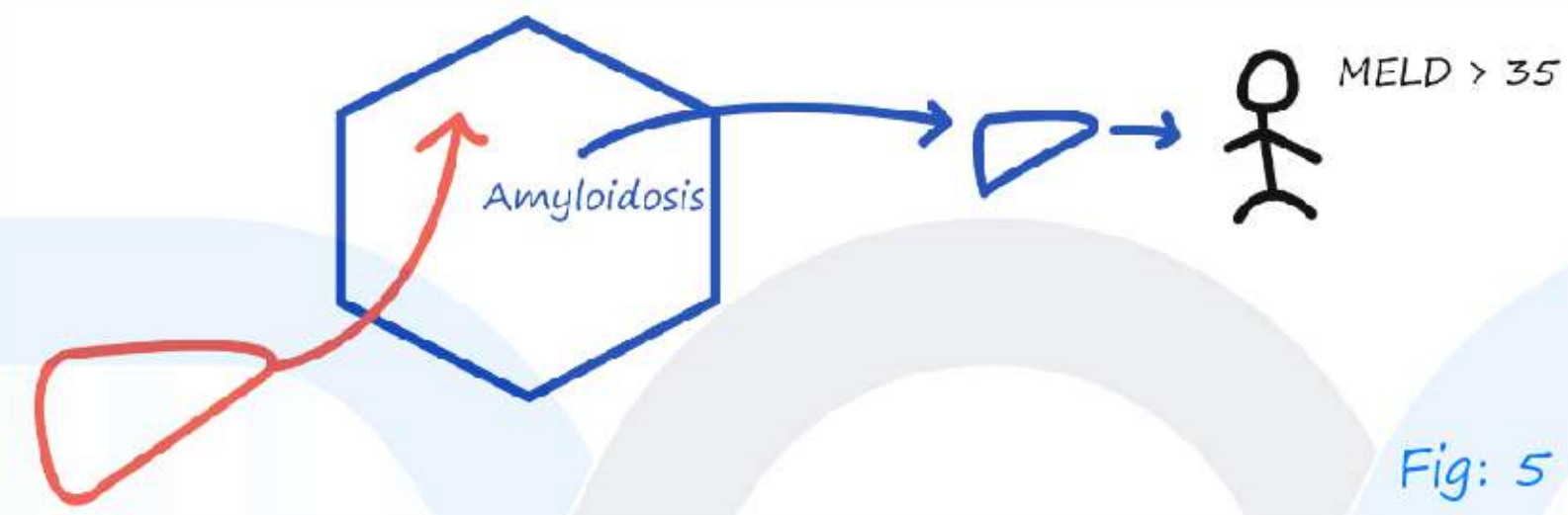

Fig: 5

3.Split liver transplant

- Segments 5,6,7,8 can be given to adults.
- Segments 2,3 for children.

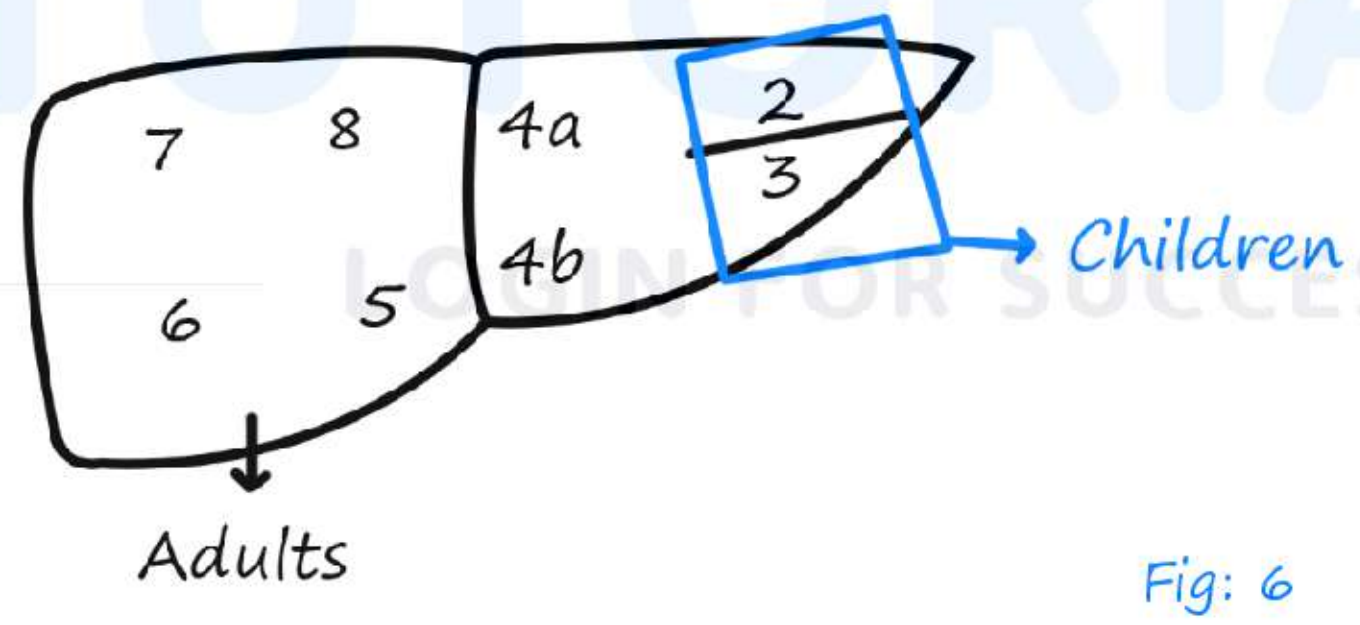

Fig: 6

AnaTafseer.com
TUTORIALS
LOGIN FOR SUCCESS

AfraTafreeh.com

4.Live donor –

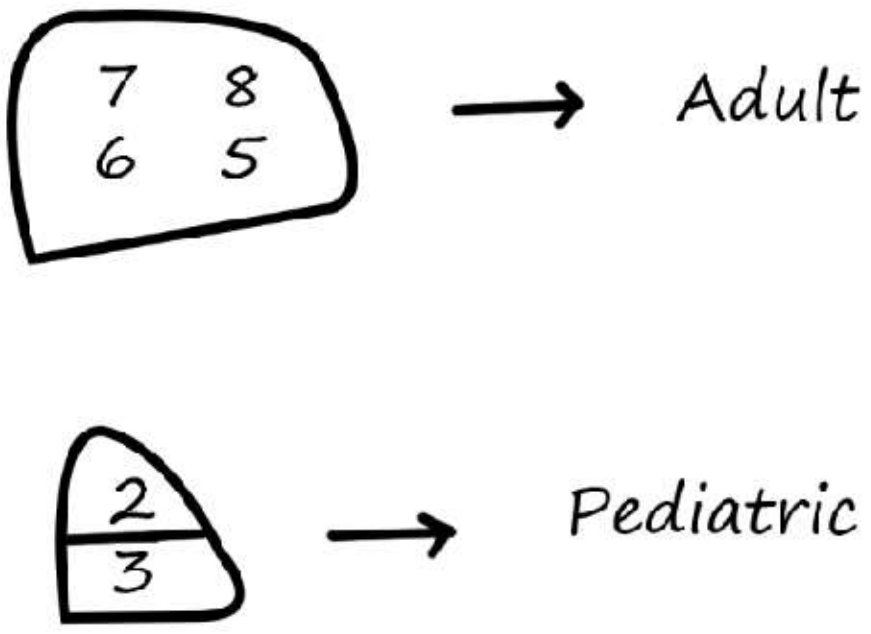

Fig: 7

Steps in orthotopic liver transplant 00:22:33

- Cadaveric liver contains
  - IVC
  - Portal vein
  - Hepatic a
  - Bile duct

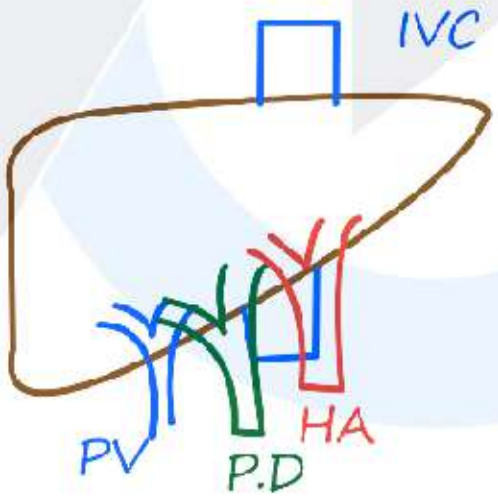

- Recipient liver – cirrhotic

DX TUTORIALS
LOGIN FOR SUCCESS

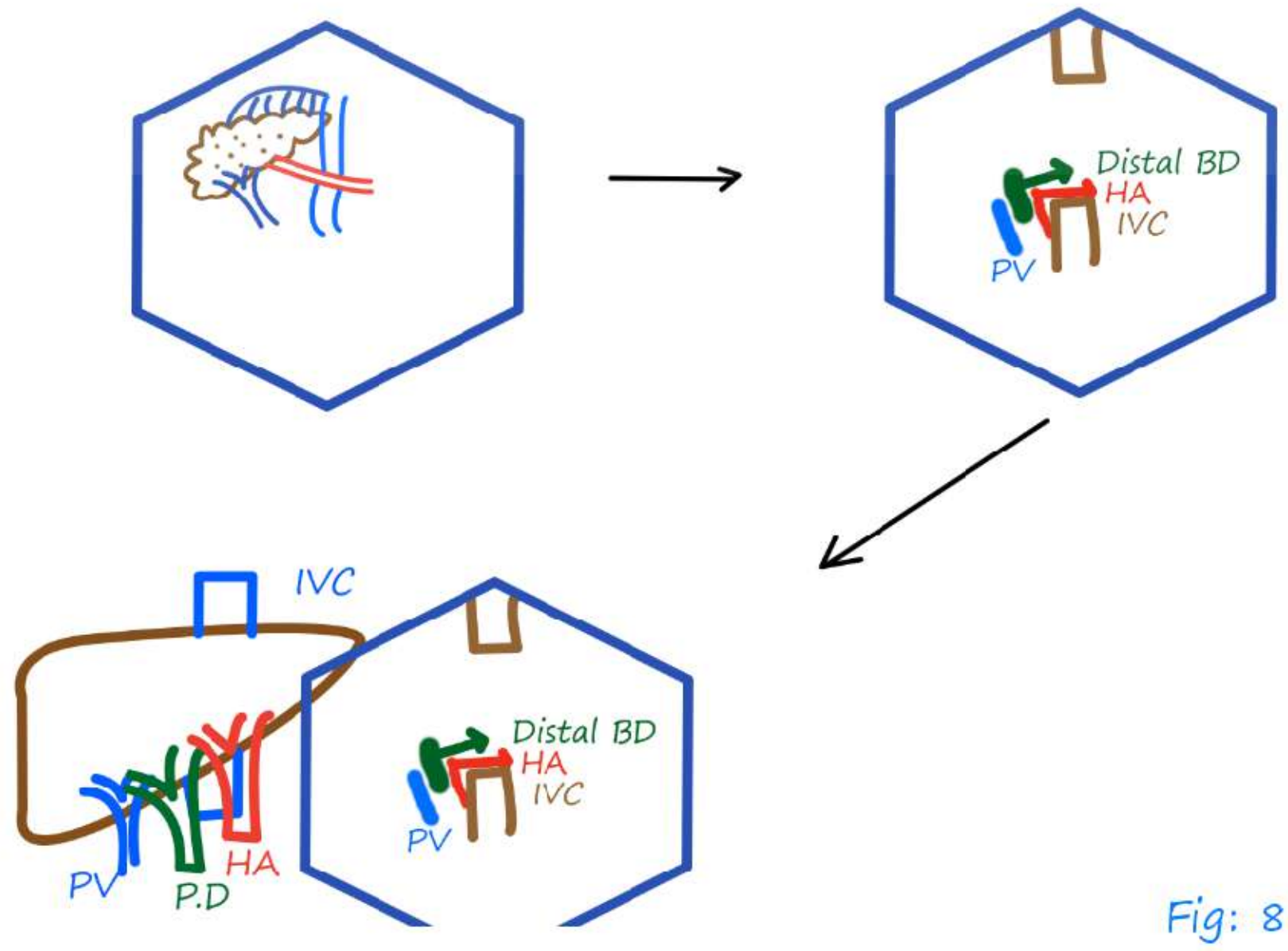

Fig: 8

Anastomosis in following order

1. IVC → supra f/b infra
2. PV anastomosis
3. H.A anastomosis
4. B.D anastomosis

- Following portal vein anastomosis, patient may develop reperfusion syndrome characterized by sudden
  - Hypotension
  - Bradycardia
  - End to End bile duct anastomosis is done
  - Bile duct anastomosis C/I in
    - Primary sclerosing cholangitis
    - EHBA

↓

Bile duct anastomosed with Roux en Y jejunum loop

AfraTafreeh.com
TUTORIALS
LOGIN FOR SUCCESS



Fig: 9

Piggy Back Anastomosis

- Only recipient liver removed
- Donor liver with IVC anastomosed with recipient IVC.

AfraTafreeh.com

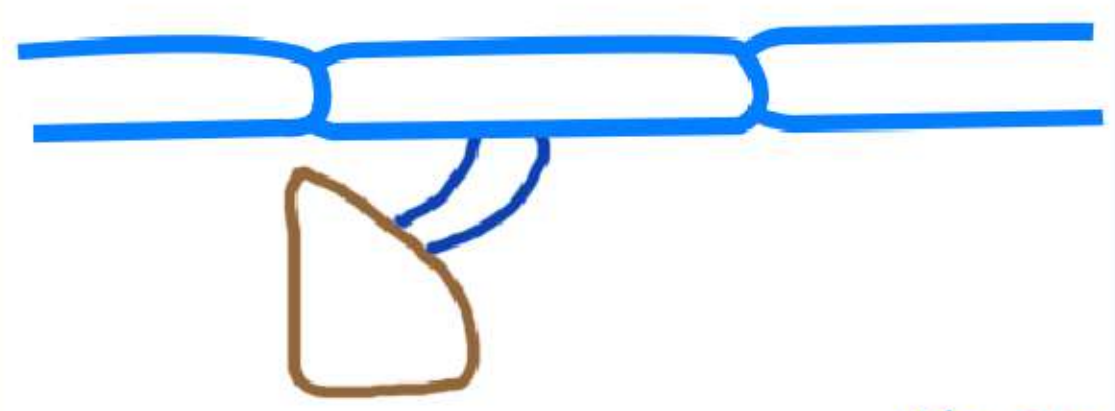

Fig: 10

- Hemodynamically stable

Rejections 00:29:51

Rejections

Hyperacute (days)
↓
Rare/not happens

Acute (1-6 months)
↓
- H.A thrombosis
↓
Immediately Re-transplant
- PV thrombosis
↓
No re-transplant advised

Chronic (>6 months)
↓
Vanishing bile duct syndrome

TUTORIALS LOGIN FOR SUCCESS

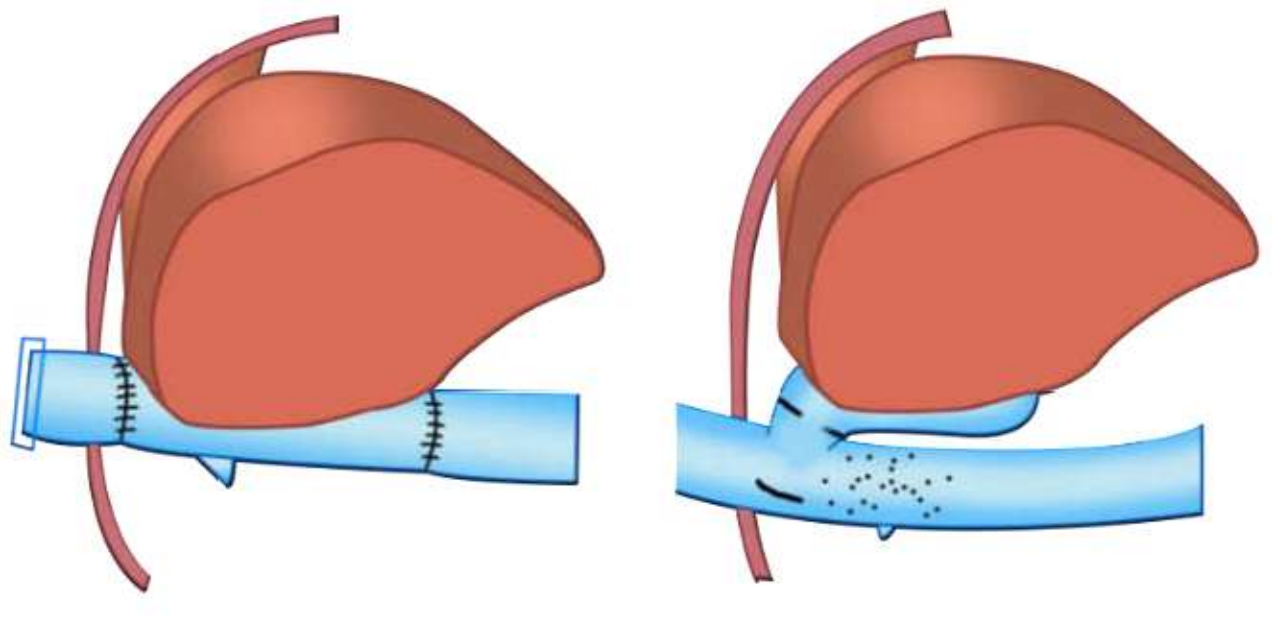

Fig: 11

Renal Transplant 00:37:20

- Most common cause – Renal failure d/t diabetic Nephropathy (adults)
- Most common cause (children) – Chronic glomerulonephritis
- Heterotopic graft → kept in right iliac fossa (or) Left iliac fossa

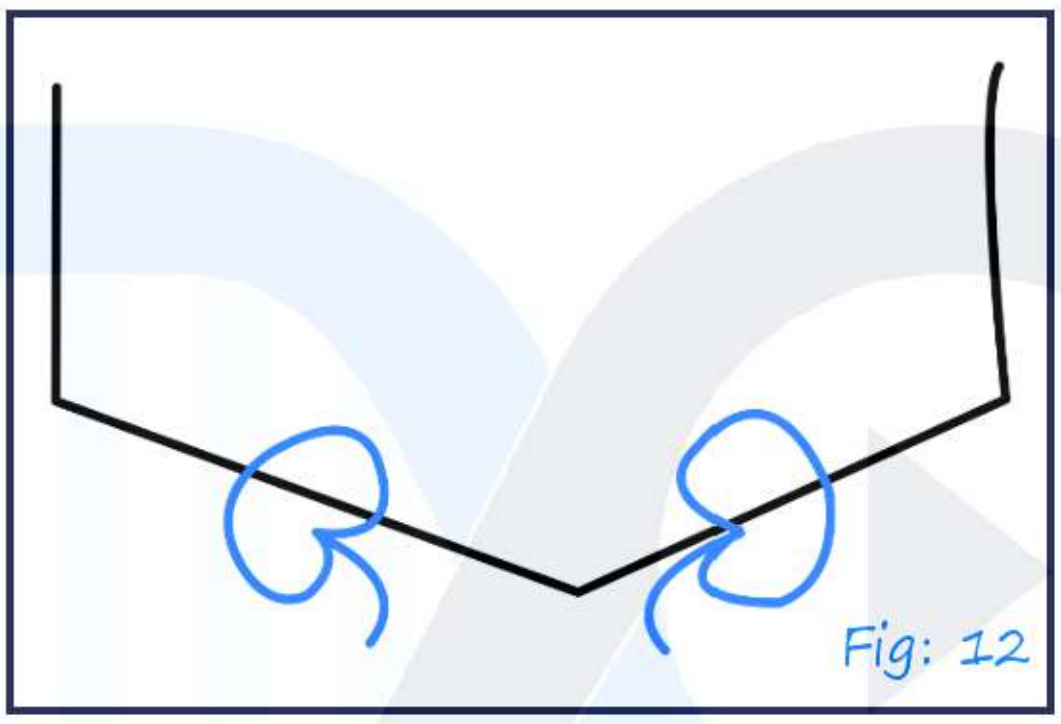

Fig: 12

AfraTafreeh.com

- Cadaveric — right side most common
  live donor
  ↓
  Left kidney because left renal vein is long

TUTORIALS LOGIN FOR SUCCESS

Donor criteria 00:39:39

- 18-70 years
- BMI <35
- No cancer
- No active sepsis
- Kidney – normally function
- ABO/HLA matching

AfraTafreeh.com

Clinical for donor

- BMI > 40
- DM ⊕
- Malignancy
- HIV +, sepsis ⊕
- RFT – GFR <70
  Albuminuria
  HTN
- Horse shoe kidney
- Kidney stones

Procedure 00:42:01

- Ureter will be anastomosed with bladder.

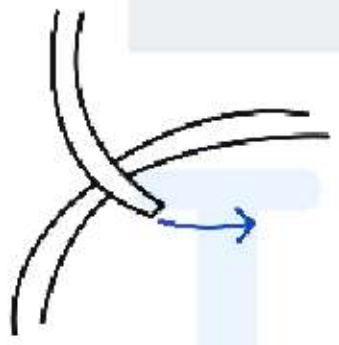

Short tunnel technique → Lich Gregoir
↓
Most common done, best

Long tunnel technique → lead better
politano

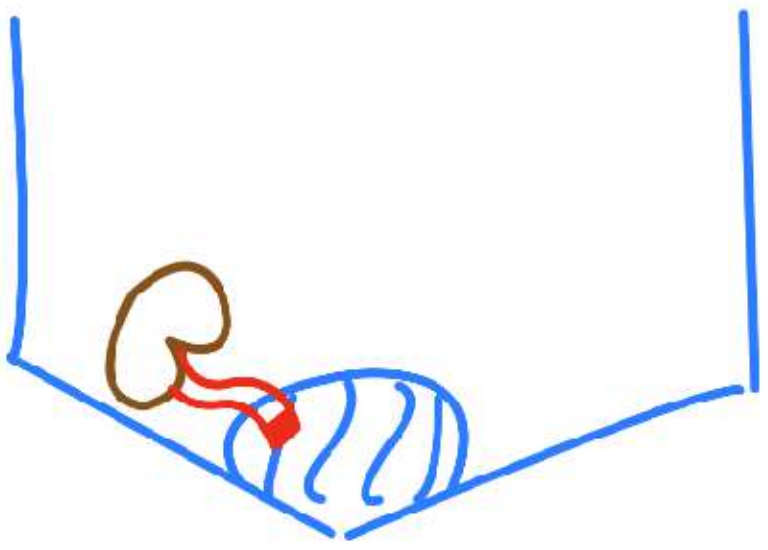

DOC TUTORIALS
LOGIN FOR SUCCESS



Renal vein anastomosed with common iliac vein

↓

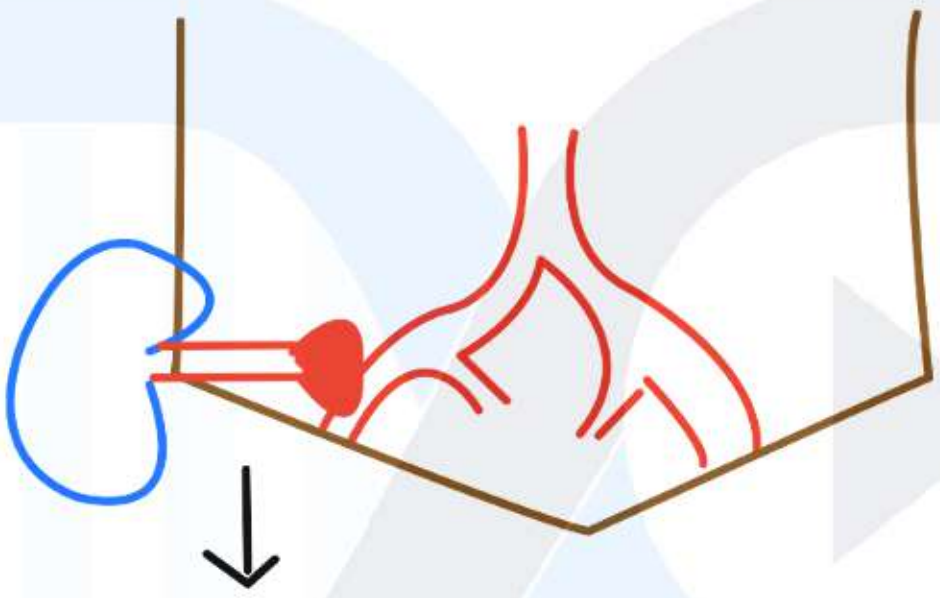

↓

End to End anastomosis with internal iliac artery

↓

Renal artery stenosis is more common with live donor renal transplant

AfraTafreeh.com
DOC TUTORIALS
LOGIN FOR SUCCESS

Complications 00:47:40

Complications

Donor

↓

Most common – urinary retention & paralytic ileus

Recipient

↓

- Haemorrhage
- Renal vein thrombosis (1-5%)
- Renal artery thrombosis (1%)
- Renal artery stenosis (1-23%)
  - → Hypertension

AfraTafreeh.com

- Viral infection
- Bacterial infection
- Lymphocele

– Polyoma BK virus → ureteric strictures

- Allograft Dysfunction → BANFF classification
- Risk factors for chronic rejection of kidney
  ↓
  – HLA mismatch
  – H/O acute rejection
  – Long cold ischemic time
  – CMV ⊕
  – Increases Blood lipids
  – Poor compliance immunosuppression

Other Rare Transplants 00:51:53

Intestine

- Most common indication → short bowel syndrome

Children	**Adults**
↓	↓
Gastroschisis	Acute SMA
Mid gut volvulus	ischemia

- TPN failure is the most common indication of small intestine transplant
  ↓

i. TPN – liver failure

ii. TPN – CV thrombosis

iii. TPN - >2 infections

iv. Frequent dehydration

v. Single fungal line infections

- SB needed → Donor

Cadaveric donor	Live donor	Xenograft
↓ - Isolated SB - SB + liver (most common done) - Multivisceral T_x ↓ SB + Stomach + liver ± colon - Modified multivisceral T_x ↓ Liver is not included	↓ 150-200 cm of ileum ICA/ICV	↓ Pigs

- Body weight of donor – 50-75% of recipient

AfraTafreeh.com
TUTORIALS
LOGIN FOR SUCCESS

AfraTafreeh.com

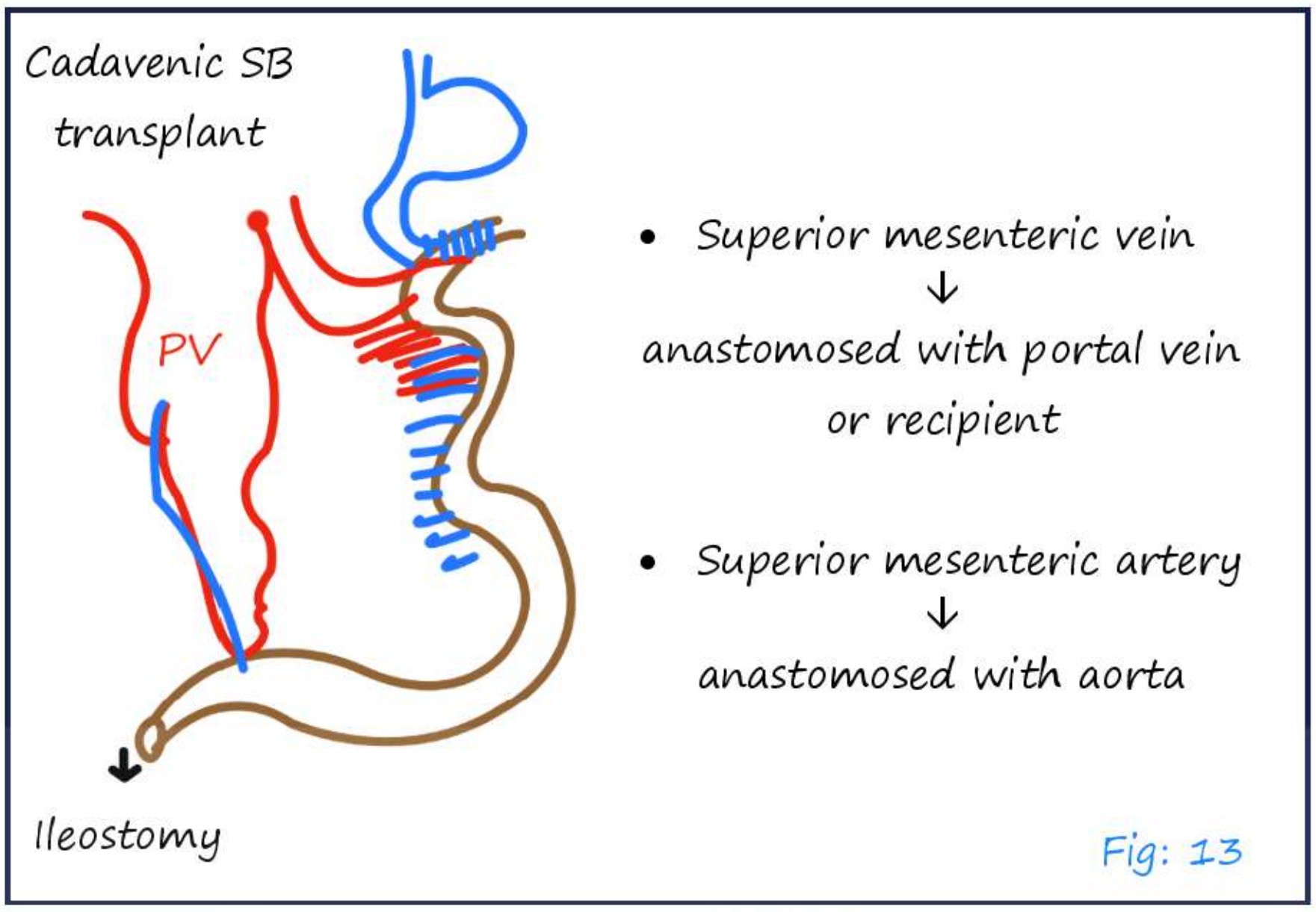

Fig: 13

- Rejection – Highest chance of rejection (70–80%)
  ↓
  Fever, pain, Increases stool output
  – Ileoscopy & B_x to look for rejection.
- GVHD – most common → 0–14%

TUTORIALS
LOGIN FOR SUCCESS

New markers

- Stool for calprotectin
  Stool for citrulline
- Post-transplant lymphoproliferative disorder (PTLD)
  ↓
  10–20%
- Most common complication (70–90%) → Bacterial infection

Extra Edge point 00:62:12



↓

Better prognosis

combined liver + SB

- Most common cause of death – infection (sepsis)
- Most common cause of graft loss – sepsis

Pancreas 01:03:22

- Done by Kelly & Lillehei
- Donor age group: 10-45 years
- Only cadaveric donor
- Most common complication – Graft thrombosis

Types

SPK (80%) ↓ Simultaneous pancreas & kidney

PTA (15%) ↓ Pancreatic T_x alone



PAK ↓ Pancreas after kidney T_x



AfraTafreeh.com
DOC TUTORIALS
LOGIN FOR SUCCESS

AfraTafreeh.com

Better survival
85%-1 year
survival rate

- Indications
  - Type I – (SDDM) → C-peptide deficiency
  - Type II → C-peptide < 2ng/ml
- **Contraindications for donor**
  - Type I DM
  - Pancreatic surgery
  - Chronic pancreatitis
  - IPMN

TUTORIALS
LOGIN FOR SUCCESS

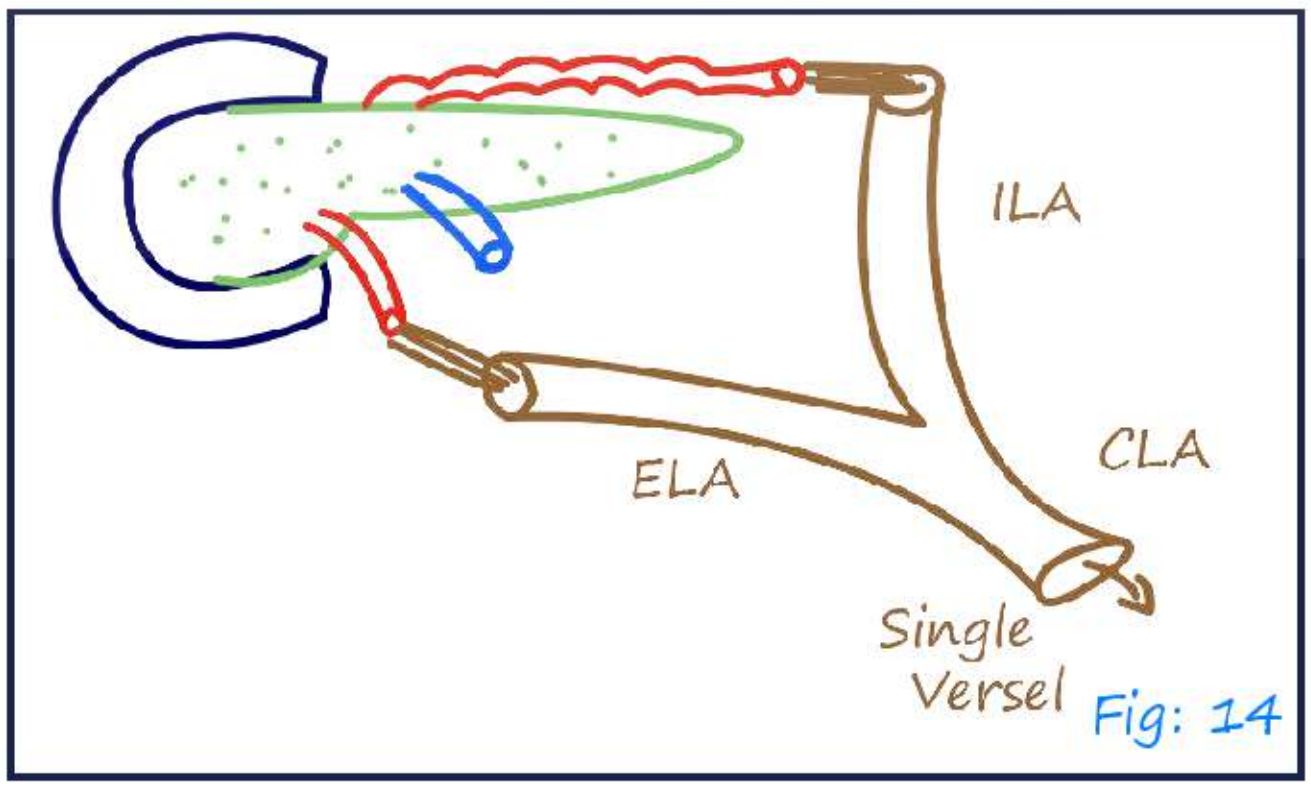

Fig: 14

- In pancreas, we have to do arterial anastomosis

Venous anastomosis

- 'C' shaped duodenum is anastomosed with bowel

↓

Enteric drainage (most common)

↓

- Physiological drainage
- No increase of infection
- No UTI

Disadvantage: – leaks ⊕

- Duodenum anastomosed with bladder

- Urinary amylase can be monitored

↓

Decreased → early rejection can be diagnosed

- Advantages – leak rate is less.
- Disadvantages – Urethritis, UTI

metabolic acidosis

- Most common cause of graft failure – Graft thrombus (SMB>artery)

↓

Pancreas removed

DOC TUTORIALS
LOGIN FOR SUCCESS
AfraTafreeh.com

AfraTafreeh.com

- Most common cause of death – CVS causes
- Other causes of rejection

  ↓

  - Leak
  - Bleeding
  - Infection
  - Necrosis
  - Abscess

Islet cell T_x 01:12:50

- 8000-10,000 Islets/kg of body weight needed to make a patient insulin free

  → 4 donor pancreas

  ↓

  Islets separated and injected into portal vein

  ↓

  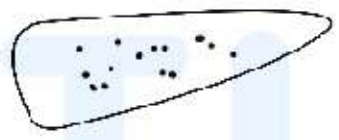 → Insulin

  Complications → Bleeding

  PV thrombosis

- Edmonton protocol
  - Steroids not used
  - IL-2 antibodies are used

Heart Transplant 01:15:19

- Always orthotopic
- Most common cause – Ischemic dilated cardiomyopathy

- Structures preserved → Atrial cuff
  - Aorta
  - SVC
  - IVC
  - Pulmonary a
- Anastomosis –
  - i. Left atrial cuff
  - ii. SVC/IVC
  - iii. Aorta
  - iv. Pulmonary artery

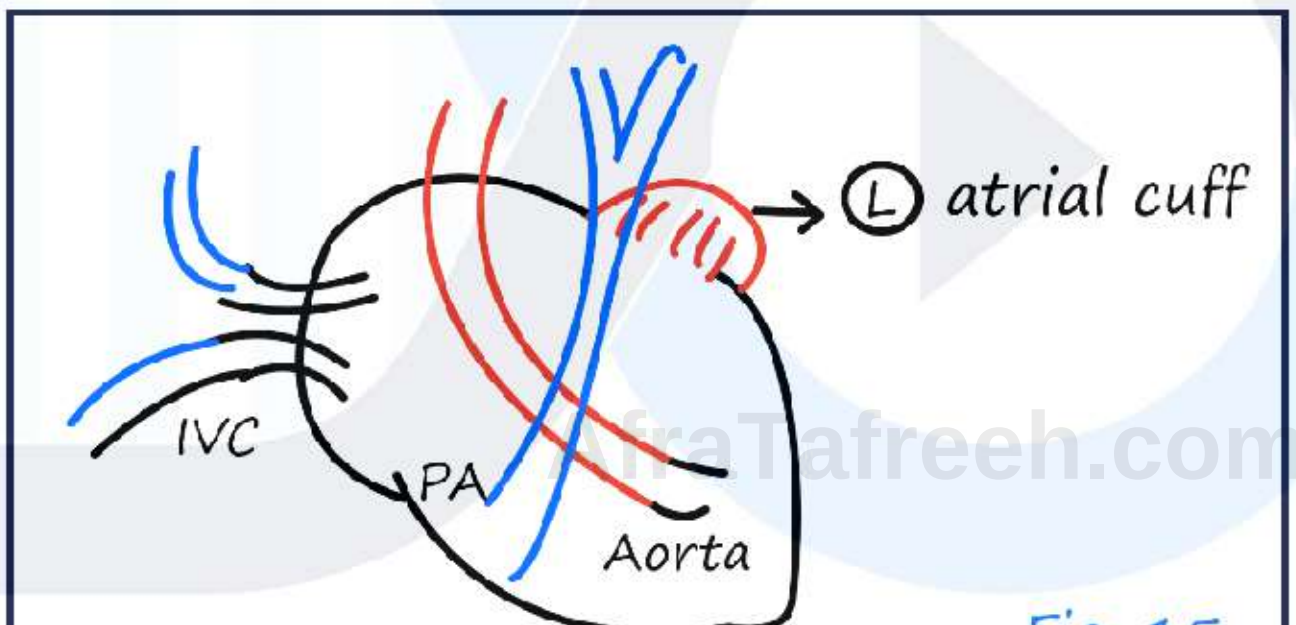

Fig: 15

- 1st heart transplant – Bernard

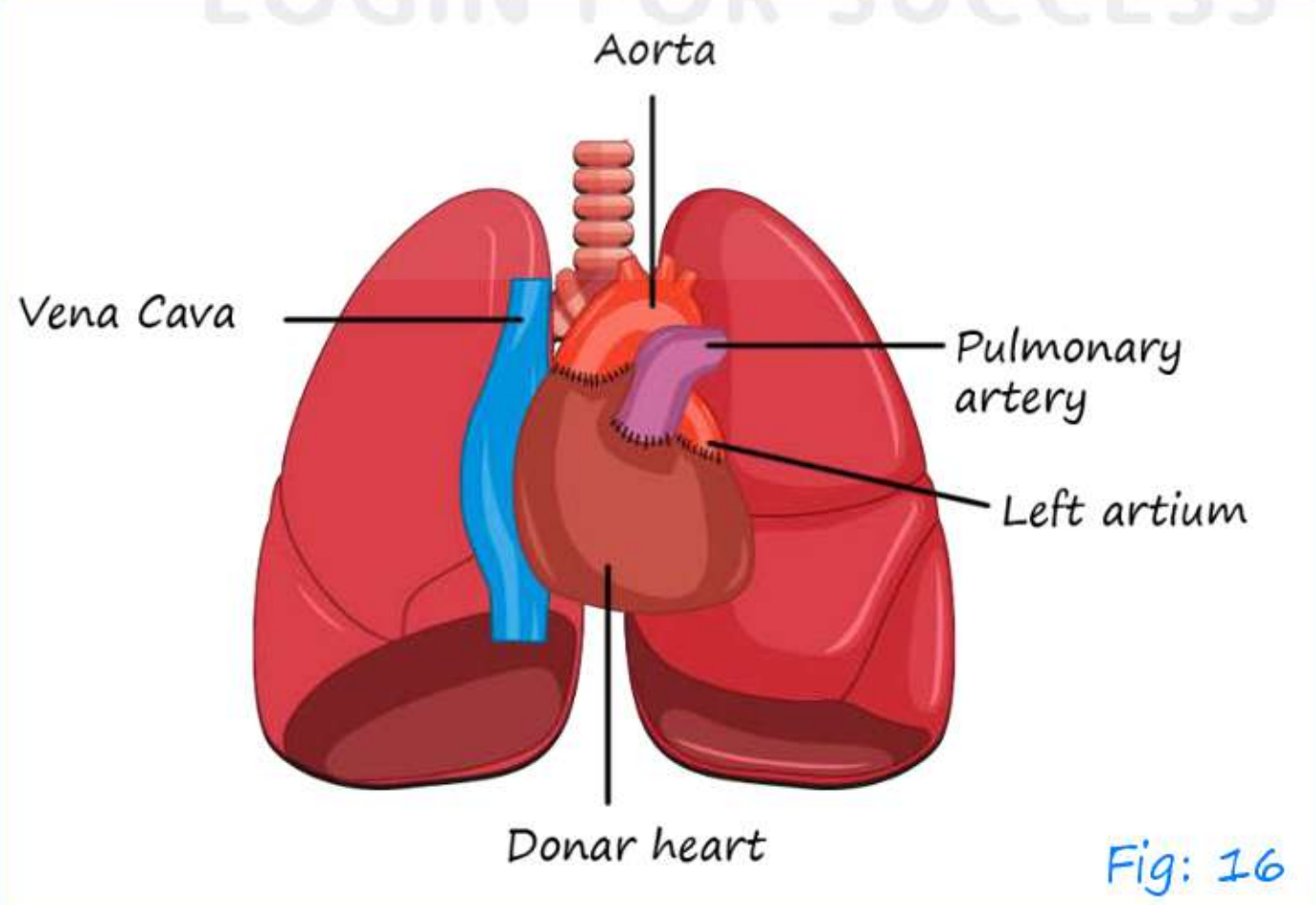

Fig: 16